



Human Osteology

Third Edition

Tim D. White
Michael T. Black
Pieter A. Folkens



HUMAN OSTEOLOGY

This page intentionally left blank

HUMAN OSTEOLOGY

Third Edition

Tim D. White

*Human Evolution Research Center (HERC), and
Department of Integrative Biology
University of California
Berkeley, California*

Michael T. Black

*Phoebe A. Hearst Museum of Anthropology
University of California
Berkeley, California*

Pieter A. Folkens

*AHP Media Group
Benicia, California*



Amsterdam • Boston • Heidelberg • London • New York • Oxford
Paris • San Diego • San Francisco • Singapore • Sydney • Tokyo



Acquisitions Editor: Liz Brown
Editorial Project Manager: Kristi Anderson
Marketing Manager: Kristin Banach
Composition: A Higher Porpoise Design Group
Cover/Interior Printer: RR Donnelley

Academic Press is an imprint of Elsevier
30 Corporate Drive, Suite 400, Burlington, MA 01803, USA
525 B Street, Suite 1800, San Diego, California 92101-4495, USA
The Boulevard, Langford Lane, Kidlington, Oxford, OX5 1GB, UK

© 2012 ELSEVIER INC. All rights reserved.

Text and images: © 2011 Tim D. White, Michael T. Black, & Pieter A. Folkens

Front cover photograph: Adult male skull, B-139 (mirror imaged), Spencer R. Atkinson Library of Applied Anatomy, University of the Pacific, Arthur A. Dugoni School of Dentistry

No part of this publication may be reproduced or transmitted in any form or by any means, electronic or mechanical, including photocopying, recording, or any information storage and retrieval system, without permission in writing from the publisher. Details on how to seek permission, further information about the Publisher's permissions policies and our arrangements with organizations such as the Copyright Clearance Center and the Copyright Licensing Agency, can be found at our website: www.elsevier.com/permissions.

This book and the individual contributions contained in it are protected under copyright by the Publisher (other than as may be noted herein).

Notices

Knowledge and best practice in this field are constantly changing. As new research and experience broaden our understanding, changes in research methods, professional practices, or medical treatment may become necessary.

Practitioners and researchers must always rely on their own experience and knowledge in evaluating and using any information, methods, compounds, or experiments described herein. In using such information or methods they should be mindful of their own safety and the safety of others, including parties for whom they have a professional responsibility.

To the fullest extent of the law, neither the Publisher nor the authors, contributors, or editors, assume any liability for any injury and/or damage to persons or property as a matter of products liability, negligence or otherwise, or from any use or operation of any methods, products, instructions, or ideas contained in the material herein.

Library of Congress Cataloging-in-Publication Data
Application submitted

British Library Cataloguing-in-Publication Data
A catalogue record for this book is available from the British Library.

ISBN: 978-0-12-374134-9

For information on all Academic Press publications
visit our Web site at www.elsevierdirect.com

Printed in China
11 12 13 9 8 7 6 5 4 3 2 1

Working together to grow
libraries in developing countries

www.elsevier.com | www.bookaid.org | www.sabre.org

ELSEVIER | BOOK AID International | Sabre Foundation

CONTENTS

Preface

Preface to the Third Edition	xxi
Preface to the Second Edition	xxiii
Preface to the First Edition	xxv

Chapter 1

Introduction	1
1.1 Human Osteology	1
1.2 A Guide to the Text	2
1.3 Teaching Osteology	5
1.4 Resources for the Osteologist	6
1.5 Studying Osteology	6
1.6 Working with Human Bones	7
Suggested Further Readings	8

Chapter 2

Anatomical Terminology	11
2.1 Planes of Reference	11
2.2 Directional Terms	13
2.2.1 General	13
2.2.2 Hands and Feet	14
2.2.3 Teeth	14
2.3 Motions of the Body	15
2.3.1 General	15
2.3.2 Hands and Feet	16
2.4 General Bone Features	16
2.4.1 Projections and Parts	16
2.4.2 Depressions and Openings	17
2.5 Useful Prefixes and Suffixes	18
2.6 Anatomical Regions	21
2.7 Shape-related Terms	22
Suggested Further Readings	23

Chapter 3

Bone Biology and Variation 25

3.1	Variation	25
3.2	A Few Facts about Bone	27
3.3	Bones as Elements of the Musculoskeletal System	28
3.4	Gross Anatomy of Bones	32
3.5	Molecular Structure of Bone	35
3.6	Histology and Metabolism of Bone	35
3.7	Bone Growth	37
3.8	Morphogenesis	39
3.9	Bone Repair	40
	Suggested Further Readings	42

Chapter 4

Skull: Cranium and Mandible 43

4.1	Handling the Skull	51
4.2	Elements of the Skull	51
4.3	Growth and Architecture, Sutures and Sinuses	52
4.4	Skull Orientation	54
4.5	Craniometric Landmarks	54
4.5.1	Unpaired (Midline) Craniometric Landmarks	55
4.5.2	Paired Craniometric Landmarks	58
4.6	Learning Cranial Skeletal Anatomy	59
4.7	Frontal	60
4.7.1	Anatomy	60
4.7.2	Growth	63
4.7.3	Possible Confusion	63
4.7.4	Siding	63
4.8	Parietals	64
4.8.1	Anatomy	64
4.8.2	Growth	66
4.8.3	Possible Confusion	66
4.8.4	Siding	66
4.9	Temporals	67
4.9.1	Anatomy	67
4.9.2	Growth	70
4.9.3	Possible Confusion	70
4.9.4	Siding	70
4.10	Auditory Ossicles	71
4.11	Occipital	71
4.11.1	Anatomy	71
4.11.2	Growth	74
4.11.3	Possible Confusion	74
4.11.4	Siding	75
4.12	Maxillae	75
4.12.1	Anatomy	75
4.12.2	Growth	77
4.12.3	Possible Confusion	77
4.12.4	Siding	77

4.13	Palatines	78
4.13.1	Anatomy	78
4.13.2	Growth	79
4.13.3	Possible Confusion	79
4.13.4	Siding	79
4.14	Vomer	79
4.14.1	Anatomy	79
4.14.2	Growth	80
4.14.3	Possible Confusion	80
4.14.4	Siding	80
4.15	Inferior Nasal Conchae	81
4.15.1	Anatomy	81
4.15.2	Growth	81
4.15.3	Possible Confusion	81
4.15.4	Siding	81
4.16	Ethmoid	82
4.16.1	Anatomy	82
4.16.2	Growth	83
4.16.3	Possible Confusion	83
4.16.4	Siding	83
4.17	Lacrimals	83
4.17.1	Anatomy	83
4.17.2	Growth	84
4.17.3	Possible Confusion	84
4.17.4	Siding	84
4.18	Nasals	84
4.18.1	Anatomy	84
4.18.2	Growth	84
4.18.3	Possible Confusion	85
4.18.4	Siding	85
4.19	Zygomatics	85
4.19.1	Anatomy	85
4.19.2	Growth	86
4.19.3	Possible Confusion	86
4.19.4	Siding	86
4.20	Sphenoid	87
4.20.1	Anatomy	87
4.20.2	Growth	91
4.20.3	Possible Confusion	91
4.20.4	Siding	91
4.21	Mandible	91
4.21.1	Anatomy	91
4.21.2	Growth	95
4.21.3	Possible Confusion	95
4.21.4	Siding	95
4.22	Measurements of the Skull: Craniometrics	96
4.22.1	Cranial Measurements	96
4.22.2	Cranial Indices	97
4.23	Cranial Nonmetric Traits	97
4.24	Mastication	99
	Suggested Further Readings	99

Chapter 5

Teeth	101
5.1 Dental Form and Function	102
5.2 Dental Terminology	103
5.3 Anatomy of a Tooth	104
5.4 Dental Development	107
5.5 Tooth Identification	109
5.6 To Which Category Does the Tooth Belong?	110
5.6.1 Incisors	110
5.6.2 Canines	112
5.6.3 Premolars	112
5.6.4 Molars	112
5.7 Is the Tooth Permanent or Deciduous?	112
5.7.1 Diagnostic Criteria	112
5.7.2 Special Cases	112
5.8 Is the Tooth an Upper or a Lower?	114
5.8.1 Upper versus Lower Incisors	114
5.8.2 Upper versus Lower Canines	114
5.8.3 Upper versus Lower Premolars	115
5.8.4 Upper versus Lower Molars	116
5.9 What is the Position of the Tooth?	116
5.9.1 Upper Incisors: I ¹ versus I ²	116
5.9.2 Lower Incisors: I ₁ versus I ₂	117
5.9.3 Upper Premolars: P ³ versus P ⁴	117
5.9.4 Lower Premolars: P ₃ versus P ₄	118
5.9.5 Upper Molars: M ¹ versus M ² versus M ³	119
5.9.6 Lower Molars: M ₁ versus M ₂ versus M ₃	120
5.10 Is the Tooth from the Right or the Left Side?	121
5.10.1 Upper Incisors	121
5.10.2 Lower Incisors	121
5.10.3 Upper Canines	122
5.10.4 Lower Canines	123
5.10.5 Upper Premolars	123
5.10.6 Lower Premolars	123
5.10.7 Upper Molars	123
5.10.8 Lower Molars	124
5.11 Dental Measurements: Odontometrics	126
5.12 Dental Nonmetric Traits	127
Suggested Further Readings	127

Chapter 6

Hyoid and Vertebrae	129
6.1 Hyoid	129
6.1.1 Anatomy	129
6.1.2 Growth	130
6.1.3 Possible Confusion	130
6.1.4 Siding	130
6.1.5 Hyoid Measurements	130
6.1.6 Hyoid Nonmetric Traits	130
6.2 General Characteristics of Vertebrae	131

6.2.1	Anatomy	131
6.2.2	Growth	135
6.3	Cervical Vertebrae	136
6.3.1	Anatomy and Identification	136
6.3.2	Special Cervical Vertebrae	136
6.3.3	Siding	139
6.4	Thoracic Vertebrae	139
6.4.1	Anatomy and Identification	139
6.4.2	Special Thoracic Vertebrae	142
6.4.3	Siding	142
6.5	Lumbar Vertebrae	143
6.5.1	Anatomy and Identification	143
6.5.2	Identifying Lumbar Position	143
6.5.3	Siding	143
6.6	Vertebral Measurements	146
6.7	Vertebral Nonmetric Traits	146
6.8	Functional Aspects of the Vertebrae	147

Chapter 7

Thorax: Sternum and Ribs 149

7.1	Sternum	149
7.1.1	Anatomy	149
7.1.2	Growth	151
7.1.3	Possible Confusion	151
7.1.4	Siding	151
7.1.5	Sternal Measurements	152
7.1.6	Sternal Nonmetric Traits	152
7.2	Ribs	153
7.2.1	Anatomy	153
7.2.2	Special Ribs	156
7.2.3	Growth	156
7.2.4	Possible Confusion	156
7.2.5	Siding	156
7.2.6	Costal Measurements	157
7.2.7	Costal Nonmetric Traits	158
7.3	Functional Aspects of the Thoracic Skeleton	159

Chapter 8

Shoulder Girdle: Clavicle and Scapula 161

8.1	Clavicle	161
8.1.1	Anatomy	161
8.1.2	Growth	163
8.1.3	Possible Confusion	164
8.1.4	Siding	164
8.1.5	Clavicular Measurements	164
8.1.6	Clavicular Nonmetric Traits	165
8.2	Scapula	165
8.2.1	Anatomy	165
8.2.2	Growth	170

8.2.3	Possible Confusion	171
8.2.4	Siding	172
8.2.5	Scapular Measurements	172
8.2.6	Scapular Nonmetric Traits	173
8.3	Functional Aspects of the Shoulder Girdle	174

Chapter 9

Arm: Humerus, Radius, and Ulna 175

9.1	Humerus	175
9.1.1	Anatomy	175
9.1.2	Growth	181
9.1.3	Possible Confusion	181
9.1.4	Siding	181
9.1.5	Humeral Measurements	183
9.1.6	Humeral Nonmetric Traits	184
9.2	Radius	184
9.2.1	Anatomy	184
9.2.2	Growth	188
9.2.3	Possible Confusion	188
9.2.4	Siding	189
9.2.5	Radial Measurements	190
9.2.6	Radial Nonmetric Traits	190
9.3	Ulna	191
9.3.1	Anatomy	191
9.3.2	Growth	195
9.3.3	Possible Confusion	195
9.3.4	Siding	196
9.3.5	Ulnar Measurements	196
9.3.6	Ulnar Nonmetric Traits	197
9.4	Functional Aspects of the Elbow and Wrist	197

Chapter 10

Hand: Carpals, Metacarpals, & Phalanges 199

10.1	Carpals	202
10.1.1	Scaphoid	202
10.1.2	Lunate	203
10.1.3	Triquetral	204
10.1.4	Pisiform	204
10.1.5	Trapezium	205
10.1.6	Trapezoid	206
10.1.7	Capitate	206
10.1.8	Hamate	207
10.1.9	Growth	208
10.1.10	Possible Confusion	208
10.1.11	Carpal Measurements	208
10.1.12	Carpal Nonmetric Traits	208
10.2	Metacarpals	209
10.2.1	First Metacarpal (Thumb)	209
10.2.2	Second Metacarpal	209

10.2.3	Third Metacarpal	209
10.2.4	Fourth Metacarpal	209
10.2.5	Fifth Metacarpal	213
10.2.6	Growth	213
10.2.7	Possible Confusion	214
10.2.8	Siding	214
10.2.9	Metacarpal Measurements	214
10.2.10	Metacarpal Nonmetric Traits	215
10.3	Hand Phalanges	215
10.3.1	Proximal Hand Phalanges	216
10.3.2	Intermediate Hand Phalanges	216
10.3.3	Distal Hand Phalanges	216
10.3.4	Growth	216
10.3.5	Possible Confusion	216
10.3.6	Siding	216
10.3.7	Manual Phalangeal Measurements	216
10.3.8	Manual Phalangeal Nonmetric Traits	217
10.4	Functional Aspects of the Hand	218

Chapter 11

Pelvis: Sacrum, Coccyx, and Os Coxae 219

11.1	Sacrum	219
11.1.1	Anatomy	219
11.1.2	Growth	223
11.1.3	Possible Confusion	223
11.1.4	Siding	223
11.1.5	Sacral Measurements	225
11.1.6	Sacral Nonmetric Traits	225
11.2	Coccyx	226
11.2.1	Anatomy	226
11.2.2	Coccygeal Measurements	226
11.2.3	Coccygeal Nonmetric Traits	226
11.3	Os Coxae	227
11.3.1	Anatomy	227
11.3.2	Growth	233
11.3.3	Possible Confusion	234
11.3.4	Siding	234
11.3.5	Coxal Measurements	236
11.3.6	Coxal Nonmetric Traits	237
11.4	Pelvis	237
11.4.1	Anatomy	239
11.4.2	Pelvic Measurements	240
11.5	Functional Aspects of the Pelvic Girdle	240

Chapter 12

Leg: Femur, Patella, Tibia, and Fibula 241

12.1	Femur	241
12.1.1	Anatomy	241
12.1.2	Growth	250

12.1.3	Possible Confusion	250	
12.1.4	Siding	250	
12.1.5	Femoral Measurements	250	
12.1.6	Femoral Nonmetric Traits	252	
12.2	Patella		252
12.2.1	Anatomy	252	
12.2.2	Growth	253	
12.2.3	Possible Confusion	253	
12.2.4	Siding	253	
12.2.5	Patellar Measurements	253	
12.2.6	Patellar Nonmetric Traits	254	
12.3	Tibia		254
12.3.1	Anatomy	254	
12.3.2	Growth	261	
12.3.3	Possible Confusion	261	
12.3.4	Siding	261	
12.3.5	Tibial Measurements	261	
12.3.6	Tibial Nonmetric Traits	263	
12.4	Fibula		263
12.4.1	Anatomy	263	
12.4.2	Growth	268	
12.4.3	Possible Confusion	269	
12.4.4	Siding	269	
12.5.5	Fibular Measurements	269	
12.5.6	Fibular Nonmetric Traits	270	
12.4	Functional Aspects of the Knee and Ankle		270

Chapter 13

Foot: Tarsals, Metatarsals, & Phalanges 271

13.1	Tarsals		276
13.1.1	Talus	276	
13.1.2	Calcaneus	277	
13.1.3	Cuboid	280	
13.1.4	Navicular	281	
13.1.5	Medial (First) Cuneiform	281	
13.1.6	Intermediate (Second) Cuneiform	282	
13.1.7	Lateral (Third) Cuneiform	282	
13.1.8	Growth	283	
13.1.9	Possible Confusion	283	
13.1.10	Tarsal Measurements	283	
13.1.11	Tarsal Nonmetric Traits	284	
13.2	Metatarsals		285
13.2.1	First Metatarsal	285	
13.2.2	Second Metatarsal	285	
13.2.3	Third Metatarsal	285	
13.2.4	Fourth Metatarsal	285	
13.2.5	Fifth Metatarsal	285	
13.2.6	Growth	290	
13.2.7	Possible Confusion	290	
13.2.8	Siding	290	
13.2.9	Metatarsal Measurements	290	
13.2.10	Metatarsal Nonmetric Traits	291	

13.3	Foot Phalanges	291
13.3.1	Proximal Foot Phalanges	292
13.3.2	Intermediate Foot Phalanges	292
13.3.3	Distal Foot Phalanges	292
13.3.4	Growth	292
13.3.5	Possible Confusion	292
13.3.6	Siding	293
13.3.7	Pedal Phalangeal Measurements	293
13.3.8	Pedal Phalangeal Nonmetric Traits	294
13.4	Functional Aspects of the Foot	294

Chapter 14

Anatomical and Biomechanical Context 295

14.1	Anatomical Conventions	295
14.2	Biomechanical Conventions	296
14.3	Interpreting the Figures	297
14.4	Cranium and Mandible	299
14.5	Clavicle	301
14.6	Humerus	303
14.7	Radius	305
14.8	Ulna	307
14.9	Os Coxae	309
14.10	Femur	311
14.11	Tibia	313
14.12	Fibula	315

Chapter 15

Field Procedures for Skeletal Remains 317

15.1	Search	318
15.2	Discovery	318
15.3	Excavation and Retrieval	319
15.4	Transport	328
	Suggested Further Readings	329

Chapter 16

Laboratory Procedures and Reporting 331

16.1	Setting	331
16.2	Stabilization	332
16.3	Preparation	333
16.3.1	Preparing Archaeological Bones	333
16.3.2	Preparing Forensic Bones	334
16.3.3	Preparing Fossilized Bones	334
16.4	Restoration	336
16.5	Sorting	337
16.6	Metric Acquisition and Analysis	339
16.6.1	Traditional Osteometric Tools	339
16.6.2	Analysis	341

16.7	Photography	345
16.7.1	Equipment	345
16.7.2	Exposure and Film (or other Recording Media)	346
16.7.3	Lighting and Setup	348
16.7.4	Legal and Ethical Considerations	348
16.8	Radiography	349
16.9	Microscopy	350
16.10	Molding and Casting	351
16.11	Computing	352
16.12	Reporting	352
16.13	Curation	355
	Suggested Further Readings	355

Chapter 17

Ethics in Osteology **357**

17.1	Ethics and the Law	357
17.2	Respecting the Dead: Appropriate Individual Behavior	358
17.3	Speaking for the Dead: Ethics in Forensic Osteology	358
17.3.1	Boundaries of Evidence	359
17.3.2	The Expert Witness	359
17.4	Caring for the Dead: Considerations in the Curation of Remains	361
17.5	Custody of the Dead: “Repatriation” and the U.S. Native American Graves Protection and Repatriation Act	362
17.5.1	Ethics in Collision: Respecting the Living	362
17.5.2	NAGPRA: Context, History, and Intent	365
17.5.3	The Future	367
17.6	Ethics in Human Paleontology	374
17.7	Relevant Codes of Ethics and Ethical Statements	375
	Suggested Further Readings	376

Chapter 18

Assessment of Age, Sex, Stature, Ancestry, and Identity of the Individual **379**

18.1	Accuracy, Precision, and Reliability of Determinations	380
18.2	From Known to Unknown: Using Standard Series	381
18.3	Estimation of Age	381
18.3.1	Estimating Subadult Age from Teeth	385
18.3.2	Estimating Adult Age from Teeth	387
18.3.3	Estimating Adult Age from Cranial Suture Closure	389
18.3.4	Estimating Subadult Age from Long-bone Length	391
18.3.5	Estimating Subadult Age from Epiphyseal Closure	391
18.3.6	Estimating Adult Age from the Pubic Symphyseal Surface	394
18.3.7	Parturition Changes at the Pubic Symphysis	397
18.3.8	Estimating Adult Age from the Auricular Surface of the Ilium	400
18.3.9	Estimating Adult Age from the Sternal Rib End	404
18.3.10	Estimating Adult Age by Radiographic Analysis	405
18.3.11	Estimating Adult Age from Bone Microstructure	405
18.3.12	Multifactorial Age Estimation	406

18.4	Determination of Sex	408
18.4.1	Sexing the Skull Using Overall Robusticity	412
18.4.2	Sexing the Mandible	414
18.4.3	Sexing the Teeth	415
18.4.4	Sexing the Postcranial Skeleton	415
18.5	Estimation of Stature	418
18.6	Estimation of Ancestry	421
18.7	Identifying the Individual	425
	Suggested Further Readings	426

Chapter 19

	Osteological and Dental Pathology	429
19.1	Description and Diagnosis	430
19.1.1	Description	431
19.1.2	Diagnosis	432
19.2	Skeletal Trauma	433
19.2.1	Fracture	433
19.2.2	Dislocation	436
19.2.3	Vascular Disruption	437
19.2.4	Artificially Induced Shape Changes	437
19.3	Congenital Disorders	439
19.3.1	Cranial Malformations	439
19.3.2	Vertebral Malformations	439
19.3.3	Other Congenital Malformations	440
19.4	Circulatory Disorders	440
19.4.1	Osteochondritis Dissecans	440
19.4.2	Legg-Calvé-Perthes Disease	440
19.5	Joint Diseases	441
19.5.1	Osteoarthritis	441
19.5.2	Diffuse Idiopathic Skeletal Hyperostosis (DISH)	443
19.5.3	Rheumatoid Arthritis	443
19.5.4	Ankylosing Spondylitis	443
19.6	Infectious Diseases and Associated Manifestations	443
19.6.1	Bacterial Infections	444
19.6.2	Other Infections	447
19.7	Metabolic Diseases	447
19.7.1	Vitamin-D-related Syndromes	447
19.7.2	Scurvy	447
19.7.3	Osteoporosis	447
19.7.4	Poisoning	448
19.8	Endocrine Disorders	448
19.8.1	Pituitary Disorders	448
19.8.2	Other Glandular Disorders	448
19.9	Hematopoietic and Hematological Disorders	448
19.9.1	Red Blood Cell Disorders (Anemias)	448
19.9.2	White Blood Cell Disorders	450
19.10	Skeletal Dysplasias	450
19.10.1	Achondroplasia	450
19.10.2	Osteogenesis Imperfecta	450
19.10.3	Fibrodysplasia Ossificans Progressiva	452
19.10.4	Other Skeletal Dysplasias	452

19.11 Neoplastic Conditions	452
19.11.1 Osteomata (Osteomas)	452
19.11.2 Primary Malignant Bone Tumors	453
19.11.3 Osteochondromas	453
19.11.4 Fibrosarcomas (Fibroblastic Sarcomas)	453
19.11.5 Other Neoplastic Conditions	454
19.12 Diseases of the Dentition	454
19.12.1 Periodontal Disease	454
19.12.2 Caries	455
19.12.3 Enamel Hypoplasia	456
19.12.4 Dental Calculus	456
19.12.5 Artificial Dental Modification	456
19.13 Musculoskeletal Stress Markers	457
Suggested Further Readings	458

Chapter 20

Postmortem Skeletal Modification	459
20.1 Bone Fracture	460
20.2 Bone Modification by Physical Agents	462
20.2.1 Chemistry	462
20.2.2 Rock, Earth, and Ice	463
20.2.3 Abrasion	464
20.2.4 Fire	464
20.3 Bone Modification by Nonhuman Biological Agents	464
20.3.1 Nonhuman Animals	464
20.3.2 Plants	466
20.4 Bone Modification by Humans	466
20.4.1 Cut Marks, Chop Marks, and Scrape Marks	468
20.4.2 Percussion Marks	468
20.4.3 Projectiles	472
Suggested Further Readings	473

Chapter 21

The Biology of Skeletal Populations: Discrete Traits, Distance, Diet, Disease, and Demography	475
21.1 Nonmetric Variation	476
21.1.1 Dental Nonmetric Variation	478
21.1.2 Cranial Nonmetric Variation	479
21.1.3 Postcranial Nonmetric Variation	479
21.2 Estimating Biological Distance	480
21.3 Diet	482
21.3.1 Dental Macrowear and Microwear	482
21.3.2 Caries and Calculus	483
21.3.3 Chemical Analyses	483
21.4 Disease and Demography	485
Suggested Further Readings	489

Chapter 22

Molecular Osteology	491
22.1 Sampling	491
22.2 DNA	493
22.2.1 PCR and methodology	493
22.2.2 Contamination	493
22.2.3 Taphonomy of DNA	494
22.2.4 Applications	494
22.3 Amino Acids	496
22.4 Isotopes	496
Suggested Further Readings	497

Chapter 23

Forensic Case Study—Homicide: “We have the Witnesses but No Body”	499
23.1 A Disappearance in Cleveland	500
23.2 Investigation	500
23.3 Inventory	500
23.4 Identification	501
23.5 Conclusion	504

Chapter 24

Forensic Case Study—Child Abuse, the Skeletal Perspective	507
24.1 Child Abuse and the Skeleton	507
24.2 A Missing Child Found	508
24.3 Analysis	508
24.4 The Result	512

Chapter 25

Archaeological Case Study—The Bioarchae- ology of the Stillwater Marsh, Nevada	513
25.1 Background	513
25.2 Geography of the Carson Sink	514
25.3 Exposure and Recovery	515
25.4 Analysis	516
25.5 Affinity	517
25.6 Osteoarthritis	517
25.7 Limb Shaft Cross-Sectional Anatomy	518
25.8 Physiological Stress	519
25.9 Dietary Reconstruction	519
25.10 The Future	519

Chapter 26

**Archaeological Case Study—Anasazi
Remains from Cottonwood Canyon 521**

26.1	Cannibalism and Archaeology	521
26.2	Cottonwood Canyon Site 42SA12209	522
26.3	Discovery	523
26.4	Analysis	524
26.4.1	Patterns of Damage	524
26.4.2	Sorting and Refitting	524
26.4.3	Minimum Number, Age and Sex of the Individuals	527
26.5	What Happened? The Osteological Contribution	529

Chapter 27

**Paleontological Case Study—The Pit
of the Bones 533**

27.1	Atapuerca	534
27.2	Discovery	535
27.3	Recovery	536
27.4	Paleodemography	538
27.5	Paleopathology	538
27.6	Functional and Phylogenetic Assessment	540
27.7	Continuing Mysteries	540

Chapter 28

**Paleontological Case Study—“Ardi,” the *Ardi-
pithecus ramidus* Skeleton from Ethiopia 541**

28.1	Background	541
28.2	Finding Fossils	543
28.3	The Geography, Geology, and Geochronology of Aramis	545
28.4	Discovering “Ardi”	546
28.5	Recovering “Ardi”	549
28.6	Restoring “Ardi”	554
28.7	Documenting “Ardi”	555
28.8	Studying “Ardi”	555
28.9	Publishing “Ardi”	557

Appendix 1	
Imaging Methodology	559
Appendix 2	
A Decision Tree (“Key”) Approach to Tooth Identification	563
Appendix 3	
Online Resources for Human Osteology	573
Glossary	577
Bibliography	593
Index	633

This page intentionally left blank

PREFACE TO THE THIRD EDITION

MUCH HAS HAPPENED during the two decades since the first edition of this book. We have the benefit of innumerable comments from a generation of students and instructors who have used the text to learn and to teach. Their helpful suggestions improved the second edition and drove the evolution of this third edition.

The number of osteological features presented in this edition has increased to make it a more comprehensive reference for human skeletal anatomy. All anatomical terminology has been revised to reflect the latest standards in international anatomical terminology, most importantly the *Terminologia Anatomica* (Federative Committee on Anatomical Terminology, 1998).

CT scans of all major long bones have been added (taken from the bones of the same individual used to illustrate the postcrania). These will help readers become familiar with the cross-sectional characteristics of these elements. These are incorporated into a new chapter with color anatomical plates designed to assist the student in understanding the relationship between bony morphology and soft-tissue anatomy.

Additional detail on the timing of appearance and fusion of primary and secondary centers of ossification has been added. A section on nonmetric traits has been added to each of the descriptive chapters, as well as sections illustrating and defining measurements most commonly used in human osteology.

A new case study has been added, describing the entire process entailed in a major paleoanthropological discovery; in this case, that of the first skeleton of *Ardipithecus ramidus*. A new appendix has been added that offers students an alternative method for identifying isolated teeth.

The glossary has been enlarged with cross-references, acronyms, and many new terms. The chapter on anatomical terminology has been enriched with information on the Latin and Greek roots of many morphological terms. The index has been greatly enlarged and restructured to facilitate the use of this book as a reference volume.

Many thanks to the students who painstakingly proofread multiple revisions of the manuscript, greatly improving the book. In particular, thanks go to Caitlin Ibarra, Alex Levin, and Colleen Young for their work on the rough drafts of chapters. Ben Mersey and Sabrina Sholts checked the final drafts for consistency and accuracy. Josh Carlson deserves special thanks for coordinating these proofreading efforts and for extensive bibliographic scholarship and figure layout. Leslea Hlusko provided assistance with a new section on dental development, and Owen Lovejoy provided assistance on bone biology. Henry Gilbert was instrumental in developing and adapting the graphics and photographic content of the new “Ardi” case study chapter. David DeGusta provided helpful suggestions for revising the chapter on molecular osteology. Socorro Báez was the source of many valuable suggestions for improving the chapter on osteological and dental pathology.

Lyman Jellema has provided pivotal assistance in each of the editions of this book. He and Yohannes Haile-Selassie were generous and flexible in arranging for CT scanning and additional photography. The micro-CT scans of long bones were taken by Andrew Burghardt of the Musculoskeletal Quantitative Imaging Research Group, in the Department of Radiology and Biomedical Imaging at U.C. San Francisco. Thanks to Dorothy Dechant at the Institute of Dental History and Craniofacial Study, Spencer R. Atkinson Library of Applied Anatomy, University of the Pacific, Arthur A. Dugoni School of Dentistry for providing permissions, assistance, and specimens used to illustrate this book.

Tari Broderick, Nancy Maragioglio, Liz Brown, Renske van Dijk, and Kristi Anderson at Elsevier all played instrumental roles in making this book possible, and we thank them all. We would also like to offer thanks to the staff of the Phoebe A. Hearst Museum of Anthropology for their support and patience.

Finally, a huge debt of gratitude is due to Natasha Johnson (wife of MTB). Without her unflagging motivation, love, support, and assistance over the past four years, this edition would not have been possible. Thank you.

Tim D. White
Michael T. Black
Pieter A. Folkens

PREFACE TO THE SECOND EDITION

WITH NEARLY A DECADE of advances in osteological research—and the positive response to the first edition—it was time to revise *Human Osteology*. This revision was driven by colleagues and students who found the first volume valuable and called for “more and better.” We have strengthened and updated each chapter, added a host of new figures, tables, and features, and incorporated new standards. Among the advances are a new glossary and new sections on morphogenesis, bone modification, and disease and demography. The chapter on assessing age, sex, stature, ancestry, and identity has been greatly strengthened, and an occupation section has been added to the paleopathology chapter. A new chapter on molecular osteology and four new case studies have been added.

Many of our colleagues contributed excellent suggestions for revision. We have tried to incorporate as many as were feasible. In particular, we thank those authors who wrote published reviews, as well as Susan Antón, Donna Boyd, Kristian Carlson, Mark Fleishman, David Frayer, Marie Geise, Haskel Greenfield, Mark Griffin, Rebecca Keith, Murray Marks, Debra Martin, David Mills, Mary Ellen Morbeck, Robert Paine, John Verano, and Richard Wilkinson. We obviously couldn't add all the things that all the users and reviewers requested, but we have done our best to honor all the good advice from these colleagues.

The most important contributor to the completion of the second edition was David DeGusta. His research and writing skills are apparent throughout, and he contributed much of the new chapter on molecular osteology. As with the first edition, Lyman Jellema was tireless in tracking down the bones to illustrate the new growth sections, and we sincerely appreciate his professionalism, kind assistance, and attention to detail (Lyman even sent cat toys to prevent the felid *Lubaka* from chewing on specimens). Susan Chin helped to construct the glossary and the guide to electronic resources in osteology. Clark Larsen, Phil Walker, and Juan Luis Arsuaga contributed background and photographs of their work featured in the new case studies, and Robert Paine contributed new photographs in Chapter 3. Gene Hammel helped with demographic questions, Henry Gilbert helped with figures, and José Miguel Carretero provided critical observations on the hand skeleton. Alan Shabel was a skilled and tireless proofreader. Thanks again go to the students in Berkeley's “Osteo U” for all their critical observations and helpful suggestions that made this a better book.

Tim D. White
Pieter A. Folkens

This page intentionally left blank

PREFACE TO THE FIRST EDITION

ANATOMISTS, FORENSIC SCIENTISTS, osteologists, paleontologists, and archaeologists frequently encounter human remains in their work. These remains are used by such researchers to investigate both the recent and the ancient past. For these scholars, an illustrated human osteology book represents an important tool for identification and analysis in both field and laboratory.

In the educational setting, memorizing the name of each bone in the human skeleton is easily accomplished. Each year thousands of students prove this in introductory anatomy and physical anthropology courses. This book is intended to serve as a text for students who wish to advance their osteological skills beyond this level — to be able to accurately identify isolated and fragmentary skeletal remains, and to use these remains to learn something about the individuals represented by only bones and teeth.

Recent professional literature suggests that some students of physical anthropology have misinterpreted the de-emphasis of “traditional” osteometric methods — that they have mistakenly concluded that basic identification no longer has an important role in the field. This book puts great emphasis on the identification of bones and teeth. Such identification is fundamental to students and professionals in paleontological, archaeological, and forensic contexts. Basic identification of element, side, and taxon is a prerequisite to further interpretive analysis in all three settings. In this text, we devote attention to these basics while attempting to provide introduction and access to the wide range of modern work on the human skeleton.

I (T. W.) do not consider myself a human osteologist in the traditional sense of the word. My interests are more archaeological and paleontological. I wrote this book after teaching a decade's worth of introductory human osteology classes at the University of California at Berkeley. For many of those years I supplemented Bass's text (1987 and earlier editions) with a variety of other books and papers. With this background, I concluded that my notes, handouts, and experience could be added to information available in a number of other sources and distilled into a single text for use in a one-semester college course on human osteology.

It is essential that instructors secure skeletal remains to use in teaching osteology. The two-dimensional images in this textbook should prove valuable in instruction and learning. They have been carefully crafted to show a maximum amount of anatomical information. These photographs cannot, however, substitute for work with the actual bones and teeth. For students to derive the most knowledge from this book they should have access to a minimum of one articulated adult human skeleton, one complete disarticulated adult skeleton, one child's skeleton, and a variety of fragmentary human bones. It should be understood that this is a bare minimum, and it is recommended that students be introduced to a much wider range of skeletal materials during their study. If archaeological material is to be used in instruction, it is essential that *every* piece be individually labeled and that the bone be solid enough to withstand heavy handling.

Whatever success Pieter Folkens and I have achieved in developing a useful book we owe largely to the approximately 175 students who met the challenge of weekly laboratory examinations and exhaustive midterms in what one class described as “Osteo U.” Gary Richards was a graduate of the first class in osteology that I taught. He has served as a teaching associate in most of the others. Thanks are extended to him for the hard work, patience, and talent he devoted to the class.

A number of colleagues have made this book possible. William Woodcock at Academic Press first suggested the text. Academic Press editor John Thomas made it readable, and Linda Shapiro, Kerry Pinchbeck, Lisa Herider, Nancy Olsen, and Chuck Arthur saw it through to completion. Gene Hammel and M. J. Tyler of the Department of Anthropology provided the initial Macintosh that made it possible, and Apple Computer's generous grant to the Institute of Human Origins assisted in the preparation of the text. Bruce Latimer and Lyman Jellema of the Cleveland Museum of Natural History helped us to obtain the Hamann-Todd postcranial skeleton illustrated here. Mitchell Day assisted in providing specimens for illustrations from the University of the Pacific School of Dentistry's Atkinson Cranio-Osteological Collection of the A. W. Ward Museum, and Jane Becker and Gary Thodas of that institution provided assistance in extending this loan. Susan Antón and Gary Richards provided invaluable assistance in obtaining material from the University of California Lowie Museum of Anthropology collections. Their curatorial work on these collections, as well as support of this work by the National Science Foundation, is gratefully acknowledged. Kent Lightfoot of Berkeley's Archaeological Research Facility provided assistance with records and photographs (15.3–15.6). Betty Clark of Berkeley's Cowell Hospital assisted in providing the radiographs used in the text. Thanks go to Bob Jones of U.C. Berkeley's Museum of Vertebrate Zoology for removing the grease from the illustrated skeleton. Andrew Mackenzie, Michael Black, and Richard May assisted in choosing Lowie Museum specimens used to illustrate variation. Larissa Smith of the Institute of Human Origins helped with translations. Clark Larsen provided helpful critical comments on an early draft of the manuscript. Yoel Rak and Bill Kimbel critically reviewed Chapter 4, improving it considerably. Owen Lovejoy, Bruce Latimer, and Scott Simpson thoroughly reviewed later drafts of the book, providing innumerable corrections, clarifications, and valuable suggestions. Walter Hartwig read the page proofs. The students in U.C. Berkeley's Introduction to Human Osteology, Fall 1986, 1987, 1988, and 1990 classes, deserve special mention for commenting extensively on drafts of this text. Special thanks go to Jeni McKeighen for editorial and indexing assistance. We thank all of these reviewers for their contributions to the book and take full responsibility for any errors of fact that made it past this set of dedicated readers. Ray Wood and Thomas Holland of the University of Missouri provided advice on specimen photography. Bill Pack generously offered his photographic studio and his expertise, and LuAnn Taylor and Todd Telander gave valued assistance during photographic sessions. Film processing and printing were accomplished by the good people at GAMMA Photographic Labs of San Francisco. Larry Zimmerman, Douglas Ubelaker, George Gill, and Owen Lovejoy kindly granted permission to reprint their photographs and drawings, and Scott Simpson provided much help in obtaining illustrative material. Thanks go to the Harry Frank Guggenheim Foundation for support of research conducted by T. W. in parallel with this book. Generous assistance with the case studies was provided by D. C. Johanson, Bill Kimbel, Berhane Asfaw, Gen Suwa, and Gerald Eck (Olduvai); by Jerry Fetterman (Cottonwood Canyon); and by Owen Lovejoy and Scott Simpson (Cleveland Homicide). These workers took valuable time from their ongoing research efforts in order to round out the book by sharing their unique photographs, insights, and experience.

Tim D. White
Pieter A. Folkens

Chapter 1

INTRODUCTION

BONES HAVE BEEN ENTOMBED for millions of years in sediments left by ancient lakes, swamps, and rivers that once dotted Ethiopia's Afar Depression. Today, as erosion cuts into these ancient layers, the fossils reach the barren Afar surface, often shattering into small, glistening, multicolored fragments of bone and teeth. Thinly scattered among the osseous and dental remains of thousands of crocodiles, turtles, hippopotami, giraffes, carnivores, baboons, pigs, horses, antelopes, and other animals found in the surface fossil assemblages are the remains of primitive human ancestors. While paleontologists search Afar outcrops for osteological clues about prehistoric human form, archaeologists uncover the osteological remains of the inhabitants of Herculaneum who perished as Mount Vesuvius erupted, burying them with their possessions. On the other side of the globe, anthropologists probe into a recent grave containing skeletal parts that may be those of a Nazi war criminal. And around the world, forensic anthropologists assess the sex and age of recovered remains to help law enforcement officials.

1.1 Human Osteology

A thread that binds these and thousands of other investigations is **human osteology**, the study of human bones. The scientists performing the investigations employ their knowledge of the human skeleton in recovering and interpreting the bones. Outside of anatomical and medical science, there are three main areas in which knowledge of human osteology is often applied. First, osteological work is often aimed at identification of the relatively recently deceased and is usually done in a legal context. This work, which pertains to the public forum, most often a court of law, is called **forensic osteology**, a division of forensic anthropology. The other two contexts in which human osteological knowledge is commonly applied are historical. The context can be ancient and purely **paleontological**, as with the Pliocene pre-cultural hominids of Africa. Alternatively, the context can be relatively recent, part of an **archaeological** record. For example, human bones in the Aztec centers of Mexico were chronicled just a few hundred years ago by the Spanish during the "conquest" of Mexico. Osteological analysis of materials from such cultural contexts is routinely undertaken as part of archaeological research. Archaeologists concentrate on cultural residues of former human occupations, but they stand to gain a great deal of valuable information from the skeletal remains of the ancient inhabitants. It has recently become fashionable to refer to the study of human remains from archaeological contexts as "**bioarchaeology**." However, human skeletal parts are only a small part of the biological remains characterizing most archaeological sites — indeed, most archaeological sites lack human remains altogether!

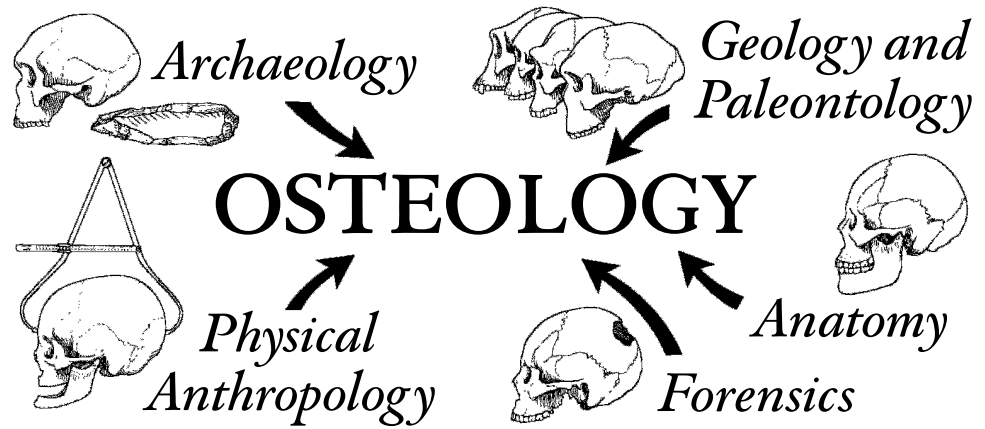


Figure 1.1 Osteology and associated scientific disciplines.

The information that human or protohuman remains can provide makes the recovery of bones a critically important activity. Skeletal anatomy (including teeth) reflects the combined action of genes and environment. The skeleton forms the framework for the body, whereas the teeth form a direct interface between the organism and its environment. Bones can carry in their shape, or **morphology**, the signature of soft tissues with which they were associated during life — tissues including muscles, ligaments, tendons, arteries, nerves, veins, and organs. These soft tissues usually disappear soon after death. The skeleton, however, often preserves evidence of the former existence and nature of many of these other body parts.

Because the bones and teeth of the skeleton are resistant to many kinds of decay, they often form the most lasting record of an individual's existence. It is possible to estimate an individual's age, sex, and stature from the bones and teeth. Study of the skeleton often makes it possible to discern a variety of pathologies from which the individual may have suffered. Analysis of groups of individuals may offer insights into prehistoric population structure, biological affinities, cultural behaviors, and patterns of disease. The evolutionary history of humanity itself is being read from the fossil record — a record comprising mostly teeth and bones. Figure 1.1 illustrates the place of osteology in relation to other scientific disciplines.

1.2 A Guide to the Text

The goal of **forensic** osteology often involves identification of an unknown individual. The process of personally identifying the remains of the recently dead individual is called **individuation**. To narrow the possibilities, the forensic osteologist first ascertains whether the remains are human and then begins to explore the individual characteristics, such as age, sex, and stature, comparing these variables in the hope of obtaining an exclusive match with what is known about the missing individual. Human osteologists working in **archaeological** contexts usually cannot perform such personal identification. Rather, their concerns lie with characteristics of the individual and with the insights that skeletal remains of many individuals, representing biological populations, might provide on diet, health, biological affinity, and population history. Osteologists working in a **paleontological** context (and note that many fossils of Pliocene and Pleistocene

age are found in archaeological contexts) are interested in using the normally rare fossil remains of human ancestors and other relatives to learn all these things and also to discern evolutionary relationships.

Skeletal remains can provide meaningful clues about the recent and the ancient past to all these investigators. To use these clues, one must master some fundamentals. This book is about those fundamentals.

The most difficult part of writing and revising this book has been choosing among the many things that could have been included in a single volume. The “perfect” osteology book would be a gigantic volume illustrating all stages of skeletal growth, all variations in the adult skeleton, and all skeletal elements of all mammals that might be confused with a human. It would cover bone histology, skeletal embryology and morphogenesis, and biomechanics. The volume would contain bibliographic references to all papers published in osteology and would include full accounts of every skeletal measurement and identification technique published and all applicable tables. But given the constraints of format, production, and cost, our goal was to produce a single text that is simultaneously accessible to the college student and useful to the practicing professional osteologist. Scheuer and Black’s 2000 and 2004 volumes are excellent companions to this book. They present extensive illustrations of immature human skeletal remains.

A book such as this cannot possibly do justice to the large body of professional literature on human osteology available in other books and in journals such as the *American Journal of Physical Anthropology*, *Journal of Human Evolution*, *Journal of Dental Research*, *Human Biology*, *Paleopathology Newsletter*, and the *International Journal of Osteoarchaeology*. Rather than reprint the data found in these primary sources, and in secondary compilations such as Krogman and İşcan (1986) and Bennett (1993), we have built pathways to them. Our “**Suggested Further Readings**” sections briefly introduce samples of books and professional papers that the reader seeking further details on each chapter topic might consult. All of these references, as well as those cited in the chapter texts, are included in the bibliography at the end of the book. Neither the suggested further readings nor the bibliography attempts to be comprehensive. Instead, these sources were compiled to provide the professional with an orientation to the primary literature and to give the student a set of sound departure points for further study in human osteology and related topics. This approach is intended to encourage all users of the book to directly consult the original literature in the acquisition and application of osteological knowledge. Through this direct approach, advanced students will achieve a better understanding of the nature of original research in human osteology and a firsthand familiarity with the results of this research.

In this book we focus on the first two basic questions that any human osteologist must answer about a bone or collection of bones whether in a forensic, archaeological, or paleontological context:

- **Are the bones human?**
- **How many individuals are present?**

Whether the context is forensic, archaeological, or paleontological, these questions usually must be answered before further analysis is possible. This manual, a guide to human osteology, emphasizes the anatomy of the human skeleton. The skeletal remains of some other animals, particularly when fragmentary, are often difficult to distinguish from human bones and teeth. Although there are no general differences that ensure effective sorting between human and non-human bones, the first step in answering the question of whether the bones are human is to become familiar with the human skeleton in all of its many variations in shape and size. France (2009) illustrates whole bones of mammals most often confused with humans, but this confusion rarely involves whole bones. Fragmentary nonhuman remains are more problematic and are encountered more frequently. Once a familiarity with the range, or envelope, of variation characterizing the modern human species is achieved, further work in comparative osteology of both extinct and extant mammals becomes a much easier task. With further comparative work comes more experience, and with that experience the osteologist is better able to make the basic identifications required.

Information on determining the age, sex, stature, and identity of skeletonized individuals is provided in later chapters of the book. These second-level questions and many others, including those about biomechanical capability, phylogenetic relationships, and geographic affinities, however, can be answered accurately only after the elements and individuals have been identified correctly. Too often the first, basic identifications are overlooked or hastily performed, and thus any succeeding analyses are built on weak foundations.

We conclude this introductory chapter by considering some advice on methods and techniques for studying, learning, and teaching human osteology. In Chapter 2 we introduce anatomical terminology—the vocabulary of osteology that is essential in the scientific study of bony and dental tissues. Chapter 3 is an introduction to bone as a tissue. Skeletal growth is introduced here, along with a presentation of the major internal structure and functions of bones, teeth, and joints. The critical topic of intraspecific variation (variation within a species) is discussed and its various sources are identified and illustrated.

Chapters 4–13 form the core of the book. In these chapters we consider one anatomical region at a time, beginning with the bones of the skull. A separate chapter and format are employed for the dentition. We introduce Chapters 4–13 with brief accounts of the phylogenetic history of the body segment(s) and osteological elements described in the chapter. This approach sets the osteological elements in a broad evolutionary framework. These introductory statements are mostly drawn from the excellent functional human anatomy text by Cartmill, Hylander, and Shafland (1987), and the interested reader may pursue further details there and in other comparative texts such as Jarvik (1980) and Shubin (2009).

In the descriptive chapters (4–13), each bone is shown individually, in various views, by means of photographs and, when possible, CT (computerized tomographic) sections. For ease of comparison, the scale for all individual bones is natural size, whereas teeth are shown twice natural size. For paired bones, only the right side is shown unless otherwise indicated. Orientations for the articulated crania are standard, and other bones are illustrated in orientations showing the most anatomy. For example, the “anterior view” of the frontal bone is a photograph of the anterior surface of that bone. Because our focus is on external morphology, and because the dimension of depth is sacrificed when depicting bones and teeth on the printed page, we developed new methods to illustrate osteological form. Our goal was to accurately portray external morphology while minimizing the confusing stains, translucency, and shine found in natural bones and teeth. Details of the preparation and photography of these specimens are given in Appendix 1.

Human osteology texts often depict human skeletons and their elements as if they were interchangeable. Sets of illustrations often provide little or no visual information on the relative sizes of different parts of the skeleton. Furthermore, bones are often unscaled and/or derived from several individuals in such illustrations. This sacrifices additional information on proportionality and fosters misguided typological thinking. To remedy this situation, we chose the skeleton of a single individual to illustrate all the elements of the postcranial skeleton. All postcranial elements shown in the descriptive chapters of this book are from a single modern human individual, Hamann-Todd specimen number 857, a 24-year-old black male who stood 5'7" tall (170 cm) and weighed 138 lb (62.6 kg). This skeleton was chosen for its relatively few unusual features (noted in the captions for each element), completeness, and excellent preservation. Articulated cranial and all dental specimens illustrated in Chapters 4 and 5 are of recent Mesoamerican origin, and the disarticulated bones of the cranium are all from a single modern individual from Southern Asia. Note that these cranial bones are from a 16-year-old individual whose age allowed the bony elements to be disarticulated and shown intact. This young individual had not fully developed all the markers of cranial robusticity illustrated by the articulated skull.

Each descriptive chapter is organized systematically. The element is first named and its articulations identified. Under the “**Anatomy**” section for each element, the major parts and osteologically significant features of each element are identified in **bold** typeface and described.

The function and soft tissue relations for most structures are identified in *italic* typeface. It is not our intention to give a complete listing of muscle origins and insertions. Instead, we provide

data on soft tissue to make functional sense of bony features while reinforcing the reality of bone as an integral part of the musculoskeletal system. Readings cited at the end of Chapter 3 include human anatomy texts that the student may wish to obtain as companions to this one. Students interested in pursuing soft tissue anatomy are urged to consult these books.

Ossification of each element is briefly considered in the descriptive chapters under a section called “**Growth**.” Further details on development of various elements are presented in Chapter 18. The “**Possible Confusion**” and “**Siding**” sections provide information to complement the illustrations and allow effective identification of isolated and fragmentary skeletal elements. The “**Nonmetric Traits**” sections identify and describe the characters most widely used in human osteology, traits largely drawn from Buikstra and Ubelaker (1994), Finnegan (1978), and Pietrusewsky (2002), and present some additional variants not traditionally considered as nonmetric traits. The “**Measurements**” sections provide definitions and techniques employed in gathering metric data from human skeletal remains (largely following Martin, 1928, and Buikstra and Ubelaker, 1994, but also incorporating Arensburg, 1991; Bass, 1995; Bush et al., 1983; Dauber and Feneis, 2007; Flander, 1978; Gómez-Olivencia, et al., 2009; Howells, 1973; Latimer and Ward, 1993; McCown and Keith, 1939; Moore-Jansen and Jantz, 1994; O’Higgins, et al., 1997; Schwartz, 1995; Steele, 1976; Trinkaus, 2003; Trinkaus and Svoboda, 2006; and Trinkaus et al., 1999).

A color atlas of muscle origins and insertions, ligamentous attachments, and articular surfaces for a selection of major bones is presented in Chapter 14. The attachment sites are shown overlain on the bones of the same individual used to illustrate Chapters 4–13, along with CT scans taken of the major long bones.

In Chapter 15 we consider the discovery and recovery of osteological material. This chapter also covers transport of the remains to the laboratory, primary cleaning of the material, and restoration. In Chapter 16 we trace skeletal material through a variety of analytical techniques, including measurement and photography, and we conclude with a section on the reporting of human osteological remains.

In Chapter 17 we consider ethics in osteology. Chapter 18 is a guide to the assessment of an individual’s age, sex, race, and stature from skeletal remains. In Chapter 19 we consider some of the most common pathologies encountered in human skeletal remains. Chapter 20 is a discussion of **taphonomy**, the study of processes that affect skeletal remains as they move along the often tortuous path between death and curation. In Chapter 21 we address the subject of how the biology of now-dead human populations, particularly the diet, demography, and affinities, might be studied. Chapter 22 covers the rapidly growing field of molecular osteology.

The text then considers six case studies to show how the fundamentals outlined in the first 22 chapters have been applied in very different investigations involving hominid skeletal material. There are two studies each from forensic, archaeological, and paleontological contexts.

Measurements in this book are expressed in the metric system, as is standard in osteology and most modern sciences. Carter (1980) provides a good history of the English and metric systems for students unfamiliar with metric terms or for those who remain unconvinced of the metric system’s utility in modern scientific investigation.

1.3 Teaching Osteology

Instruction in human osteology should begin at the undergraduate level, whether in biology or anthropology. Two of us (TDW and MTB) have found that an intensive, one-semester, upper division course in osteology provides a good foundation for undergraduate and graduate students interested in forensic anthropology, bones in archaeological context, and hominid paleontology. Indeed, courses in these specialty fields prove far more meaningful to students with such a foundation. We have found that students learn best when challenged by frequent examination, when able to access a wide series of original comparative specimens during their studies, and when kept to a rigorous schedule of weekly quizzes and frequent comprehensive exams (with timed identification stations).

This book is topically organized for ease of access by users at all levels. Instructors will have their own preferences for the order of presentation, and the book is organized to allow this. Our personal preference for teaching an introductory human osteology course is to begin with Chapters 1 (introduction) and 2 (terminology), and then proceed directly to Chapters 4 (skull) and 5 (teeth). By covering the skull and dentition chapters early in the semester, the students are continually challenged with the most difficult parts of the skeleton. They work on this for the remainder of the course, thereby maximizing their learning and retention of this information. During the students' laboratory work on the skull and teeth, we cover Chapters 3 (bone biology) and 17 (ethics) and proceed to lecture on recovery and analysis (Chapters 15 and 16), covering the cranial half of Chapter 18 (age, sex, etc.). Case studies are introduced throughout the course. At the midsemester mark we turn to the postcranial skeleton, studying Chapters 6–13 and exploring case studies, population biology (Chapter 21), and molecular osteology (Chapter 22). After the students have mastered basic identification of all elements in the skeleton, the semester finishes up with a look at how paleopathology (Chapter 19) and taphonomy (Chapter 20) extend the morphological envelopes of human skeletal remains. The book and the lectures provide the vocabulary (see the glossary), basic concepts, and references necessary for the student to approach, use, learn, and eventually master the primary professional research literature on human osteology.

1.4 Resources for the Osteologist

The most important single resource for the osteologist is a collection of skeletal remains. Ideally, the laboratory should have a growth series of skeletons of individuals of known age to accompany mounted skeletons of several individuals, as well as element collections in which many individuals of known sex, age, occupation, and pathology are represented. A collection of skeletal remains from a variety of modern nonhuman animals is also very important, as is a cast collection of fossil hominoids. The laboratory should also have a full set of casts of standard comparative sets, such as the ASU dental trait plaques and the Suchey-Brooks pubic symphyseal aging casts. A full set of osteometric instruments is invaluable, as is having access to a radiographic facility for radiographs and CT scans. Access to cadavers for dissection in a human anatomy laboratory is also desirable. Of course, like the ideal textbook, the ideal laboratory can only be approached, never realized.

Beyond the physical plant, proper equipment, and a collection of specimens for analysis and comparison in the laboratory, a key resource for the human osteologist is a comprehensive corpus of publications. A library with comprehensive published resources on forensics, human osteology and anatomy, zooarchaeology, and human paleontology is essential (even smaller libraries can meet this requirement, if they have an active interlibrary loan program). A collaborative community of researchers and students with whom the novice or experienced osteologist can interact completes the ideal setting.

1.5 Studying Osteology

The gulf between knowing the names of elements in an adult skeleton and correctly identifying the taxon, element, and side of an isolated, fragmentary bone or tooth is a wide one. It must often seem to the student that an instructor is performing magic in correctly identifying, for example, a human left upper third premolar. It is, however, far from magic. The ability to identify skeletal material is a skill that can be acquired only through intensive study of actual specimens.

It is not enough to be able to side and identify intact elements, because intact elements are rarely found in field paleontological situations and only sometimes found in archaeological and

forensic contexts. The many hominid specimens “recovered” from faunal collections because they were originally misidentified as nonhominid are ample testimony to many specialists’ superficial knowledge of the skeleton. Even the recently published Neanderthal DNA nuclear genome (Green et al., 2010) came from exactly such originally underidentified fragments. Learning to identify bones and teeth can be slow, painful, and frustrating, but the rewards make the effort worthwhile. The loss of scientific data and the professional embarrassment caused by a misidentification make the effort essential.

A great way to reinforce and extend your learning is to partner with another motivated student and challenge each other with numerous mock quizzes. After you’ve identified a few bones or fragments, using the book and your notes whenever necessary, challenge your partner to identify one of the more difficult pieces in one minute or less, without referring to the book, notes, or other skeletal or comparative material. It’s a great way to identify your weaknesses, to improve upon your skills, and to get accustomed to the fast-paced format of osteological quizzes.

Students may find many techniques useful in learning the skeleton. First, remember that the osteologist always has an intact comparative skeleton close at hand, even in remote field situations—the skeleton embedded in his or her own body. It is useful to visualize and even **palpate** (feel your own bones through the skin) the way in which an isolated skeletal element might “plug into” your own body. This is particularly true for identifying and siding teeth, which are conveniently exposed in the osteologist’s mouth. Never ridicule an osteologist who holds a radius against the right forearm and then shifts it to the left forearm before identifying it; that osteologist will probably side the bone correctly. When identifying the side of any identified skeletal element, all the osteologist has to do is establish three axes (the plural of axis, pronounced ‘*ack-sees*’) in space: top to bottom, side to side, and front to back. Anatomical features of the bone will assist in this, thereby providing the clues necessary for correct identification and orientation.

A second tip for identifying skeletal remains involves hierarchies of decisions. Begin identifying a bone by deciding which elements it cannot be. For example, a radius fragment cannot be a cranial bone or tooth (which excludes hundreds of possibilities), a tibia or humerus (too small), a metatarsal (too big), or even a fibula (wrong shape). You will be surprised how soon you can exclude all but the correct choice if you approach identification in this way.

No matter how often you misidentify a bone or tooth, keep trying. Do not constantly use the articulated skeleton or intact skull as a crutch. There is great osteological truth to the idea that “with every mistake we must surely be learning.” Try to learn from your mistakes. Try to identify the kinds of mistakes you are making. Are you most often misidentifying immature specimens? If so, set out a growth series for each skeletal element and see how the shape of the bone changes with growth. Are you having trouble with nonhuman skeletal parts? If so, look at a range of human variation to get a good idea of how much variation to expect. Are you simply confusing one part of the skeleton for another? If so, look at all the elements in the skeleton that might mimic each other when fragmentary and check the “**Possible Confusion**” sections in the descriptive chapters of this book. Keep this book nearby. It is much easier to carry than a skeleton, and the life-size photographs in many views should facilitate comparisons and identifications.

1.6 Working with Human Bones

Because the results of human osteology have an impact on so many disciplines, there are a variety of career options that involve human skeletal remains. Most of these choices involve the academic setting. As a result, most professional human osteologists work in colleges, universities, and museums. Even in forensic anthropology, the most “applied” of human osteological endeavors, coroners, medical examiners, and law enforcement agencies most often turn to local or national specialists employed in higher education (Galloway and Simmons, 1997). Most human osteologists and hominid paleontologists are also employed as teachers and researchers in academic settings, often teaching in departments of anthropology or biology or in medical school departments

of anatomy. Some are employed by cultural resource management (CRM) firms, but these positions are often short-term and project-oriented.

Wherever employed, the human osteologist is involved with specimens in collections. As you work with human bones and teeth, always respect them as objects of scientific inquiry. In some ways, skeletal resources are like books in a library. Bones and teeth have the potential, if read correctly, to inform about the living, breathing people to whom they once belonged. Treat these remains with care; some of them are fragile and all of them are irreplaceable.

Respect any system of organization in which you find skeletal material. Never mix bones and teeth of different individuals, even for a short time or with the best of intentions. Remember that mixing of bones results in a loss of contextual information—an action that is potentially even more devastating than physical breakage of an element. In the library, history books shelved incorrectly in the biology section become unavailable to any historian who wishes to consult them. Bones returned to the wrong storage location are almost impossible to retrieve.

Finally, respect the people who came before you by treating their bones with care. Respect the generations of students and professionals who will follow you by keeping the bones and their provenience intact.

Suggested Further Readings

There are several introductory osteology textbooks. These books are highly variable in their content, the quality of their illustrations, and their coverage. In addition to these, the human anatomy books identified at the end of Chapter 4 are useful supplements to the study of human osteology.

Aiello, L., and Dean, C. (1990) *An introduction to human evolutionary anatomy*. San Diego, CA: Elsevier. 608 pp.

A simultaneous introduction to both functional anatomy and paleoanthropology, exploring the types of biobehavioral deductions that can be drawn from human fossils.

Alexander, R. M. (2004) *Human bones: A scientific and pictorial investigation*. New York, NY: Pi Press. 208 pp.

An introduction to human bones and skeletal biomechanics by one of the world's most respected biomechanists.

Baker, B. J., Dupras, T. L., and Tocheri, M. W. (2005) *The osteology of infants and children*. College Station, TX: Texas A&M University Press. 192 pp.

An introductory guide to the identification of immature human skeletal remains.

Bass, W. M. (2005) *Human osteology: A laboratory and field manual* (5th ed.). Columbia, MO: Missouri Archaeological Society. 365 pp.

An introductory manual that emphasizes identification.

Brothwell, D. R. (1981) *Digging up bones* (3rd ed.). Ithaca, NY: Cornell University Press. 208 pp.

A beginner's guide to recovery and analysis of skeletal remains.

Buikstra, J. E., and Ubelaker, D. H. (Eds.) (1994) *Standards for data collection from human skeletal remains*. (Report Number 44). Fayetteville, AR: Arkansas Archaeological Survey. 206 pp.

The essential osteological standards volume in North America.

- France, D. (2009) *Human and nonhuman bone identification: A color atlas*. Boca Raton, FL: CRC Press. 584 pp.
 Filled with thousands of photographs, this is an excellent guide to nonhuman osteology for forensic anthropologists and others working in North America.
- Goldberg, K. E. (1985) *The skeleton: Fantastic framework*. New York, NY: Torstar Books. 165 pp.
 An enjoyable, readable guide to the skeleton for the layperson. Excellent color photographs.
- Katzenberg, M. A., and Saunders, S. R. (Eds.) (2008) *Biological anthropology of the human skeleton* (2nd ed.). New York, NJ: Wiley-Liss. 680 pp.
 An edited volume that brings together 30 specialists to explore recent advances, limitations, and future directions for work in nearly 20 areas of modern osteological research.
- Komar, D. A., and Buikstra, J. E. (2007) *Forensic anthropology: Contemporary theory and practice*. New York, NY: Oxford University Press. 362 pp.
 A comprehensive overview of the current state of forensic anthropology.
- Matshe, E. W., Burbridge, B., Sher, B., Mohamed, A., and Juurlink, B. (2004) *Human osteology & skeletal radiology: An atlas and guide*. Boca Raton, FL: CRC Press. 448 pp.
 An introductory text on human osteology that incorporates large numbers of plain film radiographs, CT scans, and MRI images alongside photographs of bones.
- Schaefer, M., Black, S., and Scheuer, L. (2009) *Juvenile osteology: A laboratory and field manual*. San Diego, CA: Academic Press. 284 pp.
 A concise and easy-to-use quick reference for the identification of immature human skeletal remains.
- Schwartz, J. H. (2006) *Skeleton keys: An introduction to human skeletal morphology, development, and analysis* (2nd ed.). New York, NY: Oxford University Press. 416 pp.
 An introduction to human osteology.
- Shipman, P., Walker, A., and Bichell, D. (1985) *The human skeleton*. Cambridge, MA: Harvard University Press. 343 pp.
 A guide that stresses functional aspects of the skeleton at many levels.
- Shubin, N. (2009) *Your inner fish: A journey into the 3.5-billion-year history of the human body*. New York, NY: Vintage Books. 256 pp.
 An enjoyable introductory book that places the anatomical structures that comprise humans into an evolutionary context.
- Steele, D. G., and Bramblett, C. A. (1988) *The anatomy and biology of the human skeleton*. College Station, TX: Texas A&M University Press. 304 pp.
 An atlas dedicated to the identification and biology of the human skeleton.
- Ubelaker, D. H. (1996) Skeletons testify: Anthropology in forensic science. *Yearbook of Physical Anthropology* 39: 229–244.
 An overview of osteology's role in forensic science.
- Ubelaker, D. H. (2008) *Human skeletal remains: Excavation, analysis, interpretation* (illust. ed.). New Brunswick, NJ: Aldine Transaction. 146 pp.
 A guide to human osteology that emphasizes recovery and interpretation. Excellent photographs of excavations. The text features comparative photographs of skeletal elements of large mammals common in North America.

This page intentionally left blank

Chapter 2

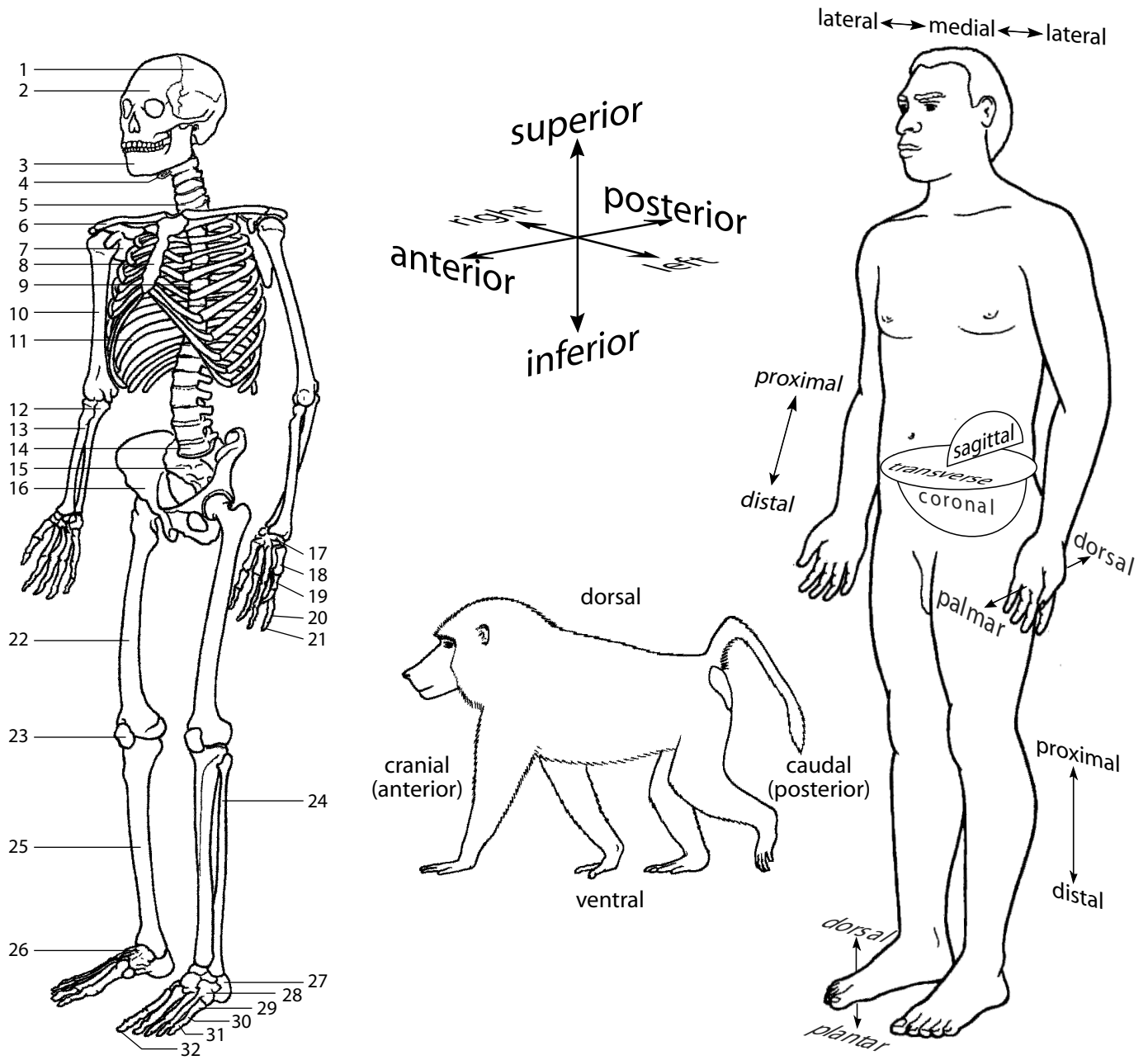
ANATOMICAL TERMINOLOGY

ANATOMISTS AND ANTHROPOLOGISTS throughout the world use a specific vocabulary to describe the human body. Anatomical nomenclature is both concise and precise, allowing unambiguous communication among all researchers who study skeletal material. Indeed, it is virtually impossible to follow even basic descriptions or interpretations in paleontology, physical anthropology, medicine, human anatomy, and a variety of allied disciplines without a command of the basic, general anatomical terms introduced in this chapter. Here we define the essential planes of reference, directional terms, body motions, and bony formations necessary for the detailed study of human osteology. Because anatomical nomenclature has evolved from a classical foundation, and because many of the names used to describe bones and their parts are derived from Latin and Greek terms, we also include a section on roots, prefixes, and suffixes. Building on this foundation, we also offer sections on anatomical regions, shape-related terms, and age-related terms. A working knowledge of these terms will facilitate learning the names of bones and their parts.

Anatomical terminology for hominids assumes that the body is in what is called **standard anatomical position** (Figure 2.1). Standard anatomical position is that of a human standing, looking forward, feet together and pointing forward, arms alongside the trunk with palms facing forward and thumbs pointing away from the body. The result of this careful positioning is that none of the long bones are crossed from the viewer's perspective. The terms **left** and **right** refer to the sides of the individual being studied, not to the observer's own right or left sides. **Cranial** skeletal anatomy refers to the skull; the remainder of the skeleton is called **postcranial** anatomy. The **axial skeleton** refers to the bones of the trunk, including the vertebrae, sacrum, ribs, and sternum. The **appendicular skeleton** refers to the bones of the limbs, including the shoulder and pelvic girdles, and the hands and feet.

2.1 Planes of Reference

Three basic reference planes are used in human osteology. The **sagittal** (**midsagittal**, **median**, or **midline**) plane divides the body into symmetrical right and left halves. Any planar slice through the body that parallels the sagittal plane is called a **parasagittal section**. The **coronal** (**frontal**) plane passes through bregma (the intersection of the sagittal and coronal sutures; see Section 4.5.1) and divides the body into anterior and posterior halves and is placed at right angles to the sagittal plane. Any planar slice through the body that parallels the coronal plane is called a **paracoronal section**. A **transverse** (**horizontal**) plane slices through the body at any height but always passes perpendicular to the sagittal and frontal planes.



- | | | | |
|---------------------------------|----------------------------------|-------------------------------------|-------------------------------------|
| 1. Paired cranial elements (22) | 9. Thoracic vertebrae (12; var*) | 17. Carpals (16) | 26. Talus (2) |
| 2. Single cranial elements (5) | 10. Humerus (2) | 18. Metacarpals (10) | 27. Calcaneus (2) |
| 3. Mandible (1) | 11. Ribs (24; var*) | 19. Proximal hand phalanges (10) | 28. Other tarsals (10) |
| 4. Hyoid (1) | 12. Ulna (2) | 20. Intermediate hand phalanges (8) | 29. Metatarsals (10) |
| 5. Cervical vertebrae (7) | 13. Radius (2) | 21. Distal hand phalanges (10) | 30. Proximal foot phalanges (10) |
| 6. Clavicle (2) | 14. Lumbar vertebrae (5; var*) | 22. Femur (2) | 31. Intermediate foot phalanges (8) |
| 7. Scapula (2) | 15. Sacrum (1) | 23. Patella (2) | 32. Distal foot phalanges (10) |
| 8. Sternum (1) | 16. Os coxae (2) | 24. Fibula (2) | Coccyx (1; not visible) |
| | | 25. Tibia (2) | TOTAL: 206 Adult |

* Commonly variable elements indicated by (var*)

Figure 2.1 Directional terms and planes for a human and a quadrupedal mammal. Knowledge of the directional terms and planes of reference is necessary for any work in human anatomy. In human osteology, these terms are essential for the study and comparison of skeletal elements. Both the human body and human skeleton are presented in standard anatomical position: standing straight, facing straight ahead, arms at sides, palms and toes facing forward.

2.2 Directional Terms

In osteology it is useful to refer to directions of motion or the relative locations of various skeletal parts. All of the directional terms used here refer to the human body in standard anatomical position, but it is important to note that most of these terms are applicable to all mammals. A few terms may occasionally cause confusion when **hominid** (the zoological family of primates to which humans and their immediate ancestors and near-relatives belong) and nonhominid bones are being compared because humans are **orthograde** (trunk upright) bipeds and most other mammals are **pronograde** (trunk horizontal) quadrupeds.

2.2.1 General (Figure 2.1)

- a. **Superior**: toward the head end of the hominid body. The *superior* boundary of the human parietal bone is the sagittal suture. **Cephalic** and **cranial** are synonymous with superior in bipeds, and unlike superior, they can be used homologously for both bipeds and quadrupeds.
- b. **Inferior**: opposite of superior; for hominids, body parts away from the head. The *inferior* surface of the calcaneus, or heel bone, is the part of the bone that rests nearest to, or lies in contact with, the ground. **Caudal**, toward the tail, is often used in the description of quadrupedal anatomy.
- c. **Anterior**: toward the front of the hominid body. The breastbone, or sternum, is located *anterior* to the backbone, or vertebral column. **Ventral**, toward the belly, may be used homologously for bipeds and quadrupeds.
- d. **Posterior**: opposite of anterior; for hominids, toward the back of the individual. The occipital bone is on the *posterior* and inferior end of the skull. **Dorsal** is often used for homologous parts of the quadruped anatomy.
- e. **Medial**: toward the midline. The sternum is *medial* to the adjacent distal ribs.
- f. **Lateral**: opposite of medial; away from the midline. The thumb occupies a *lateral* position relative to the little finger in standard anatomical position.
- g. **Proximal**: nearest the axial skeleton, usually used for limb bones. The *proximal* end of the upper arm bone, the humerus, is the end toward the shoulder.
- h. **Distal**: opposite of proximal; farthest from the axial skeleton. The *distal* end of the terminal foot phalanx fits into the front end of a shoe.
- i. **External**: outer; closer to the surface. The rib cage is *external* to the lungs and heart.
- j. **Internal**: opposite of external; inner. The *internal* surface of the parietal is marked by a set of grooves made by blood vessels that lie external to the brain.
- k. **Extrinsic**: external to that which it acts upon. *Flexor pollicis longus*, a muscle that flexes the thumb, is considered an *extrinsic* hand muscle because the belly of the muscle is found deep in the forearm, not the hand itself.
- l. **Intrinsic**: internal to that which it acts upon. *Flexor pollicis brevis*, another muscle that flexes the thumb, is considered an *intrinsic* hand muscle because the muscle is located entirely in the hand.
- m. **Endocranial**: inner surface of the cranial vault. The brain fills the *endocranial* cavity.
- n. **Ectocranial**: outer surface of the cranial vault. The temporal line is on the *ectocranial* surface of the parietal.
- o. **Superficial**: closer to the surface. The ribs are *superficial* compared to the heart.
- p. **Deep**: opposite of superficial; far from the surface. The dentine core of a tooth is *deep* to the enamel.
- q. **Subcutaneous**: just below the skin. The anteromedial surface of the tibia is *subcutaneous*.

2.2.2 Hands and Feet (Figure 2.1)

- a. **Palmar:** palm side of the hand. The *palmar* surfaces of the digits bear fingerprints.
- b. **Plantar:** sole of the foot. The *plantar* surface of the foot contacts the ground during normal walking.
- c. **Volar:** a general term, referring to the ‘hollow’ of either the hand or foot: in the hand, *volar* is synonymous with palmar, and in the foot, it is synonymous with plantar.
- d. **Dorsal:** top of the foot or the back of the hand. The *dorsal* surfaces of hands and feet often bear hair, whereas the palmar and plantar surfaces do not.

2.2.3 Teeth (Figure 2.2)

- a. **Mesial:** toward the midline point of the dental arch where the central incisors contact each other. The anterior portion of molar and premolar crowns and the medial parts of canines and incisors are called the *mesial* parts of these teeth. The *mesial* surface of the canine touches the incisor next to it, and the *mesial* surface of the first molar touches the premolar next to it.
- b. **Distal:** opposite of mesial. The *distal* half of a premolar is the posterior half of the tooth.
- c. **Lingual:** toward the tongue. The *lingual* surfaces of tooth crowns are usually hidden from view when a person smiles.
- d. **Labial:** opposite of lingual; toward the lips; usually reserved for incisors and canines. The *labial* surfaces of incisors are observed when a person smiles.
- e. **Buccal:** (pronounced ‘buckle’) opposite of lingual; toward the cheeks; usually reserved for premolars and molars. A wad of chewing tobacco is sometimes wedged between the cheek and the *buccal* surfaces of the molars of American baseball players.
- f. **Interproximal:** the area of a tooth in contact with an adjacent tooth in the same jaw. Dental floss often gets stuck in *interproximal* areas.

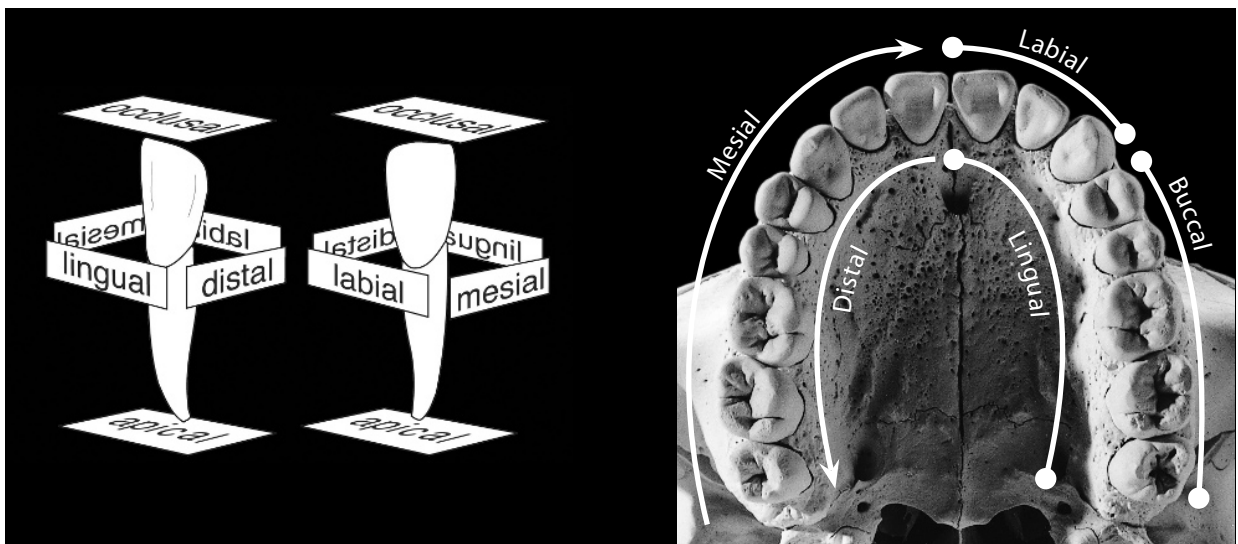


Figure 2.2 Directional terms and planes of reference for human teeth.

- g. **Occlusal:** facing the opposing dental arch, usually the chewing surface of each tooth. Caries (“cavities”) are often found on the irregular *occlusal* surfaces of the molar teeth.
- h. **Apical:** at or towards the tip of the root. Blood vessels enter the pulp cavity through an *apical* opening.
- i. **Cervical:** at, around, or pertaining to either the neck proper (the portion of the body between the head and shoulders) or to any of a number of anatomical constrictions referred to as ‘neck’ or ‘cervix.’ Dental plaque tends to build up along the *cervical* margins of teeth.
- j. **Incisal:** the biting, or occlusal, edge of the incisors. The *incisal* edges of the central incisors are used to bite into an apple.
- k. **Mesiodistal:** axis running from mesial to distal. The *mesiodistal* dimension of a molar may be reduced by interproximal wear.
- l. **Buccolingual** and **labiolingual:** axis running from labial or buccal to lingual. The incisors of Neanderthals often have large *labiolingual* dimensions.

2.3 Motions of the Body

Movement of the body is accomplished by muscles acting directly or via tendons on bones. The less mobile attachment point that anchors a muscle is called the **origin** of the muscle. The **insertion** is the site of muscle attachment with relatively more movement than the origin.

2.3.1 General

- a. **Flexion:** generally, a bending movement that decreases the angle between body parts. When a hand is clenched into a fist there is strong *flexion* of the phalanges on the metacarpal heads. By convention, *flexion* at the shoulder or hip joint refers to a ventral (forward) movement of the limb.
- b. **Extension:** opposite of flexion; a straightening movement that increases the angle between body parts. The classic karate chop is made by a rigid hand in which the fingers are extended. By convention, *extension* at the shoulder or hip joint is a dorsal (backward) swing of the limb.
- c. **Abduction:** movement of a body part, usually a limb, away from the sagittal plane. When the arm is raised to the side from standard anatomical position, *abduction* of the arm occurs. For the special case of fingers and toes, *abduction* is movement of the digit away from the midline of the hand or foot (spreading the digits).
- d. **Adduction:** opposite of abduction; movement of a body part, usually a limb, toward the sagittal plane. Bringing the arm down to slap the side of the thigh is *adduction*. For the special case of fingers and toes, *adduction* is movement of the digit toward the midline of the hand or foot (closing the digits).
- e. **Circumduction:** a combination of abduction and adduction, as well as flexion and extension, that results in an appendage being moved in a cone-shaped path. When the driver of a slow vehicle signals someone behind him to pass, this “waving on” is often done by *circumducting* the arm.
- f. **Rotation:** motion that occurs as one body part turns on an axis. The movement of the head of the radius on the distal humerus is an example of *rotation*.
- g. **Opposition:** motion in which body parts are brought together. *Opposition* of the thumb and finger tips allows us to grasp small objects.

2.3.2 Hands and Feet

- a. **Pronation:** rotary motion of the forearm that turns the palm from anteriorly facing (thumb lateral) to posteriorly facing (thumb medial). Typewriters are used with the hand in *pronation*.
- b. **Supination:** opposite of pronation; rotary motion of the forearm that returns the palm to a position in which the thumb is lateral. When chimpanzees beg for food the hand is often held in *supination*.
- c. **Dorsiflexion:** flexion of the anterior portion of the foot away from the ground. When a mime walks on her heels, her feet are *dorsiflexed*.
- d. **Plantarflexion** (or **volarflexion**): opposite of dorsiflexion; flexing of the anterior portion of the foot inferiorly, toward the ground at the ankle. Action in both dorsiflexion and plantarflexion occurs at the ankle. When a ballerina walks on her toes, her feet are strongly *plantarflexed*.
- e. **Eversion:** turning the sole of the foot outward so that it faces away from the midline of the body. Also known as **pronation** of the foot.
- f. **Inversion:** turning the sole of the foot inward so that it faces toward the midline of the body. Also known as **supination** of the foot.

2.4 General Bone Features

Whereas the directions and motions described in Sections 2.2 and 2.3 have very precise meanings, the series of general terms applied to bony features is more ambiguous and cross-cutting. For example: the theoretical question “when is a tubercle big enough to be called a tuberosity (or a trochanter)?” is rarely faced by the osteologist. This is because the conventional labels for various bones and bone parts are always adopted to ensure stability of nomenclature and effectiveness of communication. Specific terms for nearly all bones and their parts are already established, and have been for a long time. The “greater trochanter” of a femur, for example, identifies a particular, unique structure for all human osteologists. Recognize that the following terms are often vague by themselves, but are unambiguous when coupled with element-specific names introduced in Chapters 4–13.

2.4.1 Projections and Parts

- a. **Process:** a bony prominence. The mastoid *process* forms the prominence behind the ear.
- b. **Eminence:** a bony projection; usually not as prominent as a process. The articular *eminence* of the temporal bone is the rounded area with which the mandibular condyle articulates during chewing.
- c. **Spine:** generally a longer, thinner, sharper process than an eminence. Synonymous with **spinous process**. Vertebral *spinous processes* are used in the identification of various vertebrae.
- d. **Tuberosity:** a large, usually rugose (roughened) eminence of variable shape; often a site of tendon or ligament attachment. The deltoid *tuberosity* marks the shaft of the humerus.
- e. **Tubercle:** a small, usually rugose eminence; often a site of tendon or ligament attachment. The conoid *tubercle* is found along the inferior edge of the clavicle.
- f. **Trochanter:** one of two large, prominent, blunt, rugose processes found only on the femur. The larger of these is called the greater *trochanter*, the smaller is the lesser *trochanter*.

- g. **Malleolus** (pl. **malleoli**): a rounded protuberance adjacent to the ankle joint. It is easy to palpate (examine by touch) both lateral and medial *malleoli*.
- h. **Boss**: a smooth, round, broad eminence. Female skulls tend to show more *bossing* of the frontal bone than those of males.
- i. **Articulation**: an area where adjacent bones are in contact (via cartilage or fibrous tissue) at a joint. The proximal surfaces of the tibia are said to *articulate* with the distal end of the femur.
- j. **Condyle**: a rounded articular process. The occipital *condyles* lie on the base of the cranium and articulate with the uppermost vertebra, the atlas.
- k. **Epicondyle**: a nonarticular projection adjacent to a condyle. The lateral *epicondyle* of the humerus is located just proximal to the elbow, adjacent to the lateral condylar surface.
- l. **Head**: a large, rounded, usually articular end of a bone. The *head* of the humerus is the superior (proximal) end of the bone.
- m. **Shaft**, or **diaphysis** (pl. **diaphyses**): the long, straight section between the ends of a long bone. The femoral *shaft* is roughly circular in cross section.
- n. **Epiphysis** (pl. **epiphyses**): in general usage, usually the end portion or extremity of a long bone that is expanded for articulation. The proximal *epiphysis* of the tibia is the expanded end of the bone that articulates with the femur. See Chapter 3 for more precise definitions of the diaphysis, epiphysis, and metaphysis.
- o. **Neck**: the section of a bone between the head and the shaft. The *neck* of the femur is long relative to the size of the femoral head in some early hominids.
- p. **Torus** (pl. **tori**): a bony thickening. The supraorbital *torus* on some *Homo erectus* frontal bones is very thick.
- q. **Ridge**: a linear bony elevation, often roughened. The lateral supracondylar *ridge* of the humerus borders the bone above the lateral epicondyle.
- r. **Crest**: a prominent, usually sharp and thin ridge of bone; often formed between adjacent muscle masses. The sagittal *crest* is a structure on the skull that forms during the development of large *temporalis muscles* in the gorilla.
- s. **Line**: a raised linear surface, not as thick as a torus or as sharp as a crest. The inferior temporal *lines* mark the superior extent of the *temporalis muscles*.
- t. **Hamulus**: a hook-shaped projection. The *hamulus* of the wrist's hamate bone gives the bone its name.
- u. **Facet**: a small articular surface on a bone, or a tooth-to-tooth contact. Bodies of the thoracic vertebrae have *facets* for articulation with the heads of ribs. Occlusal *facets* form on the chewing surfaces of the teeth shortly after crown eruption.
- v. **Ramus** (pl. **rami**): a branch. The pubic bone splits into two *rami* around the obturator foramen.

2.4.2 Depressions and Openings

- a. **Fossa** (pl. **fossae**): a depressed area; usually broad and shallow. The olecranon *fossa* is located on the posterior surface of the distal humerus, where it receives the proximal ulna during full extension of the arm.
- b. **Fovea** (pl. **foveae**): a pit-like, depressed area; usually smaller than a fossa. The anterior *fovea* of an unworn molar is seen in occlusal view.
- c. **Groove**: a long pit or furrow. The intertubercular *groove* passes between two tubercles on the humerus.

- d. **Sulcus** (pl. **sulci**): a long, wide groove. A strong supratatorial *sulcus* is present on African ape crania but is weak or absent on *Australopithecus* crania.
- e. **Fontanelle**: a space between cranial bones of an infant. The soft spot atop a baby's head indicates the presence of a *fontanelle*.
- f. **Suture**: where adjacent bones of the skull meet (articulate). The lambdoidal *suture* is between occipital and parietal bones.
- g. **Foramen** (pl. **foramina**): an opening through a bone, usually a passage for blood vessels and nerves. The mental *foramen* is an opening on the lateral surface of the mandible.
- h. **Canal**: a tunnel-like passage, usually extending from a foramen. The carotid *canal* is found at the base of the skull.
- i. **Canaliculus** (pl. **canaliculi**): a very small passage or duct. Within compact bone, cells called osteocytes are locally interconnected via a network of *canaliculi*.
- j. **Meatus** (pl. **meati or meatuses**): a short, wide canal. The external acoustic *meatus* is the canal that connects the middle and outer ear.
- k. **Sinus** (pl. **sinuses**): a cavity within a cranial bone. The frontal *sinus* is well-developed in some early hominid crania.
- l. **Alveolus** (pl. **alveoli**): a tooth socket. The canine *alveolus* in the mandible is deeper than the incisor alveolus.

2.5 Useful Prefixes and Suffixes

- a. **A-**: without, or not (Greek). Cartilage is *avascular* in adults.
- b. **Allo-**: other or different (Greek). Changes in body proportions occur as a result of *allometric* growth, *i.e.*, different body parts growing at different rates.
- c. **Ante-**: before, ahead of, preceding, or in front of (Latin). *Antemortem* injuries occur before the death of the individual.
- d. **Anti-**: opposite or against (Greek, contrasts with *pro-*). Because of lateral symmetry, each right bone has a left *antimere*.
- e. **Apo-**: separate, apart, away from, or detached (Greek). Secondary growth centers at sites of muscular insertions are called *apophyses*, or traction epiphyses.
- f. **Basi-**: of, or relating to the bottom or base (Latin, *basis*, base, pedestal). The bottom of the cranium is referred to as the *basicranium*.
- g. **Bi-**: twice, double, on both sides, in both directions, between both (Latin, see also *di-*). The osteometric measurement 'bi-iliac breadth' is often used as a proxy (or surrogate) for body width.
- h. **Brachi-, brachio-, or -brachial**: of, or relating to the arm, specifically the upper arm (Latin, *brachialis*, from *brachium*, arm). The *brachioradialis* muscle reaches from the humerus to the radius. Do not confuse with *brachy-*.
- i. **Brachy-**: short (Greek, *brakhus*, short). A cranium that is short (front-to-back) relative to its width (side-to-side) is considered to be *brachycephalic*. Do not confuse with *brachi-*.
- j. **-cep-, -ceps**: head or heads (Latin, *ceps*, from *caput*, head). The *biceps brachii* muscle has two distinct heads, each originating from a different part of the scapula.
- k. **Chondro- or -chondro-**: cartilage or cartilaginous (Greek, *khondros*, grain or cartilage). *Chondroblasts* are cartilage-forming cells.
- l. **Circum-**: around (Latin). The action of swinging your arm in a large circle is called *circumduction*.

- m. **Con-**: with or together (Latin). A disease present from birth is called a *congenital* disease.
- n. **Cost-** or **-costal**: related to a rib or ribs (Latin, *costa*, rib). The *costoclavicular* ligament runs between the clavicle and the first rib.
- o. **Cyt-**, **-cyte**, or **-cytic**: a mature cell (Greek, *kutos*, vessel). *Osteocytes* are found in lacunae (small spaces in the bone in which living bone cells live), trapped by the very matrix they have secreted.
- p. **Demi-**: half (Latin). The sixth thoracic vertebra has both superior and inferior *demifacets*.
- q. **Di-**: twice or double (Greek, see also *bi-*). The *digastric* muscle is named for its two bellies.
- r. **Dia-**: across, through, or apart (Greek). A long bone's *diaphysis* reaches from one epiphysis to the other.
- s. **Dis-**: undoing, removal, reversal, or absence (Latin). When part of a joint is separated from the rest of the joint, it is referred to as a *dislocation*.
- t. **Ecto-**: outside (Greek, contrasts with *endo-*). Button sarcomas, small cancerous lesions, are frequently found on the *ectocranial* surface of the cranial vault.
- u. **Endo-**: inside (Greek, contrasts with *ecto-*). *Endocranial* capacity is often used as a proxy for brain size in skeletal remains.
- v. **Epi-**: at, upon, close to, adjacent, above, or in addition (Greek). The bony endplates of a growing bone are called *epiphyses*.
- w. **-form**, **-iform**: having the shape or form of (Latin). The *piriform* aperture is an opening roughly in the shape of a pear.
- x. **Hemi-**: half (Greek, similar to *semi-*). The humeral head is only *hemispheric*, while the femoral head is much closer to spherical.
- y. **Hetero-**: other, or different (Greek, contrasts with *homo-*). Humans, like most mammals, have complex and differentiated teeth, a trait called *heterodonty*.
- z. **Homo-**: similar, same, or identical (Greek, contrasts with *hetero-*). The vertebral column is made up of a set of serially *homologous* elements.
- aa. **Hypo-**: less than, under, beneath, below, or to a lesser degree (Greek, contrasts with *hyper-*. See also *sub-*). The *hypoglossal* nerve enters the underside of the tongue.
- ab. **Hyper-**: more than, over, beyond, above, or to a greater degree (Greek, contrasts with *hypo-*; see also *super-*). The radial tuberosity was enlarged and roughened, probably in response to a hypertrophied *biceps brachii* muscle.
- ac. **Infra-**: below or beneath (Latin). The *infraorbital* foramen opens beneath the eye socket.
- ad. **Inter-**: between. An *interosseous* membrane connects the shafts of the tibia and the fibula.
- ae. **-itis**: denotes an inflammatory disease (Greek). *Osteitis* is an inflammation of bony tissue.
- af. **Lacri-/lacry-**: of, belonging to, or related to tears (Latin, *lacrima*, "tear"). The *nasolacrimal* duct drains tears into the nasal cavity.
- ag. **Meso-**: intermediate, medium (Greek, *mesos*, middle). The *mesosternum* is referred to as the corpus sterni.
- ah. **Meta-**: between or with (Greek). The *metaphysis* is an area of growth sandwiched between the epiphysis and the diaphysis.
- ai. **Neuro-**: related to the brain or central nervous system (Greek, *neuron*, nerve or sinew). The *neurocranium* is that part of the cranium that houses the brain.
- aj. **-oma** (pl. **-omata**): growth or tumor. (Latin, from Greek) An *osteoma* is a bone tumor.
- ak. **Ortho-**: straight or upright (Greek). An animal whose trunk is kept habitually upright is said to have *orthograde* posture.
- al. **-osis**: designates a disease, condition, or disorder (Greek). *Osteoporosis* is a condition in which bone becomes less dense (*i.e.*, more porous).

- am. **Osteo-** or **-osteo-**: of, or relating to, bones (Greek, *osteon*, “bone”). The study of bones is called *osteology*.
- an. **Para-**: beside, next to, or parallel to (Greek). A body has only one sagittal plane, but it may have an infinite number of *parasagittal* planes.
- ao. **Peri-**: near, around, or about (Greek). The membrane that tightly covers a bone is called the *periosteum*.
- ap. **-physis** (pl. **-physes**): a growth, projection, or protuberance (Greek). The rear articular surfaces of vertebrae extend towards their neighbors on *zygapophyses*.
- aq. **-phyte**: a pathological outgrowth (Greek, *phyton*, “plant”). Abnormal bony outgrowths are called *osteophytes*.
- ar. **Platy-**: broad and flat (Greek). Side-to-side flattening of the tibia is called *platycnemia*.
- as. **Pre-**: before — with respect to location, time, degree, or importance (Latin). The vertebrae above the sacrum are referred to collectively as *presacral* vertebrae.
- at. **Proto-**: first, largest, primary, most important (Greek, *protos*, first). The *protocone* dominates the other molar cusps.
- au. **Retro-**: having a location behind (Latin, *retro*, backward). Neanderthals have a *retromolar* sulcus behind their lower wisdom tooth.
- av. **Semi-**: half or partly (Latin, similar to *hemi-*). The *semicircular* canals of the middle ear house the organs of balance.
- aw. **Splanchno-**: related to the viscera or internal organs (latinized Greek). The part of the cranium that encases the beginnings of the digestive and respiratory systems is called the *splanchnocranium*.
- ax. **-stital**: related to a place where something stands (Latin, *sistere*, to stand). Bone growth that happens between the epiphyses and pushes them apart is called *interstitial* bone growth.
- ay. **Sub-**: under, below, beneath, or less than (Latin, see also *hypo-*). The *subclavius* muscle attaches to the underside of the clavicle.
- az. **Super-**: above, extra, beyond, in addition, or greater than (Latin, see also *hyper-*). There are usually only three molars per side and per arch. Occasionally, an additional molar will develop; these are called *supernumerary* molars.
- ba. **Supra-**: above, beyond, in addition (Latin, related to *super-*). The *supraspinous* fossa, as its name suggests, is a depression found above the scapular spine.
- bb. **Syn-**: similarly, alike, or together (Latin, *syn*, from Greek *sun*, together). Cranial sutures are one kind of *synarthrosis* — a nearly immovable articulation — where bones are held together by fibrous connective tissue.
- bc. **-topic**: place or usual location (Greek, *-topia*, from *topos*, place). *Heterotopic* ossification is a condition in which bone tissue is formed in places in the body other than the skeleton.
- bd. **-trophy**: maintenance, nourishment (Greek, *trophia*, nourishment). If muscles are not used, they *atrophy*; if heavily used, they *hypertrophy*.
- be. **Tri-**: having three parts (Latin, *tri*, three). The *triceps* brachialis muscle has three heads, each originating from a different location but all merging into a single insertion.
- bf. **Zygo-**: denoting a joining or pairing (Greek, *zupon*, “yoke”). There are two *zygomatic* bones, one at each side of the face.

2.6 Anatomical Regions

There are many specific terms for anatomical regions or parts of the body that, once learned, will help you make sense of the countless anatomical terms to which they contribute.

- a. **Antebrachial:** of, belonging to, or related to the forearm (Latin, *ante* + *brachium*, before the arm).
- b. **Antecubital:** of, belonging to, or related to the front of the elbow (Latin, *ante* + *cubitus*, before the elbow).
- c. **Axillary:** of, belonging to, or related to the armpit (Latin, *axilla*, armpit). Do not confuse *axillary* with *axial*.
- d. **Brachial:** of, belonging to, or related to the arm, specifically the upper arm (Latin, *brachium*, arm).
- e. **Buccal:** of, belonging to, or related to the cheek (Latin, *bucca*, cheek).
- f. **Carpal:** of, belonging to, or related to the wrist (Latin, *carpus*, wrist).
- g. **Cephalic:** of, belonging to, or related to the head (Greek, *kephale*, head).
- h. **Cervical:** of, belonging to, or related to the neck (Latin, *cervix*, neck).
- i. **Cnemial:** of, belonging to, or related to the shin or tibia (Greek, *cnem*, tibia).
- j. **Costal:** of, belonging to, or related to the ribs (Latin, *costa*, rib).
- k. **Coxal:** of, belonging to, or related to the pelvis, hip, or hip-joint (Latin, *coxa*, hip).
- l. **Crural:** of, belonging to, or related to the leg, specifically the lower leg or calf (Latin, *crus*, leg).
- m. **Cubital:** of, belonging to, or related to the elbow (Latin, *cubitus*, elbow).
- n. **Cutaneous:** of, belonging to, or related to the skin (Latin, *cutis*, skin).
- o. **Dermal:** of, belonging to, or related to the skin (Greek, *derma*, skin).
- p. **Digital:** of, belonging to, or related to the finger(s) or toe(s) (Latin, *digitus*, finger).
- q. **Dorsal:** of, belonging to, or related to the back (Latin, *dorsum*, back).
- r. **Femoral:** of, belonging to, or related to the leg, specifically the thigh, or upper leg (Latin, *femur*, thigh).
- s. **Glossal:** of, belonging to, or related to the tongue (Greek, *glossus*, tongue).
- t. **Hallucial:** of, belonging to, or related to the big toe (Latin, *allex*, big toe).
- u. **Lingual:** of, belonging to, or related to the tongue (Latin, *lingua*, tongue or language).
- v. **Lumbar:** of, belonging to, or related to the loin, or lower back (Latin, *lumbus*, loin).
- w. **Manual:** of, belonging to, or related to the hand (Latin, *manus*, hand).
- x. **Mental:** of, belonging to, or related to the chin (Latin, *mentum*, chin).
- y. **Nasal:** of, belonging to, or related to the nose (Latin, *nasale*, nose).
- z. **Neural:** of, belonging to, or related to the brain or nervous system (Greek, *neuron*, nerve).
- aa. **Nuchal:** of, belonging to, or related to the nape, or back of the neck (Latin, *nucha*, neck or spinal cord).
- ab. **Orbital:** of, belonging to, or related to the eye socket (Latin, *orbita*, eye socket).
- ac. **Patellar:** of, belonging to, or related to the front of the knee (Latin, *patella*, kneecap).
- ad. **Pedal:** of, belonging to, or related to the foot (Latin, *pes*, foot).
- ae. **Pollical:** of, belonging to, or related to the thumb (Latin, *pollex*, thumb, big toe).
- af. **Popliteal:** of, belonging to, or related to the back of the knee (Latin, *popliteus*, back of the knee).

- ag. **Tarsal:** of, belonging to, or related to the ankle (Latin, *tarsus*, ankle).
- ah. **Temporal:** of, belonging to, or related to the temples (Latin *temporalis*, from *tempus* or *tempor-*, time; so named because one of the hallmarks of age is gray hair at the temples).
- ai. **Thoracic:** of, belonging to, or related to the chest (Latin from Greek, *thorax*, breast-plate, cuirass, chest, or breast).
- aj. **Vascular:** of, belonging to, or related to vessels, specifically blood vessels (Latin, *vascularis*, from *vasculum*, a diminutive of *vas*, vessel).

2.7 Shape-related Terms

A number of terms are used by anatomists and osteologists to describe the shape of anatomical structures.

- a. **Ala** (pl. **alae**): in the shape of a wing (Latin, *ala*, wing).
- b. **Arch:** in the shape of a simple, symmetrical curved line (Latin, *arcus*).
- c. **Bifid:** split into two parts by a cleft or notch (Latin: *bi*, two, and *fid-*, from *findre*, to cleave or split). See *bifurcated*.
- d. **Bifurcated:** split into two branches or forks (Latin, *bifurcus*, two-forked). See *bifid*.
- e. **Bilobate:** composed of two distinct (but connected) lobes or blunt projections.
- f. **Cervix/Cervical:** restricted or constricted (Latin, *cervix*, neck).
- g. **Concave:** having a profile or a surface that curves inward (Latin, *con-*, together, and *cavus*, hollow).
- h. **Conoid:** having a cone-like shape (Greek, *konooides*, from *conus*, cone, and *-oides*, form).
- i. **Convex:** having a profile or a surface that curves outward (Latin, *convexus*, vaulted, arched).
- j. **Coracoid:** shaped like a raven's beak (Greek, *korakoeides*, from *korax*, raven).
- k. **Coronoid:** hook-shaped (Greek).
- l. **Crenulate:** finely wrinkled, notched, or undulating (French, *crenel*, from Latin *crena*, notch).
- m. **Cristal:** crested, in the shape of a crest (Latin, *crista*, tuft, plume, crest).
- n. **Cruciate:** crossed, or cross-shaped (Latin *cruciatum*, from *crux*, *cruc-*, cross, and *-atum*, adjectival ending; see also *cruciform*).
- o. **Cruciform:** in the shape of a cross (Latin *crux*, *cruc-*, cross, and *-form*, shaped; see also *cruciate*).
- p. **Cuneiform:** in the shape of a wedge (Latin, *cuneiformis*, from *cuneus*, wedge).
- q. **Deltoid:** in the shape of the Greek letter Δ (*delta*); *i.e.*, having a triangular shape or outline.
- r. **Hamate:** hook-shaped (Latin; see also *uncinate*). The hamate bone has a process which helps enclose the carpal tunnel.
- s. **Helical:** in the shape of a helix (Latinized Greek, *helix*, screw-shaped).
- t. **Hemispherical:** a spherical object cut exactly in half results in two hemispherical objects.
- u. **Interdigitated:** intricately joined together (articulated), as when fingers are woven together.
- v. **Lambdoid:** in the shape of the Greek letter λ (*lambda*), much like an inverted 'Y'.
- w. **Laminar:** wall-like; usually applied to thin, vertical structures (Latin, *lamina*, thin plate).
- x. **Lentiform:** in the shape of a lentil; lens-shaped (Latin, *lent-*, lentil, and *-form*, shaped).
- y. **Lobate:** having a lobe or lobes (Latin, *lobus*, a round projecting part).

- z. **Lunate:** shaped like a crescent, esp. like a crescent moon (Latin *luna*, moon).
- aa. **Navicular:** in the shape of a boat (Latin *navicula*, little boat).
- ab. **Obturator:** obstructed; closed or blocked off (Latin, *obturare*, to obstruct).
- ac. **Ovoid:** in the shape of an oval (Latin, *ovoides*, from *ovum*, egg).
- ad. **Parabolic:** in the shape of a parabola; a symmetrical curving line whose branches get gradually and increasingly close to parallel without ever becoming parallel (Latinized Greek, *parabole*, from *para*, beside, and *bole*, a throw).
- ae. **Pisiform:** in the shape of a pea (Latin, *pisiformis*, pea-shaped).
- af. **Quadrangle:** rectilinear; in the general shape of a rectangle or square; *i.e.*, having four sides joining at 90° angles (Latin, *quadratus*, made square, from *quattuor*, four).
- ag. **Rectus:** in a straight line; straight, linear (Latin, *rectus*, straight).
- ah. **Rhomboid:** shaped like a rhombus (any parallelogram besides a square or rectangle) (Latinized Greek, *rhombos*).
- ai. **Sellar:** having a saddle shape (Latin, *sella*, seat or saddle).
- aj. **Sesamoid:** shaped like a sesame seed (Latinized Greek, *sesamon*, sesame seed).
- ak. **Sigmoid:** in the shape of the Greek letter 'S' (Σ , *sigma*). Recursively curving, like a snake.
- al. **Spherical:** having the shape of a perfectly round ball (Latinized Greek, *sphairikos*, from *sphaira*, sphere).
- am. **Squamous:** scale-like; in the form of a reptile's scale (Latin, *squamosus*, from *squama*, scale).
- an. **Stenotic:** abnormally narrowed or constricted (used for passages and internal spaces) (Latinized Greek, *stenos*, narrow).
- ao. **Toroidal:** a wide ridge or shelf that is semi-circular or bulging in cross section (Latin, *torus*, swelling).
- ap. **Trochlear:** spindle- or spool-shaped (Latin, *trochlea*, pulley). In the shape of a pulley, grooved in the center and raised on the edges.
- aq. **Uncinate:** hook-shaped (Latin, *uncinatus*, from *uncinus*, hook; see also *hamate*).
- ar. **Vault:** the arched roof of a cavity (Old French *voute*, from Latin, *volvere*, to roll).

Suggested Further Readings

Virtually all texts in human anatomy provide guides to anatomical terminology.

Bass, W.M. (2005) *Human osteology: A laboratory and field manual* (5th ed.). Columbia, MO: Missouri Archaeological Society. 365 pp.

Appendices for the osteology student are concise sources of information on bone nomenclature.

Dauber, W., and Feneis, H. (2007) *Pocket atlas of human anatomy: Founded by Heinz Feneis* (5th ed.). New York, NY: Thieme. 545 pp.

A comprehensive reference, thoroughly aligned with the latest terminology of the Federative Committee on Anatomical Terminology.

Federative Committee on Anatomical Terminology. (1998) *Terminologia Anatomica: International anatomical terminology*. New York, NY: Thieme. 292 pp. + CD-ROM.

This work revises the international standards for anatomical nomenclature, superseding all editions of the *Nomina Anatomica*.

Kachlik, D., Baca, V., Bozdechova, I., Cech, P., and Musil, V. (2008) Anatomical terminology and nomenclature: Past, present and highlights. *Surgical and Radiologic Anatomy* 30:459–466.

A history of modern systems of anatomical terminology, from the *Basiliensia Nomina Anatomica* of 1895 to the most recent revision, the *Terminologia Anatomica* of 1998.

Lisowski, F. P., and Oxnard, C. E. (2007) *Anatomical terms and their derivation*. Hackensack, NJ: World Scientific Publishing. 136 pp.

A pocket-sized guide to anatomical terminology, providing a means to better understand those terms by exploring their origins in Greek and Latin words.

O’Rahilly, R. (1989) Anatomical terminology, then and now. *Acta Anatomica* 134:291–300.

A good history of the first 25 centuries of anatomical nomenclature.

Sakai, T. (2007) Historical evolution of anatomical terminology from ancient to modern. *Anatomical Science International* 82:65–81.

A comprehensive investigation of systems of organizing and naming anatomical structures created over the past 1800 years.

Chapter 3

BONE BIOLOGY AND VARIATION

BONE, AS A CONNECTIVE TISSUE, and bones, as elements, may be studied on several hierarchical levels. Information derived from many skeletons may be used in reconstructing **population** biology (Chapter 21). Study of the various elements of a single skeleton may be used to elucidate the biological aspects of an **individual** (Chapters 18 and 19). Such assessments are built on a foundation that emphasizes the identification of the bony **elements** that constitute each human skeleton (Chapters 4–13). Before embarking on a systematic consideration of human skeletal elements, it is useful to consider bone biology. This chapter should therefore be considered an essential stepping stone to the descriptive and interpretive chapters that follow.

It is important to note the multiple functions of bone as a tissue and of bones as organs. Bones act as essential mechanical components of the **musculoskeletal system**. They serve to protect and support soft tissues; to anchor muscles, tendons, and ligaments; and as the rigid levers that muscles operate to produce movement. Bones also function as physiologically critical centers for the production of blood cells, as storage facilities for fat, and as reservoirs of important elements such as calcium (essential for blood clotting and muscle contraction). Bone as a tissue is adapted to these functions. The varied mechanical and physiological functions of bones as organs are intimately related to both the gross and microscopic (including molecular) structure of bone tissue, which we review in this chapter.

Bone is a dynamic tissue that allows for growth during **ontogeny** (development) of the individual. It is shaped and reshaped by cells that reside within it. Because of this, the gross shape, or **morphology**, of bones can be altered during life. The shape and size of bones and teeth can also vary dramatically between individuals. Before introducing bone biology at the level of the molecule, the cell, and the gross element, it is critical that we examine a property of all biological structures, the property of **variation**. Understanding and appreciating variation in bony and dental gross anatomy is critically important in any work with the human skeleton.

3.1 Variation

If we were to take a random sample of 50 male and 50 female living individuals from various human populations, it would be easy to establish physical characteristics that would allow each person to be recognized individually. Variation would be employed in sorting among individuals within the population, and only in the rare instance of identical twins would there be much difficulty in distinguishing different people. This is because the human species, like other species, exhibits variation. This variation extends to the teeth and bones of the skeleton.

In identifying our friends and acquaintances, we make use of our ability to recognize variation. Without variation in physical features it would be impossible for us to identify one another at the group and individual levels. In fact, our use of soft tissue variation seems so natural that we take it for granted. Oddly enough, however, the amount of variation in the hard tissues of the body is often not anticipated by students of osteology. Shape and size in human bones and teeth vary widely, and analysis of this variation makes human osteology simultaneously challenging for the beginner and useful for the professional.

There are four major factors leading to variation in human skeletal anatomy. One source of this variation is **ontogeny**, or growth. A great deal of skeletal variation in size and shape is observed along the continuum of growth between fetus and adult. This variation can be used by the osteologist in determining the age at death from skeletal remains. In Chapter 18 we discuss how such analyses are conducted.

A second source of skeletal variation in humans is the sex of the individual. Humans are moderately **sexually dimorphic** in body size, and in any given skeletal population this dimorphism is manifested in the relatively smaller size of female bones and teeth. This size variation is accompanied by shape variation, which allows certain skeletal elements to be used in determining the sexual identity of prehistoric remains. In Chapter 18 we discuss sex determination of osteological material.

A third type of variation is **geographic**, or **population-based**. Different human groups vary in many skeletal and dental characteristics. This geographic variation can be employed to assess the geographic (sometimes called racial) affinity of skeletal remains. In Chapters 18 and 21 we consider the use of this kind of variation in the study of past and present human populations.

Finally, even individuals of the same age, sex, and population differ in anatomy; apart from most identical twins, no two people are identical in their external size and shape. Skeletal elements are not exceptions to this rule. Normal variation between different individuals of the same age, sex, and population is called **individual**, or **idiosyncratic variation**. This variation can be substantial, but it is too often overlooked. Figure 3.1 illustrates the influences of ontogeny, sex, and idiosyncrasy on variation in the talus, one of the bones of the ankle.

A profusion of classifications of fossils has been created by the failure to appreciate normal skeletal variation in modern species and the failure to understand the principles and goals of taxonomy (White, 2009b). In the resulting forest of family trees, ill-conceived species and genera are hung like ornaments. Normal variation within closely related **extant** (modern) species must guide our expectations of variation in species whose members lived in the past. For this reason, osteologists unfamiliar with normal variation in the present are inclined to misinterpret similar variation in the past as indicating multiple species. To help avoid such misinterpretation, the paleontologist must become familiar with variation in modern humans and their closest relatives, the great apes, by studying large skeletal collections. In assessing any skeletal element, note ontogenetic changes in shape and size by studying different individuals who died at different ages. To assess normal variation in the adult skeleton arising from the other sources identified previously, try to examine a large, mixed-sex sample of individuals. Figures 3.1, 3.2, 3.3, and 3.4 illustrate variation in size and shape in single-site, balanced-sex samples from prehistoric California.

The reality of dimensional (size) and morphological (shape) variation in the hard tissues of individuals makes **typology**, the practice of choosing a single individual to characterize a species, a particularly unsuitable approach to the study and understanding of human osteology and evolution. Yet, to illustrate basic points of anatomy and identification it is necessary to begin somewhere. In using this book's chapters on identification (Chapters 4–13), the student should think of the skeletal elements chosen for illustration as representative, but never as typical. There is no "typical" individual. We illustrate variation in skeletal size and shape in this book to reinforce the fact that such variation in biological structures is normal and to be expected.

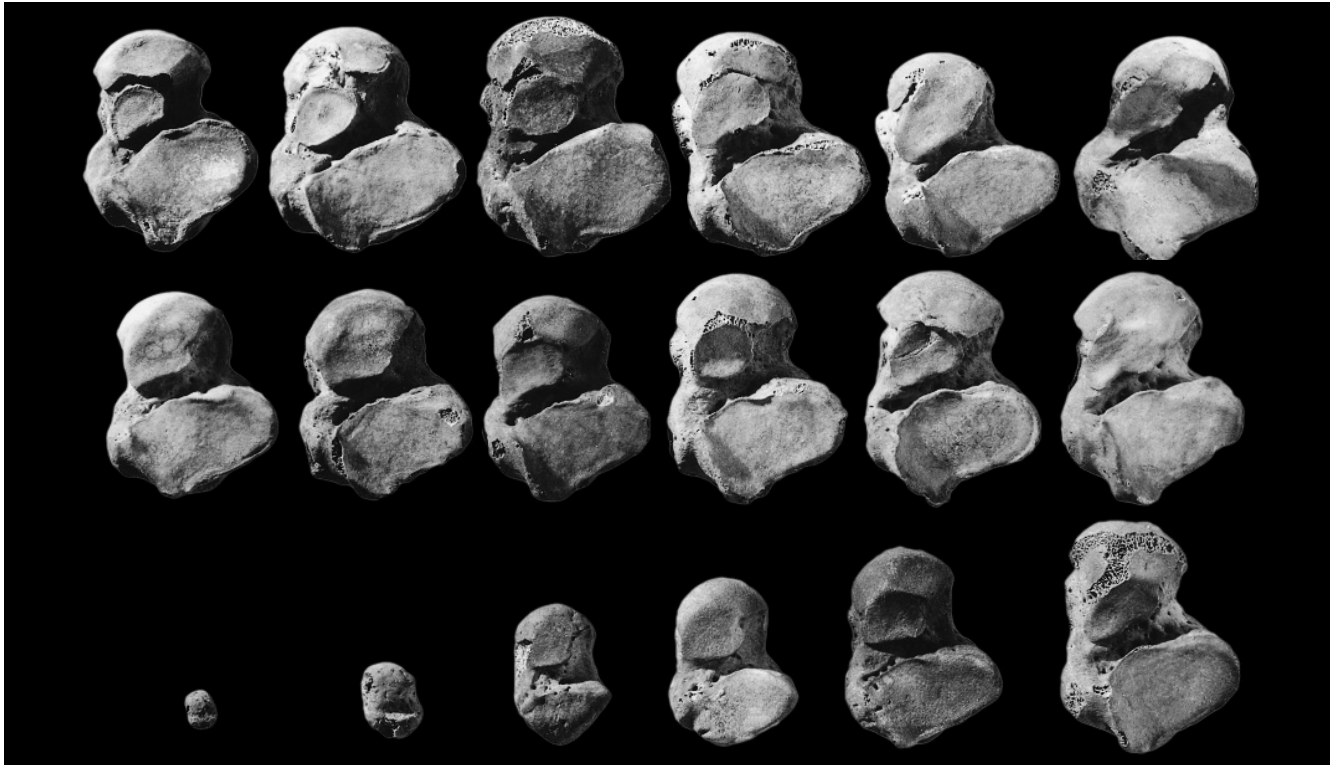


Figure 3.1 Types of variation. Normal variation in a bone of the ankle, the talus (viewed from the inferior, or lower, aspect; the anterior, or front, surface of each bone is toward the top of the page). All of the tali shown here were selected from a single-site skeletal sample of 50 pre-historic Californians to illustrate skeletal variation attributable to age, sex, and idiosyncrasy. All specimens are from the left side except for the specimen in the upper right corner, which has been mirrored for easier comparison. One-half natural size.

Top: Idiosyncratic variation. Six adult male tali chosen from a sex-balanced sample of 50 adult individuals. Variation in this series is seen in the size and shape of the overall bone outline as well as in the proportions of the parts of the bone and in the topography of the various surfaces. Such variation is common in human skeletal remains.

Middle: Sex variation. Three adult female (*left*) and three adult male (*right*) specimens chosen at random from a sex-balanced sample of 50 adult skeletons. *Homo sapiens* is a primate species whose sexual dimorphism in body size is moderate by primate standards, less than the gorilla, but more than the common chimpanzee. Chapter 19 considers sexual dimorphism in the human skeleton.

Bottom: Ontogenetic variation. The specimen at the far left is a talus from a newborn child. Tali from individuals at ages 1.5, 6, 10, 12, and 18 years show ontogenetic changes in size and shape of this skeletal element.

3.2 A Few Facts about Bone

Bone—one of the strongest biological materials in existence, particularly in terms of bearing weight (its compressive strength)—is the main supporting tissue of the body. During human running, the bones of the knee joint are loaded with a force in excess of five times the weight of the entire body. Yet, despite its great strength, bone is a very lightweight material. The skeleton itself constitutes less than 20% of the weight of the entire body, whereas a framework of steel bars performing the same mechanical functions as the human skeleton would weigh four to five times more. Bone is a **composite** material, formed of protein (collagen) and mineral (hydroxyapatite). Bone differs from steel because it is a living tissue that can repair and reshape itself in response to external stresses. More detailed reviews of the physical, geometric, and mechanical properties of bone as a tissue, and bones as organs, are provided by Burr (1980) and Currey (1983, 2002).

Bone is the virtually universal rigid underpinning of the musculoskeletal system, and must therefore routinely resist compression, tension, shear, bending, and torsion during the lifetime of

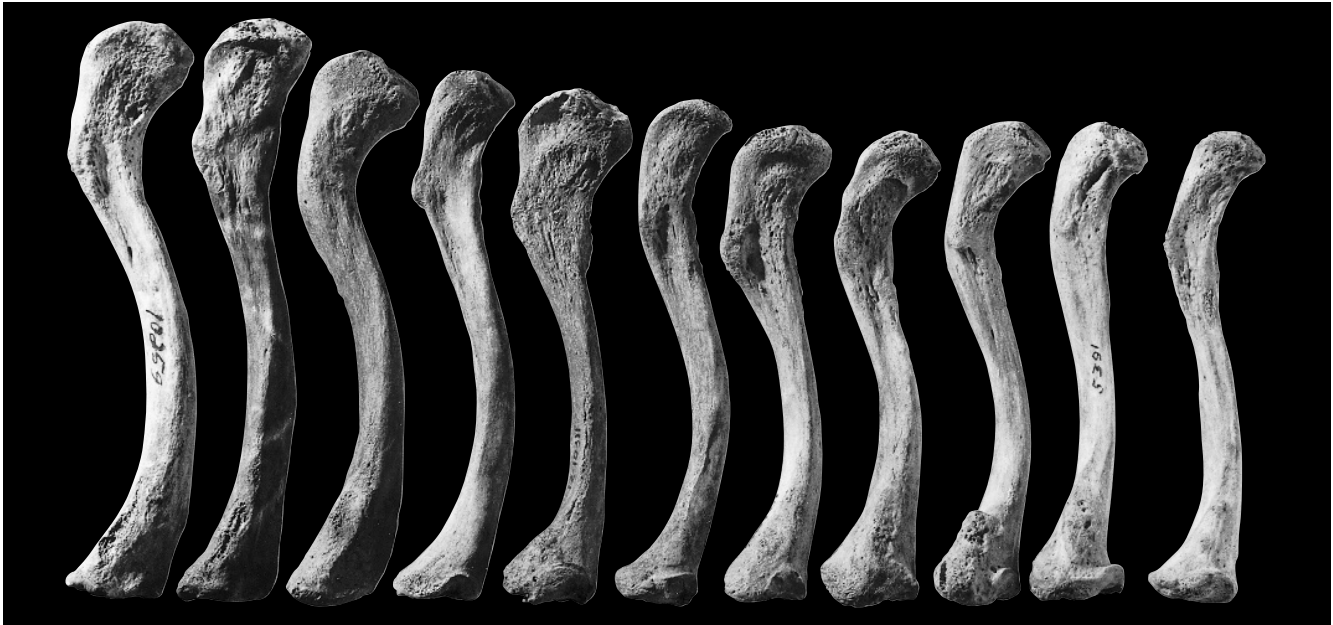

Figure 3.2 Normal variation. Adult human clavicles (collarbones) selected to illustrate the total range of variation in size, outline, and topography in a single-site, sex-balanced sample of 80 normal prehistoric Californians. Note the variation in overall size, in the shape of the bone, and in the topography of the surface. This kind and amount of variation should be expected in any normal sample of similar age and mixed sex composition. These right-side specimens are shown in inferior view, with the lateral (arm end) toward the top of the page. One-half natural size.

an individual. In 1869 the German surgeon Julius Wolff formulated a physiological “law” that today bears his name. Wolff observed that bones are living, highly vascularized, structures that can change shape during life (**remodel**), and hypothesized that such changes would in some way systematically improve their capacity to resist such external loading. Simply put, Wolff’s Law (referred to as the “law of bone transformation” in 1883) holds that bone is deposited where it is needed and resorbed where it is not needed.

This view that skeletal responses deploy bone in mechanically beneficial ways became generally assumed to underlie not only minor, local changes in the skeleton, but extensive developmental changes that contributed to overall bone form. While extensive experimental research has demonstrated that bone is certainly responsive to loading, such responses have been found to be highly complex and difficult to understand. In addition, more recent investigation of the underlying factors responsible for bone form has demonstrated an overwhelming influence of genetic factors (especially transcription factors specific to growth regions within the bone) in determining overall form. Therefore, natural selection is still the primary key to exploring how and why bones assume their adult shape. Before considering how bones operate at the molecular, cellular, and gross anatomical levels, it is important that we understand the roles of bones in the musculoskeletal system.

3.3 Bones as Elements of the Musculoskeletal System

In the most basic terms, the musculoskeletal system is a system of bony levers operated by **muscles**. Any connection between different skeletal elements is called a **joint**. Bones in the skeleton **articulate** at joints and are connected to one another by means of **ligaments** and **cartilage**. Cartilage is a tough and dense but elastic and compressible connective tissue. Bones are moved by muscles acting directly on the bones or indirectly via **tendons**, which are closely packed par-

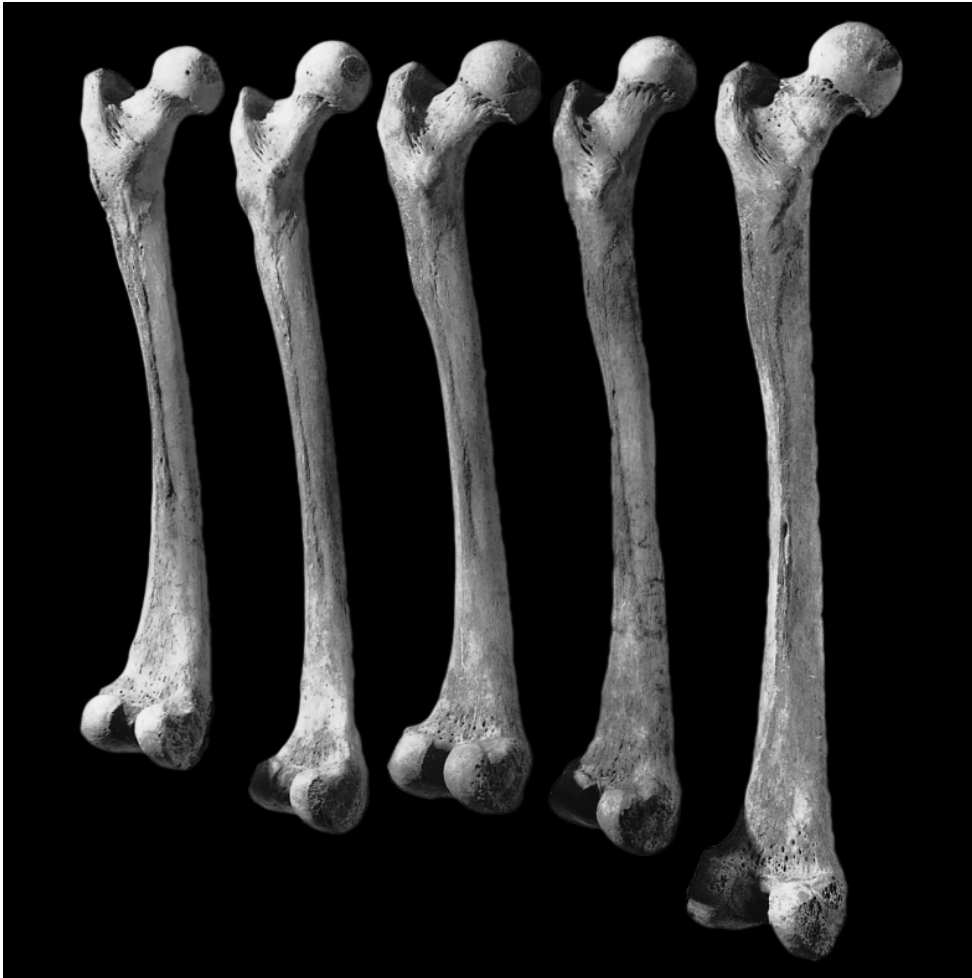


Figure 3.3 Normal variation. Adult human femora (upper leg bones) selected to illustrate the size and shape variation encountered in a single-site, sex-balanced sample of 100 normal prehistoric Californians. There is considerable variation between specimens shown here in size, robusticity, markings of muscle attachments, and proportions and angles of the different parts of each femur. These left-side specimens are shown in posterior view, with the superior (top) end of the bone toward the top of the page. One-third natural size.

allel bundles of collagen fibers. Movement at the joints is controlled and limited by the shapes of the articular surfaces and by ligaments that bind the joints together and prevent dislocation (Figure 3.5).

The hip, elbow, knee, and thumb joints are all examples of freely moving joints called **synovial joints**. The surfaces of the bones participating in synovial joints are coated with a thin (usually 1–5 mm) layer of slick, articular cartilage called **hyaline cartilage**. The area between the adjacent bones is the **joint cavity**, a space lined by a membrane that secretes a lubricant called **synovial fluid**, which resembles egg white in consistency. This fluid nourishes cartilage cells of the joint and is confined to the joint by the fibrous **joint capsule**, a sac made of connective tissue. It is reinforced by ligaments connecting to the periosteum of the articulating bones (Section 3.4). The combination of hyaline cartilage coating the bone surfaces and synovial fluid lubricating these surfaces gives synovial joints durability with smooth movement and low friction.

Synovial joints are often classified according to the geometric properties of the articulation. The hip joint is a **spheroidal**, or **ball-and-socket** joint, with the hemispherical femur head fitting

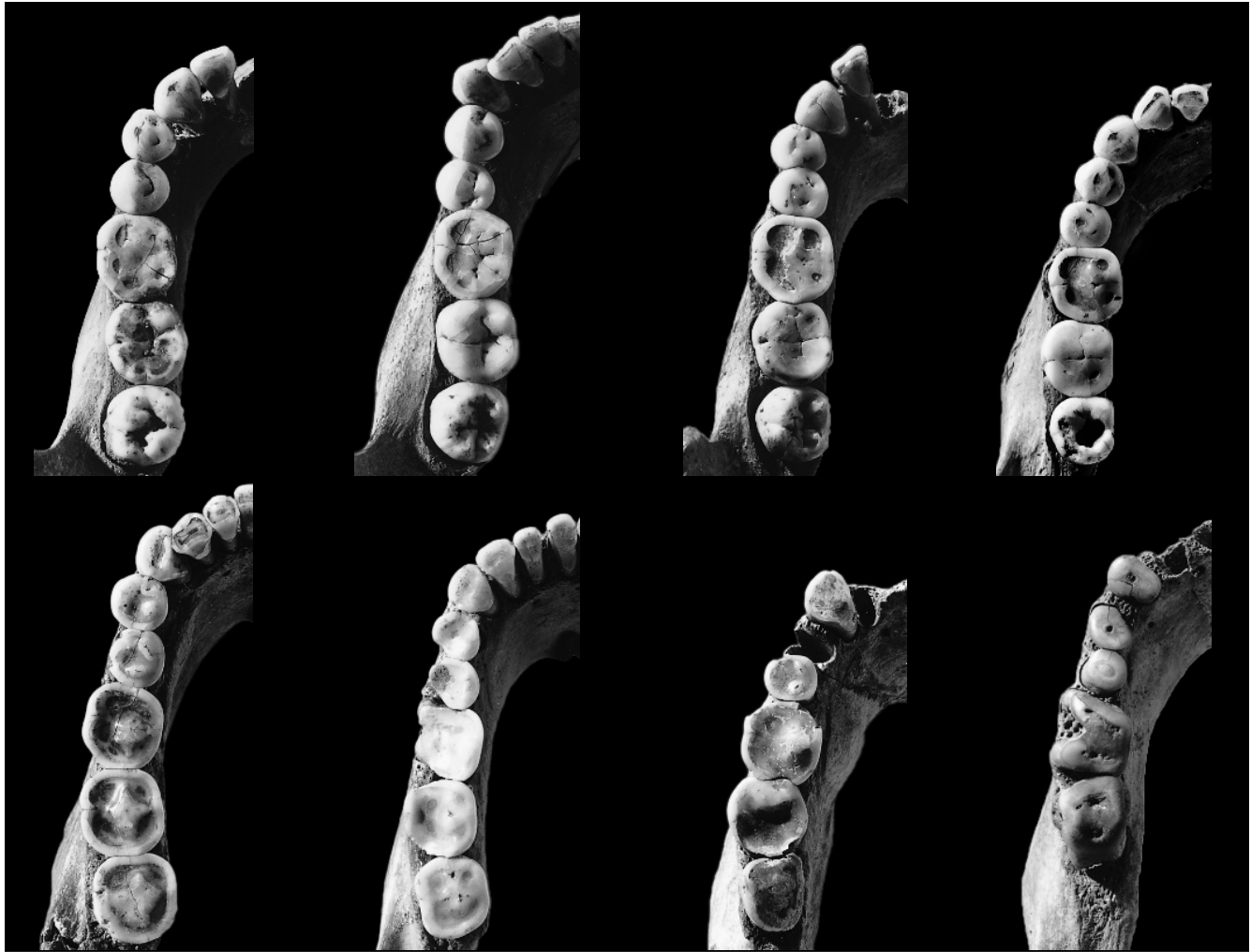

Figure 3.4 Dental variation due to age (reflected in wear), sex, and idiosyncrasy. The tooth rows shown here were selected from a single-site, sex-balanced skeletal sample of 60 prehistoric (Late Horizon) Californians. Note the differences in wear, size, and shape of the teeth as well as the variation in tooth row curvature and length.

into the acetabulum, a cavity in the pelvis. This joint structure allows movement in many directions. The elbow and knee joints are called **hinge** joints because they allow a hinge-like movement limited mostly to one plane. The joint at the base of the thumb is called a **saddle-shaped**, or **sellar**, joint because of its shape. It allows movement in two basic directions. **Planar** joints allow two bones to slide across one another, examples of which can be found in the wrist and the arch of the foot.

Because of their mobility, synovial joints are the most obvious joints in the musculoskeletal system, but there are two other important joint types in the body: cartilaginous joints and fibrous joints. In **cartilaginous joints** (or **synchondroses**), the articulating bones are united by means of cartilage, and very little movement is allowed. The temporary joints between growth centers (described later) in a single growing bone are cartilaginous. Some of these joints persist in adulthood, such as the cartilaginous connections between the ribs and the breastbone (sternum). A **symphysis** is a type of cartilaginous joint in which the fibrocartilage between the bone surfaces is covered by a thin layer of hyaline cartilage. **Syndesmoses** are tight, inflexible fibrous joints between bones that are united by bands of dense, fibrous tissue in the form of membranes

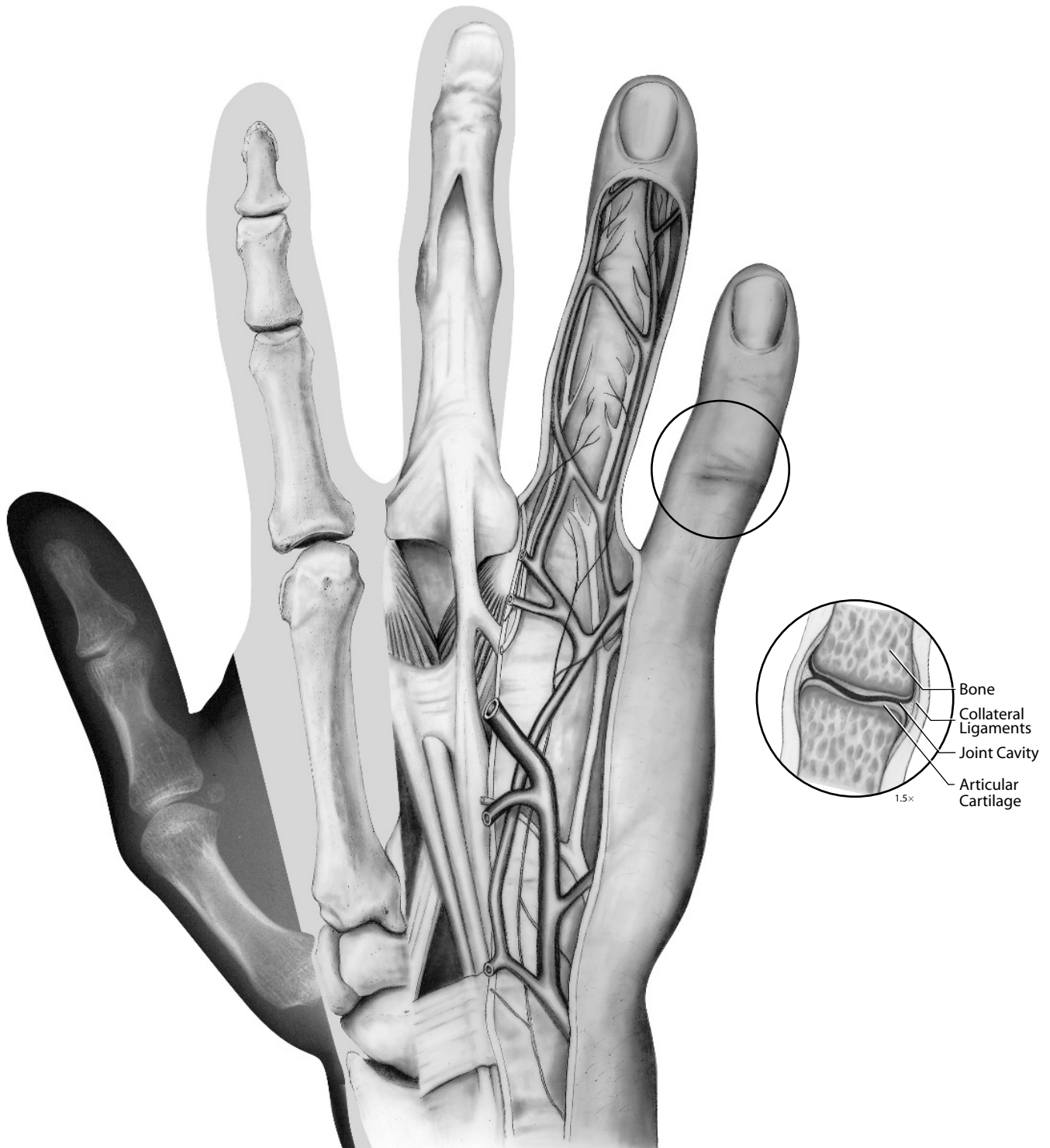


Figure 3.5 Dorsal view of a human right wrist and hand. This composite illustration combines the techniques of sectioning (little finger), dissection (ring and middle fingers), and radiography (thumb). The bones are embedded in a matrix of soft tissues including skin, nerves, arteries, veins, muscles, ligaments, tendons, and joint cartilage. In the assessment of external bone morphology, neither the soft tissue matrix nor the internal structure should be forgotten.

or ligaments; an example is the joint at which the two lower leg bones (tibia and fibula) articulate above the ankle (the distal tibiofibular articulation). **Cranial sutures** are fibrous joints of the skull; these are interlocking, usually tortuous joints in which the bones are close together and the fibrous tissue between them is thin. A **gomphosis** is the joint between the roots of the teeth and the bone of the jaws. When any two bony elements fuse together, the result is called a **synostosis**.

Movement of the skeleton takes place, for the most part, at synovial joints. This movement is caused by the muscles, which work by contracting across joints between bones. Muscles usually attach to two different bones, but they may attach to several. Most muscles are connected to bones via **tendons**. **Ligaments** are cords, bands, or sheets of collagenous bundles that extend between and bind the bones forming a joint. Ligaments resist tension, thereby strengthening the joint and permitting only movements compatible with the function of the joint.

Muscle attachment sites are conventionally identified in relative terms. The site that stays relatively stable during contraction of the muscle is called the **origin**. For the appendages, this is usually the attachment site closest to the trunk. The site that is moved by the contraction of a muscle is termed the **insertion**. For example, the muscles that flex the fingers originate in the anterior compartment of the forearm and insert on the fingerprint side of the finger bones (phalanges). Actions caused by muscles are usually reciprocal. At the elbow joint, different muscles cause opposite motions such as **extension** (straightening the arm) and **flexion** (bending the arm). Such muscles are called **antagonists**. Muscles are often identified by the primary action that their contraction causes. Chapters 4–14 introduce some of the major muscles that move the human skeleton and leave traces of their origins and insertions on the bones. For now, we can easily illustrate several basics of the musculoskeletal system with the human hand and arm. Muscles in the forearm are easily palpated as the hand is clenched and opened. These muscles act via tendons, which become very visible across the front and back of the wrist when it is flexed and extended. For example, the *extensor digitorum muscle*, a resident of the forearm, functions in extending the four fingers as it operates via four tendons that cross the wrist.

3.4 Gross Anatomy of Bones

The wide range of bone shapes in the human skeleton seem to defy classification at first. However, the bones in the body are easily partitioned into a few basic, but overlapping shapes. The limb bones and many of the hand and foot bones, usually called long bones, are tubular in shape, with expanded ends (Figure 3.6). The bones of the cranial vault, shoulder, pelvis, and rib cage tend to be flat and tabular. The bones of the ankle, wrist, and spine are blocky and irregular. Despite this variety of external form, the makeup of bones at both the gross and microscopic levels is remarkably constant.

At the gross level, all of the bones in the adult skeleton have two basic structural components: **compact** and **spongy** bone. The solid, dense bone that is found in the walls of bone shafts and on external bone surfaces is called compact, or **cortical**, bone. At joints, compact bone covered by cartilage during life is called **subchondral bone**. This is recognized as smoother and shinier than nonarticular compact bone and lacks the haversian systems described later.

The second kind of bone has a more spongy, porous, lightweight, honeycomb structure. This bone is found under protuberances where tendons attach: in the vertebral bodies, in the ends of long bones, in short bones, and sandwiched within flat bones. This **cancellous**, or **trabecular**, bone is named after the thin bony spicules (**trabeculae**) that form it. The molecular and cellular compositions of compact and trabecular bone tissue are identical; it is only the difference in porosity that separates these gross anatomical bone types.

Areas of trabecular bone in the growing skeleton constitute sites of the **red marrow**, a blood-forming, or **hematopoietic**, tissue that produces red and white blood cells and platelets. The **yellow marrow**, mainly a reserve of fat cells found in the **medullary cavity** (hollow inside the

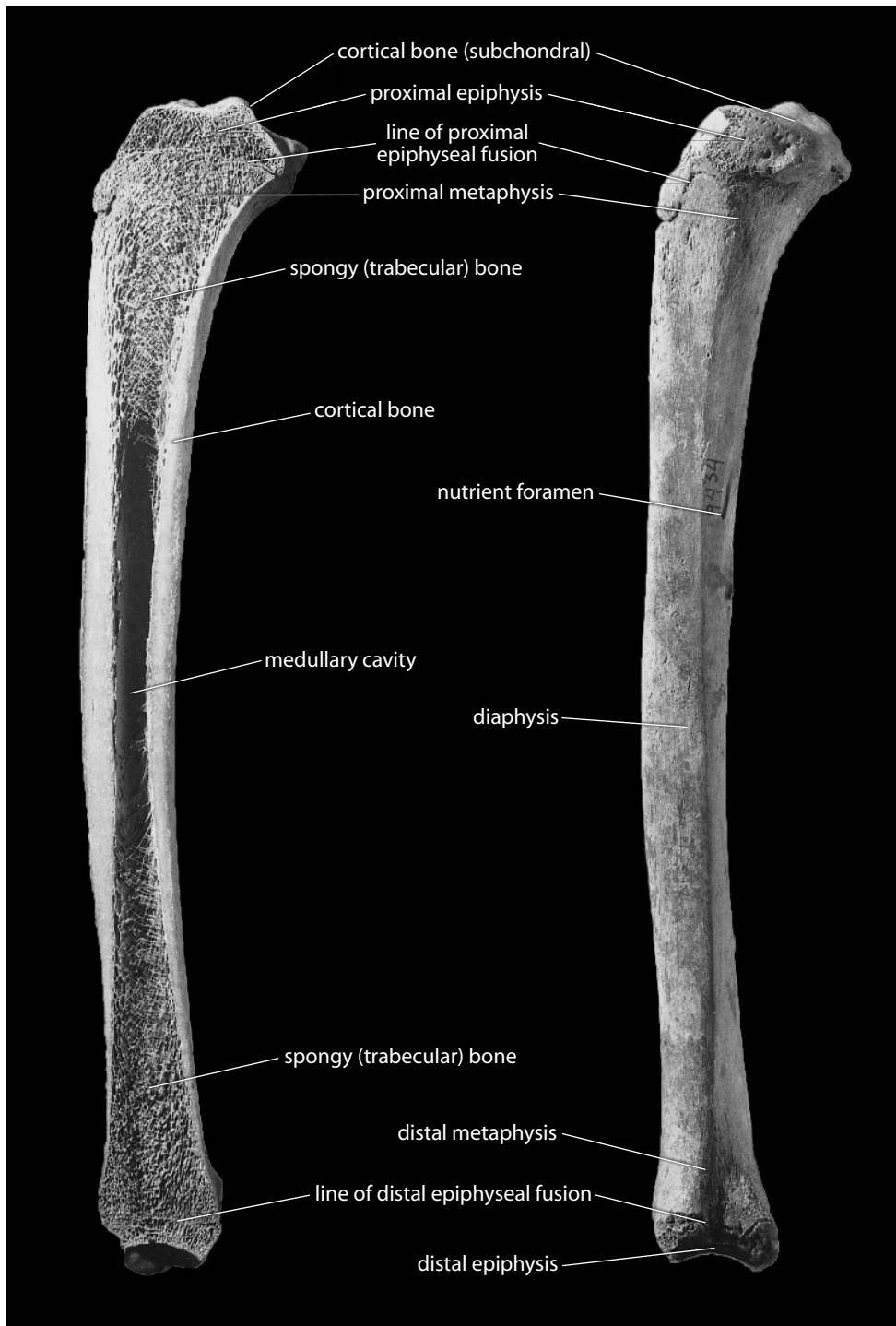


Figure 3.6 Anatomy of a bone. A left tibia (shin bone) cut in a parasagittal section to show key elements of the gross anatomy of a typical human long bone. Note the disposition of the compact and spongy bone. One-half natural size.

shaft) of tubular bones, is surrounded by compact bone. During growth, the red marrow is progressively replaced by yellow marrow in most of the long bones. As noted previously, in addition to their role in blood cell production and fat storage, bones function as organs in yet another way: bone tissue represents a calcium reservoir for the body.

Parts of tubular, or long, bones are often described according to the centers of ossification (Section 3.7) that appear during the growth process. The ends of long bones are called the **epiphyses** because they develop from secondary ossification centers of the bone (the articular surfaces of the epiphyses are parts of joints). The shaft of a long bone is called its **diaphysis** because it is the result of the primary ossification center of the bone. The expanded, flared ends of the shaft are called **metaphyses**. A good example of these parts is the knee, where the epiphysis at the knee end of the femur fuses to the metaphysis of the shaft when growth is complete. Some bones have additional growth centers called **apophyses** (or sometimes **traction epiphyses**) that form at the site of tendinous insertions. The iliac crest and the femoral trochanters are good examples of these.

During life, the outer surface of bones is usually covered with a thin tissue called the **periosteum**. This tissue is missing in dry bones, but in life it coats all bone surfaces not covered by cartilage. The periosteum is a tough, vascularized membrane that nourishes bone. Some of the thin fibers of the periosteum penetrate the surface of bone, whereas others intertwine with tendons to anchor muscles to the bone. The inner surface of bones is lined with an ill-defined and largely cellular membrane called the **endosteum**. Both periosteum and endosteum are **osteogenic** tissues—they contain bone-forming cells that are numerous and active during youth. These cells are reduced in number, but remain potentially active, in adulthood. They may be stimulated to deposit bone when the periosteum is traumatized.

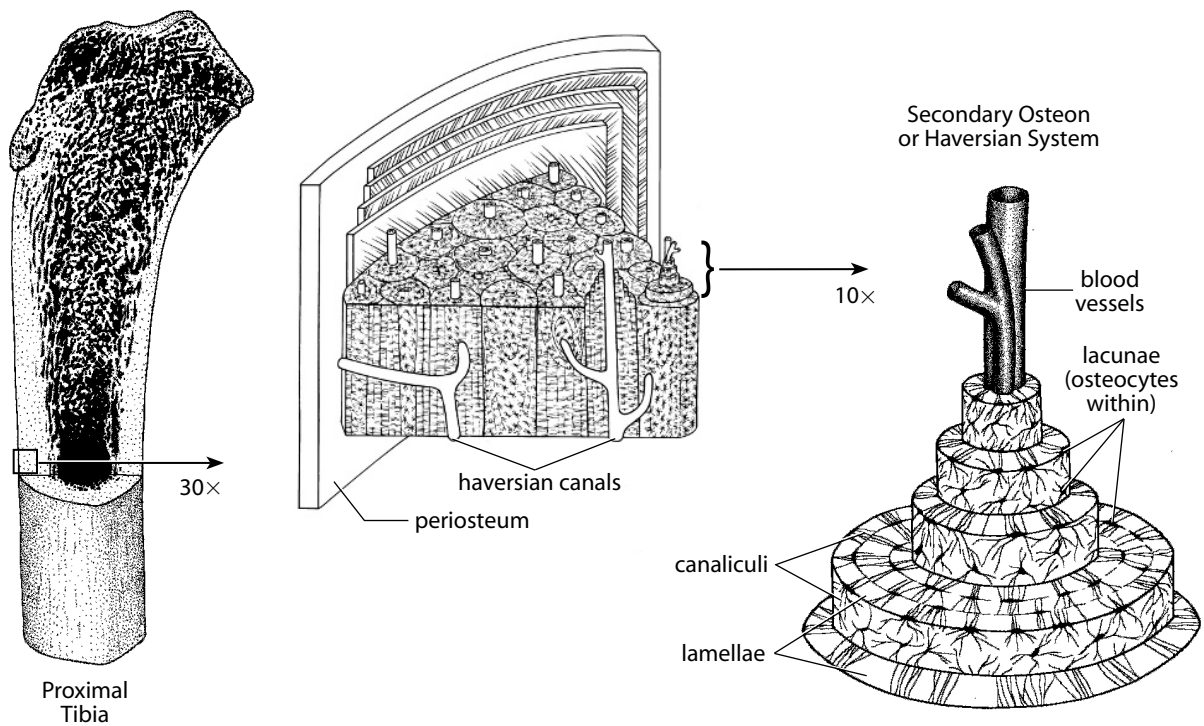


Figure 3.7 Gross and microscopic structure of bone.

3.5 Molecular Structure of Bone

We now turn to an assessment of bones at more basic molecular and cellular levels. No matter what shape a bone takes at the molecular level, its tissue is basically the same in all mammals. Bone tissue, like fiberglass, is a composite of two kinds of materials. The first component is a large protein molecule known as **collagen**, which constitutes about 90% of the organic content of bone. Collagen is the most common protein in the body. Collagen molecules intertwine to form flexible, slightly elastic fibers in bone. The collagen of mature bones is stiffened by a dense inorganic filling of the second component, **hydroxyapatite**. In bone, crystals of this mineral, a form of calcium phosphate, impregnate the collagen matrix. This weave of protein and minerals gives bone its amazing properties. The combination of materials is illustrated by two simple experiments. The mineral component gives bone its hardness and rigidity. When soaked in acid to dissolve these minerals, a bone becomes a rubber-like, flexible structure. However, when a bone is heated to combust the organic collagen, or leached out in some archaeological contexts, it becomes extremely brittle and crumbles.

Characterizations of bone at the molecular level give some clues about its physical properties, but it is important to consider that bone as a tissue must be made and maintained by cells. Bone must be responsive to stress, and it must be capable of growth. A look at the structure of bone above the level of the collagen fibril and associated mineral provides insight into these dimensions of bone function.

3.6 Histology and Metabolism of Bone

Histology is the study of tissues, usually at the microscopic level. There are two histological types of mammalian bone: **immature** and **mature**. Immature bone (**coarsely bundled bone** and **woven bone**) is the first kind of bone to develop in prenatal life. Its existence is usually temporary, as it is replaced with mature bone as growth continues. Immature bone is usually formed rapidly and characterizes the embryonic skeleton, sites of fracture repair, and a variety of bone tumors. It has a relatively higher proportion of osteocytes (see later) than mature bone. Woven bone is the more phylogenetically primitive bone type in evolutionary terms. It is coarse and fibrous in microscopic appearance, with bundles of collagen fibers arranged in a nonoriented, random pattern.

Both compact and trabecular portions of adult bones are made of mature, or **lamellar**, bone tissue, named for the orderly, organized structure produced by the repeated addition of uniform lamellae to bone surfaces during appositional growth. Compact bone is composed of dense bone that cannot be nourished by diffusion from surface blood vessels. **Haversian systems**, with their canals and canaliculi (Figure 3.7; described in this section), are the solution to this problem. In contrast, the more porous trabecular bone receives nutrition from blood vessels in surrounding marrow spaces and lacks haversian systems. Normal adult bone, both compact and trabecular, is histologically lamellar bone. Lamellar bone is usually laid down more slowly than woven bone, which it usually replaces.

Microscopic examination of a transverse section of compact bone in, for example, the tibial shaft reveals the internal structure of haversian bone (Figure 3.7). Such a section resembles an end view of a pile of sawed-off tree trunks. The cross section of each “trunk” often shows approximately four to eight concentric rings, known as **haversian lamellae**. A close examination of each lamella would reveal a bed of parallel collagen fibers. Fibers in successive lamellae, however, are oriented in different directions. This alternation of fiber direction adds strength to the structure.

Each “trunk” in the cross section of compact lamellar bone is known as a **haversian system**, or **secondary osteon**. See Figure 3.8a–3.8c for illustrations and descriptions of osteons. These haversian systems measure about 300 μm (0.3 mm) in diameter and are about 3–5 mm in length.




Figure 3.8a Bone histology. A comparison of primary and secondary osteons (from Paine and Godfrey, 1997). Polarized lighting, 200 \times . The primary osteon is an island with lamellar bone streaming around it; the larger secondary osteon intersects the lamellae of primary cortical bone. A primary osteon is composed of a vascular canal without a cement line (because it does not replace pre-existing bone). The cement line (sheath) and lamellar bone organized around the central canal characterize the secondary osteon, which fills a space left by the disappearance of pre-existing bone.



Figure 3.8b Bone histology. An intact secondary osteon with several fragmentary osteons. Secondary osteons are products of bone remodeling. Polarized lighting, 200 \times .



Figure 3.8c Bone histology. A crowded field of secondary osteons. The large Haversian canals indicate incomplete formation of several osteons. Polarized lighting, 100 \times . See Chapter 19 for a discussion of how analyses of these microscopic histological structures in bone have been employed in individual age assessment. Courtesy of Robert Paine.

They represent the basic structural unit of compact bone, and their long axes parallel that of the long bone of which they are part. Passing through the core of each haversian system is a hollow **haversian canal**, through which blood, lymph, and nerve fibers pass. Additional smaller canals, the **Volkman's canals**, pierce the bone tissue obliquely and at right angles from the periosteal and endosteal surfaces to link the haversian canals, creating a network that supplies blood and lymph to the cells of long bones.

Small cavities found within each lamella are called **lacunae**. Each lacuna harbors an **osteocyte**, a living bone cell. Nutrients are transported to these cells through **canaliculi**, minute fluid-filled channels that radiate from the centrally placed haversian canal to lacunae in succeeding lamellae or from one lacuna to others. These channels in bone tissue enable the living cells to survive in a heavily mineralized environment.

Three primary cell types are involved in forming and maintaining bone tissue. **Osteoblasts** are bone-forming cells responsible for synthesizing and depositing bone material. Osteoblasts are often concentrated just beneath the periosteum. They make large quantities of a material known as **osteoid** (pre-bone tissue), an uncalcified organic matrix rich in collagen. Calcification of bone takes place as crystals of hydroxyapatite, the inorganic component of bone, are deposited into the osteoid matrix. Once surrounded by bony matrix, the osteoblasts are called **osteocytes**, cells that reside in lacunae and are responsible for maintaining bone tissue. **Osteoclasts** are responsible for the **resorption** (removal) of bone tissue. All skeletal elements change dramatically during ontogeny and continue to be capable of change in adulthood. Bone formation takes place throughout life. The reshaping, or remodeling, of bone takes place at the cellular level as osteoclasts remove bone tissue and osteoblasts build bone tissue. The opposing processes of bone formation and resorption allow bones to maintain or change their shape and size during growth. Some osteologists distinguish between “modeling” as bone sculpting during growth and “remodeling” as the process of continuous removal and replacement of bone during life.

3.7 Bone Growth

The histological situation described in Section 3.6 accounts for the metabolism of bone and the plasticity of bone in the adult. During ontogeny, however, the skeleton undergoes tremendous growth. Osteocytes do not divide. Because bone matrix calcifies soon after being produced, the tissue cannot undergo further expansion from within. As a consequence, all bone growth is the result of bone deposition on a pre-existing surface. Indeed, bone always develops by replacement of a preexisting connective tissue. Embryologically, bone development (**osteogenesis**, or ossification) occurs in two basic settings. In **intramembranous ossification**, bones, particularly the frontal and parietal bones of the cranial vault, ossify by apposition on tissue within an embryonic connective tissue membrane. Most bones in the skeleton, however, grow through a process known as **endochondral ossification**, in which bones are preceded by cartilage precursors called cartilage models. Early in its development, *in utero*, the skeleton is flexible, but ossification is initiated before birth. Visible elements of the early skeleton are mostly composed of cartilage, a material that is good for rapid growth in an environment where the functions of support are not yet necessary. Cartilage is composed mostly of collagen and, unlike bone, it is flexible and avascular in the adult. The only difference between the two distinct mechanisms of ossification is the environment in which ossification occurs. There is no difference between the kind of bone produced.

Fetal ribs, vertebrae, the basicranium, and limb bones begin as cartilage models. Ossification occurs within the cartilage model as it is penetrated by blood vessels. Growth radiates from the location of the initial penetration, which becomes the **nutrient foramen**. A thin membrane called the **perichondrium** surrounds the cartilage model of the long bone. Osteoblasts just beneath the perichondrium in the fetal long bone begin to deposit bone around the outside of the cartilage shaft. Once this occurs, this membrane is called the **periosteum**, a fibrous connective

tissue, which in turn deposits more bone, layer by layer. As the diameter of the growing long bone shaft increases, osteoclasts on the endosteal surface remove bone and osteoblasts in the periosteum deposit bone. Thus, **appositional growth** allows shaft diameters to enlarge during development. The compact bone of an adult limb bone shaft is periosteal in origin, the original immature shaft having been removed by osteoclasts to form an enlarged medullary cavity. Slow subperiosteal apposition continues throughout life after an adolescent “growth spurt” (Garn, 1972; Garn et al., 1992).

Meanwhile, the developing long bone must also grow in length. During growth, the roughened, porous, usually irregular end of an immature long bone’s metaphysis marks the region at which most longitudinal growth occurs. Sandwiched between the metaphysis (the primary center of ossification) and the epiphysis (the secondary center of ossification) during development is a cartilaginous center known as the **growth plate (epiphyseal plate)**, a tissue layer responsible for bone formation. This plate, a layer of cartilage, “grows” away from the shaft center. The growing cartilage is replaced by bone on the diaphyseal side of the plate. As the individual grows, the epiphyseal plate is pushed farther from the primary growth center of the bone (the shaft), lengthening the bone. Ossification and growth of the bone come to a halt when cells at the growth plate stop dividing, and the epiphysis fuses with the metaphysis of the shaft. Because the ends of the long bone flare, substantial remodeling occurs as the bone lengthens during this process (Figure 3.9).

At 11 weeks before birth there are usually about 800 ossification centers, the “bony pieces” of the skeleton. At birth there are about 350 centers. As a rule, “primary” centers appear before birth, and “secondary” centers appear after birth. The secondary center at the lower end of the femur (upper leg bone) and the one atop the tibia (lower leg bone) begin to appear just prior to

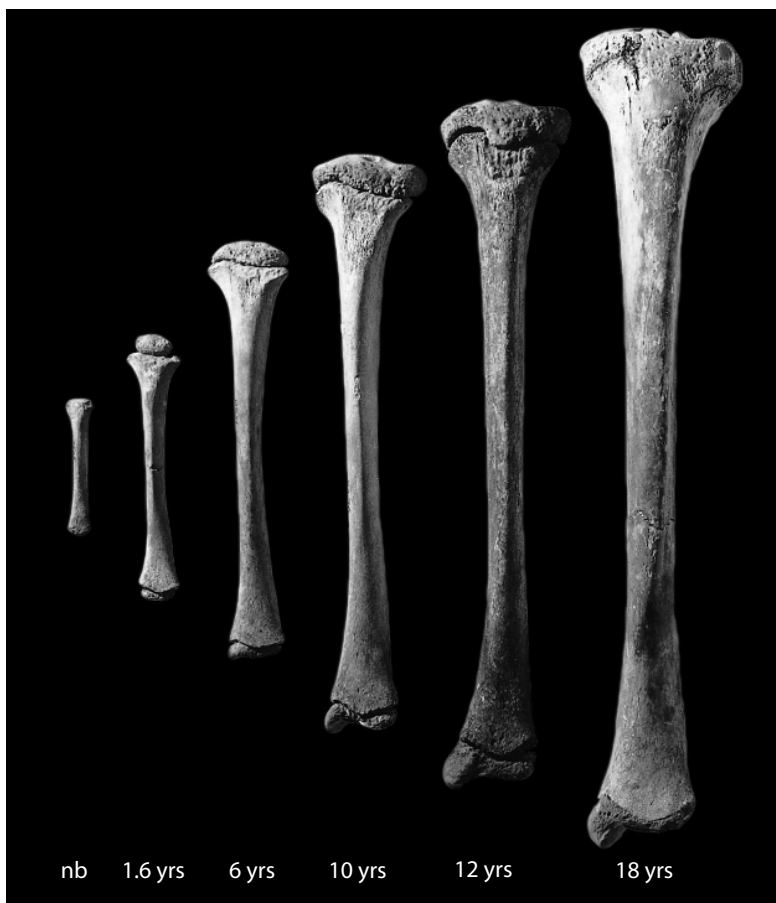

Figure 3.9 Bone growth. Growth series for the left human tibia (lower leg bone). The tibia on the far left is that of a newborn child. Larger specimens to the right are from individuals of ages 1.6, 6, 10, 12, and 18 years. Specimens are shown in anterior view, with the proximal (top) end of the bone toward the top of the page. One-fourth natural size.

birth. Most long bones develop two secondary centers in addition to the primary centers of ossification. A few long bones develop a secondary center at one end only, and typical wrist and ankle bones ossify entirely from their primary centers. By adulthood, all of the primary and secondary centers have fused to yield the average adult human complement of 206 elements, the bones of the adult human skeleton. These bones are listed in Chapter 2, Figure 2.1.

3.8 Morphogenesis

Developmental biology is currently a hyperactive field due to the application of molecular techniques to the age-old problem of how form is produced. Discoveries in molecular biology, embryonic limb development, amphibian limb regeneration, cell–cell communication, and the structure and expression of **morphogens**, growth factors, and **homeobox**-containing genes have rapidly advanced knowledge about how form is shaped during ontogeny.

As Müller (1997) points out, “self-construction” and “self-organization” are terms that convey the essential properties of development. All humans start with a single, apparently unstructured cell, the fertilized egg. Embryogenesis follows, and then birth and further development. At the end of the process, the fully developed human is an organism with an intricately wired brain that contains over a hundred trillion synaptic contacts that help make it possible for us to ask how the complex shapes and sizes of the human skeleton are encoded and how that code is translated by cells during development. Cells differentiate, communicate, and interact morphologically and functionally. Together they construct multicellular structures such as bones.

The shaping of form, or **morphogenesis**, from simple, seemingly amorphous, generative, starting cells has puzzled biologists and philosophers alike. A big step toward solving the problem came when it was demonstrated that DNA acted as a genetic code. The genome contains information about how to make distinct proteins, rRNA, tRNA, and how to replicate itself. It contains elements of a spatiotemporal program that controls the order and pattern of gene expression. As Gilbert and Singer (2010) point out, we are still trying to uncover the details of how a developing human is created on the basis of such minimal information (approximately 20,000–25,000 genes in a human). We know that different combinations of genes become effective in time and space in different cells, organs, and body regions. We know that cells interact, influencing each other. For example, a fracture of the adult humerus will stimulate production of bone and healing, but there was no way that the fertilized egg could “know” in advance that any individual’s humerus would be fractured at a particular time in adult life.

Basic events in animal development include cell proliferation (recurring cell division), cell differentiation (which occurs in a defined spatial order), and **pattern formation** (the spatiotemporal ordering of molecules, cells, or tissues to form a pattern, which can then develop at different scales). This is the process whereby spatial organization of cell differentiation is controlled. Cells obtain positional information by virtue of their location within a tissue. Cells move, migrate, and die according to genetically determined schedules. All of these events are important in morphogenesis, a process tightly choreographed by highly conserved genes and gene arrays.

Bone develops originally from embryonic mesenchymal stem cells that have a very broad range of development potentialities (they are **pluripotent**), giving rise to fat, muscle, and other cells. Along the road to their differentiation into bone-producing cells, a population of cells with more limited potential is formed. These are only able to proliferate into chondroblasts or osteoblasts. These osteoprogenitor cells persist throughout postnatal life and are found in the endosteum and periosteum. They are most active during bone growth but can be reactivated in adult life when fracture repair is initiated (Section 3.9).

During embryogenesis, an **anlage**, or aggregation of cells indicating the first trace of an organ, forms. Recent work in limb development has begun to unravel the process through which an integrated system of sequentially expressed genes and/or gene arrays guides development of the limb assigning positional address by morphogens (molecules that influence morphogenesis),

growth factors, signaling molecules, and homeoboxes (a family of highly conserved base pair sequences of the DNA that encode small proteins that activate specific genes). The homeobox sequence is preserved with only minor modifications in a wide variety of animals, and is very similar in fruit flies, birds, and mammals.

It is already clear that development of a limb is guided by morphologic data sequestered in highly systematic gene arrays and implemented by stereotyped and largely universal cellular response regimens. For example, implantation of a single acrylic bead soaked in the protein fibroblast growth factor and subsequently placed in the flank of an early chick embryo can trigger the formation of an entire new limb. It now appears that most sculpting of the skeletal frame occurs during the earliest phases of embryogenesis. Once the anlage is formed, further skeletal development appears to be directed primarily by the influence of stress history on gene expression by what may be called “assembly rules.” These guide the behavior of each connective tissue cell during this process. For the functional morphologist, these insights into morphogenesis have fundamental implications (Lovejoy et al., 1999, 2003). What this means to the practicing osteologist is that much individual skeletal variation is the product of the interaction of the environment with these assembly rules rather than a direct readout of some gene(s). For example, the expression of an intertrochanteric line on the femur (Section 12.1.1d) represents an individual variation rather than a species-specific, genetically encoded trait.

3.9 Bone Repair

Bones occasionally break, or **fracture**, when subjected to abnormal stresses or when bone is weakened pathologically. The process of repair begins as soon as the fracture occurs. Blood vessels in the haversian canals, the periosteum, and the marrow are usually ruptured by a fracture. Blood flows into the fracture zone and normally forms a **hematoma** (bloody mass) that coagulates as the blood vessels are sealed off. The periosteum is usually torn at the fracture site and pulled away from ends of the broken bones. This stimulates the osteogenic layer of the periosteum to begin forming a **callus**, fracture repair tissue that forms a sort of natural splint. The callus first consists of fibrous connective tissue that bridges the broken bone surfaces, tying them together. Within two days the osteoblasts respond, and the callus is subsequently mineralized to form woven bone, the **primary bony callus**. The primary bony callus takes about six weeks to develop. Later, this woven bone callus is converted to lamellar bone. If orientation of the broken bone ends is close to the original, and if subsequent movement at the fracture site is limited (especially by immobilizing the bone), the callus may become so remodeled that evidence of fracture is eventually present only in radiographs. Further remodeling may completely eliminate any evidence of the fracture. Chapter 19 illustrates some effects of fracture in bone. Recent clinical work has shown that proteins known as bone morphogenetic proteins (BMPs) can be combined with a matrix composed partly of demineralized collagen and applied to serious fractures to speed healing (De Biase and Capanna, 2007).

In a fascinating intersection of applied and basic research, it turns out that these proteins are produced by genes belonging to a very ancient family — genes homologous to those in fruit flies. The nightmarish disease called fibrodysplasia ossificans progressiva (FOP) is a heritable disorder of connective tissue characterized by congenital malformation of the large toes and progressive, disabling endochondral osteogenesis in predictable anatomical patterns. Disease progression brings fusion of adjacent bones of the spine, limbs, thorax, and skull, leading to immobilization (Figure 3.10). Disease flare-ups can occur spontaneously or can be induced by minor trauma such as intramuscular drug injections. This abnormal bone buildup occurs because the FOP patient’s white blood cells erroneously manufacture BMP-3, triggering inappropriate heterotopic (“other” + “place”) bone growth at sites of injury (Shafritz et al., 1996).

A mutation in the ACVR1 (activin receptor type-1) gene was found to be the cause of FOP (Shore et al., 2006). The ACVR1 mutation (called R206H ACVR1) results in a change to one of

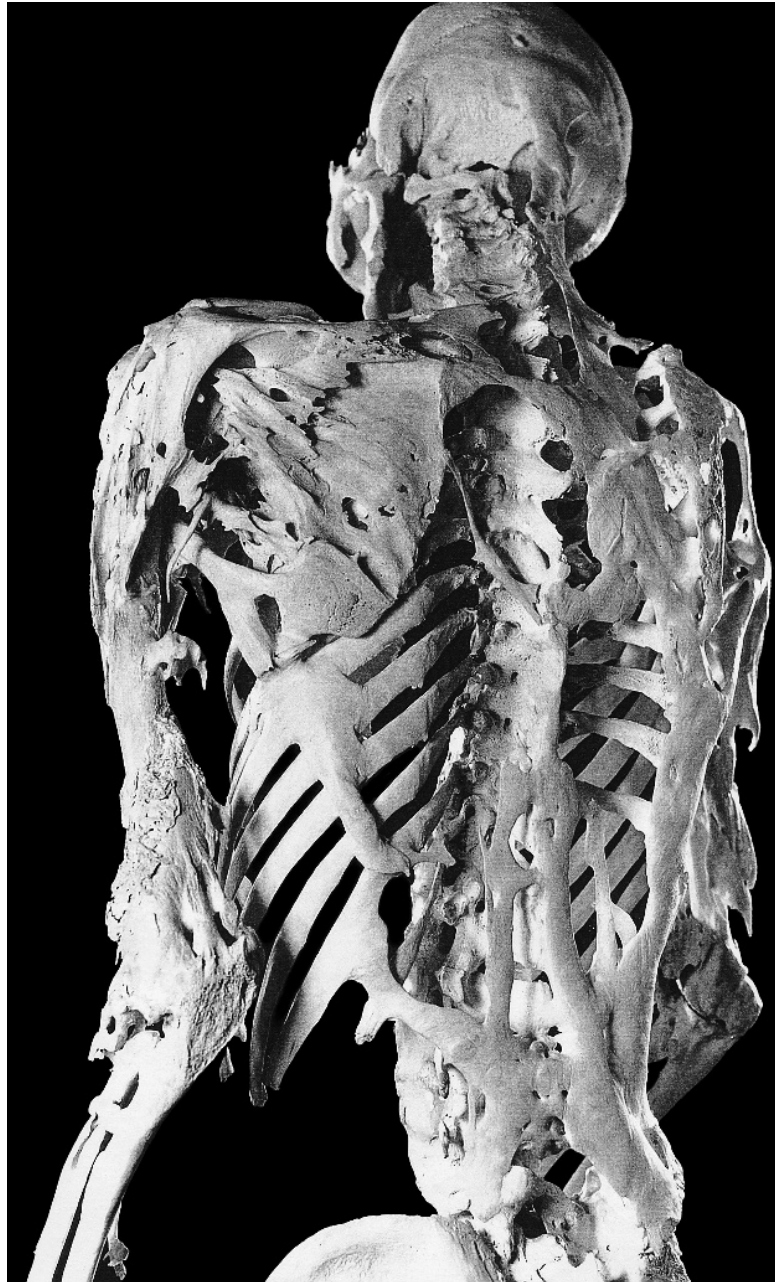


Figure 3.10 Advanced bony manifestations of fibrodysplasia ossificans progressiva in a 39-year-old man. See Section 3.9 for details. Courtesy of Fred Kaplan, Mütter Museum, College of Physicians of Philadelphia (Shafritz et al., 1996).

the gene's 509 amino acids. In people with FOP, the mutation causes amino acid position 206 to code for the amino acid arginine instead the amino acid histidine. This small change to the ACVR1 gene, an important BMP signaling switch for the cartilage cells in metaphyses, as well as in skeletal muscle, is all that is needed to start turning skeletal muscle into bone and imprison its victims in a "second skeleton." The precise molecular physiology of the R206H ACVR1 mutation is still being investigated, with the hope of finding a treatment and eventual cure for FOP. Such remarkable findings at the intersection of basic research in molecular genetics and applied research in the medical clinic are now commonplace in biology. They hold out the promise to allow a fuller understanding of how skeletal form develops and how broken bones can be healed.

Suggested Further Readings

Active research into bone biology at all levels renders many older texts obsolete. The sources below provide supplementation to the discussion presented above.

Bilezikian, J. P., Raisz, L. G., and Martin, T. J. (2008) *Principles of bone biology* (3rd ed.). San Diego, CA: Elsevier. 1900 pp. in 2 volumes

A comprehensive reference to nearly all aspects of modern bone biology.

Bronner, F., and Farach-Carson, M. C. (2003) *Bone formation*. London, UK: Springer-Verlag. 160 pp.

An edited volume covering the current state of research into the cellular mechanisms of regulation, bone growth, and bone disorders.

Currey, J. (2002) *Bones: Structure and mechanics*. Princeton, NJ: Princeton University Press. 456 pp.

An excellent and approachable text on the biological and mechanical properties of bone.

Fawcett, D. W., and Jensch, R. P. (2002) *Bloom & Fawcett: Concise histology* (2nd ed.). New York, NY: Arnold. 352 pp.

A comprehensive textbook with chapters on cartilage, bone, and teeth, with fine illustrations.

Gilbert, S. F., and Singer, S. R. (2010) *Developmental biology* (9th ed.). Sunderland, MA: Sinauer Associates. 685 pp.

A thorough introduction to the major topics in contemporary developmental biology.

Hall, B. K. (2005) *Bones and cartilage: Developmental and evolutionary skeletal biology*. San Diego, CA: Elsevier Academic Press. 792 pp.

An in-depth review of the major topics in bone and cartilage research. Interesting, accessible, and well-illustrated introduction to both the growth of bone and its evolutionary origins.

Minelli, A. (2009) *Forms of becoming: The evolutionary biology of development*. Princeton, NJ: Princeton University Press. 242 pp.

An accessible introduction to the principles of modern evolutionary developmental biology.

Ogden, J. A. (1990) Histogenesis of the musculoskeletal system. In: D. J. Simmons (Ed.) *Nutrition and bone development*. Pp. 3–36. New York, NY: Oxford University Press.

An excellent review of bone development.

Ortner, D. J. (2003) *Identification of pathological conditions in human skeletal remains* (2nd ed.) San Diego, CA: Academic Press. 645 pp.

This illustrated text includes a good chapter on the biology of skeletal tissues.

Zollikofer, C. P. E., and Ponce de León, M. S. (2010) The evolution of hominin ontogenies. *Seminars in Cell and Developmental Biology* 21: 441–452.

An introduction to the emerging, synthetic field of evolutionary developmental paleoanthropology.

Chapter 4

SKULL: CRANIUM AND MANDIBLE

THE BONES OF THE HUMAN SKULL can be divided into three basic types, with the bones of each type being derivatives of specific structures in or around the head of our aquatic ancestors. Most bones of the skull base lie underneath the brain and are at least partly preformed in cartilage. These bones represent the primitive vertebrate braincase. The facial bones and bones of the roof and sides of the skull are dermal bones, formed in sheets of connective tissue under the skin. Dermal bone served as an armor plating for the primitive fishes, especially as a protective covering for the vital head parts. The rest of the bones of the skull are derived from the gill arches of primitive fish ancestors. Primitive vertebrates had no jaws. The earliest jaws were derived from the first, or mandibular, gill arch. Bones of this structure moved forward under the braincase to become the upper and lower jaws. These primitive jaws became sheathed in, and were eventually replaced by, dermal bones. Meanwhile, original gill arch bones migrated to the middle ear region, where they became two of the three tiny bones associated with hearing.

The skull is the most complex portion of the skeleton and is of major importance in human osteology. It is one of the keys to aging, sexing, and understanding the evolutionary history of hominids. The complexity of the human skull can best be understood by recognizing the widely differing functions it performs. It forms the bony foundation for the senses of sight, smell, taste, and hearing. It houses and protects the brain. In addition, the skull forms the framework of the chewing apparatus. Given these varied functions, it is no wonder that the skull is a complex structure.

Before moving to a detailed consideration of the individual bones of the skull, it is useful to consider this part of the anatomy as a unit (Figures 4.1–4.7). The following terms refer to some of the most convenient landmarks to use when considering the skull as a whole. The eye sockets are the **orbits**. The hole between and below the orbits, the nose hole, is the **anterior nasal aperture**, or **piriform aperture**. The ear holes are **external acoustic meati** (the singular is **meatus**), and the large oval hole in the base of the skull is the **foramen magnum**. The thin bony bridges at the sides of the skull are the **zygomatic arches**. The teeth are part of the skull, but because of their importance and peculiar anatomy an entire chapter is devoted to them (Chapter 5).

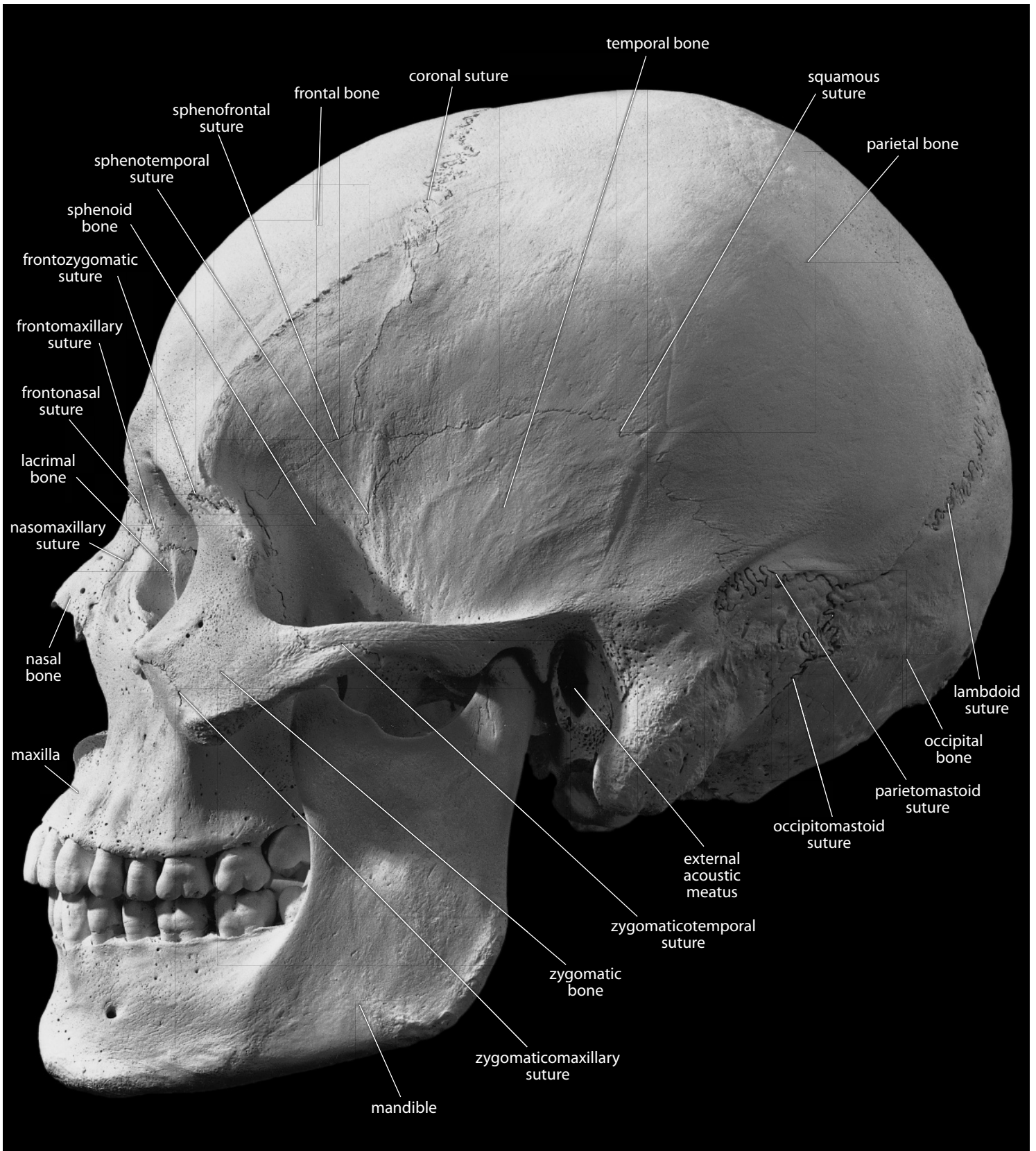


Figure 4.1 Adult male skull, lateral. Natural size.

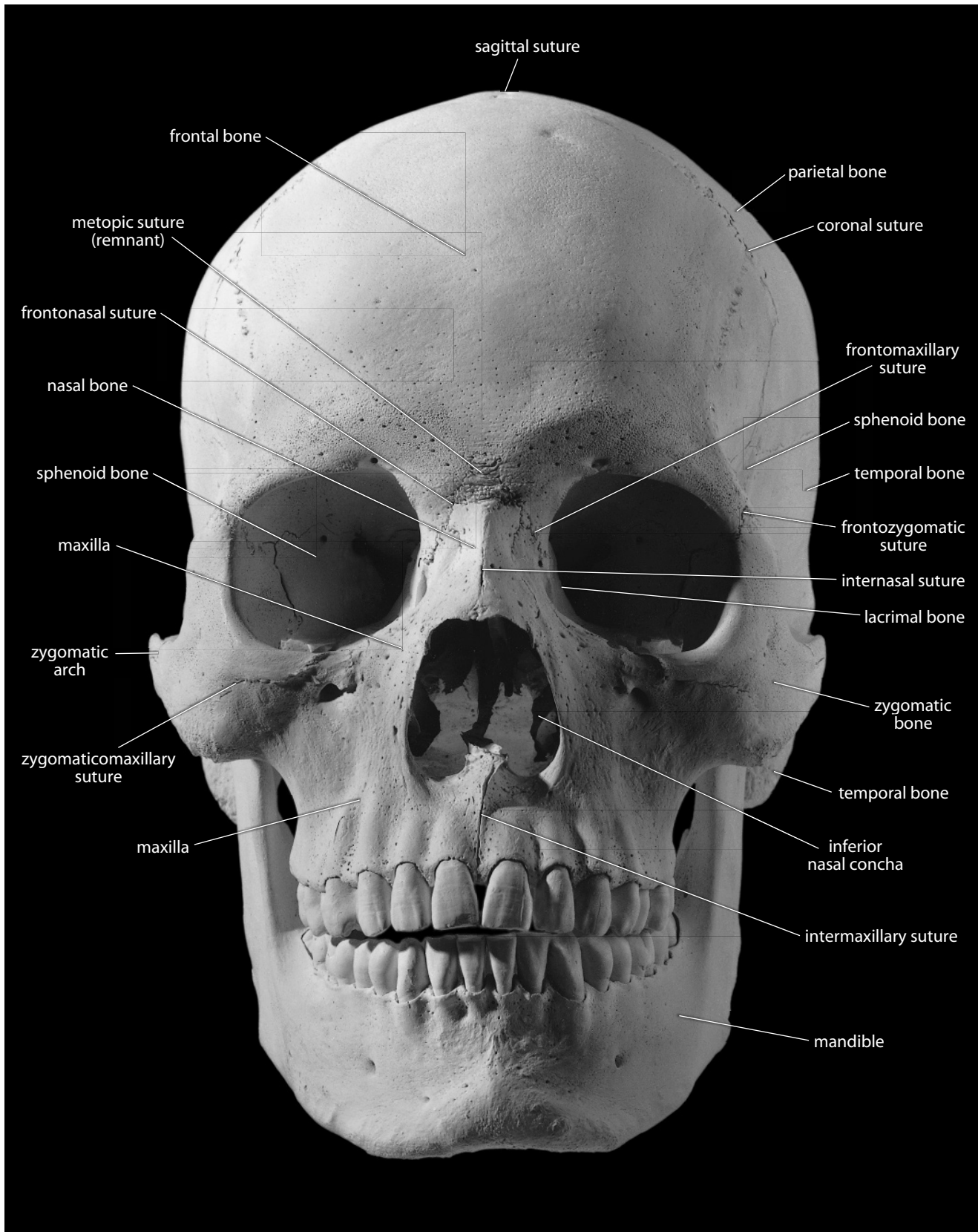


Figure 4.2 Adult male skull, anterior. Natural size.

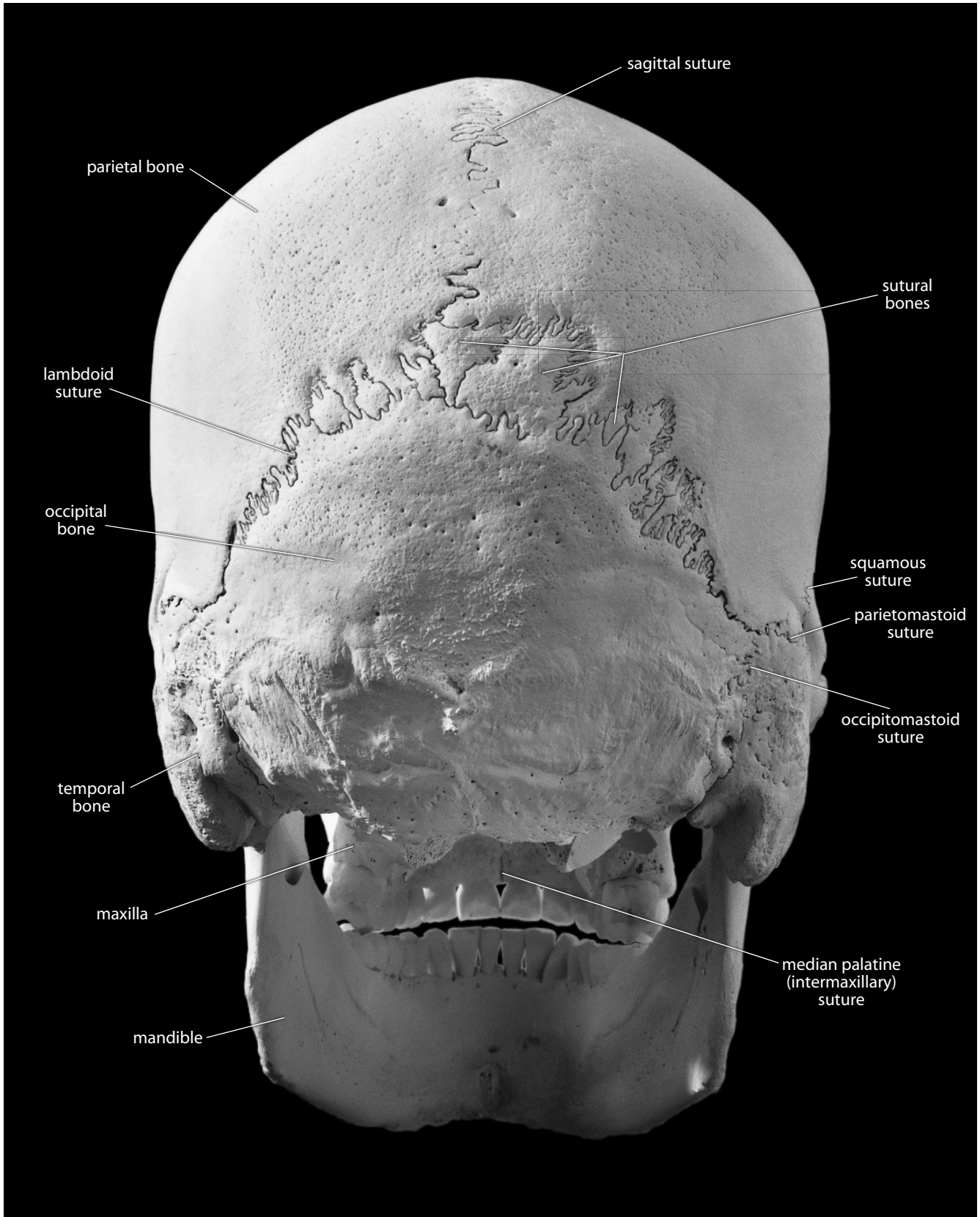


Figure 4.3 Adult male skull, posterior. Natural size.

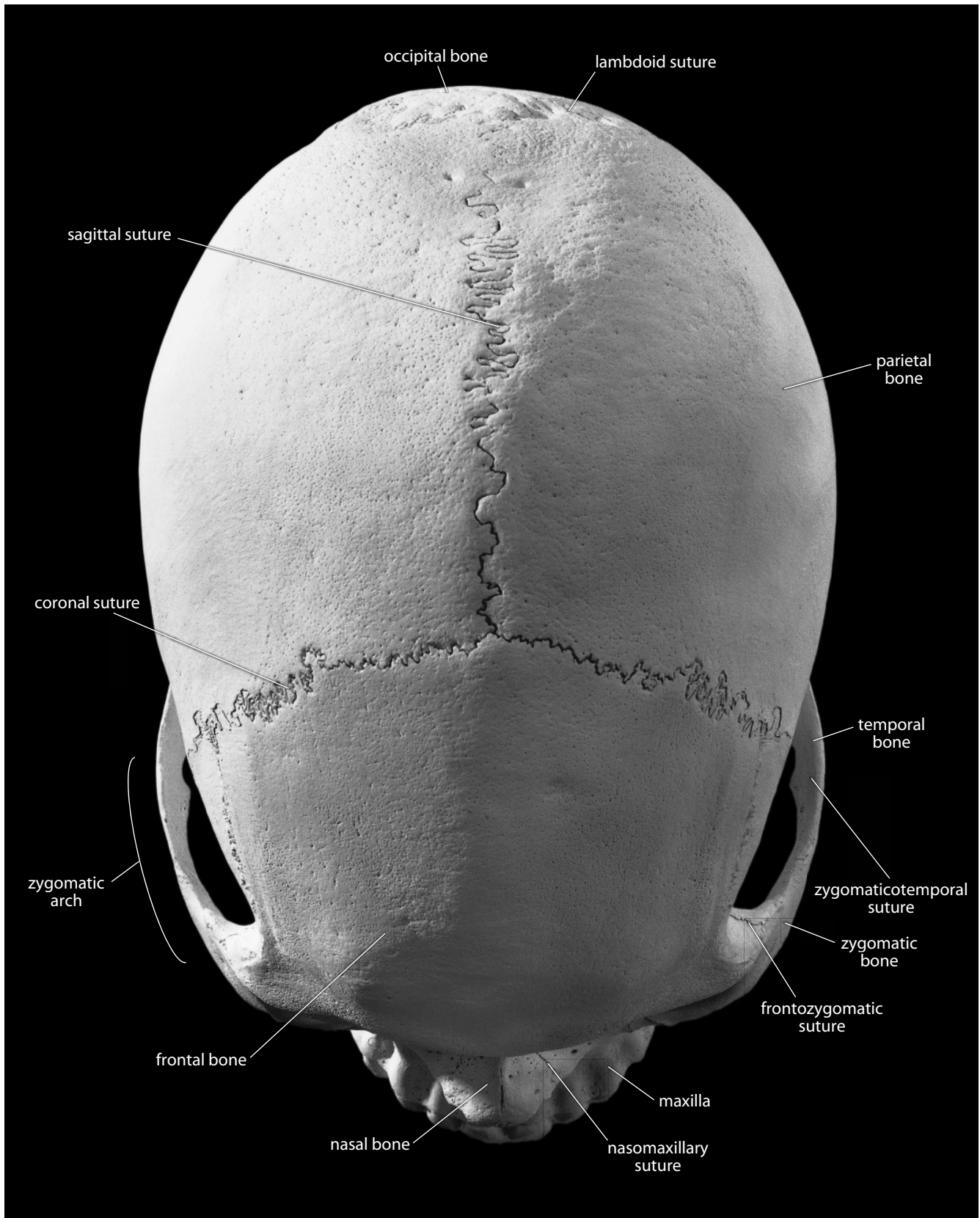


Figure 4.4 Adult male cranium, superior. Natural size.

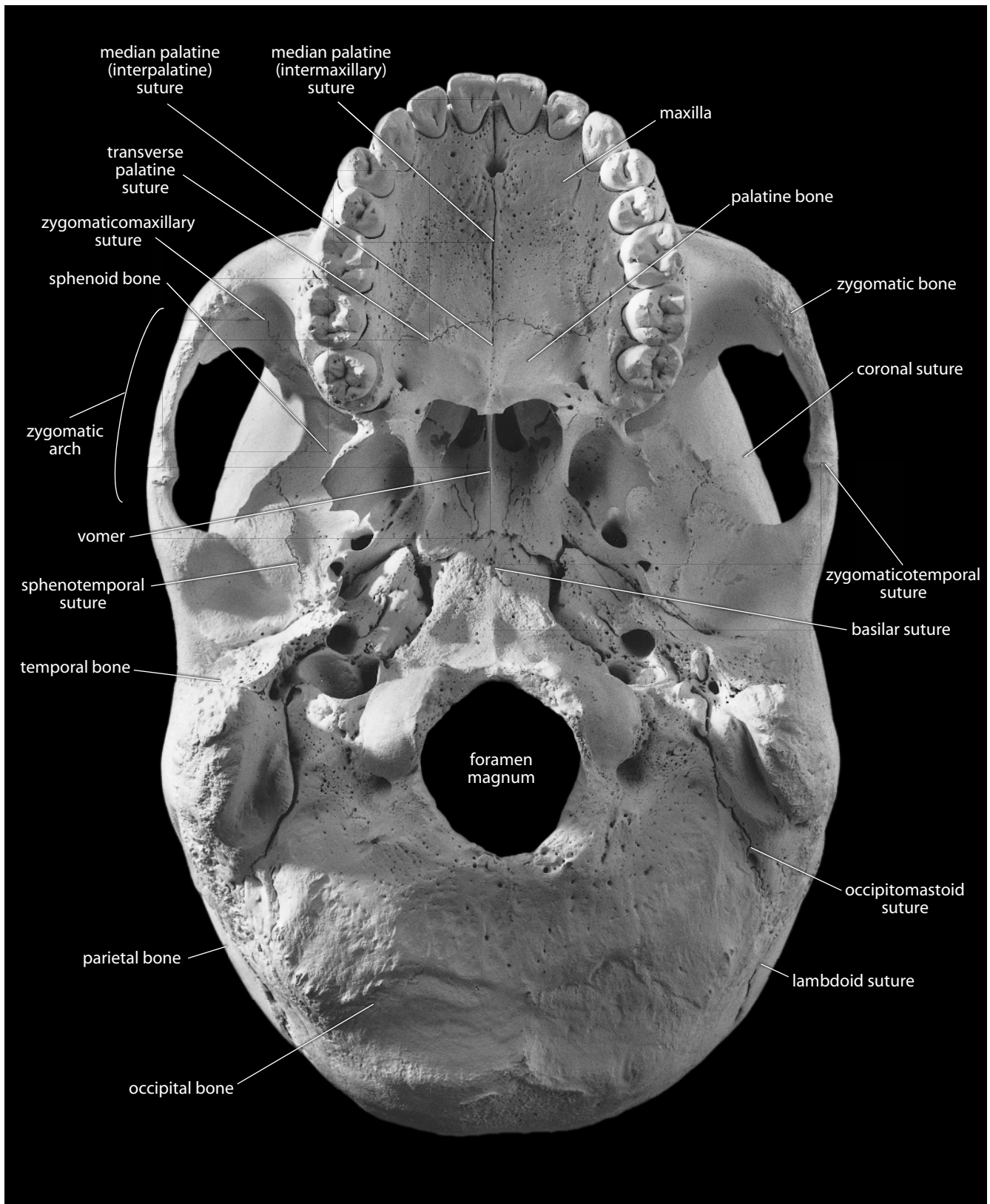


Figure 4.5 Adult male cranium, inferior. Natural size.

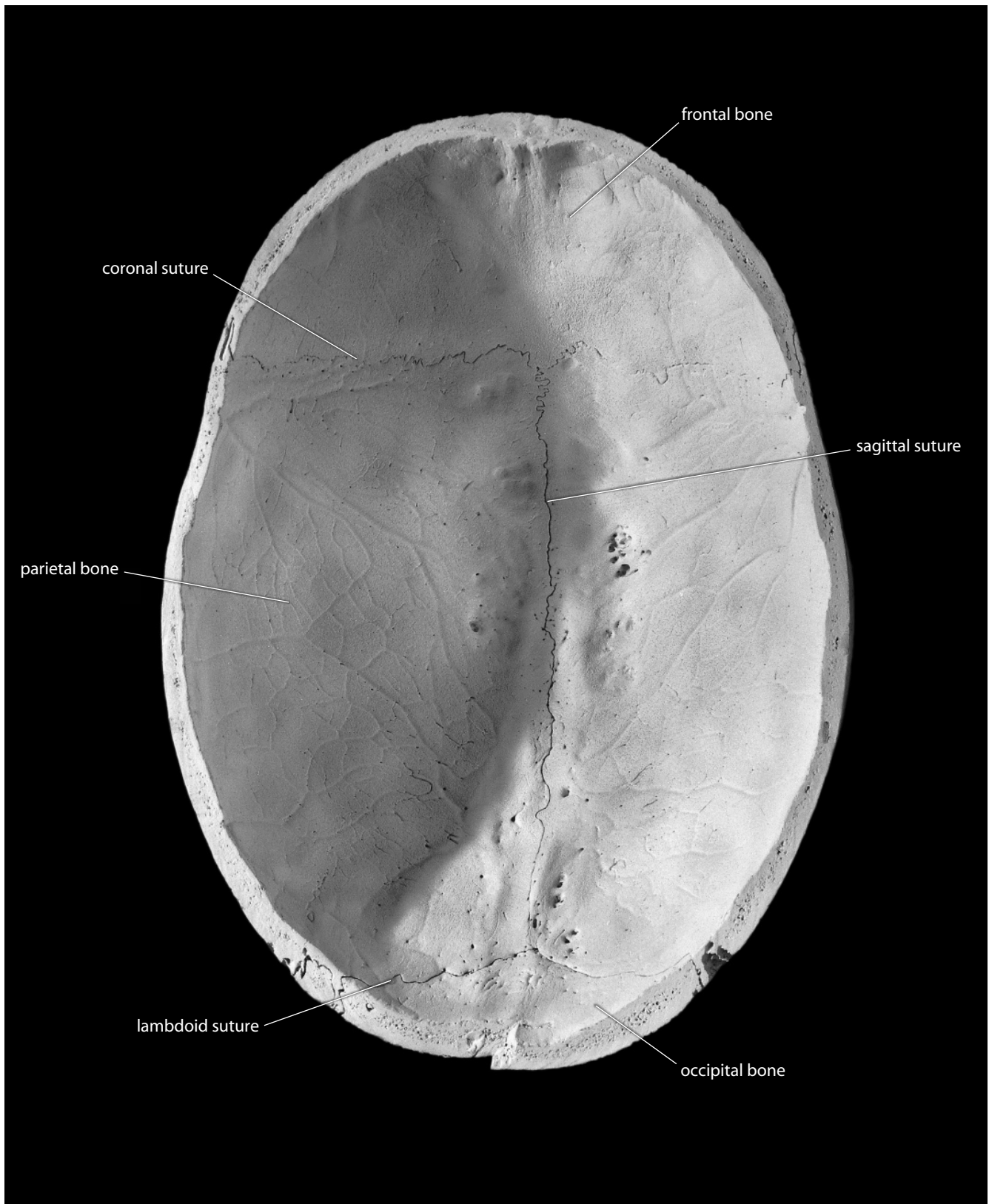


Figure 4.6 Adult male cranium, endocranial, superior part. Natural size.

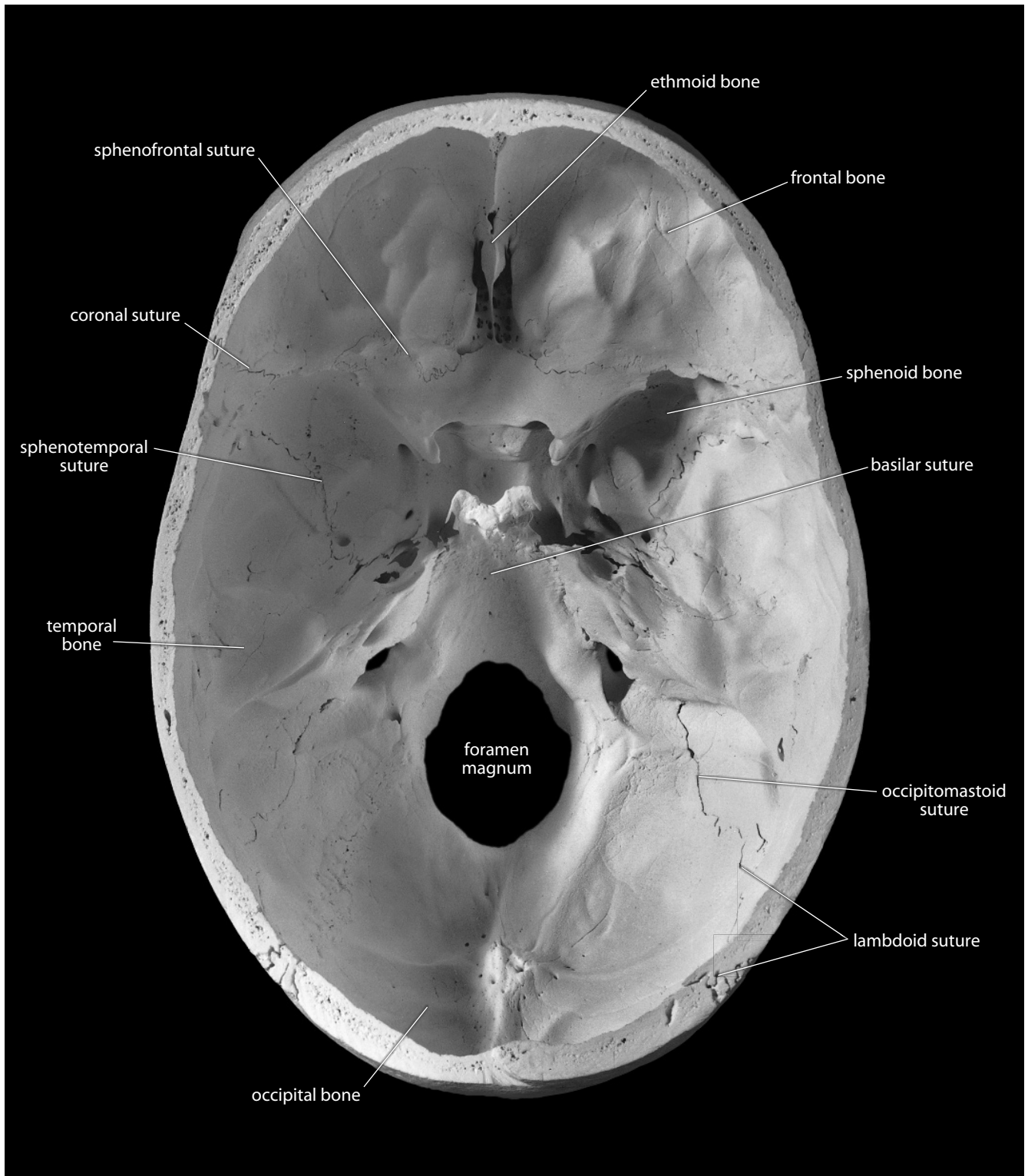


Figure 4.7 Adult male cranium, endocranial, inferior part. Natural size.

4.1 Handling the Skull

In addition to being one of the most complex parts of the skeleton, some of the elements of the skull are also the most delicate. During study, the skull should be handled above a padded surface and stabilized against rolling on the surface by means of sandbags or cloth rings designed for this purpose. It is rarely necessary to store or manipulate the lower jaw in its natural anatomical position relative to the upper jaw. When this position is called for, however, note that the colliding upper and lower teeth are fragile and susceptible to chipping. Care should be exercised when occluding the upper and lower jaws in this fashion, and padding should always be placed between the teeth if the skull is stored in this position.

In handling the skull, always use common sense and both hands. A finger or thumb placed in and behind the foramen magnum will not damage the bone, but other openings, such as the orbits or zygomatic arches, are more fragile and should never be used as gripping surfaces. In addition to the thin bones within the orbits, those delicate parts that are susceptible to damage during cranial manipulation include the edges and insides of the nasal aperture as well as the thin, projecting pterygoid plates and styloid processes at the base of the skull. If a tooth becomes dislodged during study, place it into a clear plastic bag and label the bag with the specimen number and the position of the tooth.

The temptation to test the mechanical properties of dry bone by probing, twisting, poking, stabbing, shaking, or scraping should always be resisted. However, in the course of handling osteological material, breakage does occur. Fortunately, it is normally a simple matter to glue the bone back together. This should be done promptly by the laboratory supervisor so that the broken pieces are not lost permanently (Chapter 16).

4.2 Elements of the Skull

The term “skull” is often misused in common speech. Terms such as this have very specific meanings to anatomists and osteologists. It is worthwhile to review the proper use of terminology.

- The **skull** is the entire bony framework of the head, including the lower jaw.
- The **mandible** is the lower jaw.
- The **cranium** is the skull without the mandible.
- The **calvaria** (or **calvarium**) is the cranium without the face.
- The **calotte** is the calvaria without the base.
- The **splanchnocranium** is the facial skeleton.
- The **neurocranium** is the braincase.

The three basic divisions of the endocranial surface at the base of the neurocranium correspond to the topography of the base of the brain. These anterior, middle, and posterior cranial fossae are respectively occupied by the frontal lobes, temporal lobes, and cerebellum of the brain.

When the ear ossicles (three pairs of tiny bones associated with hearing) are included and the hyoid excluded, there are usually 28 bones in the adult human skull. Distinguishing these bones is occasionally made difficult because some of them fuse together during adult life. For this reason, it is advisable to begin study with young adult specimens, in which the bones are most readily recognizable. In addition to the 28 normal skull bones, there are often **sutural bones** (also called **Wormian bones**, or **extrasutural bones**), which are irregular ossicles that occur along some sutures. A large, triangular **inca bone** is occasionally found at the rear of human crania.

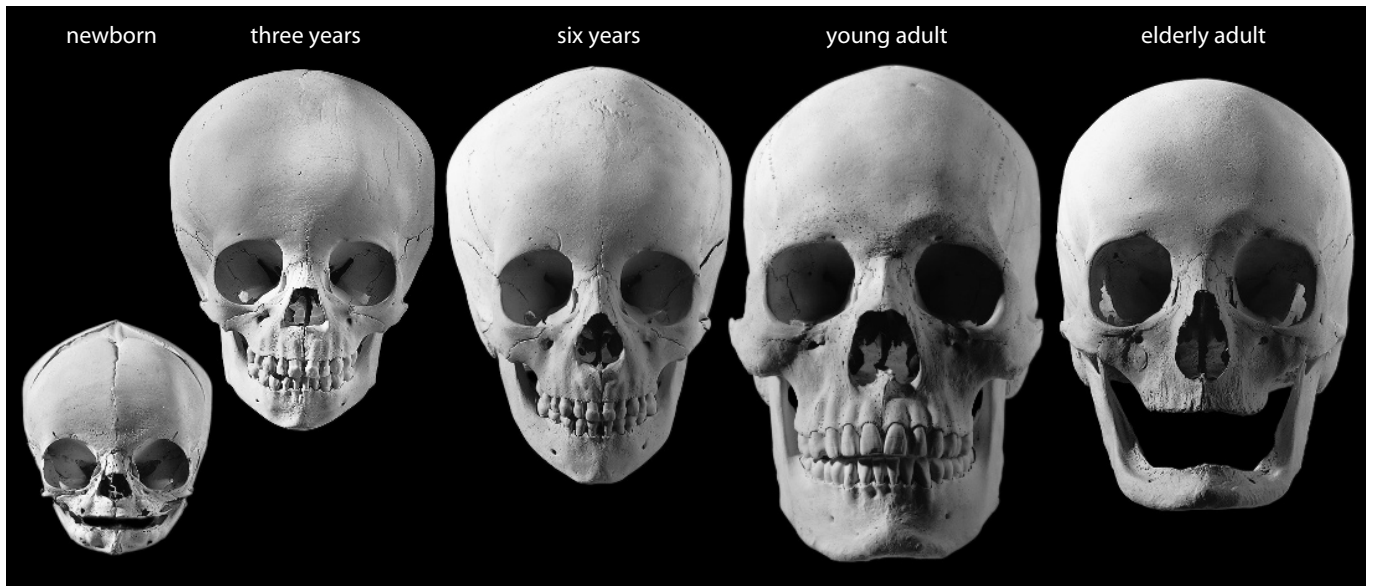


Figure 4.8 **Growth in the human skull.** (*Above and opposite*) Note the change in proportions of face and vault through the series. All specimens are shown in facial and lateral views. Approximately one-third natural size.

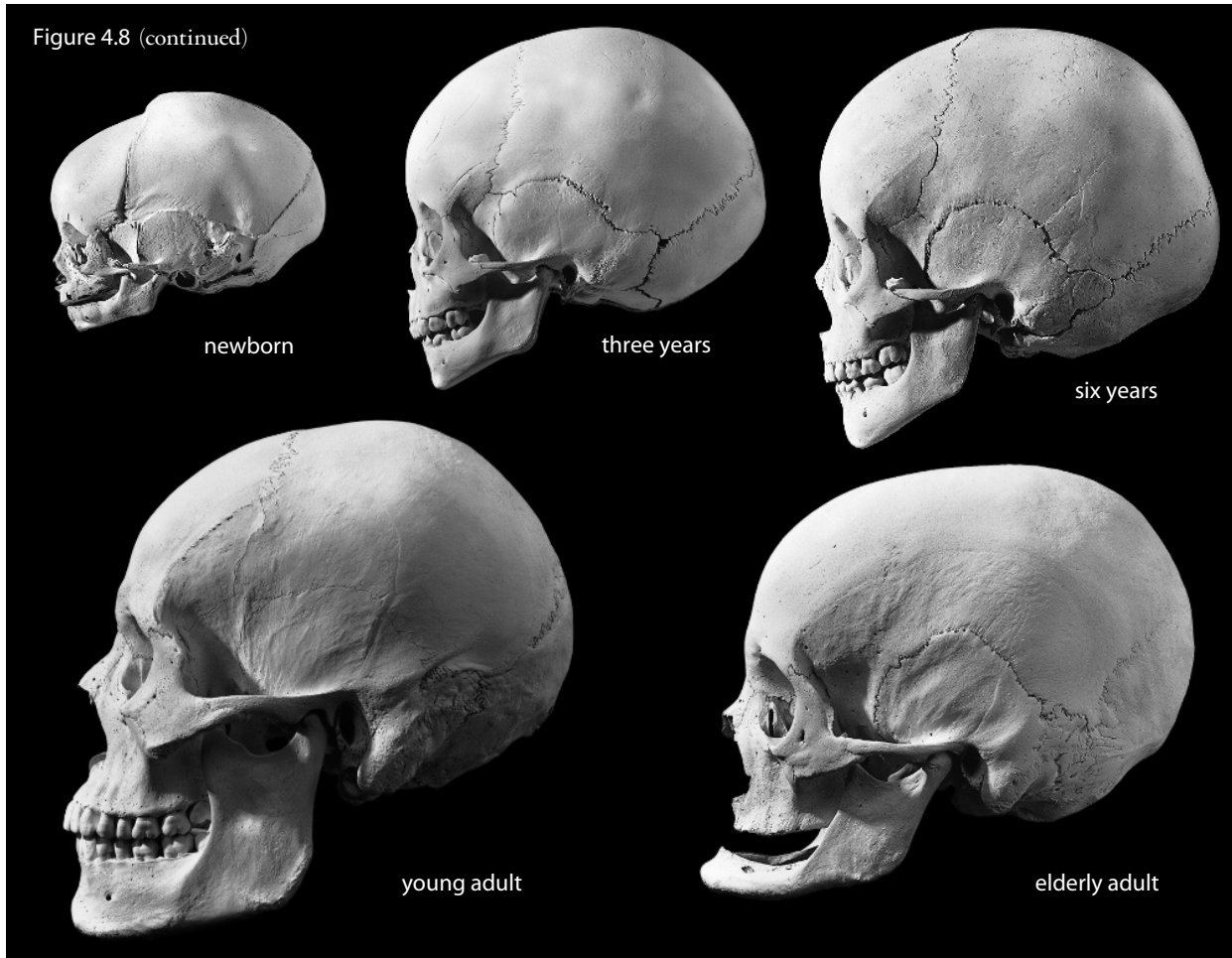
4.3 Growth and Architecture, Sutures and Sinuses

The human skull is a fascinating structure when viewed from a phylogenetic perspective. In early vertebrates, two kinds of bone evolved, **dermal bone** and **cartilage-replacement bone**. The modern human skull is derived from both kinds of bone. Dermal bones form the sides and roof of the skull and make up the facial skeleton. The bones of the cranial base, known collectively as the **basicranium**, are mostly preformed in cartilage: the **ethmoid bone** surrounds the olfactory apparatus and nerves, the **sphenoid bone** surrounds the optic nerves, the two **temporal bones** surround the auditory system, and the **occipital bone** surrounds the spinal cord. Some bones, like the occipital, sphenoid, and temporal, combine dermal and cartilage-replacement portions. The remaining bones in the skull (mandible, greater wings of the sphenoid, ear ossicles, hyoid) are derived from the gill arches of primitive vertebrates.

At birth the skull is made up of 45 separate elements and is large relative to other parts of the body. The facial part of the newborn skull, however, is relatively small, reflecting the dominance of brain development at this stage of maturation. The face “catches up” to the neurocranium as development, particularly in the mandible and maxilla, proceeds. Important stages in the development of the skull include emergence of the first set of teeth (between the ages of 6 and 24 months), the emergence of the permanent teeth (beginning at about 6 years), and puberty. Figure 4.8 illustrates growth of the skull.

In the adult, the skull bones contact along joints with interlocking, sawtooth, or zipper-like articulations called **sutures**. Many of these sutures derive their name directly from the two bones that contact across them. For example, **zygomaticomaxillary sutures** are sutures between the zygomatics and maxillae, and **frontonasal sutures** are short sutures between the frontal and nasals. Some sutures have special names. The **sagittal suture** passes down the midline between the parietal bones. The **metopic** (or **frontal**) **suture** passes between unfused frontal halves and only rarely persists into adulthood. The **coronal suture** lies between the frontal and parietals. The **lambdoid** (or **lambdoidal**) **suture** passes between the two parietals and the occipital. **Squamous sutures** are unusual, scale-like, beveled sutures between temporal and parietal bones. The **basilar suture** (which, before fusion, is called the **sphenooccipital synchondrosis**) lies between the

Figure 4.8 (continued)



sphenoid and the occipital. **Parietomastoid sutures** pass between the parietals and the temporals, constituting posterior extensions of the squamous suture. **Occipitomastoid sutures** pass between the occipital and temporals on either side of the vault.

Before adulthood, several of these sutures are preformed as **synchondroses** — semi-rigid joints made with hyaline cartilage. These synchondroses are temporary and will eventually be replaced either by **syndesmoses** — rigid ligamentous joints — or by bony fusion. These synchondroses are named differently than sutures: the **sphenooccipital synchondrosis** precedes the basilar suture, the **sphenopetrosal synchondrosis** precedes the sphenotemporal suture, the **petrooccipital synchondrosis** precedes the occipitomastoid suture, the **posterior intraoccipital synchondrosis** marks the site of future fusion of the squamous and lateral portions of the occipital bone, the **anterior intraoccipital synchondrosis** marks the site of future fusion of the basilar and lateral portions of the occipital bone, and the **sphenoethmoidal synchondrosis** precedes the sphenoethmoidal suture.

At birth the cranial vault has six areas which, instead of being covered by bone, are covered by dense connective tissue between plates of bone. These “soft spots,” or **fontanelles**, are cartilaginous membranes that eventually harden and turn to bone. There are six fontanelles: two paired and two single. The **anterior** and **posterior fontanelles** are single, along the midline at either end of the sagittal suture. The **mastoid** and **sphenoidal fontanelles** are paired, with one of each on the right and left sides of the cranium.

Sinuses are void chambers in the cranial bones that enlarge with the growth of the face. There are four basic sets of sinuses, one each in the maxillae, frontal, ethmoid, and sphenoid. These sinuses are linked to the nasal cavity and, in life, irritation of their mucous membranes may cause swelling, draining, and headache-related discomfort.

4.4 Skull Orientation

The most useful and informative comparisons between skulls of different individuals are usually comparisons made with both skulls in the same orientation. The convention used in orienting the skull is the **Frankfurt Horizontal (FH)**, named for the city in which the convention was established in 1884. The Frankfurt Horizontal is a plane defined by three points: the right and left **porion** points (located at the top of each external acoustic meatus) and the left **orbitale** (located at the bottom of the left orbit). These and other craniometric landmarks are presented in Section 4.5.

Skulls are normally viewed from five standard perspectives, all in Frankfurt Horizontal (as illustrated in Figures 4.1–4.5). Viewed from above, the skull is seen in **norma verticalis**. When viewed from either side, the skull is seen in **norma lateralis**. **Norma occipitalis** is the posterior view of the skull. Viewed from the front the skull is seen in **norma frontalis**; viewed from the base it is seen in **norma basilaris**. All of these views are perpendicular or parallel to the Frankfurt Horizontal.

4.5 Craniometric Landmarks

Because the skull has been the focus of much physical anthropological investigation, an extensive network of craniometric landmarks has been developed to allow researchers to take comparable measurements on skulls. Early in the 20th century the main focus in physical anthropology was on measuring skulls and comparing these measurements. Today there is a return to an appreciation of the anatomy between the measuring points. Still, it is necessary to have a set of conventions to ensure unambiguous reporting and comparison of osteological material. In addition, even nonmetric descriptions often use a terminology of the skull which makes reference to these landmarks. Indeed, the vocabulary of the skull's measuring points is vital for researchers in osteology and paleontology. In Chapter 16 we provide information on how to measure osteological materials.

Before going into a more detailed discussion of cranial anatomy, we introduce the landmarks most frequently used in measurement and description of the human skull. These landmarks are defined for anatomically modern humans. Because of this, it may not be possible or useful to use them when measuring other extant or extinct primate species.

The craniometric landmarks are best considered in two basic sets: unpaired craniometric landmarks are located in the midsagittal plane, and paired landmarks lie on either side of this plane. Figures 4.9–4.11 indicate the major craniometric landmarks defined here.

Three basic kinds of cranial measurements are most often used. The first is the familiar **cranial capacity**, which describes the volume within the neurocranium. Most measurements taken on the skull are **linear** measurements between two points, the line between the two points sometimes being referred to as a **chord**. The third kind of measurement is a curvilinear measurement called an **arc**. The observer should always take care to see that the landmarks being used for measuring points are unbroken and clearly visible. Comparisons should always be made between individuals of similar age. Exceptions to these cautions should always be noted in any osteology report. The list of landmarks given here includes most points in use today. For a slightly extended list, see Martin and Saller (1957), the source of all abbreviations used here.

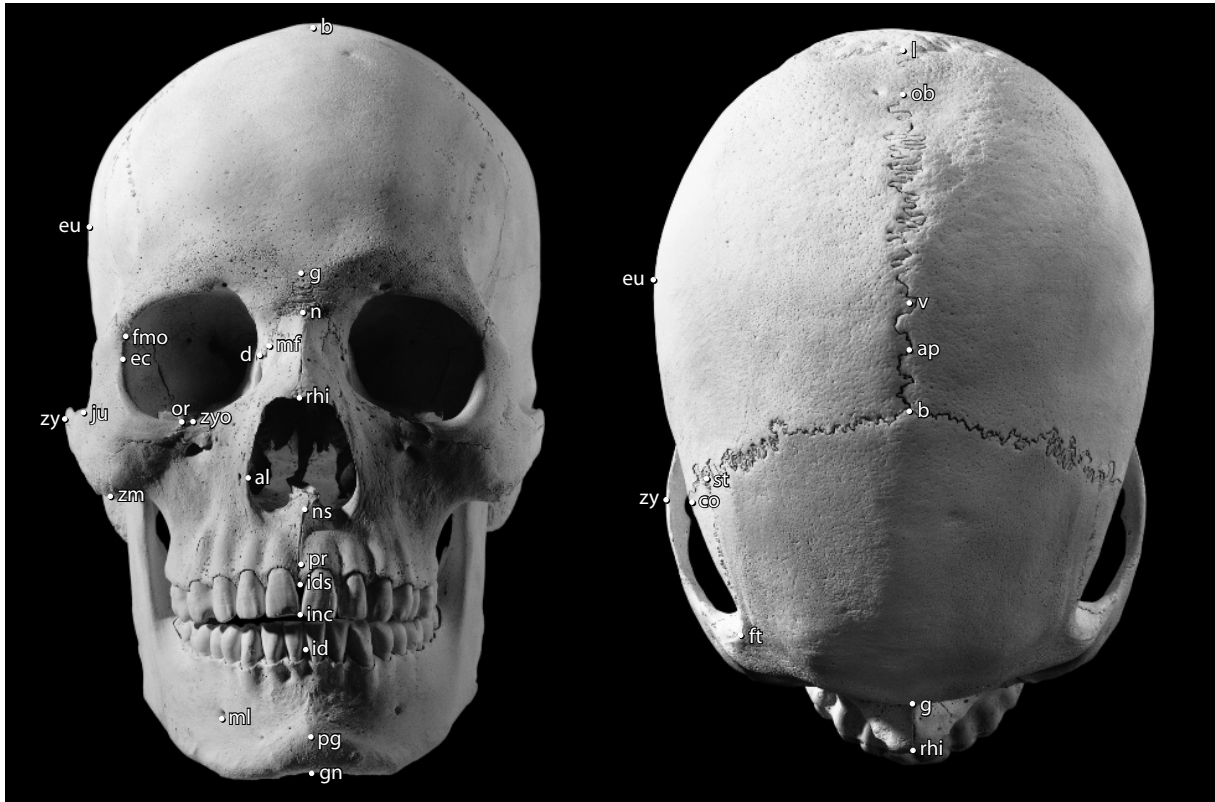


Figure 4.9 Bones and osteometric points of the human skull. *Left*: anterior; *right*: superior. One-half natural size.

4.5.1 Unpaired (Midline) Craniometric Landmarks

Note that the landmarks defined here are arranged in order from the upper incisors around the vault's midline to the lower incisors.

- inc. **Incision** is the point at the occlusal surface where the upper central incisors meet.
- ids. **Alveolare** (or **infradentale superius**) is the midline point at the inferior tip of the bony septum between the upper central incisors.
- pr. **Prosthion** is the midline point at the most anterior point on the alveolar process of the maxillae.
- ns. **Nasospinale** is the point where a line tangent to the inferiormost points of the two inferior curves of the anterior nasal aperture margin crosses the midline.
- rhi. **Rhinion** is the midline point at the inferior free end of the internasal suture.
 - n. **Nasion** is the midline point where the two nasal bones and the frontal intersect.
 - g. **Glabella** is the most anterior midline point on the frontal bone, usually above the frontonasal suture.
 - m. **Metopion** is an instrumentally determined, ectocranial midline point on the frontal where the elevation of the frontal above the chord from nasion to bregma is greatest.

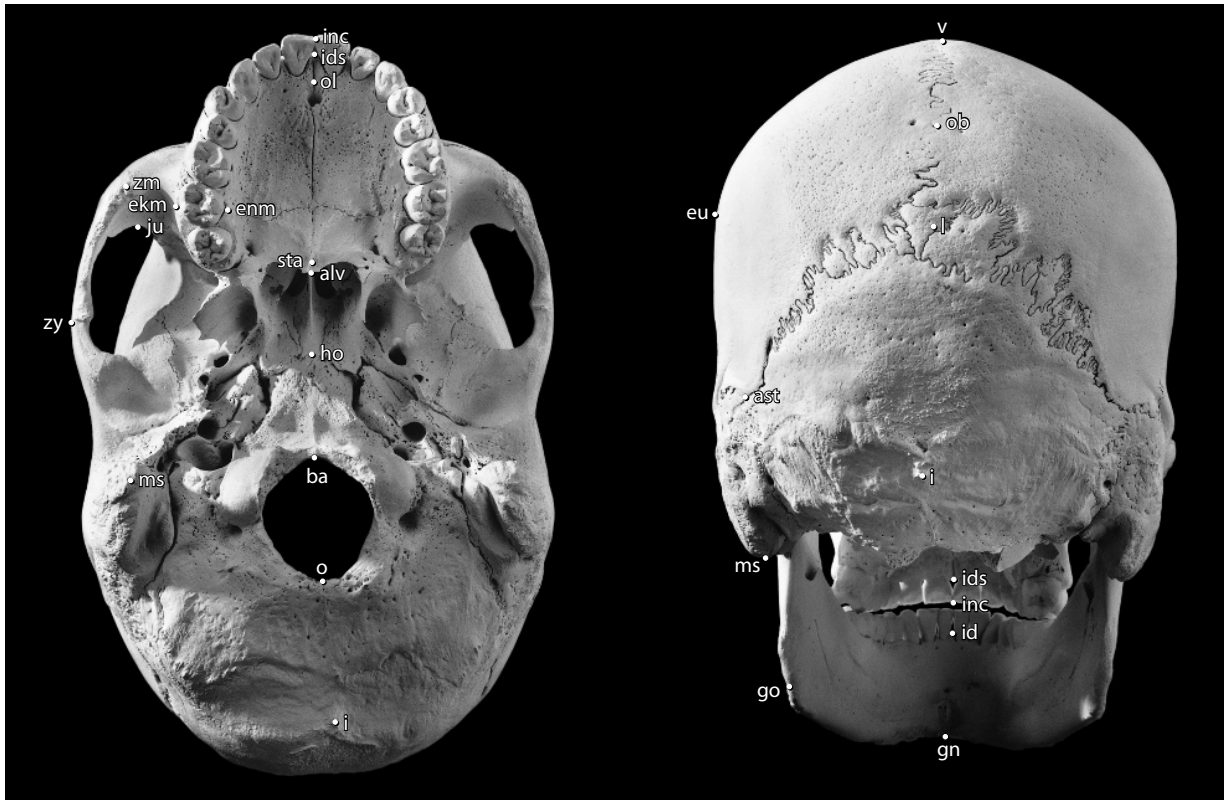


Figure 4.10 Bones and osteometric points of the human skull. *Left:* inferior; *right:* posterior. One-half natural size.

- b. **Bregma** is the ectocranial point where the coronal and sagittal sutures intersect.
- ap. **Apex** is an instrumentally determined, ectocranial midline point placed where a paracoronary plane through the right and left poria (Section 4.5.2) intersects the midsagittal skull outline.
- v. **Vertex** is determined instrumentally when the skull is in Frankfurt Horizontal. It is the highest ectocranial point on the skull's midline.
- ob. **Obelion** is an ectocranial midline point where a line connecting the parietal foramina (when present) intersects the midline.
- l. **Lambda** is the ectocranial midline point where the sagittal and lambdoid sutures intersect. In cases such as the one illustrated in Figures 4.3 and 4.10, sutural bones make placement of this point difficult. When in doubt, choose the point where the lateral halves of the lambdoid suture and the lower end of the sagittal suture would be projected to meet.
- op. **Opisthocranion** is an instrumentally determined point at the rear of the cranium. It is defined as the midline ectocranial point at the farthest chord length from glabella.
- i. **Inion** is an ectocranial midline point at the base of the external occipital protuberance. The bony anatomy in this region is highly variable, with crests, lumps, or odd projections of bone possible. Normally, inion is defined as the point at which the superior nuchal lines merge in the external occipital protuberance.
- o. **Opisthion** is the midline point at the posterior margin of the foramen magnum.

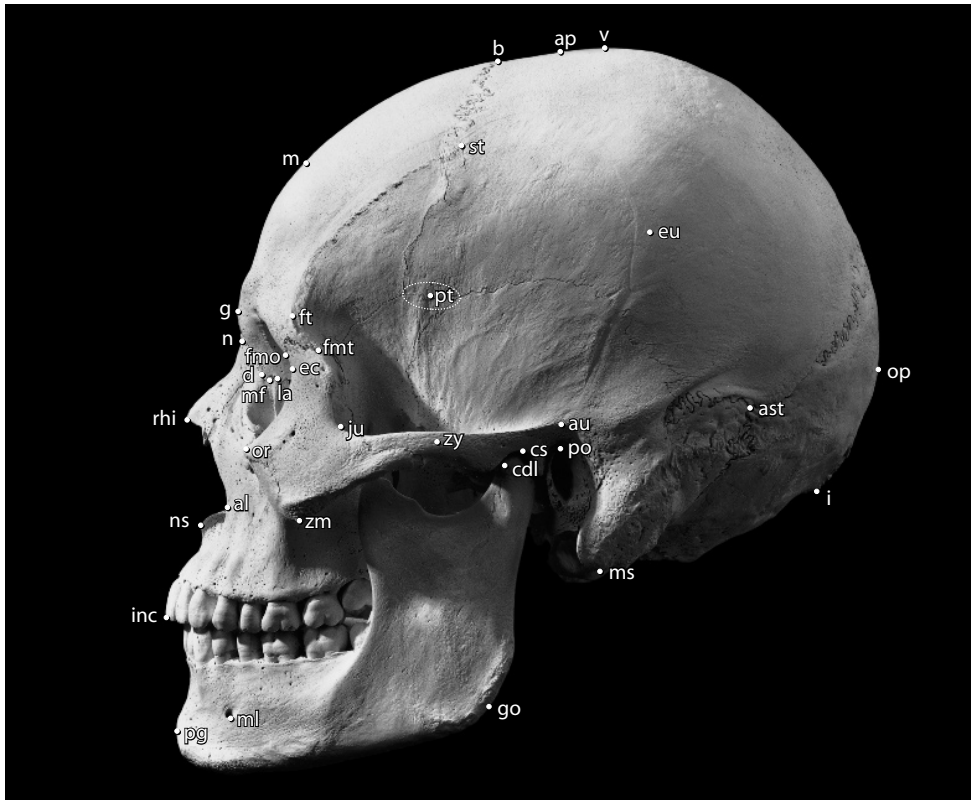


Figure 4.11 Bones and osteometric points of the human skull, lateral. One-half natural size.

- ba. **Basion** is the midline point on the anterior margin of the foramen magnum. For cranial height measurements, the point is placed on the anteroinferior portion of the foramen's rim. For some measurements (eg, cranial base length and basion–prosthion length), the point is located on the most posterior point of the foramen's anterior rim and is sometimes distinguished as **endobasion**.
- sphba. **Sphenobasion** is the point where the midsagittal plane intersects the basilar suture. This point has been obliterated by synchondrosis on the specimen illustrated in Figures 4.5 and 4.10.
- ho. **Hormion** is the most posterior midline point on the vomer.
- alv. **Alveolon** is the point on the median palatine (intermaxillary) suture where a line drawn between the posterior ends of the alveolar ridges crosses the midline.
- sta. **Staphylion** is the point on the median palatine (intermaxillary) suture where a line drawn between the deepest parts of the notches (free edges) at the rear of the palate crosses the midline.
- ol. **Orale** is the midline point on the hard palate where a line drawn tangent to the posterior margins of the central incisor alveoli crosses the midline.
- gn. **Gnathion** is the most inferior midline point on the mandible.
- pg. **Pogonion** is the most anterior midline point on the chin of the mandible.
- id. **Infradentale** is the midline point at the superior tip of the septum between the mandibular central incisors.

4.5.2 Paired Craniometric Landmarks

- zm. **Zygomaxillare** is the most inferior point on the zygomaticomaxillary suture.
- al. **Alare** is instrumentally determined as the most lateral point on the margin of the anterior nasal aperture.
- or. **Orbitale** is the lowest point on the orbital margin.
- zy. **Zygion** is the instrumentally determined point of maximum lateral extent of the lateral surface of the zygomatic arch.
- ju. **Jugale** is the point in the depth of the notch between the temporal and frontal processes of the zygomatic.
- ec. **Ectoconchion** is instrumentally determined as the most lateral point on the orbital margin.
- mf. **Maxillofrontale** is the point where the anterior lacrimal crest of the maxilla meets the frontomaxillary suture.
- la. **Lacrimale** is the point where the posterior lacrimal crest meets the frontolacrimal suture.
- d. **Dacryon** is the point where the maxillolacrimal suture meets the frontal bone.
- zyo. **Zygoorbitale** is the point where the orbital rim intersects the zygomaticomaxillary suture.
- fmo. **Frontomalare orbitale** is the point where the frontozygomatic suture crosses the inner orbital rim.
- fmt. **Frontomalare temporale** is the point where the frontozygomatic suture crosses the temporal line (or outer orbital rim).
- ft. **Frontotemporale** is the point where the temporal line reaches its most anteromedial position on the frontal.
- st. **Stephanion** is the point where the coronal suture crosses the temporal line.
- pt. **Pterion** is a region, rather than a point, where the frontal, temporal, parietal, and sphenoid meet on the side of the vault. The sutural contact pattern in this area is highly variable.
- co. **Coronale** is the point on the coronal suture where the breadth of the frontal bone is greatest.
- eu. **Euryon** is the instrumentally determined ectocranial point of greatest cranial breadth.
- po. **Porion** is the uppermost point on the margin of the external acoustic meatus.
- au. **Auriculare** is a point vertically above the center of the external acoustic meatus at the root of the zygomatic process, a few millimeters above porion.
- ast. **Asterion** is the point where the lambdoid, parietomastoid, and occipitomastoid sutures meet.
- ms. **Mastoidale** is the most inferior point on the mastoid process.
- ekm. **Ectomolare** is the most lateral point on the outer surface of the alveolar margins of the maxilla, often at the second molar position.
- enm. **Endomolare** is the most medial point on the inner surface of the alveolar margin opposite the center of the M² crown.

- cdl. **Condylion laterale** is the most lateral point on the mandibular condyle.
- cs. **Condylion superior** is the most superior point on the mandibular condyle.
- cdm. **Condylion mediale** is the most medial point on the mandibular condyle.
- cr. **Coronion** is the point at the tip of the coronoid process of the mandible (observed in Figures 4.9–4.11).
- go. **Gonion** is a point along the rounded posteroinferior corner of the mandible between the ramus and the body. To determine the point, imagine extending the posterior ramus border and the inferior corpus border to form an obtuse angle. The line bisecting this angle meets the curved gonial edge at gonion.
- ml. **Mentale** is the most inferior point on the margin of the mandibular mental foramen.

4.6 Learning Cranial Skeletal Anatomy

To learn cranial skeletal anatomy, approach the skull systematically. First, study the skull of a young adult, observing all sutures between the bones. Then, study a growth series, noting how each bone and suture changes during ontogeny. Finally, use the descriptions in Sections 4.7–4.21 to learn the features of each bone of the skull. These features are the keys to identifying the various bones of the skull by element and side. Intact cranial bones have rather unique morphologies. You will rarely have difficulty differentiating them.

Because the various bones of the skull are often found in a disarticulated or fragmentary state, each bone or pair of bones must be given individual consideration. To identify and side fragments of the cranium, follow these steps: Determine whether the piece is cranial vault or face. Note any blood vessel impressions, sutures, foramina, surface textures, bone thickness changes, muscle attachments, sinus walls, or tooth roots or sockets. Note the thickness of the piece and its cross-sectional anatomy at the break, including sinus development. Carefully note the morphology of any visible sutures.

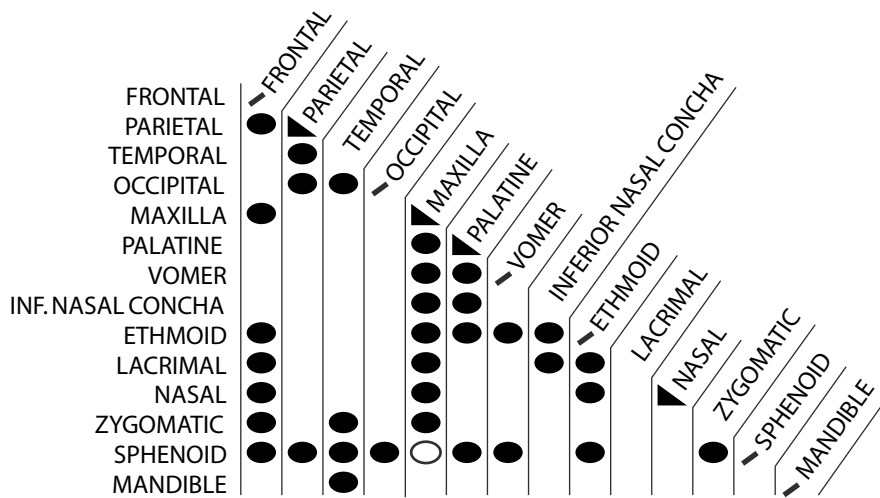


Figure 4.12 Articulation of bones in the human skull. Key: ● : articulates; ○ : sometimes articulates; ▲ : articulating pair; ◆ : unpaired element.

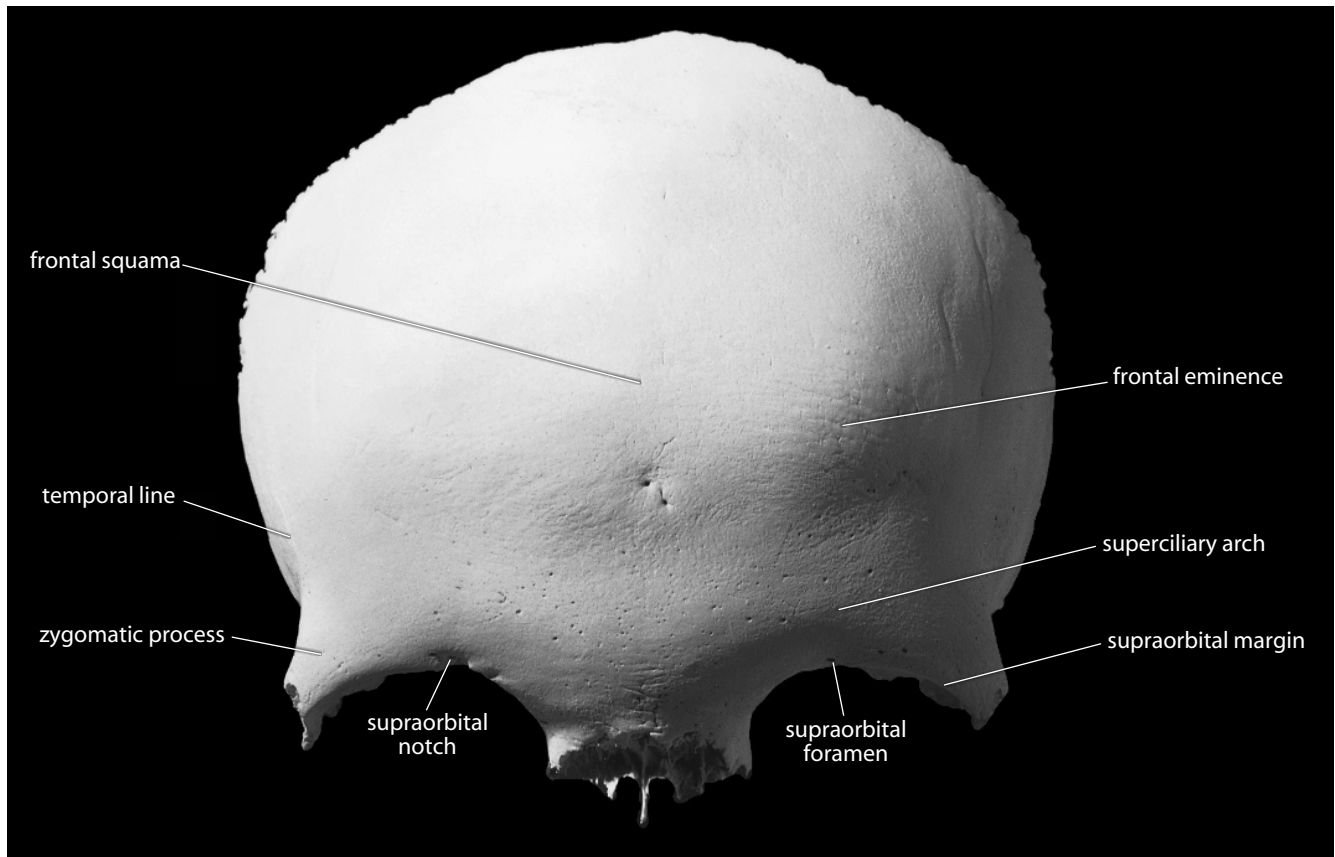
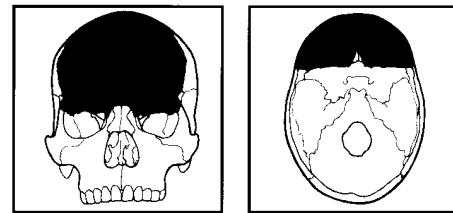


Figure 4.13 Frontal, anterior (ectocranial). Natural size.



4.7 Frontal (Figures 4.13–4.16)

4.7.1 Anatomy

The frontal is located at the front of the neurocranium. It articulates with the parietals, nasals, maxillae, sphenoid, ethmoid, lacrimals, and zygomatics. The frontal is one of the largest and most robust cranial bones. It consists of two general parts: one vertical and one horizontal.

- a. The vertical **frontal squama** forms the forehead.
- b. The **horizontal portion** acts to roof the orbits and to floor the frontal lobes of the brain.
- c. **Frontal eminences** (or **tubers** or **bosses**) dominate the ectocranial surface. These paired frontal bosses mark the location of the original centers of ossification of this bone.
- d. **Temporal lines** on the lateral ectocranial surface mark the attachment of the *temporalis muscle*, a major elevator of the mandible, and its covering, the *temporal fascia*, a fascial sheet that covers the *temporalis*. The temporal line defines the superior edge of the temporal sur-

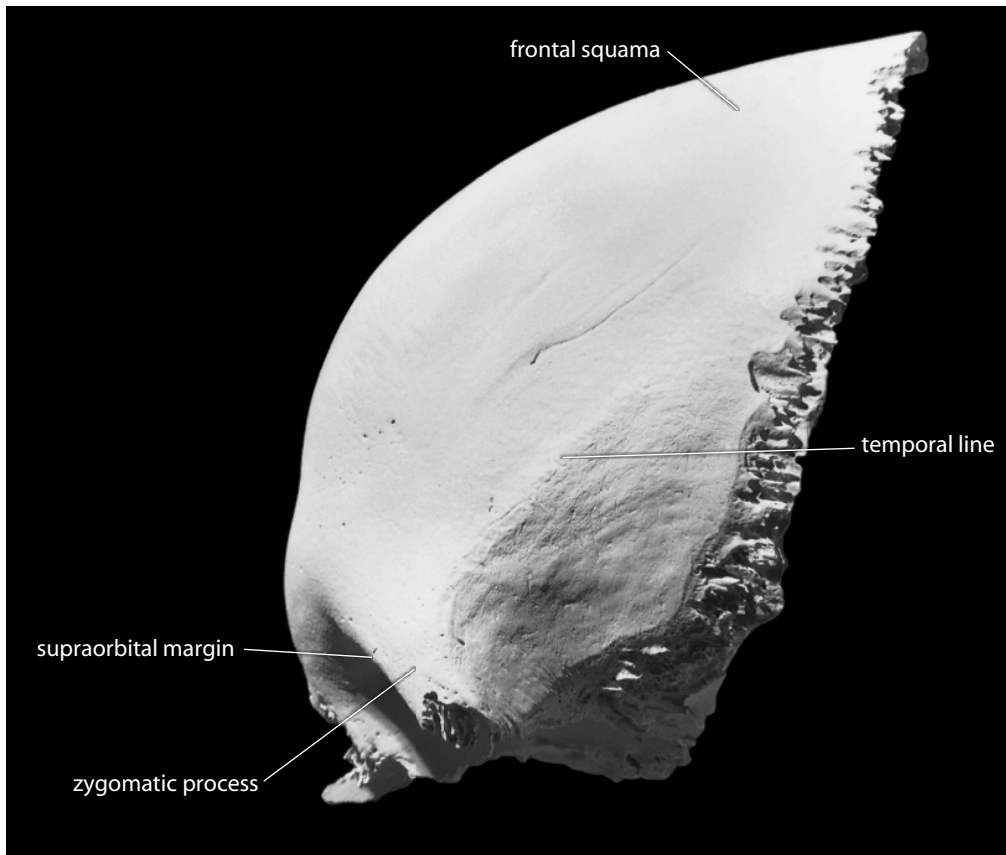


Figure 4.14 Frontal, left lateral (ectocranial). Natural size.

face (and fossa). This line becomes a crest in its anterior, lateral extent (on the zygomatic process of the frontal). It often divides into superior and inferior lines as it sweeps posteriorly.

- e. **Zygomatic processes** form the most lateral and anterior corners of the frontal.
- f. **Superciliary arches** (brow ridges) are the bony tori over the orbits. They are most prominent in males and are sometimes joined by a prominent glabellar region.
- g. **Supraorbital margins** are the upper orbital edges. These are notched or pierced by the supraorbital notch or foramen.
- h. **Supraorbital notches** (or **foramina**, if the notches are bridged) are set along the medial half of the superior orbital rim. They transmit the *supraorbital vessels* and *supraorbital nerve* as they pass superiorly to the forehead region.
- i. The **metopic** (or **frontal**) **suture** is a vertical suture between right and left frontal halves. Its persistence is variable, but only occasionally does it last into adulthood. Traces of it are observed most often in the glabellar region in adults.
- j. **Meningeal grooves** for the *middle meningeal arteries* are present on both sides of the concave endocranial surface of the frontal squama. The *brain* is covered with a tough outer protective membrane, the *dura mater*, whose blood supply comes from the *meningeal arteries*.
- k. The **sagittal sulcus** is a vertical groove that runs down the midline of the endocranial surface. It lodges the *superior sagittal sinus*, a large vessel that drains blood from the brain.
- l. The **frontal crest** is a midline crest confluent with the anterior end of the sagittal sulcus.

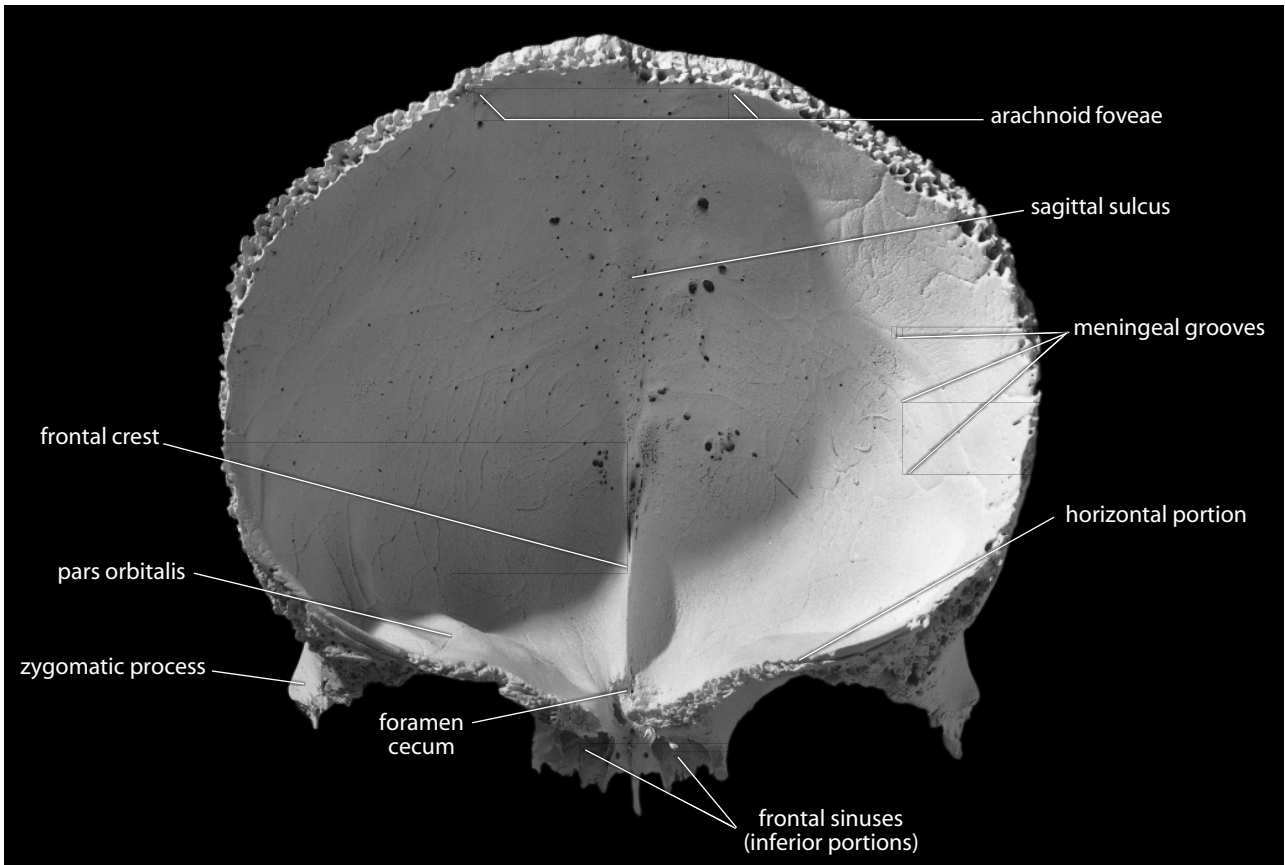


Figure 4.15 Frontal, posterior (endocranial). Natural size.

This crest gives attachment to the *falx cerebri*, a strong membrane between the two cerebral hemispheres of the brain.

- m. The **foramen cecum**, a foramen of varying size, is found at the root, or base, of the frontal crest and transmits a small vein from the frontal sinus to the superior sagittal sinus.
- n. **Arachnoid** (or **granular**) **foveae** are especially apparent near the coronal suture along the endocranial midline. They are features associated with another covering layer of the brain, the *arachnoid*, which is a delicate, avascular membrane lying beneath the *dura mater*. Tufts of *arachnoid*, the *arachnoid granulations*, push outward against the *dura*, causing resorption of the bone and the formation of foveae on the endocranial surface. On both sides of the midline the endocranial surface of the frontal bears depressions for convolutions of the frontal lobes of the brain.
- o. The **pars orbitalis**, or **orbital plate**, is the horizontal portion of the frontal. Its endocranial surface is undulating (bumpy), conforming to the inferior surface of the frontal lobe. Its inferior surface (orbital surface) is smoother and concave.
- p. **Lacrima fossae**, for the *lacrima glands*, are found at the lateral, inferior parts of the orbital (inferior) surfaces of the frontal.
- q. The **ethmoidal notch** is the gap separating the two orbital plates of the frontal. The ethmoid bone fills this notch in the articulated cranium.
- r. **Frontal sinuses**, generally anterior to the ethmoidal notch, extend for a variable distance between outer and inner bone tables of the frontal and sometimes penetrate the orbital

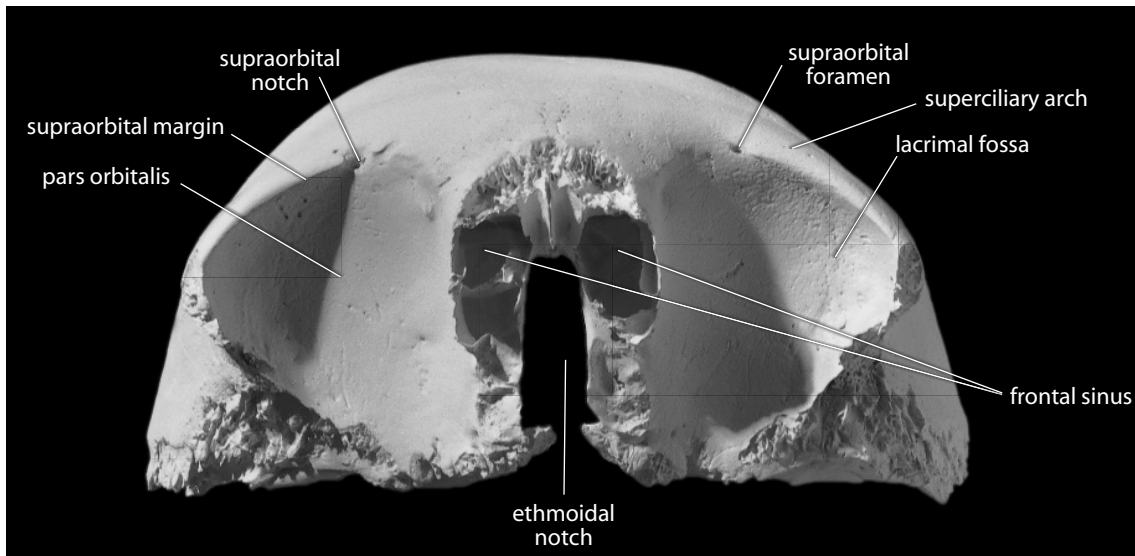


Figure 4.16 Frontal, inferior (ectocranial). Natural size.

plates. Personal identification in forensic cases has been accomplished by employing radiographs of this region. Distinctive patterns of frontal sinuses can then be used for individuation.

4.7.2 Growth

The frontal ossifies intramembranously from two primary centers. At birth these centers are separate. They fuse along the metopic suture (midline), usually during a child's second year.

4.7.3 Possible Confusion

- When fragmentary, the frontal is confused most often with the parietals. The meningeal impressions are larger and more dense on the parietals, and the endocranial surfaces of the parietals are less undulating than those of the frontal.
- The frontal is the only major vault bone with a substantial sinus and adjacent orbital rims.

4.7.4 Siding

Isolated fragments of frontal squama may be difficult to side. Siding the frontal or any other bone or tooth, whether fragmentary or intact, is often simplified by holding the element in its correct orientation adjacent to that region of your own skull. In other words, attempt to imagine the fragment fitting into your own anatomy. The coronal suture is posterior and courses anterolaterally, toward the face, from bregma. This means that the sagittal and coronal sutures do not meet at right angles. This fact can be very useful in siding fragments of frontal squama.

- The anteromedially placed frontal sinus is often exposed in broken pieces.
- The ectocranially placed temporal lines swing medially and weaken posteriorly.


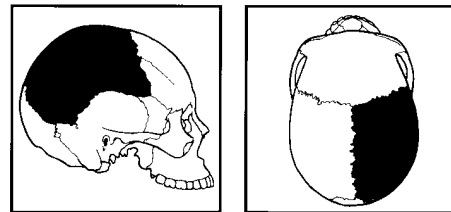


Figure 4.17 **Right parietal, lateral (or ectocranial)**. Anterior is toward the right, superior is up. Natural size. See Figure 4.1 for more strongly expressed temporal lines.



4.8 Parietals (Figures 4.17–4.18)

4.8.1 Anatomy

The parietals form the sides and roof of the cranial vault. Each parietal articulates with the opposite parietal and with the frontal, temporal, occipital, and sphenoid. Parietals are basically square and are the largest bones of the vault, with a fairly uniform thickness.

- a. The **frontal angle** is located at bregma.




Figure 4.18 Right parietal, medial (or endocranial). Anterior is toward the left, superior is up. Natural size.

- b. The **sphenoidal angle** is located at pterion.
- c. The **occipital angle** is located at lambda.
- d. The **mastoid angle** is located at asterion.
- e. The **parietal tuber** (or **boss** or **eminence**) is the large, rounded eminence centered on the ectocranial surface of the parietal. It marks the center of ossification of the bone.
- f. **Temporal lines** dominate the ectocranial surface, arching anteroposteriorly.
- g. The **superior temporal line** anchors the *temporal fascia*.
- h. The **inferior temporal line** indicates the most superior extent of the *temporalis muscle*.
- i. When present, the **parietal foramen** is located close to the sagittal suture near lambda. It transmits a small vein through the parietal to the superior sagittal sinus.

- j. The **parietal striae** are striations, or “rays,” that pass posterosuperiorly for some distance on the ectocranial surface of the parietal from their origin on its beveled squamous edge.
- k. **Meningeal grooves** for *middle meningeal arteries* dominate the endocranial surface of the parietal. These arteries supply the *dura mater*. The most anterior branch parallels the coronal edge of the parietal, and most of the branches traverse the bone toward its occipital angle.
- l. The **sagittal sulcus** is made when the parietals are articulated and the shallow grooves along the sagittal edge of each parietal combine along the endocranial midline. This sulcus is a posterior continuation of the same feature on the frontal.
- m. **Arachnoid** (or **granular**) **foveae** are concentrated endocranially along the anterior extent of the sagittal edge of each parietal. They are functionally equivalent to structures of the same name described for the frontal (Section 4.7.1n).
- n. The **sigmoid sulcus** (or **sulcus for the sigmoid** and/or **transverse sinus**) crosses the mastoid angle of the parietal, cutting a groove on the endocranial surface. It marks the course of the *transverse* (or *sigmoid*) *sinus*, a vessel that drains blood from the brain.

4.8.2 Growth

The parietal bone ossifies intramembranously, with ossification extending radially from a combined center near the parietal boss. The four corners of the bone are not ossified at birth, and the remaining spaces are the fontanelles.

4.8.3 Possible Confusion

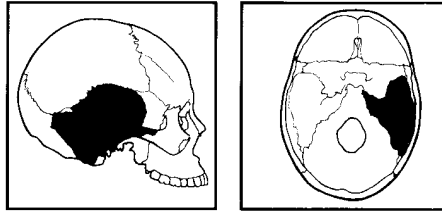
When fragmentary, the parietal is confused most often with the frontal, occipital, or temporal. The frontal, occipital, and temporal do not have parietal foramina, as many meningeal grooves, or ectocranial striae associated with an externally facing beveled suture (the squamous).

- The cross section of a parietal is more regular (thickness does not vary as much) than those of the other vault bones.
- The temporal line is a constant feature across the length of the parietal.
- The endocranial surface of this bone is not as undulating and irregular as that of the frontal or the occipital.

4.8.4 Siding

Siding is difficult only when the parietal bone is very fragmentary. The meningeal grooves are oriented vertically along the coronal suture and more horizontally near the squamous suture.

- The coronal suture, unlike the sagittal suture, is an interdigitating, rather than an interlocking, zipper-like, or jigsaw-like articulation. The large *anterior middle meningeal vessel* makes an impression along this suture endocranially.
- The thickest corners are the occipital and mastoid angles.
- The mastoid angle bears a sulcus endocranially.
- The squamous suture is lateral and inferior, and the parietal striae angle posterosuperiorly.



4.9 Temporals (Figures 4.19–4.21)

4.9.1 Anatomy

Temporals form the transition between cranial wall and base, house the delicate organs of hearing, and form the upper surface of the jaw joints. The highly irregular shape of the temporal is related to the varying functions of the bone. The temporal articulates with the parietal, occipital, sphenoid, zygomatic, and mandible. The jaw joint, or temporomandibular joint, is often abbreviated TMJ. Parts of the temporal bone are very robust and, for this reason, are often more resistant to destruction than other parts of the cranial vault.

- a. The thin, plate-like **temporal squama** rises almost vertically to form the cranial walls and articulate with the parietals along the squamous suture.
- b. The **petrous pyramid** (or **pyramidal process**) is the massive, dense bony part that dominates the endocranial aspect of the temporal. The sharp superior edge of the endocranial petrous surface angles anteromedially, separating the *temporal* and *occipital lobes* of the brain and housing the internal ear. The petrous is wedged between the occipital and the sphenoid. The end-on (anteromedial) view is into the carotid canal (Section 4.9.1v). This petrous part of the bone houses the delicate organs of hearing and equilibrium, including the tiny movable malleus, incus, and stapes bones.
- c. The **external acoustic** (or **auditory**) **meatus (EAM)** is the external opening of the ear canal, which passes anteromedially for about 2 cm. The inner end of the canal is closed by the tympanic membrane (eardrum) in the living individual.
- d. The **zygomatic process** of the temporal is a thin projection of bone that forms the posterior half of the zygomatic arch. Its anterior edge is the serrated zygomaticotemporal suture, its superior edge is an attachment for the *temporal fascia*, and its inferior edge anchors fibers of the *masseter muscle*.
- e. The **suprameatal crest** is the superior root of the zygomatic process. It runs horizontally above the EAM where the craniometric point auriculare is located.
- f. The **supramastoid crest** is the posterior extension of the suprameatal crest. The continuous raised edge of these crests marks the limit of the *temporalis muscle* and *temporal fascia* attachment.
- g. The **parietal notch** is formed by the posterosuperior border of the temporal where the squamous and parietomastoid sutures meet.
- h. The **mastoid process** bears an external surface that is roughened for the attachment of several muscles including the following: *sternocleidomastoideus*, *splenius capitis*, and *longissimus capitis*. These muscles function in extension, flexion, and rotation of the head. The *temporalis muscle* may also attach in this region when the supramastoid crest is present on the mastoid area, as in some humans and many fossil hominids. Internally, the thin-walled mastoid process is occupied by a number of variably developed voids known as **mastoid cells**.
- i. The **mastoid foramen** (occasionally multiple) is located near the posterior edge of the mastoid process along the occipitomastoid suture. It transmits a small branch of the *occipital artery*, which supplies the dura mater, the diploë (spongy bone sandwiched between inner and outer bone tables of cranial vault bones), and the mastoid air cells.

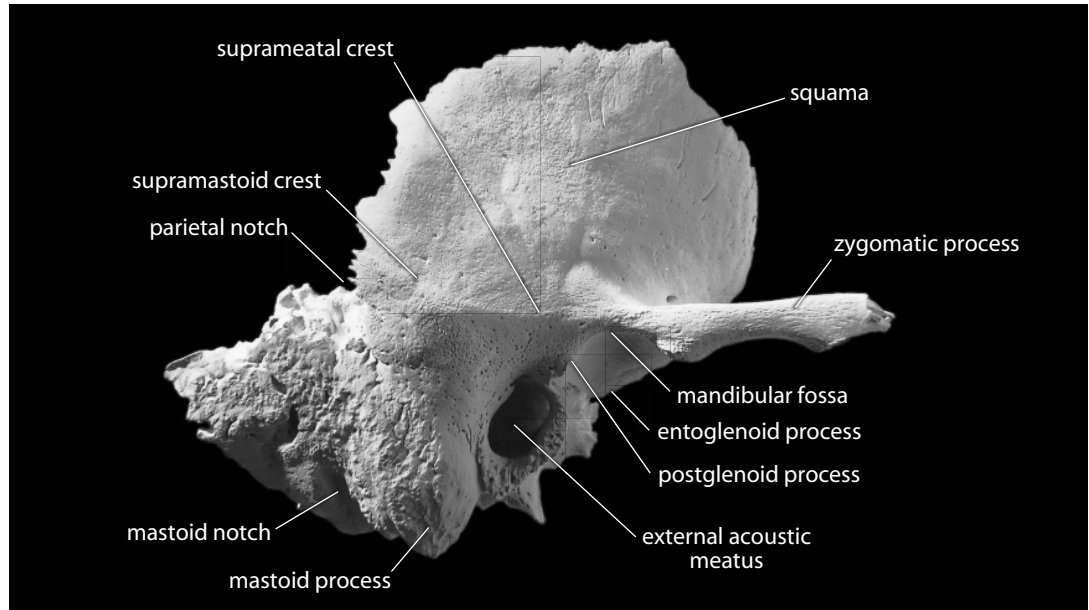


Figure 4.19 Right temporal, lateral (ectocranial). Anterior is toward the right, superior is up. Natural size.

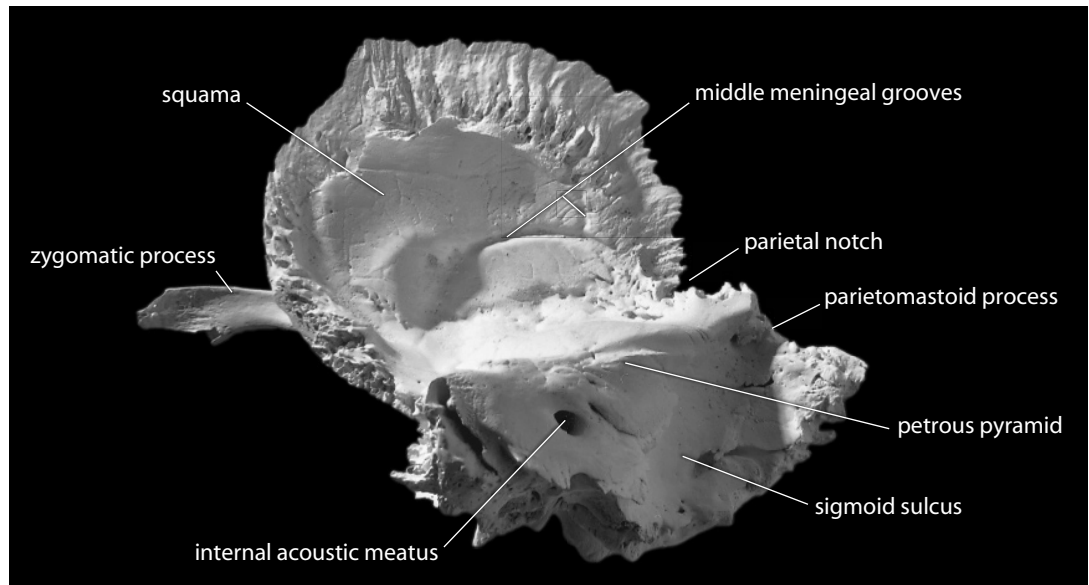


Figure 4.20 Right temporal, medial (endocranial). Anterior is toward the left, superior is up. Natural size.

- j. The **mastoid notch** (or **digastric groove**) for attachment of the *digastric muscle* is the vertically oriented furrow medial to the mastoid process.
- k. The **occipital groove** (or **sulcus**) lies just medial to the mastoid notch. It is a shallow furrow that lodges the *occipital artery*.
- l. The **temporomandibular articular surface** is the smooth, articular surface inferior to the root of the zygomatic process. There is considerable topographic relief to this inferiorly facing surface.

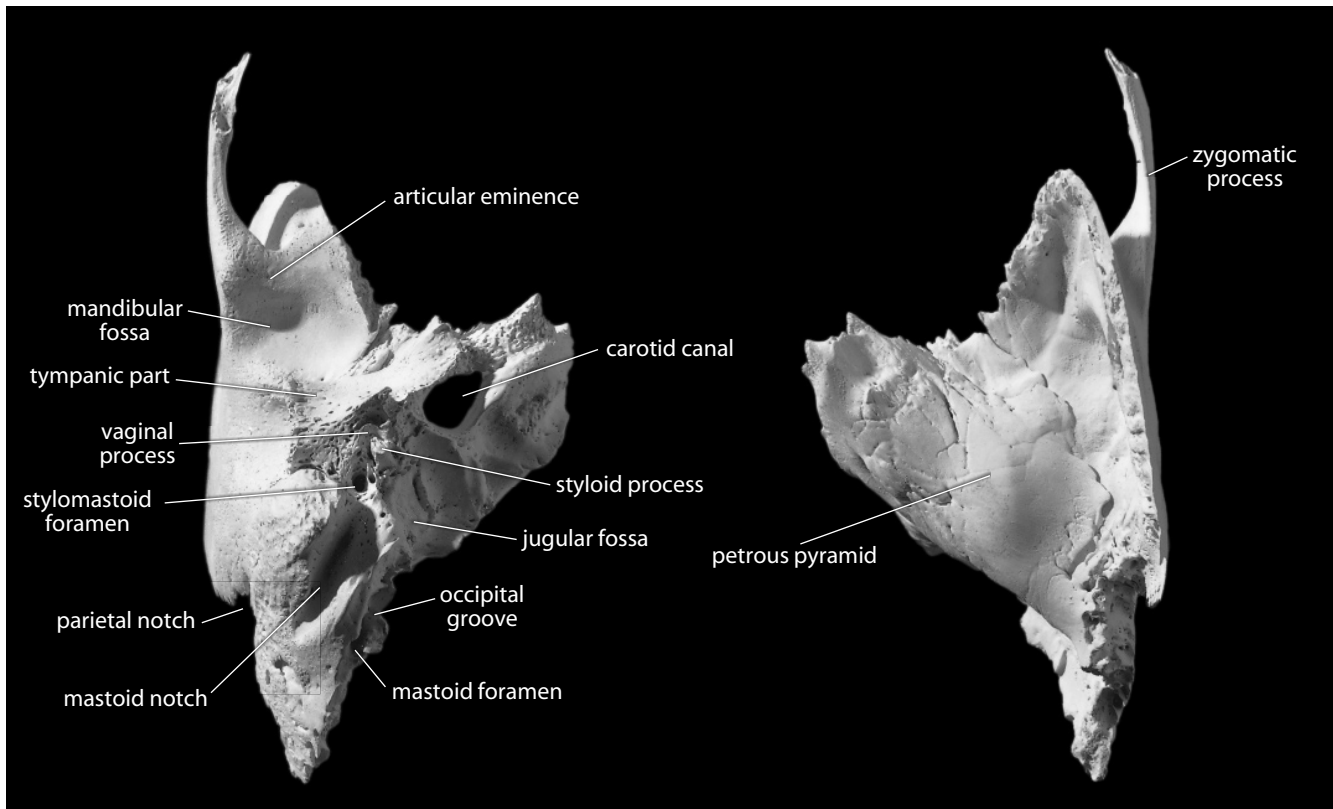


Figure 4.21 **Right temporal.** *Left:* inferior view, anterior is up, medial is to the right; *right:* superior view, anterior is up, medial is to the left. Natural size.

- m. The **articular eminence** forms the anterior portion of the temporomandibular articular surface.
- n. The **mandibular** (or **glenoid**) **fossa** lies posterosuperior to the articular eminence. The eminence and the fossa itself are bounded medially by the sphenosquamous suture. In chewing, the condyle of the mandible moves anteriorly onto the eminence and posteriorly into the fossa as well as from side to side in actions at the TMJ. In life there is a fibrocartilaginous *articular disk* interposed between the mandibular condyle and the fossa.
- o. The **postglenoid process** is a projection that lies just anterosuperior to the EAM, interposed between the **tympanic part** of the bone (which forms most of the rim of the EAM) and the mandibular fossa. This rim is roughened for the attachment of the cartilaginous part of the EAM.
- p. The **entoglenoid process** is the inferior projection of the articular surface at the medial edge of the articular eminence.
- q. The **tympanic part** of the temporal lies posterior to the TMJ. Its anterior surface, forming the rear wall of the mandibular fossa, is nonarticular.
- r. The **styloid process** is a thin, pointed bony rod that points anteroinferiorly from the base of the temporal bone. It is a slender projection of variable length and is fragile and often broken or missing (as on the illustrated specimen, where its distal end has snapped off). It anchors the *stylohyoid ligament* (sometimes partly ossified) and several small muscles.
- s. The **stylohyoid foramen**, located immediately posterior to the base of the styloid

process, is for the exit of the *facial nerve* (cranial nerve 7) and the entrance of the *stylomastoid artery*.

- t. The **vaginal process** ensheathes the base of the styloid process.
- u. The **jugular fossa** is located just medial to the base of the styloid process. This deep fossa houses the *bulb of the internal jugular vein*, a vessel that drains blood from the head and neck.
- v. The **carotid canal** is a large circular canal that transmits the *internal carotid artery*, a major source of blood for the head, and the *carotid plexus* of nerves. It is situated medial to the styloid process at the level of the sphenosquamous suture, just anterior to the jugular fossa.
- w. **Middle meningeal grooves** are narrow, well-defined channels that mark the endocranial surface of the temporal. The larger, more diffuse undulations on this surface are related to convolutions of the *temporal lobe* of the brain.
- x. The **internal acoustic** (or **auditory**) **meatus** is located about midway along the posterior surface of the petrous pyramid and transmits the *facial* and *acoustic nerves* (cranial nerves 7 and 8, respectively) as well as the *internal auditory artery*.
- y. The **sigmoid sulcus** is the large, curving groove set at the posterior base of the petrous pyramid on the endocranial surface of the mastoid part of the temporal bone. This sulcus houses the *sigmoid sinus*, an anteroinferior extension of the *transverse sinus*, which is a major vessel draining blood from the brain into the *internal jugular vein*. Note that this sulcus is a continuation of the sulcus on the posteroinferior corner of the parietal.

4.9.2 Growth

Growth of the temporal is complex, with both membranous and endochondral ossification. It ossifies from eight centers during fetal development, not counting those of the middle ear or tympanic ring. As birth approaches, only three main centers remain: the squama, the petrous part, and the tympanic ring.

4.9.3 Possible Confusion

Even when fragmentary, it is difficult to confuse the temporal with other bones because of its unique morphology. The broken elements that may present some trouble are the squama and zygomatic process.

- The temporal squama overlaps the parietal. It is thinner than the parietal or frontal.
- Fragmentary temporal processes of the zygomatic bone are not as thin and long as the zygomatic process of the temporal.

4.9.4 Siding

- For isolated mastoid sections, the mastoid tip points inferiorly and the entire mastoid angles anteriorly.
- The mastoid notch (or digastric groove) is posterior and medial.
- For isolated petrous pyramids, the internal acoustic foramen is posterior and the pyramid tapers anteromedially.
- For isolated fragments of squama, the squamous suture surface overlaps the ectocranial surface of the parietal. Grooves for the middle meningeals branch posteriorly and slightly superiorly.

- For broken zygomatic processes, the articular eminence is posterior, the superior edge of the arch is thinnest, and the zygomaticotemporal suture runs from posteroinferior to anterosuperior.

4.10 Auditory Ossicles (Figure 4.22)

The tiny ear ossicles, the **malleus** (hammer), **incus** (anvil), and **stapes** (stirrup), are housed in the tympanic cavity of the temporal. The first is connected to the *tympanic membrane*, or *eardrum*, and the others are located more medially. These bones are so small that they are best observed under magnification. They are often lost during skeletal recovery and are seldom studied.

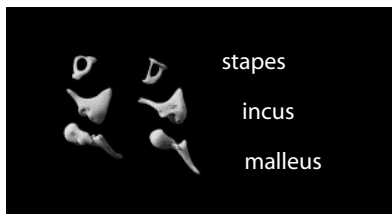
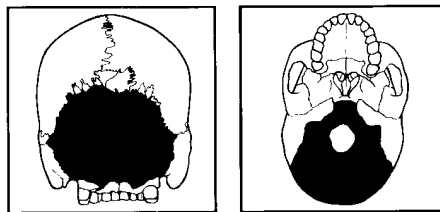


Figure 4.22 Auditory ossicles viewed from both sides. Natural size.



4.11 Occipital (Figures 4.23–4.24)

4.11.1 Anatomy

The occipital bone is set at the rear of the cranium and articulates with the temporals, sphenoid, parietals, and the uppermost vertebra, the atlas.

- The **foramen magnum** is the large hole in the occipital through which the *brainstem* passes inferiorly into the vertebral canal.
- The **squamous** portion of the occipital bone is by far the largest, constituting the large plate of bone posterior and superior to the foramen magnum.
- The **occipital planum** is that part of the occipital squama that lies above the superior nuchal lines (Section 4.11.1e). The section of squama inferior to the lines is the **nuchal planum**.
- The **external occipital protuberance** lies on the ectocranial midline where the occipital and nuchal planes meet. It is highly variable in appearance and heavier and more prominent in male individuals.
- Superior nuchal lines** lie to either side of the midline on the ectocranial surface of the squamous portion. The nuchal plane and occipital planes merge at these superiorly convex lines. Several *nuchal muscles* attach to and below these lines and function to extend and rotate the head.

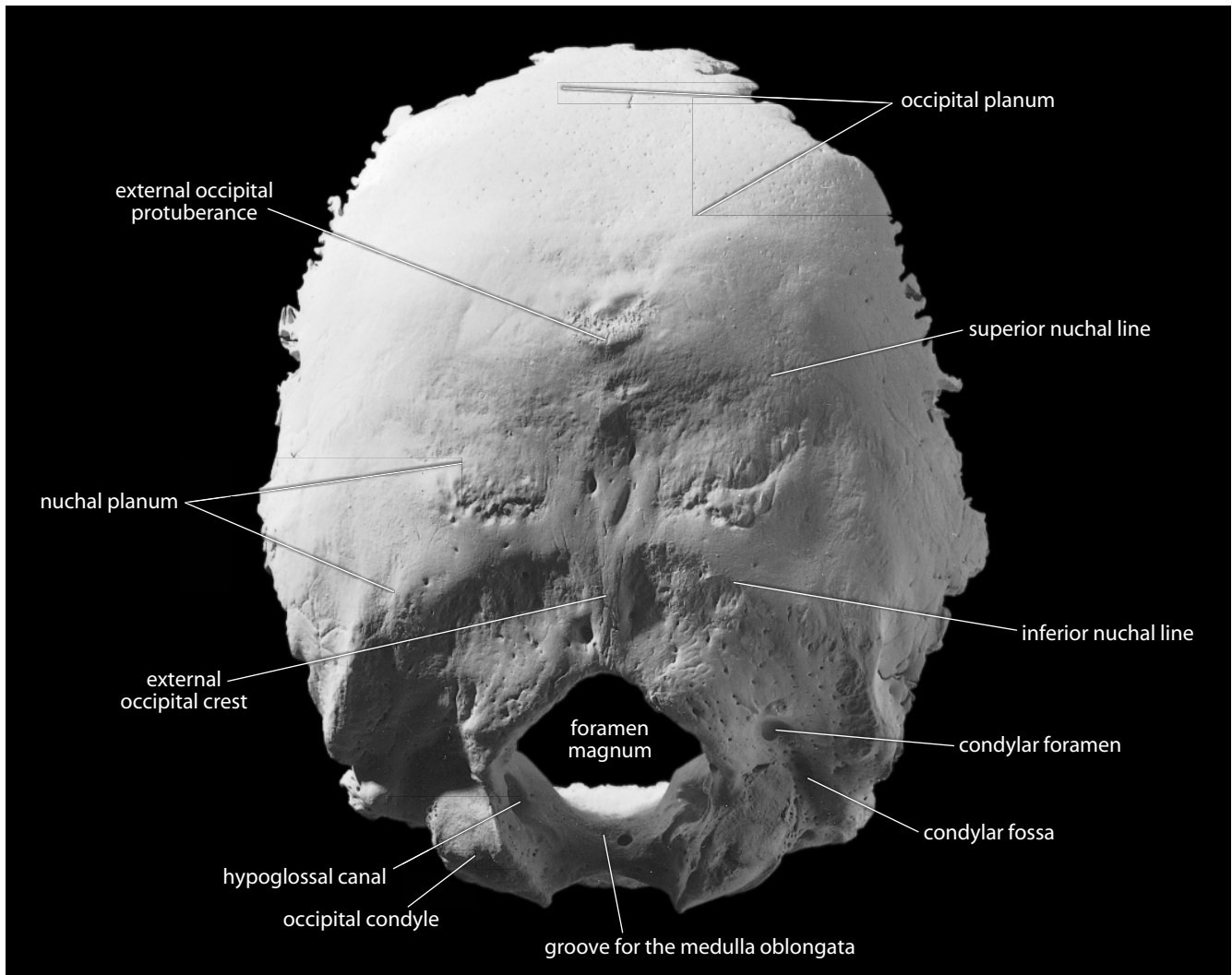


Figure 4.23 Occipital, posteroinferior (ectocranial). Superior is up. Natural size.

- f. **Inferior nuchal lines** parallel the superior lines but are located about midway on the ectocranial nuchal plane. Fascia separating *nuchal muscles* attach to the line, whereas additional *nuchal muscles* attach inferior to this line.
- g. The **external occipital crest** (or **median nuchal line**) is a highly variable median line or crest that passes between the right and the left *nuchal musculature*. It stretches from the external occipital protuberance to the rear of the foramen magnum, anchoring the *nuchal ligament*.
- h. The **basilar part** is the thick, square projection anterior to the foramen magnum. This part articulates with the petrous portions of both temporals and with the sphenoid via the basilar (or sphenoccipital) suture.
- i. The **lateral** (or **condylar**) **parts** of the occipital lie to either side of the foramen magnum, articulating with the temporals.

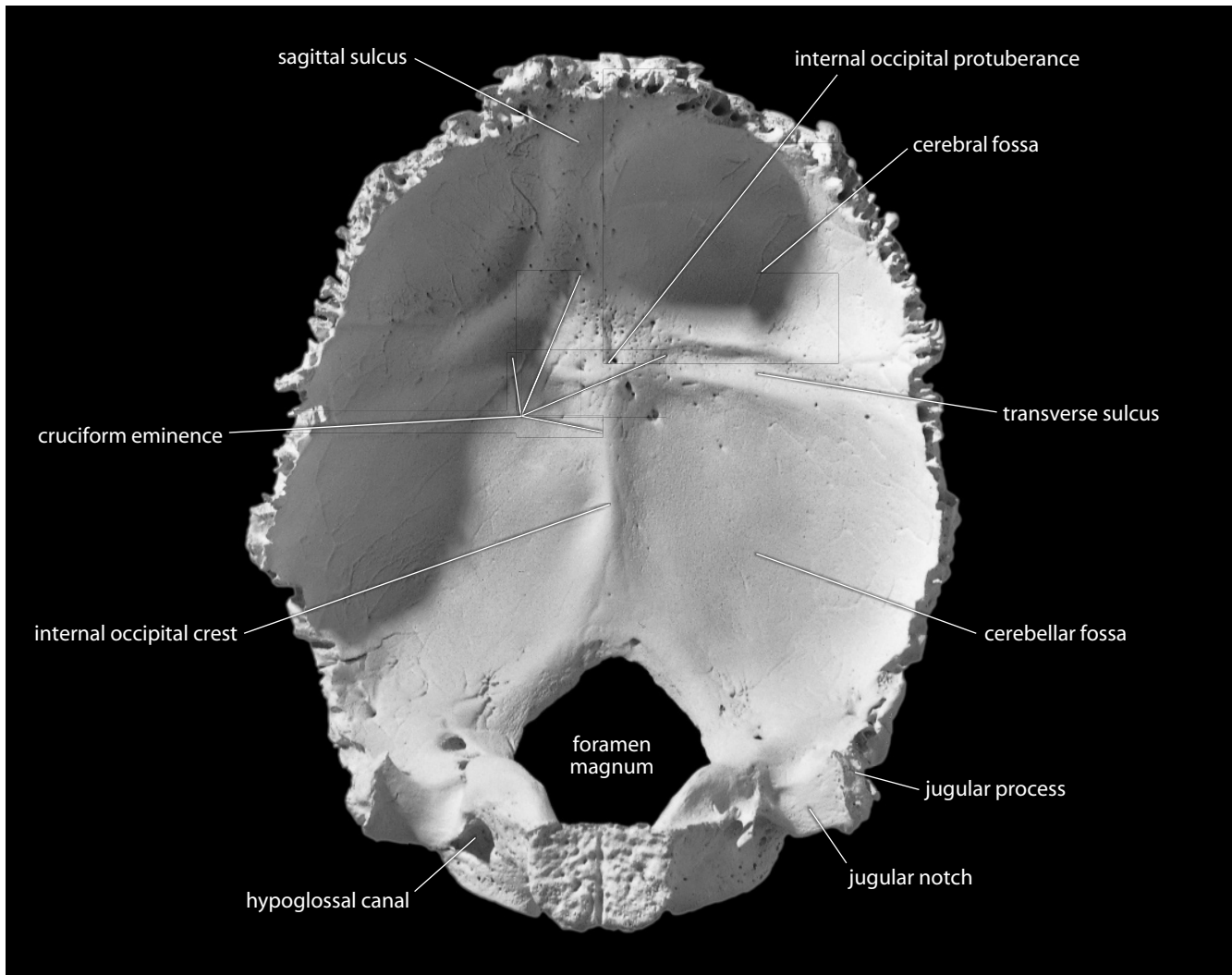


Figure 4.24 Occipital, anterior (endocranial). Superior is up. Natural size.

- j. **Occipital condyles** are raised oval structures on either side of the foramen magnum. Their inferior surfaces are convex. The articular surfaces of these condyles fit into the concave facets of the atlas vertebra.
- k. **Condylar fossae** are ectocranial depressions immediately posterior to the condyles. These fossae receive the posterior margin of the superior facet of the atlas vertebra when the head is extended backward.
- l. **Condylar foramina** (and **canals**) perforate the occipital at the depth of the condylar fossae, where each transmits an *emissary vein*.
- m. **Hypoglossal canals** are tunnels through the anterior part of the base (therefore superior in placement) of each condyle. These canals give exit to *hypoglossal nerves* (cranial nerve 12) and entrance to arteries.
- n. **Jugular processes** are laterally directed corners of the bone placed lateral to the condyles. The tips of these processes lie at the anteriormost point along the occipitomastoid suture.

- o. The **jugular notch** is excavated into the anterior surface of the jugular process. This notch forms the posterior half of the jugular foramen in the articulated cranium, with the anterior half being contributed by the temporal bone (Section 4.9.1u).
- p. The **cruciform eminence** divides the endocranial surface of the occipital squama into four fossae. It is so named because it is cross-shaped.
- q. **Cerebral fossae** are triangular depressions below the lambdoid suture on the endocranial surface of the occipital. They house the *occipital lobes* of the brain's *cerebrum*.
- r. The **cerebellar fossae** occupy the inferior part of the endocranial surface of the occipital squama. Therein rest the *cerebellar lobes* of the brain.
- s. The **internal occipital protuberance** lies at the center of the cruciform eminence.
- t. The **sagittal (or occipital) sulcus** passes superiorly from the internal occipital protuberance. It is a deep endocranial groove marking the posterior extension of the *sagittal sinus*, a major blood drainage pathway from the brain.
- u. The **internal occipital crest** is the inferior arm of the cruciform eminence. Sometimes it bears a sulcus that continues on one or both sides of the foramen magnum. Such a sulcus, called an **occipitomarginal sulcus**, represents an alternative pathway for blood to drain from the brain.
- v. **Transverse sulci** form the transverse arms of the cruciform eminence. They house the *transverse sinuses*. The one on the right is usually larger and communicates directly with the sagittal sulcus. However, variations in the soft tissue and bony manifestations of this cranial venous drainage system are common and sometimes pronounced. The transverse sulcus of the occipital connects with the sigmoid sulcus of the temporal and endocranial jugular process, often via the transverse (or sigmoid) sulcus on the mastoid angle of the parietal.
- w. The **groove for the medulla oblongata** is the hollowing on the endocranial surface of the basilar part of the occipital, the clivus.

4.11.2 Growth

The occipital is another bone with both membranous and endochondral ossification. At birth the occipital consists of four parts: the squama, the lateral parts that bear the condyles, and the basilar part. The squamous and lateral portions unite at about age 4, and by age 6 the basilar part attaches to these. The synostosis (fusion) between the occipital and the sphenoid (across the sphenoccipital synchondrosis) normally takes place between 18 and 25 years of age.

4.11.3 Possible Confusion

Even when fragmentary, the occipital is difficult to confuse with other bones of the vault.

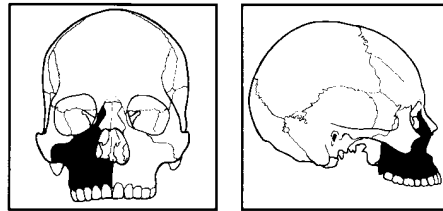
- There is wide variation in thickness across the occipital squama that is not found in the parietals or the frontal.
- The occipital lacks meningeal grooves endocranially and has much more ectocranial rugosity than seen on the parietal or frontal.

Other possible confusion may come when extrasutural bones are encountered. These bones are sometimes quite large, particularly along the lambdoid suture. One even has a name, the **inca bone**. This is a large, triangular, symmetrical bone placed at the top of the occipital, just below lambda.

4.11.4 Siding

Isolated fragments of the occipital are easily sided by locating the lambdoid suture.

- For isolated condyles, the edge of the foramen magnum is medial and somewhat posterior to the condylar body centers.
- The condylar fossa is posterior, and the hypoglossal canals tunnel from anterolateral to posteromedial.



4.12 Maxillae (Figure 4.25)

4.12.1 Anatomy

Maxillae are a pair of bones that form the dominant portion of the face. Functionally, the maxillae hold the tooth roots and form most of the nasal aperture and floor, most of the hard palate, and the floors of the orbits. Most of the maxillary bone is light and fragile, the exception being the portion that holds the teeth. Maxillae comprise four basic processes. They articulate with each other and with the frontal, nasals, lacrimals, ethmoid, inferior nasal conchae, palatines, vomer, zygomatics, and sphenoid.

- The **alveolar process** is the horizontal portion of the maxilla that holds the tooth roots.
- Alveoli** for the tooth roots are present all along the alveolar process, except where these have been resorbed following the loss of teeth.
- The **canine jugum** is a bony eminence over the maxillary canine root on the facial surface of the maxilla.
- The **zygomatic process** forms much of the cheek.
- The **infraorbital foramen** is located below the inferior orbital rim on the facial surface and transmits the *infraorbital nerve* (a division of cranial nerve 5) and *vessels* to the face.
- The **canine fossa** is a hollow of variable extent located on the facial surface just below the infraorbital foramen, where the zygomatic, frontal, and alveolar processes of the maxilla come together.
- The **anterior nasal spine** is the thin projection of bone on the midline at the inferior margin of the nasal aperture.
- The **infraorbital sulcus** (or **groove**) is centered on the posterior half of the orbital floor and opens posterosuperiorly. It connects anteroinferiorly with the infraorbital foramen via the **infraorbital canal**.
- The **maxillary sinus** is the large void in the body of the maxilla, superior to the alveolar process and inferior to the orbital floor.
- The **frontal process** rises to articulate with the frontal, nasals, lacrimal, and ethmoid.
- The **anterior lacrimal crest** is a vertical crest located on the lateral aspect of the frontal process of the maxilla, and marking the anterior extent of the **lacrimal groove**. The lacrimal

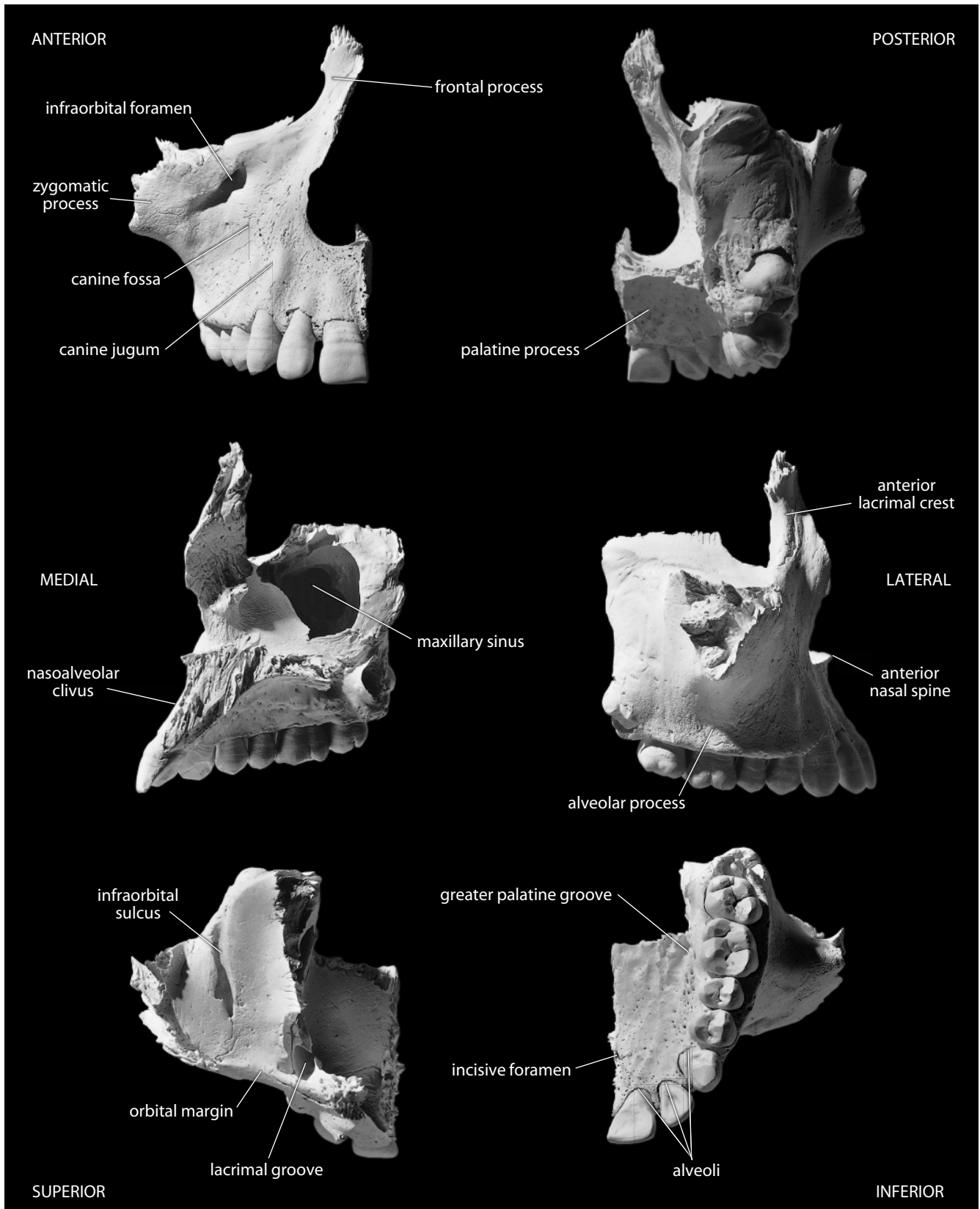


Figure 4.25 Right maxilla. Natural size.

groove of the maxilla combines with the lacrimal bone to form the **lacrimal canal**. This canal houses the *nasolacrimal duct*, which drains tears inferiorly into the nasal cavity.

- l. The **palatine process** forms the anterior two-thirds of the hard palate and floor of the nasal cavity.
- m. The **incisive foramen** perforates the anterior hard palate at the midline.
- n. The **incisive canal** is bilobate, opening via the incisive foramen, with each lobe enclosed by one of the maxillae. Each lobe of the canal transmits the *terminal branch of the greater palatine artery* and the *nasopalatine nerve*.
- o. The **premaxillary suture** is sometimes seen in the wall of the incisive canal and on the adjacent palatal surface, particularly in young individuals.
- p. The **greater palatine groove** at the rear of the hard palate marks the junction of the palatine and alveolar processes. This groove is for the *greater palatine vessels* and *nerve*.
- q. The **maxillary tuber** is the rugose surface at the posterior end of the alveolar process. It is variable in expression, articulating with the pyramidal process of the palatine and sometimes with the lateral pterygoid plate of the sphenoid.
- r. The **nasopalveolar clivus** is the surface between the canine jugae, the base of the piriform aperture, and the alveolar margin.

4.12.2 Growth

Each maxilla ossifies from two main combined centers, one for the maxilla proper and one for the premaxilla. These fuse early in human development, about the ninth week *in utero*, but the suture between them may persist into adulthood in the region adjacent to the incisive canal.

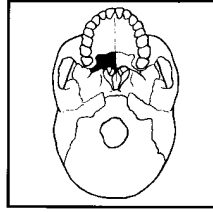
4.12.3 Possible Confusion

Small fragments of maxilla might be confused with other cranial bones. Because the bone is complex, it is helpful to note the diagnostic features useful in identifying it. These include the alveolar region, the sharp edges of the nasal aperture, the edge of the lacrimal canal, the large maxillary sinus, and the unique, serrated intermaxillary suture.

4.12.4 Siding

Fragments of maxilla may prove difficult to side and the use of comparative specimens may prove necessary.

- For a broken frontal process, the thinner edge is anterior and medial, the medial surface is vascularized (perforated by blood vessels), and the anterior lacrimal crest is lateral.
- For any segment with alveolar bone preserved, tooth roots or sockets can be used as a guide to medial, lateral, anterior, and posterior.



4.13 Palatines (Figure 4.26)

4.13.1 Anatomy

The small, delicate, L-shaped palatine bones form the rear of the hard palate and part of the wall and floor of the nasal cavity. Individual palatine bones are almost never found in an isolated, intact state; they generally accompany the maxillae and sphenoid, to which they are tightly bound. In addition to these two, palatines articulate with the vomer, inferior nasal conchae, ethmoid, and with each other.

- a. The **horizontal plate** of the palatine forms the posterior third of the hard palate.
- b. The **greater palatine foramen** (or **canal**) perforates the rear corner of the hard palate and is formed as the alveolar process of the maxilla meets the horizontal plate of the palatine. This canal transmits the *greater palatine vessels* and *nerve*.

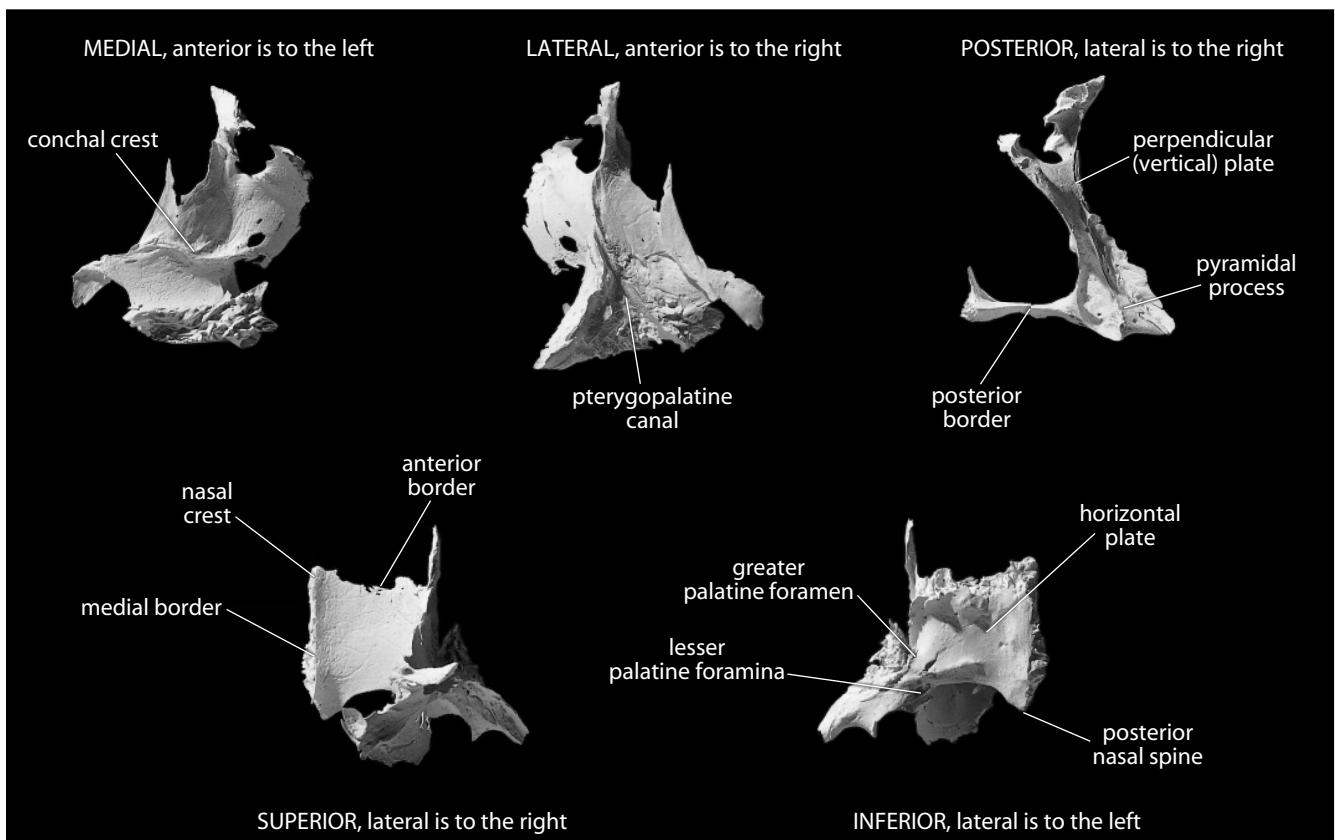


Figure 4.26 Right palatine. Natural size.

- c. The two halves of the **pterygopalatine canal** become visible, sweeping posterosuperiorly, when the maxilla and perpendicular plate of the palatine are disarticulated.
- d. The **posterior nasal spine** is located on the superior surface of the horizontal plate. The superior, or nasal cavity, surface of the plate is smoother and more regular than the palatal surface.
- e. **Lesser palatine foramina**, for the transmission of *lesser palatine nerves*, are located on the posterolateral corner of the hard palate posterior to the greater palatine foramina, near the junction of the perpendicular and horizontal plates.
- f. The **perpendicular (or vertical) plate** is appressed tightly to the posteromedial wall of the maxilla opposite the maxillary sinus, between the pterygoid plates of the sphenoid and the posterior margin of the alveolar process of the maxilla.
- g. The posterior border of the perpendicular plate is the thickest border. It bears a serrated groove that articulates with the medial pterygoid plate of the sphenoid. This area of the bone is called the **pyramidal process**.
- h. The **conchal crest** is a subhorizontally oriented crest placed not quite halfway up the perpendicular plate on the medial surface of the plate. This crest is for articulation with the inferior nasal concha.

4.13.2 Growth

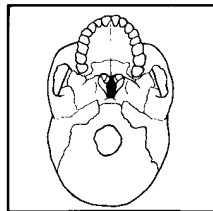
Palatine bones ossify intramembranously from single centers.

4.13.3 Possible Confusion

Because the palatines are almost always attached to the maxillae and sphenoid, identification is not usually difficult. When small, isolated fragments of palatine are encountered, note the free posterior edge of the horizontal plate and the smooth, even concavity on the nasal surface of this plate.

4.13.4 Siding

Because isolated fragments of palatine most often preserve the horizontal plate, note that the superior surface is smooth, that the inferior (palatal) surface is rough, that the posterior edge is non-articular, and that greater and lesser palatine foramina are posterolateral.



4.14 Vomer (Figure 4.27)

4.14.1 Anatomy

The vomer is a small, thin, plow-shaped, midline bone that occupies and divides the nasal cavity. It articulates inferiorly on the midline with the maxillae and the palatines, superiorly with the sphenoid via its wings, and anterosuperiorly with the ethmoid. Thus, the bone forms the postero-inferior part of the nasal septum, which divides the nasal cavity.

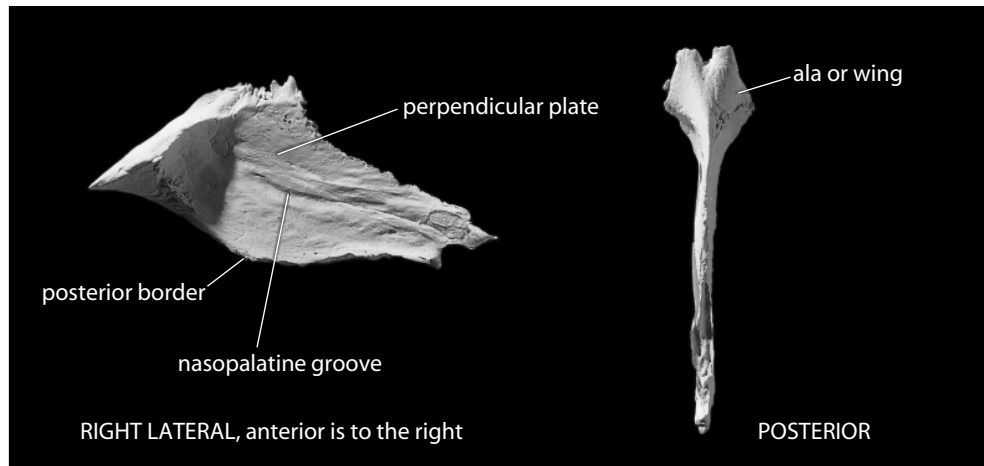


Figure 4.27 **Vomer**. Superior is up. Natural size.

- a. **Alae**, or **wings**, of the vomer are located on either side of a deep midline furrow on the superior surface of the vomer. This part of the bone is the thickest and sturdiest and is tightly appressed to the sphenoid.
- b. The **perpendicular plate** of the vomer is a thin vertical sheet of bone on the midline below the wings.
- c. The nonarticular **posterior border** of the vomer divides the posterior nasal aperture into two halves.
- d. **Nasopalatine grooves** lodge *nasopalatine nerves* and *vessels*, marking both sides of the perpendicular plate, where they run anteroinferiorly from the alae.

4.14.2 Growth

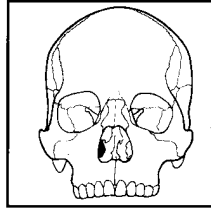
Another bone with both endochondral and membranous ossification, the vomer ossifies from two plates (laminae) on either side of a median plate of cartilage. By puberty, the lamellae are virtually united, but the bilaminar origin of the bone is discernible in the cleft between the alae.

4.14.3 Possible Confusion

Because of the midline placement of the vomer, symmetry is the best guide to identification. Isolated vomers are rarely found and almost never recovered intact. To avoid confusion with other thin bones, such as the sphenoid, note that the vomer has alae and that the perpendicular plate is symmetrical, with a free posterior edge.

4.14.4 Siding

The nonmidline portions of the vomer are so small that siding criteria are unnecessary for this bone.



4.15 Inferior Nasal Conchae (Figure 4.28)

4.15.1 Anatomy

Inferior nasal conchae extend horizontally along the lateral walls of the nasal cavity, articulating with the medial wall of the maxillae and with the palatines. They also articulate with the ethmoid and lacrimals superiorly. The bones are rarely found isolated because they are so fragile. Their shape is variable, with the anterior and posterior extremities tapered to a point, and the inferior surface free, thickened, and vascularized. Inferior nasal conchae function in olfaction and in humidifying inhaled air.

- The **maxillary process** of the inferior nasal concha is the delicate hook of bone extending towards the medial surface of the maxilla.
- The **lamina** of the inferior nasal concha is a thin, vertical, undulating sheet of bone extending medially and inferiorly from the maxillary process.
- The **lacrima process** of the inferior nasal concha extends superiorly to contribute to the medial wall of the inferior lacrimal canal.
- The **ethmoidal process** of the inferior concha is just posterior to the lacrimal process.

4.15.2 Growth

The inferior nasal conchae ossify from single centers.

4.15.3 Possible Confusion

Because inferior nasal conchae are so fragile, they are virtually never found intact as isolated specimens. Small fragments might be mistaken for ethmoid, sphenoid, or lacrimal. Note, however, that the surface texture of the inferior nasal conchae is highly perforated by numerous tiny apertures, giving them a fragile and lightweight aspect.

4.15.4 Siding

There is little use for knowledge of siding inferior nasal conchae.

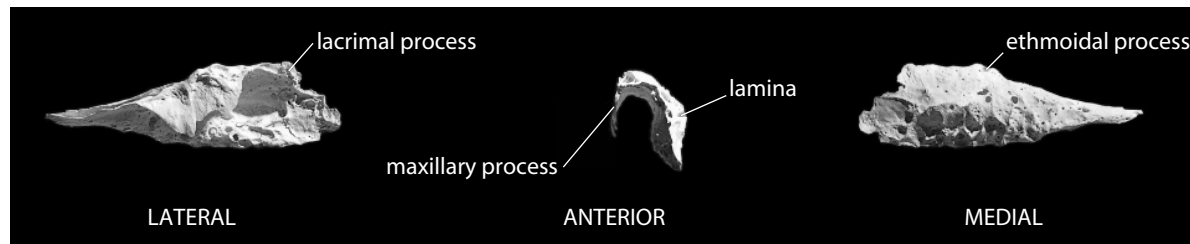
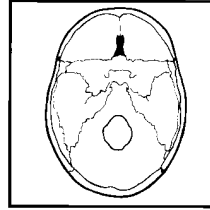


Figure 4.28 **Right inferior nasal concha.** *Left:* lateral view, anterior is to the right, superior is up; *middle:* anterior view, lateral is to the left, superior is up; *right:* medial view, anterior is to the left, superior is up. Lit from the upper right for detail. Natural size.



4.16 Ethmoid (Figure 4.29)

4.16.1 Anatomy

The ethmoid bone is exceedingly light and spongy. It is roughly the size and shape of an ice cube, but is only a fraction as heavy. It is located between the orbits, centered on the midline. It articulates with 13 bones: the frontal, sphenoid, nasals, maxillae, lacrimals, palatines, inferior nasal conchae, and vomer. The ethmoid is virtually never found as a unit because of its fragility. It is best viewed in a specially disarticulated skull, where its complexity can be appreciated.

- a. The **cribriform plate** is best observed endocranially, where the ethmoid can be seen to fill the ethmoidal notch of the frontal. The cribriform plate roofs the nasal cavities, and because it is perforated by many tiny foramina it looks like a sieve. *Olfactory nerves* (cranial nerve 1) perforate this plate as they pass up to the brain from the mucous lining of the nose.
- b. The **crista galli** is a perpendicular projection of the cribriform plate of the ethmoid into the endocranial cavity. It is interposed between *olfactory bulbs*, and its posterior surface anchors the *falx cerebri*, a fold of the *dura mater* extending into the longitudinal fissure of the brain between the two *cerebral hemispheres*.
- c. The **labyrinths**, or **lateral masses**, of the ethmoid lie to either side of the midline and consist of a series of thin-walled ethmoidal cells. The lateral plates of the ethmoidal labyrinths form most of the medial orbital walls, and the medial plates form the upper walls of the nasal cavity.
- d. The **perpendicular plate** of the ethmoid is a flattened lamina placed at the midline between the lateral masses. It forms part of the nasal septum and articulates inferiorly with the vomer.

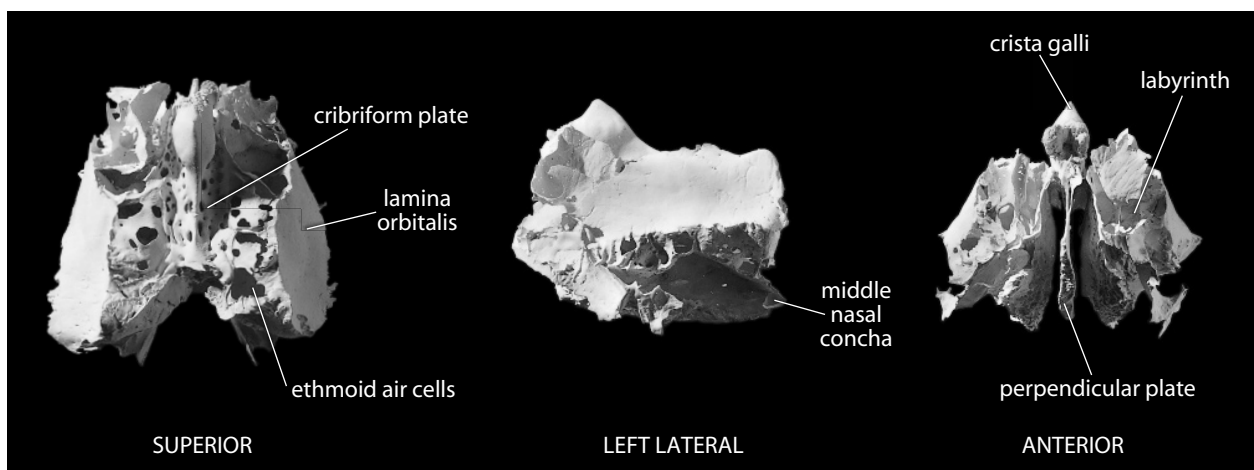


Figure 4.29 **Ethmoid**. *Left*: superior view, anterior is up; *middle*: left lateral view, anterior is to the left; *right*: anterior view, superior is up. Natural size.

4.16.2 Growth

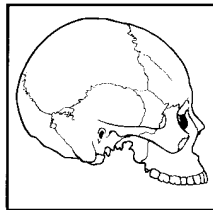
The ethmoid is the only basicranial bone that is entirely preformed in cartilage. It ossifies from three centers, one for each labyrinth and one for the perpendicular plate. During the first year after birth, the perpendicular plate and crista galli begin to ossify. They are joined in the second year to the labyrinths.

4.16.3 Possible Confusion

The thin plates of the ethmoid might be difficult to identify when found isolated, but this bone is rarely found by itself. More often, pieces of it adhere to the other bones it articulates with, most commonly the frontal or sphenoid. The perpendicular plate might be confused with the vomer, but the vomer has a nonarticular posterior edge and a thickened edge where the alae join.

4.16.4 Siding

The portions of ethmoid that are usually found isolated are both midline structures—the crista galli and the perpendicular plate.



4.17 Lacrimals (Figure 4.30)

4.17.1 Anatomy

The lacrimals are very small, thin, fragile bones of rectangular shape. The lacrimals make up part of the medial walls of the orbits anterior to the ethmoid. They articulate with the frontal, maxillae, ethmoid, and inferior nasal conchae. They are virtually never found alone but are often attached to facial fragments. The lacrimals have orbital and nasal (lateral and medial) surfaces and four borders.

- a. The **posterior lacrimal crest** is a vertical crest on the medial orbital wall that bounds the posterior half of the lacrimal groove.

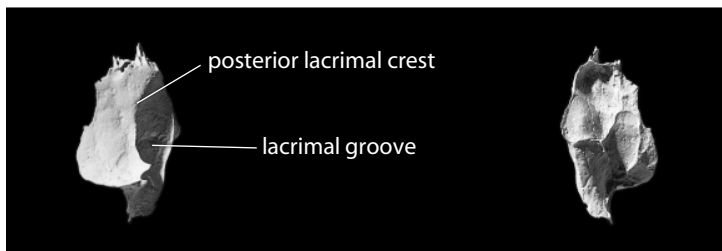


Figure 4.30 **Right lacrimal.** *Left:* lateral view, anterior is to the right, superior is up; *right:* medial view, anterior is to the left, superior is up. Natural size.

- b. The **lacrima groove** (or **sulcus**) forms the posterior portion of the superior end of the lacrimal canal.

4.17.2 Growth

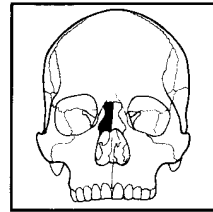
The lacrimal ossifies intramembranously from a single center.

4.17.3 Possible Confusion

The lacrimal crest is diagnostic, and although the lacrimal is virtually never found alone, it can often help to identify adjacent bones.

4.17.4 Siding

The posterior lacrimal crest is oriented vertically, and the lacrimal groove is anterior to the crest. The base of the crest sweeps anteriorly to become a margin for the lacrimal canal.



4.18 Nasals (Figure 4.31)

4.18.1 Anatomy

The nasals are small, thin, rectangular bones placed on either side of the midline below the glabella region of the frontal. Their free inferior ends form the top margin of the anterior nasal aperture. The nasals articulate with the frontal superiorly, with each other medially, and with the frontal processes of the maxillae laterally. They articulate posteriorly with the ethmoid.

- a. The **nasal foramen** perforates the facial surface and transmits a vein.

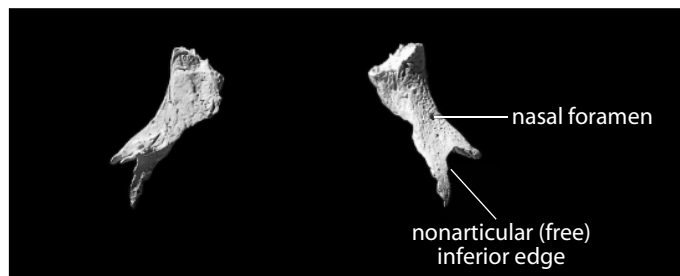


Figure 4.31 **Right nasal.** *Left:* medial view, anterior is to the left, superior is up; *right:* lateral view, anterior is to the right, superior is up. Natural size.

4.18.2 Growth

Each nasal ossifies intramembranously from a single center.

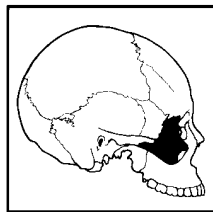
4.18.3 Possible Confusion

It is difficult to confuse the nasal with other bones because of its diagnostic internasal suture, the external foramen and internal groove, the smooth outer and rough inner surface, and the non-articular, free inferior edge.

4.18.4 Siding

Use the criteria mentioned in Section 4.18.1 to side nasal bones.

- The free edge is inferior, the thickest articular edge is medial, and the frontonasal suture is interdigitating and superior.



4.19 Zygomatics (Figure 4.32)

4.19.1 Anatomy

Zygomatics form the prominent corners (cheeks) of the face. The edges are easily identifiable, with the rounded orbital rim, the sharp area around jugale adjacent to the temporal fossa, and the roughened inferior border. Each zygomatic bone articulates, via its three main processes, with the frontal, sphenoid, temporal, and maxilla.

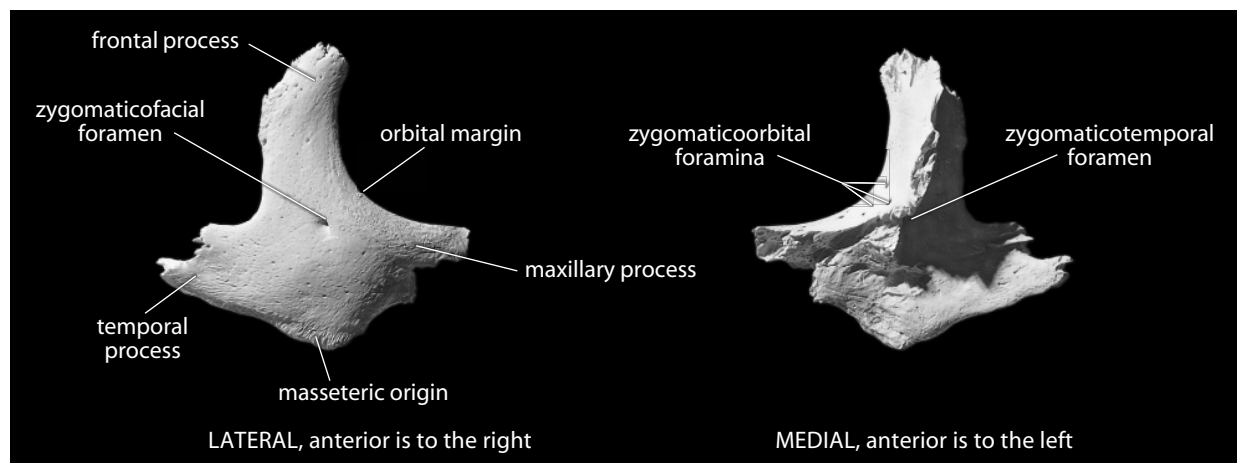


Figure 4.32 Right zygomatic. Superior is up. Natural size.

- a. The **frontal process** rises vertically and separates the orbit from the temporal fossa.
- b. The **temporal process** extends posteriorly, joining the zygomatic process of the temporal bone to form the zygomatic arch.
- c. The **maxillary process** extends toward the midline, forming the inferolateral orbital margin.
- d. The **zygomaticofacial foramen** perforates the convex lateral surface of the zygomatic. It is often multiple, allowing the passage of the *zygomaticofacial nerve* (a division of cranial nerve 5) and *vessels*.
- e. The **masseteric origin**, the roughened, expanded inferior edge of the bone, extends from the zygomaticomaxillary to the temporozygomatic suture (and on to the temporal). This is the main attachment point for the *masseter muscle*, a major elevator of the mandible.
- f. **Zygomaticoorbital foramina** perforate the inferolateral corner of the orbital cavity for the passage of the *zygomaticotemporal* and *zygomaticofacial nerves* (also divisions of cranial nerve 5).
- g. The **zygomaticotemporal foramen** is centered in the temporal surface of the zygomatic. It transmits the *zygomaticotemporal nerve*.

4.19.2 Growth

The zygomatic bone ossifies from three centers that fuse into a single combined center during fetal development.

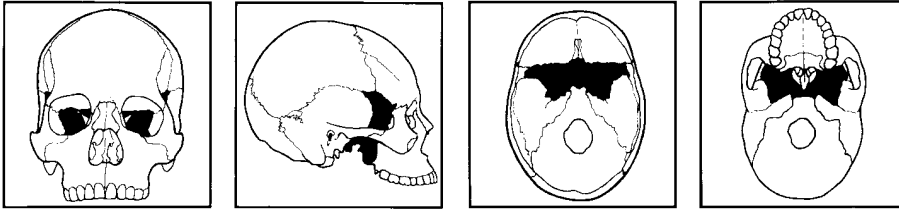
4.19.3 Possible Confusion

The three diagnostic borders of the zygomatic bone make identification easy. The most frequent confusion comes in mistaking the zygomatic process of the temporal for the zygomatic bone. None of the processes of the zygomatic bone proper are as thin or extended as the zygomatic process of the temporal.

4.19.4 Siding

To side isolated or fragmentary zygomatic bones, remember the relations of this bone to the orbit, the *masseter muscle*, and the temporal fossa.

- The masseteric attachment is inferior, and the convex surface is anterior and lateral, and is perforated by foramina.
- The orbital rim is blunter than the jugal margin posterior to it.



4.20 Sphenoid (Figures 4.33–4.36)

4.20.1 Anatomy

The sphenoid is the most complex bone of the cranium. Although its name means “wedgelike,” its shape is far more elaborate. It is very difficult to visualize this bone when working with an articulated cranium because it has surfaces that face many directions—endocranially, inferiorly, laterally, and anteriorly. The sphenoid is situated between the bones of the cranial vault and those of the face. For this reason, and because many parts of the bone are thin, the sphenoid is virtually never found intact in broken crania. Instead, portions of it adhere to other cranial pieces.

The many articulations of the sphenoid were noted above as each of the 12 bones it touches were introduced. These are reviewed in the descriptions given here. The articulating midline bones are the vomer, ethmoid, frontal, and occipital. The sphenoid also articulates with the paired parietals, temporals, zygomatics, and palatines (and sometimes, the maxillae) lateral to the midline. Examination of the sphenoid is simplified by dealing with four basic parts of the bone, the body, greater and lesser wings, and the pterygoid plates. For an overall perspective, view the sphenoid from behind, visualizing it as a flying animal with a central body, two pairs of wings, and dangling talons (the pterygoid plates).

- a. The **body** is the only part of the sphenoid that lies on and immediately adjacent to the midline. This is the most substantial part of the bone. Its anterior surface forms the posterosuperior wall of the nasal cavity and articulates with the cribriform and perpendicular plates of the ethmoid. Posteriorly, the body articulates with the occipital across the sphenoid-occipital synchondrosis (basilar suture); anteroinferiorly it articulates with the vomer.
- b. **Optic canals** are seen to either side of the body. They pass anteroinferior to the lesser wings, just medial and superior to the superior orbital fissure. The *optic nerve* (cranial nerve 2) and *ophthalmic artery* pass through these canals on their way to the eyeballs.
- c. The **sella turcica** (“Turkish saddle”) is a saddle-shaped depression on the endocranial surface of the sphenoid. It is located endocranially, posterior and inferior to the optic canals, atop the body of the sphenoid, decorated by the four clinoid processes.
- d. The **hypophyseal (pituitary) fossa** is the deepest depression of the sella. It holds the *pituitary gland*, the manufacturer of growth hormones.
- e. The **dorsum sellae** is the square plate of bone that forms the posterior boundary of the sella turcica.
- f. The **posterior clinoid processes** are the two highly variable tubercles located at the superolateral corners of the dorsum sellae.
- g. The **clivus** is the slight endocranial hollow that slopes posteriorly from the dorsum sellae toward the basilar suture.
- h. The **sphenoidal sinuses** are large, paired hollows within the body of the sphenoid.
- i. The **sphenoidal rostrum** is a midline bony projection on the anteroinferior surface of the body of the sphenoid. It fits into the fissure between the alae of the vomer.

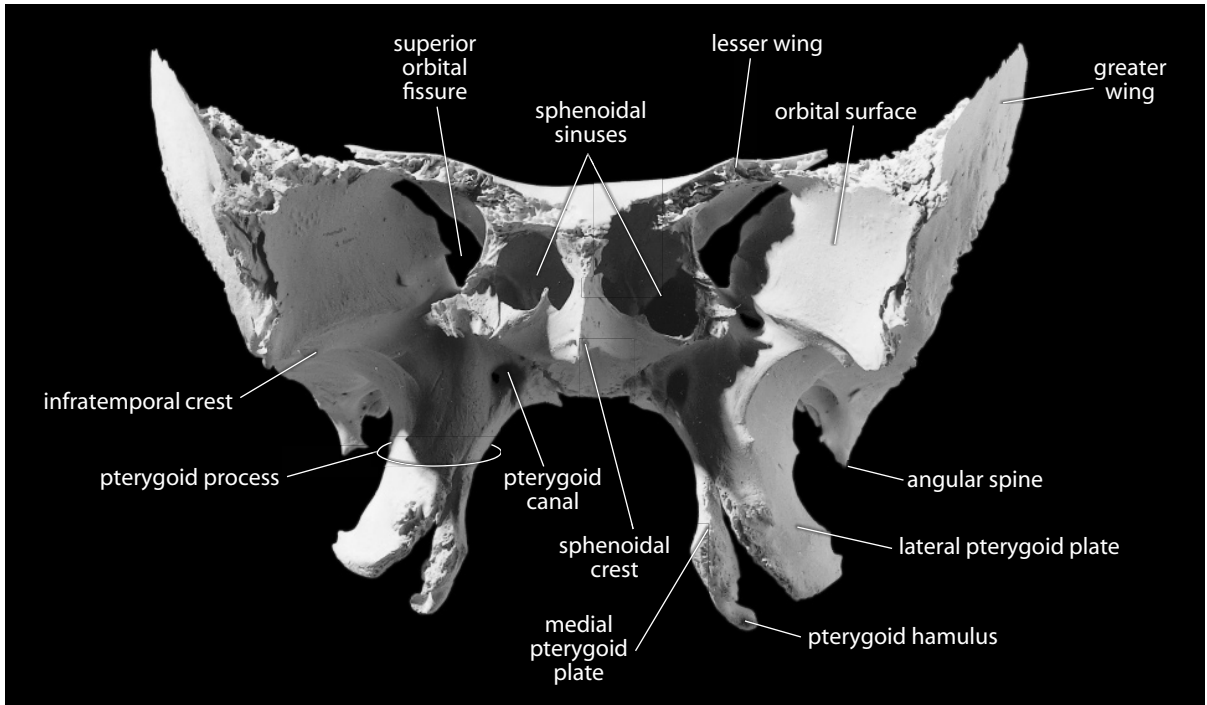


Figure 4.33 Sphenoid, anterior. Superior is up. Natural size.

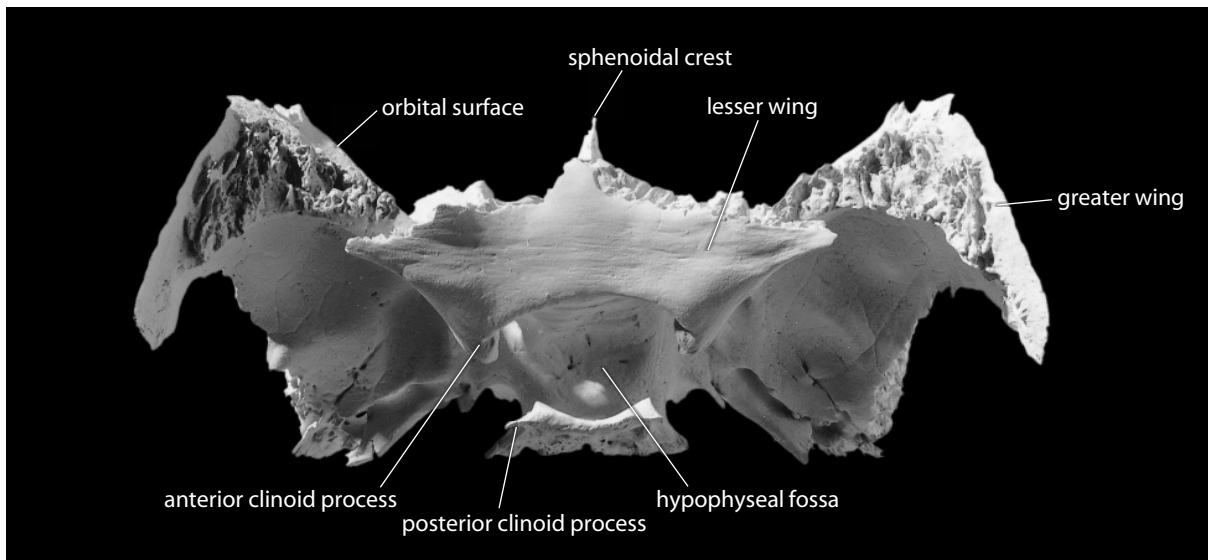


Figure 4.34 Sphenoid, superior (endocranial). Anterior is up. Natural size.

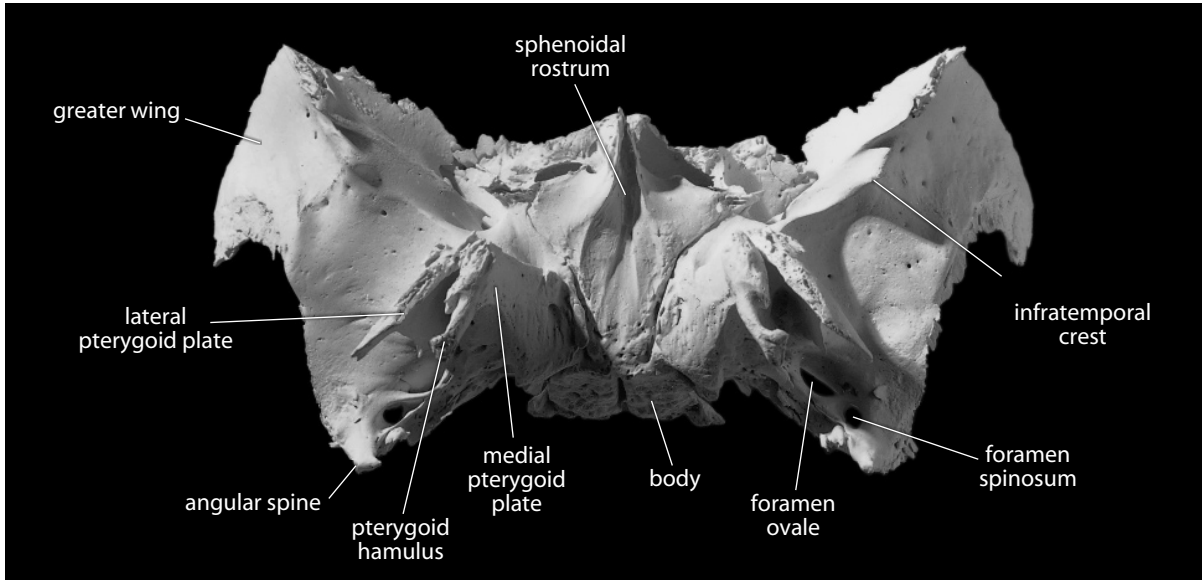


Figure 4.35 Sphenoid, inferior. Anterior is up. Natural size.

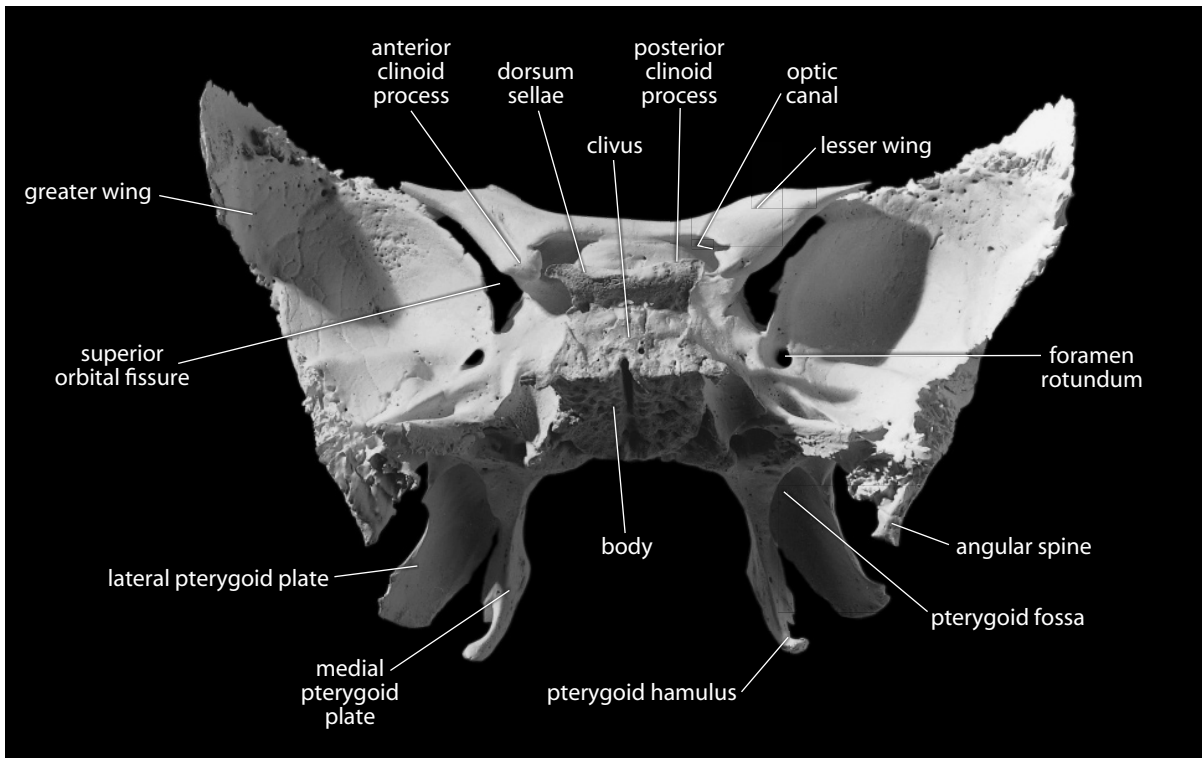


Figure 4.36 Sphenoid, posterior. Superior is up. Natural size.

- j. The **sphenoidal crest** is continuous with the rostrum, extending superiorly from it on the anterior surface of the body of the sphenoid. This midline sphenoidal crest articulates with the perpendicular plate of the ethmoid and forms part of the septum of the nose.
- k. The **greater wings** of the sphenoid (right and left) are attached to the body. They are the segments that extend the farthest laterally from the body, forming most of the middle cranial fossae endocranially and much of the temporal fossae ectocranially. The greater wings articulate with the temporals, parietals, frontal, zygomatics, and maxillae.
- l. The **superior orbital fissures** are the open spaces (gaps) between the inferior surfaces of the lesser wings and the anterior surfaces of the greater wings. The fissures are visible at the back of the orbits in an anterior view of the cranium. The superior orbital fissure and three foramina identified later are best seen on the endocranial surface of the sphenoid. These openings are arranged in the form of an arc that sweeps posterolaterally from the midline in the area where the greater wing and body merge. The arc is sometimes called the “crescent of foramina.”
- m. The **foramen rotundum** is situated in the most anterior and medial part of the middle cranial fossae at the junction of the greater wings and the body. These foramina transmit the *maxillary nerves* (another division of cranial nerve 5) that run just inferior to the superior orbital fissures.
- n. The **foramen ovale** is located posterior to the foramen rotundum on each side, approximately in line with the dorsum sellae in endocranial view. These foramina transmit the *mandibular nerves* and *accessory meningeal arteries*.
- o. The **foramen spinosum** is located on each greater wing just posterolateral to the foramen ovale. The foramina spinosa are set in the posteroinferior spines of the sphenoid, very close to the temporal bones. They transmit the *middle meningeal vessels* and branches from the *mandibular nerves*.
- p. The **infratemporal crests** mark the ectocranial surfaces of the greater wings. They form the base of the temporal fossae at about the level of the zygomatic arches.
- q. The **orbital surfaces** of the greater wings of the sphenoid, which form the lateral wall of each orbit, are very smooth and flat in comparison to the endocranial surfaces.
- r. The **lesser wings**, which are much smaller than the greater, are thin, wing-shaped posterior projections of the endocranial surface. These partially floor the right and left frontal lobes of the brain. They arise from the superior surface of the body and articulate with the horizontal orbital plates of the frontal.
- s. The **anterior clinoid processes** are the posteriormost projections of the lesser wings. These give attachment to the *tentorium cerebelli*, a segment of *dura mater* that separates the cerebellum from the occipital part of the *cerebral hemispheres* of the brain.
- t. The **angular spine** (or **sphenoid spine**) is the inferiormost projection of the greater wing, located posterior to foramina spinosum and ovale. It serves as an attachment point for the *pterygospinous ligament*.
- u. The **pterygoid processes** of the sphenoid are visible only from below or to the side of the cranium. The pterygoid processes are each divided into two thin plates.
- v. The **lateral pterygoid plate** (or **lamina**) is a thin vertical plate of bone seen in lateral view of the cranium.
- w. The **medial pterygoid plate** (or **lamina**) is a thin vertical plate of bone that roughly parallels the lateral plate in orientation but is set closer to the midline. Each pair of pterygoid plates articulates anteriorly with the palatines. These four thin projections provide attachment for the *medial pterygoideus muscles*, mandibular elevators.
- x. **Pterygoid fossae** are rough-floored hollows between the medial and lateral pterygoid plates.
- y. The **pterygoid hamulus** is the hook-like process forming the posterolateral, basal corner of each medial pterygoid plate.

- z. **Pterygoid canals** perforate the bone above the pterygoid plates and run along the base of these plates.

4.20.2 Growth

The sphenoid is mostly formed in cartilage; only the pterygoid plates form dermally. Growth is complex, with a number of centers of ossification involved, but this bone is recognizable by the time of birth.

4.20.3 Possible Confusion

Because it has so many parts, broken fragments of sphenoid are often difficult to identify. Only an intensive study of the various anatomical parts introduced above will allow confident identification of isolated fragments. Fortunately, fragments of sphenoid are usually attached to other cranial bones, and identification is aided by this fact. The parts most often found isolated are the greater wings and the body.

The nature of the suture between the temporal, parietal, and sphenoid helps in the identification and siding of sphenoid fragments. The sphenoid overlaps the parietal superiorly and underlaps the temporal posteriorly. It abuts the temporal in basicranial aspect.

4.20.4 Siding

- For pterygoid plates, the pterygoid fossa faces posteriorly, and the plates have nonarticular, sharp posterior and inferior edges.
- For the greater wing, the smooth, flat orbital surfaces face anteriorly, and the concave temporal surfaces face laterally.
- The endocranial surface is posterosuperior, and its base is marked by the foramina rotunda, ovale, and spinosa. The latter foramen is at the spine of the greater wing, the most posterolateral extent of the wing, often on the sphenosquamous suture.
- For a fragmentary lesser wing, the free, nonarticular end is posterior, the wing tips face laterally, and parts of the frontal often adhere anteriorly. The anterior clinoid process points posteriorly.

4.21 Mandible (Figures 4.37–4.39)

4.21.1 Anatomy

The mandible, or lower jaw, articulates through its condyles (via an articular disk) with the temporal bones at the temporomandibular joint. The primary function of this bone is in **mastication** (chewing). The mandible holds the lower teeth and provides insertion surfaces for the muscles of mastication. These two functions are performed by the two basic parts of the mandible: the body (corpus) and the ascending ramus.

- a. The **body** (or **corpus**, or **horizontal ramus**) is the thick, bony part of the mandible that anchors the teeth. With its implanted teeth, the corpus of the mandible is very hard, dense, and resistant to destruction. For this reason, mandibular corpora outlast other body parts in bone assemblages that have been ravaged by carnivores or subjected to physical degradation.

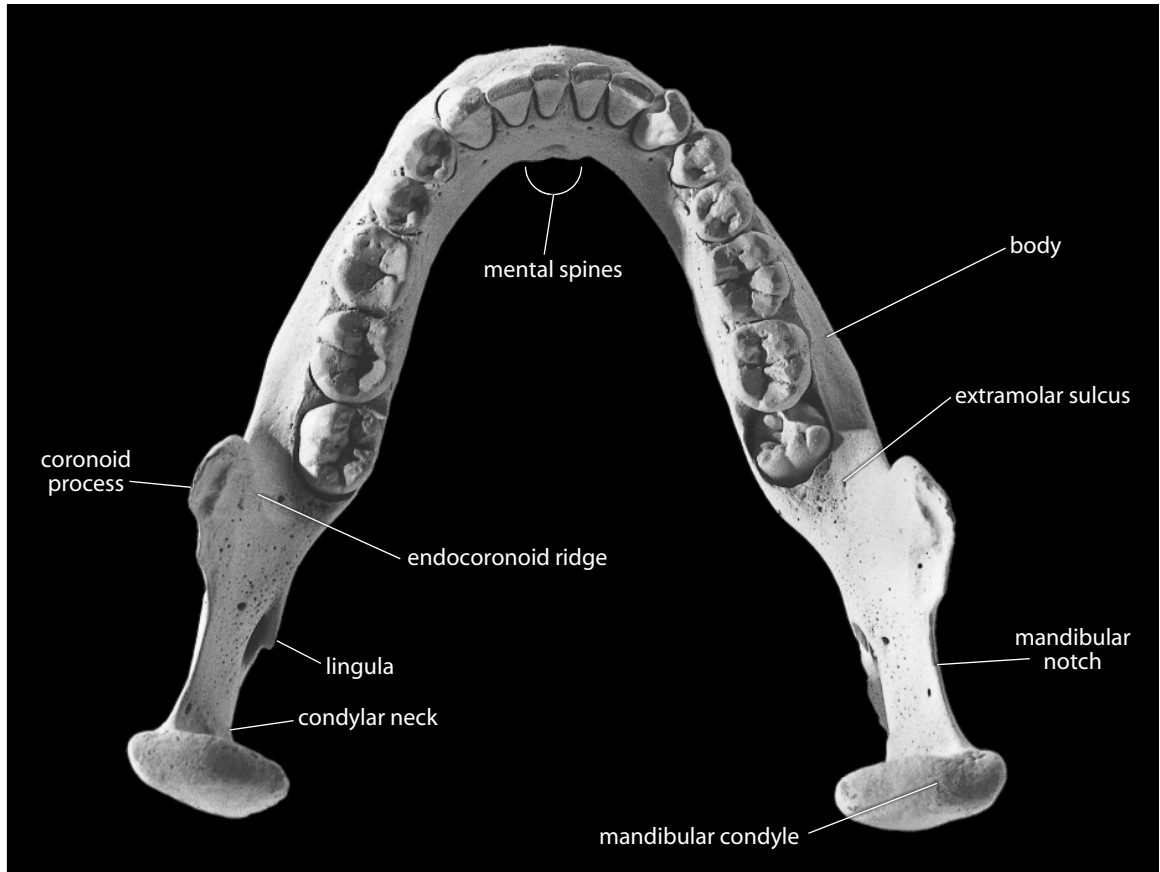


Figure 4.37 Mandible, superior. Natural size.

- b. The **alveolar portion** of the corpus contains the **alveoli** for the tooth roots, except where these have been resorbed following the loss of teeth.
- c. The **mental foramen** is the large, sometimes multiple foramen located on the lateral corpus surface, near mid-corpus, below the premolar region. This foramen transmits the *mental vessels* and *nerve* (another division of cranial nerve 5).
- d. The **oblique line** is a weak eminence that passes from the root of the ramus to the area at the rear of the mental foramen.
- e. The **extramolar sulcus** is the gutter between the root of the anterior edge of the ramus and the lateral alveolar margin of the last molar. This area gives rise to the *buccinator muscle*, the muscle of the cheek.
- f. The **mylohyoid line** obliquely crosses the medial surface of the corpus, beginning near the alveolar margin at the last molar position and diminishing as it runs anteroinferiorly. It marks an attachment site for the *mylohyoid muscle*, a muscle that forms the muscular floor of the oral cavity and acts to elevate the *tongue* and hyoid bone.
- g. The **submandibular fossa** is the hollow beneath the alveolar portion that runs along the medial corpus, inferior to the mylohyoid line. In life, the *submandibular gland*, one of the salivary glands, rests in this fossa.
- h. The **sublingual fossa** is the hollowing beneath the alveolar region, superior to the my-

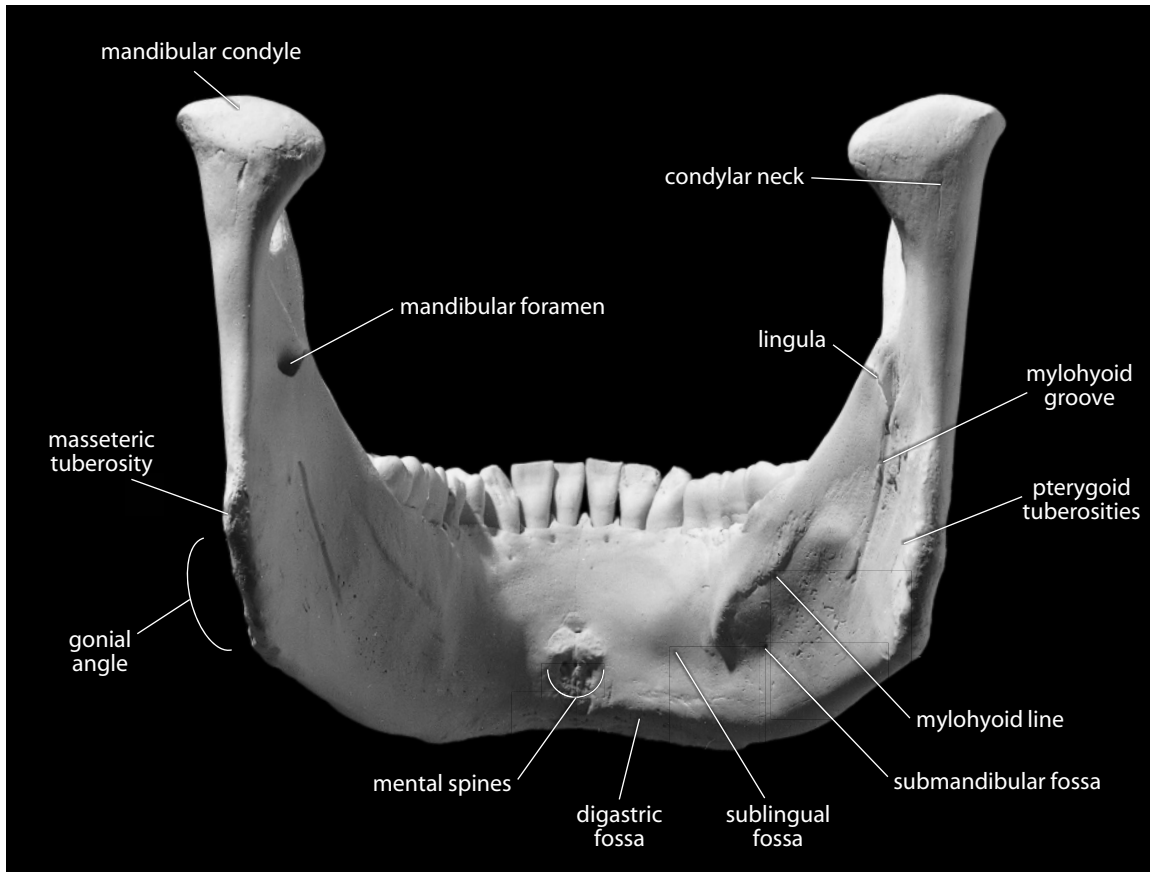


Figure 4.38 Mandible, posterior. Natural size.

lohyoid line in the premolar region. The *sublingual gland*, another salivary gland, rests in this fossa.

- i. A **mandibular torus** is the variably developed thickening of the alveolar margin just lingual to the cheek teeth. This feature takes on a billowed appearance in its most extreme manifestations but is often imperceptible.
- j. The **mandibular symphysis** technically refers only to the midline surfaces of unfused right and left mandibular halves in individuals less than 1 year of age. It is often used as a more general term referring to the anterior region of the mandible between the canines.
- k. The **mental spines** lie near the inferior margin of the inner (posterior) surface of the anterior corpus. They are variable in prominence and anchor the *genioglossus* and *geniohyoid muscles*, muscles of the tongue.
- l. The **digastric fossae** are the pair of roughened depressions on the posteroinferior aspect of the corpus adjacent to the midline. They face posteroinferiorly and are attachment sites for the *digastric muscles*, depressors of the mandible.
- m. The **mental protuberance** (or **eminence**) is the triangular eminence, or bony chin, at the base of the corpus in the anterior symphyseal region. It is separated from the alveolar margins of the incisors by a pronounced incurvation or “mental sulcus” (or the “labiomental sulcus” if flesh is still attached to the depression) in modern humans.

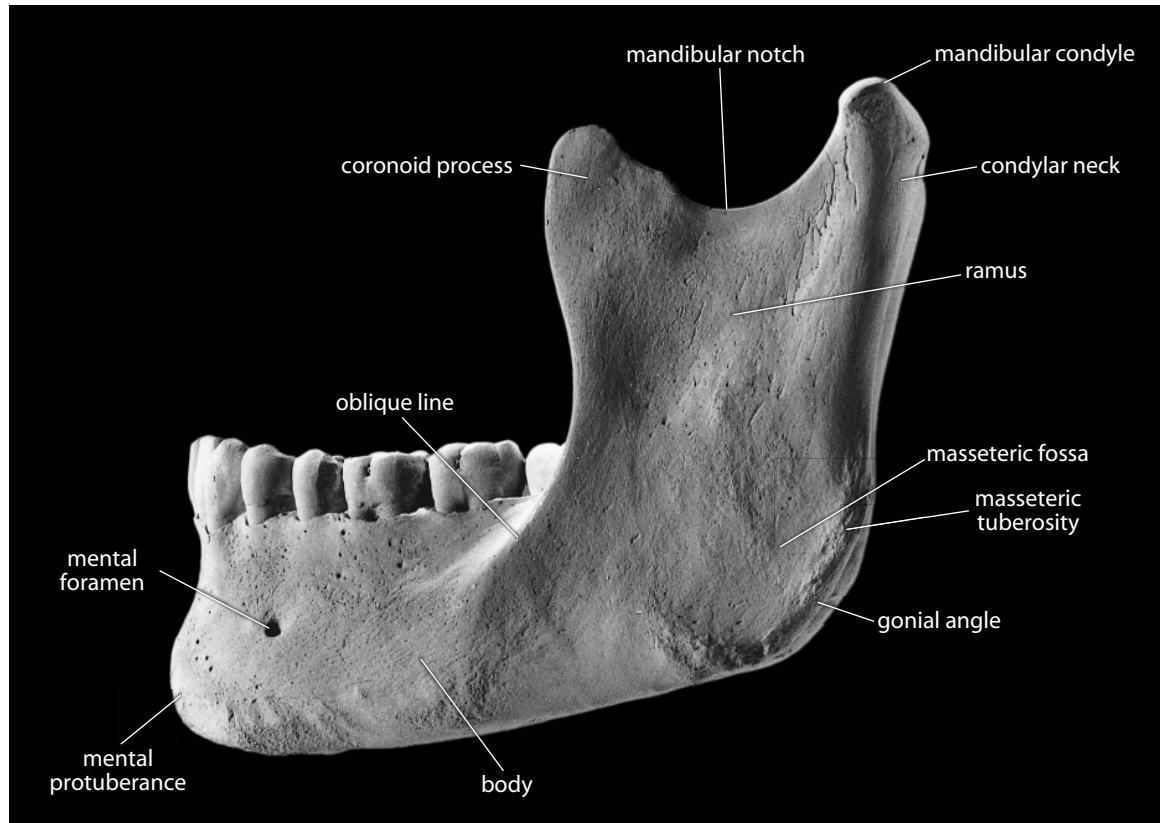


Figure 4.39 Mandible, lateral. Natural size.

- n. The **ramus** (or **ascending ramus**) is considerably thinner than the corpus. This vertical part of the mandible rises above the level of the teeth and articulates with the cranial base.
- o. The **mandibular condyle** is the large, rounded, articular prominence on the posterosuperior corner of the ramus. It articulates at the temporomandibular joint.
- p. The **condylar neck** is the area just anteroinferior to the condyle. A head of the *lateral pterygoideus muscle* attaches to the anteromedial surface of the neck just below the articular surface of the condyle, in the **pterygoid fovea**. This muscle acts to depress and stabilize the mandibular condyle during chewing.
- q. The **coronoid process** of the ramus is thin and triangular, varying widely in shape and robusticity. Its anterior border is thickened and convex, and its posterior edge is concave and thinner. Both medial and lateral surfaces of this process receive the insertion of the *temporalis muscle*.
- r. The **mandibular notch** (or **incisura**) is the notch between the condyle and the coronoid process.
- s. The **gonial angle** is the rounded posteroinferior corner of the mandible. The *masseter muscle* attachment is centered on the lateral surface of the ramus, all along the angle.
- t. The **masseteric tuberosity** is the raised, roughened area at the lateral edge of the gonial angle at which the *masseter muscle* attaches. This area is often joined by oblique ridges

raised by *masseter* attachment. When the edge of the gonial angle projects far laterally from the rest of the ramus, the gonial area is said to be strongly **everted**.

- u. The **masseteric fossa** is a variably expressed hollowing on the lateral surface of the gonial angle.
- v. The **endocoronoid ridge** (or **buttress**) is the vertical ridge extending inferiorly from the coronoid tip on the inner (medial) aspect of the ramus.
- w. The **mandibular foramen** enters the bone obliquely, centered in the medial surface of the ramus. The *alveolar vessels* and *inferior alveolar nerve* (a division of cranial nerve 5) enter the bone through this opening, running through the mandible via the **mandibular canal**.
- x. The **lingula** is a sharp, variably shaped projection at the edge of the mandibular foramen. It is the attachment point for the *sphenomandibular ligament*.
- y. The **mylohyoid groove** (or **sulcus**) crosses the medial surface of the ramus, running anteroinferiorly from the edge of the mandibular foramen. It lodges the *mylohyoid vessels* and *nerve*.
- z. **Pterygoid tuberosities** interrupt the medial surface of the gonial angle posteroinferior to the mylohyoid groove. They mark the insertion of the *medial pterygoideus muscle*, an elevator of the mandible.

4.21.2 Growth

The mandibular halves are separate at birth; they join during the first year at the symphysis. At birth the mandible holds unerupted deciduous teeth in crypts below the surface. The eruption of these teeth and their permanent counterparts effects dramatic changes on the mandible during ontogeny. Loss of permanent teeth results in resorption of the alveolar portion of the mandible.

4.21.3 Possible Confusion

Only small fragments of mandible can be confused with other bones. Where tooth sockets are present, the bone must be the maxilla or mandible. The former has a sinus above the molar roots.

- The mandibular corpus has a much thicker cortex than the maxilla, as well as a basal contour.
- The coronoid process might be mistaken for thin cranial bones, such as the sphenoid or zygomatic. Note, however, that the coronoid does not articulate and its edges are therefore nonsutural.

4.21.4 Siding

To side fragments of the mandible, remember that the incisors are anterior and closer to the midline than the molars, and that the ramus is posterior, with greater relief on its medial surface.

- For isolated condyles, the border of the mandibular notch is continuous with the lateral side of the condyle (most of the condyle itself lies medial to the plane of the ramus).
- For isolated coronoids, the notch is posterior, the tip superior, and the endocoronoid ridge is medial.
- For isolated gonial angles, the tuberosities for the *medial pterygoideus* are medial and are anterosuperiorly directed.

4.22 Measurements of the Skull: Craniometrics

Measurements of the skull are used for sex determination, age estimation, racial affinity, biomechanical load calculations, analyses of encephalization, and others. A huge number of potential chords, arcs, volumes, and indices can be defined, measured, and calculated on any human skull, according to the particular research or documentary goals of the metrician. A basic set of commonly used measurements taken on intact skulls was defined by Buikstra and Ubelaker (1994), and serves as a baseline and introduction to this topic. They recommend that 34 standard cranial measurements be taken on intact skulls. The “Standards” metrics of Buikstra and Ubelaker (1994) are presented below, along with adjusted descriptive terms and additional useful metrics and indices (see Section 4.5 for osteometric point abbreviations and definitions).

4.22.1 Cranial Measurements

1. Maximum cranial length: (g–op)
2. Maximum cranial breadth: (eu–eu)
3. Bizygomatic breadth (or diameter): (zy–zy)
4. Biauricular breadth: (au–au)
5. Maximum cranial height (or basion–bregma height): (ba–b)
6. Cranial base length: (ba–n)
7. Basion–prosthion length: (ba–pr)
8. Frontal chord: (n–b)
9. Parietal chord: (b–l)
10. Occipital chord: (l–o)
11. Total facial height: (gn–n)
12. Upper facial height: (pr–n)
13. Upper facial breadth: (fmt–fmt)
14. Minimum frontal breadth: (ft–ft)
15. Nasal aperture height (or nasal height): (ns–n)
16. Nasal aperture breadth (or nasal breadth): (al–al)
17. Orbital height: (greatest, perpendicular to breadth)
18. Orbital breadth: (d–ec)
19. Biorbital breadth: (ec–ec)
20. Interorbital breadth: (d–d)
21. Palate length: (ol–sta)
22. Palate breadth: (enm–enm)
23. Maxillo-alveolar breadth: (ekm–ekm)
24. Maxillo-alveolar length: (pr–ids)
25. Foramen magnum length: (ba–o)
26. Foramen magnum breadth: (greatest, perpendicular to length)
27. Mastoid length: (vertical component of au–ms)
28. Bicondylar breadth: (cdl–cdl)
29. Bigonial breadth: (go–go)
30. Mandibular length: (horizontal component of pg–go)

31. **Mandibular angle:** (angle between inferiormost two points of corpus and the posteriormost two points of ramus + condyle)
32. **Maximum ramal breadth:** (anteriormost of ramus – line connecting the posteriormost two points of ramus + condyle)
33. **Minimum ramal breadth:** (smallest, perpendicular to height)
34. **Maximum ramal height:** (cs–go)
35. **Mandibular body height:** (base–alveolar margin, at mental foramen)
36. **Mandibular body breadth:** (maximum breadth at mental foramen)
37. **Symphyseal height (or chin height):** (gn–id)

4.22.2 Cranial Indices

1. **Cranial index:** $(\text{cranial breadth} \div \text{cranial length}) \times 100$
2. **Cranial module:** $(\text{cranial length} + \text{cranial breadth} + \text{cranial height}) \div 3$
3. **Cranial length-height index:** $(\text{cranial height} \div \text{cranial length}) \times 100$
4. **Cranial breadth-height index:** $(\text{cranial height} \div \text{cranial breadth}) \times 100$
5. **Total facial index:** $(\text{total facial height} \div \text{bizygomatic breadth}) \times 100$
6. **Upper facial index:** $(\text{upper facial height} \div \text{bizygomatic breadth}) \times 100$
7. **Nasal aperture index:** $(\text{nasal aperture breadth} \div \text{nasal aperture height}) \times 100$
8. **Orbital index:** $(\text{orbital height} \div \text{orbital width}) \times 100$
9. **Palatal index:** $(\text{palate breadth} \div \text{palate length}) \times 100$

4.23 Cranial Nonmetric Traits

Whereas there are dozens of cranial nonmetric traits, Buikstra and Ubelaker (1994) consider 21 of them to be of particular importance. The 21 traits from Buikstra and Ubelaker (1994) are listed below. Note that when a trait cannot be evaluated because the anatomy is not preserved, the trait is scored as “unobservable.”

- **Persistent metopic suture:** The metopic suture will often remain patent (unfused) beyond childhood. This trait is usually scored as complete (*i.e.*, unfused), absent (fused), or partial.
- **Supraorbital notch or foramen:** The presence, number, and occlusion of supraorbital structures should be documented. For each orbit, note whether supraorbital foramina are absent, present, or multiple. Incompletely closed foramina are called notches. Note whether notches are absent, present, or multiple, and estimate whether the notch is more or less than 50% occluded with spicules.
- **Persistent infraorbital suture:** Usually scored as absent, partial, or complete.
- **Multiple infraorbital foramina:** Note whether absent (*i.e.*, has only a single foramen), internally subdivided, two distinct foramina, or more than two distinct foramina.
- **Size and number of zygomaticofacial foramina:** The standard choices for this trait are: absent, a single large foramen, one large and any number of smaller foramina, two large foramina, two large foramina and any number of smaller foramina, a single small foramen, or multiple small foramina.

- **Presence of a parietal (or obelionic) foramen:** For each side, determine whether a parietal foramen (near obelion) is present or absent on the outer table of the parietal. If present, is it located on the parietal proper, or within the sagittal suture?
- **Presence of sutural bones:** Note the presence or absence of each of these named ossicles: epipteric bone, coronal ossicle, bregmatic bone, sagittal ossicle, apical bone, lambdoid ossicle, asterionic bone, occipitomastoid ossicle, and parietal notch bone.
- **Presence of an inca bone:** Note whether an inca bone is absent, partial, or complete, as well as whether it's single, bipartite, or tripartite.
- **Patent condylar canal:** Record whether the canal is patent (open) or nonpatent.
- **Divided hypoglossal canal:** Bony extensions will sometimes completely or partially divide the hypoglossal canal. For each side, determine whether such a division exists, whether it is complete or partial, and whether the division is inside the canal or on its medial/endocranial surface.
- **Flexure of superior sagittal sulcus:** Note whether the superior sagittal sulcus turns right, turns left, or bifurcates at the internal occipital protuberance.
- **Incomplete foramen ovale:** Is the foramen ovale distinct from foramen lacerum, or do the margins of both combine into a single, irregular opening?
- **Incomplete foramen spinosum:** Is the foramen spinosum distinct from foramen lacerum, or do the margins of both combine into a single, irregular opening?
- **Pterygospinous bridge or spur:** The pterygospinous ligament (extending from the angular spine to the lateral pterygoid plate) is sometimes ossified to a greater or lesser extent. If the ossification completely bridges the gap, it is called a bridge; otherwise, it is called a spur. An example of a pterygospinous spur can be seen on the left side of the individual in Figure 4.5.
- **Pterygo-alar bridge (or bar):** The pterygo-alar ligament (extending from the lateral pterygoid plate to just medial of foramen ovale) typically ossifies into a 'bar' in lemurs and monkeys, but is only rarely so in apes and humans. If the ossification bridges the gap, it is called a bridge (or bar); otherwise, it is a spur.
- **Tympanic dehiscence:** During the first years of life, the tympanic portion of the temporal ossifies, except for an opening called the **Foramen of Huschke**, which is itself usually ossified by the age of 5. When this foramen remains patent into adulthood, it is referred to as tympanic dehiscence.
- **Auditory exostosis (or torus):** Is the external acoustic meatus occluded to any degree by a bony nodule? If so, is it $<1/3$ occluded, $1/3 - 2/3$ occluded, or $>2/3$ occluded?
- **Mastoid foramen:** For each side, is a mastoid foramen present or absent? If present, is there one, two, or more than two foramina? Note whether the foramina are located on the occipital bone, the temporal bone, and/or within the occipitomastoid suture.
- **Multiple mental foramina:** For each side, is a mental foramen present or absent? If present, is there one, two, or more than two foramina?
- **Mandibular torus:** For each side, is a distinct mandibular torus present or absent? If present, is it barely perceptible, moderate (2–5 mm projection) or marked (>5 mm projection)?
- **Mylohyoid bridge:** There may be a partial or complete bony bridge over the mylohyoid groove. If so, is it near the mandibular foramen, near the center of the groove, or both? If both, is there a gap between the two parts of the bridge, or is it continuous?

4.24 Mastication

Rather than studying bones as inert objects with strange names and processes, they are best appreciated as the living foundations of the organism. Our introduction to the skull revealed bony structures that house a variety of organs such as the brain and the eyes. Much of the anatomy of the skull is devoted to its function in chewing. Study of the masticatory system has given physical anthropologists insight into the diet of extant and extinct primates, including human ancestors. It is useful to conclude our examination of the skull with an analysis of the musculoskeletal system behind human mastication. This analysis provides an excellent reminder that the external and internal architecture of bones is strongly related to function.

Chewing takes place through the coordinated action of the musculoskeletal system of the head. Abundant evidence of the soft-tissue components of this system has been noted in the form of muscular and ligamentous attachments. Foramina and grooves for blood vessels and nerves on the mandible, zygomatics, frontal, parietals, temporals, and other bones are more evidence of soft tissues.

The masticatory system is devoted to generating forces across the opposing mandibular and maxillary teeth. There are elevators of the mandible (muscles that pull the lower jaw and its teeth up and against the maxillary teeth) and depressors of the mandible. The primary muscles that elevate the mandible during chewing (and their major attachments) are as follows: The **temporalis muscle** originates on the side of the cranial vault inferior to the superior temporal line and inserts on the sides, apex, and anterior surface of the coronoid process of the mandible. The **masseter muscle** originates on the inferior surface of the zygomatic arch and inserts on the lateral surface of the mandibular ramus and the gonial angle of the mandible. The **medial pterygoideus muscle** originates on the medial surface of the lateral pterygoid plate of the sphenoid and inserts on the medial surface of the mandibular gonial angle.

When the teeth are forcefully clenched, it is easy to palpate the active *masseter* and *temporalis muscles* on either side of the jaw and temple. The act of clenching involves stimulation of fibers in each of these muscles. This stimulation comes from nerves which can be traced back to the brain. The muscle fibers contract, and this contraction brings the bony attachment points of the muscles closer together, forcefully elevating the mandibular teeth against their maxillary counterparts. Any food between the teeth is reduced by this activity to a smaller size and then passed farther down into the digestive system. All of this coordinated, complex working of the masticatory system takes place thousands of times each day without our paying much attention to it.

Suggested Further Readings

The descriptions of cranial anatomy in this chapter, and the descriptions of postcranial anatomy in Chapters 6–13, may be supplemented by any of several osteology and anatomy texts.

Abrahams, P. H., Boon, J. M., Spratt, J. D., Hutchings, R. T., and McMinn, R. M. H. (2007) *McMinn's clinical atlas of human anatomy* (6th ed.). St. Louis, MO: Mosby/Elsevier. 386 pp. + DVD.

Excellent photographic illustrations in a large, well-organized format.

Agur, A. M. R., and Dalley, A. F. (2008) *Grant's atlas of anatomy* (12th ed.). Philadelphia, PA: Lippincott Williams & Wilkins. 834 pp.

A large-format, soft-bound atlas, excellent as a quick laboratory reference for examining the relationships between bones and soft tissues.

Bass, W. M. (2005) *Human osteology: A laboratory and field manual* (5th ed.). Columbia, MO: Missouri Archaeological Society. 365 pp.

An introductory manual emphasizing identification.

Buikstra, J. E., and Ubelaker, D. H. (Eds.) (1994) *Standards for data collection from human skeletal remains*. Fayetteville, AR: Arkansas Archaeological Survey. 206 pp.

The standard work to consult when documenting human remains.

Cartmill, M., Hylander, W., and Shafland, J. (1987) *Human structure*. Cambridge, MA: Harvard University Press. 448 pp.

A functionally and evolutionarily oriented introductory anatomy textbook.

Krogman, W. M., and İşcan, M. Y. (1986) *The human skeleton in forensic medicine* (2nd ed.). Springfield, IL: C. C. Thomas. 551 pp.

An essential source book—the descriptions and references to work on skeletal growth make good supplements to this book.

Matshes, E. W., Burbridge, B., Sher, B., Mohamed, A., and Juurlink, B. (2004) *Human osteology & skeletal radiology: An atlas and guide*. Boca Raton, FL: CRC Press. 448 pp.

An introductory text on human osteology that incorporates large numbers of plain film radiographs, CT scans, and MRI images alongside photographs of bones.

Sampson, H. W., Montgomery, J. L., and Henryson, G. L. (1991) *Atlas of the human skull*. College Station, TX: Texas A&M University Press. 200 pp.

A black-and-white photographic atlas picturing all the bones of the skull. The photographs are presented in different scales depending on the size of the bone pictured.

Schaefer, M., Black, S., and Scheuer, L. (2009) *Juvenile osteology: A laboratory and field manual*. San Diego, CA: Academic Press. 384 pp.

A handy spiral-bound guide to immature human osteology. Includes a series of forms useful for the inventory and age determination of immature remains.

Standring, S. S. (2008) *Gray's anatomy: The anatomical basis of clinical practice* (40th ed.). New York, NY: Churchill Livingstone. 1576 pp.

This continually updated classic is the most complete single reference available in the field of human anatomy.

Steele, D. G., and Bramblett, C. A. (1988) *The anatomy and biology of the human skeleton*. College Station, TX: Texas A&M University Press. 291 pp.

An atlas dedicated to the identification and biology of the human skeleton.

Chapter 5

TEETH

THE UPPER AND LOWER JAWS are dermal bones with a fascinating evolutionary history. Teeth in the upper and lower jaws appear to have evolved from fish scales. The living core of a mammalian tooth is a dense bone-like material called **dentin**, or **dentine**, a special type of calcified but slightly resilient connective tissue that extends into a socket in the jaw. The crown of the tooth is covered with a layer of extremely hard, brittle material known as **enamel**. These basic tissues have been molded by evolution into an impressive variety of shapes and sizes among the vertebrates.

Teeth are some of the most important parts of human anatomy for the osteologist. Teeth owe their importance in paleontology and anthropology to a variety of factors. Of all the skeletal elements, teeth are the most resistant to chemical and physical destruction. They are, therefore, overrepresented relative to other parts of the skeleton in almost all archaeological and paleontological assemblages. In addition to being abundant, teeth constitute a focus of anthropological and paleontological interest because they are so informative about the individual who possessed them. Teeth provide information on the age, sex, health, diet, and evolutionary relationships of extant and extinct mammals, hominids included.

Teeth are formed deep within the jaws and then erupt through the gum tissue once nearly complete. Unlike the changing shapes of other skeletal elements, tooth crown morphology can only be altered by **attrition** (tooth wear), breakage, cultural modification (*eg*, tooth filing), or demineralization once the crown erupts. Tooth morphology can be used to effectively differentiate between populations within a species, species within a genus, and so forth. The stability and adaptive significance of dental form establish teeth as a centerpiece in many comparative populational and evolutionary studies. Finally, teeth are the only hard tissues of the body that are directly observable without dissection or radiography.

Dental measurement and terminology are discussed in Chapter 2. Dental pathology is reviewed in Chapter 19. The use of teeth in sexing and aging is discussed in Chapter 18. The use of dental traits in estimating population distance is covered in Chapter 21. The principles of identification discussed in this chapter form the foundation upon which all other aspects of dental studies are based.

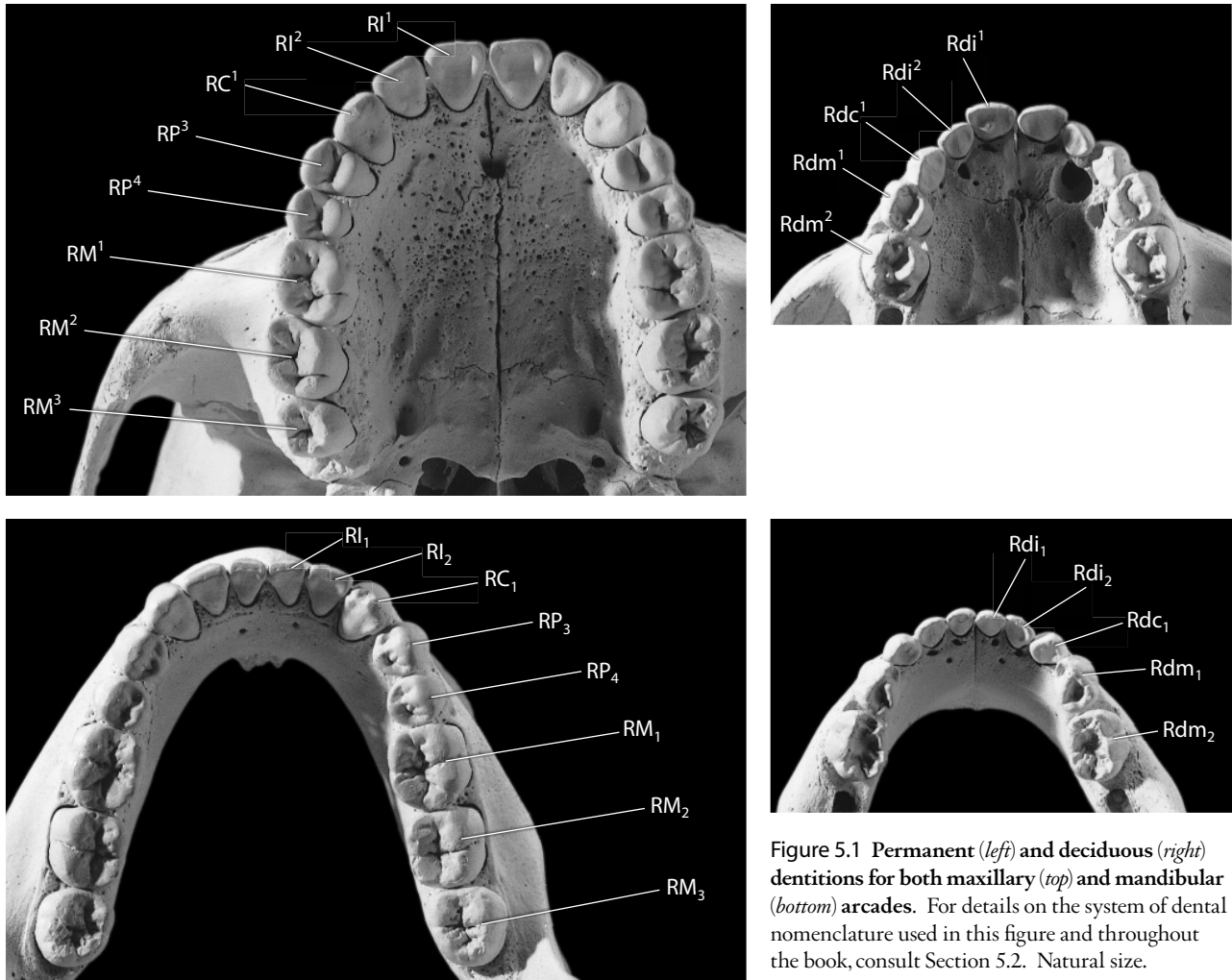


Figure 5.1 Permanent (*left*) and deciduous (*right*) dentitions for both maxillary (*top*) and mandibular (*bottom*) arcades. For details on the system of dental nomenclature used in this figure and throughout the book, consult Section 5.2. Natural size.

5.1 Dental Form and Function

Teeth constitute the only part of the skeleton that interacts directly with the environment, serving to seize and **masticate** (chew) food. Both the internal composition and the external morphology of teeth are adapted to this primary function in considerable detail among mammals. The particular functions played by specific tooth categories in mammals vary by taxa, but in general, incisors serve primarily to nip or bite food into manageable pieces, canines serve to grasp and capture prey, and premolars and molars serve to chop or crush these pieces further before swallowing.

In adult hominids (Figure 5.1), **incisors** are the eight spatulate teeth in the front of the upper and lower jaws (four in each jaw, two on the right and two on the left). Unworn incisors display sharp, thin cutting edges. Modern human canines function primarily as posterior extensions of the incisor rows, but they retain a more conical shape than the incisors. Human **premolars** are termed “bicuspid” by dentists. In humans there are four premolars in the upper jaw and four in the lower jaw. **Molars** make up the remainder of the human tooth row. Molars are the largest teeth; their extensive chewing surfaces emphasize crushing and grinding rather than biting and shearing. There are usually six molars in both upper and lower adult human jaws.

Humans have retained the primitive mammalian pattern of having two successive sets of teeth. The **deciduous** (**primary** or '**milk**') dentition is the first set of teeth to form, erupt, and function in the first years of life. These teeth are systematically shed and replaced by their counterparts in the **permanent** (**secondary**) dentition throughout childhood and adolescence.

5.2 Dental Terminology

Section 2.2.2 identifies some directional terms specific to teeth. Because work on dental anatomy makes extensive use of these terms, a brief review is essential here. In dental anatomy, the **mesial** portion of the tooth is closest to the point where the central incisors contact each other, and **distal** is the opposite of mesial (Figure 5.3). The **lingual** part of the tooth crown is toward the tongue. **Labial** is the opposite of lingual but is usually reserved for the incisors and canines. **Buccal** is also the opposite of lingual but is usually reserved for the premolars and molars, where the term refers to that part of the tooth that lies toward the cheeks. **Interproximal** tooth surfaces contact adjacent teeth, and the chewing surface of the tooth is the **occlusal surface**. The tooth roots are suspended in **sockets** (**alveoli**) in the mandible and maxillae by periodontal ligaments.

To fully identify a tooth, five variables must be specifically reported: category of tooth, permanent or deciduous dentition, upper or lower arcade, position within the tooth category series, and side.

- a. Tooth **category** indicates whether the tooth is an incisor, canine, premolar, or molar. Study of the teeth is considerably simplified through the use of a conventional shorthand that unambiguously identifies each tooth. In this shorthand, **I** indicates an incisor, **C** indicates a canine, **P** indicates a premolar, and **M** indicates a molar.
- b. **Dentition** indicates to which of the two successive sets of teeth the tooth belongs: the deciduous dentition or the permanent dentition. When **I**, **C**, **P**, or **M** are capitalized, the tooth is understood to be from the permanent dentition. When **i**, **c**, or **m** are shown in lowercase and preceded by the letter **d**, they denote deciduous incisors, canines, and molars. Because the deciduous molars are replaced by permanent premolars, paleontologists usually refer to these teeth as deciduous premolars. Thus the paleontological abbreviation **dp** is the equivalent of the anthropological **dm**.
- c. The **positions** of all teeth are indicated by numbers, indicating the relative position that the tooth holds among teeth of the same category in the tooth row. The numeric positions for each category of tooth increase distally, beginning at 1, the number assigned to the tooth in the mesialmost position. To make comparisons of homologous teeth easier between mammalian species, scientists have traditionally numbered each position according to its location in the primitive mammalian tooth row. Primitive mammals had 3 incisors, 1 canine, 4 premolars, and 3 molars in both arcades (abbreviated with the **dental formula** $\frac{3:1:4:3}{3:1:4:3}$). Through the course of evolution, humans (as well as apes and Old World monkeys) have lost the primitive third incisor and the first two primitive premolars (our dental formula is $\frac{2:1:2:3}{2:1:2:3}$). Thus human incisors are numbered either **1** or **2** (for central or lateral incisors, respectively). Human canines are all **1s**. Because humans have lost the first two primitive premolars, human premolars are referred to as **3s** and **4s** (or **1s** or **2s** for the nonpaleontologically inclined), and molars can be **1s**, **2s**, or **3s**.
- d. The **arcade** (or **arch**) from which a tooth originates specifies whether the tooth developed in the maxilla or in the mandible. The shorthand convention for indicating arch is to write the position numeral as superscript (e.g., M^3) for maxillary (or upper) teeth, and to write the position numeral in subscript (e.g., M_2) if the tooth is a mandibular (or lower) tooth. To avoid confusion in handwritten designations, draw a line above or below the numeral to indicate the intended position of the number.
- e. Finally, the **side** from which the tooth originates — whether right or left — is designated by either **R** or **L**, respectively.

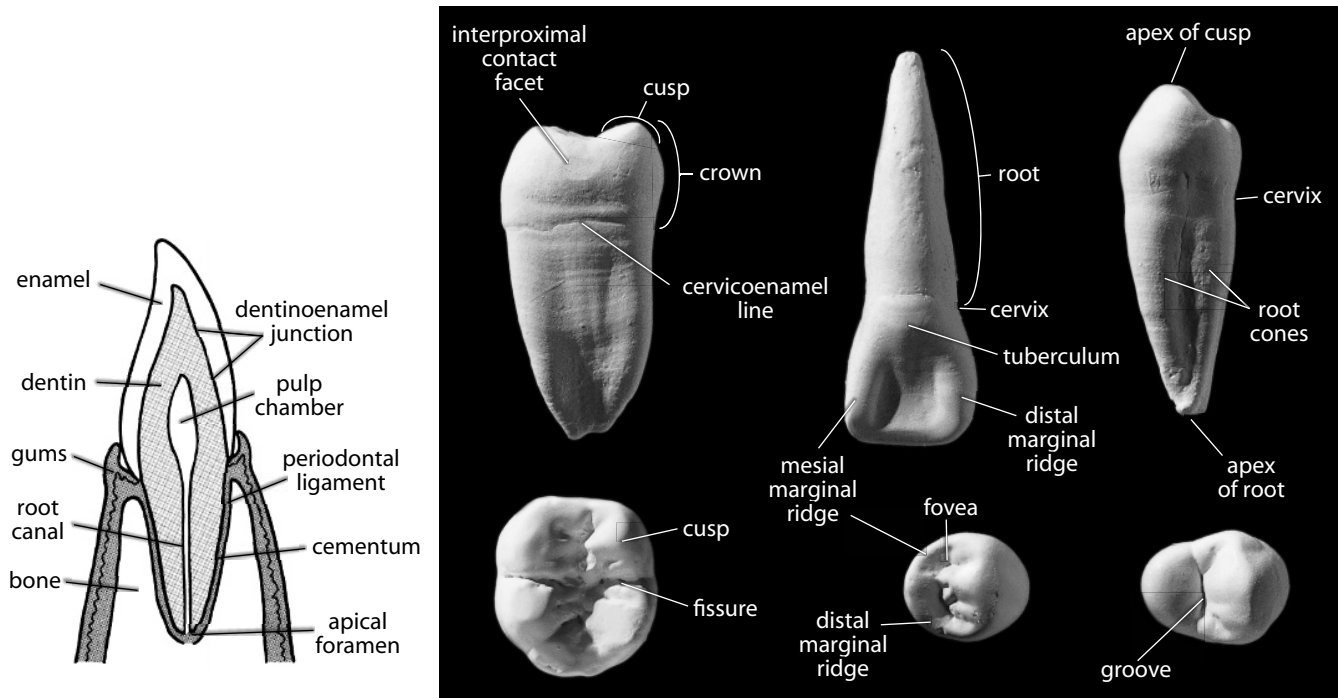


Figure 5.2 Dental anatomy. *Left:* sectioned tooth showing internal structure. *Right: top row, from left:* right lower second molar, mesial view; right upper central incisor, lingual view; right lower third premolar, mesial view. *Right: bottom row, from left:* left lower first molar, occlusal view; right lower fourth premolar, occlusal view; left upper third premolar, occlusal view. Shown twice natural size.

Using these conventions, the left deciduous second mandibular incisor is designated Ld_i_2 , whereas the right permanent first maxillary molar is designated RM^1 . Because there is only one canine per arcade-side, some practitioners use an alternative system of nomenclature for the canines — a bar representing the occlusal plane is used to indicate position; thus \bar{C} and \underline{C} are more often used as synonyms than C_1 and C^1 .

5.3 Anatomy of a Tooth

Figure 5.2 shows the various elements of a human tooth. There are some features so commonly found in teeth of all kinds that they are worth listing separately.

- a. The **crown** is the part of the tooth covered by enamel.
- b. The **root** is the part of the tooth that anchors the tooth in the alveolus of the mandible or maxilla. **Primary roots** are comprised of one or more **root cones** which may be completely fused (often discernible by shallow developmental grooves) or partially or completely bifurcated to become separate (secondary) roots.
- c. **Enamel**, the specialized hard tissue that covers the crown, is both avascular and acellular. It is about 97% mineralized, essentially fossilized once it is formed.
- d. **Cementum** is a bone-like tissue that covers the external surface of tooth roots.
- e. **Dentin** (or **dentine**) is the tissue that forms the core of the tooth. This tissue has no vascular supply but is supported by the vascular system in the pulp and is lined on the inner surface (the walls of the pulp cavity) by odontoblasts, dentin-producing cells. These

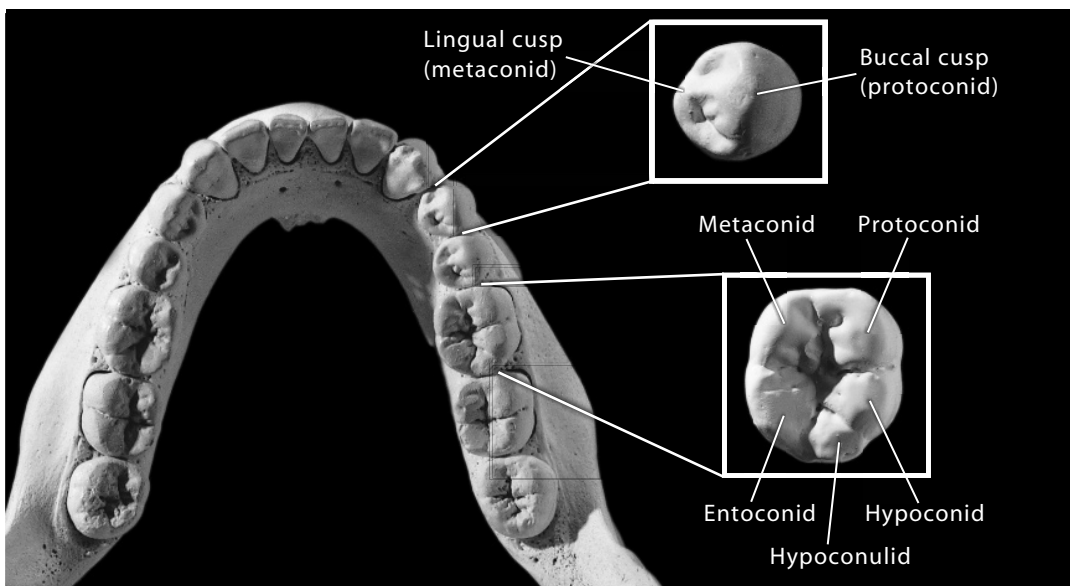
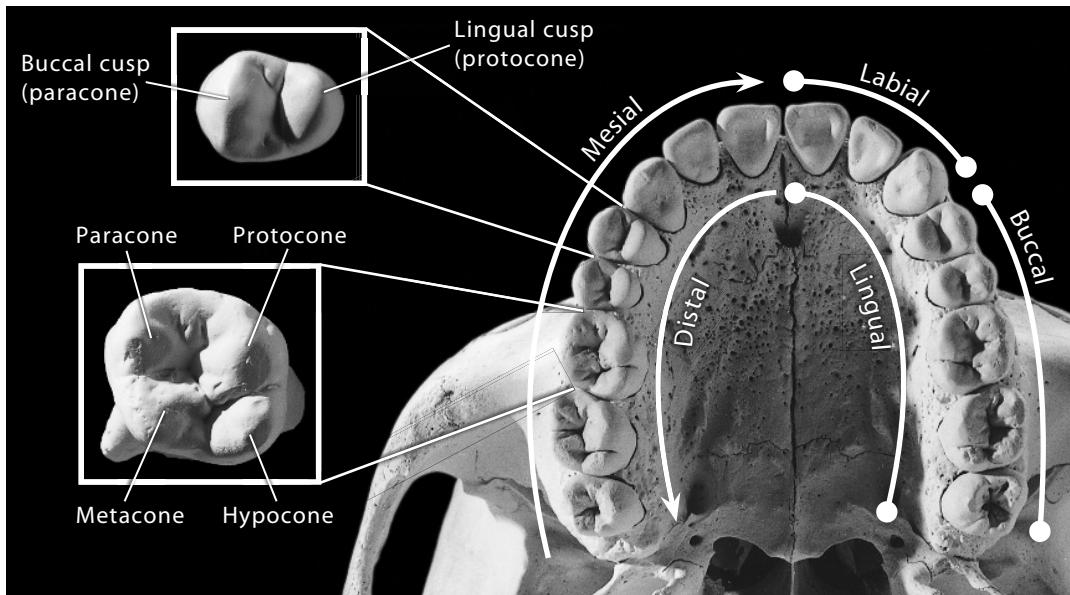


Figure 5.3 Directional terms for teeth and major cusp names for teeth. Arcades shown natural size; inset third premolars and first molars shown twice natural size.

cells have the same relationship to dentin that osteoblasts have to bone. Dentin underlies the enamel of the crown and encapsulates the pulp cavity, the central soft tissue space within a tooth. Occlusal wear may expose dentin, and because dentin is softer than enamel, the resulting exposures are usually occlusally concave.

- f. The **cervix** (or **neck**) is the constricted part of the tooth at the junction of the crown and root.
- g. The **cementoenamel** (or **cervicoenamel**) **line** (or **junction**) (**CEJ**) is the line encircling the crown at the cervix, marking the most rootward extent of the enamel.
- h. The **dentinoenamel junction** (**DEJ** or **EDJ**) is the boundary between the enamel cap and the underlying dentin.

- i. The **pulp chamber** is the expanded part of the pulp cavity at the crown end of the tooth.
- j. The **root canal** is the narrow end of the pulp cavity at the root end of the tooth.
- k. **Calculus** is a calcified deposit commonly found on the sides of tooth crowns. The origins of calculus lie with plaque, colonies of microorganisms that establish themselves on the teeth.
- l. The **pulp** is the soft tissue within the pulp chamber. This includes nerves and blood vessels.
- m. The **apical foramen** is the opening at each root tip, or **apex**, through which nerve fibers and vessels pass from the alveolar region to the pulp cavity.
- n. A **cusps** is an occlusal projection of the crown. Major cusps on molars are named individually (Figure 5.3). Knowledge of relative cusp position, size, and wear is often valuable in identifying isolated teeth. Cusps of the upper teeth end with the suffix **-cone**, whereas cusps on the lower teeth end with the suffix **-conid**. The tip of a cusp is the **apex**.
 The **protocone** is the mesiolingual cusp on an upper molar. Cusplets, grooves, or other topographic features on its mesiolingual surface are called **Carabelli's effects**.
 The **hypocone** is the distolingual cusp on an upper molar.
 The **paracone** is the mesiobuccal cusp on an upper molar.
 The **metacone** is the distobuccal cusp on an upper molar.
 The **protoconid** is the mesiobuccal cusp on a lower molar. Cusplets, grooves, or other forms on the mesiobuccal surface of the protoconid are called **protostylid effects**.
 The **hypoconid** is the distobuccal cusp on a lower molar.
 The **metaconid** is the mesiolingual cusp on a lower molar.
 The **entoconid** is the distolingual cusp on a lower molar.
 The **hypoconulid** is the fifth, distalmost cusp on a lower molar.
 Cusplets on the incisal edges of unworn incisors are called **mamelons**.
- o. A **crest** is a large elevated feature originating from a cusp. A **ridge** is a smaller, less-defined version of a crest.
- p. A **cingulum** is a ridge of enamel that partly or completely encircles the sides of a tooth crown. While reduced or absent on human molars and premolars, it figures prominently in the crown morphology of incisors, canines, and deciduous molars.
- q. A **tuberculum** is a bulge, derived from the cingulum, found on the lingual surface of incisors and canines near the cervical margin.
- r. A **fissure** is a cleft on the occlusal surface between cusps. Fissures divide the cusps into patterns. The most widely acknowledged of these is the **Y-5 pattern**, a pattern in which the five lower molar cusps are arranged such that the metaconid and hypoconid contact each other across a short fissure.
- s. A **groove** is a large, linear, trough-like fissure between cusps.
- t. A **fovea** is a small, defined, often circular depression on a crown.
- u. The primitive mammalian (**tribosphenic**) cusp pattern was a triad of cusps in both upper and lower molars. From this pattern, a remarkable variety of forms has arisen through evolution, ranging from the tall columnar molars of warthogs to the blade-like molars of some carnivores. In humans, as in most other primates, the mesial (anterior) part of the molar is referred to as the **trigon** (**trigonid** in lower molars). The distal (posterior) part of the primate molar, added onto the modified original triangle of cusps, is called the **talon** (or **talonid** in lower molars).
- v. **Interproximal contact facets (IPCFs)** are facets formed between adjacent teeth in the same jaw; **occlusal contact facets** result from contact of mandibular and maxillary teeth during chewing.

In addition to these anatomical parts of teeth, a few additional terms used to describe and interpret teeth are also useful. **Supernumerary** teeth are extra teeth that exceed the expected number of teeth in any given tooth category. For example, supernumerary molars (fourth molars) are very rare in humans but more common in apes. **Agensis** is the lack of tooth formation at a given position. **Hypoplasia** (hypomineralization) is a disturbance of enamel formation that often manifests itself in transverse lines, pits, or other irregularities on the enamel surface. **Hypercementosis** is a condition in which an excess of cementum forms on the root. **Taurodontism** refers to the condition in which the pulp chamber is expanded relative to the normal condition. **Caries** is a disease process resulting in the demineralization of dental tissues. **Shovel-shaped** incisors have strongly developed mesial and distal lingual marginal ridges, imparting a “shovel” appearance to the tooth. Several of these features are given further consideration in Chapters 19 and 21, where the uses of teeth in paleopathology and the study of populational affiliation are discussed.

5.4 Dental Development

Even before birth, germs of the deciduous teeth have formed within the jaws. When formation of each deciduous and permanent crown is complete and some root formation has occurred, it is erupted. When developing within the jaw, the **tooth buds**, or **germs**, reside in hollows in the alveolar bone called crypts. Within the crypt, calcification of the enamel cap of a tooth crown begins at the cuspal apices and proceeds **rootward**. Crown formation, including enamel calcification, is completed before eruption and before the roots are completely formed. The last parts of a tooth to develop, after eruption, are the root apices. Before replacements by their adult counterparts, the roots of the deciduous teeth are **resorbed** (eaten away by osteoclasts) prior to the shedding of each tooth. In Chapter 18 we describe the timing of these processes and discuss their use in aging subadult human dentitions.

Enamel is formed by cells called **ameloblasts** through a process known as **amelogenesis**. Unlike bone, dental tissues are usually not remodeled during life. Once formation of the enamel is complete, only changes through physical (wear) or chemical (decay) processes are possible. Dentin is formed by cells called **odontoblasts** through a process known as **dentinogenesis**. Primary dentin is laid down during tooth formation and secondary dentin is laid down during the stage of root maturation.

The processes of tooth genesis are similar in all mammals. The striking differences between mammalian tooth shape, size, and structure come as a result of the differing activity of the two cell types (ameloblasts and odontoblasts), and this activity is in turn regulated by the DNA. Thus, because of the stability of post-eruptive form, teeth have a better possibility of more directly reflecting the genes than other parts of the skeleton. For these reasons, teeth are widely used in the assessment of biological distance between human populations (Chapter 21). Insults to the organism during the developmental span of any tooth, however, can directly affect the morphology of the tooth. An example of this is the phenomenon of **enamel hypoplasia** (discussed in Chapter 19).

Once erupted, teeth begin to wear away as they are used in mastication. Wear is usually most pronounced on the lingual occlusal surfaces of maxillary premolars and molars and on the buccal occlusal surfaces of mandibular premolars and molars. For anterior teeth, the wear pattern is more variable because these teeth are often used in **paramasticatory** functions (those besides simple biting and chewing; for instance, clamping a smoking pipe between the cheek teeth, or using the biting ability of the anterior dentition to serve as a kind of ‘third hand’ in processing animal hides). In general, occlusal wear is lingually biased on uppers, and labially biased on lower anterior teeth. Conditions of overbite, underbite, and edge-to-edge occlusion are some of the variants seen in humans.

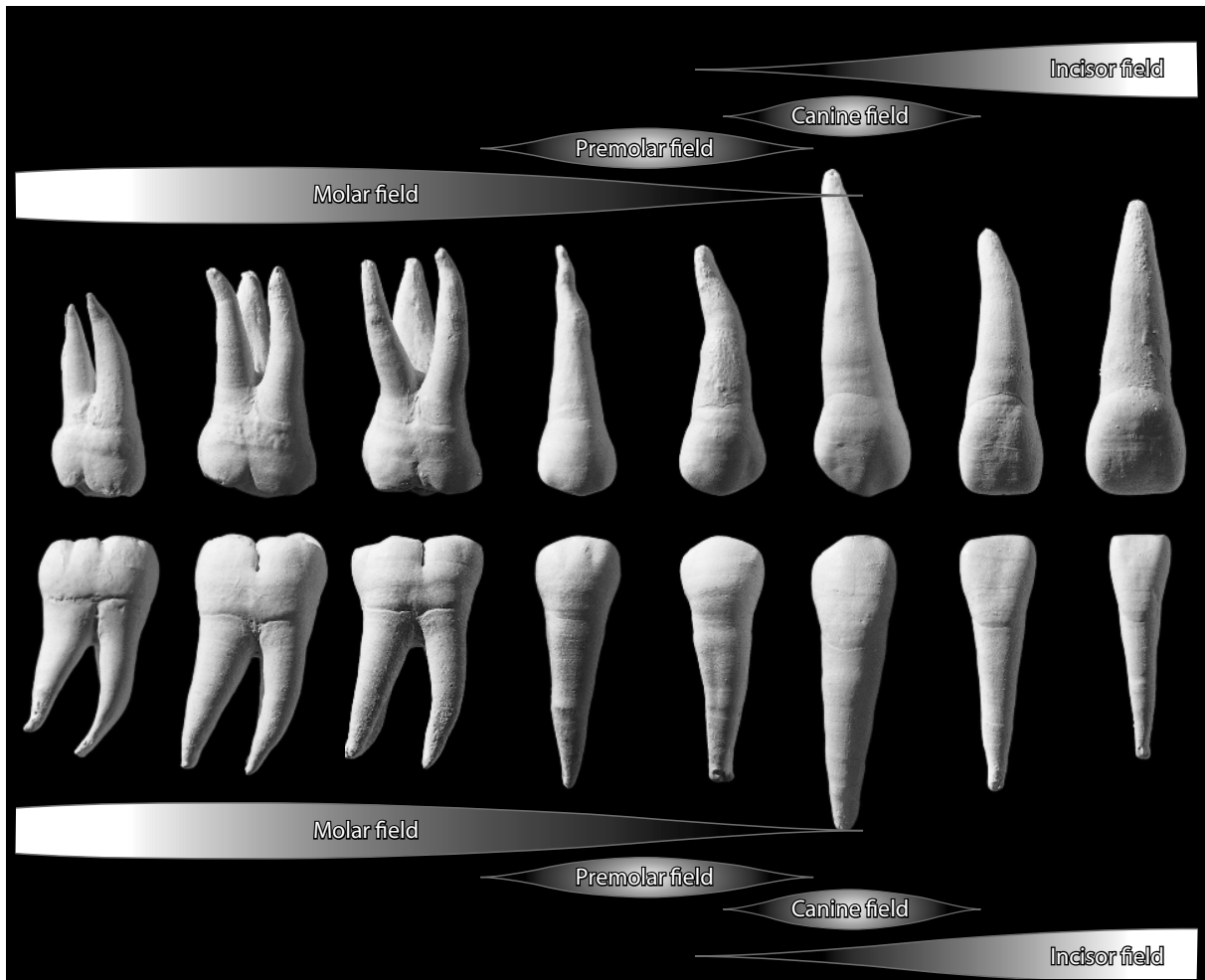


Figure 5.4 A heuristic diagram illustrating the relative location and interplay of the dental morphogenic fields in humans. With only minor modifications and name changes, this diagram could also represent the general effect of either the clone model or the homeobox code hypothesis of dental form. Teeth are shown at approximately 1.5 times normal size.

5.4.1 Dental Pattern Formation

How do the clumps of cells—first branchial arch ectoderm and neural crest ectomesenchyme—at the distal end of the dental arcade develop into molars, while the clumps of cells at the mesial end become incisors? Why do teeth at the boundary zone between two tooth categories tend to resemble each other more than those located further away from the boundary zone? These questions have been asked and debated for over 70 years, but the answers are still uncertain.

There are three primary hypotheses that account for dental patterning and differentiation: the **dental morphogenic field theory**, the **dental clone theory**, and the **odontogenic homeobox code hypothesis**.

In 1939, Butler proposed that the teeth forms in the fossil Cenozoic mammals he was studying were determined by their location relative to three dental morphogenic fields: incisor, canine, and molar. In 1945, Dahlberg applied Butler's dental morphogenic field concept to the human permanent dentition, and added a fourth dental field to account for premolar shape. Recently,

Hlusko and Mahaney (2009) tested Butler's hypothesis and found general support for the morphogenic field hypothesis, and also found evidence of some genetic distinction between molars and premolars. According to the morphogenic field model, each tooth primordium starts out as pluripotent (capable of differentiating into any of several ultimate forms), and the final form the tooth takes is influenced by its specific history of exposure to morphogens during growth. An M1 primordium exposed to the concentrated morphogens of a young molar field will end up looking more 'molar-like' than an M3 primordium exposed to the decreased concentration of morphogens of an aging field.

While the morphogenic field model holds that final tooth shape is the product of ectomesenchymal cells acquiring positional information from branchial arch ectoderm, the dental clone model holds that all the information necessary for the formation of tooth shape is contained in the ectomesenchymal cells themselves. According to the clone model, all teeth (both permanent and deciduous) of a given category of tooth originate as clones from a single progenitor (per arcade, per side). In this model, the first clones produced by a progenitor produce the most prototypical teeth, while later clones have increasingly reduced potency and, therefore, less fidelity to the prototypical ideal.

A last hypothesis, the odontogenic homeobox code hypothesis (Thomas and Sharpe, 1998; Sharpe, 2003; Cobourne and Sharpe, 2010), contends that signalling molecules within the oral epithelium exert time-dependent influence upon the ectomesenchymal cells by establishing specific homeodomains (domains of homeobox gene expression). Thus, for every tooth-producing region of the mandible and maxilla, there is a specific combination of homeobox genes within the oral epithelium that determine the ultimate morphology of the teeth that develop in those regions.

It is important to note that the odontogenic homeobox code hypothesis is based on studies of gene expression and gene knock-out studies of mice, while the former two hypotheses are based on phenotypic data and have no basis in genetics whatsoever. In any case, these hypotheses are not necessarily competing or mutually exclusive. For the purposes of this chapter, the most important lessons to be garnered are these:

- The ultimate morphology of a tooth results from a complex interaction of location, timing, and genetic regulation.
- Teeth of the same category are influenced by many of the same genes, and there is some genetic distinction between different categories of teeth.
- Teeth at the boundaries between tooth categories tend to look more like the adjacent tooth category than teeth located further from the boundary.

5.5 Tooth Identification

Because teeth are often found separated from the jaws that originally held them, because they are relatively abundant, and because of their importance in osteological work in forensics, archaeology, and paleontology, it is important to be able to identify isolated teeth fully and accurately. A full and exact identification of each of the 20 deciduous and 32 permanent human teeth seems like a formidable task, but with a little organization and an appropriate analytical framework, the job can be considerably simplified.

Mammalian teeth reflect millions of years of evolution. As a general rule, the variation between different tooth categories has been reduced in humans (becoming "homogenized"), whereas morphological variation at each tooth position has tended to increase. Thus, compared to the teeth of even our closest relatives the apes, human teeth are more difficult to identify. For those interested in the range of variation commonly encountered in human teeth, we recommend Taylor (1978) and Scheid (2007).

In both apes and humans, it is easy to distinguish between the anterior teeth (incisors and canines) and the posterior teeth (molars). With only slightly more difficulty, you can determine whether teeth are incisors, canines, premolars, or molars. Most problems of identification come in distinguishing left from right, maxillary teeth from mandibular teeth, deciduous teeth from permanent teeth, and recognizing the different tooth positions. A few hints and an organizational structure greatly facilitate the study and recognition of individual teeth.

The steps toward identification of isolated teeth are outlined here in a logical order. It should prove possible to identify virtually all unworn and most worn human teeth by following this order. When using the identification criteria presented in this chapter, always keep variation in mind. Note the degree of wear on any tooth you examine; many of the identification criteria rely on the tooth being human, with minimal wear. When identifying a worn tooth, attempt to mentally reconstruct the original, unworn crown morphology and overall proportions. Only through experience with a range of human teeth will the researcher become familiar with the normal, expected variation within the human species. Thus, when it is not initially obvious whether the tooth is human, working through the steps in detail may make it possible to identify and eliminate nonhuman teeth. Worn bear and pig teeth may resemble human teeth superficially, but moderate experience with modest samples of worn and unworn human teeth will almost always be adequate to allow an accurate diagnosis.

While many shortcuts to identification are available, remember that there is no single, magic criterion that will always successfully distinguish one tooth from all others. Shortcuts will give you a good idea of the direction you should follow in your analysis, but you should always use multiple criteria for each identification, checking each one independently and making your decision based on the preponderance of the evidence whenever there is conflict. The criteria to check include the overall crown **profile** (shape) from different views; the number, location, and size of cusps, fissures, foveae, and other crown morphology; the number, location, and orientation of roots; the presence, placement, and shape of interproximal contact facets; and the location and orientation of occlusal contact facets.

Many of the criteria presented here for identifying modern human teeth are relative, and hence dependent on comparing one observation, index, or size against another. Thus, some of the comparative criteria may be difficult to evaluate at first, but they will quickly become easier as you examine more and more teeth. Remember that every student of osteology conveniently carries around a full or partial comparative adult dentition within the mouth at all times. For identifications of category, arcade, position, and side, the osteologist may find it useful to imagine properly placing the unidentified tooth into his or her own dentition. Whether identifying isolated teeth or just fragments of teeth, it is often helpful to proceed in the order of the questions presented below. An alternative “Key” approach to tooth identification is presented in Appendix 2.

Except where otherwise stated, all images of teeth in this chapter are reproduced at twice natural size. Root orientation in mesial, buccal, labial, and lingual views is anatomical (maxillary roots point up, toward the top of the page). Occlusal views are shown with the mesial crown edge toward the top of the page. Note that the enamel of the illustrated teeth does not appear shiny. Enamel is normally translucent and shiny, but these characteristics combine to obscure crown topography in photographs. To solve this problem, we coated the teeth illustrated here with an opaque, thin pigment prior to photography (Appendix 1).

5.6 To Which Category Does the Tooth Belong? (Figure 5.5)

5.6.1 Incisors

- Incisor crowns are flat and blade-like.
- The outline of the occlusal dentine patch of the incisor exposed by wear is rectangular or square.

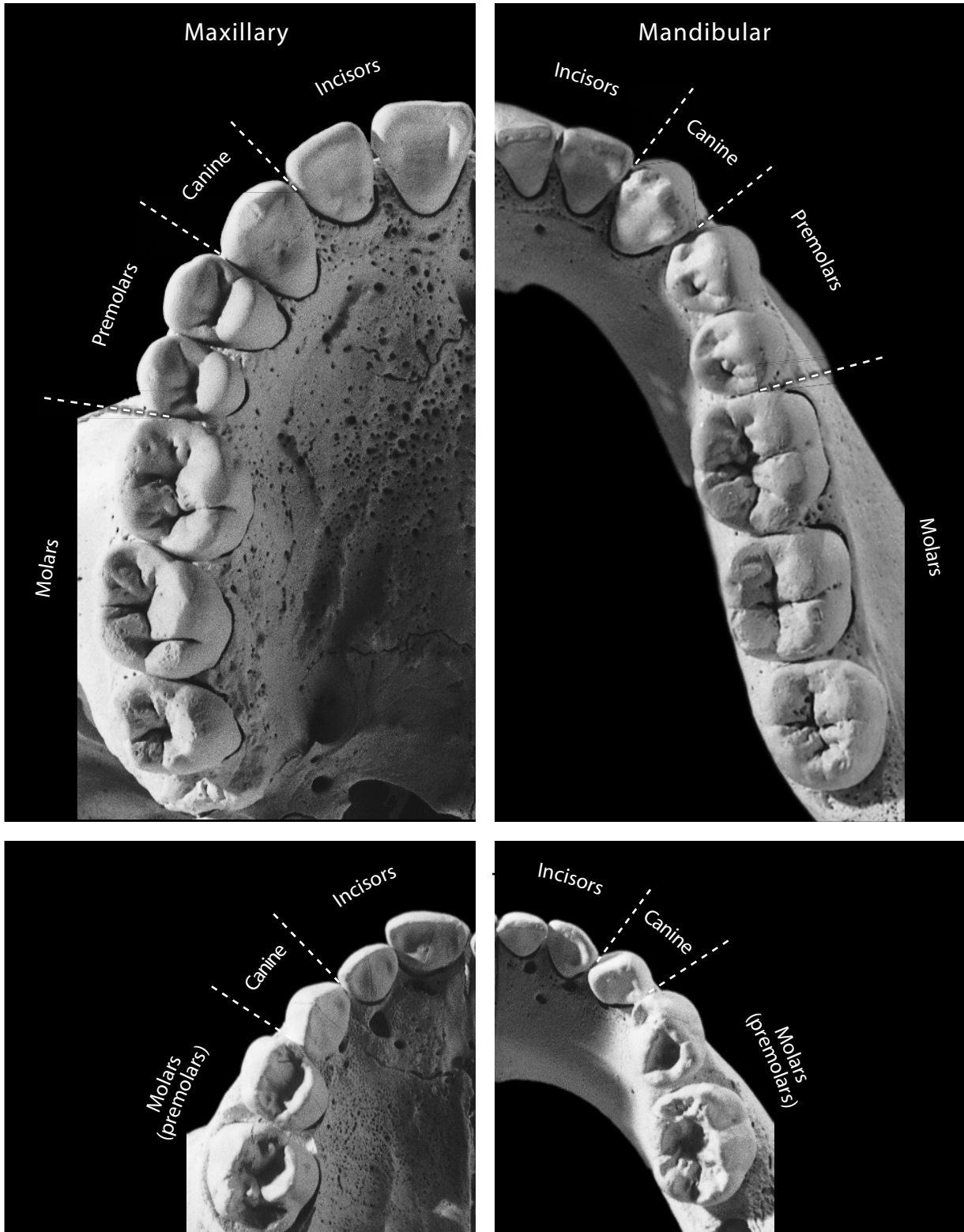


Figure 5.5 A comparison of maxillary and mandibular right half arcades for permanent (*top*) and deciduous (*bottom*) dentitions. Occlusal, right side, twice natural size.

5.6.2 Canines

- Canine crowns are conical and tusklike.
- The outline of the occlusal dentine patch of the canine exposed by wear is diamond shaped.
- Canine roots are longer than other roots in the same dentition.
- Some canines may be confused for incisors. Note, however, the longer, larger canine root relative to crown height and the oval canine crown cross section.

5.6.3 Premolars

- Premolar crowns are round, shorter than canine crowns, and smaller than molar crowns. They usually have two cusps.
- Premolars are usually single rooted.
- Some lower third premolars may be mistaken for canines. Note, however, the smaller crown height and shorter root of the premolar.

5.6.4 Molars

- Molar crowns are larger, squarer, and bear more cusps than other teeth.
- Molars usually have multiple roots.
- Reduced third molars are sometimes mistaken for premolars. To avoid this, note the relationship of root length to crown height, the round or oval outline of the premolars in occlusal aspect, and the comparatively regular cusp pattern on the premolar crowns.

5.7 Is the Tooth Permanent or Deciduous? (Figure 5.6)

5.7.1 Diagnostic Criteria

- To identify deciduous teeth, adult criteria outlined both above and below are applicable (except where indicated in Special Cases, section 5.7.2, below).
- Deciduous crowns have enamel that is thinner relative to crown size.
- Deciduous tooth crowns are more bulbous in shape, with the enamel along the crown walls often bulging out above the enamel line more prominently than in permanent teeth.
- Deciduous tooth roots are thinner and shorter. The deciduous molar roots are more divergent.
- Deciduous tooth roots are often partly resorbed, particularly below the crown center of deciduous molars.

5.7.2 Special Cases

- Deciduous first upper and lower molar crowns have peculiar shapes. The upper is triangular in outline, with a strongly projecting buccal paracone surface. The lower has a low talonid and an extensive buccal protoconid surface.
- Deciduous upper canines differ from adult upper canines in that the mesial occlusal edge is generally longer than the distal occlusal edge.

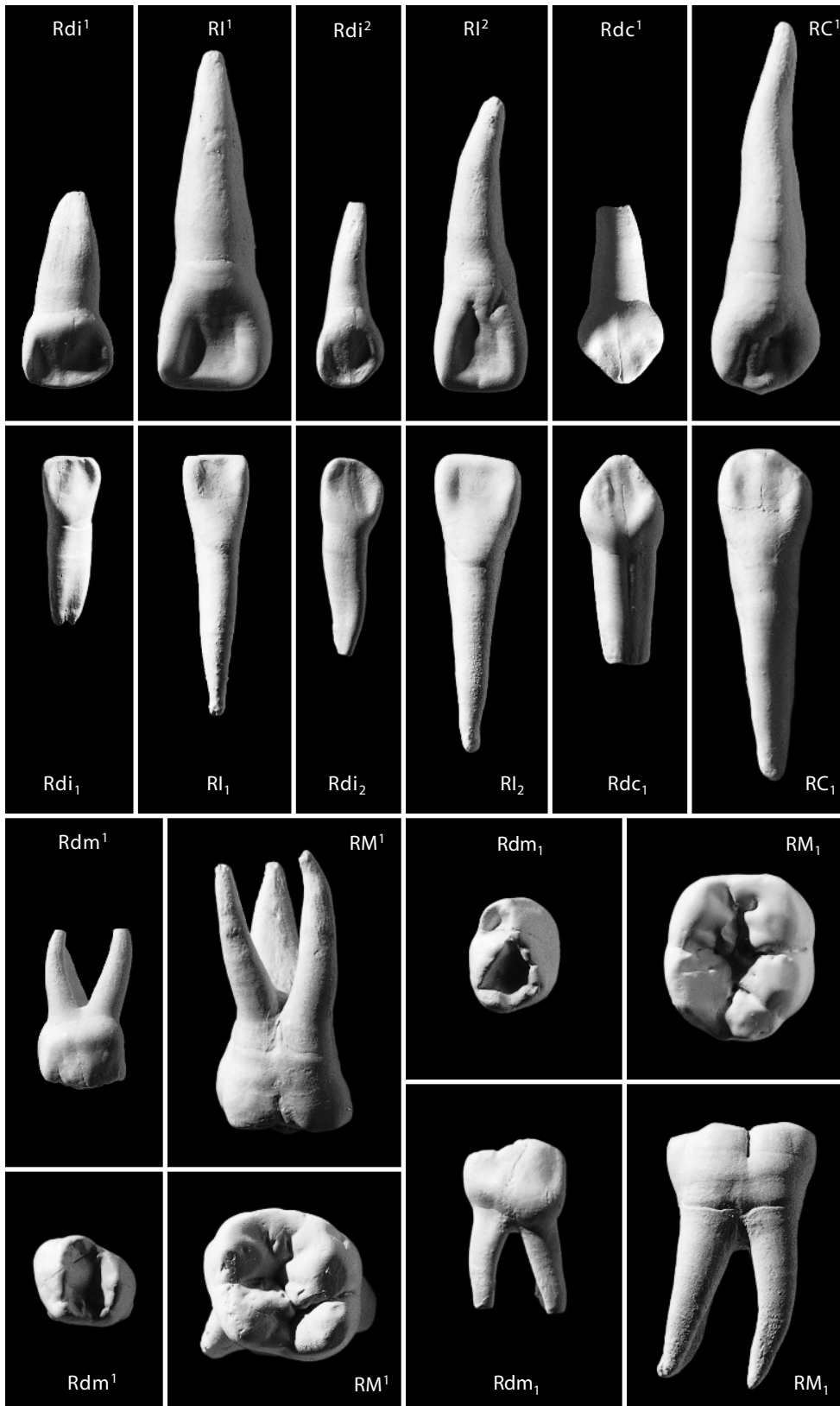


Figure 5.6 Deciduous and permanent teeth compared. Incisors and canines in lingual view; molars in buccal and occlusal views. Right side, twice natural size.

5.8 Is the Tooth an Upper or a Lower?

To identify deciduous teeth, adult criteria outlined both above and below are applicable.

For incisors and canines, view the crown lingually. Gauge the maximum mesiodistal length and maximum crown height (correcting the latter for wear if necessary). When the height dimension is twice the length (*i.e.*, tall narrow crowns), the tooth is probably a lower.

For molars, determine the mesiodistal crown axis by observing the placement of the protocone or protoconid (mesial and lingual, and mesial and buccal, respectively; the largest and most heavily worn cusp) and the disposition of the interproximal contact facets (IPCFs), which must be mesial and distal.

5.8.1 Upper versus Lower Incisors (Figure 5.7)

- Upper incisor crowns are broad (mesiodistally elongate) relative to their height. Lower incisor crowns are narrow compared to their height.
- Upper incisor crowns have much lingual relief. Lower incisor crowns have comparatively little lingual topography.
- Upper incisor roots are usually more circular in cross section. Lower incisor roots are usually more mesiodistally compressed in cross section.

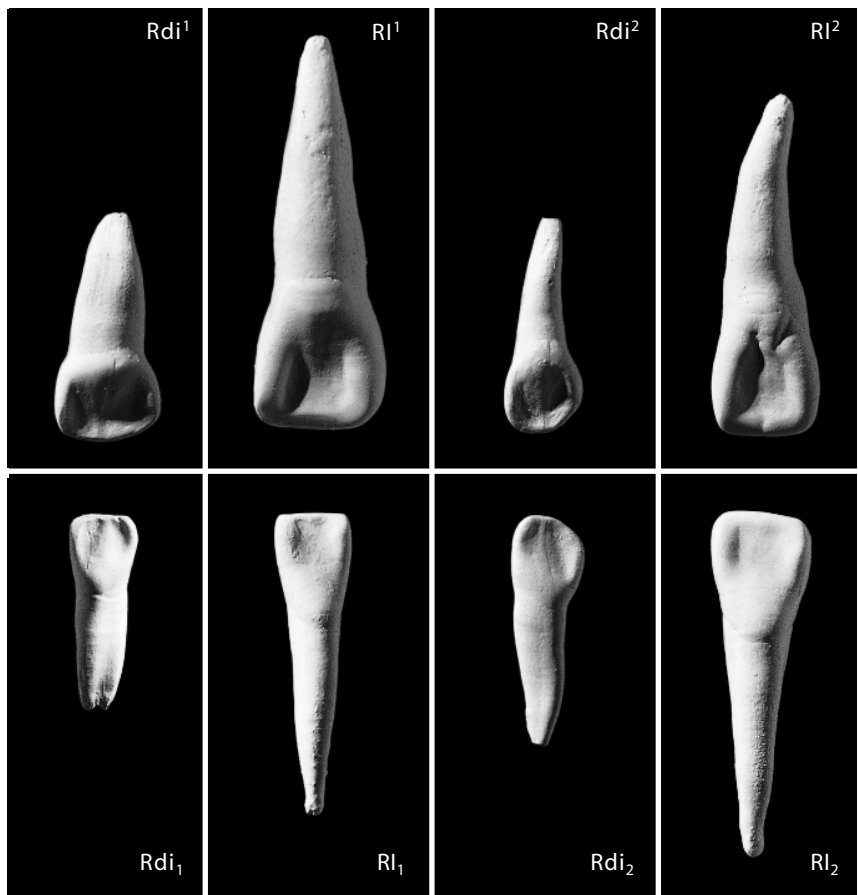


Figure 5.7 Upper and lower deciduous and permanent incisors compared. Right side, lingual view, twice natural size.

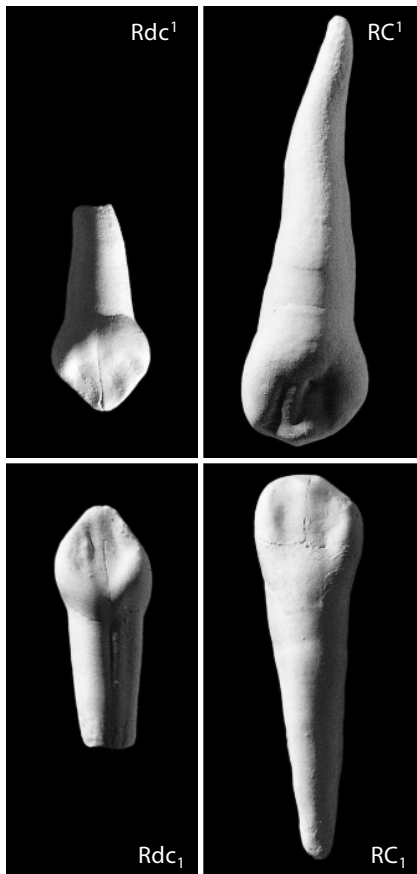


Figure 5.8 Upper and lower deciduous and permanent canines compared. Right side, lingual view, twice natural size.

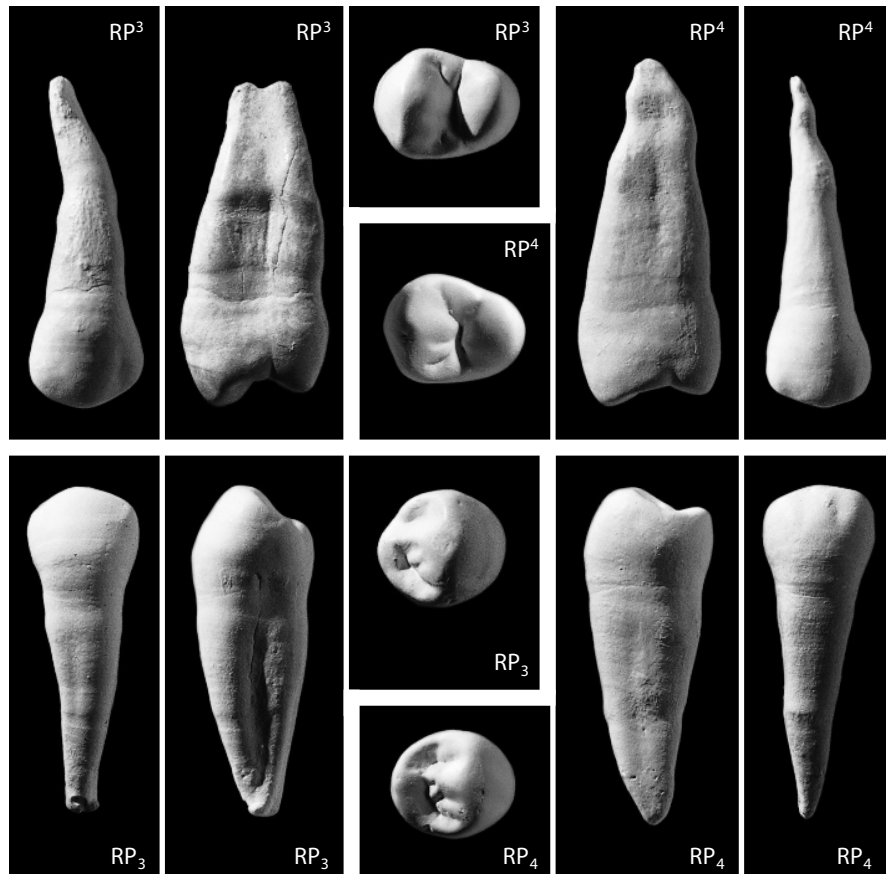


Figure 5.9 Upper and lower permanent premolars compared. Right side, buccal, mesial, and occlusal views, twice natural size.

5.8.2 Upper versus Lower Canines (Figure 5.8)

- Upper canine crowns are broad (mesiodistally elongate) relative to their height. Lower canine crowns are narrow relative to their height.
- Upper canine crowns have much lingual relief. Lower canines have comparatively little lingual relief.
- Upper canine crowns have apical wear that is mostly lingual. Lower canines have apical occlusal wear that is mostly labial.

5.8.3 Upper versus Lower Premolars (Figure 5.9)

- Upper premolar crowns have two cusps of nearly equal size. Lower premolar crowns show comparatively high disparity in buccal and lingual cusp size, with the buccal cusp dominating the lingual in height and area.
- Upper premolar crowns have strong occlusal grooves oriented mesiodistally (median grooves) between the major cusps. Lower premolar crowns have comparatively weak median grooves.
- Upper premolar crowns are more oval in occlusal outline. Lower premolar crowns are more circular in occlusal outline.

5.8.4 Upper versus Lower Molars (Figure 5.10)

- Upper molar crowns usually have three or four major cusps. Lower molar crowns usually have four or five major cusps.
- Upper molar crowns have outlines in the shape of a rhombus (skewed rectangle) in occlusal view. Lower molar crowns have square, rectangular, or oblong outlines.
- Upper molar crowns have cusps placed asymmetrically relative to the mesiodistal crown axis. Lower molar crowns have cusps placed symmetrically about the crown midline.
- Upper molars usually have three major roots that are variably fused. Lower molars usually have two major roots but occasionally have three.

5.9 What is the Position of the Tooth?

5.9.1 Upper Incisors: I¹ versus I² (Figure 5.11)

- Upper central incisor (I¹) crowns are larger than upper lateral incisor (I²) crowns.
- Upper central incisor (I¹) crowns have a greater mesiodistal length:height ratio than upper lateral incisor (I²) crowns in labial view.
- Upper central incisor (I¹) crowns are more symmetrical in labial view than upper lateral incisor (I²) crowns.
- Upper central incisor (I¹) roots are shorter and stouter relative to crown size than upper lateral incisor (I²) roots.

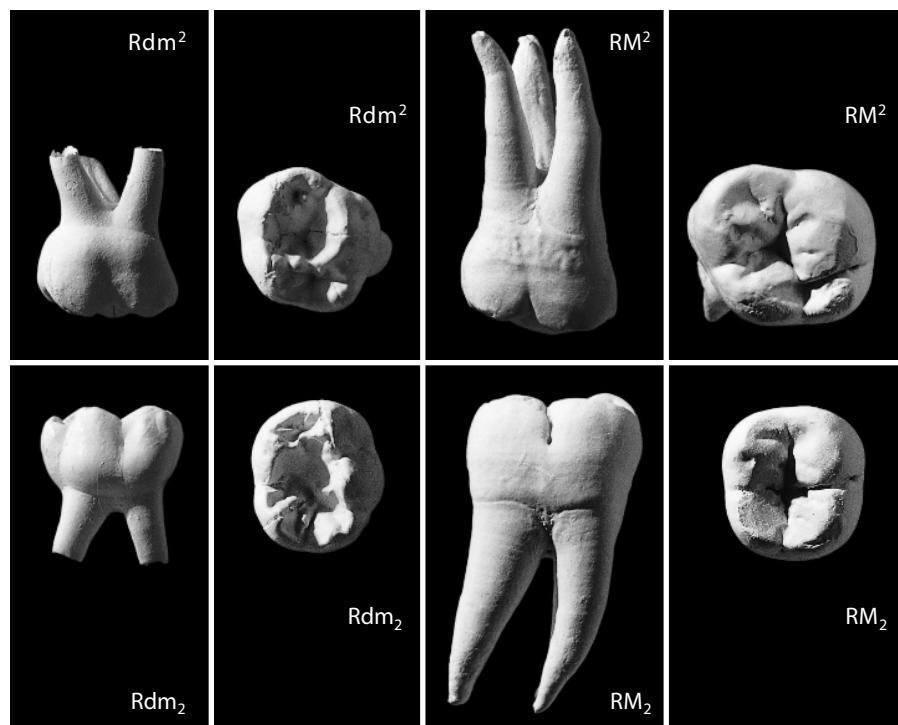


Figure 5.10 Upper and lower deciduous and permanent molars compared. Right side, buccal and occlusal views, twice natural size.

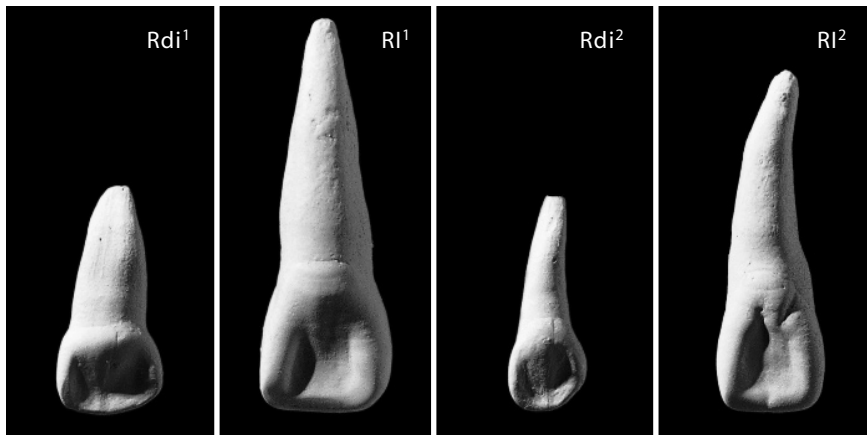


Figure 5.11 Upper deciduous and permanent incisors compared. Right side, lingual view, twice natural size.

5.9.2 Lower Incisors: I_1 versus I_2 (Figure 5.12)

- Lower central incisor (I_1) crowns are slightly smaller than lower lateral incisor (I_2) crowns.
- Lower central incisor (I_1) crowns have a smaller mesiodistal length: height ratio than lower lateral incisor (I_2) crowns in labial view.
- Lower central incisor (I_1) crowns are slightly more symmetrical in labial view than lower lateral incisor (I_2) crowns; the distal I_2 crown edges flare distally in this view.
- Lower central incisor (I_1) roots are shorter, both relative to crown height and absolutely, than I_2 roots.

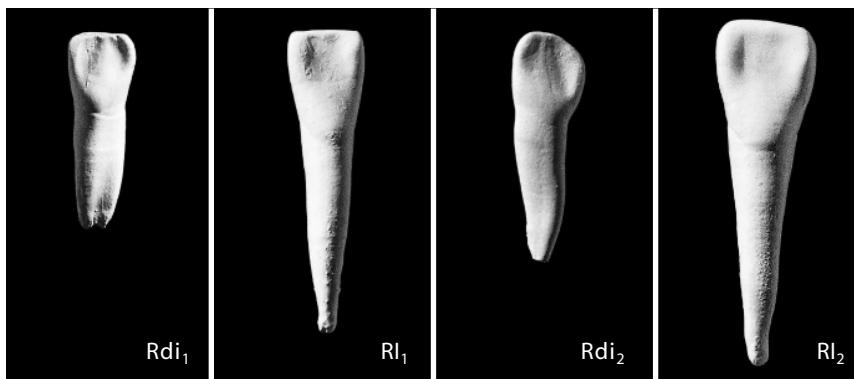
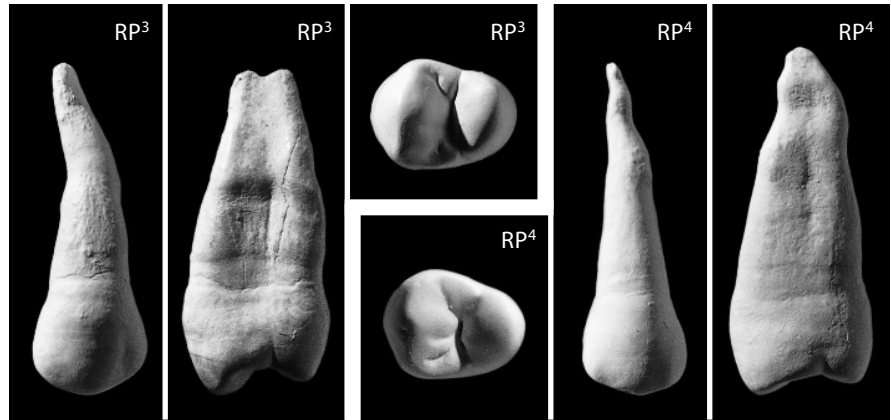


Figure 5.12 Lower deciduous and permanent incisors compared. Right side, lingual view, twice natural size.

5.9.3 Upper Premolars: P^3 versus P^4 (Figure 5.13)

- Upper third premolar (P^3) crowns have major lingual cusps that are small compared to major buccal cusps. Upper fourth premolar (P^4) crowns have major buccal and lingual cusps of more equivalent size in occlusal view.
- Upper third premolar (P^3) crowns have less symmetric, more triangular outlines in occlusal view than upper fourth premolar (P^4) crowns. The latter are rounder because the relative mesiodistal length of the major buccal cusp is not as great as in the P^3 crown (the lingual cusp of the P^4 crown is relatively larger in both length and area).

Figure 5.13 Upper permanent premolars compared. Right side, buccal, mesial, and occlusal views, twice natural size.

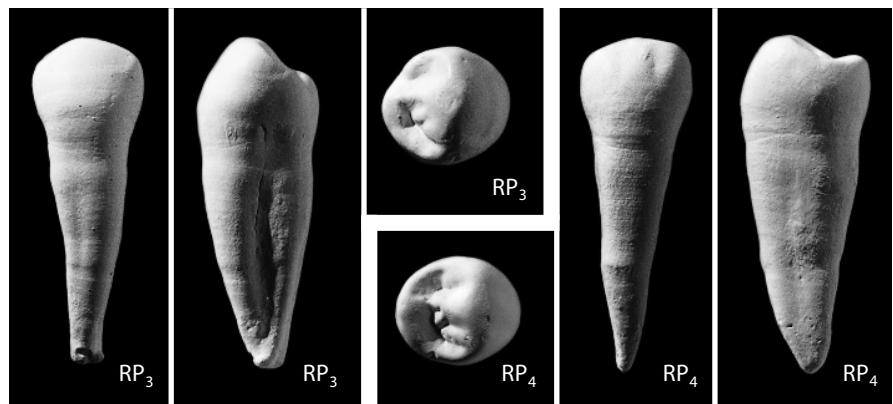


- Upper third premolar (P³) crowns have more concave mesial surfaces and more deeply indented mesial occlusal outlines than upper fourth premolar (P⁴) crowns.
- Upper third premolar (P³) crowns show more mesiobuccal projection of the cervicoenamel line than upper fourth premolar (P⁴) crowns.
- Upper third premolar (P³) crowns contact mesially with the canine. The resulting small mesial IPCF is distinctive, usually curved, and vertically elongate. The mesial IPCF on the upper fourth premolar (P⁴) is usually more symmetrical and buccolingually elongate.
- Upper third premolar (P³) roots are usually double, bilobate, or apically bifurcated. Upper fourth premolar (P⁴) roots are usually single.

5.9.4 Lower Premolars: P₃ versus P₄ (Figure 5.14)

- Lower third premolar (P₃) crowns have a major lingual cusp that is small, relative to the dominant major buccal cusp, in both occlusal area and height. The major lingual cusp is often expressed merely as a small lingual ridge. Lower fourth premolar (P₄) crowns have major buccal and lingual cusps of more equivalent size, and the major buccal cusp is less pointed than on a P₃ crown.

Figure 5.14 Lower permanent premolars compared. Right side, buccal, mesial, and occlusal views, twice natural size.



- Lower third premolar (P_3) crowns have a mesial fovea placed very mesially, close to the mesial occlusal edge in occlusal view. Lower fourth premolar (P_4) crowns have more distally placed mesial foveae.
- Lower third premolar (P_3) crowns have less symmetry of occlusal outline than lower fourth premolar (P_4) crowns.
- Lower third premolar (P_3) crowns have much smaller talonids than lower fourth premolar (P_4) crowns.
- Lower third premolar (P_3) crowns bear mesial (canine) IPCFs analogous to those discussed earlier for the upper counterparts.

5.9.5 Upper Molars: M^1 versus M^2 versus M^3 (Figure 5.15)

- Upper first molar (M^1) crowns have four well-developed cusps arranged in a rhombic shape. Upper third molars (M^3) tend to be smaller and more crenulate (furrowed on the occlusal surface) than first molars, with more irregular cusp positioning relative to the major crown axes. Upper third molars (M^3) usually lack a hypocone in humans. Upper second molar (M^2) crowns are intermediate to the first and third molar crowns in morphological attributes.

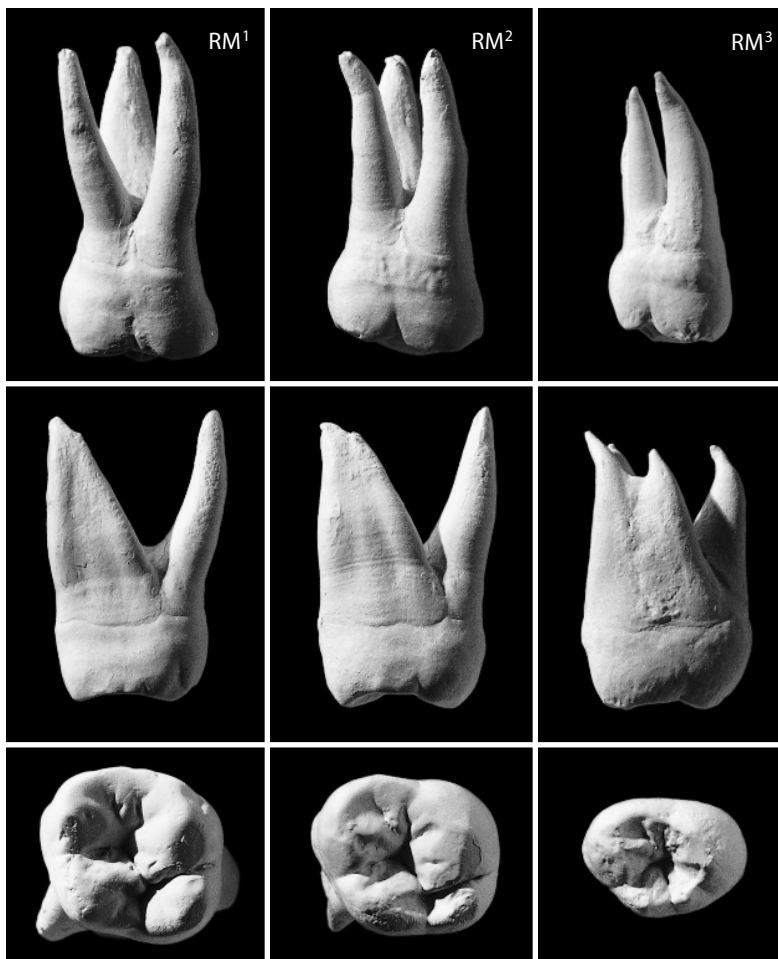


Figure 5.15 Upper permanent molars compared. Right side, buccal, mesial, and occlusal views, twice natural size.

- Upper first molars (M^1) have three long, separate, and divergent roots. Upper third molars (M^3) tend to have fused roots and lack distal IPCFs. Upper second molar (M^2) roots are intermediate.

5.9.6 Lower Molars: M_1 versus M_2 versus M_3 (Figure 5.16)

- Lower first molar (M_1) crowns have five well-developed cusps usually arranged in the classic Y-5 pattern. Lower third molars (M_3) usually have four or fewer cusps with more variable arrangement. Lower third molars (M_3) tend to be smaller and more crenulate than first molars, with more irregular cusp positioning relative to the major crown axes. Lower second molar (M_2) crowns are intermediate to the first and third molar crowns in morphological attributes.
- Lower first molars (M_1) have two long, separate, and divergent roots. Lower third molars (M_3) tend to have fused roots and lack distal IPCFs. When the mesial and distal roots remain separate, the distal one is post-like, set below a rounded posterior crown profile. Lower second molar (M_2) roots are intermediate.

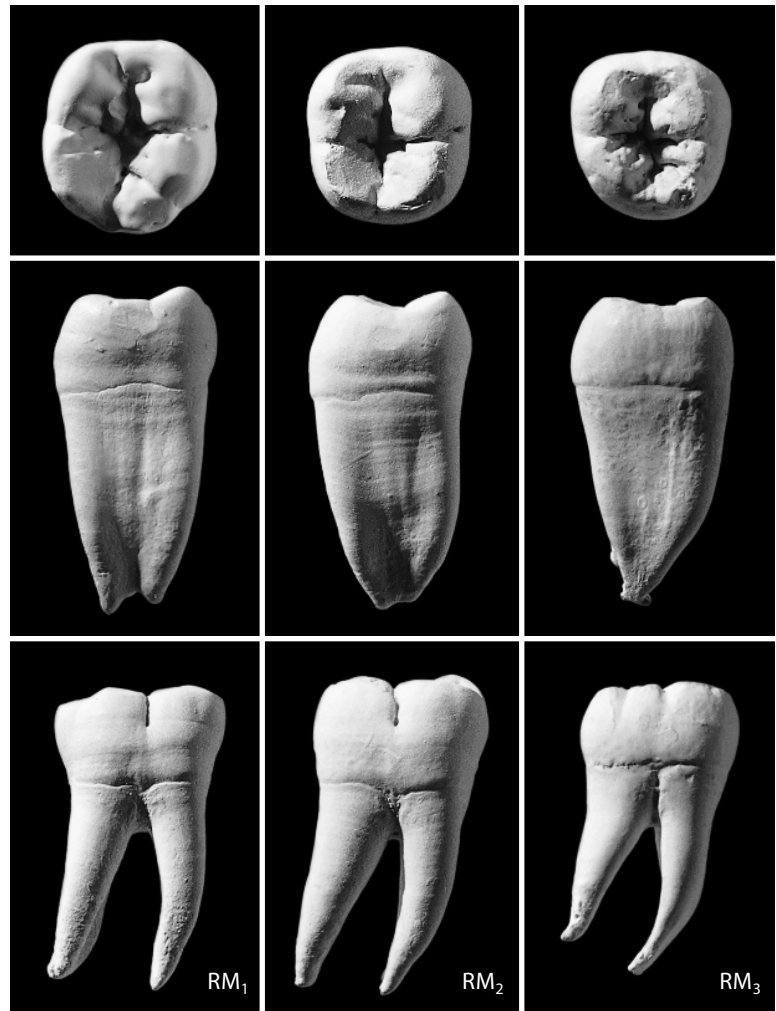

Figure 5.16 Lower permanent molars compared. Right side, occlusal, mesial, and buccal views, twice natural size.

5.10 Is the Tooth from the Right or the Left Side?

5.10.1 Upper Incisors (Figure 5.17)

Make the first two observations in labial view, orienting the specimen as it would rest in dentition, with the occlusal surface horizontal. The root axis angles posterolaterally in the maxilla. The distal occlusal corner is more rounded than the mesial.

- The long axis of the root angles distally relative to the vertical (cervicoincisal) axis of the crown, with the root tip usually leaning distally.
- The I^1/I^1 IPCF is more planar (flatter), wider, and more symmetrically placed than the more irregular, vertically elongate I^1/I^2 IPCF.
- The distal root surface is more deeply grooved than the mesial root surface.

5.10.2 Lower Incisors (Figure 5.17)

Make the first, third, and fourth observations in labial view, orienting the specimen as it would rest in dentition, with the occlusal surface horizontal.

- The root axis angles posterolaterally.
- The distal occlusal corner is more rounded than the mesial.

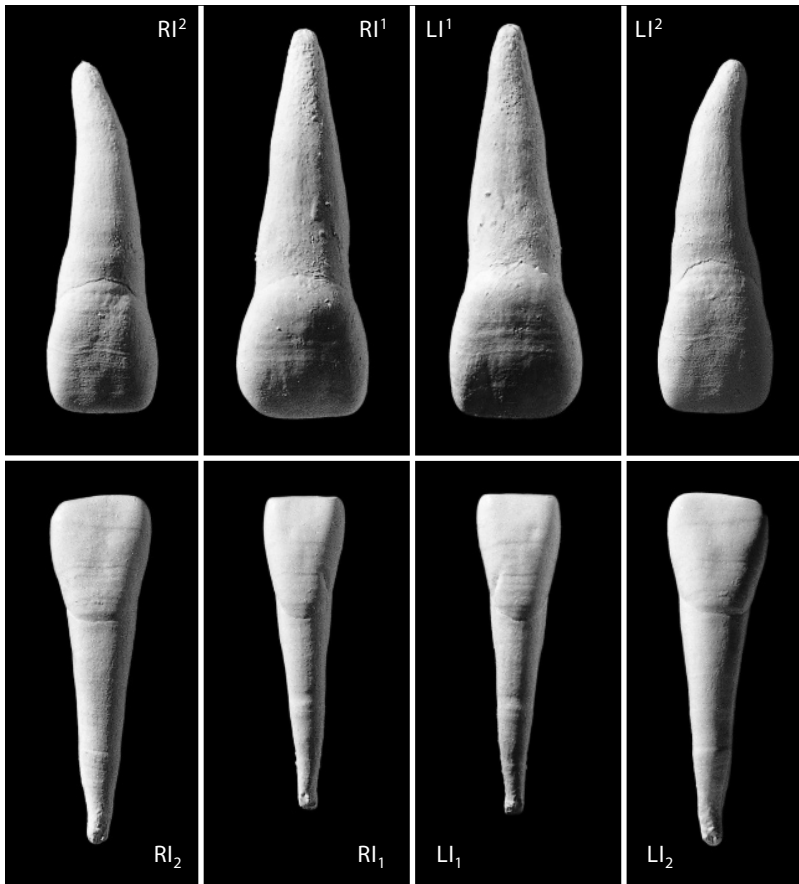


Figure 5.17 Right and left upper and lower permanent incisors. Labial view, twice natural size.

- The I_1/I_1 IPCF is more planar (flatter) and symmetrically placed than the I_1/I_2 IPCF.
- The occlusal wear most often angles distally and inferiorly relative to the vertical (cervico-incisal) axis of the crown.
- The long axis of the root angles distally relative to the vertical (cervico-incisal) axis of the crown, with the root tip usually leaning distally.

5.10.3 Upper Canines (Figure 5.18)

Make the first two observations in labial view with the tooth oriented as it would rest in dentition.

- The mesial occlusal edge (ridge joining crown shoulder with apex) is usually shorter than the distal occlusal edge.
- The long axis of the root angles distally relative to the vertical (cervico-incisal) axis of the crown.
- The distal IPCF (for P^3) is usually larger and especially broader than the mesial (lateral incisor) IPCF.

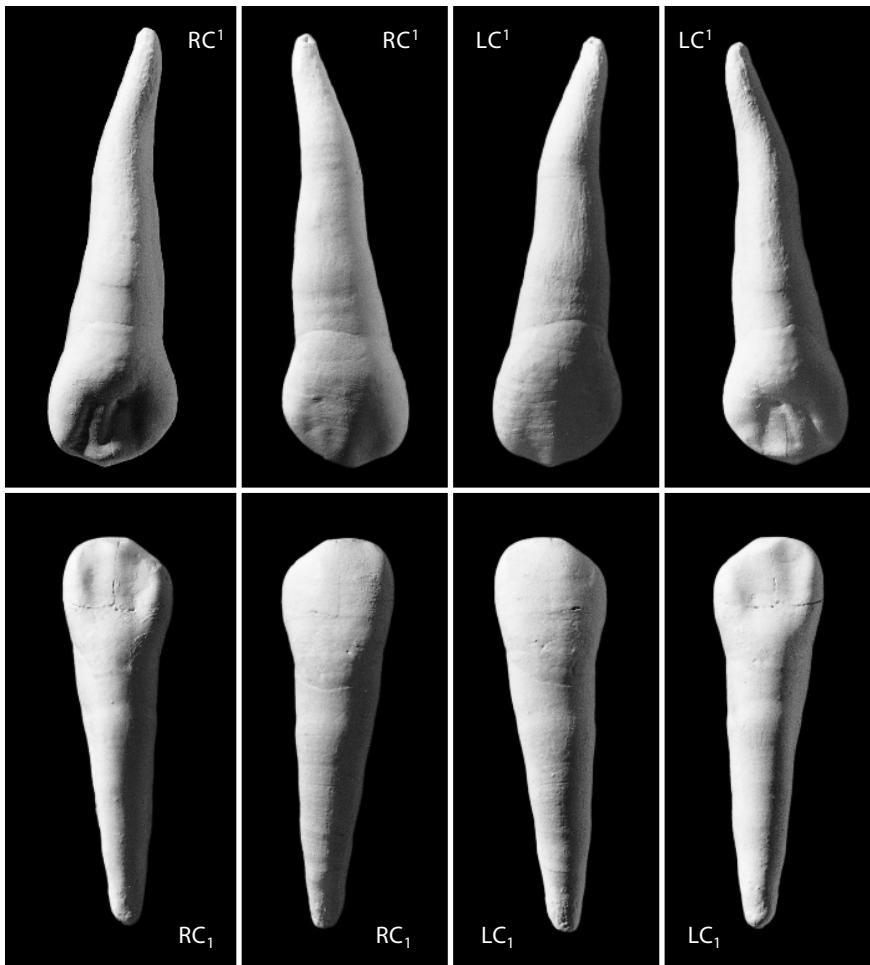


Figure 5.18 Right and left upper and lower permanent canines. Lingual and labial views, twice natural size.

- The distal root surface is more deeply grooved than the mesial root surface.
- The mesial enamel line has a higher crownward arch.

5.10.4 Lower Canines (Figure 5.18)

All of the criteria used to side upper canines are applicable to lower canines.

5.10.5 Upper Premolars (Figure 5.19)

- IPCFs (when present) are mesial and distal, and the major median groove between cusps is oriented mesiodistally.
- The major lingual cusp is centered mesially relative to the major buccal cusp. Note for worn teeth that the center of the dentine exposure usually corresponds to the placement of the original cusp apex.
- The major lingual cusp is smaller, less occlusally prominent, and usually more heavily worn than the major buccal cusp.
- The long axis (axes) of the root(s) angle(s) distally relative to the vertical (cervicoincisal) axis of the crown.

5.10.6 Lower Premolars (Figure 5.19)

- The IPCFs (when present) are mesial and distal.
- The major buccal cusp is larger, more occlusally prominent, and usually heavily worn more than the major lingual cusp.
- The major lingual cusp is centered mesially relative to the main buccolingual axis of the crown in occlusal view.
- The talonid, if present, is distal.
- The long axis (axes) of the root(s) angle(s) distally relative to the vertical (cervicoincisal) axis of the crown.

5.10.7 Upper Molars (Figure 5.20)

- IPCFs (when present) are located on the mesial and distal crown faces.
- The protocone is the largest, most heavily worn cusp. It occupies the mesiolingual crown corner.
- The hypocone is the smallest (sometimes absent) cusp. It occupies the distolingual crown corner.
- Lingual cusps are less prominent than buccal cusps and have heavier wear.
- In occlusal view, the lingual crown surface is more visible than the buccal crown surface.
- The largest of the three roots is often compressed buccolingually and set beneath the protocone and hypocone.
- The two smaller roots are rounder and set buccally (one mesial and one distal), and the mesiobuccal root is usually larger.
- All roots angle distally with respect to the major crown axes.

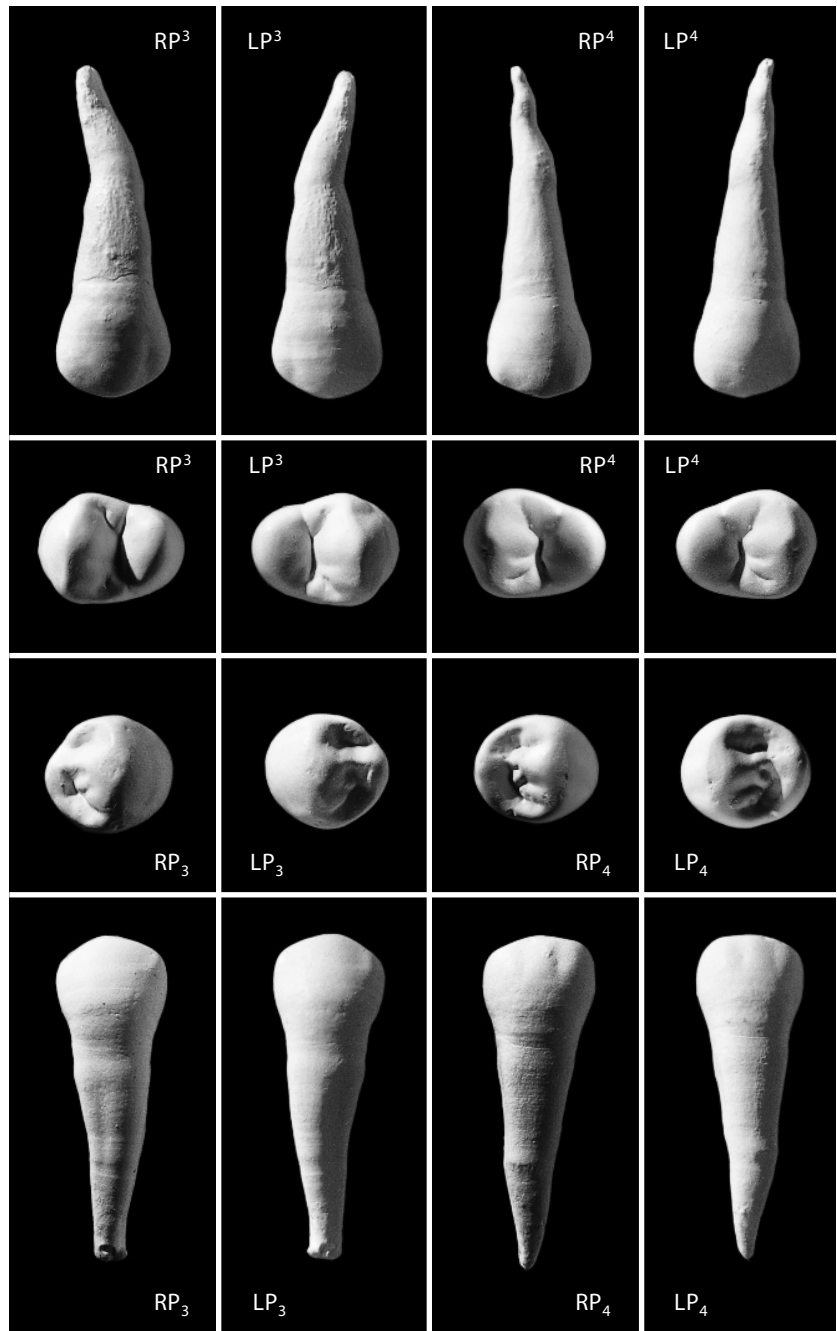


Figure 5.19 Right and left upper and lower permanent premolars. Buccal and occlusal views, twice natural size.

5.10.8 Lower Molars (Figure 5.20)

- IPCFs (when present) are located on the mesial and distal crown faces.
- The longest crown axis is usually mesiodistal.
- The protoconid is the largest, most heavily worn cusp. It occupies the mesiobuccal crown corner.
- The hypoconulid is the smallest cusp (unless there are additional, smaller cusps, labeled C-6, C-7, and so on). It is placed distally and centered on the mesiodistal crown axis.

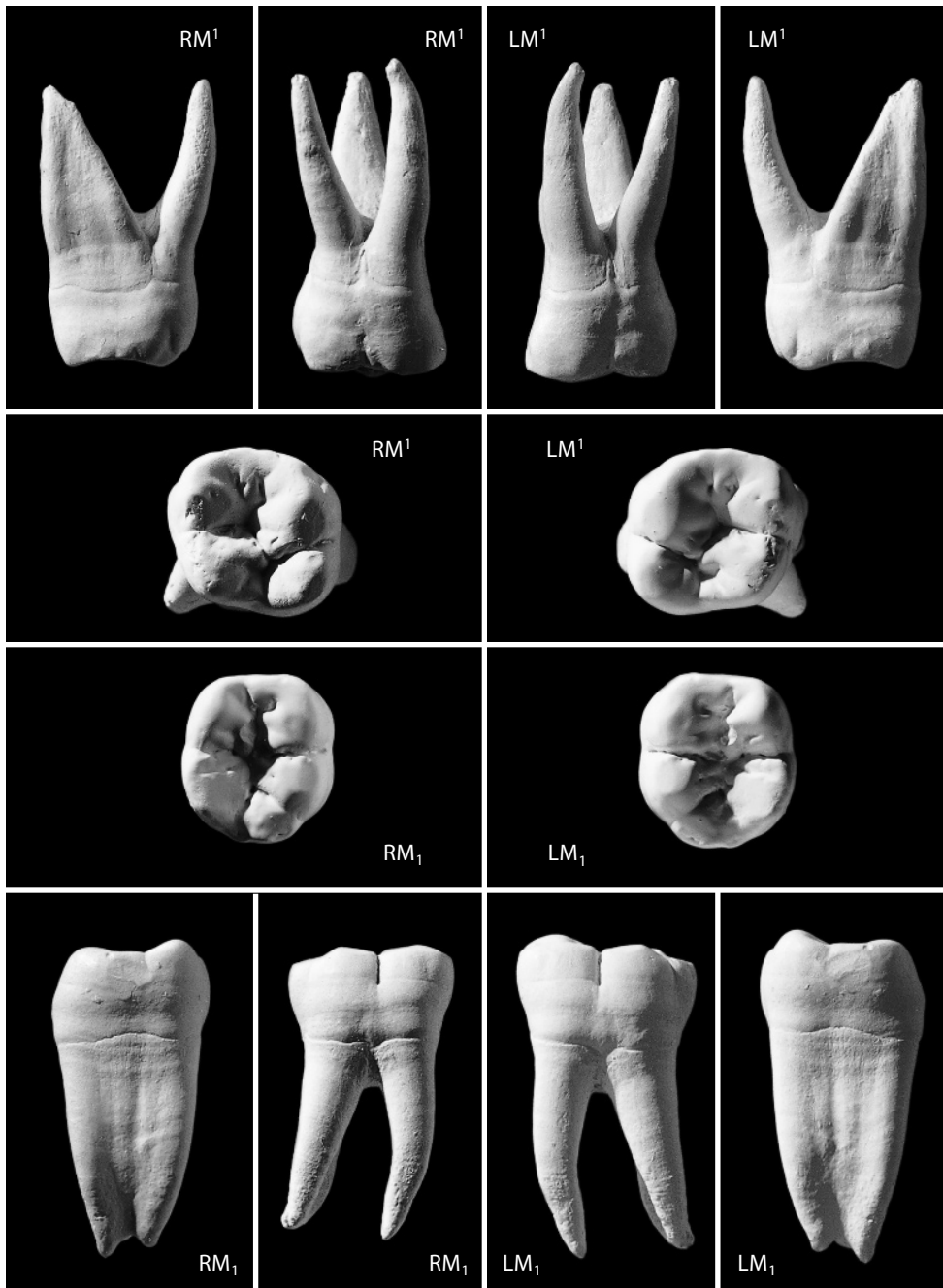


Figure 5.20 Right and left upper and lower permanent molars. Mesial, buccal, and occlusal views, twice natural size.

- The buccal cusps are occlusally less prominent than the lingual cusps and have heavier wear.
- The two major roots are compressed mesiodistally and set under the mesial and distal crown halves.
- All roots angle distally with respect to the major crown axes.

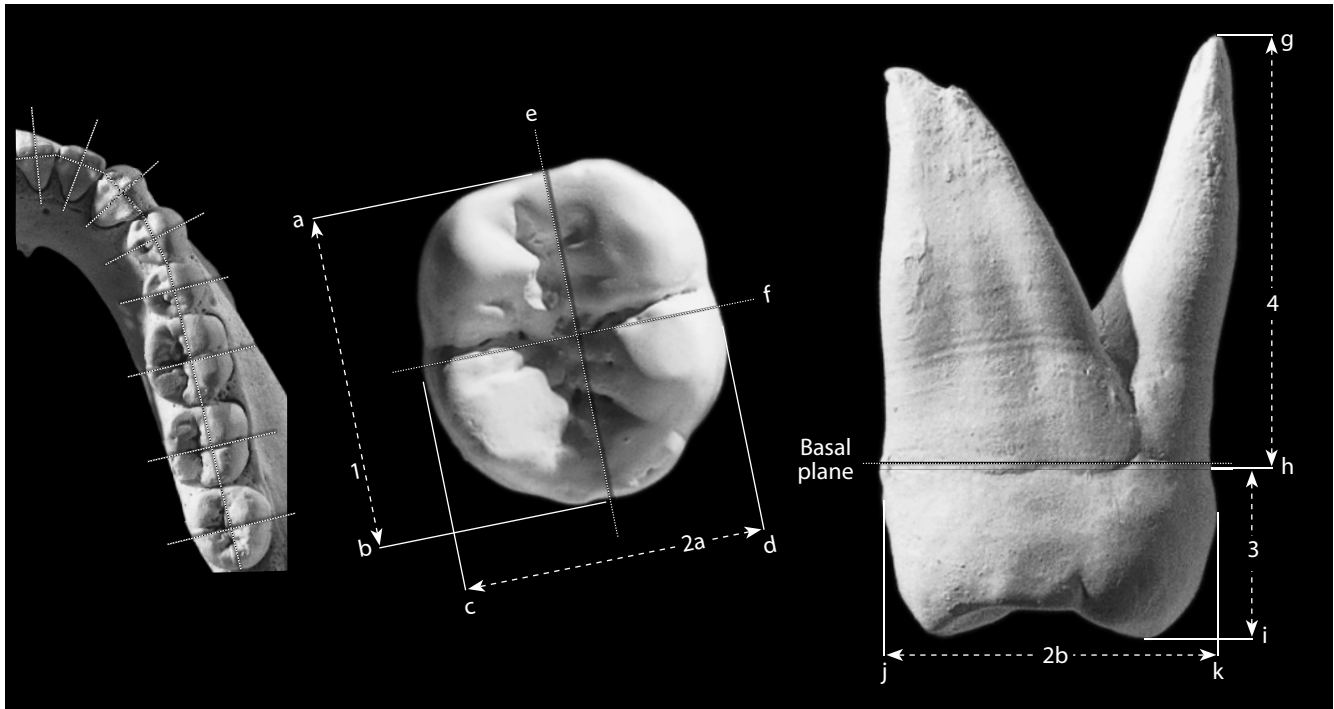


Figure 5.21 Measurements of teeth. Note that the mesiodistal axis for each tooth crown must be determined according to its placement in the tooth row (*left*). The labiolingual (or buccolingual) crown axis is then defined as being perpendicular to the mesiodistal axis. Mandibular hemiarcade, natural size; isolated molars, four times natural size.

Locations: a) mesialmost point on mesial surface of crown; b) distalmost point on distal surface of crown; c) lingualmost point on buccal surface of crown; e) buccalmost point on lingual surface of crown; e) mesiodistal crown axis; f) buccolingual crown axis; g) apex of root; h) cervix, cemento enamel line or junction (CEJ); i) apex of lingual cusp (protocone); j) buccalmost point on buccal surface of crown; k) lingualmost point on lingual surface of crown.

Measurements: 1) mesiodistal crown diameter, LM_1 ; 2a) buccolingual crown diameter, LM_1 ; 2b) buccolingual crown diameter, RM^2 (taken at widest point along crown height); 3) lingual crown height, RM^2 ; 4) lingual root length, RM^2 .

5.11 Dental Measurements: Odontometrics (Figure 5.21)

Measurements of teeth are used throughout physical anthropology, forensic anthropology, and paleoanthropology in investigations of age, diet, sex, taxonomy, and health. The use of finely pointed steel calipers to measure teeth is a potentially destructive activity, and if the hands are not steadied atop a desk during the operation, movement of caliper relative to tooth surface can result in serious chippage and crushing at the caliper tip. Extreme caution is called for; the caliper is replaceable but the specimen is not.

1. **Mesiodistal crown diameter (or length)** (White, 1977: 198; Suwa, 1990: 40–43): Taken with a fine pointed (or dental) sliding caliper held parallel to the crown base (basal plane). This dimension is the absolute length along the mesiodistal crown axis as the tooth typically rests in the dental arcade, normally between the mesial and distal interproximal facets (IPCFs) except for abnormally rotated teeth. It is most accurately measured on erupted but unworn teeth, as interproximal contact facets will cause measurements to be smaller than the actual dimension. Note estimated compensation for IPCF dimensional reduction and do not measure teeth where such estimation is not possible.

2. **Buccolingual crown diameter (or breadth)** (White, 1977: 198; Suwa, 1990: 40–43): Taken with a fine pointed (or dental) sliding caliper parallel to the crown base. Is the maximum distance between buccal and lingual crown faces on an axis perpendicular to that of the mesiodistal crown diameter. Avoid including calculus.
3. **Crown height** (White, 1977: 198; Suwa, 1990: 40–43): With a fine pointed (or dental) sliding caliper, measure the vertical distance from the cementoenamel junction (CEJ) to the unworn apex (reconstructing for wear, if necessary) of the highest adjacent crown. Be sure to specify the region of the molar or premolar crown for which the height is being measured (*eg.*, mesiobuccal crown height); incisor and canine crown heights are taken from the incisal margin to the labial line, along the central crown axis.
4. **Root length** (Garn et al., 1978: 636): With a fine pointed (or dental) sliding caliper, measure the vertical distance from the cementoenamel junction (CEJ) to the root apex (avoid resorbed or incomplete roots). Be sure to specify the root for which the length is being measured (*eg.*, lingual root length).

5.12 Dental Nonmetric Traits

Nonmetric traits of the teeth are a staple of dental anthropology. Whereas many of these variants have been called out in the preceding descriptive sections, there are dozens more that can be found in Hanihara (2008), Hillson (1996), and Scott and Turner (1988, 1997).

Suggested Further Readings

Because they are central to so many studies, an enormous literature on teeth has developed over several centuries (see, for example, Metress and Conway, 1974, for a partial bibliography through 1974, and Foley and Cruwys, 1986; Scott and Turner, 1988; Kelly and Larsen, 1991; Hillson, 1996; and Alt et al., 2003, for more recent reviews). Anthropologists, paleontologists, forensic analysts, and dental researchers all continue to contribute to this literature. *Dental Anthropology*, a publication of the Dental Anthropology Association, is a newsletter/journal with articles, reviews, and regular bibliographies.

Alt, K. W., Rösing, F. W., and Teschler-Nicola, M. (Eds.) (2003) *Dental anthropology: Fundamentals, limits and prospects*. New York, NY: Springer. 564 pp.

An introduction to, and survey of, research in dental anthropology.

Avery, J. K. (Ed.) (2001) *Oral development and histology* (3rd ed.). New York, NY: Thieme. 480 pp.

A comprehensive textbook on oral anatomy.

Hillson, S. (1996) *Dental anthropology*. Cambridge, UK: Cambridge University Press. 373 pp.

Everything about teeth, from an anthropological perspective.

Hillson, S. (2005) *Teeth* (2nd ed.). Cambridge, UK: Cambridge University Press. 388 pp.

An excellent guide to all matters having to do with teeth. Fine illustrations of a variety of mammalian teeth and a full consideration of human teeth from many perspectives.

Irish, J. D. and Nelson, G. C. (Eds.) (2008) *Technique and application in dental anthropology*. Cambridge, UK: Cambridge University Press. 470 pp.

This edited volume focuses on methodological aspects of dental anthropology, discussing a variety of techniques useful in the study of teeth.

Kelley, M. A., and Larsen, C. S. (Eds.) (1991) *Advances in dental anthropology*. New York, NY: Wiley-Liss. 389 pp.

An edited volume covering the spectrum of dental anthropology.

Kieser, J. A. (2008) *Human adult odontometrics: The study of variation in adult tooth size*. Cambridge, UK: Cambridge University Press. 208 pp.

A comprehensive guide to dental measurements and metric variation in human teeth.

Nelson, S. J. (2009) *Wheeler's dental anatomy, physiology and occlusion* (9th ed.). St. Louis, MO: Saunders/Elsevier. 368 pp. + CD-ROM.

Considered the standard reference work for dentistry, this well-illustrated volume has useful chapters on deciduous teeth, dental eruption, and occlusion, as well as 7 chapters dedicated to the morphology of specific categories of teeth.

Scheid, R. C. (2007) *Woelfel's dental anatomy: Its relevance to dentistry* (7th ed.). Baltimore, MD: Lippincott Williams and Wilkins. 534 pp.

Everything about teeth, from the dentist's perspective. Excellent illustrations of variation among many individuals for each tooth.

Scott, G. R., and Turner, C. G. (1997) *The anthropology of modern human teeth: Dental morphology and its variation in recent human populations*. New York, NY: Cambridge University Press. 382 pp.

A comprehensive guide to the anthropological utility of dental variation in modern humans.

Steele, D. G., and Bramblett, C. A. (1988) *The anatomy and biology of the human skeleton*. College Station, TX: Texas A&M University Press. 291 pp.

A good atlas with labeled photographs and written descriptions of human teeth.

Taylor, R. M. S. (1978) *Variation in morphology of teeth: Anthropologic and forensic aspects*. Springfield, IL: C. C. Thomas. 384 pp.

An eye-opening guide to variation in human dental anatomy.

Van Beek, G. C. (1983) *Dental morphology: An illustrated guide* (2nd ed.). Woburn, MA: Butterworth-Heinemann. 144 pp.

A good introduction to dental morphology, with large, labeled illustrations of each tooth and a handy glossary of specialized terms.

Chapter 6

HYOID AND VERTEBRAE

IN EARLY VERTEBRATES, a chain of cartilage-replacement bones formed around the notochord to give it stiffness. Over time, these bones developed processes that wrapped around the dorsal side of the nerve cord. Today we know these bones as vertebrae, elements from which the entire subphylum Vertebrata derives its name. In most modern vertebrates, the vertebrae have replaced the notochord as the principal means of support for the central part of the body. The sacrum and coccyx are vertebrae, but they function as parts of the bony pelvis. The hyoid bone, an intermediary between the skull and postcranial skeleton, combines skeletal elements of the second and third pharyngeal arches associated with the gills of primitive fish.

6.1 Hyoid (Figure 6.1)

6.1.1 Anatomy

The hyoid bone is located in the neck and can be palpated immediately above the *thyroid cartilage* (the protuberance on the anterior surface of the neck). It is the only bone in the body that does not articulate with another bone. Instead, it is suspended from the tips of the styloid processes of the temporal bones by the *stylohyoid ligaments*. The hyoid gives attachment to a variety of muscles and ligaments that connect it to the cranium, mandible, tongue, larynx, pharynx, sternum, and shoulder girdle. Its shape is highly variable and it is often fractured in forensic cases involving strangulation (Pollanen and Ubelaker, 1997). The U-shaped hyoid consists of three major parts that are variably fused:

- a. The **body** straddles the midline. It is a thin, posterosuperiorly concave, curved bone that articulates with, or is fused laterally to, the hyoid horns.
- b. The **greater horns** are long, thin structures that form the posterior sides of the hyoid bone and project posterolaterally from the body on either side. The tip of each horn is a slightly expanded tubercle that serves as the attachment for the *lateral thyrohyoid ligament*.
- c. The **lesser horns** are small, conical eminences on the superior surface of the bone in the area where the body and greater horns join. Their variably ossified apices give attachment to the *stylohyoid ligaments*.

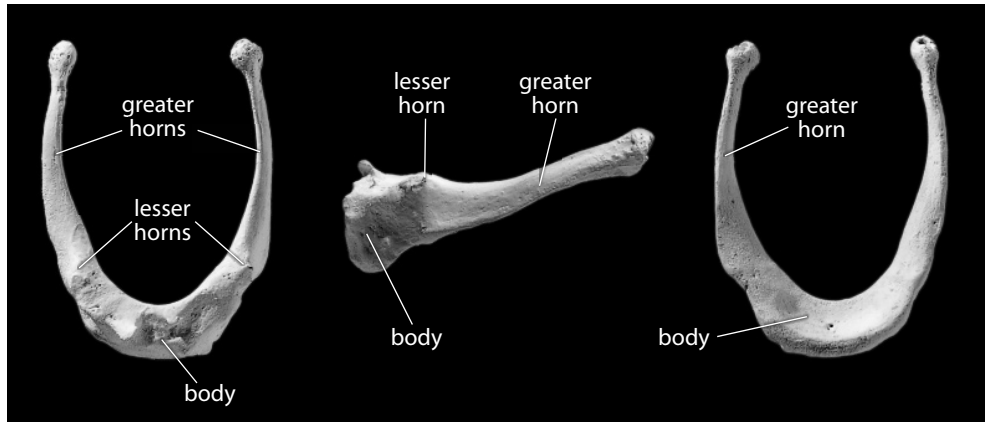


Figure 6.1 Hyoid. *Left:* superior view, posterior is up; *center:* lateral view, anterior is to the left, superior is up; *right:* inferior view, posterior is up. Natural size.

6.1.2 Growth

The hyoid ossifies from six centers: two for the body and one for each of the greater and lesser horns.

6.1.3 Possible Confusion

Hyoids are mistaken most frequently for immature vertebral sections.

- The body is far thinner and more plate-like than a vertebral centrum, or even any part of a vertebral arch.
- The horns are longer and thinner than the spinous processes of any vertebral element.

6.1.4 Siding

- The widest part of the greater horn is anterior, and the horn thins as it sweeps posteriorly, superiorly, and laterally to end in the tubercle.
- The superior surface bears the lesser horns.

6.1.5 Hyoid Measurements

Measurements of the hyoid are rarely taken or used, and can be defined as appropriate to the research question.

6.1.6 Hyoid Nonmetric Traits

- There are no commonly cited nonmetric traits on the hyoid, and variation in this element is rarely noted.

6.2 General Characteristics of Vertebrae

Because the fused vertebrae of the sacrum and coccyx form part of the bony pelvis, they are described in Chapter 14. This chapter describes the 24 movable vertebrae—the seven cervical, 12 thoracic, and five lumbar vertebrae. In this section we introduce parts common to most vertebrae; in the following sections we concentrate on each class of vertebra.

6.2.1 Anatomy (Figures 6.2–6.4)

The vertebral column is most often composed of 33 elements in the adult human. Of these, 24 are separate (movable vertebrae), and the others are variably fused within the bony pelvis. It should always be possible to identify isolated, even fragmentary individual vertebrae by type—cervical, thoracic, or lumbar. Cervical vertebrae are in the neck, thoracic vertebrae in the thorax, and lumbar vertebrae just superior to the bony pelvis. Within these units, individual vertebrae are designated by letter (L, lumbar; T, thoracic; and C, cervical) and identified by number from superior to inferior. For example, the most superior thoracic vertebra is designated T-1.

Successive vertebrae articulate directly with one another across synovial joints. All moveable vertebrae have two superior and two inferior articular facets. These four facets control movement between adjacent vertebrae; their shapes are the key to the function and identification of different vertebrae. Individual vertebrae are united within the vertebral column by ligaments and muscles that hold them together as a flexible unit. The three primary functions of each vertebra are to bear body weight, to anchor muscles and ligaments, and to protect the *spinal cord*. When the entire column or large segments of the column are available for a single individual, it is easy to identify each vertebra by type and number. From the cervical vertebrae through the lumbar vertebrae, each successive vertebral body (or centrum) is larger caudally because of successively greater weight-bearing responsibilities. Some individual vertebrae, like the atlas (C-1), are diagnosed easily, even if isolated, because of their unique morphology. Others, particularly mid-cervicals and mid-thoracics, are far more difficult to identify by number when found disassociated from the other vertebrae.

In life, adjacent vertebrae are separated by *intervertebral disks* that are made up of concentric rings of specialized fibrocartilage. Each disk is composed of a circumferential band of fibrous tissue and fibrocartilage known as the *annulus fibrosus*. At the center of the disk is a soft substance known as the *nucleus pulposus*. These tissues are surrounded by a *fibrous capsule*, which binds together adjacent vertebral bodies and encapsulates the disks. These soft tissue components are critical for movement in the vertebral column. The intervertebral disks make up more than one-fifth of the column's total height in life and contribute to its distinctive longitudinal curvature. Disks are thickest in the lumbar and cervical regions where the vertebral column is most freely movable.

Individuals can vary in the number of vertebrae they have in each category. This variation may occur in over 10% of all individuals in a skeletal population. Variation from the usual condition most often involves the shifting of a vertebral element from its typical category to an adjacent category. The most frequent deviation from the usual pattern of 7 cervical, 12 thoracic, and 5 lumbar vertebrae is the case of an extra thoracic or lumbar vertebra with an associated shift, as with 13 thoracic and 4 lumbar vertebrae.

We first describe the basic components of any vertebra before describing particular vertebral categories:

- a. The **vertebral foramen** is the hole in each vertebra through which the *spinal cord* passes. Each vertebra thus forms a segment of the vertebral canal passing down the vertebral column.
- b. The **vertebral body** (or **centrum**) is a spool-shaped structure that constitutes the main weight-bearing portion of a vertebra (except in the cases of the atlas and axis). The body is very thin-walled, composed mostly of lightweight, fragile, spongy bone, and it is therefore

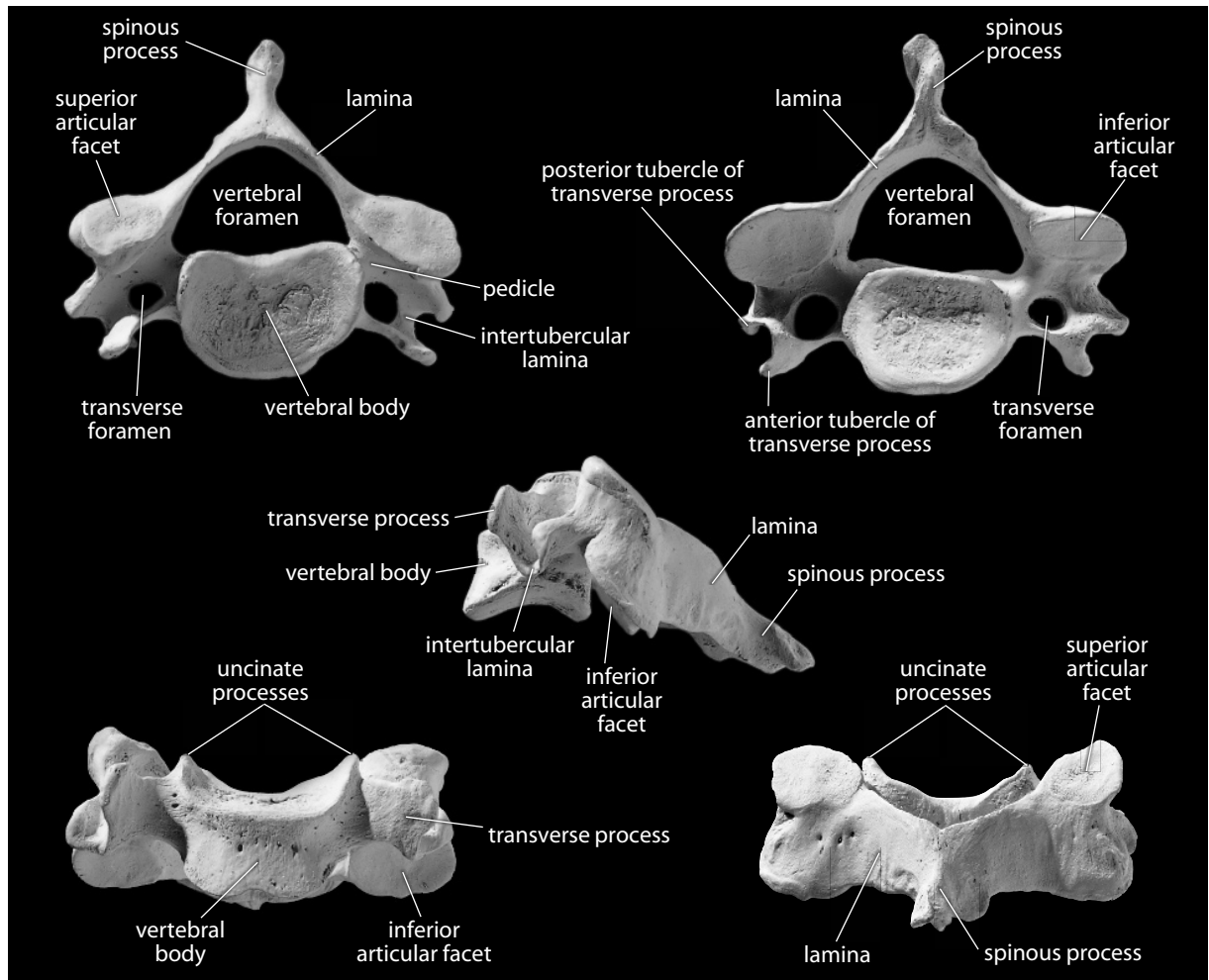


Figure 6.2 **Fifth cervical vertebra.** A “typical” cervical vertebra. *Top left:* superior view, posterior is up; *top right:* inferior view, posterior is up; *center:* left lateral view, posterior is to right; *bottom left:* anterior view, superior is up; *bottom right:* posterior view, superior is up. Natural size.

very susceptible to postmortem damage. It is also a center for blood production. The large foramen at the midline on its posterior surface is for the exit of the *basivertebral vein*.

- c. The **vertebral** (or **neural**) **arch** encloses the *spinal cord* posterior to the vertebral body.
- d. The **pedicle** is the short segment of the arch close to the vertebral body, attached more superiorly to the body than inferiorly.
- e. Posterior to each pedicle is the **lamina**, the plate-like part of the arch that attaches the pedicle to the spinous process.
- f. The **spinous process** projects posteriorly on the midline and serves to anchor the *interspinous* and *supraspinous ligaments* and several muscles. These ligaments limit flexion of the vertebral column. Because the spinous processes act as levers for muscular action, the length, size, and slope of individual spines depend on the functional role which various back muscles play.
- g. One **transverse process** is found on each side of each vertebra. Like spinous processes, the transverse processes act as levers for the muscles attached to them. Movements of the axial skeleton are made possible by the muscles acting on these levers. Movement is

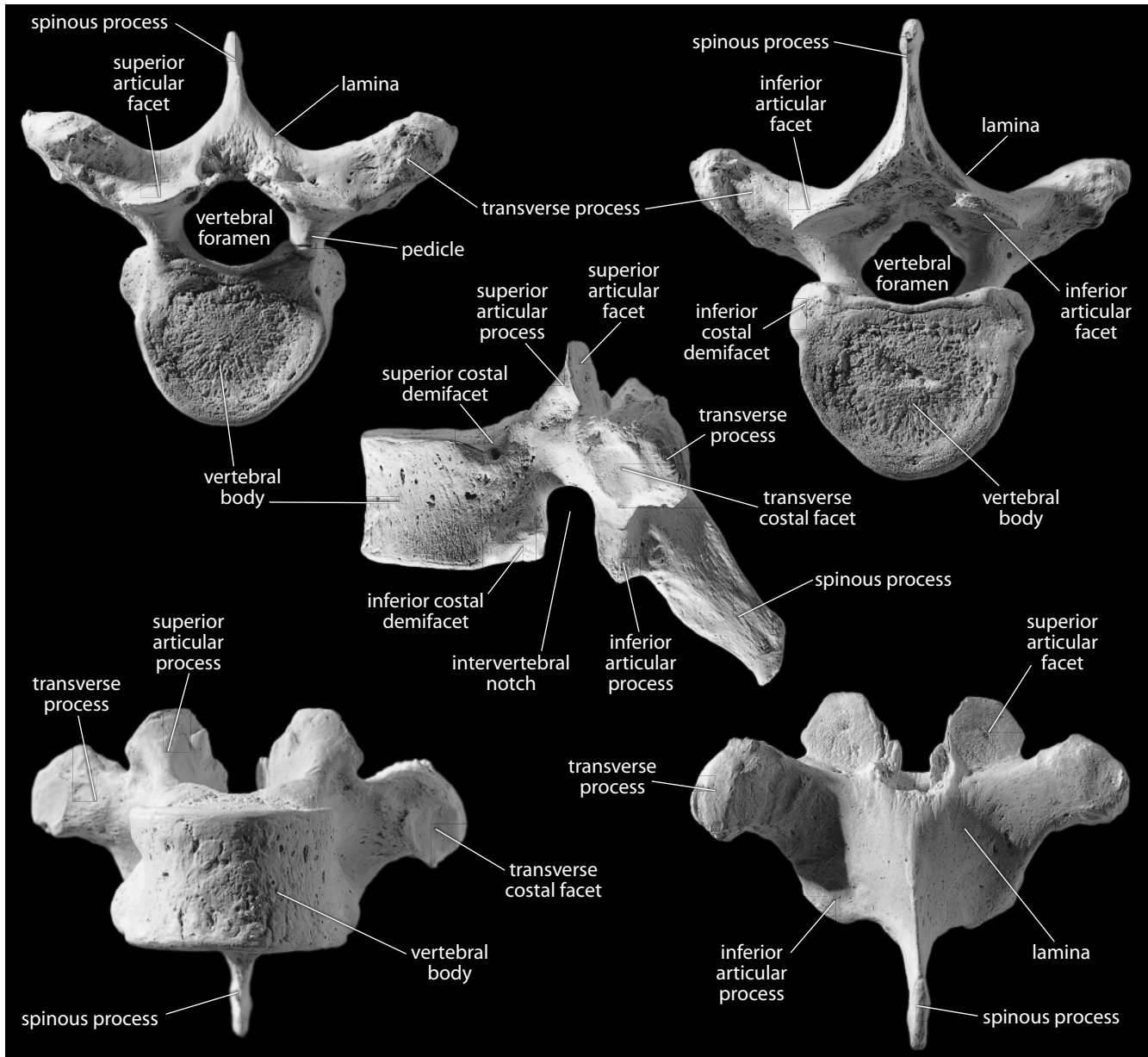


Figure 6.3 Seventh thoracic vertebra. A “typical” thoracic vertebra. *Top left:* superior view, posterior is up; *top right:* inferior view, posterior is up; *center:* lateral view, superior is up; *bottom left:* anterior view, superior is up; *bottom right:* posterior view, superior is up. Lateral view (center) is lit from the lower left to accentuate costal articulations. Natural size.

restricted by the ligaments that hold the individual vertebrae together. The transverse processes of thoracic vertebrae articulate with the ribs.

- h. **Superior articular facets** face posterosuperiorly in most cervical vertebrae, posteriorly in the thoracic vertebrae, and posteromedially in the lumbar vertebrae.
- i. **Inferior articular facets** face in the opposite directions of the superior facets for each vertebral class.
- j. The superior and inferior articular facets of thoracic and lumbar vertebrae are located on **superior** and **inferior articular processes**, respectively.

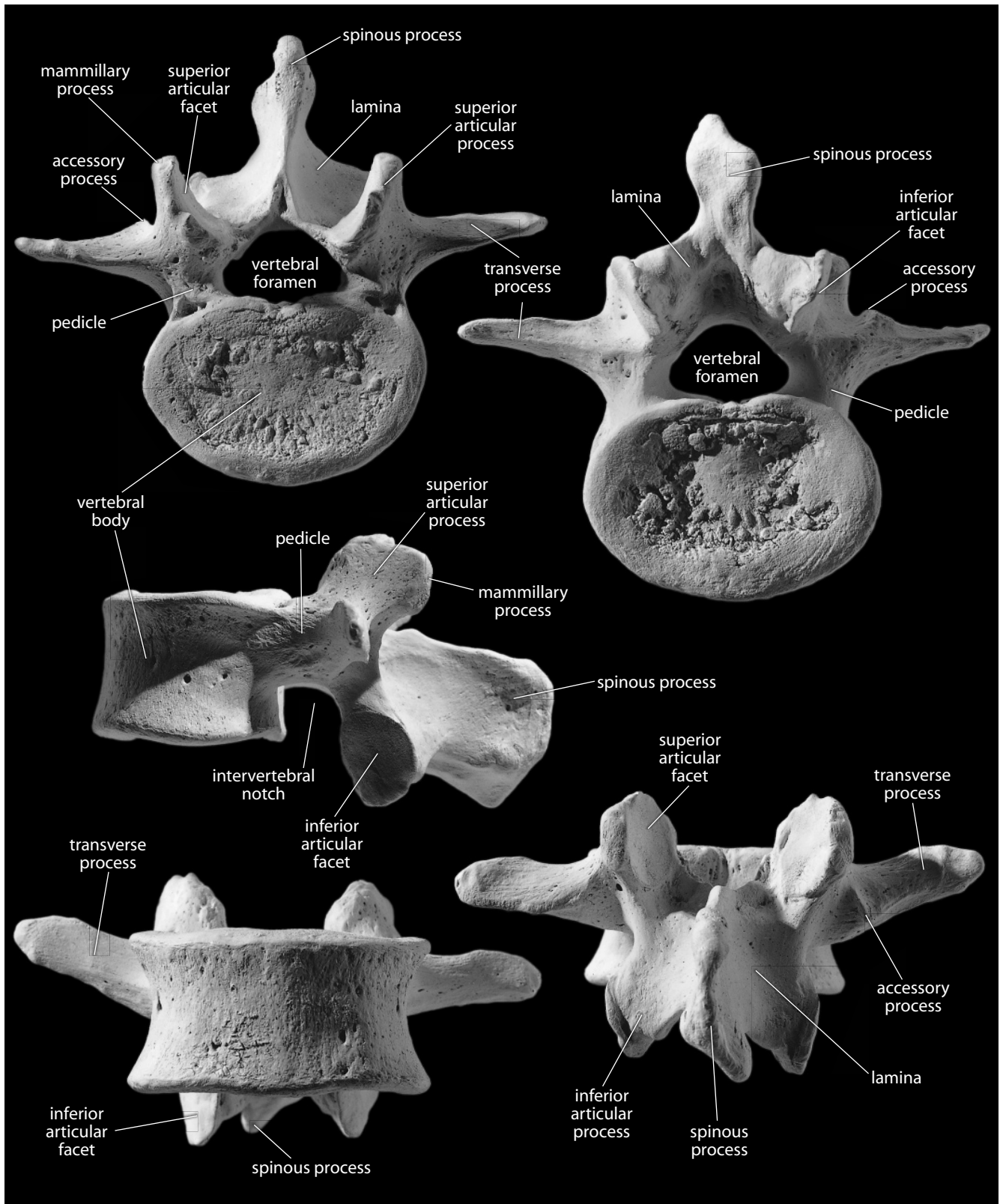


Figure 6.4 Third lumbar vertebra. A “typical” lumbar vertebra. *Top left:* superior view, posterior is up; *top right:* inferior view, posterior is up; *center:* lateral view, superior is up; *bottom left:* anterior view, superior is up; *bottom right:* posterior view, superior is up. Lateral view (center) is lit from the upper right to accentuate the spine and inferior articular facet. Natural size.

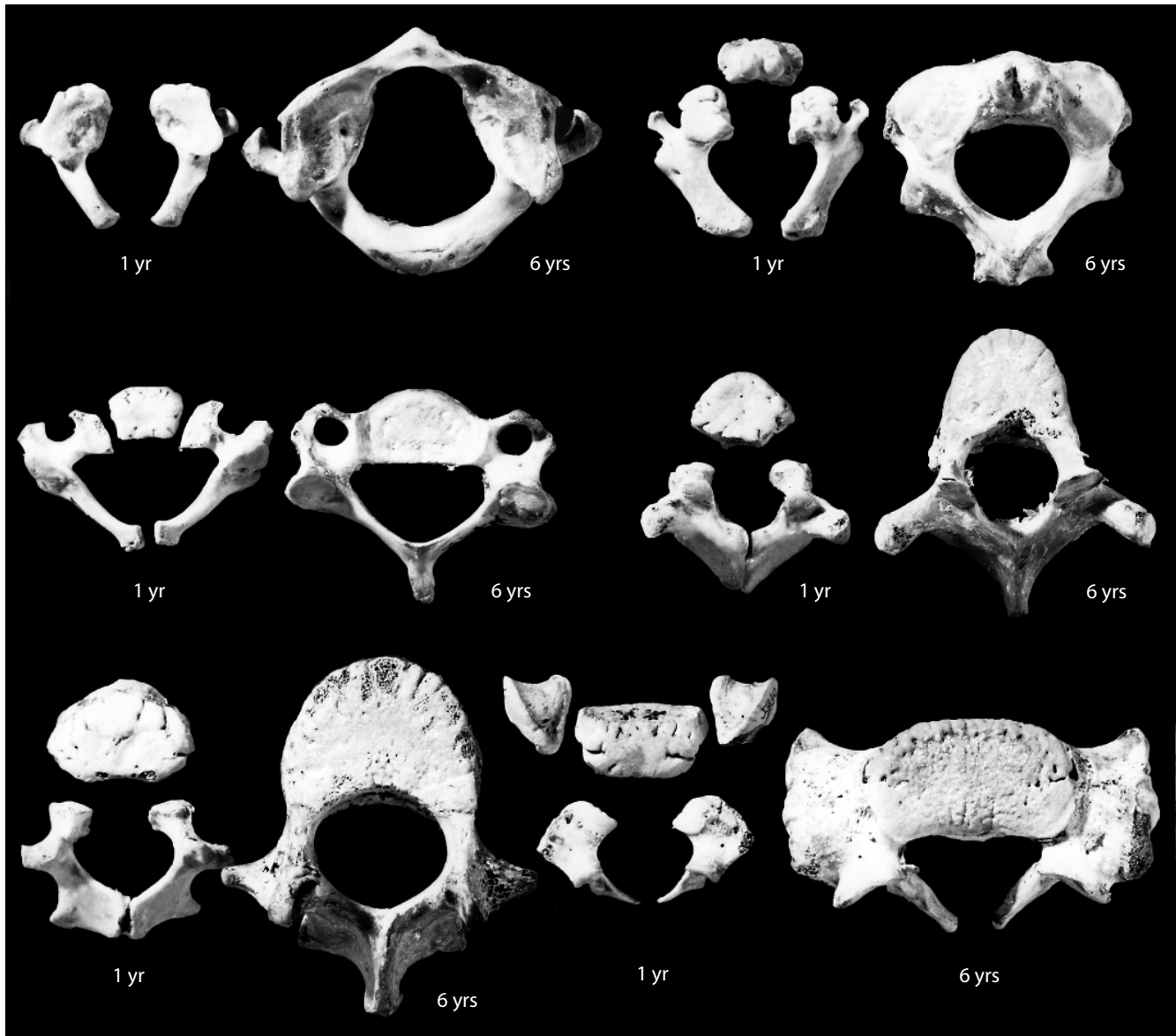


Figure 6.5 Vertebral growth. The pairs of immature vertebrae in superior view contrast a one-year-old with a six-year-old in each case. Top row: atlas (*left*), axis (*right*). Middle row: fifth cervical vertebra (*left*), fifth thoracic vertebra (*right*). Bottom row: second lumbar vertebra (*left*), first sacral vertebra (*right*). Anterior is up. Natural size.

6.2.2 Growth (Figure 6.5)

Most vertebrae ossify from three primary and five secondary centers. In immature vertebrae, the three primary centers are the centrum and the two halves of the vertebral arch (the body is composed of this centrum plus a small segment of each vertebral arch half). Secondary centers are found at the tips of each transverse process and of the spine. Flattened, ring-like apophyses surround the periphery of the superior and inferior surfaces of each body. The superior and inferior surfaces of immature vertebral bodies have a “billowed” appearance, with a thin bony ring instead of a round plate of bone (plates are found in many other mammals). This fuses to the body upon skeletal maturation.

6.3 Cervical Vertebrae ($n = 7$) (Figures 6.2 and 6.6)

Cervical vertebrae that share the characteristic cervical pattern are C-3 through C-6. We first describe this pattern and then assess the three remaining cervical vertebrae.

6.3.1 Anatomy and Identification

- a. The **bodies** of cervical vertebrae are smaller and thinner than those of thoracic or lumbar vertebrae.
- b. The **uncinate processes** on the lateral margins of the cervical bodies create bodies which have interlocking, saddle-shaped superior and inferior surfaces.
- c. The roughly triangular **vertebral foramina** of cervical vertebrae are large and wide relative to the size of the vertebral body.
- d. Cervical **transverse processes** are very small and gracile, and each is pierced by a **transverse foramen**. These foramina house the *vertebral arteries*, which pass upward to the posterior part of the brain.
- e. The lateral portion of the cervical transverse process is complex, consisting of:
 1. a **posterior tubercle of the transverse process**, the small bump which is the cervical homolog of the tubercle of a rib.
 2. an **anterior tubercle of the transverse process**, another small bump which is the cervical homolog of a rib head.
 3. the **intertubercular lamina**, a downward-directed arch between the two tubercles which is the cervical homolog of a rib neck.
- f. The **spinous processes** of cervical vertebrae project fairly horizontally behind the vertebral body (mostly posteriorly, partly inferiorly). They are usually bifurcated (bifid) from C-1 to C-5, and often asymmetrical at their posterior tips, shorter than thoracic spinous processes, and not as massive as lumbar spinous processes.
- g. The **superior and inferior articular facets** of cervical vertebrae are cup-shaped or planar. The superior and inferior facets are parallel; both pass from anterosuperior to posteroinferior. The inferior facet is situated more posterior to the vertebral body than the superior facet.

6.3.2 Special Cervical Vertebrae (Figures 6.6–6.7)

- The **atlas** (C-1) lies between the cranium and the axis. Superior articular facets of the atlas are concave and elongate and receive the condyles of the occipital bone. The atlas vertebra has no vertebral body, lacks a spinous process, and has no articular disks superior or inferior to it. On the posterior surface of the anterior bony rim of this vertebra (the anterior edge of the vertebral foramen) there is an oval articulation for the dens of the axis.
- The **axis** (C-2) also lacks a typical vertebral body but has a projecting process (the **dens**, or **odontoid process**) that forms a pivot for the atlas. Thus, when the head is nodded up and down, movement is mostly at the joint between the occipital condyle and C-1. When the head turns from side to side, the atlas rotates about the dens of the axis.
- The **seventh cervical vertebra** (C-7) is transitional between a typical cervical and a typical thoracic vertebra. Its vertebral body is the largest of the cervicals and has a flat inferior surface. Its spine most closely resembles a thoracic spine and is usually the uppermost vertebral spine palpable in the midline of the back in a living individual.

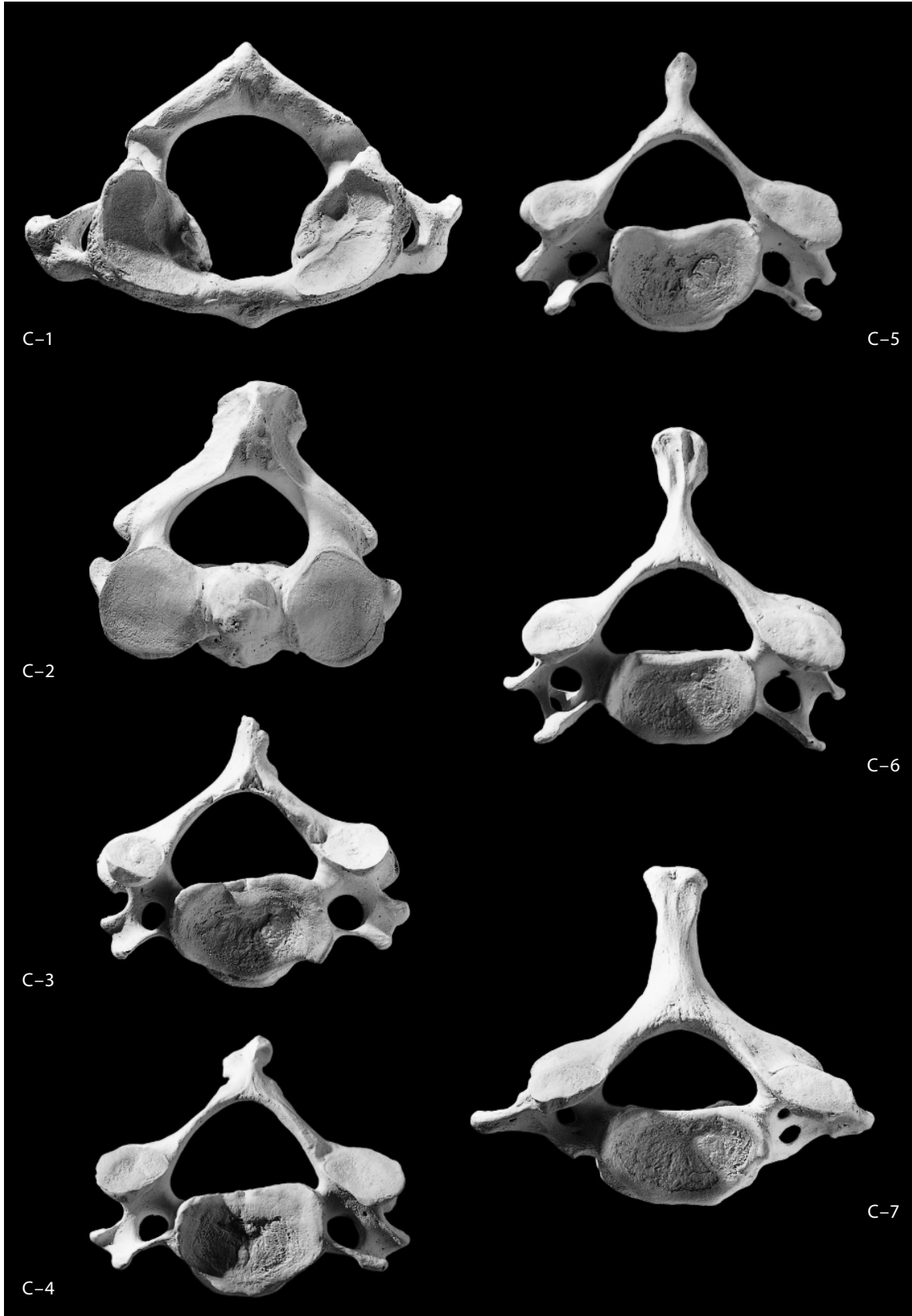


Figure 6.6 Cervical vertebrae, superior. Posterior is up. Natural size.

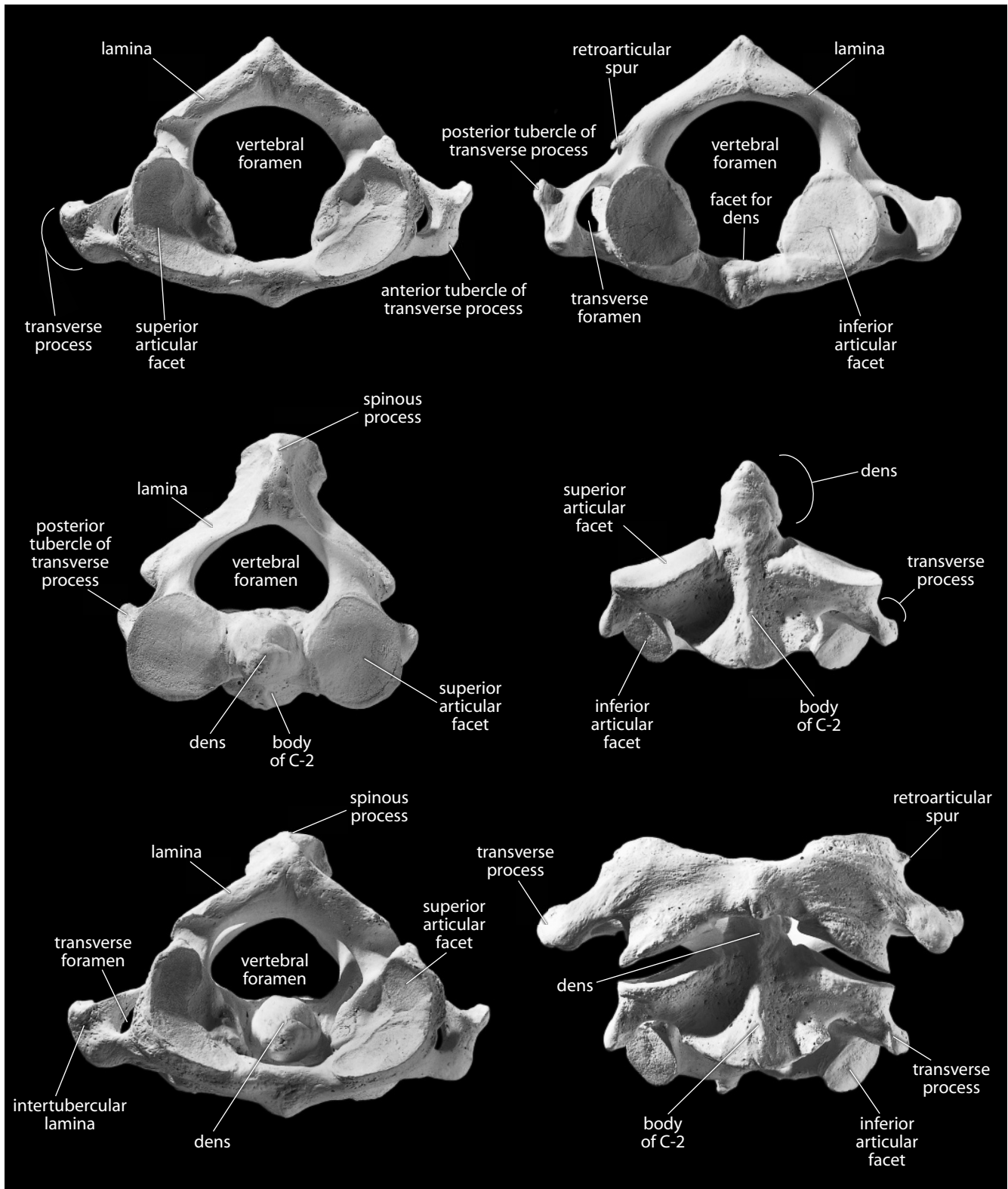


Figure 6.7 Atlas and axis vertebrae. *Top left:* atlas, superior view, posterior is up; *top right:* atlas, inferior view, posterior is up; *middle left:* axis, superior view, posterior is up; *middle right:* axis, anterior view, superior is up; *bottom left:* articulated atlas and axis, superior view, posterior is up; *bottom right:* articulated atlas and axis, anterior view, superior is up. Natural size.

6.3.3 Siding

- The long axis of the spinous process is directed posteroinferiorly.
- The superior articular facet faces posterosuperiorly, and the inferior one faces the opposite direction.
- The uncinata processes are superior and lateral.

6.4 Thoracic Vertebrae ($n = 12$) (Figures 6.3 and 6.8)

Thoracic vertebrae that share the characteristic thoracic pattern are T-2 through T-6. We first describe this pattern, then assess the four remaining thoracic vertebrae. Each thoracic vertebra articulates with a pair of ribs.

6.4.1 Anatomy and Identification

- a. The **bodies** of thoracic vertebrae are intermediate in size between cervical and lumbar vertebrae. Upper thoracic bodies are roughly triangular in superior outline, whereas lower thoracic vertebral bodies are more circular.
- b. Thoracic vertebrae bear **costal facets** (or **foveae**), articular surfaces for the ribs, on either the vertebral body, the transverse process, or both. **Transverse costal facets** are found on the anterior aspect of the lateral ends of transverse processes for T-1 through T-10. **Superior costal demifacets** are found at the superior margin of the posterior vertebral body on thoracic vertebrae T-2 through T-9. **Inferior costal demifacets** are found at the inferior margin of the posterior vertebral body on thoracic vertebrae T-1 through T-8. Complete **costal facets** are found on the posterior vertebral bodies of thoracic vertebrae T-1 and T-10 through T-12.
- c. The **vertebral foramina** of thoracic vertebrae are round or diamond-shaped, and are subequal to (T-1), or substantially smaller than (T-2 to T-10), the size of the vertebral body.
- d. The **transverse processes** of thoracic vertebrae are longer, larger, and more robust than those of cervical vertebrae, and do not possess transverse foramina. The angle of the transverse processes is nearly 180° at T-1 and gradually narrows to roughly 90° at T-11.
- e. The **aortic impression** is a variable flattening that may be found on the left side of the bodies of mid-thoracic vertebrae. The impression usually becomes gradually more ventral from superior to inferior. The impression marks where the largest artery in the body runs against the vertebral column.
- f. The **spinous processes** of thoracic vertebrae are longer and more slender than those of cervical or lumbar vertebrae, and each terminates in a distinct tubercle. From a lateral perspective, the spinous processes of the uppermost and lowermost thoracic vertebrae are closer to horizontal than the spinous processes of the middle thoracic vertebrae, which are much more inferiorly inclined.
- g. The **superior** and **inferior articular facets** of all thoracic vertebrae but T-12 are very flat (planar). Except for T-1 and T-12, the articular facets are set vertically, facing directly anteriorly (the inferior facet) or posteriorly (the superior facet).
- h. The superior and inferior surfaces of the **pedicle** have **superior** and **inferior intervertebral notches** for the *spinal nerves* that emerge from the *spinal cord* to innervate corresponding body segments. These nerves pass through the gaps formed by adjacent articulating notches, the **intervertebral foramina**.

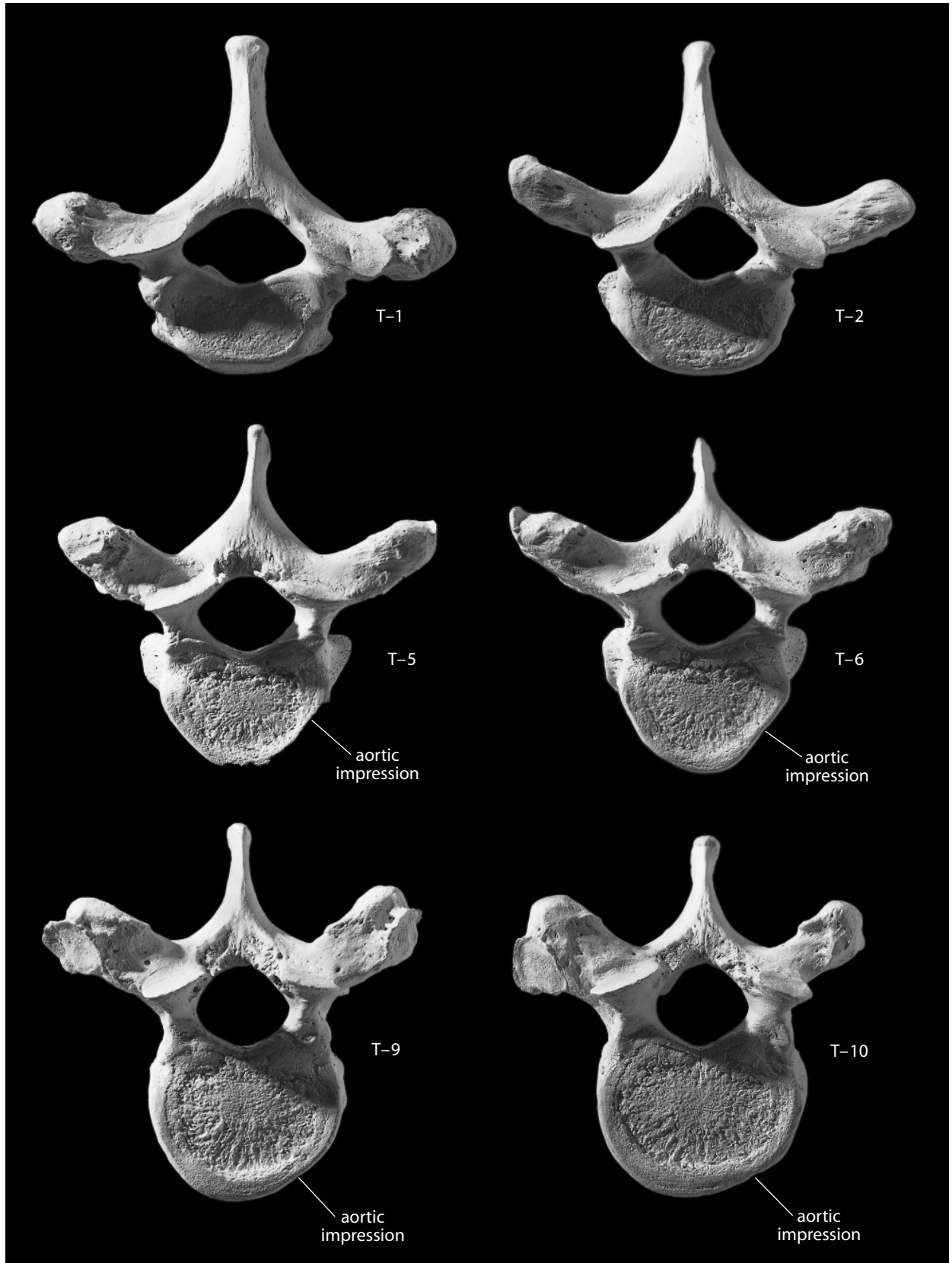
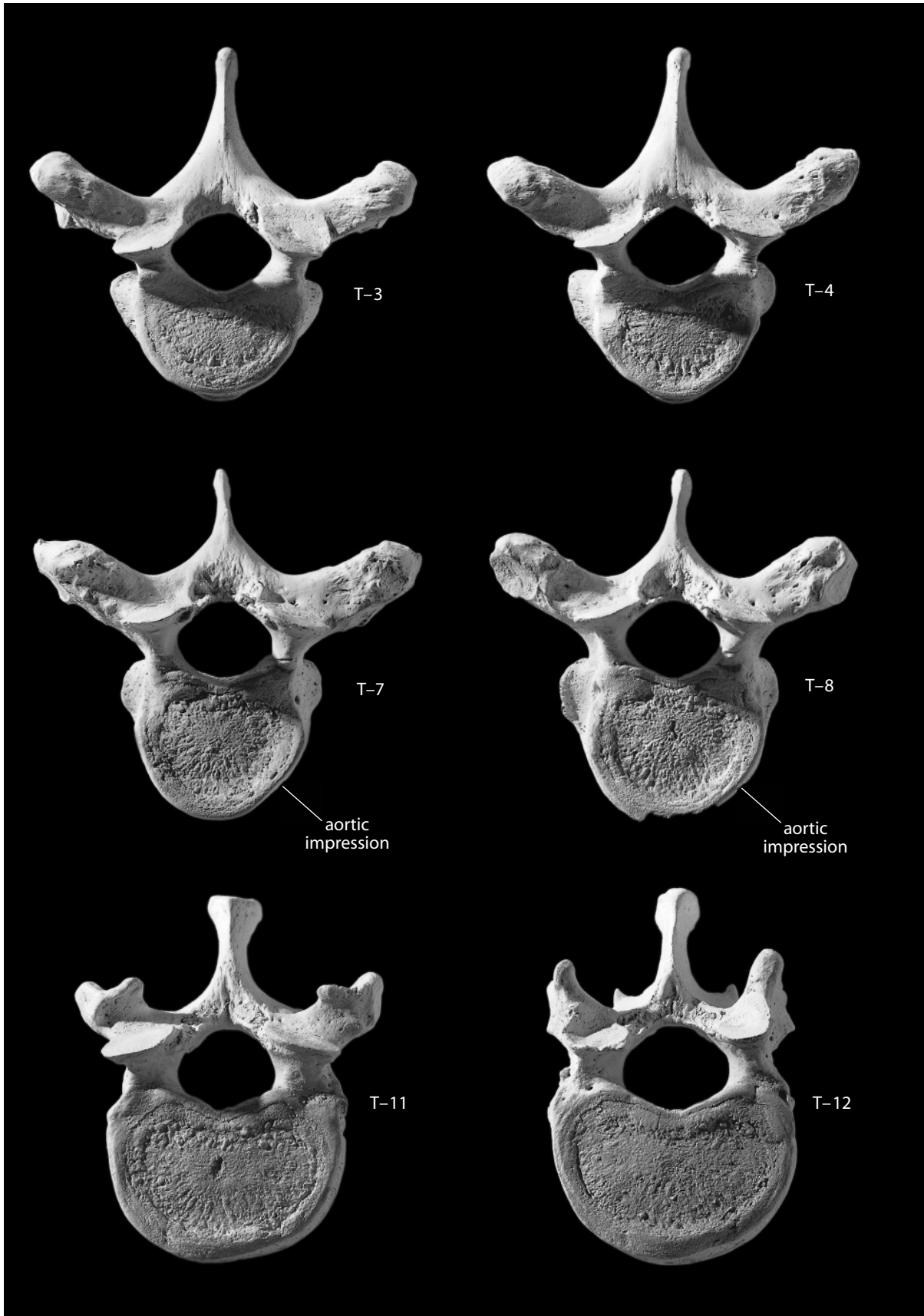


Figure 6.8 Thoracic vertebrae, superior. (*above and opposite*) Posterior is up. Natural size.



6.4.2 Special Thoracic Vertebrae (Figure 6.9)

- The **first thoracic vertebra** (T-1) has a whole costal facet superiorly and a half costal facet inferiorly. It retains more cervical-like characteristics of its spine and body than any other thoracic vertebra.
- The **tenth thoracic vertebra** (T-10) usually has a complete, superiorly placed costal facet on each side of the vertebral body and costal articulations on the transverse processes.
- The **eleventh thoracic vertebra** (T-11) has an intact, superiorly placed costal facet on each side of the vertebral body, but no costal articulation on the transverse processes.
- The **twelfth thoracic vertebra** (T-12) resembles T-11, but the inferior articular facets assume the lumbar pattern.

6.4.3 Siding

- The long axis of the spinous process is posterior and is angled sharply inferiorly, particularly in the mid-thoracic region.
- The superior articular facet faces posteriorly, and the inferior one faces anteriorly.
- The costal articulation on the transverse processes faces anterolaterally.
- In lateral aspect the inferior articular facets are separated from the rear half of the vertebral body by a considerable gap (the inferior intervertebral notch).
- The inferior dimensions of the body are greater than its superior dimensions.

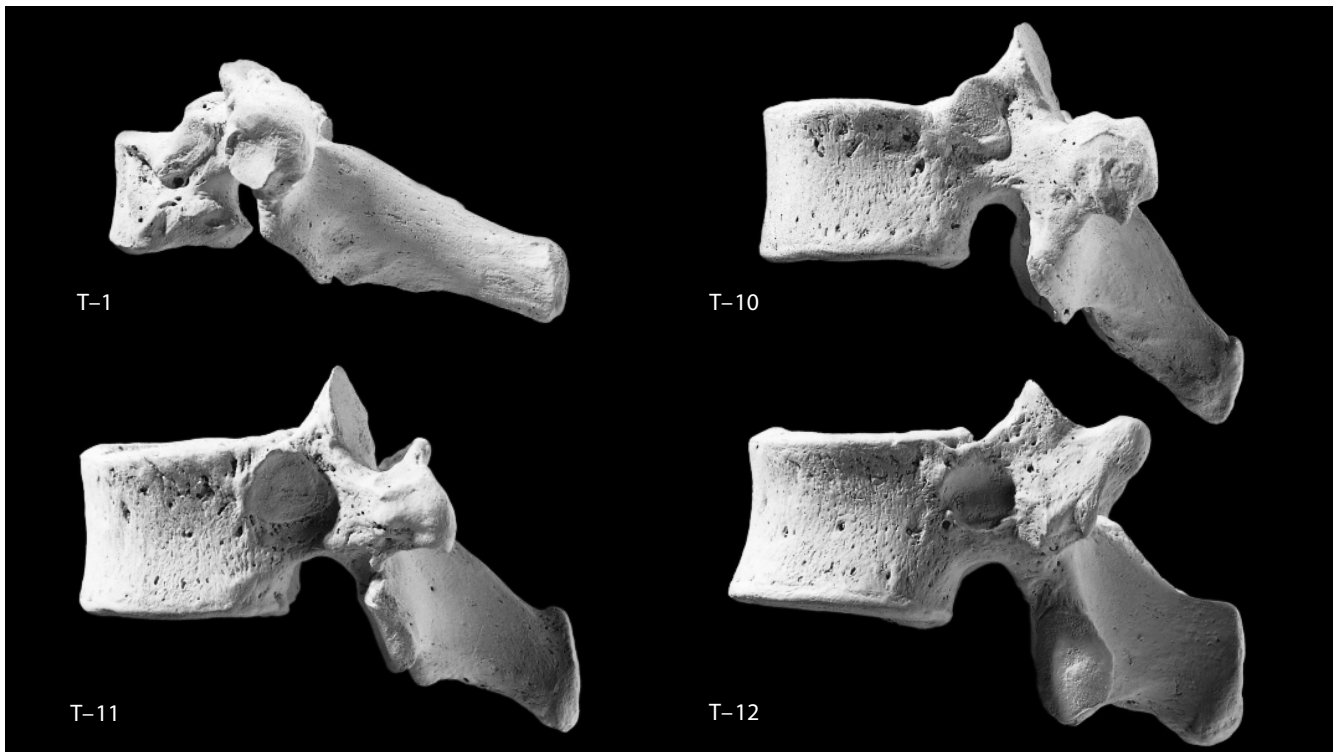


Figure 6.9 Special thoracic vertebrae, lateral. Superior is up. *Top left:* first thoracic vertebra; *top right:* tenth thoracic vertebra; *bottom left:* eleventh thoracic vertebra; *bottom right:* twelfth thoracic vertebra. Natural size.

6.5 Lumbar Vertebrae ($n = 5$) (Figures 6.4, 6.10, and 6.11)

It is comparatively easy to identify individual positions of isolated lumbar vertebrae. Like the thoracic and cervical vertebrae, the lumbar vertebrae increase progressively in size from superior to inferior (L-1 to L-5). Lumbar vertebrae are the largest of all the unfused vertebrae. Note that the individual illustrated in this manual has a sacralized L-5 with a pair of extra sacral articular surfaces.

6.5.1 Anatomy and Identification

- a. The **bodies** of lumbar vertebrae are larger than those of cervical or thoracic vertebrae. Lumbar bodies lack costal pits and transverse foramina. The superior outlines of lumbar bodies are ovoid, although L-1 and L-2 may be somewhat kidney-shaped.
- b. The **vertebral foramina** of lumbar vertebrae are triangular in outline, and are very small relative to the size of the vertebral bodies.
- c. The **spinous processes** of lumbar vertebrae are hatchet-shaped, large, blunt, and more horizontally oriented than other vertebral spinous processes (they are orthogonal to the coronal plane).
- d. The **transverse processes** of lumbar vertebrae are relatively smaller and thinner than thoracic transverse processes and they lack any articular surfaces. They are rudimentary or absent on L-1 and increase in size and projection inferiorly.
- e. The **superior** and **inferior articular facets** are not parallel in lumbar vertebrae; instead, the superior articular facets are concave (cupped) and face posteromedially. The inferior articular facets are convex and face anterolaterally.
- f. The **mammillary process** is a somewhat elongated tubercle that originates from the posterolateral margin of the superior articular process.
- g. The **accessory process** is a variable, diminutive tubercle on the dorsal aspect of the base of the lumbar transverse process.

6.5.2 Identifying Lumbar Position

The L-1 is the smallest of the series. When viewing the posterior surface of a lumbar vertebra (Figure 6.11), imagine a quadrangle connecting the centers of four superior and inferior articular facets. In L-1 and L-2, this outline is a vertically elongate rectangle. In L-3 and L-4 the outline resembles a square. In L-5 the outline is a horizontally elongate rectangle.

6.5.3 Siding

- The long axis of each transverse process passes from the vertebral body and lamina superolaterally.
- The superior articular facets are concave and face posteromedially, whereas the inferior facets are convex and face anterolaterally.
- Note the large gap (the inferior intervertebral notch) between the inferior articular facets and the posterior surface of the vertebral body in lateral aspect. The arch originates from the superior half of the vertebral body.

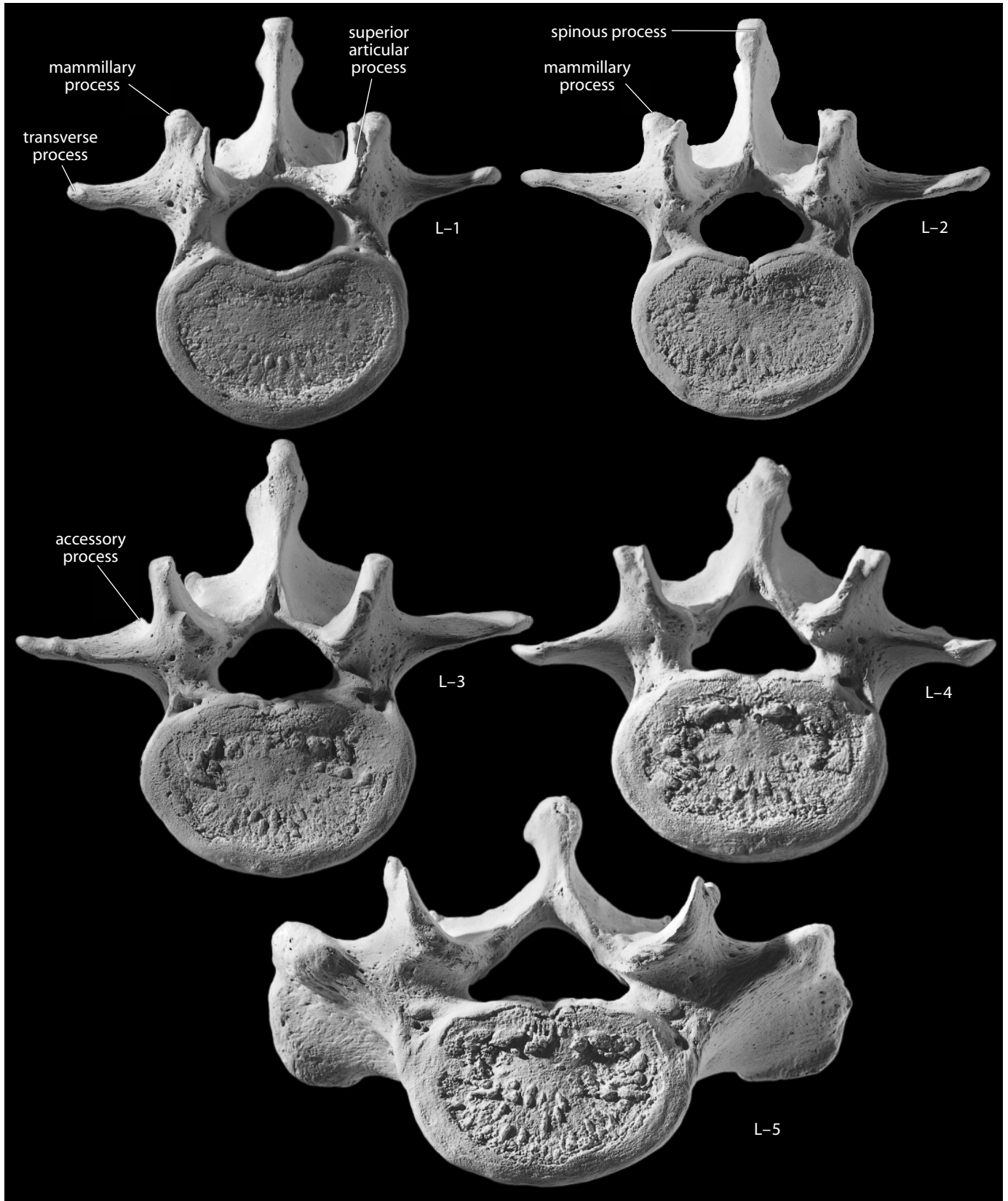


Figure 6.10 Lumbar vertebrae, superior. Posterior is up. Note that the L-5 of this individual is “sacralized” and articulates in five places with the sacrum. Natural size.

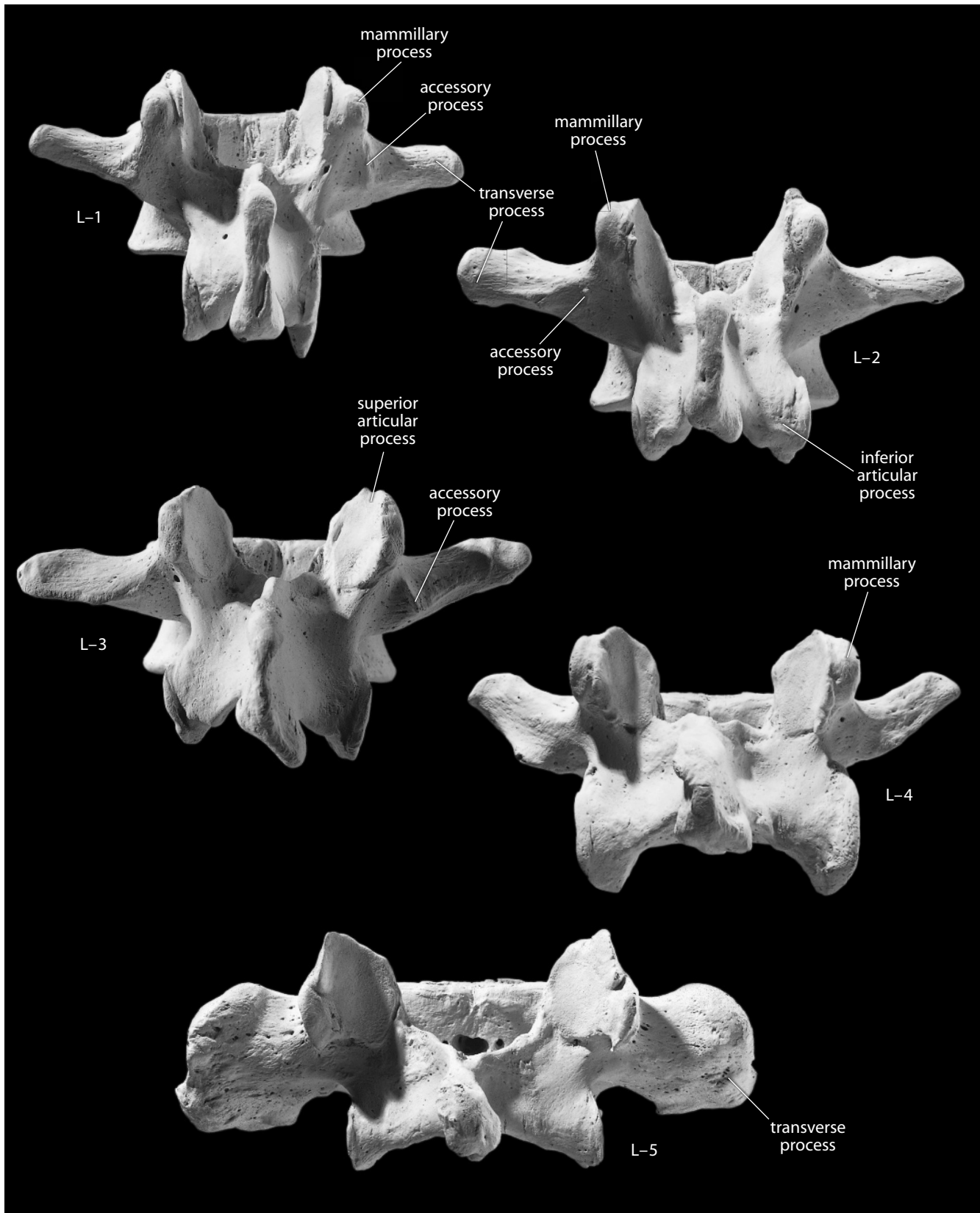


Figure 6.11 Lumbar vertebrae, posterior. Viewing the bones in this aspect allows their individual identification. Superior is up. Natural size.

6.6 Vertebral Measurements (Figure 6.12)

Measurements of the vertebrae are used for body mass estimation, stature reconstruction, posture reconstruction, locomotor analyses, and other analyses.

1. **Spinous process length** (O'Higgins et al., 1997: 107): Place the stationary end of the sliding caliper at the posteriormost point of the superior border of the vertebral canal at midline and, keeping the caliper parallel to the long axis of the spinous process, measure the distance to the distalmost tip of the spinous process.
2. **Spinous process angle** (Latimer and Ward, 1993: 287): Rest one arm of a goniometer on the midline of the cranial end of the body, and adjust the other arm so that it is parallel to the cranial edge of the spinous process.
3. **Ventral height of the body** (Martin, 1928: 998, #1): With a sliding caliper, measure the craniocaudal dimension of the ventral border of the body at midline.
4. **Superior dorsoventral body diameter** (Martin, 1928: 999, #4): With a sliding caliper, measure the maximum anteroposterior dimension of the superior surface of the vertebral body, including the annular rings. While the ventral point is taken at midline, the dorsal point is extended by the right and left projections of the vertebral disk surface.
5. **Superior transverse body diameter** (Martin, 1928: 999, #7): With a sliding caliper, measure the maximum transverse dimension of the superior surface of the vertebral body, including the annular rings.
6. **Vertebral canal length** (Martin, 1928: 1000, #10): With a sliding caliper, measure the maximum dorsoventral diameter of the cranial end of the vertebral canal.
7. **Vertebral canal breadth** (Martin, 1928: 1000, #11): With a sliding caliper, measure the maximum mediolateral diameter of the cranial end of the vertebral canal.
8. **Vertebral canal index** (Martin, 1928: 1000; Trinkaus and Svoboda, 2006: 292): $(\text{vertebral canal length} \div \text{vertebral canal breadth}) \times 100$.

6.7 Vertebral Nonmetric Traits

- **Shifts in vertebral numbers:** In some cases, the last vertebra of one region will mirror the morphology of the next caudalmost region (called a “caudal shift”), or the first vertebra of one region will mirror the morphology of the next cranialmost region (called a “cranial shift”). Such variation is much more common in the sacral and lumbar regions.
- **Retroarticular bridge or spur:** A bridge or spur is sometimes found on the atlas between the posterior transverse process and the vertebral arch immediately posterior to the superior articular (condylar) facet. The atlas illustrated in this book has a retroarticular spur on its right side (Figure 6.7).
- **Accessory transverse foramen in C-3 to C-6:** The transverse foramen is sometimes divided more cranially than C-7. The individual used to illustrate this book has a right accessory foramen at the level of C-6 (Figure 6.6).
- **Cervical rib:** In early tetrapods, each vertebra was associated with a pair of ribs, but in later mammals (including humans), only the thoracic vertebrae are associated with independent ribs. These cervical and lumbar ribs were not simply lost; they became reduced in size and were incorporated into the transverse processes of these vertebrae. Occasionally, however, a cervical rib will form and articulate with C-7. Such cervical ribs are highly variable; they may be very short, or they may extend all the way to the first costal cartilage.

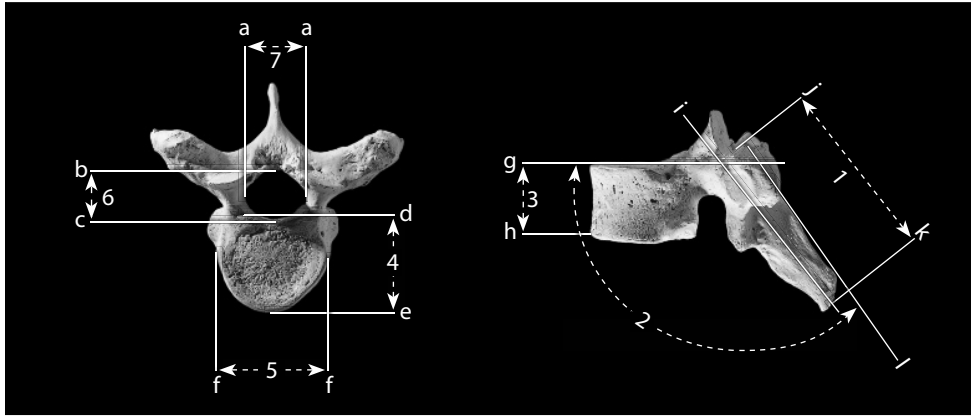


Figure 6.12 Vertebral measurements. One-half natural size.

Locations: a) lateralmost point of vertebral canal; b) dorsalmost point of vertebral canal; c) ventralmost point of vertebral canal; d) dorsalmost point(s) of superior vertebral body; e) ventralmost midline point of superior vertebral body; f) lateralmost point of superior vertebral body; g) line defined by the cranialmost midline points of the vertebral body; h) caudalmost ventral midline point of vertebral body; i) long axis of the spinous process; j) posteriormost point of the superior border of the vertebral canal; k) dorsalmost point on spinous process; l) line defined by the craniodorsalmost points of the spinous process.

Measurements: 1) spinous process length; 2) spinous process angle; 3) ventral height of the body; 4) superior dorsoventral body diameter; 5) superior transverse body diameter; 6) vertebral canal length; 7) vertebral canal breadth.

6.8 Functional Aspects of the Vertebrae

Compared to many other animals, humans have a specialized head, large limbs, and a relatively short vertebral column. Different portions of the column perform independent functions, and the shapes of the individual vertebrae are therefore different. The vertebral column can be divided into five regions: cervical, thoracic, lumbar, sacral, and coccygeal. The thoracic segment is concave anteriorly. The sacral and coccygeal segments are described in Chapter 11 on the pelvic girdle. Both the cervical and lumbar segments of the vertebral column are concave dorsally, permitting habitually erect posture. Most vertebrae share basic parts: arch, body, articular processes, transverse processes, and spinous processes. This correspondence of parts in sequential bones is called **serial homology**.

The different shapes of the different parts of each vertebra correspond to the functions they perform in different parts of the vertebral column. The most flexible part of the column is the neck, where cervical bodies are small, intervertebral disks are thick, and vertebral foramina are large, permitting much freedom of movement. Thoracic disks are much thinner, and the superior and inferior articular facets of these vertebrae are parallel. The lumbar region is second to the cervical in mobility, with thick disks and articular facets that are cup-shaped. Both thoracic and lumbar vertebrae allow anteroposterior bending of the column, but this movement is more restricted in the thoracic region. Medial and lateral bending of the column is also restricted in the thoracic region, but thoracic vertebrae allow for medial and lateral rotation (axial twisting of the column), which is limited in the lumbar region.

This page intentionally left blank

Chapter 7

THORAX: STERNUM AND RIBS

IN PRIMITIVE, AIR-BREATHING FISHES, breathing was accomplished by swallowing movements in which air was gulped into the lungs. Early reptiles improved on this system when they evolved a means to respire via the musculoskeletal mechanics of the thoracic skeleton. This was made possible as the thoracic ribs extended ventrally from the vertebral column to reach the sternum. The sternum formed a kind of ventral bony column that fused into a bony bar and anchored the distal ends of the ribs. Further soft tissue specializations led to more sophisticated breathing functions.

The skeleton of the human thorax, or chest, is like a basket or cage composed of cartilage and bone. It is attached dorsally to the vertebral column. This structure encloses and protects the principal organs of circulation and respiration, the heart and lungs, and is the base to which the upper limbs are attached. The major bones forming the thorax are the sternum and the 12 ribs on each side. The upper seven ribs on each side connect, via cartilage, directly with the sternum and are sometimes called “true,” or “sternal,” ribs. Ribs 8–10 attach to the sternum indirectly, also via cartilage, and are sometimes called “false,” or “asternal,” ribs. The last two ribs (“floating” ribs) have short cartilaginous ends that lie free in the sides of the body wall.

7.1 Sternum (Figures 7.1–7.2)

7.1.1 Anatomy

The sternum, or breastbone, functions at its upper end to connect the shoulder girdle (clavicle and scapula) to the thorax. In addition, it anchors the anterior ends of paired ribs 1–7 via cartilage. The bone is composed of three main parts in adulthood but develops from six segments (**sternebrae**). The segment joints may all fuse in adulthood, but their location is indicated by costal notches along each side of the sternum.

- The **manubrium** is the most massive, thickest, and squarest of three main sternal elements. It is the superiormost element of the sternum and is the widest part of this bone.
- Clavicular notches** occupy the superior corners of the sternum. It is here that the manubrium articulates with the right and left clavicles.
- The **jugular (or suprasternal) notch** is the midline notch on the superior border of the manubrium.

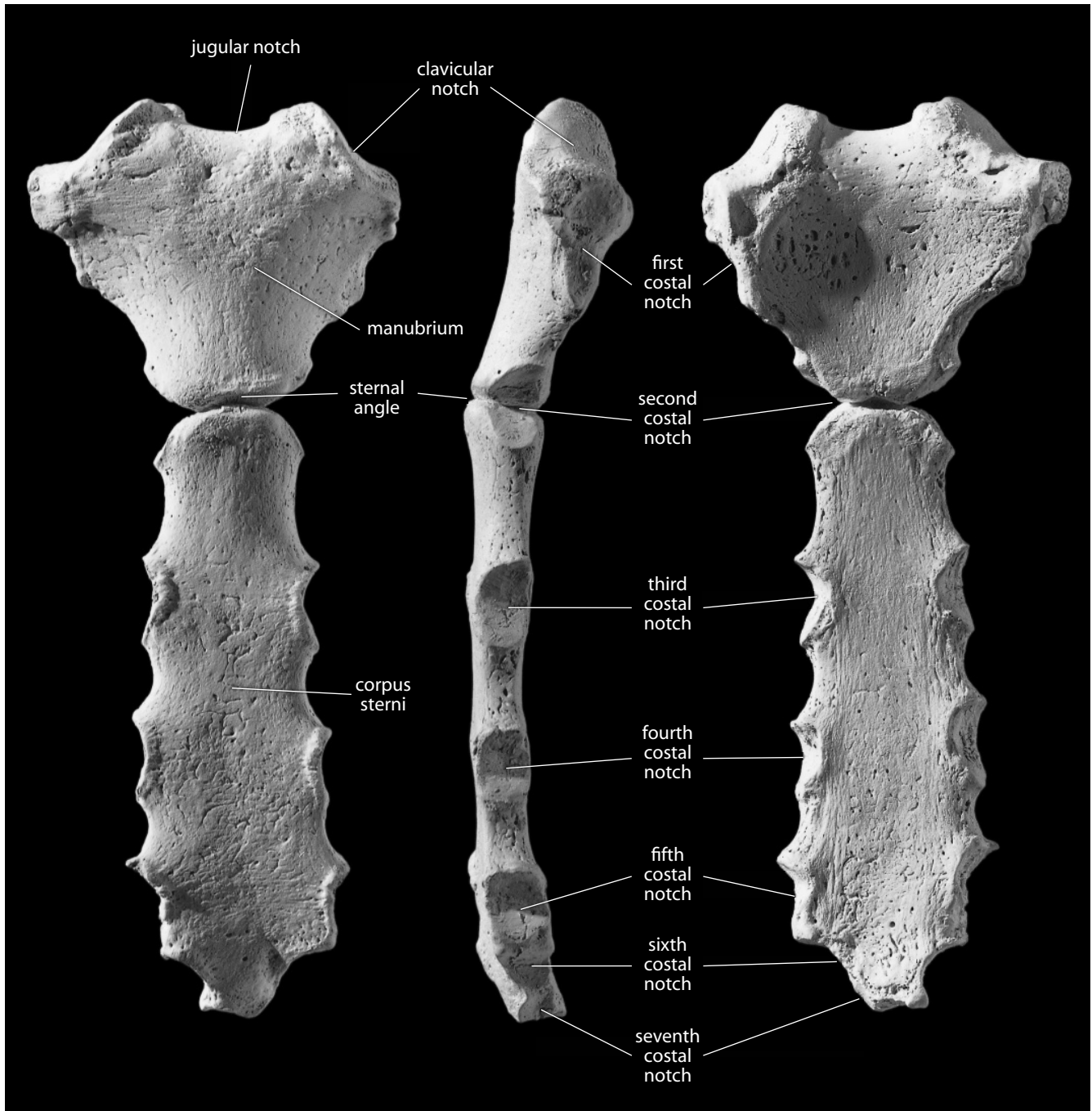


Figure 7.1 **Sternum.** *Left:* anterior view; *center:* left lateral view; *right:* posterior view. The xiphoid process on this sternum had not ossified and is not shown. Superior is up. Natural size.

- d. **Costal notches** occupy both sides of the manubrium inferior to the clavicular notches. These notches represent articulations with the costal cartilages of the first ribs. The manubrium shares articulation for the second ribs with the corpus sterni.
- e. The **corpus sterni** (or **mesosternum**) is the central part, the body, or blade, of the sternum. It is formed during ontogeny from the fusion of sternal segments (sternebrae) 2–5. The corpus sterni may fuse, partially fuse, or remain unfused with the manubrium in adulthood.
- f. The **sternal angle** (or **manubriosternal joint**) is the angle formed (viewed laterally) between the fused manubrium and the corpus sterni.
- g. The **costal notches** along either side of the corpus sterni are for articulation with the costal cartilages of ribs 2–7.
- h. **Lines of fusion** are often apparent between the sternebrae. These lines pass horizontally through the right and left costal notches for ribs 3–5.
- i. The **xiphoid process** is the variably ossified inferior tip of the sternum. It often fuses with the corpus sterni in older adults. It shares the seventh costal notch with the body. This process can be partially ossified and may ossify into bizarre asymmetrical shapes with odd perforations. In short, the xiphoid is a highly variable element. The xiphoid process of the individual chosen to illustrate this text, for example, was not ossified at the time of death.

7.1.2 Growth

The four superior centers of ossification (manubrium and corpus sterni segments 2–4) appear in fetal life. The timing of fusion between sternal segments is often irregular, but fusion between the lower two centers in the corpus sterni (segments 4 and 5) occurs soon after puberty. Fusion occurs between segments 2, 3, and 4 by early adulthood. As mentioned earlier, the manubrium and corpus sterni sometimes fail to unite, even in adulthood.

7.1.3 Possible Confusion

Fragments of the sternum might be mistaken for fragments of pelvis or immature vertebrae.

- The costal and clavicular notches, and the lines of fusion between sternal segments, should be sufficient to ensure correct identification.
- The sternum is a bone with very low density. Its cortex is paper-thin, perforated by numerous microforamina. This makes even fragmentary sterna easy to sort from other elements, such as the pelvis.
- Infant sternebrae are often confused with vertebral centra. Infant centra have rougher, less mature (*i.e.*, more billowed, granular) cortical surfaces.

7.1.4 Siding

- Fragments of manubrium and corpus sterni can be sided by noting that the anterior surface of this bone is rougher and more convex than the smooth, gently concave posterior surface.
- The lines of fusion pass horizontally, and the mediolaterally widest point on the corpus sterni is at the third segment inferior to the manubrium.

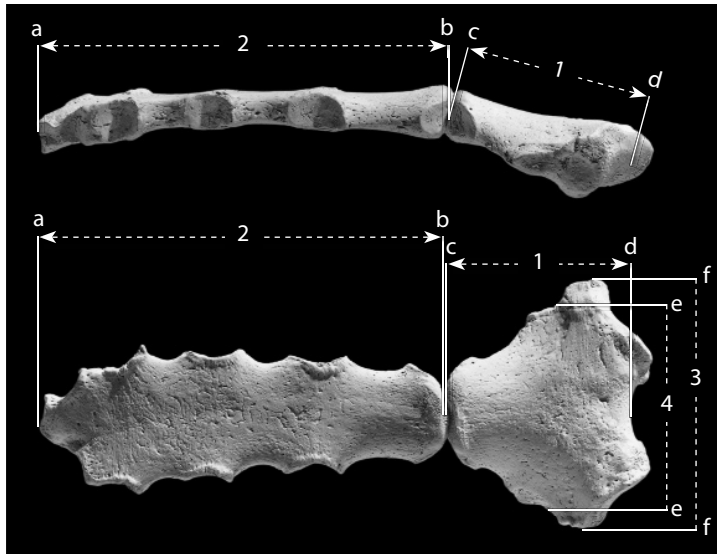


Figure 7.2 Sternal measurements. One-half natural size.

Locations: a) center of inferior articular facet of corpus sterni; b) center of superior articular facet of corpus sterni; c) center of inferior articular facet of manubrium; d) inferiormost point of jugular notch; e) centerpoint of first costal notch; f) lateralmost point on manubrium.

Measurements: 1) manubrial length; 2) length of the corpus sterni; 3) maximum manubrial breadth; 4) manubrial breadth.

7.1.5 Sternal Measurements (Figure 7.2)

Measurements of the sternum are infrequently taken or used in formulas, but are indicators of sexual dimorphism and have been used in formulaic determinations of sex.

1. **Manubrial length** (Martin, 1928: 1004, #2): Place the tip of the stationary jaw of the sliding caliper into the deepest (most inferior) point of the jugular notch and measure the distance to the inferiormost point on the inferior articular facet of the manubrium.
2. **Length of the corpus sterni** (Martin, 1928: 1004, #3): With a sliding caliper, measure the superoinferior distance from the center of the superior (manubrial) articular facet to the center of the inferior (xiphoid) articular facet.
3. **Maximum manubrial breadth** (Martin, 1928: 1004, #4): With a sliding caliper, measure the greatest breadth of the manubrium.
4. **Manubrial breadth** (Bass, 1995): With a sliding caliper, measure the distance between the centers of the first costal notches.

7.1.6 Sternal Nonmetric Traits

- The **sternal foramen** perforates the sternal body in about 7% of adult corpora sternorum (Cooper et al., 1988). Sometimes referred to as a 'perforated sternum,' the sternal foramen results from an incomplete midline fusion of the lower 2–3 sternebrae, which commonly ossify from bilateral centers, rather than from a single midline center as with the superior sternebrae.
- The fusion (synostosis) of the manubriosternal joint (between manubrium and corpus sterni) occurs in about 20% of adults (Yekeler et al., 2006). Fusion can be of two types: 1) matrical synostosis, due to a developmental anomaly resulting in an absence of a fibrocartilaginous barrier between elements, or 2) sclerotic synostosis, due to age-related degeneration of the fibrocartilaginous pad in the joint. The latter type is predominantly found in older females (Scheuer and Black, 2000).
- In about 30% of adults, the xiphoid process has at least one foramen (Yekeler et al., 2006).

7.2 Ribs (Figures 7.3–7.6)

7.2.1 Anatomy

There are usually 12 ribs on each side of the thorax, for a total of 24 in the adult male and female human body. The number of ribs is variable; there may be 11 or 13 ribs on a side, with supernumerary ribs in either the cervical or lumbar segment (Black and Scheuer, 1997). The upper seven ribs (numbers 1–7) articulate directly with the sides of the sternum via the costal cartilages and are called sternal or “**true ribs**.” Ribs 8, 9, and 10 are interconnected medially by common cartilages that attach to the sternum. Because they lack a direct sternal connection, these ribs are called asternal or “**false ribs**.” The last two ribs, 11 and 12, have free-floating distal ends, and are referred to as “**floating ribs**.” All ribs articulate via their proximal ends with thoracic vertebrae. The ribs usually increase in length from rib 1 to rib 7, and decrease from rib 7 to rib 12. Concern with the use of the sternal rib end to estimate adult age at death (Chapter 19) has led several investigators to refine methods of siding and sequencing human ribs (Mann, 1993; Hoppa and Saunders, 1998). These apply to ribs known to be from a single individual.

- a. The **head** of a rib is the swollen proximal part of the rib. It bears two articular surfaces (**demifacets**) for contact with the bodies of successive thoracic vertebrae. The first rib and ribs 10–12 are uniaxial.
- b. The **crest of the rib head** marks the separation between the two demifacets.
- c. The **neck** of a rib is the short segment between the head and the rib’s articulation with the transverse process of the thoracic vertebra.
- d. The **crest of the rib neck** runs between the head and tubercle.
- e. The **tubercle** is located on the posteroinferior corner of each rib. It articulates with the transverse process of the thoracic vertebra, presenting a medial **articular facet** for articulation with the transverse process of the thoracic vertebra, and a nonarticular portion for ligamentous attachment.
- f. The **angle** (or **costal angle**) is the sharp curve in the bone lateral to the tubercle. It is marked by a prominent line on the external surface of the shaft immediately distal (lateral) to the tubercle. This line marks the attachment of the deep muscles of the back. It also marks the shift from the caudally facing external rib surface to the more cranially oriented external surface. The tubercle-to-angle distance increases from rib 4 to rib 11.
- g. The **shaft** of a rib is the curved, tapering segment between the tubercle and the rib’s distal (ventral, anterior) end. Shafts of ribs 3–6 are thicker and rounded in section compared to those of ribs 7–12.
- h. The **costal groove** of a rib is the groove along the medial side of the inferior edge of the rib shaft. In life this groove houses an *intercostal artery, vein, and nerve*. It is most prominent on ribs 5–7.
- i. The **sternal end** of a rib is the anterior (ventral) end of the shaft. This end is a roughened, porous, cupped oval surface for the attachment of cartilage. Its surface changes substantially with increasing age. The sternal ends of ribs 11 and 12 taper to a point. The sternal ends of ribs 1–10 end in a **pit** where they meet the costal cartilage.
- j. The **cranial** (or **upper**) **edge** of most ribs is blunt, smooth, and convex.
- k. The **caudal** (or **lower**) **edge** of most ribs is sharp, with a costal groove on the medial surface. This groove gives a concave appearance to the surface of the rib that faces the body cavity.

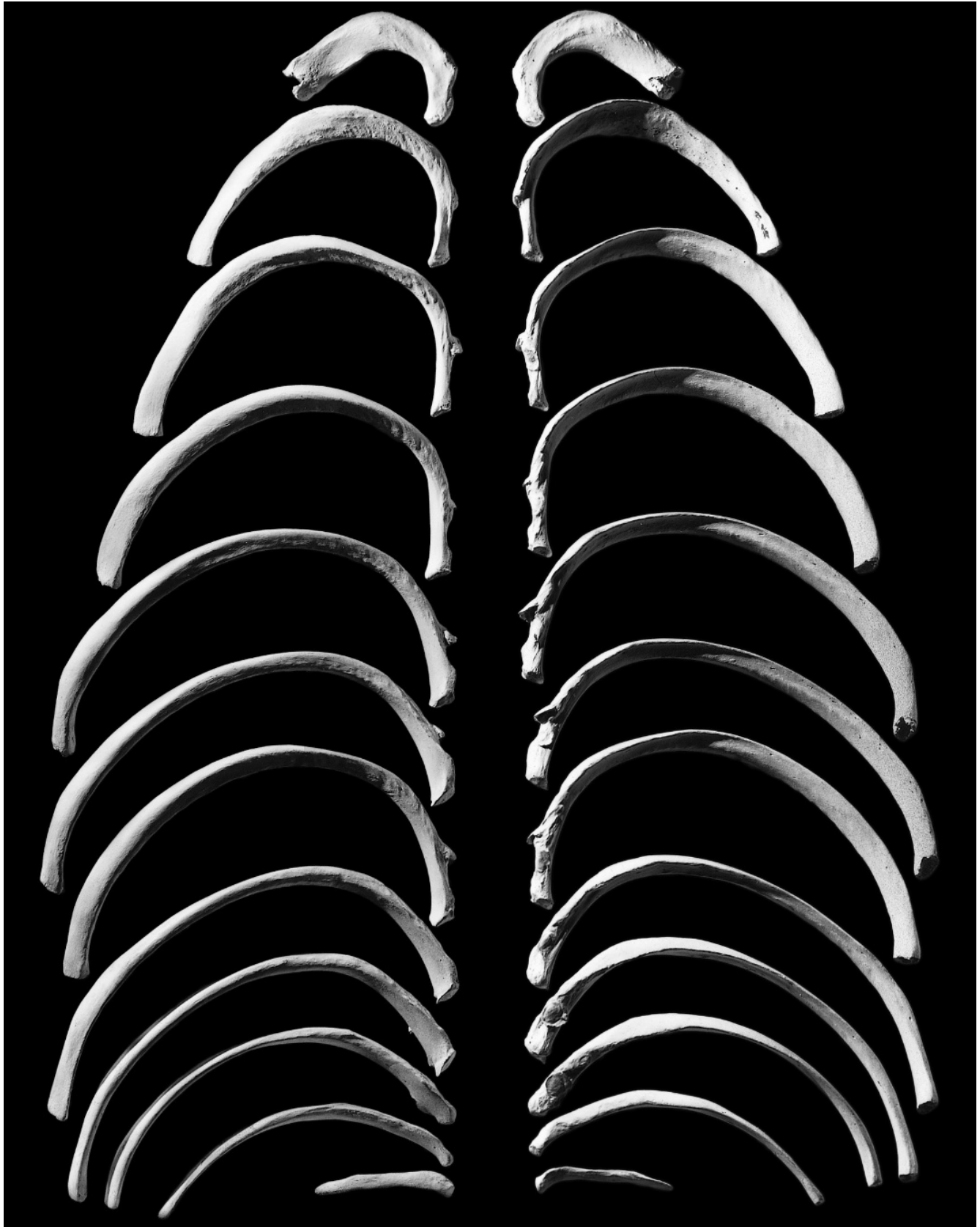


Figure 7.3 Right ribs. *Left*: superior view; *right*: inferior view. One-third natural size.

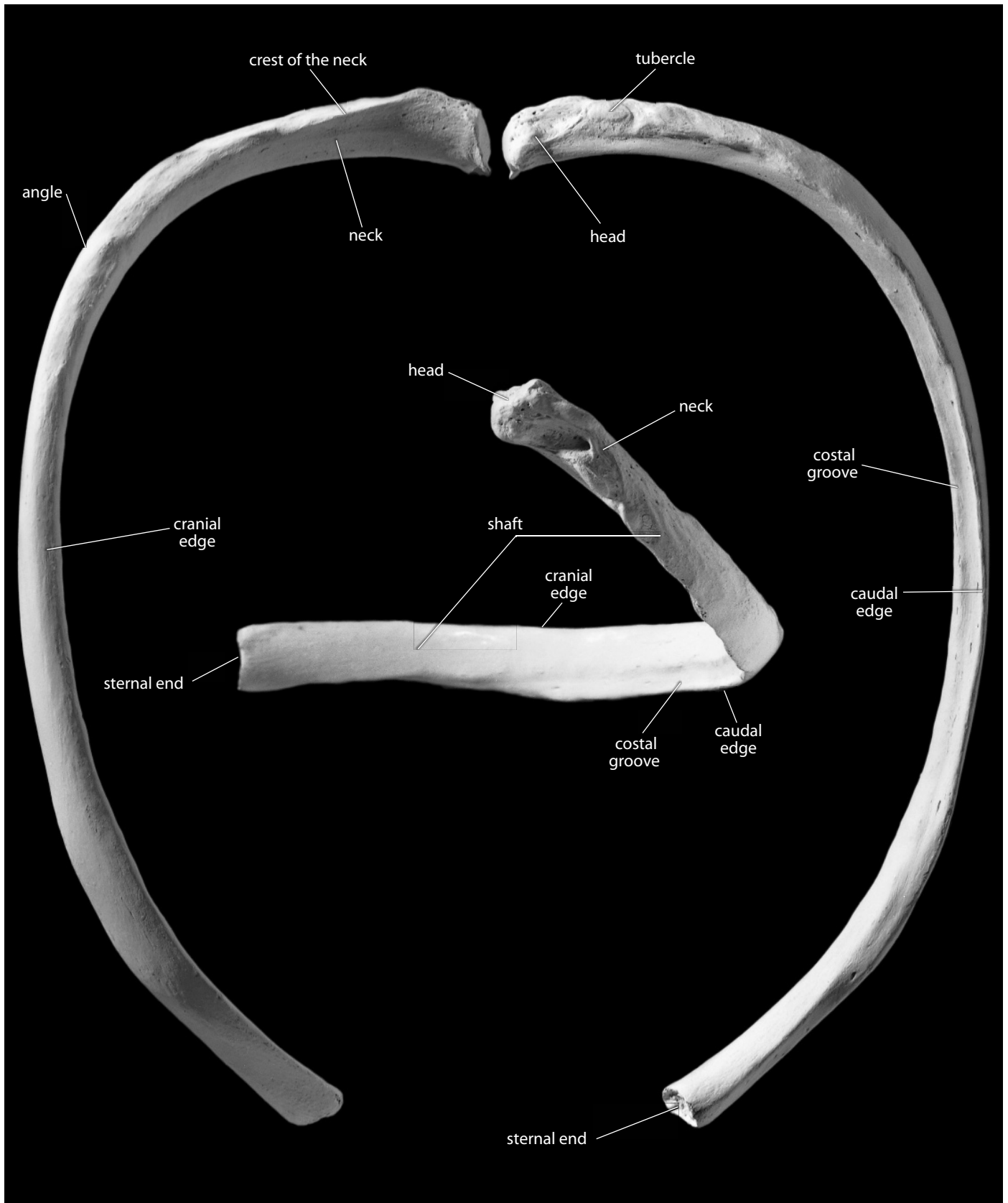


Figure 7.4 Right eighth rib, a “typical” rib. *Left:* superior view; *right:* inferior view; *inset:* posteroinferior view. Natural size.

7.2.2 Special Ribs (Figure 7.5)

- The first rib is the most unusual and therefore most easily diagnosed rib. It is a broad, superoinferiorly flattened, short, tightly curved bone with only one articular facet on its small rounded head. Its superior (cranial) surface is roughened by muscle attachments. This surface also bears two shallow grooves: the anterior one for the *subclavian vein* and the other for the *subclavian artery* and *inferior trunk of the brachial plexus* (medial) (Figure 7.5). The ridge between these grooves is prolonged ventrally into the scalene tubercle for the attachment of the *anterior scalene muscle*. There is no true inferior costal groove.
- The second rib is intermediate between the unusual first rib and the more typical ribs 3–9. It has a large tuberosity for the *serratus anterior muscle* near the external (cranial), midshaft position (Figure 7.5).
- The tenth rib is like ribs 3–9 but usually has only a single articular facet on the head.
- The eleventh rib has a single articular facet on the head and lacks a tubercle. Its sternal end is narrow and often pointed. Its shaft has a slight angle and a shallow costal groove.
- The twelfth rib is shorter than the eleventh and may even be shorter than the first. This rib is similar to the eleventh in morphology and also lacks the angle and the costal groove.

7.2.3 Growth

Ribs, except for the eleventh and twelfth, ossify from four centers. Epiphyses for the head and for the articular and nonarticular parts of the tubercle appear in the teens. They fuse to the rib body in early adulthood.

7.2.4 Possible Confusion

- A fragmentary first rib might be mistaken for an inferior ramus of the os coxae. The cortex of the rib, however, is not as thick, the surface is more irregular, and the cross section is much thinner than in the os coxae.
- Proximal ends of other ribs, when broken into short segments, could be mistaken for metatarsal or metacarpal shafts. However, the cross section of a rib is more irregular, with one sharp edge. Usually the tubercle, head, or part of the costal groove is enough to diagnose a broken specimen as a rib.
- The head and neck of the first rib are flatter and smaller, respectively, than a transverse process from a thoracic vertebra.
- The head of a rib might be confused with a broken infant ulna, but attention to bone maturity can aid in the diagnosis of these parts.

7.2.5 Siding

- For the first rib, the head and neck point inferiorly, and the superior surface bears grooves when in correct anatomical position.
- For all other ribs, the heads point toward the midline, and the tubercles are inferior.
- The cranial edge is thicker and blunter than the grooved, sharp inferior edge.
- The inner surface of the twelfth rib faces superiorly.

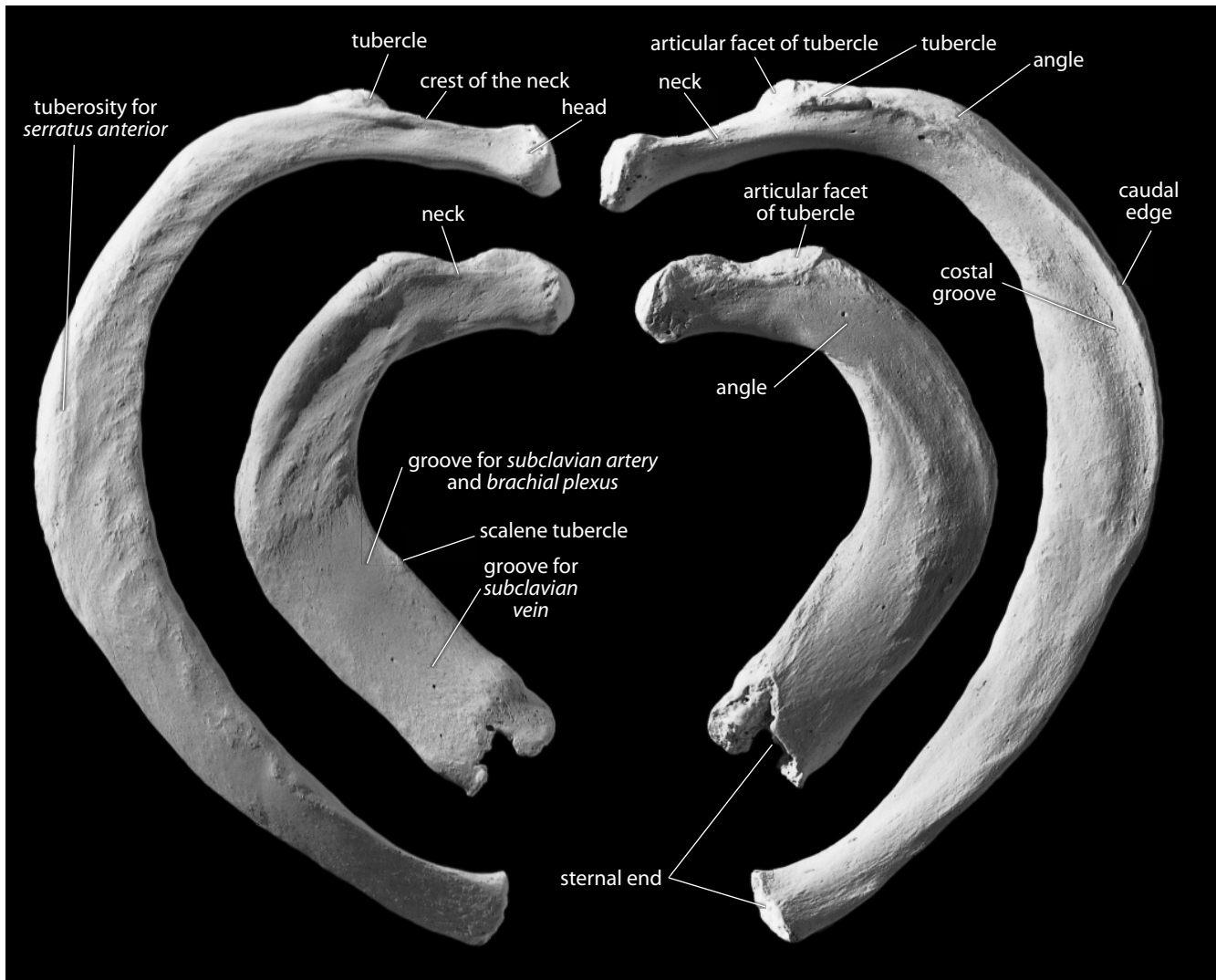


Figure 7.5 Right first and second ribs. *Left*: superior view; *right*: inferior view. Natural size.

7.2.5 Costal Measurements (Figure 7.6)

Measurements of the ribs are infrequently taken, but these values have been used in biomechanical formulas related to respiration, climatic adaptation, and trunk shape, as well as being useful in determining lateral asymmetry (helpful in diagnosing pathologies such as idiopathic scoliosis).

1. **Total rib length** (Martin, 1928: 1005, #4): Place the tip of the stationary end of the sliding caliper on the center of the head and measure the distance to the centerpoint of the sternal end.
2. **External arc of rib** (Martin, 1928: 1005, #3): With a flexible cloth measuring tape, measure the distance along the greater curvature of the rib (the external surface) from the center of the head to the centerpoint of the sternal end.

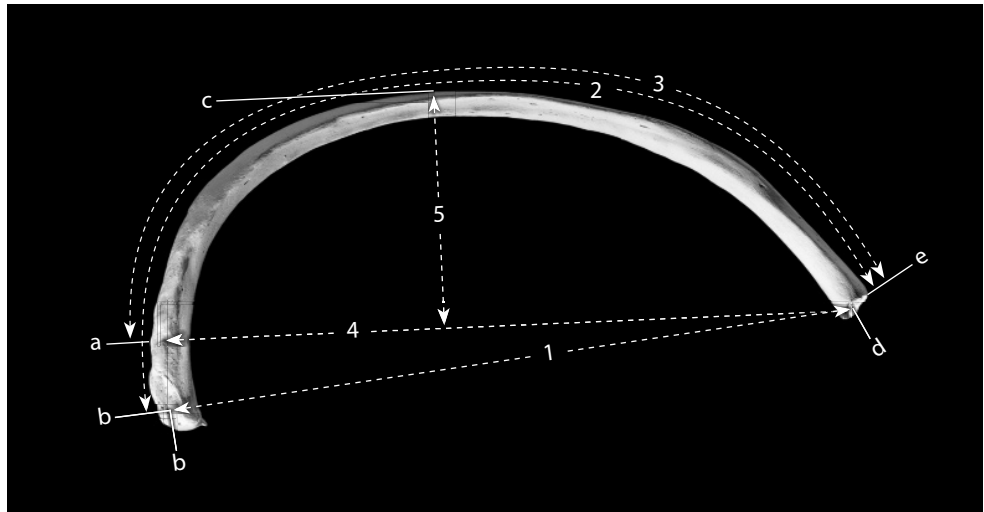


Figure 7.6 Costal measurements. One-half natural size.

Locations: a) distalmost point on tubercular articular facet; b) middle of the rib head; c) lateralmost point on shaft (point orthogonally farthest from '4'); d) center of sternal end; e) rim of sternal end.

Measurements: 1) total rib length; 2) external arc of rib; 3) tuberculoventral arc; 4) tuberculoventral chord; 5) tuberculoventral subtense.

3. **Tuberculoventral arc** (Gómez-Olivencia, et al., 2009: 78; after McCown and Keith, 1939: figure 75): With a flexible cloth measuring tape, measure the distance along the greater curvature of the rib from the distalmost point of the tubercular articular surface to the sternal end of the rib (for ribs 1–9 only).
4. **Tuberculoventral chord** (Franciscus and Churchill, 2002: 311–312; after McCown and Keith, 1939: figure 75): With a sliding caliper, measure the minimum distance from the distalmost point of the tubercular articular surface to the ventralmost point on the sternal end of the rib (for ribs 1–9 only).
5. **Tuberculoventral subtense** (Franciscus and Churchill, 2002: 312; after McCown and Keith, 1939: figure 75): Using a coordinate caliper (or two sliding calipers), measure the perpendicular distance from the tuberculoventral chord to the lateralmost point on the shaft.
6. **Sternal end maximum diameter** (Arensburg, 1991): Using a sliding caliper, measure the maximum diameter of the sternal end of the rib (i.e., along the major axis).
7. **Sternal end minimum diameter** (Arensburg, 1991): Using a sliding caliper, measure the minimum diameter of the sternal end of the rib.

7.2.6 Costal Nonmetric Traits

- **Cervical and lumbar ribs:** Supernumerary ribs are occasionally found articulating with the seventh cervical vertebra (0.2% of individuals: Galis, 1999) or the first lumbar vertebra (8.8% of individuals: Lanier, 1944).
- **Bifid ribs:** The sternal end of any true rib, but primarily ribs 3–6, may be congenitally

split (Barnes, 1994). Bifid ribs include ribs that are split into sternal ends of either equal or different lengths, ribs that have spurs indicating incomplete bifurcation, ribs that split and then rejoin (leaving a fenestration), as well as ribs that are abnormally wide (and often bilobate in cross section), or ribs that flare at the sternal end into a 'terminal club.'

7.3 Functional Aspects of the Thoracic Skeleton

This introduction to the vertebrae, ribs, and sternum treats these elements individually. It is also important to note the functional interconnections between the elements and the dynamic, coordinated role that they play in the living human. The lungs, which function to transmit gases in and out of the bloodstream, are protected by the ribs, sternum, and vertebrae. However, these skeletal elements do more than just protect the lungs, heart, and great vessels—they provide attachment for respiratory muscles and for muscles that move the forelimbs. Inhalation, bringing oxygen-rich air into the lungs, requires action of the thoracic musculoskeletal system. Expiration is usually more passive, except during heavy breathing.

The inhalation of several liters of air is accomplished by increasing the volume of the thorax. During inhalation, the diaphragm is depressed and the ribs, particularly ribs 2–6, rotate about an axis through their heads as their sternal ends and the sternum itself are lifted superiorly and slightly anteriorly. In addition, the lower ribs move into more horizontal positions, widening the transverse diameter of the thorax. These actions increase the volume of the thorax, and atmospheric pressure then forces air into the elastic lungs contained within.

There are several muscles involved in inhalation. The ribs are elevated by the *scaleni muscles*, the diaphragm (attached to the xiphoid process, the lower four ribs, and the bodies and arches of lumbar vertebrae 1–2), and the external intercostal muscles (which attach between adjacent ribs). When forceful exhalation is called for, the internal intercostal muscles, which are oriented at nearly right angles to the external ones, depress the ribs. This is assisted by contraction of abdominal muscles to decrease the volume of the thorax and thus expel air.

This page intentionally left blank

Chapter 8

SHOULDER GIRDLE: CLAVICLE AND SCAPULA

THE DEPARTURE OF FISHES from their aquatic habitat brought profound changes in locomotion. The forelimb girdle (shoulder girdle), originally attached to the rear of the head, detached and moved tailward, leaving a flexible neck. As this girdle moved caudally, some of the head's dermal armor and gill muscles remained attached to it, and as a result our own shoulder girdle is still attached to the skull by derivatives of some of these primitive gill muscles. The remaining dermal bone element constitutes part of our clavicle. The human shoulder girdle provides support and articulation for the humerus and anchors a variety of muscles. The function of the clavicle as a strut for the shoulder is made obvious when fracture of this bone is accompanied by an anteromedial collapse of the shoulder. The shoulder girdle embraces the thorax posteriorly, laterally, and anteriorly, providing a platform for movements of the forelimb.

8.1 Clavicle (Figures 8.1–8.5, 8.10)

8.1.1 Anatomy (Figures 8.1–8.5)

The clavicle is a tubular, somewhat S-shaped bone. Its medial end (sternal extremity) articulates, via a synovial joint, with the clavicular notch of the manubrium. Its lateral end (acromial extremity) articulates with the acromial process of the scapula. The clavicle is oval-to-circular in cross section (see cross sections in Chapter 14). The medial end is rounded and flared like a trumpet, and the lateral end is flattened superoinferiorly. This element is easily palpated along its length in a living person.

- a. The **sternal end** of the clavicle is stout and round and has an articular surface on its medial surface (for the manubrium) as well as a small facet lipping over onto the inferior surface (for the first costal cartilage).
- b. The **acromial end** of the clavicle is flatter and wider than the sternal end. On its lateral surface is the **acromial facet**, for articulation with the acromial process of the scapula.
- c. The **costoclavicular** (or **costal**) **tuberosity** (or **impression**) is a variable trait (see Section 8.1.6) on the inferior surface of the sternal end of the clavicle. When present, it is a broad, irregularly roughened surface that anchors the *costoclavicular ligament*, which strengthens the sternoclavicular joint.

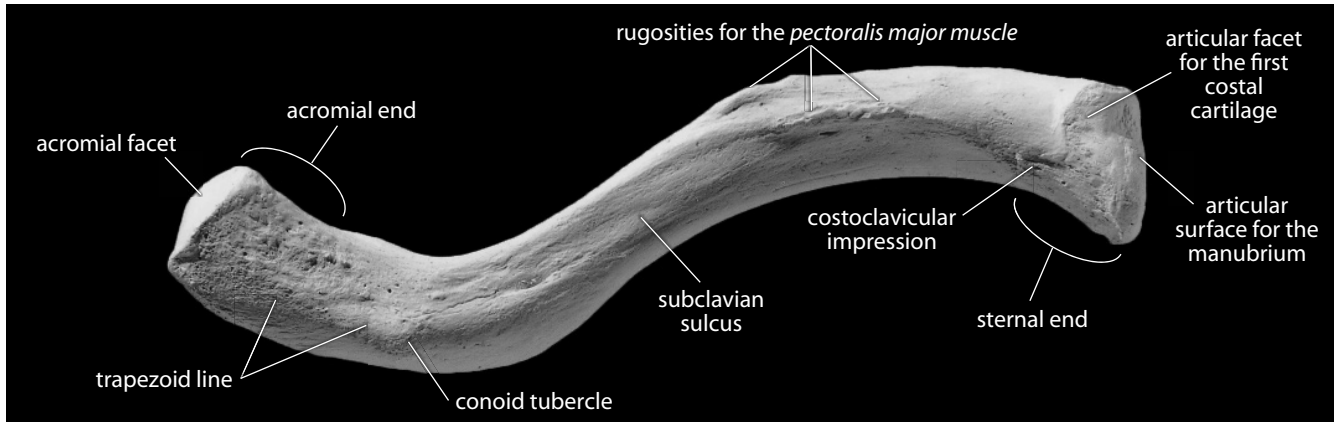


Figure 8.1 Right clavicle, inferior. Anterior is up, lateral is toward the left. Natural size.

- d. The **subclavian sulcus** (or **groove**) runs along the posteroinferior quadrant of the mid-shaft, providing a roof over the great vessels of the neck and an insertion for the *subclavius muscle* between the clavicle and the rib cage. In the case of a fracture, the *subclavius* protects these vessels by preventing motion in the free end of the jagged fractured bone.
- e. The **conoid tubercle** is found on the lateral end (acromial extremity) of the clavicle, and is located posteriorly. It is the attachment point for the *conoid ligament*, which attaches to the coracoid process of the scapula and reinforces the joint between these two bones.
- f. The **trapezoid line** (or **oblique ridge**) leads laterally from the conoid tubercle. It is the attachment site for the *trapezoid ligament*, which functions like the *conoid ligament*.
- g. The **nutrient foramen** lies along the posteroinferior edge of the bone and exits the bone medially.
- h. The **superior surface** of the clavicle bears somewhat less relief than the inferior surface, despite serving as the site of attachment of three major muscles (detailed below).
- i. The **rugosity for the trapezius muscle** can be seen along the posterolateral portion of the superior surface.

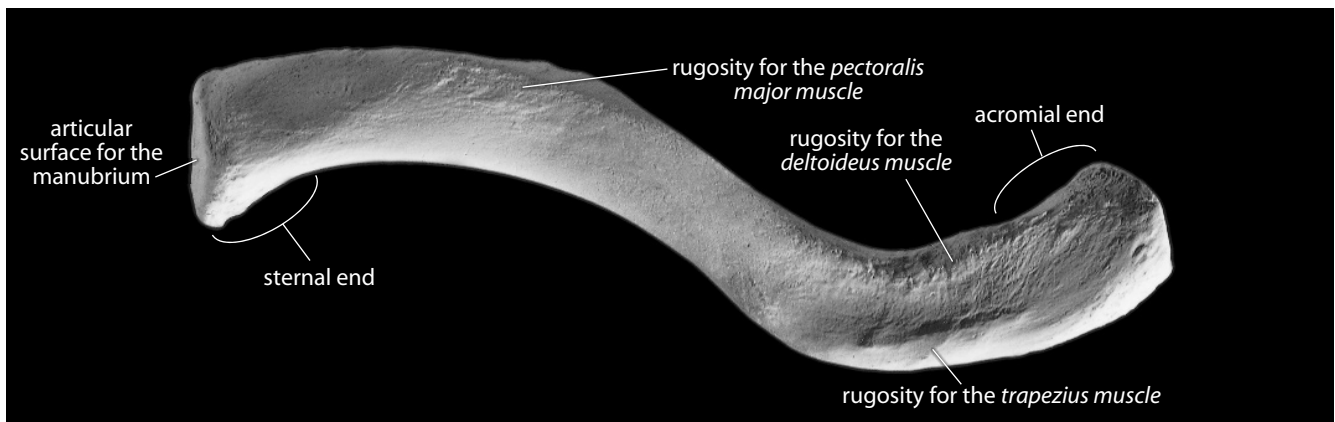


Figure 8.2 Right clavicle, superior. Anterior is up, lateral is toward the right. Natural size.

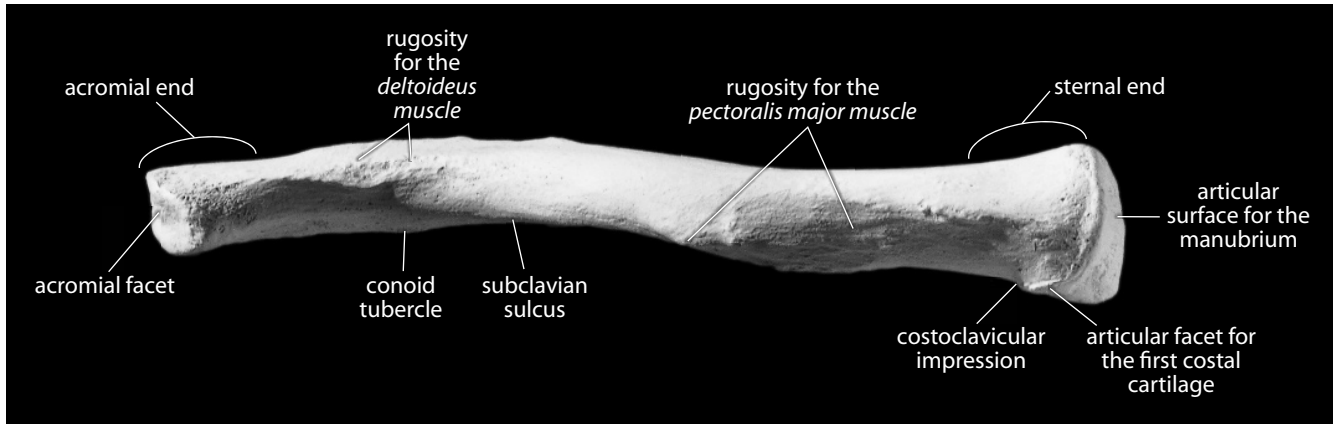


Figure 8.3 Right clavicle, anterior. Superior is up, lateral is toward the left. Natural size.

- j. The **rugosity for the *deltoideus* muscle** is found on the anterolateral margin of the superior surface.
- k. The **rugosity for the *pectoralis major*** anchors part of this muscle and marks the antero-medial portion of the clavicle.

8.1.2 Growth (Figure 8.10)

The clavicle is unusual in having two, quite different, primary centers of ossification, hinting at its complex developmental origin. The lateral half of the bone develops intramembranously (like cranial vault bones), explaining the flatter appearance of the acromial end and the lack of a distal epiphysis. The medial half of the bone is preformed in cartilage (like long bones), and develops endochondrally, with a tubular appearance, and a medial epiphysis. The bone is of additional developmental interest because it is the first to ossify *in utero* at week 5. It is also the last bone to fuse, on the sternal end, at 20–25 years of age.

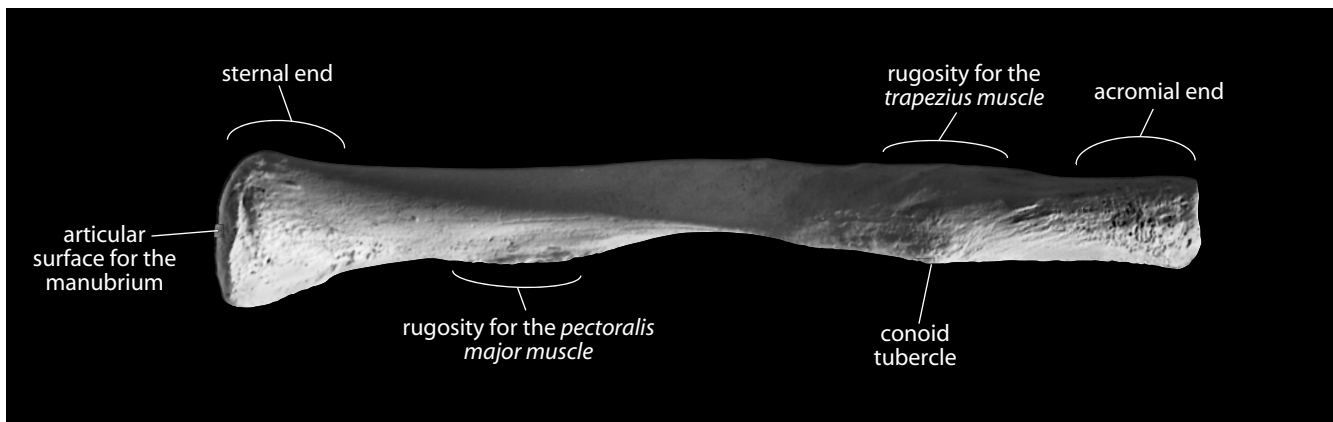


Figure 8.4 Right clavicle, posterior. Superior is up, lateral is toward the right. Natural size.

8.1.3 Possible Confusion

The lateral end of the clavicle is most often mistaken for the acromial process of the scapula in fragmentary specimens.

- The acromion of the scapula continues medially to become the scapular spine, whereas the lateral end of the clavicle becomes increasingly cylindrical as the shaft stretches medially.
- In comparisons of the tips of each bone, the facet of the clavicle is lateral and the facet of the acromion is anteromedial.

8.1.4 Siding

The following criteria should be sufficient to correctly side fragments of clavicle:

- The medial end is round; the lateral end is flattened.
- The bone bows anteriorly from the medial end, curves posteriorly at midshaft, and then sweeps anteriorly again as it reaches the lateral, flattened end. Thus, the apex of the first of the two curves which give the clavicle its S-shape is medial, and the apex of the second curve is lateral.
- Most irregularities and roughenings are on the inferior surface.
- The facet for the first costal cartilage is on the inferior edge of the medial clavicle, and the costal tuberosity is also inferior.

8.1.5 Clavicular Measurements (Figure 8.5)

The following are the most commonly taken and useful measurements of the clavicle:

1. **Maximum clavicular length** (Martin, 1928: 1005, #1; Buikstra and Ubelaker, 1994: 79, #35): Using an osteometric board, measure the greatest distance between the sternal and

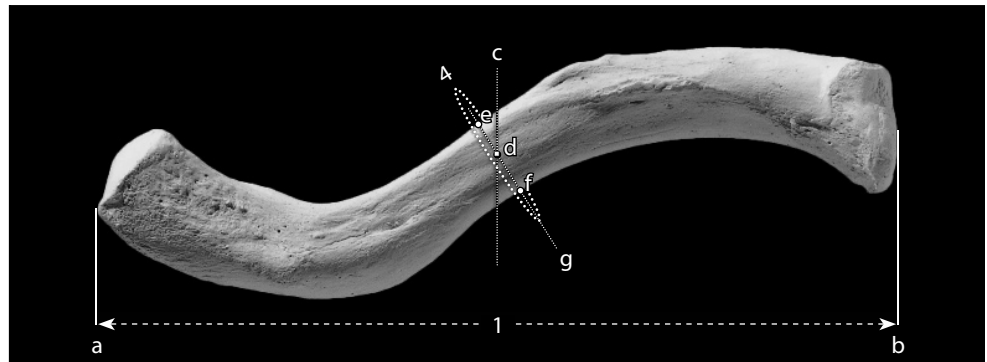


Figure 8.5 **Clavicular measurements.** Four-fifths natural size.

Locations: a) lateralmost point on acromial end; b) medialmost point on sternal end; c) midshaft (50% of maximum clavicular length); d) anteroposterior midpoint of 'c'; e) point on ventral surface that is closest to 'd'; f) point on dorsal surface that is closest to 'd'; g) line passing through 'e' and 'f'.

Measurements: 1) maximum clavicular length; 2) 'anteroposterior' midshaft diameter (*not shown, but measured along line 'g'*); 3) clavicular superoinferior midshaft diameter (*not shown, but measured along line 'g'*); 4) clavicular midshaft circumference.

acromial ends of the bone.

2. **Clavicular “anteroposterior” midshaft diameter** (Martin, 1928: 1006, #5; Buikstra and Ubelaker, 1994: 79, #36): After measuring biomechanical length, note the position of midshaft (it can be marked in a nonpermanent way, such as with nonadhesive Teflon tape). Use a sliding caliper to measure the minimum distance from the ventral surface to the dorsal surface and passing through the midpoint of midshaft.
3. **Clavicular superoinferior midshaft diameter** (Martin, 1928: 1006, #4; Buikstra and Ubelaker, 1994: 79, #37): Staying at the same location, rotate the sliding caliper 90° and measure the superoinferior diameter at midshaft.
4. **Clavicular midshaft circumference** (Martin, 1928: 1006, #6): Using a flexible cloth measuring tape, measure the smallest circumference that passes through the midpoint of midshaft.

8.1.6 Clavicular Nonmetric Traits

- **Costoclavicular sulcus:** The presence and development of this sulcus, found on the inferior aspect of the sternal end of the clavicle, may be an indicator of a habitual activity. Pietrusewsky (2002: 161) suggests it indicates “activities involving repetitive rotary or back and forth motions of the shoulder.” Usually scored as 0 (absent), 1 (present), or 2 (ridge).
- **Supraclavicular foramen:** Occasionally one of the branches of the supraclavicular nerve will become entrapped within the clavicle during development, exiting through a foramen on the superior aspect of the clavicle. Usually scored as 0 (absent) or 1 (present).

8.2 Scapula (Figures 8.6–8.11)

8.2.1 Anatomy (Figures 8.6–8.9)

The scapula is a large, flat, triangular bone with two basic surfaces: posterior (dorsal) and costal (anterior, or ventral). There are three borders that meet in three angles. The scapula articulates with the clavicle and the humerus.

- a. The **superior** (or **cranial**) **border** is the shortest and most irregular border.
- b. The **scapular** (or **suprascapular**) **notch** (or **foramen**) is a variable feature on the superior border (see Section 8.2.6). This semicircular notch is formed partly by the base of the coracoid process. It transmits the *suprascapular nerve* and may become a foramen if the ligament across its cranial edge ossifies.
- c. The **coracoid process** juts anteriorly and superolaterally from the superior border of the scapula. This finger-like, blunt, rugose projection anchors a variety of muscles, ligaments, and fascial sheets important in the function of the shoulder joint.
- d. The **subscapular fossa** is the shallow concavity that dominates the anterior (costal) surface of the scapula.
- e. The **oblique ridges** that cross the subscapular fossa from superolateral to inferomedial are formed by *intramuscular tendons* of the *subscapularis muscle*, a major muscle that functions in medial rotation and adduction of the humerus and assists in other movements of the arm at the shoulder.
- f. The **lateral** (or **axillary**) **border** is the anteroposteriorly thickest border. It is usually slightly concave.

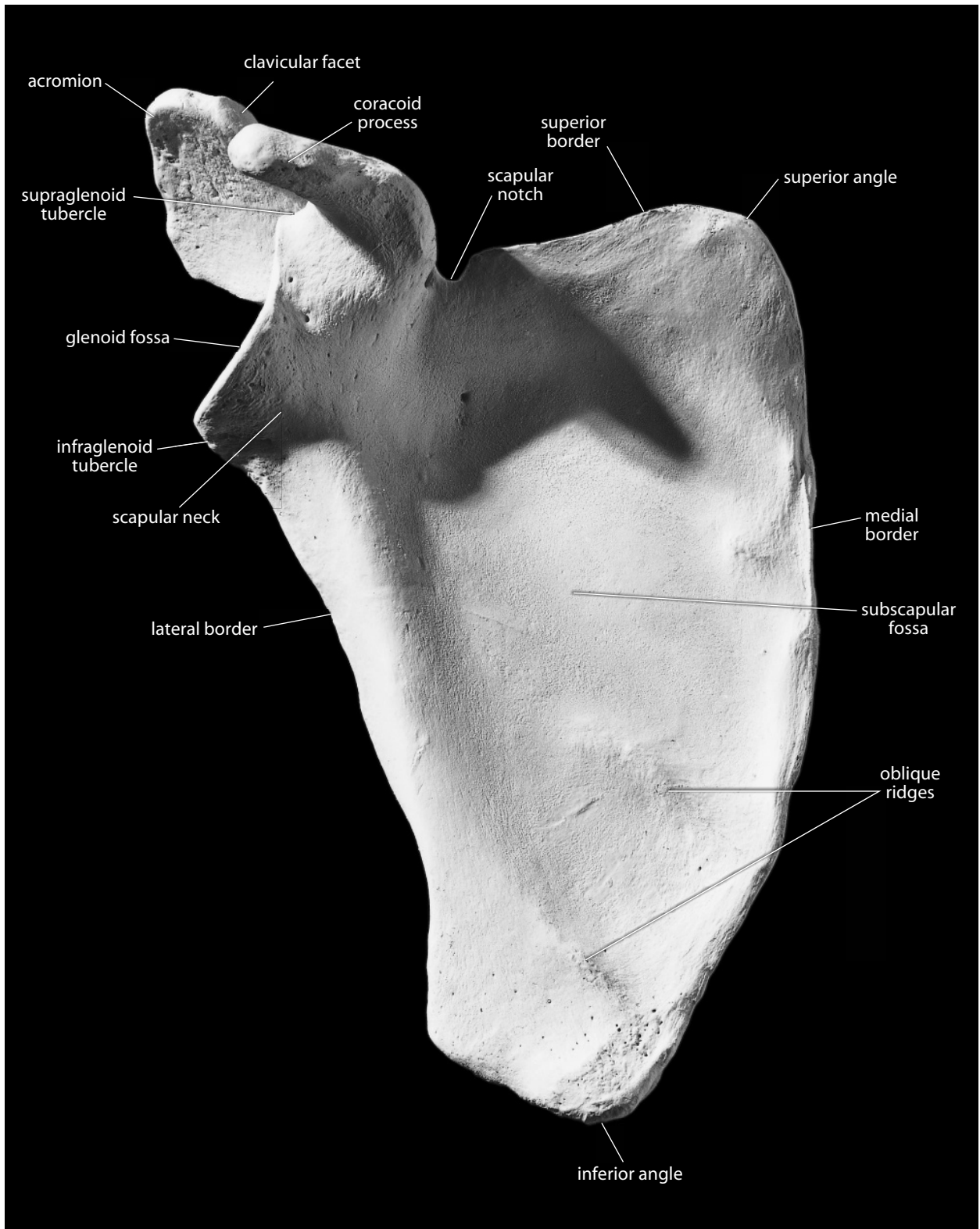


Figure 8.6 Right scapula, anterior. Superior is up, lateral is toward the left. Natural size.

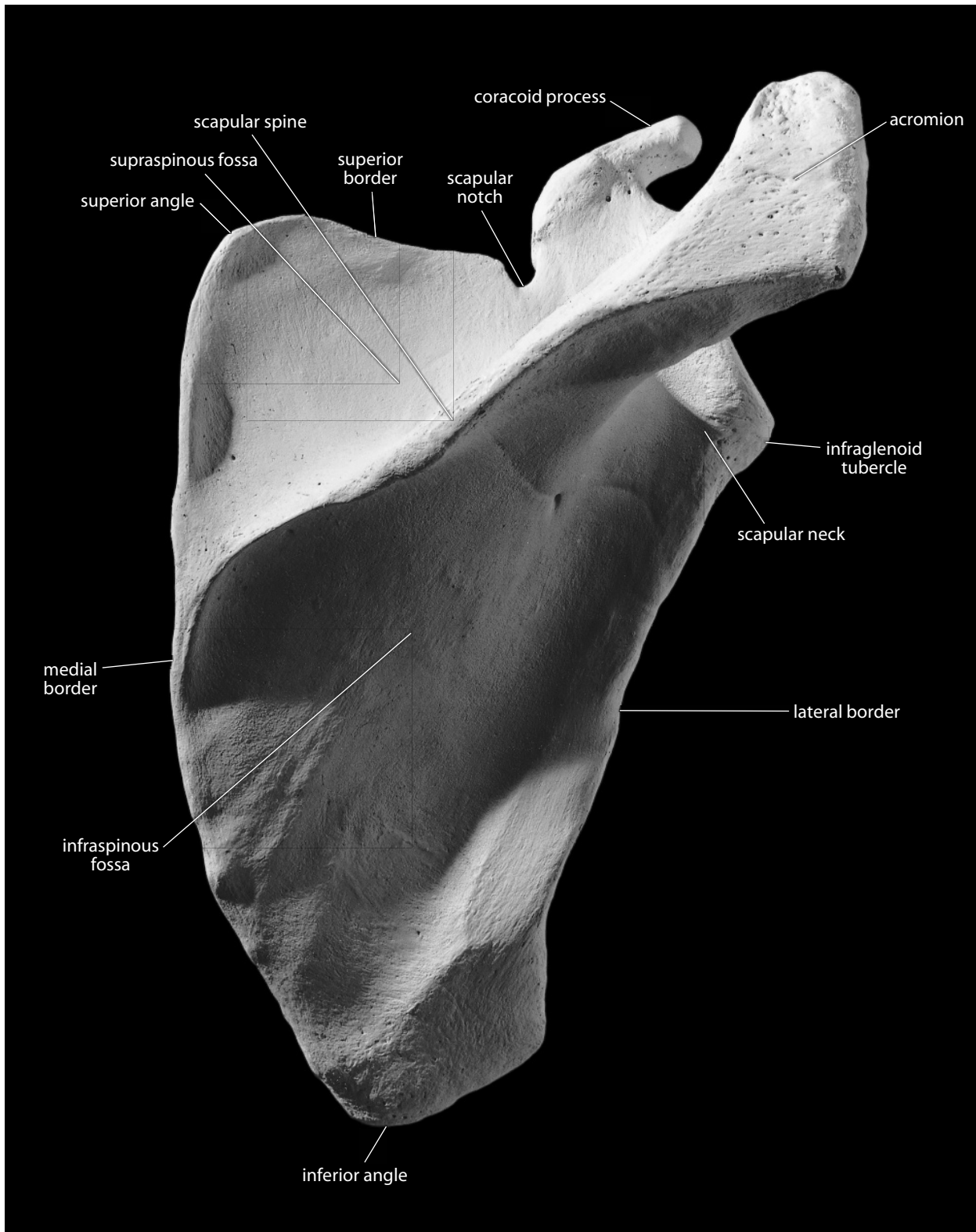


Figure 8.7 Right scapula, posterior. Superior is up, lateral is toward the right. Natural size.

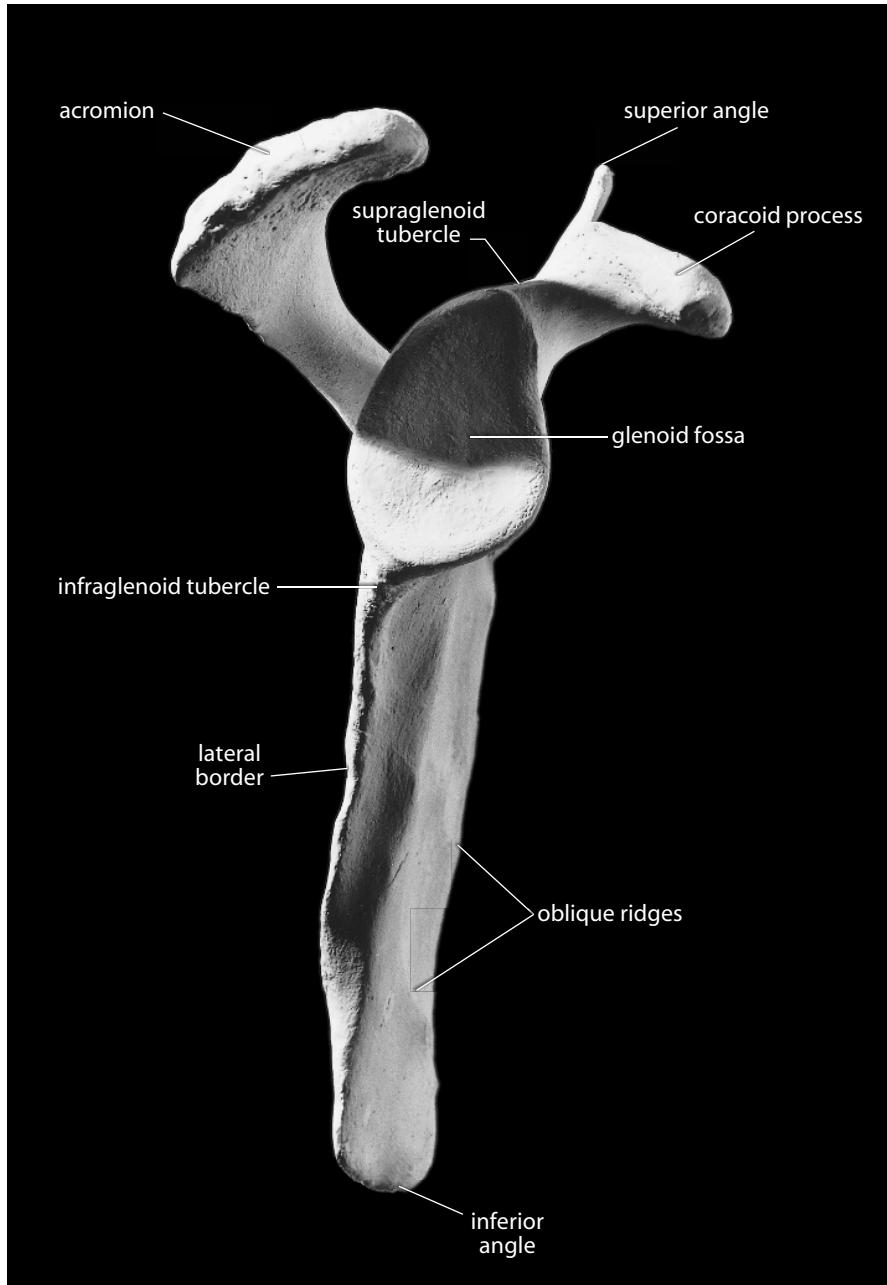


Figure 8.8 Right scapula, lateral. Superior is up, anterior is toward the right. Natural size.

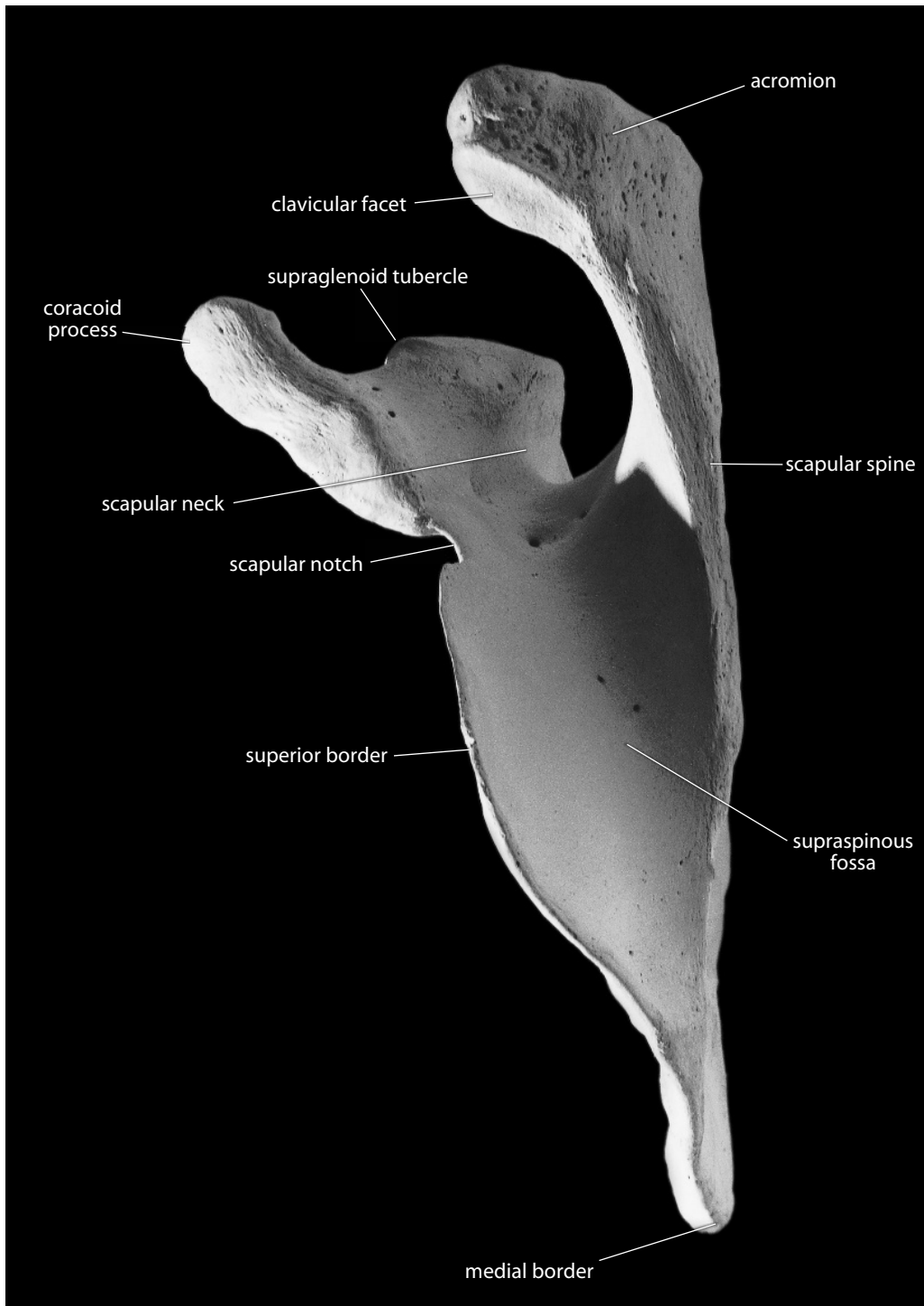


Figure 8.9 Right scapula, superior. Anterior is toward the left, lateral is up. Natural size.

- g. The **glenoid fossa** (or **cavity**) is a shallow, vertically elongate concavity that receives the head of the humerus. The shallowness of this joint allows great mobility of the humerus (circumduction comes easily), but the shoulder joint is consequently more prone to dislocation than the hip joint.
- h. The **supraglenoid tubercle** sits adjacent to the superior edge of the glenoid cavity, at the base of the coracoid process. This anchors the long head of the *biceps brachii muscle*, a flexor of the arm and forearm.
- i. The **infraglenoid tubercle** sits just adjacent to the inferior edge of the glenoid fossa. It gives origin to the long head of the *triceps brachii muscle*, an extensor of the forearm and an extensor and adductor of the arm at the shoulder.
- j. The **scapular neck** is the slightly constricted region just medial to the glenoid fossa.
- k. The **medial** (or **vertebral**) **border** is the straightest, longest, and thinnest border.
- l. The **scapular spine** dominates the posterior surface of the scapula. It passes medio-laterally across this surface, merging medially with the vertebral border and projecting laterally as the acromion process.
- m. The **acromion** (or **acromial process**) is the lateral projection of the scapular spine. Its cranial surface is very rough, providing attachment for a portion of the *deltoideus muscle*, a major arm abductor whose origins continue along the inferior edge of the scapular spine. The upper fibers of the *trapezius muscle*, which act as scapular rotators, also insert here. The anteromedial corner of the acromion bears a small articular facet for the distal end of the clavicle, the **clavicular facet**.
- n. The **supraspinous fossa** is the large, mediolaterally elongate hollowing superior to the base of the spine. It is the site of origin of the *supraspinatus muscle*, a major abductor of the arm.
- o. The **infraspinoous fossa** is the hollowing inferior to the scapular spine. This extensive, weakly concave area is the site of origin of the *infraspinatus muscle*, a lateral rotator of the arm. The intramuscular tendons of this muscle attach to the ridges on the surface of the fossa.
- p. The **superior angle** of the scapula is where the superior and medial (vertebral) borders intersect. The *levator scapulae muscle* attaches to the dorsal surface of the scapula in this region.
- q. The **inferior angle** of the scapula is where the vertebral (medial) and axillary (lateral) borders intersect. Rugosities on the costal and dorsal surfaces in this area mark the insertions of the *serratus anterior muscles* and origin of the *teres major muscle* from the medial and lateral borders, respectively.

8.2.2 Growth (Figure 8.10)

The scapula ossifies from two primary centers and seven or more secondary centers. One of the primary centers is for the scapular body, the other is for the coracoid process. The secondary centers are as follows: three associated with the coracoid, one with the acromial process, one with the inferior glenoid, one with the inferior angle, and one or more with the medial border. Ossification of the medial borders is variable, with elongated plates appearing and fusing during adolescence.

8.2.3 Possible Confusion

- When fragmentary, the scapula might be mistaken for the pelvis. In all of its flat parts, however, the scapula is thinner than the pelvis. Indeed, the scapular blade is mostly a single, thin layer of bone instead of spongy bone sandwiched between cortices as in the pelvis.

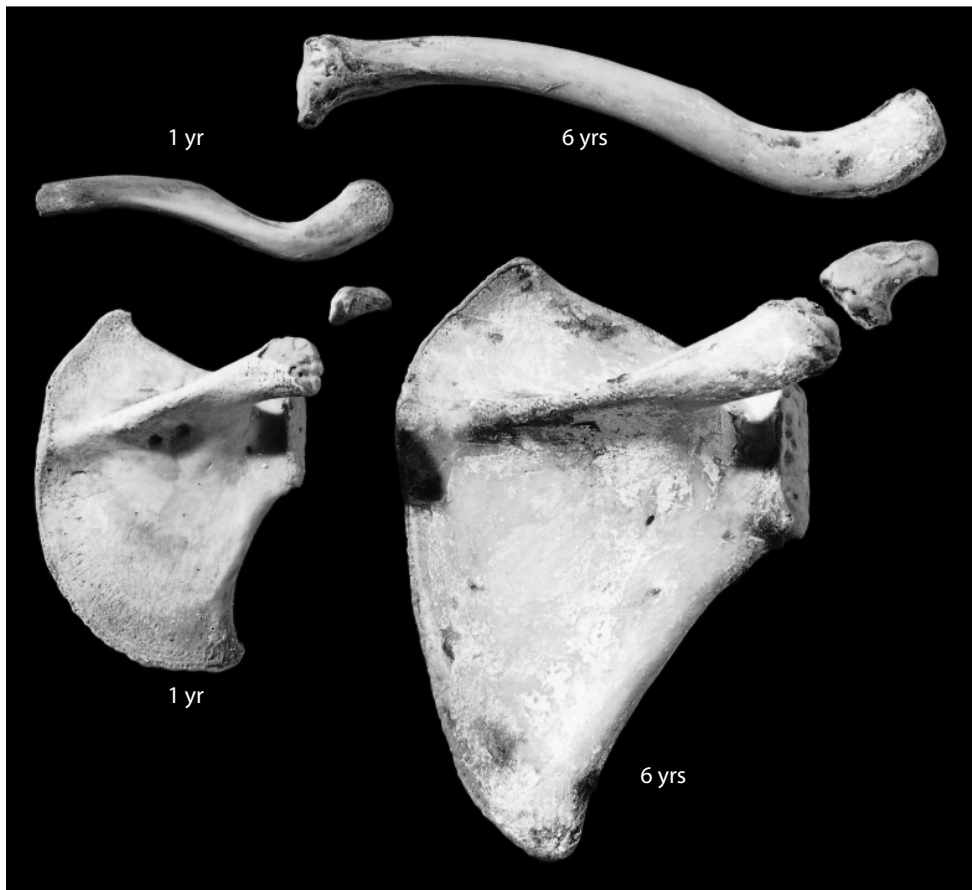


Figure 8.10 Clavicular and scapular growth. *Top:* Superior view of a one-year-old (*on left*) and a six-year-old (*on right*) clavicle. *Bottom:* Dorsal view of a one-year-old (*on left*) and a six-year-old (*on right*) scapula. Natural size.

- A broken fragment of the glenoid fossa could be mistaken for the hip joint (acetabulum). The glenoid fossa is much shallower and smaller than the acetabulum.
- The coracoid process could be mistaken for the transverse process of a thoracic vertebra, but the coracoid process is nonarticular.
- The lateral part of the acromial process is sometimes mistaken for a fragment of the lateral clavicle. However, because the acromion is continuous with the thin, plate-like spine, rather than a cylindrical shaft, this misattribution can be avoided. The inferior acromial surface is also smooth and concave; the distal clavicle is not.
- Tiny fragments of scapular blade or infant scapulae could be mistaken for wings of the sphenoid, but the thin bone of the scapula will be bounded by broken surfaces, whereas broken pieces of sphenoid pieces normally have free or sutural edges.

8.2.4 Siding

When intact, the glenoid is lateral and the spine is posterior. When fragmentary, use the following criteria:

- For an isolated glenoid, the fossa is teardrop-shaped, with its blunt end inferior. When looking directly into the correctly oriented glenoid fossa, note that the anterior edge of the fossa has a broad notch in it. The supraglenoid tubercle at the superior edge of the glenoid is displaced anteriorly. Posteriorly, the border of the glenoid is waisted, and the edge is raised and roughened. The anterior border is not as raised; it gently slopes into the rest of the scapula.
- For an isolated acromial process, the inferior surface of the acromion is concave and is smoother than the superior. The clavicular facet is placed anteromedially relative to the tip.
- For an isolated vertebral border, the anterior surface is concave and the posterior is convex. The oblique ridges run from superolateral to inferomedial (parallel to the scapular spine).
- For an isolated inferior angle, the anterior surface is concave, while the posterior is convex. The thickest border is lateral (axillary).
- For an isolated axillary border, the broad sulcus inferior to the glenoid parallels the border and is displaced anteriorly. The border itself thins inferiorly. The bony thickening is greatest (forming a “bar”) on the anterior surface. Thickness of the cortex increases as the glenoid is approached along this border.
- For an isolated coracoid process, the smooth surface is inferior, the rough superior. The anterior border is longer. The hollow on the inferior surface faces the glenoid area (posteroinferiorly).
- For an isolated spine, the spine thins medially (vertebrally) and thickens towards the acromion. The inferior border has a tubercle that points inferiorly. Adjacent to the spine, the infraspinous fossa is most deeply excavated medially. The supraspinous fossa is most deeply excavated laterally. A variably present foramen (or foramina) perforates the scapula at the superolateral base of the spine, at the depth of the supraspinous fossa.

8.2.5 Scapular Measurements (Figure 8.11)

Measurements of the scapula are used for age determination in subadults, sex determination in adults, and are included in many multivariate analyses. The following are the most commonly taken and useful measurements of the scapula:

1. **Maximum length** (or **anatomical height** or **total height**) (Martin, 1928: 1006, #1; Buikstra and Ubelaker, 1994: 79, #38): With a sliding caliper or an osteometric board, measure the distance between the superior angle and the inferior angle.
2. **Morphological** (or **anatomical**) **breadth** (Martin, 1928: 1006, #2; Buikstra and Ubelaker, 1994: 79, #39): With a sliding caliper, measure the distance between the posterior margin of the glenoid fossa and the point at which the scapular spine intersects the medial border.
3. **Length of spine** (Bass, 1995: 122, #3): With a sliding caliper, measure the distance between the point at which the scapular spine intersects the medial border and the most distal point on the acromial process.
4. **Length of supraspinous line** (Martin, 1928: 1008, #6a; Bass, 1995: 122, #4): Using a sliding caliper, measure the distance between the point at which the scapular spine intersects the medial border and the tip of the superior angle.
5. **Length of infraspinous line** (Martin, 1928: 1008, #5a; Bass, 1995: 122, #5): Using a sliding caliper, measure the distance between the point at which the scapular spine intersects the medial border and the tip of the inferior angle.
6. **Scapular index** (Martin, 1928: 1009; Bass, 1995: 122): $(\text{anatomical breadth} \div \text{anatomical height}) \times 100$.

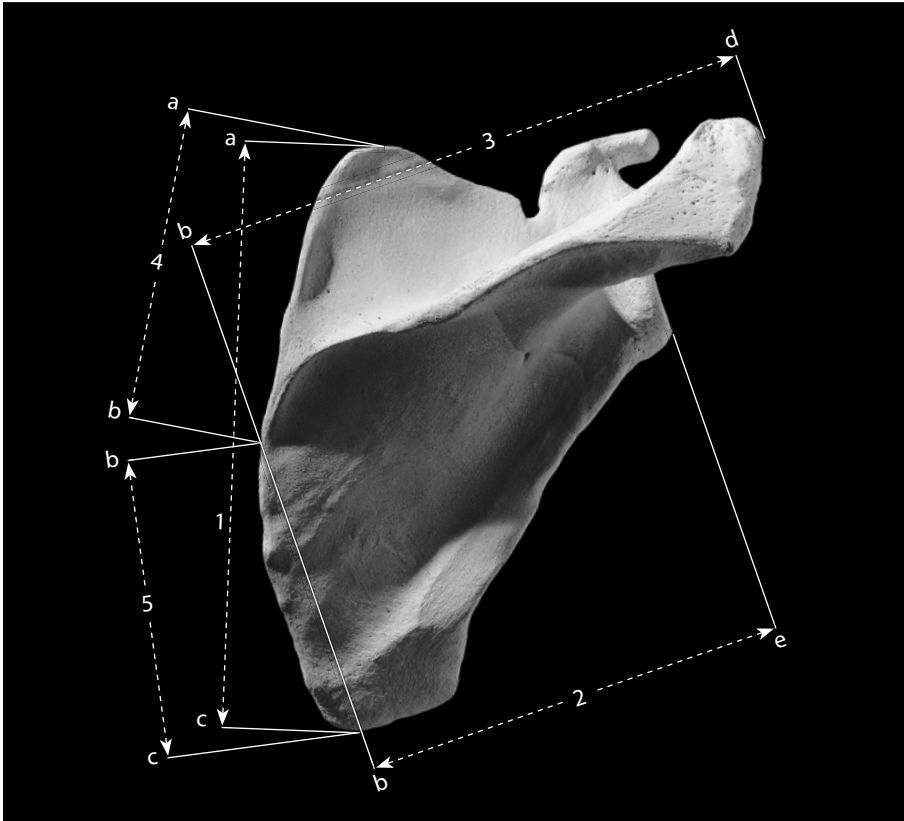


Figure 8.11 Scapular measurements. One-half natural size.

Locations: a) superiormost point of superior angle; b) intersection of scapular spine and medial border; c) inferiormost point of inferior angle; d) point on acromion farthest from 'b'; e) posterior margin of the glenoid fossa.

Measurements: 1) maximum length; 2) maximum breadth; 3) length of scapular spine; 4) length of suprascapular line; 5) length of infraspinous line.

8.2.6 Scapular Nonmetric Traits

- **Suprascapular foramen or notch form:** Occasionally, the suprascapular ligament bridging the suprascapular notch will ossify, forming a suprascapular foramen. Usually scored as 0 (absent), 1 (notch), 2 (foramen), 3 (spur/notch), or 4 (large concavity).
- **Circumflex sulcus:** A groove on the posterolateral border of the scapula that bisects the area of insertion of the *teres minor muscle*. Varies in size and depth; may be broad and shallow. Usually scored as 0 (absent) or 1 (present).
- **Unfused acromial apophysis (or os acromiale):** This epiphysis will occasionally persist as a separate bone in adulthood. Usually scored as 0 (absent) or 1 (present).
- **Humeral (or acromial) facet:** A facet on the inferior surface of the acromion, possibly activity-related. Usually scored as 0 (absent) or 1 (present).
- **Acromion shape:** Note the shape of the outline of the acromion. Usually scored as 1 (rectangular), 2 (triangular), 3 (sickle-shaped), or 4 (irregular).

- **Vertebral border:** Note the shape of the outline of the vertebral border. Usually scored as 1 (convex), 2 (concave), 3 (straight), or 4 (irregular).
- **Inferior angle shape:** Note the shape of the outline of the inferior angle. Usually scored as 1 (V-shaped), 2 (blunt), or 3 (rounded).

8.3 Functional Aspects of the Shoulder Girdle

Because the glenohumeral joint between the scapula and humerus is free to move as the scapula moves, and because the shoulder girdle has only one bony connection to the thorax, the upper limb of a human is far more mobile than the lower limb. In contrast to the shoulder, the hip joint is fixed in relation to the vertebrae. In the glenohumeral joint, there is a great disparity between the large articular surface of the humeral head and the smaller glenoid surface. This provides further mobility to the arm because the ball-shaped humeral head can rotate in any direction in the glenoid fossa. The capsule of the glenohumeral joint is ligamentous and muscular (and relatively weak), and the shoulder is therefore an easily dislocated joint.

Actions of the shoulder girdle are accomplished, for the most part, by muscles inserting on the scapula. The scapula moves, sliding and rotating on the back, in response to muscle contractions that change the orientation and position of the glenoid. One of the major scapular rotators is the *trapezius muscle*, which originates from the nuchal line of the occipital and the spines of cervical and thoracic vertebrae. The *trapezius muscle* inserts on the scapular spine, acromion, and posterolateral clavicle. The contraction of its various parts can therefore elevate, suspend, stabilize, and rotate the scapula. The *serratus anterior* works with the *trapezius*, inserting along the medial edge of the scapula's costal surface. Contraction of the lower fibers of this muscle can therefore rotate the scapula, with the opposite rotation produced by the *rhomboid major muscle*.

In all, 16 muscles affect movements of the shoulder. The scapula is a sort of mobile foundation for muscles that move the arm. The scapula itself can be moved so that the glenoid faces different directions. Muscles anchored on this mobile platform in turn move the arm via the shoulder joint. A few large, superficial muscles cross both the shoulder and elbow joints and can effect movement there.

Chapter 9

ARM: HUMERUS, RADIUS, AND ULNA

THE LIMBS OF TERRESTRIAL VERTEBRATES (tetrapods) are secondary adaptations of structures — paired fins — that were originally adapted for life in an aquatic habitat. The first vertebrates were jawless fish (Agnathans)— animals similar to modern lampreys and hagfish — which had a rudimentary axial skeleton, but lacked both jaws and paired fins. Jaws and fins evolved about 400 million years ago, allowing fish (the Gnathostomes) to locomote and feed more effectively. These early jawed fish had two sets of paired fins (a pair each of pectoral and pelvic fins) connected to flat plates of bone that were attached to the muscles of their body walls. These paired fins, flexible fans of small bones, are still seen in modern fish, which use them primarily as aids for stabilization and steering. Limbs evolved from this structural arrangement as fins were gradually co-opted for use as load-bearing appendages by early tetrapods. Although the limbs of land vertebrates seem very different from fish fins, the two homologous structures are actually highly comparable.

Each vertebrate limb has a base and three segments. The limb girdles (the pelvis for the lower limb and the scapula and clavicle for the upper limb) are the old basal fin plates of fish, which evolved to take on the function of transferring the weight of the body to the limbs of the terrestrial tetrapod. The proximal vertebrate limb segments constitute the upper arm and thigh. The intermediate limb segments, the forearm and foreleg, each comprise two bones in humans: the radius and ulna in the arm, and their serial homologs, the tibia and fibula, in the leg. This chapter examines the three bones of the two proximalmost segments of the upper limb: the humerus, radius, and ulna.

9.1 Humerus (Figures 9.1–9.8)

9.1.1 Anatomy

The upper arm bone, or **humerus**, is the largest bone in the upper limb (arm). It comprises a proximal end with a round articular head, a shaft, and an irregular distal end. The humerus articulates proximally with the glenoid fossa of the scapula and distally with both the radius and the ulna.

- a. The **humeral head** is a hemisphere on the proximal end of the humerus that faces medially and articulates with the glenoid fossa of the scapula.

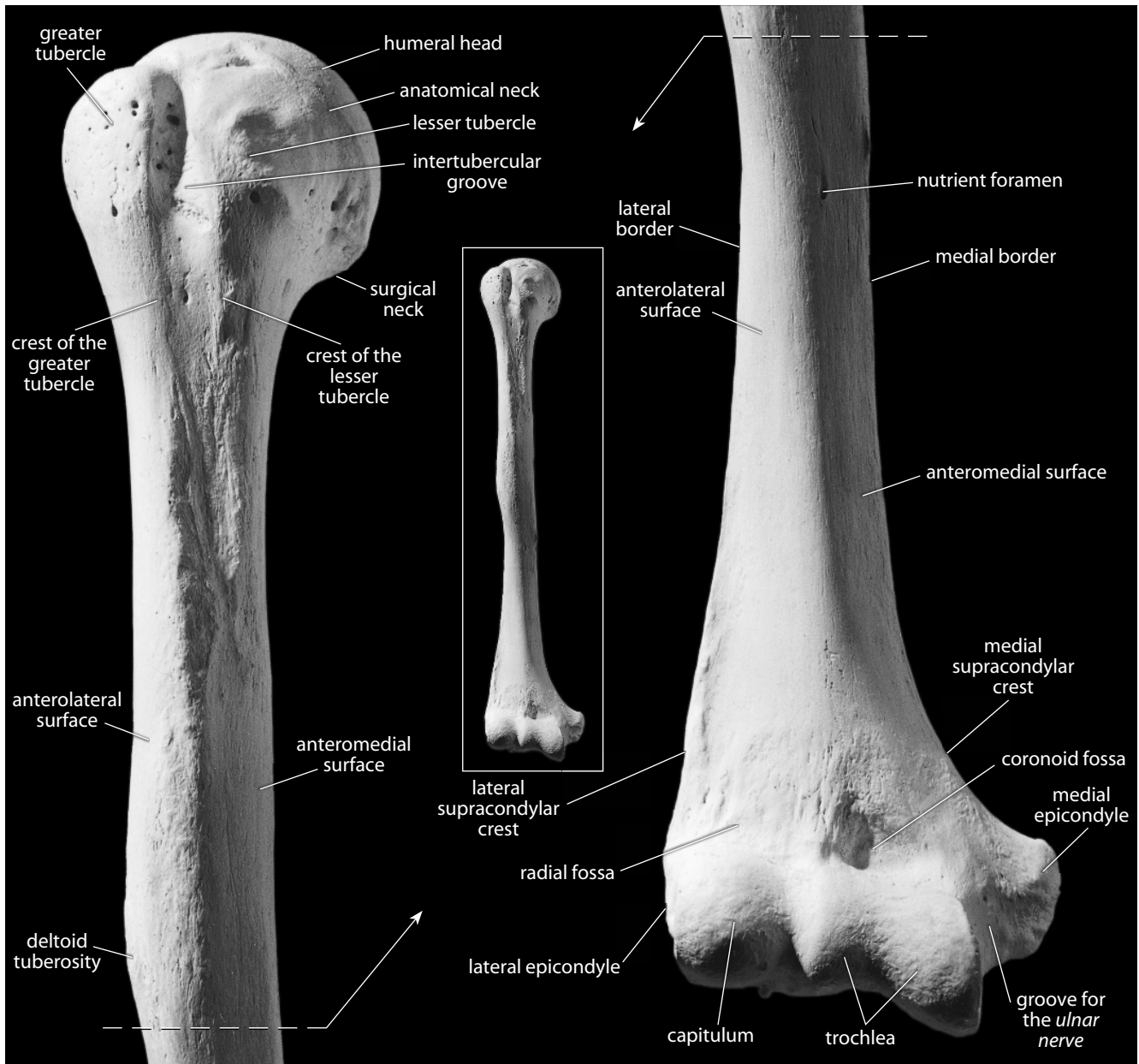


Figure 9.1 Right humerus, anterior. *Left:* proximal portion; *right:* distal portion. Natural size.

- b. The **anatomical neck** is the groove that encircles the articular surface of the humeral head and marks the area of the attachment of the *joint capsule*.
- c. The **surgical neck** is the short constricted segment inferior to the head. It links the head and shaft.
- d. The **lesser tubercle** is a small, blunt eminence anterolateral to the head on the proximal shaft. The lesser tubercle marks the insertion of the *subscapularis muscle*, which originates on the costal surface of the scapula and rotates the humerus medially.
- e. The **greater tubercle** is larger, more posterior, and projects more laterally than the lesser tubercle. The greater tubercle bears rugosities for the insertion of the *supraspinatus*,

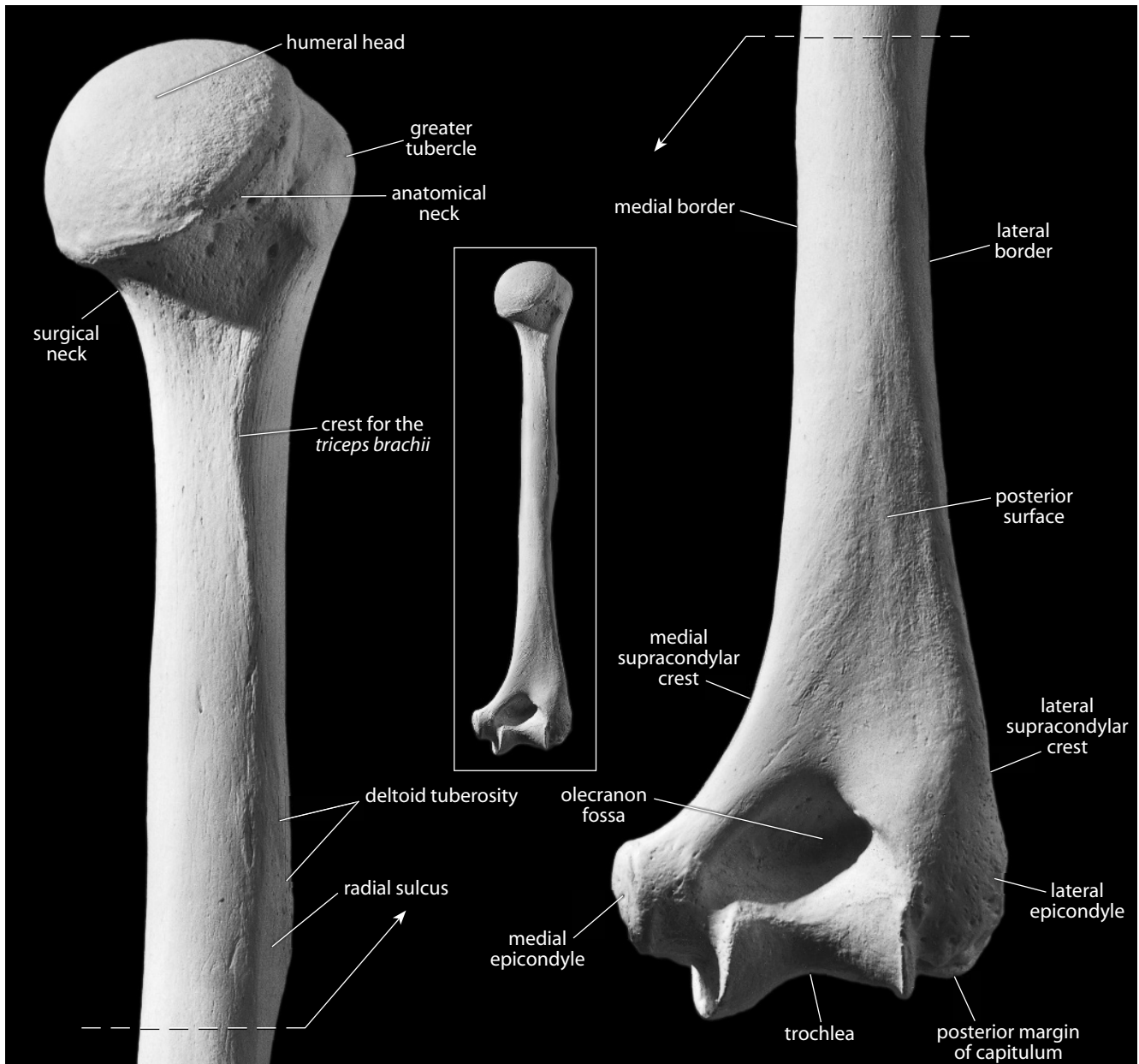


Figure 9.2 Right humerus, posterior. *Left*: proximal portion; *right*: distal portion. Natural size.

infraspinatus, and *teres minor* muscles. These muscles, together with the *subscapularis* muscle, constitute the *rotator cuff* muscles. In addition to medial and lateral rotation, these muscles also aid in adduction and abduction of the arm.

- f. The **intertubercular groove** (or **bicipital sulcus**) extends longitudinally down the proximal shaft. It begins between the two tubercles and houses the tendon of the long head of the *biceps brachii* muscle. In life, the *transverse humeral ligament* connects the two tubercles to bridge the groove and form a canal.
- g. The **crest of the greater tubercle** forms the lateral lip of the intertubercular groove. It is the insertion site for the *pectoralis major* muscle, a muscle that originates on the anteromedi-

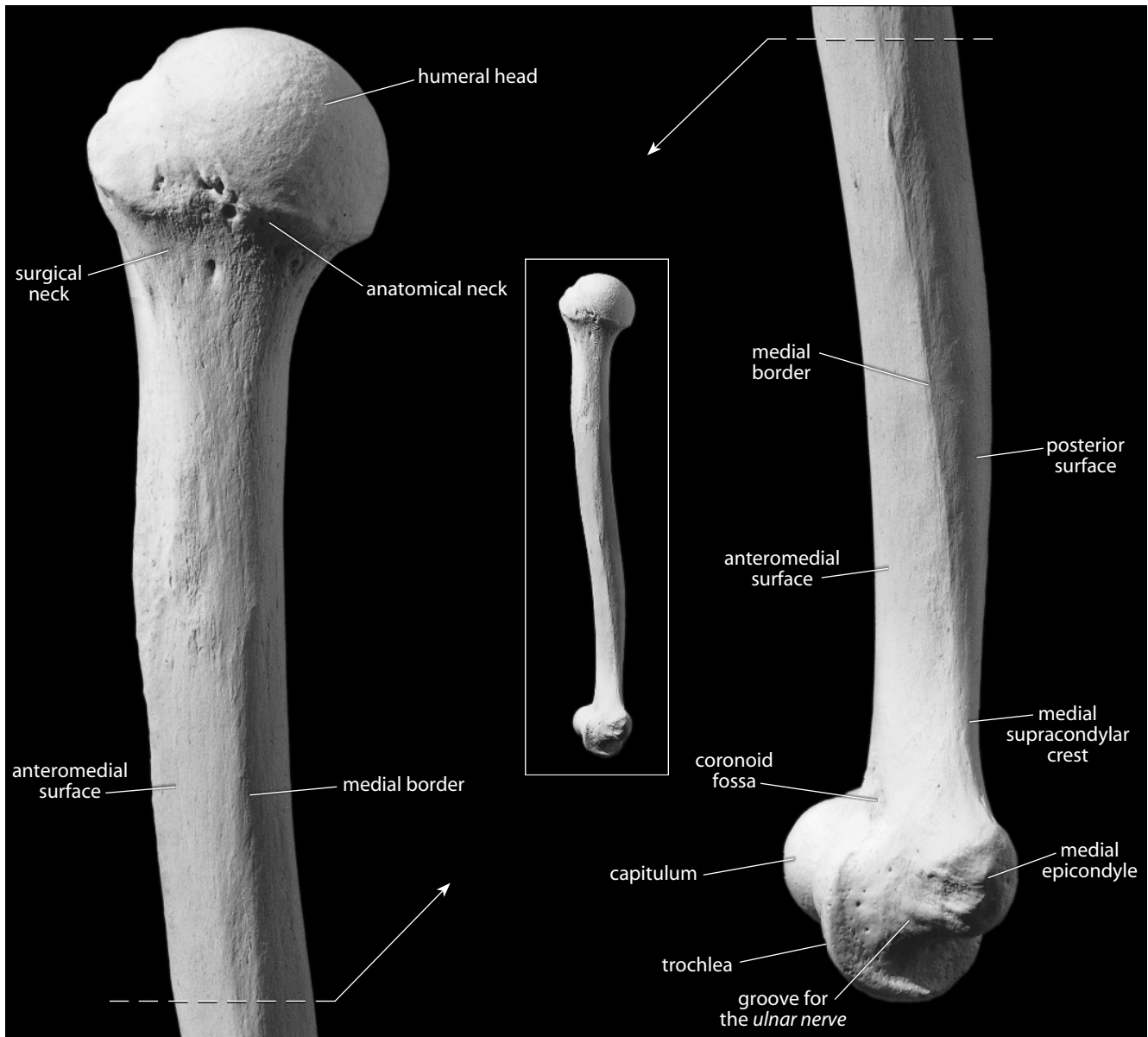


Figure 9.3 Right humerus, medial. *Left*: proximal portion; *right*: distal portion. Natural size.

- al clavicle, the sternum, and the cartilage of the true ribs. This muscle acts to flex, adduct, and medially rotate the arm.
- h. The **crest of the lesser tubercle** forms the medial lip of the intertubercular groove. It is the insertion site for the *teres major* and *latissimus dorsi muscles*, medial rotators and abductors of the arm.
 - i. The **humeral shaft** (or **body**) is variably triangular, ranging from more cylindrical in its proximal section to an anteroposteriorly compressed, rounded triangle distally (see cross sections in Chapter 14). The shaft is divided into three named surfaces.
 - j. The **anteromedial surface** is the portion of the shaft surface between the medial border and the continuation of the crest of the greater tubercle.

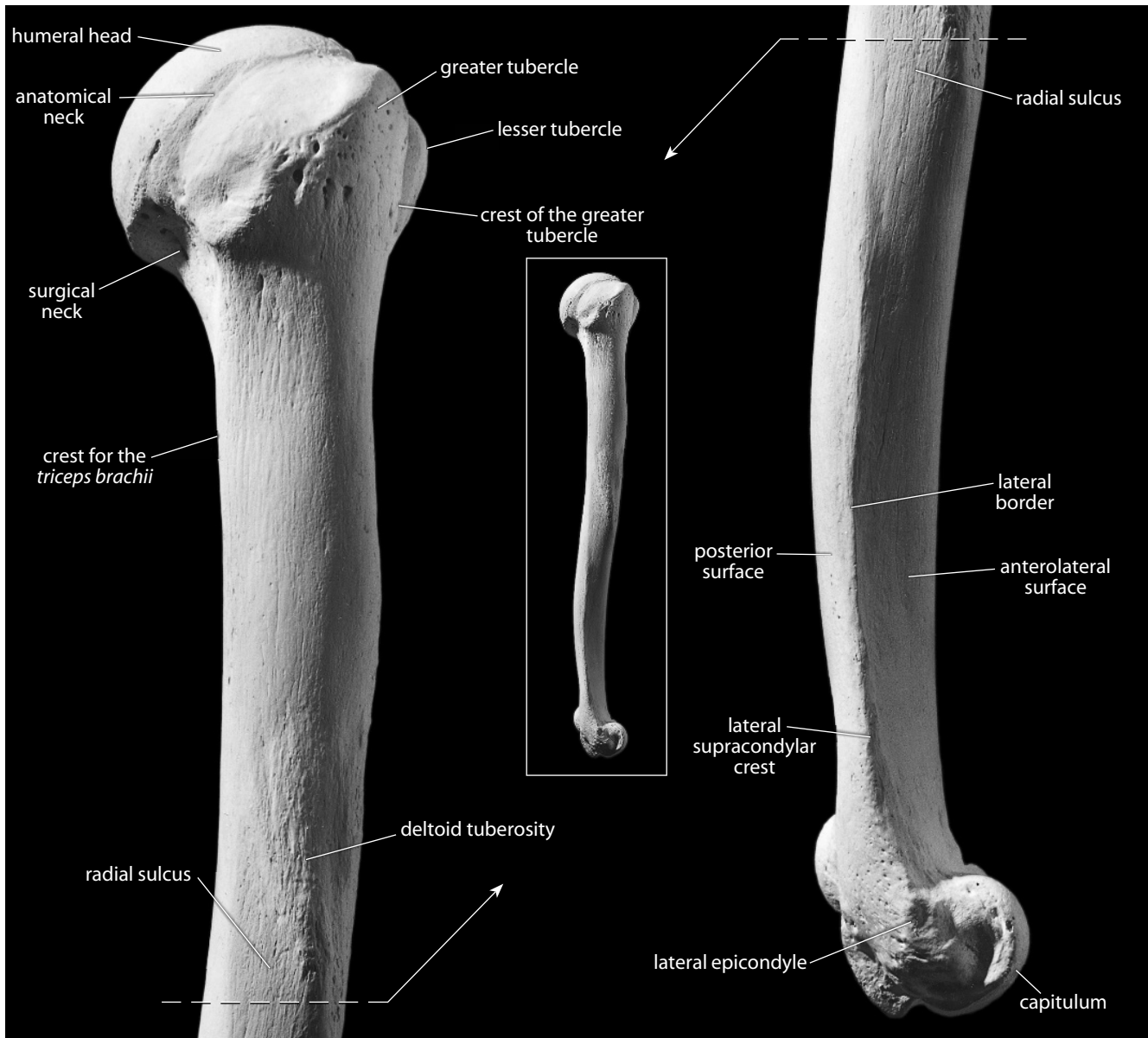


Figure 9.4 Right humerus, lateral. *Left*: proximal portion; *right*: distal portion. Natural size.

- k. The **anterolateral surface** is the portion of the shaft surface between the lateral border and the continuation of the crest of the greater tubercle.
- l. The **posterior surface** is bounded by the medial and lateral borders.
- m. The **medial border** is continuous with the medial supracondylar ridge.
- n. The **lateral border** is continuous with the lateral supracondylar ridge.
- o. The **deltoid tuberosity** is on the lateral surface of the shaft. It is the insertion site of the *deltoideus muscle*, a major abductor (among other functions) of the arm that originates from the anterior border and superior surface of the clavicle, the lateral margin and superior surface of the acromion, and the scapular spine. The deltoid tuberosity is recognized by its roughened surface. It tapers to a V-shape on the lateral aspect of the humerus.

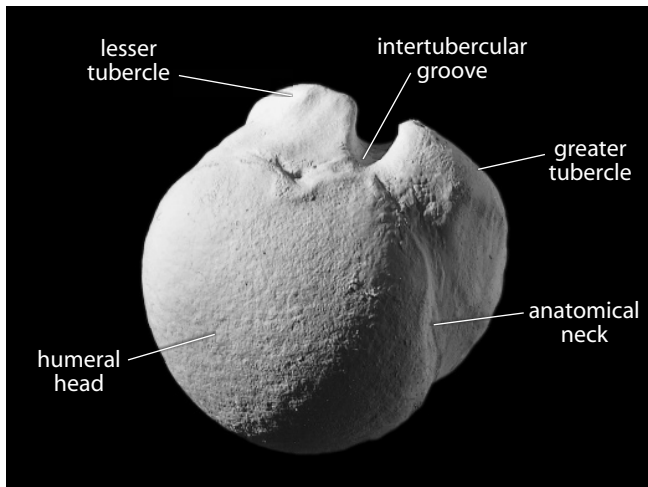


Figure 9.5 **Right humerus, proximal.** Anterior is up, lateral is to the right. Natural size.

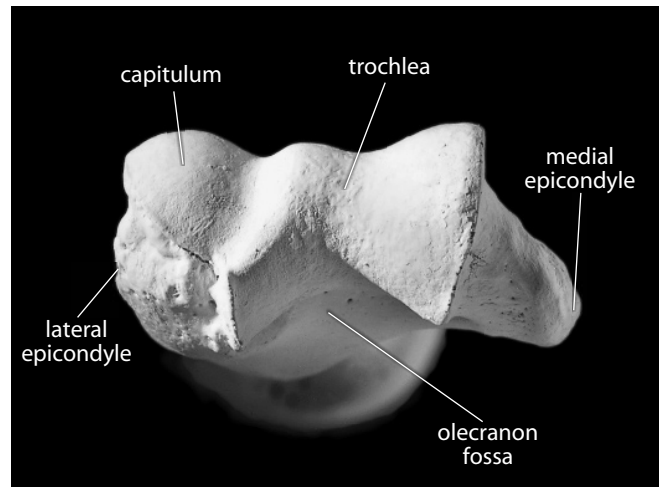


Figure 9.6 **Right humerus, distal.** Anterior is up, lateral is to the left. Natural size.

- p. The **crest for the *triceps brachii*** is found on the posterosuperior shaft, beginning just below the surgical neck and extending inferiorly to the posterosuperior tip of the deltoid tuberosity. It provides a site of attachment for the lateral head of the *triceps brachii muscle*.
- q. The **radial sulcus** (or **spiral groove**) is found on the posterior surface of the shaft. It is a shallow, oblique groove for the *radial nerve* and deep vessels that pass parallel and immediately posteroinferior to the deltoid tuberosity. Its inferior boundary is continuous distally with the lateral border of the shaft.
- r. The **nutrient foramen** is located anteromedially and exits the shaft from distal to proximal. A good way to remember the direction of entry of nutrient foramina into all of the long bones is to imagine tightly flexing your own arms (at the elbows) and legs (at the knees) in front of you. In this position you can look into the bones via the foramina. In long bones, these foramina transmit the *nutrient arteries*.
- s. The **olecranon fossa** is the largest of three hollows on the distal humerus. It is posterior, accommodating the olecranon of the ulna during forearm extension. The deepest area of this fossa is occasionally perforated, forming a foramen, or **septal aperture**.
- t. The **coronoid fossa** is the larger, medially placed hollow on the anterior surface of the distal humerus. It receives the coronoid process of the ulna during maximum flexion of the forearm.
- u. The **radial fossa** is the smaller, laterally placed hollow on the anterior surface of the distal humerus. It receives the head of the radius during maximum flexion of the forearm.
- v. The **capitulum** is the rounded eminence that forms the lateral portion of the distal humeral surface. It articulates with the head of the radius.
- w. The **trochlea** is the notch- or spool-shaped medial portion of the distal humeral surface. It articulates with the ulna.
- x. The **lateral epicondyle** is the small, nonarticular lateral bulge of bone superolateral to the capitulum. It serves as a site of attachment for the *radial collateral ligament* of the elbow and for the common tendon of origin of the *supinator* and the *extensor muscles* in the forearm.
- y. The **medial epicondyle** is the nonarticular, medial projection of bone superomedial to the trochlea. It is more prominent than the lateral epicondyle. It provides a site of attach-

ment to the *ulnar collateral ligament*, to many of the *flexor muscles* in the forearm, and to the *pronator teres muscle*.

- z. The **medial supracondylar** (or **supraepicondylar**) **crest** (or **ridge**) is superior to the medial epicondyle and forms the sharp medial border of the distal humerus.
- aa. The **lateral supracondylar** (or **supraepicondylar**) **crest** (or **ridge**) is superior to the lateral epicondyle and forms the sharp lateral border of the distal humerus.

9.1.2 Growth (Figure 9.7)

The humerus ossifies from several centers: the shaft, a compound proximal epiphysis, and a distal epiphysis. The compound proximal epiphysis is itself a composite of three centers of ossification: the head and both tubercles, all of which fuse together at 2–6 years. The distal epiphysis is composed of the capitulum and the lateral part of the trochlea, the medial part of the trochlea, the lateral epicondyle, and the medial epicondyle. The capitulum, trochlea, and lateral epicondyle all fuse together at 12–14 years, before any of them fuse to the shaft.

The compound distal epiphysis fuses to the shaft first, beginning at about 12–17 years in males, and about 11–15 years in females. The medial epicondyle fuses next, beginning at about 14–16 years in males, and about 13–15 years in females. The last to fuse is the compound proximal epiphysis, beginning at about 16–20 years in males and at 13–17 years in females (Scheuer and Black, 2000).

9.1.3 Possible Confusion

The humeral head cannot be mistaken for a femoral head because the former is only half of a sphere, whereas the latter is substantially more than half.

- The femoral head has a distinct depression, or **fovea capitis**, that the humerus lacks.
- The humeral shaft is larger and more circular in section than the radial, ulnar, or fibular shafts (see cross sections in Chapter 14).
- The humeral shaft is smaller and more irregular in section than the femoral shaft (see cross sections in Chapter 14).
- The humeral shaft is smaller and less triangular than the tibial shaft (see cross sections in Chapter 14).

9.1.4 Siding

- For an intact bone, the head faces medially, the capitulum is lateral, and the olecranon fossa is posterior.
- For an isolated proximal end, the head is medial, and the lesser tubercle and intertubercular groove are anterior.
- For an isolated distal end, the olecranon fossa is posterior, the medial epicondyle is larger, and the capitulum is lateral and oriented anteriorly. If the articular end is missing, the coronoid fossa is larger and more medial than the radial fossa.
- For an isolated shaft fragment, the deltoid tuberosity is lateral, with its posterior arm passing from posterosuperior to anteroinferior, and the nutrient foramen exits the bone toward its proximal end. A small, thin ridge runs along the entire medial edge of the shaft, and the nutrient foramen is found on this edge. The lateral lip of the intertubercular groove is stronger and longer.

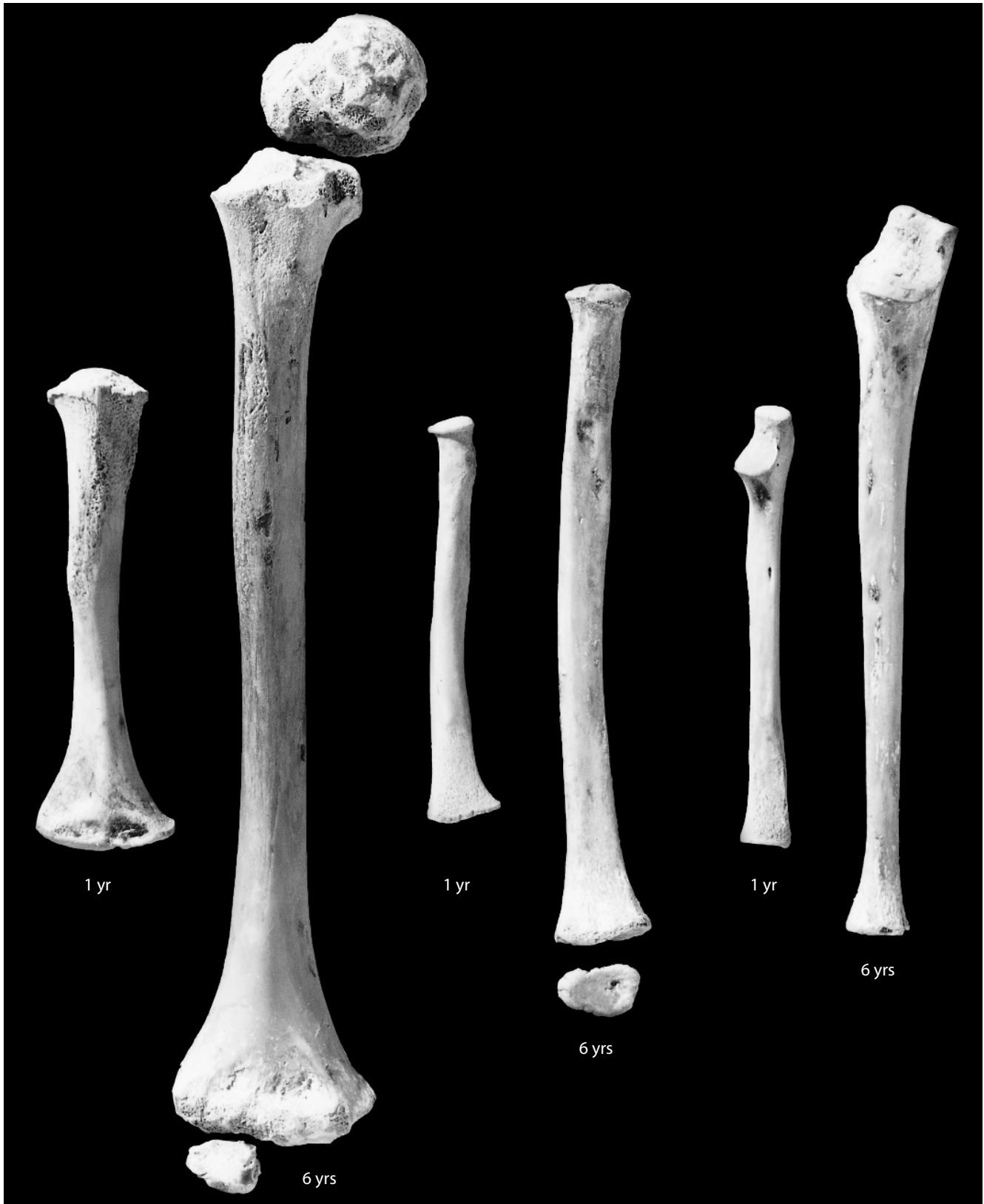

Figure 9.7 Humeral, ulnar, and radial growth. The pairs of immature humeri (*left*), radii (*center*), and ulnae (*right*), shown here in anterior view, are from a one-year-old and a six-year-old. Natural size.

9.1.5 Humeral Measurements (Figure 9.8)

Measurements of the humerus are used for stature estimation, age estimation, sex determination, biomechanical load calculations, and other analyses.

1. **Maximum humeral length** (Martin, 1928: 1010, #1; Buikstra and Ubelaker, 1994: 80, #40): The maximum length that can be measured between the top of the humeral head and the most distant point on the distal humerus. Measured with an osteometric board.
2. **Humeral biomechanical length** (Trinkaus, et al., 1999: 756): The distance between the top of the humeral head and the distalmost point on the lateral lip of the trochlea. Measured with an osteometric board.
3. **Humeral bicondylar (or bi-epicondylar) breadth** (Martin, 1928: 1010–1011, #4; Buikstra and Ubelaker, 1994: 80, #41): With a sliding caliper, measure the greatest distance between the medial and lateral epicondyles, making sure to keep the jaws of the caliper parallel to the long axis of the humeral shaft.
4. **Humeral midshaft circumference** (Martin, 1928: 1011, #7a): Determine the location of midshaft (preferably using 50% of humeral biomechanical length) and use a flexible cloth tape to determine the minimum circumference at that location.

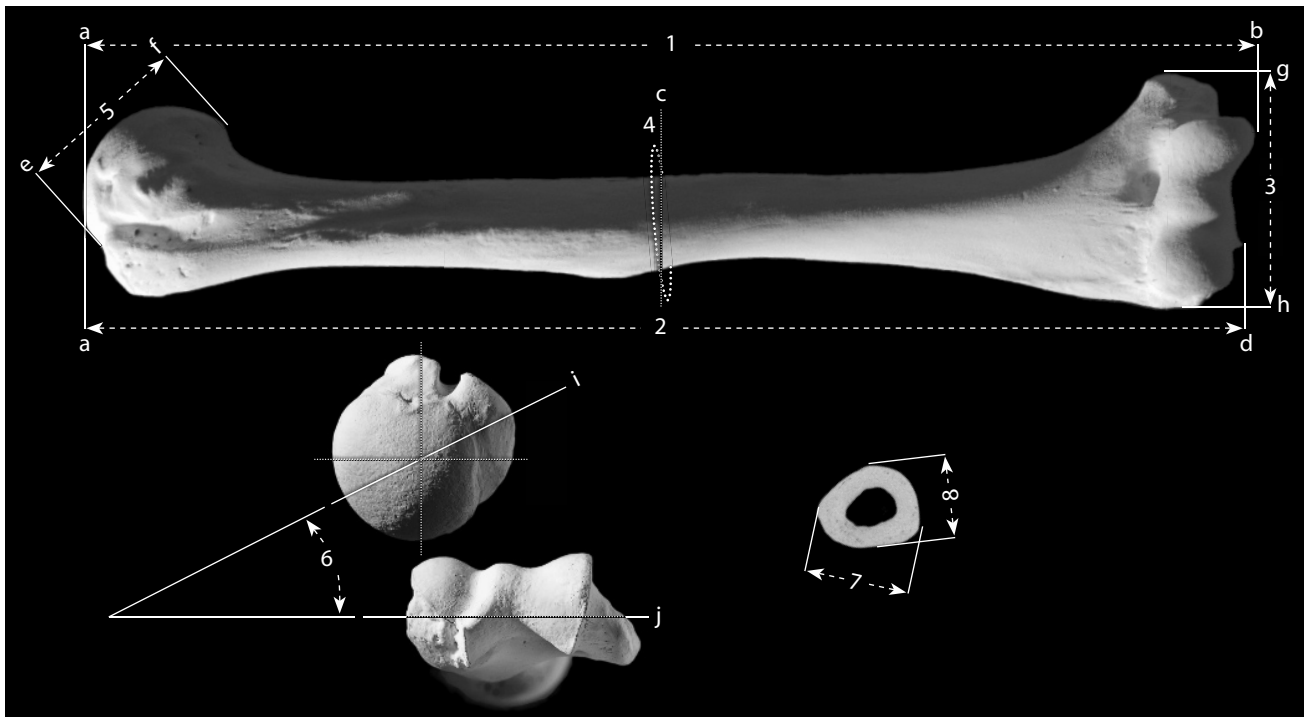


Figure 9.8 Humeral measurements. One-half natural size.

Locations: a) superiormost point of the head; b) point most distant from 'a', measured parallel to the shaft; c) 50% of '2'; d) distalmost point on lateral lip of trochlea; e) most lateral point of head ('e' and 'f' must be in the same paracoronal plane); f) most medial point of head (*ibid.*); g) medialmost point of medial epicondyle; h) lateralmost point of lateral epicondyle; i) midhumeral axis; j) distal articular axis.

Measurements: 1) maximum humeral length; 2) humeral biomechanical length; 3) humeral bicondylar (or epicondylar) breadth; 4) humeral midshaft circumference; 5) vertical head diameter; 6) humeral torsion; 7) maximum midshaft diameter (measured at 'c'); 8) minimum midshaft diameter (measured at 'c').

5. **Vertical head diameter** (Martin, 1928: 1011, #10; Buikstra and Ubelaker, 1994: 80, #42): Using a sliding caliper, measure the greatest distance between the margins of the head in a paracoronal plane.
6. **Humeral torsion** (Krahl and Evans, 1945; Larson, 2007): Position the humerus so that an imaginary line (the 'distal articular axis') drawn through the centers of the capitulum and the trochlea is parallel to the tabletop. Using a protractor or a torsionmeter, measure the angle between the tabletop and the midhumeral axis (a line that divides the proximal articular surface into anterior and posterior halves and passes through the greater tubercle between the insertion sites of the *infraspinatus* and *supraspinatus muscles*).
7. **Maximum midshaft diameter** (Martin, 1928: 1011, #5; Buikstra and Ubelaker, 1994: 80, #43): Determine the location of midshaft (50% of humeral biomechanical length) and use a sliding caliper to determine the largest cross-sectional dimension at that point.
8. **Minimum midshaft diameter** (Martin, 1928: 1011, #6; Buikstra and Ubelaker, 1994: 80, #44): Use a sliding caliper to determine the smallest cross-sectional dimension at midshaft.

9.1.6 Humeral Nonmetric Traits

- **Septal aperture:** In about 2%–11% of individuals (more common in females than males: Mays, 2008), the bone separating the olecranon and coronoid fossae becomes so thin that an opening between the two fossae is formed, a septal aperture. Usually scored as 0 (absent), or 1 (present).
- **Supracondylar process** (or **supratrochlear spur**): About 5–7 cm above the medial epicondyle, on the medial supracondylar ridge, some individuals develop an inferomedial projection which serves to anchor the *ligament of Struthers*. The ligament connects this process with the medial epicondyle. Usually scored as 0 (absent), or 1 (present).

9.2 Radius (Figures 9.7, 9.9–9.15)

9.2.1 Anatomy

The radius is the shortest of the three arm bones. It is named for its action, a turning movement about the capitulum of the humerus, which allows the bone to rotate relative to the more fixed ulna. The radius articulates proximally with the humerus at the capitulum and medially with the ulna on both proximal and distal ends. Distally, the radius articulates with two carpal bones of the wrist: the lunate (medially) and the scaphoid (laterally).

- a. The **radial head** is a round articular structure on the proximal end of the radius. It articulates, via its cupped proximal surface (**articular fovea** or **facet**), with the humeral capitulum, whereas the edge of the radial head (**articular circumference**) articulates with the radial notch of the ulna.
- b. The **radial neck** is the slender segment of the radius between the head and the radial tuberosity.
- c. The **radial** (or **bicipital**) **tuberosity** is a blunt, rugose, variably shaped structure on the anteromedial side of the proximal radius. It marks the insertion of the *biceps brachii muscle*, a flexor and weak medial rotator of the forearm, and a large *biceps bursa* that underlies this muscle.
- d. The **shaft** (or **body**) of the radius is the long, thin section between the radial tuberosity

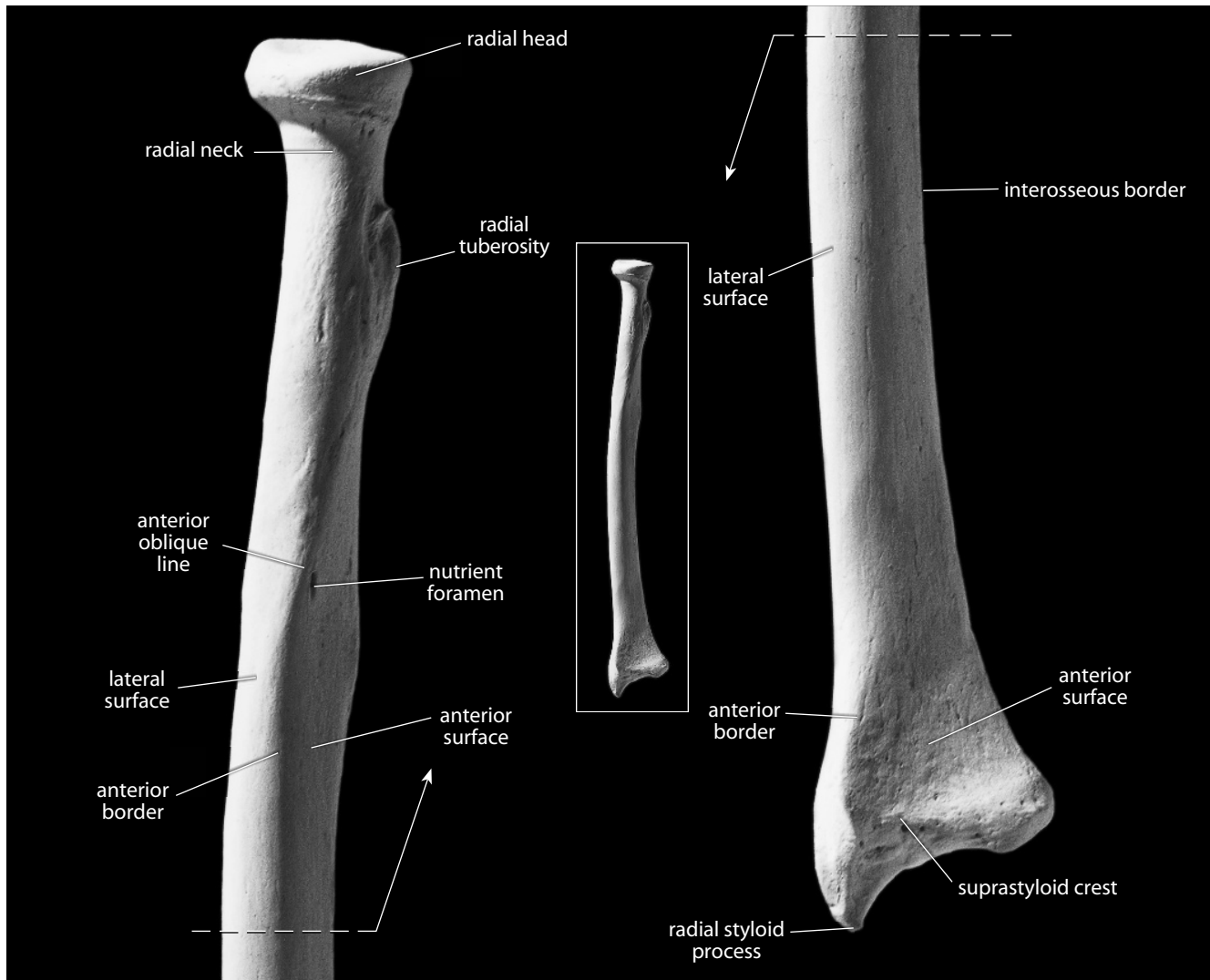


Figure 9.9 Right radius, anterior. *Left:* proximal portion; *right:* distal portion. Natural size.

and the expanded distal end. The shaft is divided into three named surfaces by three borders (or margins).

- e. The **anterior surface** is the portion of the shaft surface between the anterior and interosseous borders. It is broadest distally.
- f. The **posterior surface** lies between the posterior and interosseous borders.
- g. The **lateral surface** is bounded by the anterior and posterior borders.
- h. The **interosseous border** (or **crest**) is the sharp medial edge of the radial shaft. It serves as the attachment site for a fibrous membrane, the *interosseous membrane*, which divides the forearm into an anterior and a posterior compartment. These house and isolate the flexor and extensor groups of muscles that act across the wrist.
- i. The **anterior border** is continuous with the anterior oblique line and extends distally to the suprastyloid crest.

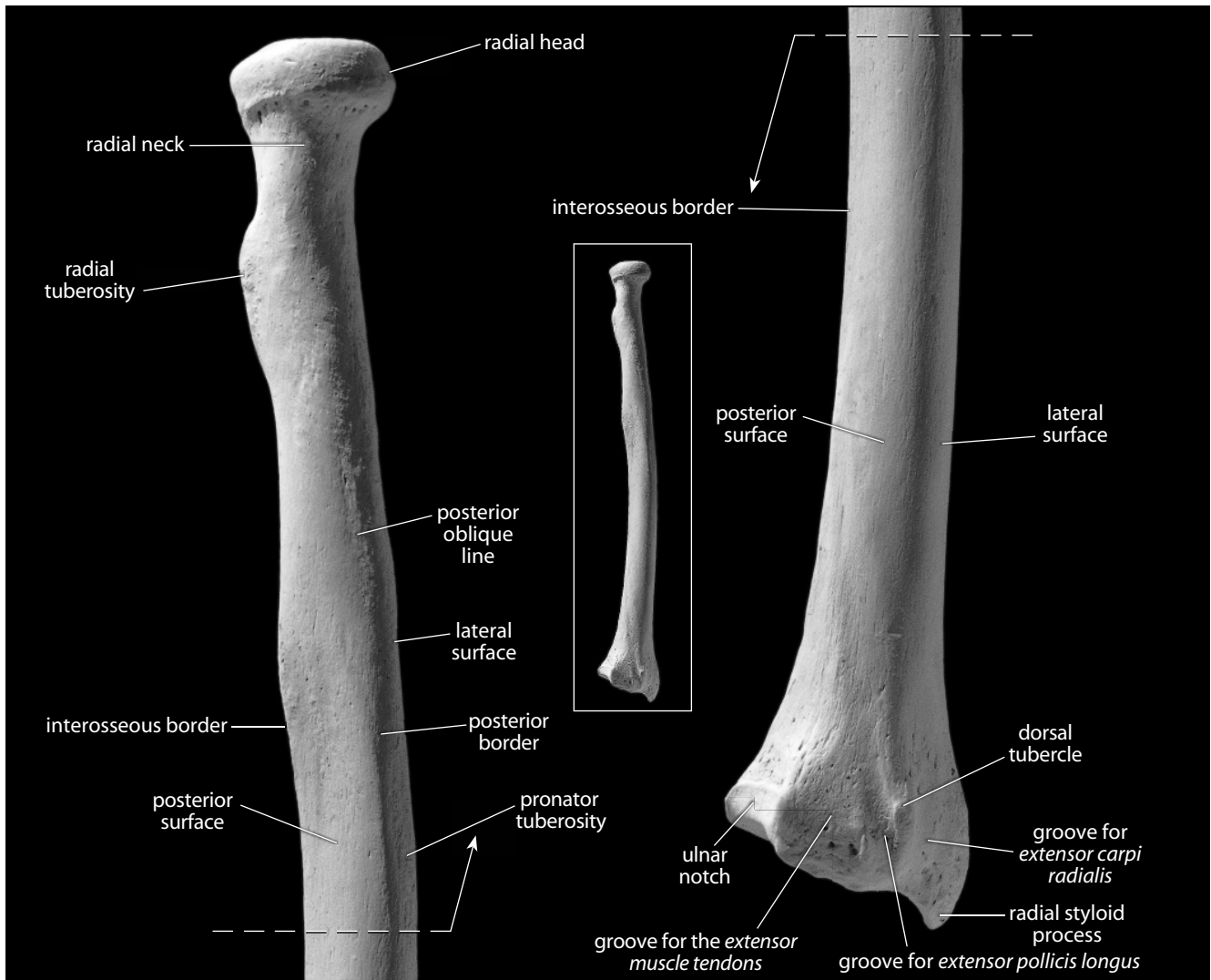


Figure 9.10 Right radius, posterior. *Left:* proximal portion; *right:* distal portion. Natural size.

- j. The **posterior border** runs distally towards the dorsal tubercle.
- k. The **nutrient foramen** exits the bone toward its distal end and is located on the anterior surface of the proximal half of the radius.
- l. The **anterior oblique line** is on the anterior surface of the shaft. It spirals inferolaterally from its origin at the base of the radial tuberosity. This line gives origin to extrinsic muscles of the hand.
- m. The **posterior oblique line** mirrors the more marked anterior oblique line, but on the posterior surface of the shaft. It spirals inferolaterally from the base of the radial tuberosity to the tuberosity for the *pronator teres muscle*.
- n. The **pronator tuberosity** (or **pronator teres impression**) is a midshaft roughening on the lateral surface marking the site of insertion of the *pronator teres muscle*.
- o. The **ulnar notch** is a concave articular hollow on the medial corner of the distal radius. It articulates with the distal end of the ulna.

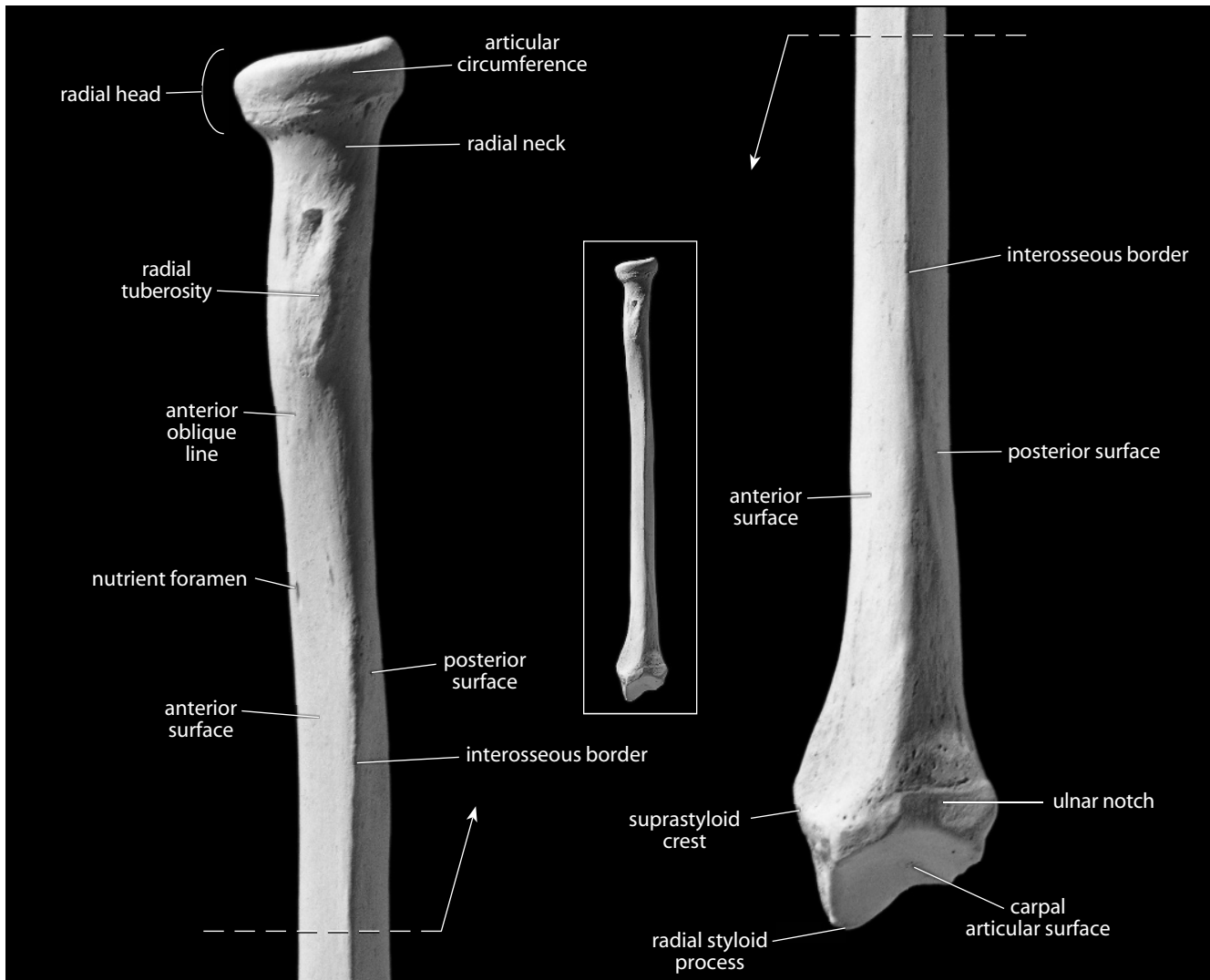


Figure 9.11 Right radius, medial. *Left*: proximal portion; *right*: distal portion. Natural size.

- p. The **carpal** (or **distal radial**) **articular surface** articulates with carpal bones—the lunate on the medial side, and the scaphoid on the lateral side.
- q. The **styloid process** is a sharp projection on the lateral side of the distal radius.
- r. The **suprastyloid crest** runs obliquely above the styloid process on the anterior surface. It serves as the attachment site of the *brachioradialis muscle*.
- s. The **dorsal** (or **Lister's**) **tubercle** is a large tuberosity on the posterior surface of the distal radius. The grooves between this and other tuberosities on the dorsum of the distal radius house the *tendons of extrinsic extensor muscles* of the hand.
- t. The **groove for the extensor muscle tendons** is the broad depression on the medial side of the posterior surface of the distal radius.
- u. The **groove for extensor pollicis longus** is immediately medial to the dorsal tubercle.
- v. The **groove for extensor carpi radialis** is the hollowing lateral to the dorsal tubercle.

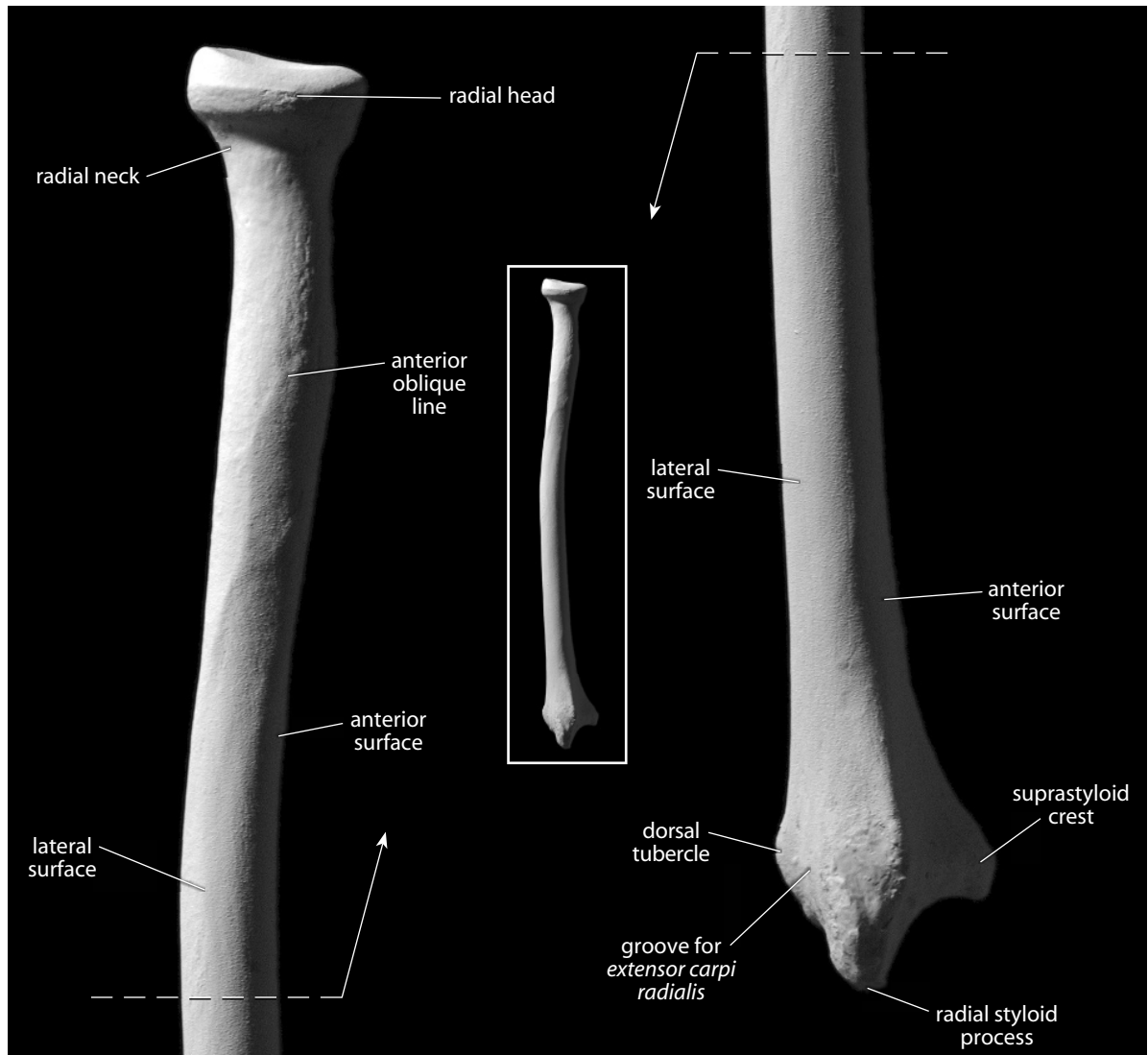


Figure 9.12 Right radius, lateral. *Left*: proximal portion; *right*: distal portion. Natural size.

9.2.2 Growth (Figure 9.7)

The radius ossifies from three centers: the shaft, the proximal epiphysis (head), and the distal epiphysis. The proximal epiphysis fuses first, beginning to fuse with the shaft at about 14–17 years in males, and about 11.5–13 years in females. The distal epiphysis begins to fuse slightly later: at about 16–20 years in males and at 14–17 years in females (Scheuer and Black, 2000).

9.2.3 Possible Confusion

Radial shaft segments might be mistaken for the ulna or fibula, and isolated distal ends might be mistaken for the clavicular notch of the manubrium, but the following features help identify fragments of the radius.

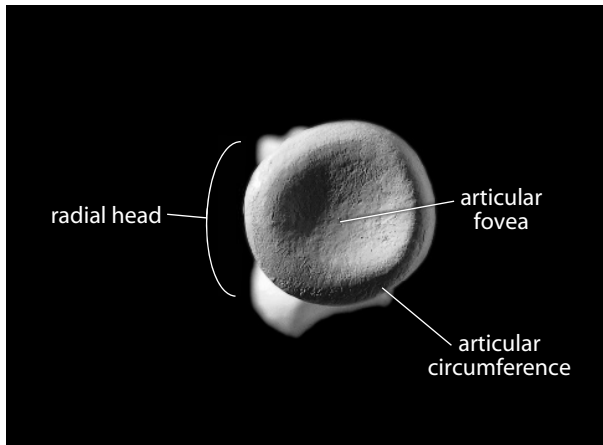


Figure 9.13 Right radius, proximal. Lateral is up, anterior is toward the left. Natural size.

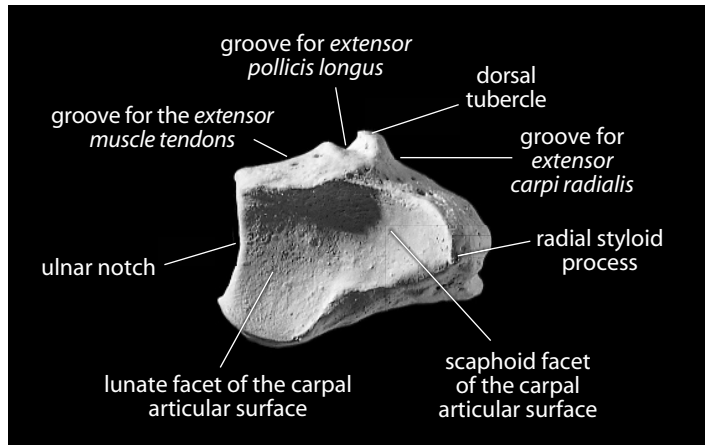


Figure 9.14 Right radius, distal. Dorsal is up, lateral is toward the right. Natural size.

- The ulnar shaft tapers continuously (the circumference decreases) from proximal to distal, whereas the radius does not (see cross sections in Chapter 14).
- The ulnar shaft has a sharp interosseous border, but the two other corners are not as evenly rounded as they are in the radius, which has a teardrop shape in cross section and a smoother, more uniform crest (see cross sections in Chapter 14).
- Most of the ulnar shaft is triangular (see cross sections in Chapter 14). The ulnar shaft only becomes round in cross section at its distal end. In contrast, the radial shaft is circular proximally and is a rounded triangle at midshaft. It is a broad, anteroposteriorly compressed oval with cortex that thins at more distal cross sections.
- The fibula, also a long slender bone with crests, is much more irregular in cross section and much longer than the radius (see cross sections in Chapter 14).
- The carpal (or distal radial) articulation has two discernible articular surfaces (or “facets,” see Figure 9.14), whereas the clavicular notch of the manubrium has only a single articular facet.

9.2.4 Siding

- For an intact radius, the ulnar notch is medial, the radial tuberosity and interosseous border are medial, the dorsal tubercles are posterior, and the styloid process is lateral.
- For an isolated proximal end, the tuberosity faces anteromedially. The medial portion of the proximal ulnar articular surface has the greatest proximodistal dimension.
- There is a small ridge on the posteromedial aspect of the neck, congruent with the superior aspect of the medial edge of the radial tuberosity.
- For an isolated segment of shaft, the interosseous border is medial, and the oblique line is anterior. The nutrient foramen exits the bone distally and is situated anteriorly on the shaft. The posterolateral surface has the greatest rugosity at about midshaft.
- For an isolated distal end, the anterior surface is smooth and flat, the posterior surface has extensor grooves, the ulnar notch is medial, and the styloid process is lateral. The styloid process is smooth on its anterior surface.

9.2.5 Radial Measurements (Figure 9.15)

Measurements of the radius are used for stature estimation, age estimation, sex determination, biomechanical load calculations, and other analyses.

1. **Maximum radial length** (Martin, 1928: 1014, #1; Buikstra and Ubelaker, 1994: 80, #45): Place the head of the radius against the stationary end of an osteometric board and use the sliding plate to measure the maximum distance to the distalmost tip of the styloid process.
2. **Radial biomechanical length** (Trinkaus, et al., 1999: 756–757): Using a spreading caliper or a large sliding caliper with inside points, measure the distance between the center (deepest point) of the radial head and the deepest point of the carpal (or distal radial) articular surface.
3. **Radial head anteroposterior diameter** (Martin, 1928: 1015, #5(1)): Using a sliding caliper, determine and measure the largest diameter of the head of the radius.
4. **Radial midshaft circumference** (Martin, 1928: 1015, #5(5)): Determine the location of midshaft (preferably using 50% of radial biomechanical length) and use a flexible cloth tape to determine the minimum circumference at that location.
5. **Radial anteroposterior midshaft diameter** (Martin, 1928: 1015, #5a; Buikstra and Ubelaker, 1994: 80, #46): Determine the location of midshaft as above, and use a sliding caliper to measure the anteroposterior diameter at that location.
6. **Radial mediolateral (or transverse) midshaft diameter** (Martin, 1928: 1015, #4a; Buikstra and Ubelaker, 1994: 80, #47): Determine the location of midshaft as above, and use a sliding caliper to measure the mediolateral diameter at that location.

9.2.6 Radial Nonmetric Traits

- There are no commonly cited nonmetric traits of the radius.

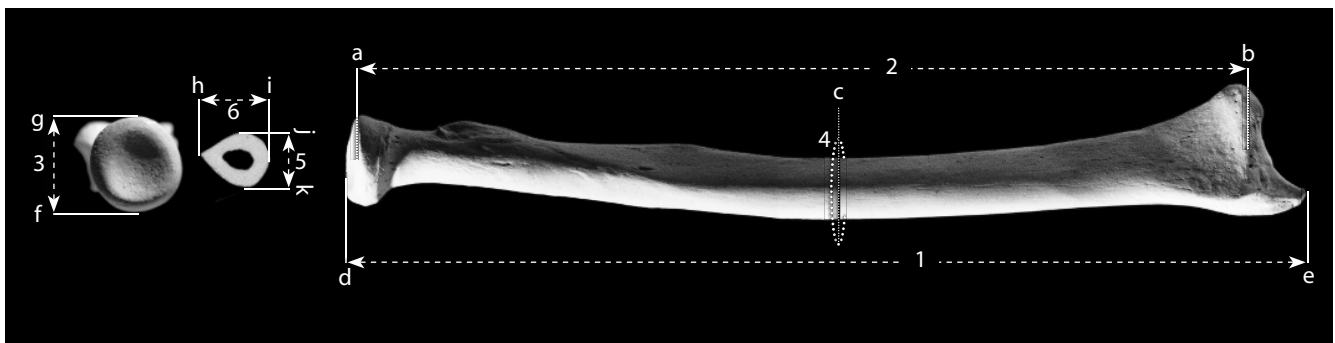


Figure 9.15 Radial measurements. One-half natural size.

Locations: a) deepest point of radial head; b) deepest point of distal articular surface; c) 50% of '2'; d) superiormost point on head; e) point on styloid process farthest from 'd'; f) posteriormost point on the articular circumference; g) anteriormost point on the articular circumference; h) medialmost point at midshaft; i) lateralmost point at midshaft; j) anteriormost point at midshaft; k) posteriormost point at midshaft.

Measurements: 1) maximum radial length; 2) radial biomechanical length; 3) radial head diameter; 4) radial midshaft circumference; 5) anteroposterior midshaft diameter (measured at 'c'); 6) mediolateral (or transverse) midshaft diameter (measured at 'c').

9.3 Ulna (Figures 9.7, 9.16–9.22)

9.3.1 Anatomy

The ulna is the longest, thinnest bone of the forearm. It articulates proximally with the trochlea of the humerus and with the head of the radius. Distally it articulates with the ulnar notch of the radius and with an articular disk that separates it from the carpal bones. This provides freer rotation of the hand and radius around the ulna than is seen in many other mammals.

- a. The **olecranon** (previously the **olecranon process**) of the ulna is the most proximal part of the bone. It is a massive, blunt process. The *triceps brachii muscle*, the primary extensor of the forearm, has its insertion on the tuberosity of this process.

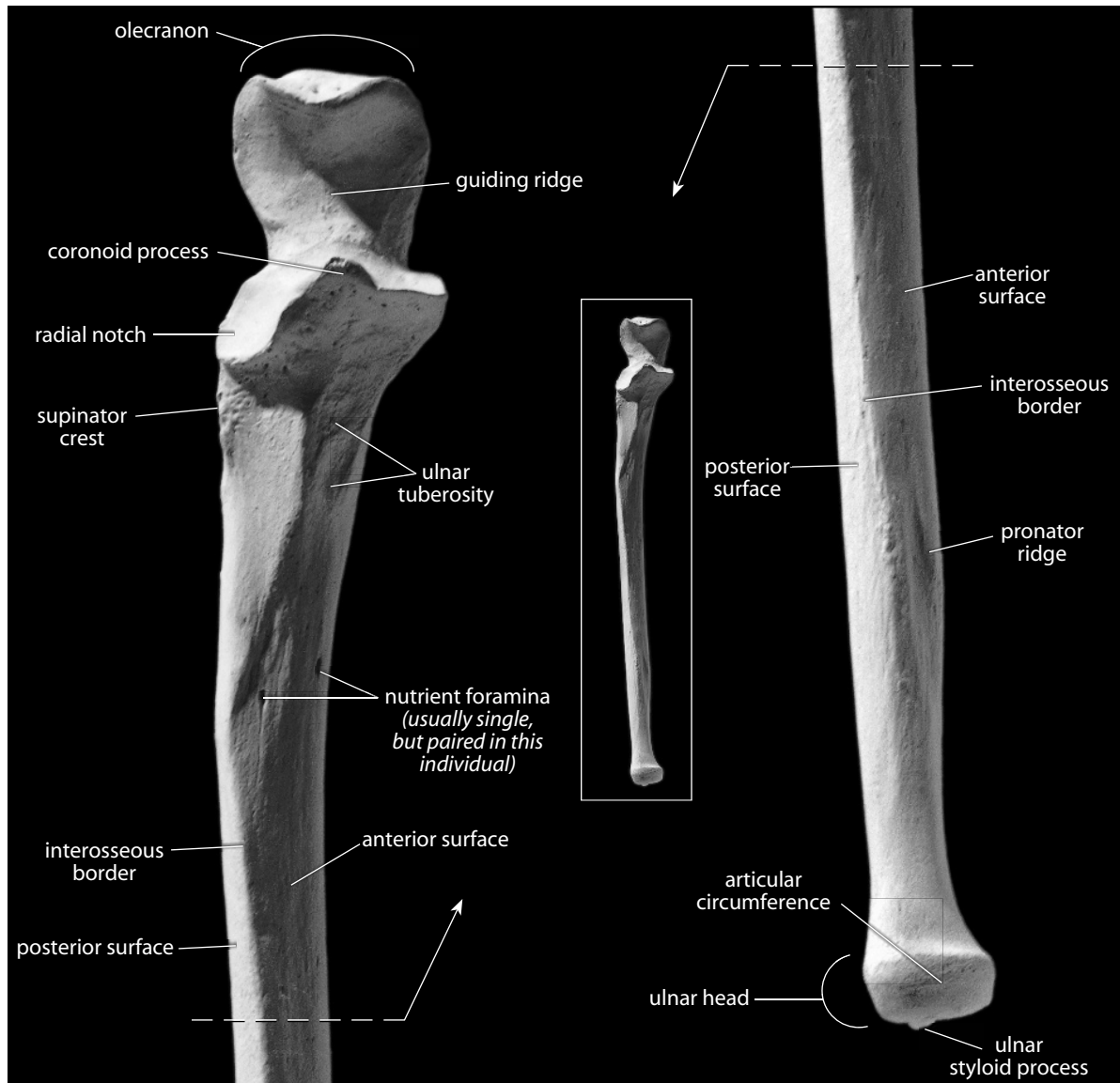


Figure 9.16 Right ulna, anterior. *Left*: proximal portion; *right*: distal portion. Natural size.

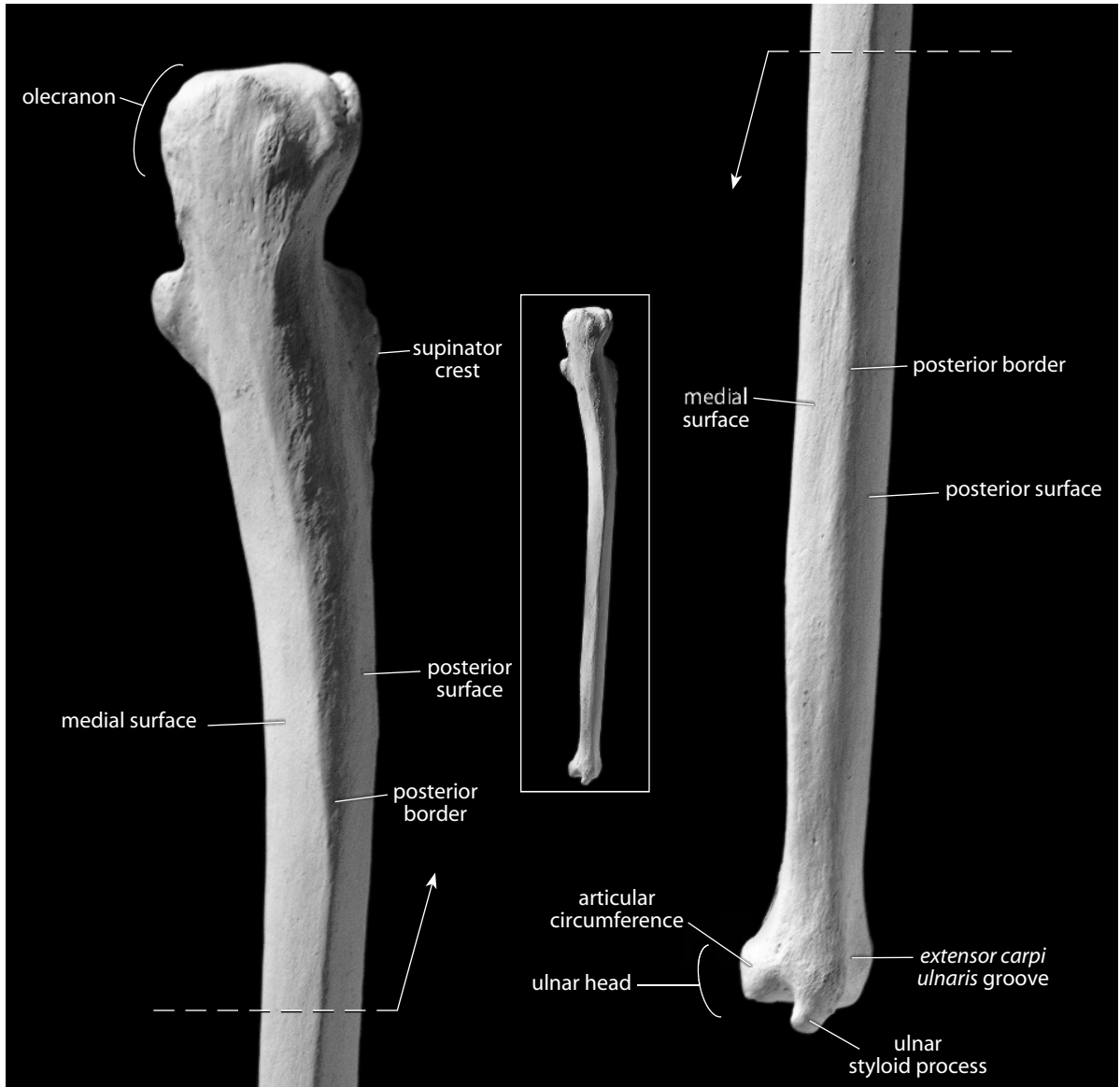


Figure 9.17 Right ulna, posterior. *Left*: proximal portion; *right*: distal portion. Natural size.

- b. The **trochlear** (or **semilunar**) **notch** of the ulna articulates with the trochlear articular surface of the distal humerus. In contrast to the more mobile radius, rotary motion is very restricted at the ulnar part of the elbow joint, sharply limiting the ulna in its ability to rotate around its long axis.
- c. The vertical **guiding ridge** separates the trochlear notch into medial and lateral portions.
- d. The **coronoid process** is the anterior, beak-shaped projection at the base of the trochlear notch.
- e. The **ulnar** (or **brachial**) **tuberosity** is a roughened depression immediately inferior to the coronoid process. It marks the insertion of the *brachialis muscle*, a flexor of the elbow that originates from the anterior surface of the humerus.

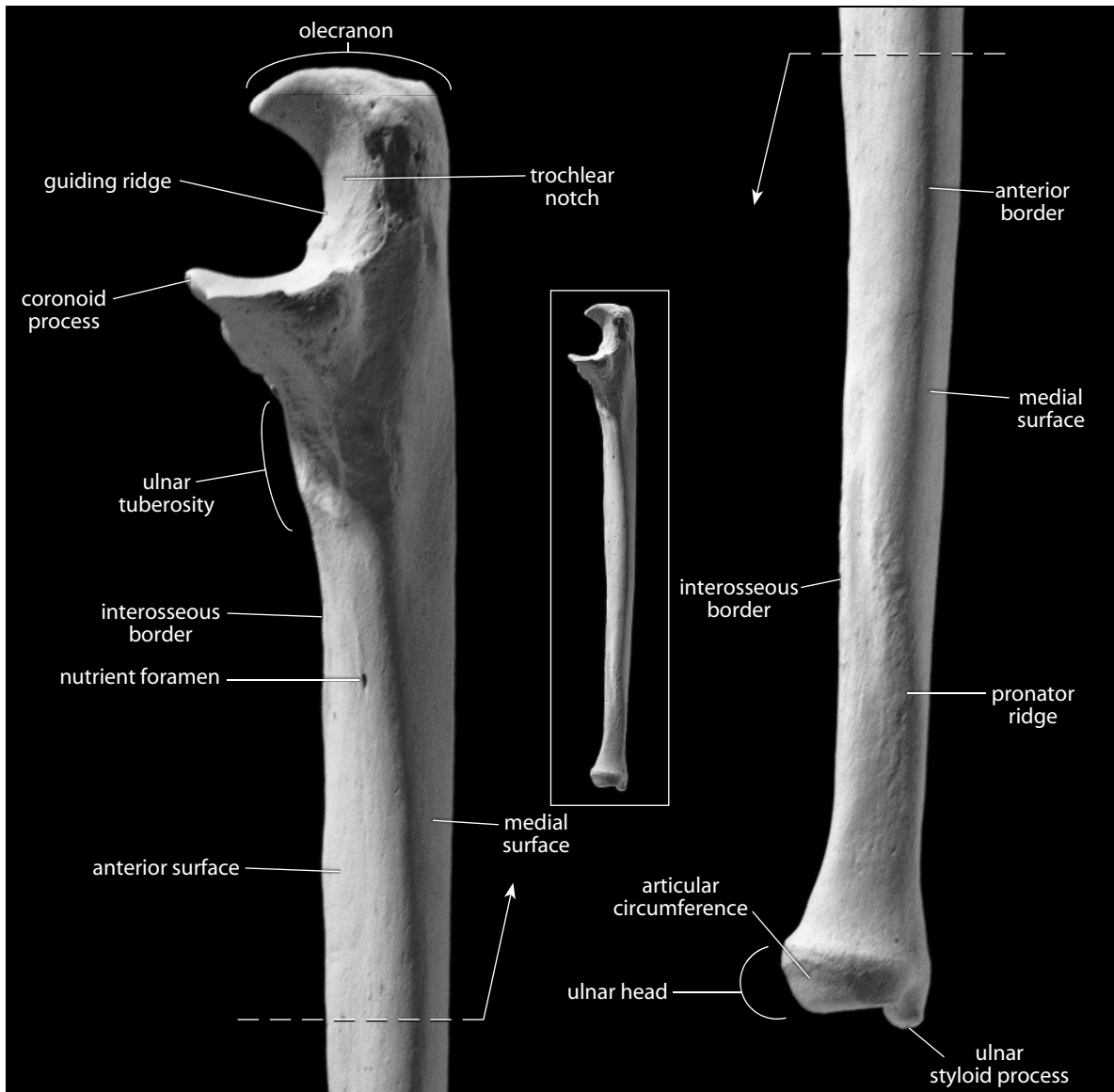


Figure 9.18 Right ulna, medial. *Left*: proximal portion; *right*: distal portion. Natural size.

- f. The **radial notch** is the small articular surface for the radius. It is located along the lateral margin of the coronoid process.
- g. The **shaft** (or **body**) is the long segment of bone between the brachial tuberosity and the inflated distal end of the ulna. The shaft is divided into three named surfaces by three borders (or margins).
- h. The **anterior surface** is the portion of the shaft surface between the anterior and interosseous borders.
- i. The **posterior surface** lies between the posterior and interosseous borders.
- j. The **medial surface** is bounded by the anterior and posterior borders.

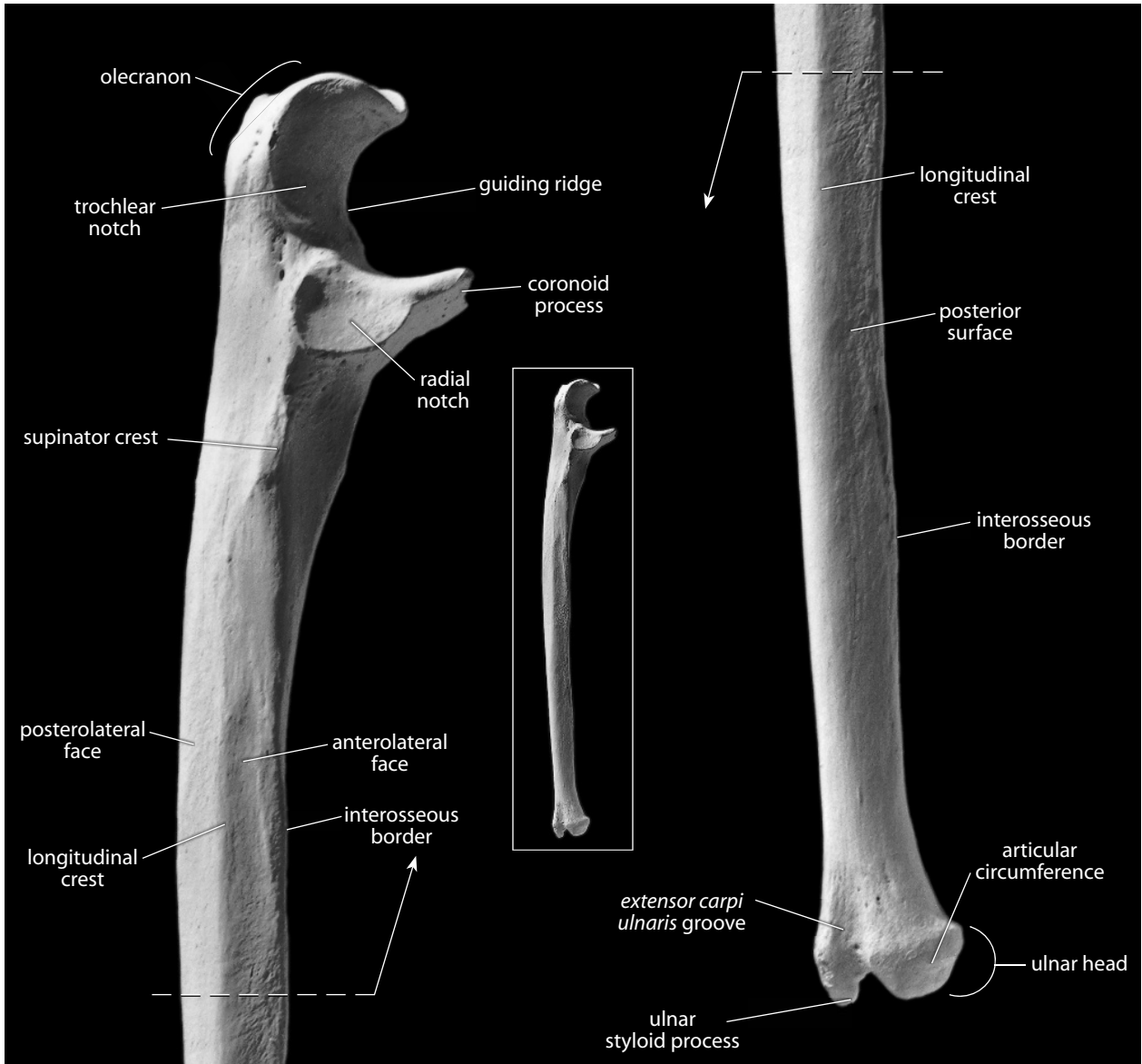


Figure 9.19 Right ulna, lateral. *Left*: proximal portion; *right*: distal portion. Natural size.

- k. The **interosseous border** (or **crest**) is the sharpest border on the ulna. It lies opposite the radius, on the lateral aspect of the ulnar shaft between the anterior and posterior surfaces.
- l. The **anterior** (or **medial**) **border** is thick and rounded, originating medial to the ulnar tuberosity and running along the anteromedial shaft. The distal one-third of the border angles posteriorly, and it terminates near the medial side of the styloid process.
- m. The **posterior border** runs distally towards the styloid process.
- n. The **longitudinal crest** divides the posterior surface into two portions: a posterolateral face and an anterolateral face.
- o. The **nutrient foramen** exits the bone in a distal direction and is found on the anteromedial ulnar shaft.

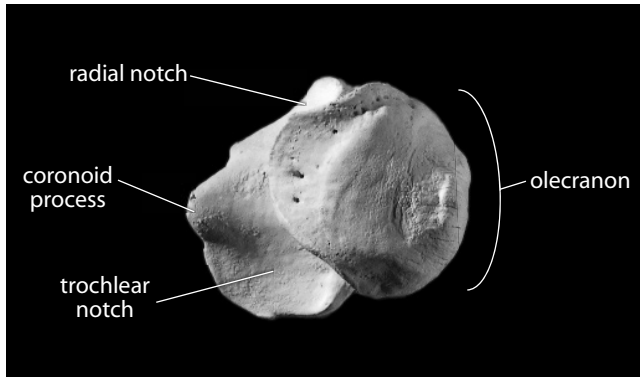


Figure 9.20 **Right ulna, proximal.** Lateral is up, anterior is towards the left. Natural size.

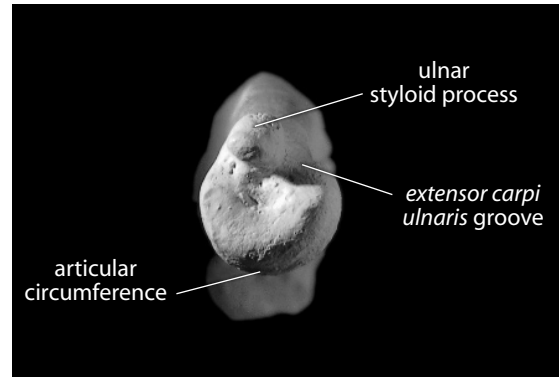


Figure 9.21 **Right ulna, distal.** Anterior is down, lateral is towards the right. Natural size.

- p. The **supinator crest** is just superior to the interosseous border but with a more anterosuperior orientation. It serves as the origin for the *supinator muscle*.
- q. The **pronator ridge** is a short, variably expressed ridge on the distal one-fourth of the shaft. It is located anteromedially and is the origin site for the *pronator quadratus muscle*.
- r. The **ulnar head** is the enlarged distal end of the bone.
- s. The **ulnar styloid process** is the sharp, distalmost projection of the ulna. It is set on the posteromedial corner of the bone. Its end gives attachment to the *ulnar collateral ligament* of the wrist. It is separated from the remainder of the head by a deep groove or pit, the **fovea**.
- t. The **extensor carpi ulnaris groove** is adjacent to the styloid process, located proximolaterally to it. It houses the tendon of the *extensor carpi ulnaris muscle*, a dorsiflexor and adductor of the hand at the wrist.
- u. The **articular circumference** (or **radial** or **circumferential articulation**) is the distal, lateral, round articulation that conforms to the ulnar notch of the radius in the same way that the radial head conforms to the radial notch of the proximal ulna.

9.3.2 Growth (Figure 9.7)

The ulna ossifies from three centers: the shaft, the proximal epiphysis (olecranon), and the distal epiphysis. The proximal epiphysis fuses first, beginning to fuse with the shaft at about 13–16 years in males, and about 12–14 years in females. The distal epiphysis begins to fuse slightly later: at about 17–20 years in males and at 14–15 years in females (Scheuer and Black, 2000).

9.3.3 Possible Confusion

The ulnar proximal and distal ends are diagnostic, but isolated shafts could be mistaken for radial or fibular shafts.

- The radial shaft is more triangular, or teardrop-shaped, in cross section. It has two rounded corners and one sharp corner. Radial shafts do not taper distally as the less regular ulnar shaft does (see cross sections in Chapter 14).

- The fibular shaft is much more irregular in cross section, with multiple sharp corners (see cross sections in Chapter 14).
- See the description of the radial shaft for further details.

9.3.4 Siding

- For an intact ulna, the olecranon is proximal and posterior, the radial notch is lateral, and the interosseous border is lateral.
- For an isolated proximal end, use the same criteria given earlier for an intact ulna. Note also that the brachial tuberosity is medially displaced.
- For an isolated shaft segment, the shaft tapers distally, and the nutrient foramen exits the bone distally and is located on the anterior shaft surface. The interosseous border is lateral. The shaft surface anterior to the crest is more hollowed proximally, but this may flatten distally. At midshaft and distally, the surface posterior to the interosseous border may display a narrow groove that is variable in expression.
- For an isolated distal end, the styloid process is posterior, and the groove for the *extensor carpi ulnaris* is lateral to the process.

9.3.5 Ulnar Measurements (Figure 9.22)

Measurements of the ulna are used for stature estimation, age estimation, sex determination, biomechanical load calculations, and other analyses.

1. **Maximum ulnar length** (Martin, 1928: 1017, #1; Buikstra and Ubelaker, 1994: 81, #48): Place the olecranon against the stationary end of an osteometric board and use the sliding plate to measure the maximum distance to the distalmost tip of the styloid process.

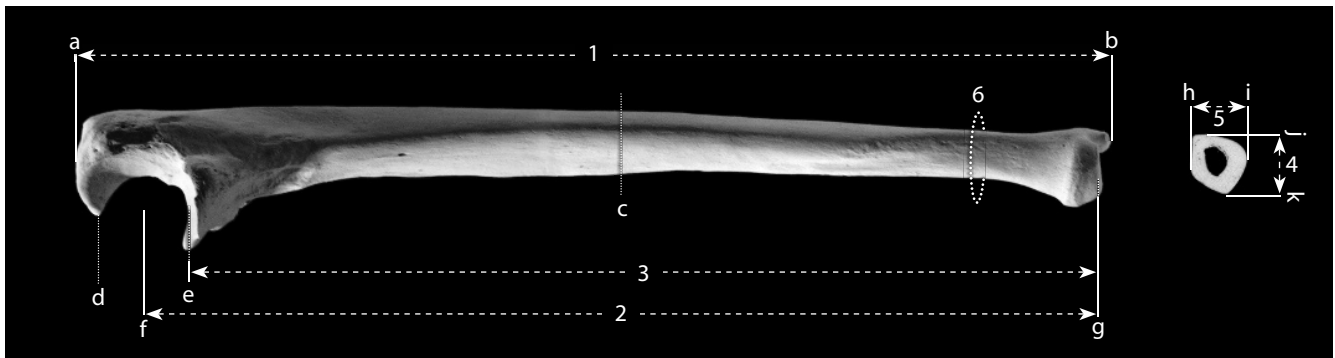


Figure 9.22 Ulnar measurements. One-half natural size.

Locations: a) superiormost tip of olecranon; b) point on the styloid process most distant from 'a'; c) midshaft (50% of '2'); d) most proximal point on trochlear surface; e) most distal point on trochlear surface; f) proximodistal midpoint of trochlear surface; g) deepest (most proximal) point on the distal surface of the ulnar head, excluding the *extensor carpi ulnaris* groove; h) lateralmost point at midshaft; i) medialmost point at midshaft; j) anteriormost point at midshaft; k) posteriormost point at midshaft.

Measurements: 1) maximum ulnar length; 2) ulnar biomechanical length; 3) ulnar physiological length; 4) maximum anteroposterior diameter (measured at 'c'); 5) maximum mediolateral (or transverse) diameter (measured at 'c'); 6) ulnar minimum circumference.

2. **Ulnar biomechanical length** (Trinkaus et al., 1999: 756): With a spreading caliper or a large sliding caliper, measure the distance between the proximodistal midpoint of the trochlear notch and the centerpoint of the distal head.
3. **Ulnar physiological length** (Martin, 1928: 1018, #2; Buikstra and Ubelaker, 1994: 81, #51): Using a large sliding caliper with inside points or a spreading caliper, place one tip of the caliper into the deepest (most distal) point of the trochlear notch, and measure the minimum distance to the deepest (most proximal) point on the ulnar head (excluding the *extensor carpi ulnaris* groove).
4. **Maximum anteroposterior diameter** (Martin, 1928: 1020, #11; Buikstra and Ubelaker, 1994: 81, #49): Determine the point along the shaft where the interosseous crest has its greatest development. Use a sliding caliper to measure the anteroposterior diameter at this point.
5. **Maximum mediolateral (or transverse) diameter** (Martin, 1928: 1020, #12; Buikstra and Ubelaker, 1994: 81, #50): Determine the point along the shaft where the interosseous crest has its greatest development. Use a sliding caliper to measure the mediolateral diameter at this point.
6. **Ulnar minimum circumference** (Martin, 1928: 1018, #3; Buikstra and Ubelaker, 1994: 81, #52): Use a flexible cloth tape to determine the minimum measurable circumference of the diaphysis (usually near the distal end of the shaft).

9.3.6 Ulnar Nonmetric Traits

- **Trochlear notch shape:** Examine the geometry of the articular surface(s) in the ulnar trochlear notch and characterize the shape of the surface(s) as being one of the following: 1 (continuous), 2 (hour-glass), 3 (discrete), 4 (indent), 5 (island), 6 (island and hour-glass), 7 (discrete and hour-glass), or 8 (indented and hour-glass).

9.4 Functional Aspects of the Elbow and Wrist

The elbow joint has a single joint capsule, but its three different bony elements operate differently within the capsule. The humeroulnar joint is a simple hinge, whereas the humeroradial joint is a pivot joint resembling a ball-and-socket joint. The proximal and distal radioulnar joints are mirror images, allowing the radius to spin during pronation and supination. The axis of rotation passes obliquely across the forearm through the proximal radius and distal ulna. The hand articulates with the forearm through the radiocarpal articulation at the wrist.

Actions of flexion and extension at the elbow joint are accomplished by contraction of two major antagonists, the *biceps brachii* (flexor) and *triceps brachii* (extensor). The former has two origins: the long head from the supraglenoid tubercle of the scapula (the tendon passes through the intertubercular groove of the humerus) and the short head from the tip of the scapular coracoid process. The insertion of this muscle on the radial tuberosity makes it a powerful flexor of the forearm at the elbow. It can also supinate the forearm. The *triceps brachii* is also a complex muscle, with three heads of origin: the long head from the infraglenoid tubercle of the scapula and the lateral and short heads from the posterior surface of the humeral shaft. This major extensor of the forearm at the elbow inserts on the olecranon of the ulna.

In addition to flexion and extension at the elbow, the unique articulation of the elbow allows for pronation and supination of the forearm. The *pronator teres muscle* originates from the medial epicondyle and medial supracondylar ridge of the humerus and inserts on the lateral radial shaft. Supination occurs when the *biceps brachii* works on the already pronated forearm. In addition, the *supinator muscle* originates on the lateral epicondyle of the humerus and the lateral surface of the

proximal ulna. It crosses to the anterior oblique line of the proximal radius, and its contraction thus causes supination.

Many muscles surround the radius and ulna. Most of these function via tendons to cause flexion and extension at the wrist and within the hand. Flexors are found in a compartment anterior to the radius and ulna, whereas extensors are located in a compartment posterior to these bones. These extrinsic hand muscles and their tendons can be easily palpated.

Chapter 10

HAND: CARPALS, METACARPALS, AND PHALANGES

THE HAND is a complex structure that represents the tetrapod's distal limb segment. It is the modified end of the ancestral fish fin, a structure based on jointed bony rays. In the generalized reptilian hand, a set of small wrist bones (carpals) forms the foundation for five digits. Each digit is composed of one large proximal segment (a metacarpal) and a chain of additional bones (the phalanges). Digital reduction and modification have occurred in a great variety of mammals, from the wings of bats to the single toes of modern horses. Humans have retained the generalized pattern of five digits. There are a total of 27 bones in each human hand, eight carpal bones arranged in two rows, followed distally by a single row of five metacarpals. Farther distally, there is a single row of five proximal phalanges, a single row of four intermediate phalanges, and a single row of five distal, or terminal, phalanges.

In addition to the 27 major hand bones, there are small bones called **sesamoid bones** that lie within tendons of the hand. These are not usually recovered and are rarely studied by osteologists, who should nevertheless always be alert to their presence as they are of considerable functional significance. In the hand, a pair of sesamoids is usually found on the palmar aspect of the first metacarpal head. Figures 10.1–10.3 summarize and illustrate articulations within the hand.

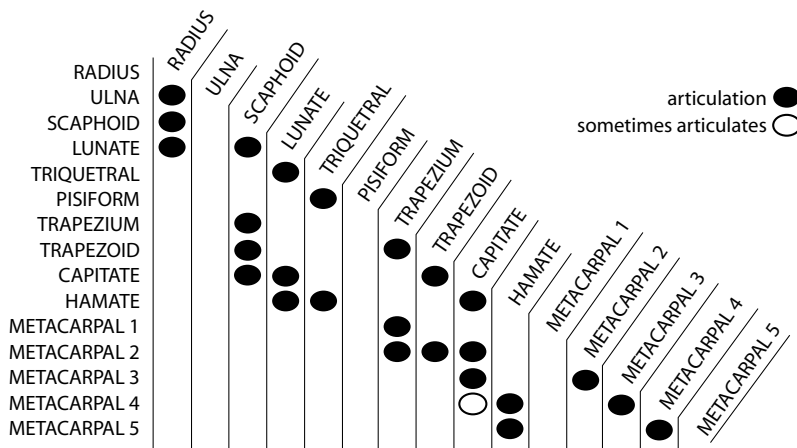


Figure 10.1 Articulation of bones in the adult human wrist and hand.

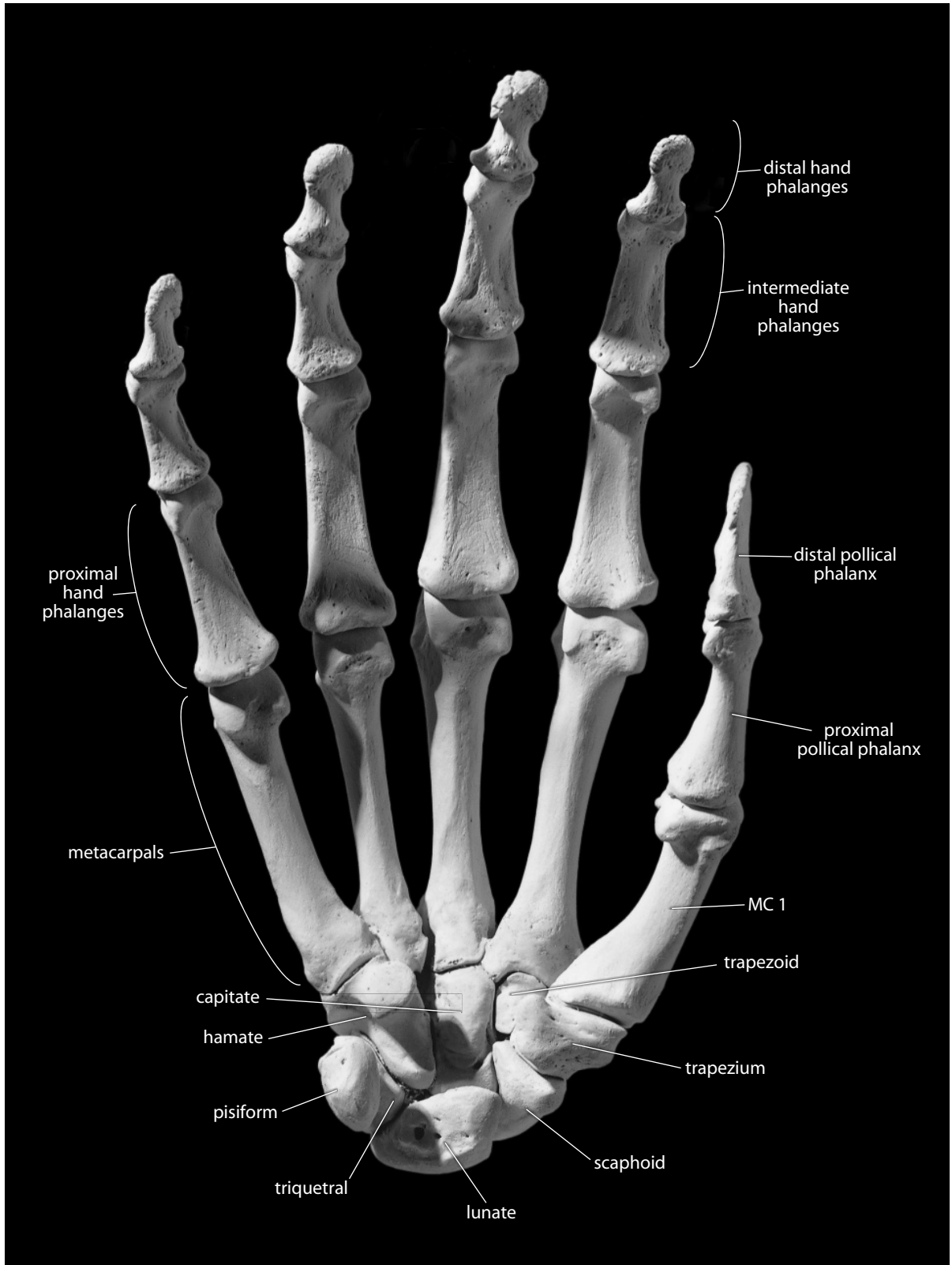


Figure 10.2 Right hand, palmar (anterior). Small sesamoid bones not included. Natural size.

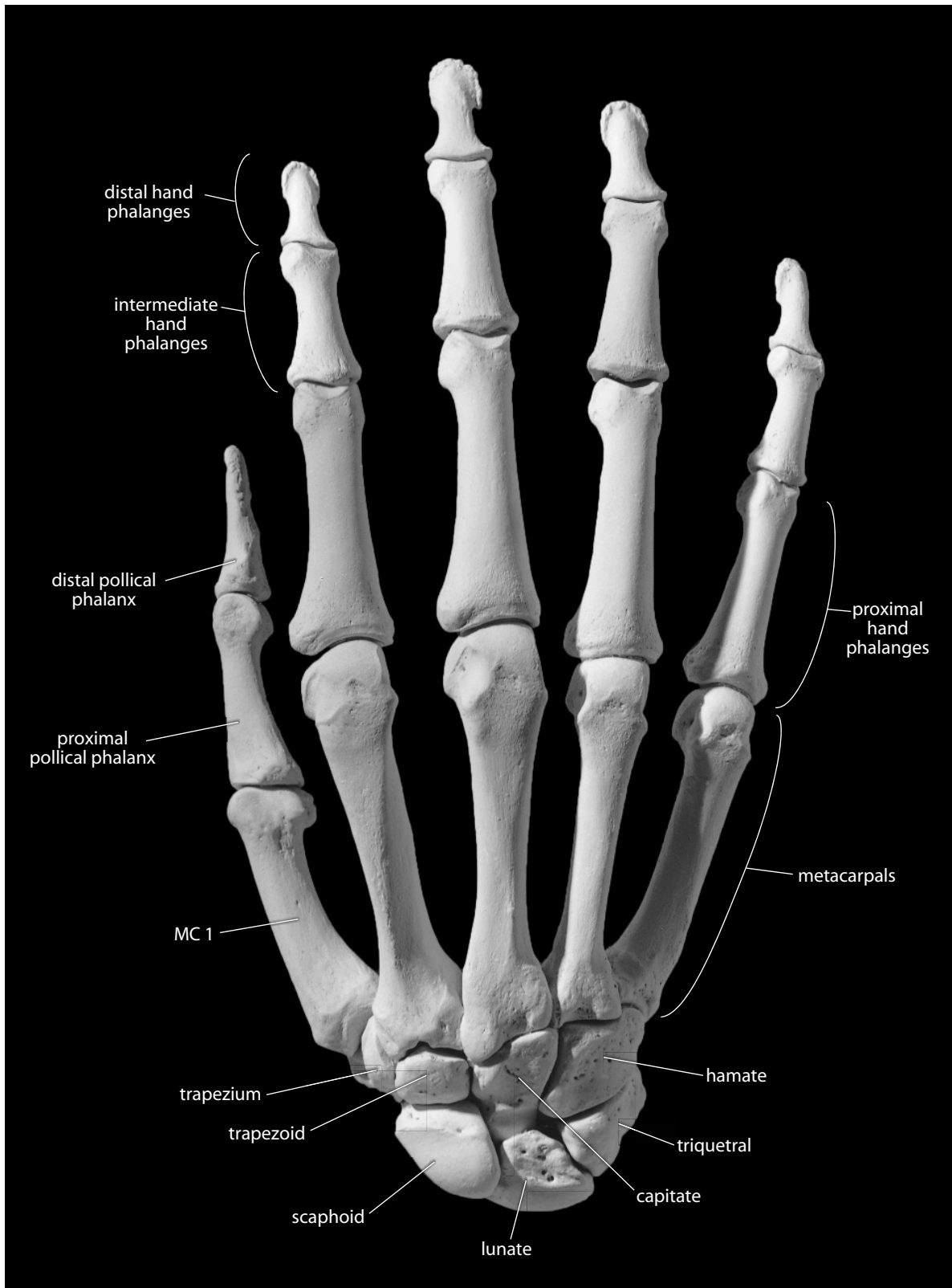


Figure 10.3 Right hand, dorsal (posterior). Small sesamoid bones not included. Natural size.

Elements of the hand skeleton are described in three categories: the **carpals**, the **metacarpals**, and the **hand phalanges**. In the carpal region of the hand, as in the tarsal region of the foot, a variety of different names have been applied to each bone as anatomical nomenclature has evolved through the years. For readers curious about this history, O’Rahilly (1989) provides a good summary.

Before analyzing the various elements that make up the hand, it is useful to note the importance of anatomical nomenclature in the study of the hand. In dealing with elements of the hand, it is easy to become confused by the terms “anterior,” “posterior,” “medial,” and “lateral” because these terms can only be applied when the specimen is in standard anatomical position. For this reason, it is useful to supplement the directional terms when possible, using the following sets of synonyms:

- anterior = palmar
- posterior = dorsal
- medial = ulnar = little finger side
- lateral = radial = thumb side

The term **ray** is often applied to each finger, or toe, including the phalanges and metacarpal of the digit. By convention, the thumb ray, or **pollex**, is identified as ray number 1. The index finger is ray 2, the middle finger is ray 3, the ring finger is ray 4, and the little finger is ray 5.

10.1 Carpals (Figures 10.4–10.11)

The eight bones of the adult wrist are often described as cubical in shape with six surfaces, but this is a misleading characterization. Each bone has a unique, diagnostic shape. For this reason, identification is straightforward. An introduction to the functional anatomy of the wrist facilitates study of the individual wrist elements. The palmar surface of the carpus, or wrist, bears four major projections. The hook of the hamate and the pisiform underlie the medial edge of the palm at the base of metacarpal 5 (MC 5). The scaphoid tubercle and crest of the trapezium underlie the lateral edge of the palm, at the base of the thumb, or pollical, metacarpal (MC 1). In life there is a fibrous band stretched transversely between these carpal elevations. This band, the *flexor retinaculum*, creates a **carpal tunnel** through which *flexor tendons* of the wrist pass.

The carpals are divided into a proximal row incorporating (from radial to ulnar) the **scaphoid**, the **lunate**, the **triquetral**, and the **pisiform**. The scaphoid and lunate both articulate with the radius. The distal row of carpals, again from radial to ulnar, is composed of the **trapezium** (or **greater multangular**), the **trapezoid** (or **lesser multangular**), the **capitate**, and the **hamate**.

10.1.1 Scaphoid (Figure 10.4)

The scaphoid bone (also known as the hand navicular) is shaped like a boat, and is one of the largest carpal bones. It is the most lateral and proximal carpal, interposed between the radius and the trapezium, at the base of the thumb.

- a. The **scaphoid tubercle** is a blunt, nonarticular projection adjacent to the hollowed capitate facet on the lateral edge of the bone. The tubercle is one of four attachment points for the *flexor retinaculum*, a fibrous band across the wrist.
- b. The **facet for the head of the capitate** is the large concave facet on the proximal side of the scaphoid.
- c. The crescent-shaped **facet for the lunate** is also on the proximal side of the scaphoid, but is on the medial edge of the bone.




Figure 10.4 Right scaphoid. Palmar is up. *Left:* view from the capitate; *right:* view from the radius. Natural size.

- d. The **radial facet** is the single, convex facet on the distal end of the scaphoid.
 - e. The **facet for the trapezoid** runs along the dorsolateral edge of the bone towards the tubercle.
 - f. The **facet for the trapezium** is found at the lateral end of the dorsal side of the bone.
- **Anatomical siding:** The facet for the head of the capitate is distal. The scaphoid tubercle is on the palmar surface and is lateral (toward the thumb).
 - **Positional siding:** Hold the scaphoid with the facet for the capitate facing you and the tubercle pointed up. The tubercle leans toward the side from which the bone comes.

10.1.2 Lunate (Figure 10.5)

The lunate has a shape that recalls the form of a crescent moon. The deeply concave surface articulates with the capitate, and the large, broad articulation opposite this shares the distal radial articular surface with the scaphoid. The lunate has five distinct articular facets:

- a. The **facet for the radius** is the large, convex articular surface that covers much of the proximomedial surface.
- b. The **facet for the scaphoid** is crescent-shaped and found on the proximolateral surface.
- c. The deeply concave **facet for the head of the capitate** is adjacent to the scaphoid facet, and is the most lateral of the three remaining facets spanning the distal surface.
- d. The **facet for the triquetral** is somewhat triangular, tapering as it nears the medial tip of the bone.

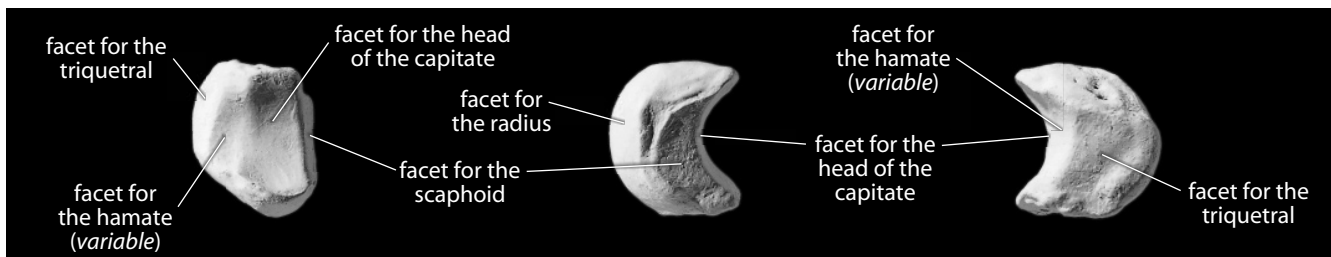


Figure 10.5 Right lunate. *Left:* view from the capitate; dorsal is up. *Middle:* view from the scaphoid, palmar is up. *Right:* view from the triquetral, palmar is up. Natural size.

- e. The **facet for the hamate** is the smallest distal facet, and it separates the other two facets.
 - **Anatomical siding:** The facet for the radius is proximal, and the facet for the capitate is distal. The long, narrow facet for the scaphoid is lateral (on the thumb side). The remaining facet, for the triquetral, is displaced dorsally. The largest nonarticular surface is palmar.
 - **Positional siding:** Position the lunate with concave facet for the capitate facing you and the flat nonarticular surface kept horizontal. The tapering medial end will point up and will be leaning towards the side from which the bone comes.

10.1.3 Triquetral (Figure 10.6)

The triquetral is the third bone from the thumb side in the proximal carpal row. It has three main articular surfaces (hence its name):

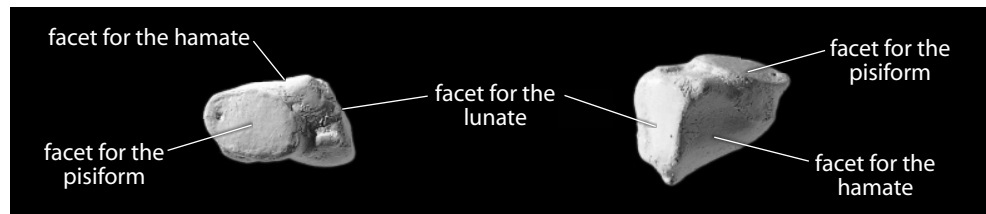


Figure 10.6 **Right triquetral.** *Left:* palmar view; lateral is up. *Right:* view from the hamate; palmar is up. Natural size.

- a. The **facet for the hamate** is the largest facet and is located distally.
- b. The **facet for the lunate** is lateral to, but continuous with, the facet for the hamate.
- c. The distinctive **facet for the pisiform** is the single, circular, isolated, and elevated facet. It is the smallest of the three facets, located on the palmar, medial surface of the bone.
 - **Anatomical siding:** The facet for the pisiform is palmar and medial. The facet for the hamate is distal. The lunate facet is lateral to, but continuous with, this facet.
 - **Positional siding:** Hold the common edge between the two largest facets toward you and oriented vertically. When the facet for the pisiform faces up, it points toward the side from which the bone comes.

10.1.4 Pisiform (Figure 10.7)

The pisiform bone is pea-shaped, with one side flattened by the triquetral articular facet. The pisiform is the smallest of the carpals. Because it develops within a tendon, it is actually a sesamoid bone. There are other, much smaller sesamoid bones found embedded in flexor tendons, for example, at some metacarpophalangeal and interphalangeal joints.

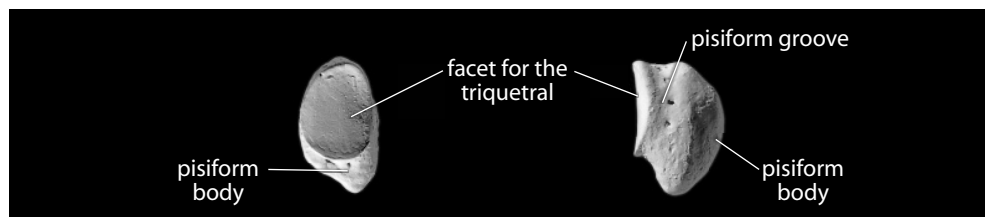


Figure 10.7 **Right pisiform.** *Left:* view from the triquetral; distal is down. *Right:* view from the proximal, palmar hamate end; the triquetral facet is up and faces the left (dorsal). Natural size.

- a. The nonarticular **pisiform body** is one of the four attachment points for the *flexor retinaculum*.
 - b. The single, ovoid **facet for the triquetral** is on the dorsal side of the bone.
 - c. The **pisiform groove** runs between the body and the facet on the radial side of the bone.
- **Anatomical siding:** The nonarticular body of the pisiform underlies the ulnar corner of the base of the palm. *Note:* The morphological variation of this bone makes siding accurate in only about 85–90% of all cases; the bone illustrated in Figure 10.7 is an example of a bone for which this siding method will *not* work.
 - **Positional siding:** Hold the facet toward you and turn the bone until the bulk of the nonarticular surface that is visible in this view is up. The groove and the bulk of this visible surface is displaced toward the side from which the bone comes. *Note:* the bone illustrated in Figure 10.7 is an example of a bone for which this siding method will *not* work.

10.1.5 Trapezium (Figure 10.8)

The trapezium (sometimes called the greater multangular) is an irregularly sided bone of medium size. It is distinguished by its largest facet, a saddle-shaped articular surface for the base of MC 1 (thumb), and by a long, raised, narrow tubercle, or crest.

- a. The **trapezial ridge** (formerly the **crest** or **tubercle**) is the elongate, proximodistally oriented projection on the palmar surface. This crest serves as an attachment point for the *flexor retinaculum*.
 - b. The **trapezial groove** is on the medial side of the crest and houses the *tendon of the flexor carpi radialis muscle*.
 - c. The sellar **facet for MC 1** is the largest facet on the bone.
 - d. The **facet for MC 2** is a small facet found on the distal apex of the trapezium.
 - e. The **facet for the trapezoid** is found on the medial side of the bone, sandwiched between the facet for MC 2 and the facet for the scaphoid.
 - f. The **facet for the scaphoid** is the most proximal facet on the bone, often appearing continuous with the facet for the trapezoid.
- **Anatomical siding:** The trapezial ridge is palmar. The groove adjacent to this tubercle is medial (toward the center of the hand). The sellar facet for MC 1 is distal and faces laterally.
 - **Positional siding:** Place the bone on a flat surface with the tubercle on top and away from you, and the concave facets on either side. The groove adjacent to the tubercle is on the side from which the bone comes.

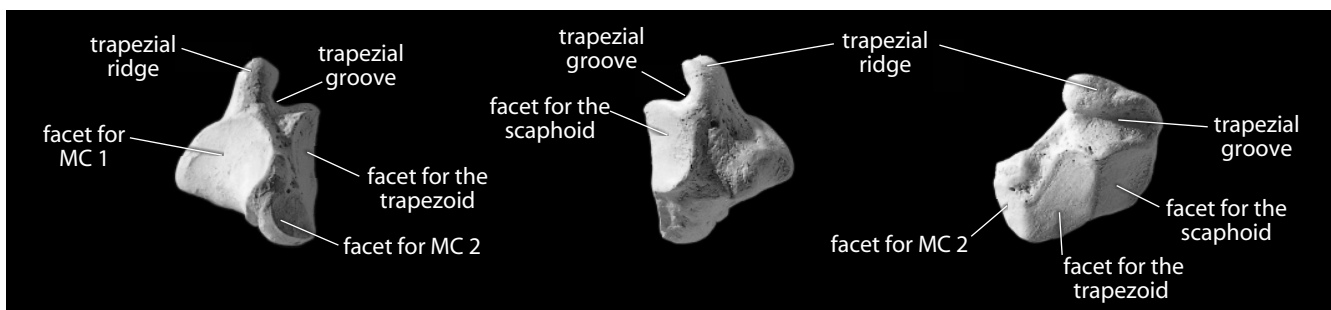


Figure 10.8 **Right trapezium.** *Left:* view from the MC 2 base; palmar is up. *Middle:* view from the lateral scaphoid end. *Right:* view from the scaphoid-trapezoid boundary (from medial), distal is to the right. Natural size.

10.1.6 Trapezoid (Figure 10.9)

The trapezoid (sometimes called the lesser multangular) is boot-shaped and is the smallest carpal bone in the distal row. It articulates distally (via a double facet) with the base of MC 2. The trapezoid has four articular surfaces and two nonarticular surfaces:

- a. The **double facet for MC 2** is the pair of convex articular surfaces on the distolateral side of the bone. If you imagine the trapezium as a boot, the double facet would extend from the laces to the toes.
 - b. The **facet for the capitate** is also a large facet on the distal end of the bone, but this facet is on the distomedial aspect of the trapezoid.
 - c. The **nonarticular palmar surface** spills onto the lateral surface of the bone and tapers dorsally to a V-shaped cleft that separates the facets for the trapezium and MC 2. This would be the opening and side zipper of the boot.
 - d. The **facet for the trapezium** is proximal to the adjacent V-shaped cleft.
 - e. The **facet for the scaphoid** is the somewhat excavated facet on the medial surface, opposite the V-shaped cleft. The sharp ridge between this facet and the facet for the trapezium forms the back of the heel of the boot.
 - f. The **nonarticular dorsal surface** is the large, flat area that would be the sole of the boot.
- **Anatomical siding:** The largest nonarticular surface is dorsal, and its most pointed corner is proximal and lateral (on the thumb side). Just palmar to this corner there is a sharp ridge where the lateral, more convex articular facet for the trapezium meets the proximal, more concave articular facet for the scaphoid.
 - **Positional siding:** Place the “sole” of the boot on the table, with the narrow, V-shaped cleft facing you. The toe of the boot then points toward the side from which the bone comes.

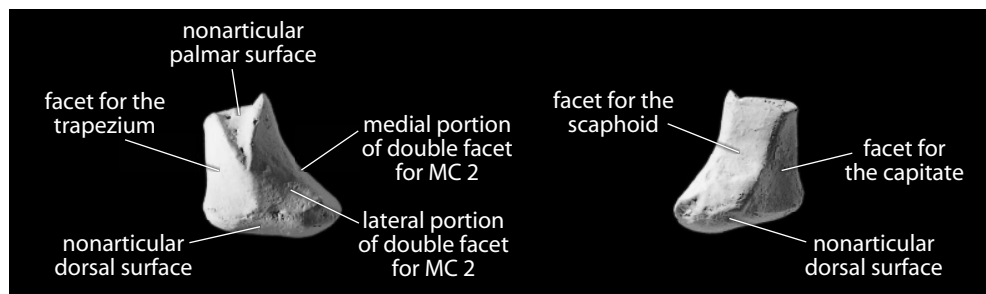


Figure 10.9 **Right trapezoid.** *Left:* view from the distalmost trapezium; palmar is up. *Right:* view from the capitate-scaphoid boundary (from proximal). Natural size.

10.1.7 Capitate (Figure 10.10)

The capitate is a large carpal bone that articulates distally with the bases of MC 3, MC 2, and (sometimes) MC 4. Its distal end is therefore squared off, while the proximal end is rounded.

- a. The **head** of the capitate is the rounded end of the bone that articulates proximally with the hollow formed by the lunate and scaphoid.
- b. The **base** of the capitate is the more squared-off end that articulates distally most directly with the base of MC 3.

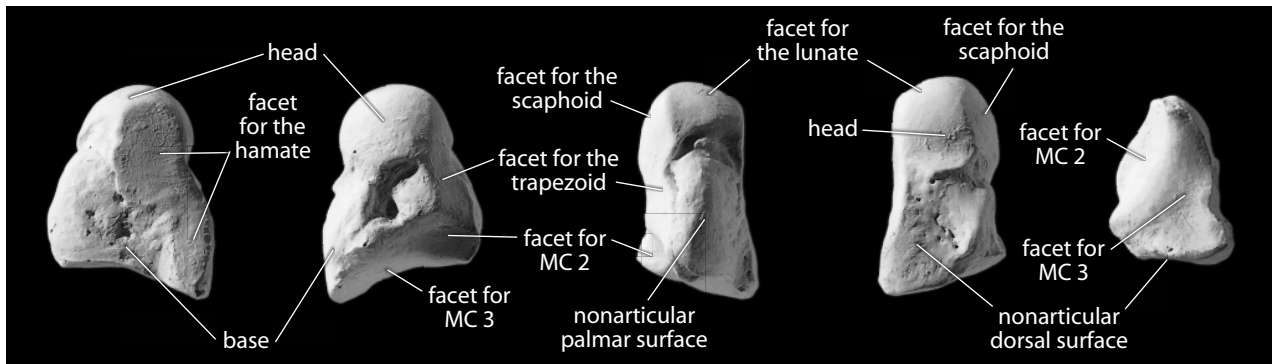


Figure 10.10 **Right capitate**. All but right: proximal is up; right: palmar is up. From left: medial view; lateral view; palmar view; dorsal view; distal view. Natural size.

- c. On the medial side of the head is a large, flat-to-concave facet, the **facet for the hamate**. Towards the base this facet is highly variable; it may extend all the way to the base or only halfway, and it may be a single facet or multiple facets.
 - d. The **facet for the scaphoid** is found on the lateral side of the head and may appear continuous with the **facet for the lunate**, which occupies the central portion of the head.
 - e. The **facet for MC 3** dominates the base of the capitate.
 - f. The **facet for MC 2** truncates the medial edge of the base of the capitate.
 - g. The **facet for the trapezoid** extends onto the medial side of the capitate from the base and reaches for the head. Like the hamate facet, this facet is highly variable in its extent.
 - h. The **nonarticular palmar surface** is thin and crest-like.
 - i. The **nonarticular dorsal surface** is the largest, flattest nonarticular surface.
- **Anatomical siding:** Proximally the head articulates in the hollow formed by the lunate and scaphoid. The largest, flattest nonarticular surface is dorsal. The more concave surface of the head is for the hamate and is thus medial (on the little finger side).
 - **Positional siding:** With the head pointing up and the base resting on the table, place the long, narrow hamate facet toward you. This articulation is on the side from which the bone comes.

10.1.8 Hamate (Figure 10.11)

The hamate is the wedge-shaped carpal bone with the **hamulus**, the hook-shaped, nonarticular projection on the palmar surface. This hamulus is one of four attachment points for the *flexor retinaculum*. The hamate has five distinct articular facets:

- a. The **facet for MC 5** is immediately beneath (dorsal to) the hamulus, and is one of two facets on the **base** of the hamulus.
- b. The **facet for MC 4** is on the medial side of the base, adjacent to the facet for MC 5.
- c. The **facet for the triquetral** is the longest facet on the hamate, extending from the proximal **apex** nearly all the way to the base.
- d. The **facet for the capitate** is the oval articular surface on the medial side of the apex.
- e. The **facet for the lunate** is variably present. When present, it is usually a narrow facet that truncates the proximal apex of the bone.

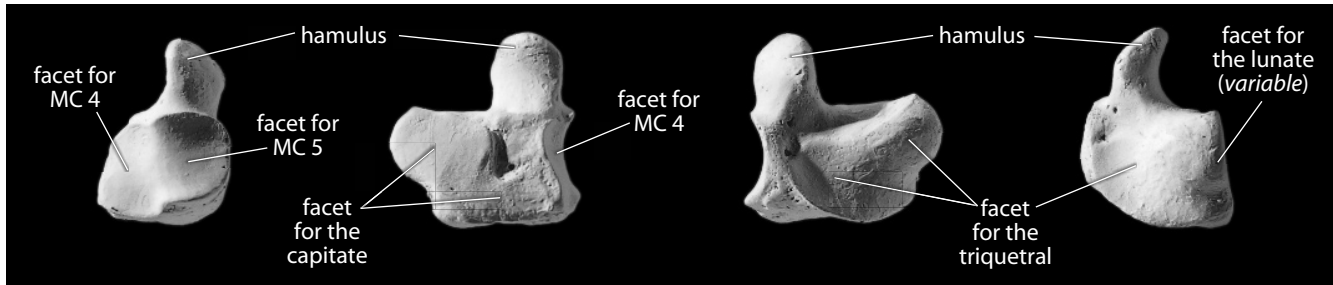


Figure 10.11 Right hamate. Palmar is up. *From left:* distal view; lateral view; medial view; proximal view. Natural size.

- **Anatomical siding:** The bone articulates distally with the bases of MC 4 and MC 5 via a double facet at the base of the hamulus. The hamulus is placed on the distal, palmar surface of the bone and is medial, hooking over the edge of the carpal tunnel in this position.
- **Positional siding:** Place the flat, nonarticular surface down with the hook and the two adjacent metacarpal facets away from you. The hook leans toward the side from which the bone comes.

10.1.9 Growth

The carpal bones each ossify from a single center.

10.1.10 Possible Confusion

Because of their small size and compact construction, the identification of fragmentary carpal bones is not usually called for. If the hand has been carefully collected, intact carpal bones are usually available. Each of these is distinctive and impossible to confuse with another. Confusion of the adult carpal bones with the tarsal bones is improbable because the former are all smaller than the latter and the shapes are all distinctive.

Many skeletons, especially those from archaeological contexts, have incomplete hands because of postmortem disturbance of the skeleton (for instance, burrowing rodents) before excavation. These animals often move smaller skeletal elements during their burrowing activities. During archaeological excavation, very small bones, such as the sesamoids, pisiform, and terminal phalanges, may be inadvertently lost if care and fine screening are not employed in recovery.

10.1.11 Carpal Measurements

There are several standard measurements for each carpal, but these are rarely used by anyone other than specialists in carpal anatomy (see Martin 1928: 1022–1030, for example).

10.1.12 Carpal Nonmetric Traits

- Supernumerary, or accessory, carpal bones occasionally form in the wrist. Several of these variants occur frequently enough to warrant specific names: the **os centrale**, **os epitriquetrum**, **os hypotriquetrum**, **os styloideum**, and **os triangulare** are the most common.

10.2 Metacarpals (Figures 10.12–10.18)

The metacarpals are numbered MC 1 (the thumb) through MC 5 (the little finger), according to the five rays of the hand. They are all tubular bones, with round distal articular surfaces (**heads**) and more rectangular proximal ends (**bases**). They are identified and sided most effectively according to the morphology of the bases.

The bases of the metacarpals articulate with their neighbors in positions 2–5. All four of the carpals in the distal row articulate with one or more metacarpal bases: the trapezium with MC 1 and MC 2, the trapezoid with MC 2, the capitate with MC 2 and MC 3 (and sometimes MC 4), and the hamate with MC 4 and MC 5.

10.2.1 First Metacarpal (Thumb)

The first metacarpal is the shortest metacarpal, broader and more robust in its shaft than the others. Its single proximal articular surface is saddle-shaped, corresponding to the facet on the trapezium.

- **Siding:** The maximum palmar projection of the bone at the base is always toward the medial side. Therefore, in a proximal view, imagine dividing the saddle-shaped proximal facet into medial and lateral portions. The medial portion of the articular surface is always smaller. The lateral palmar surface of the shaft is larger and more excavated than the medial palmar surface. Viewed dorsally, with the distal end up, the axis of maximum length is skewed basally toward the side the bone is from.

10.2.2 Second Metacarpal

The second metacarpal is normally the longest metacarpal, at the base of the index finger. The base presents a long, curved, blade-like wedge that articulates with the trapezoid, capitate, trapezium, and MC 3.

- **Siding:** The most proximal part of the base is a broad, blade-like, medially positioned wedge that bears the articulation for MC 3.

10.2.3 Third Metacarpal

The third metacarpal lies at the base of the middle finger. It is the only metacarpal with a sharp projection, the **styloid process**, at its base. It articulates with the capitate and MC 2 and MC 4 at the base.

- **Siding:** The styloid process is on the lateral, or MC 2, side of the bone.

10.2.4 Fourth Metacarpal

The fourth metacarpal lies at the base of the ring finger and is shorter and more gracile than MC 2 or MC 3. It has a fairly square base with three or four articular facets. It articulates (at its base) with the capitate (sometimes), hamate, MC 3, and MC 5.

- **Siding:** The proximal and medial basal facets share a common, right-angle articular edge.

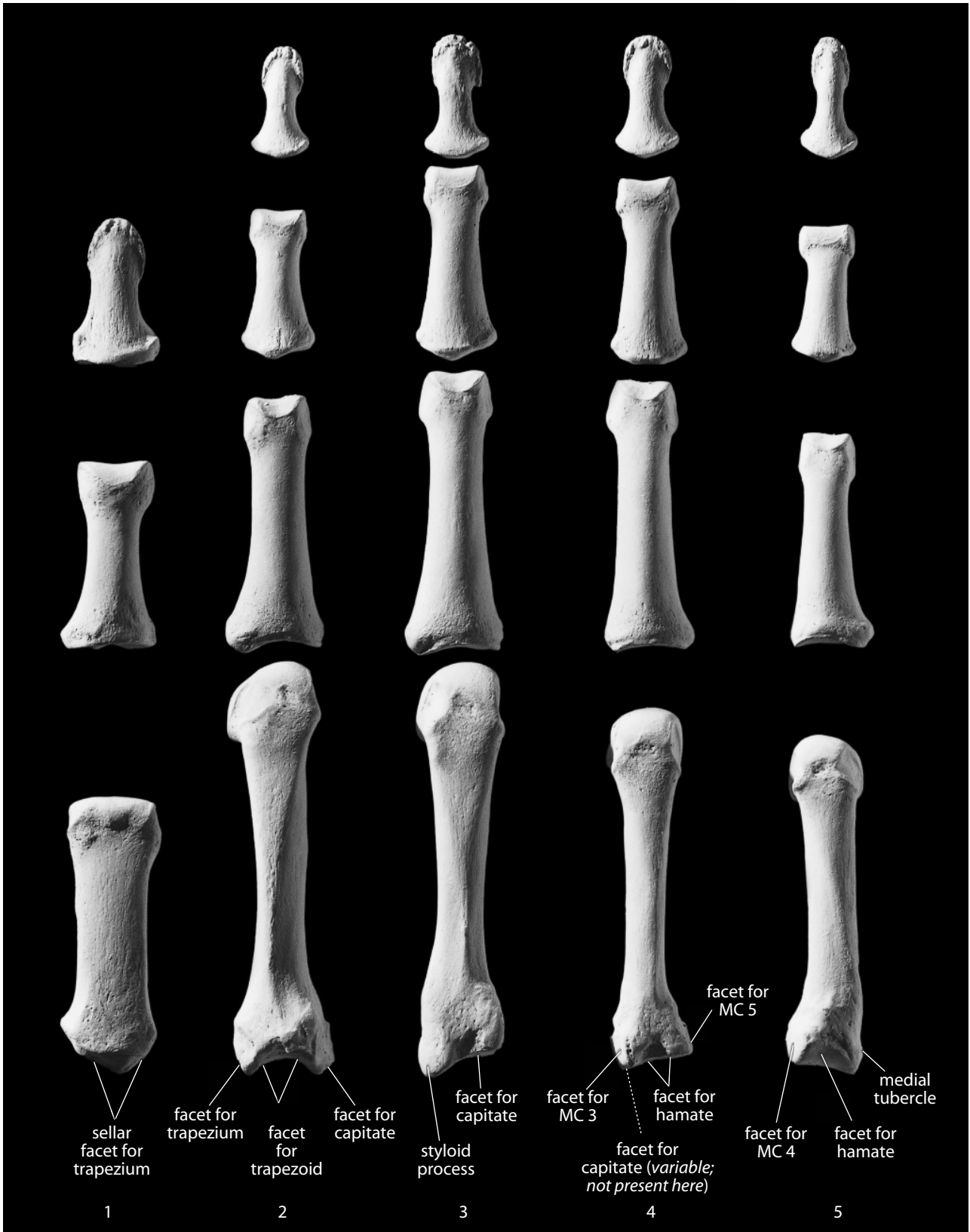


Figure 10.12 **Right hand, dorsal** (posterior). Rays 1–5, showing the metacarpals and the proximal, intermediate, and distal hand phalanges. Distal is up, lateral is toward the left. Natural size.

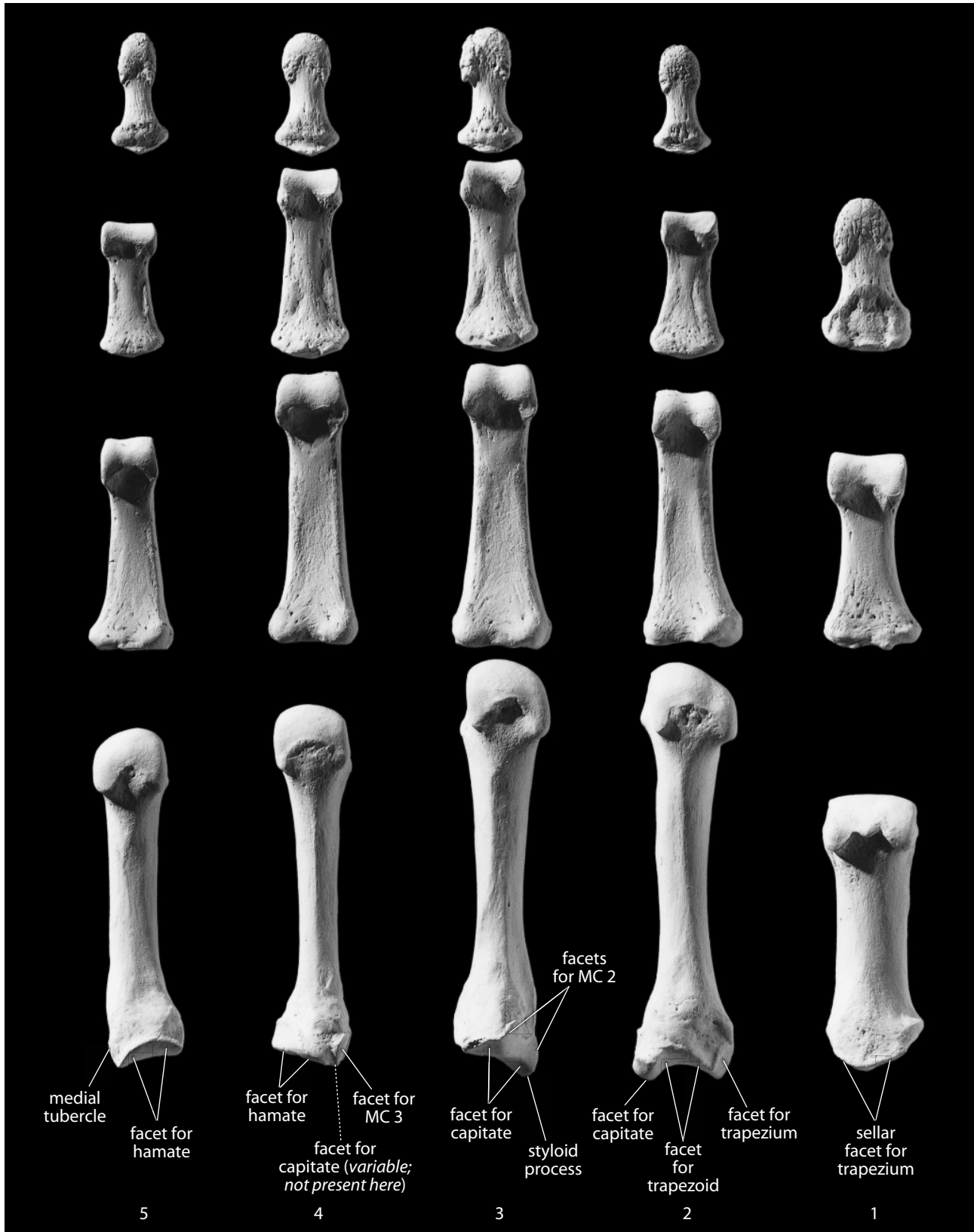


Figure 10.13 **Right hand, palmar** (anterior). Rays 1–5, showing the metacarpals and the proximal, intermediate, and distal hand phalanges. Distal is up, lateral is toward the right. Natural size.

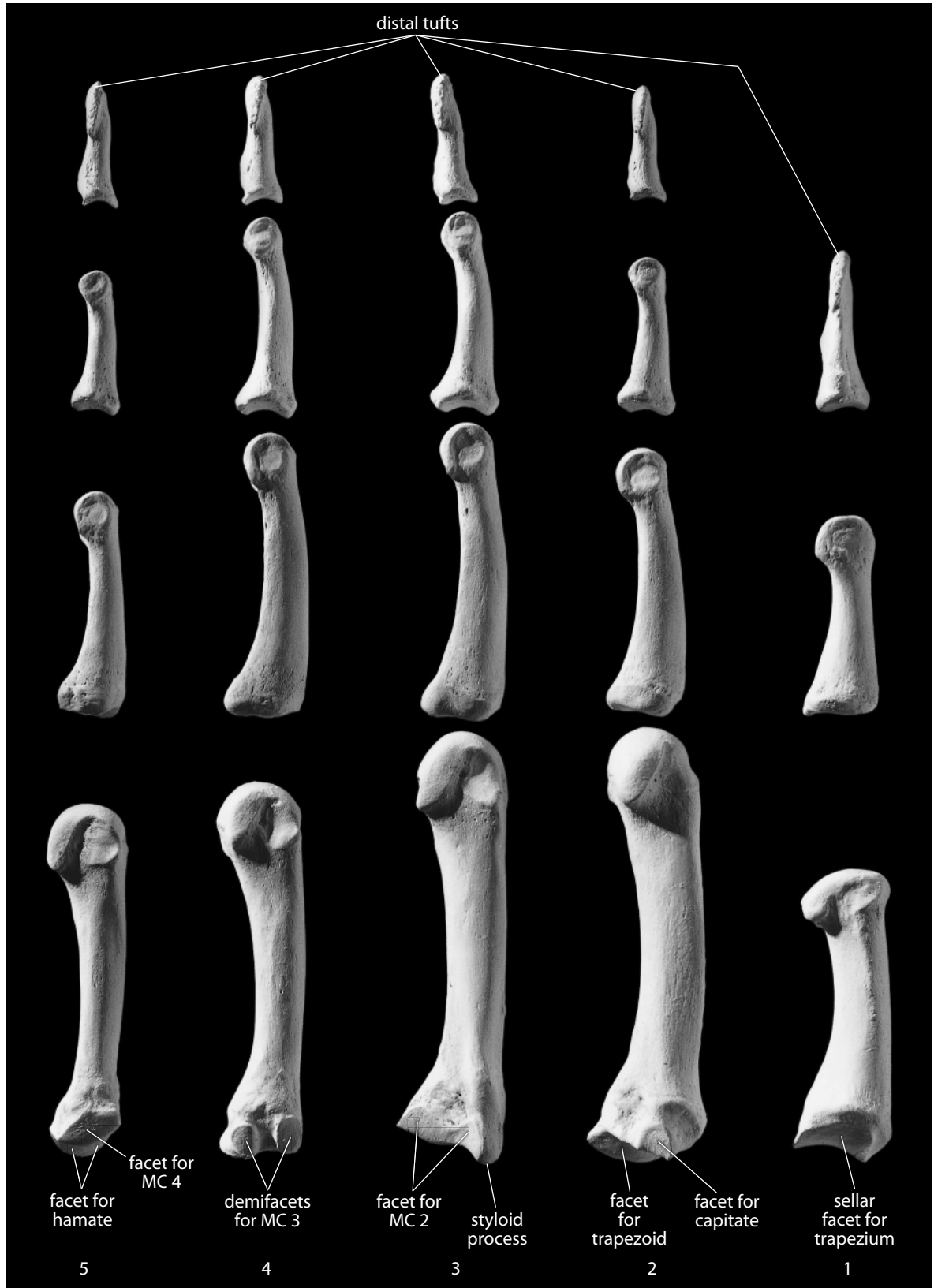


Figure 10.14 **Right hand, lateral.** Rays 1–5, showing the metacarpals and the proximal, intermediate, and distal hand phalanges. Natural size.

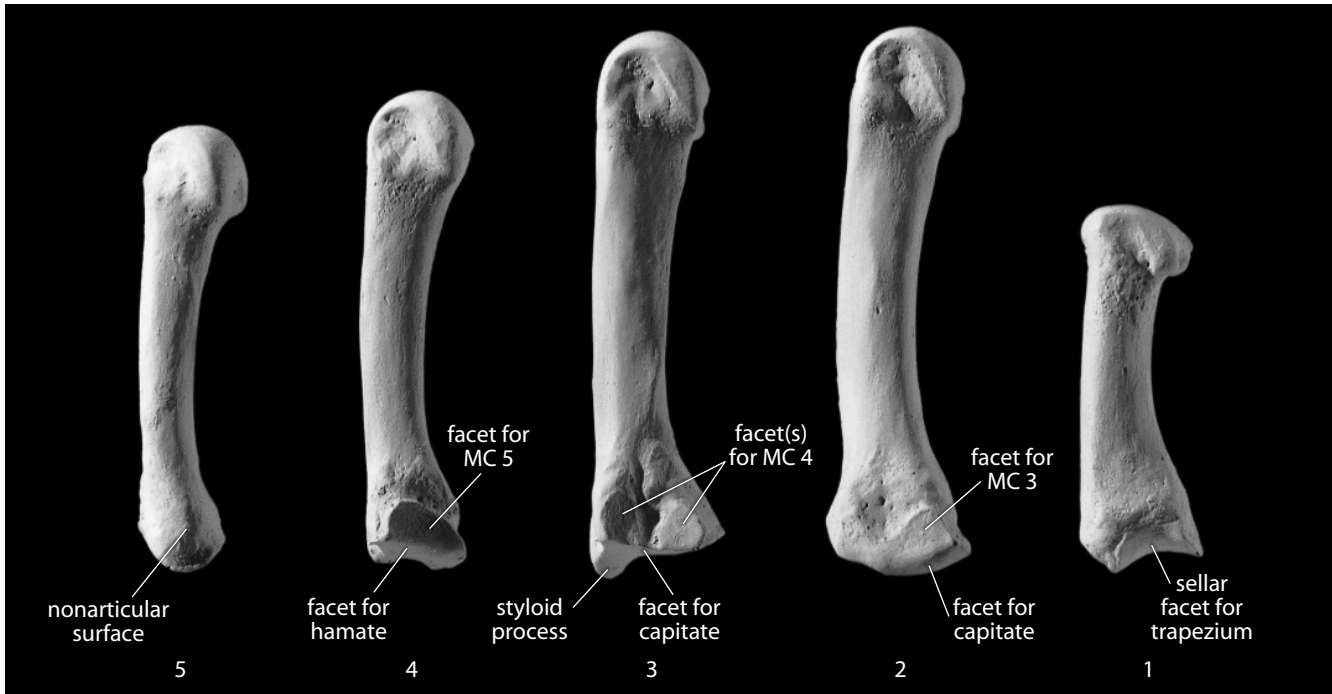


Figure 10.15 Right metacarpals, medial. Natural size.

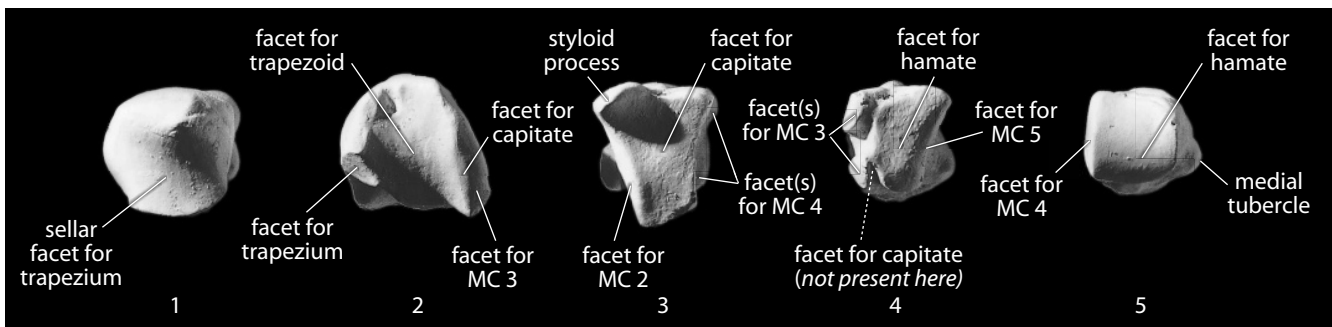


Figure 10.16 Right metacarpal bases, proximal. Dorsal is up, lateral is toward the left. Natural size.

10.2.5 Fifth Metacarpal

At the base of the little finger, the fifth metacarpal is the thinnest and shortest of the nonpollical metacarpals. It bears only two basal facets: one for the hamate and one for MC 4.

- **Siding:** The nonarticular side of the base faces medially, away from MC 4.

10.2.6 Growth (Figure 10.17)

Each metacarpal except MC 1 ossifies from two centers: a primary one for the shaft and the base, and a secondary one for the distal extremity (the head). The thumb metacarpal has a separate center for its base (but none for its distal extremity).

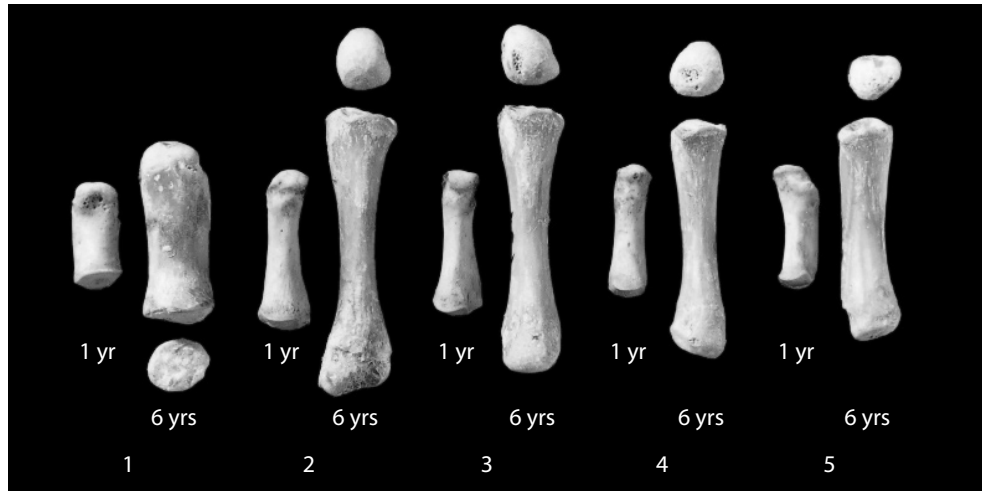


Figure 10.17 Metacarpal growth. The pairs of immature metacarpals are shown here in anterior (palmar) view, with ray 1 on the left and ray 5 on the right. They are from one-year-old and six-year-old individuals. Natural size.

10.2.7 Possible Confusion

Metacarpals 2–5 are stouter than metatarsals 2–5. Metacarpal shafts are larger in diameter relative to length and are not as straight and slender as metatarsal shafts. Metacarpal heads are more rounded than the mediolaterally compressed metatarsal heads.

10.2.8 Siding

In siding the metacarpals, the bases are always proximal, and the palmar shaft surfaces are always more concave than the dorsal surfaces in lateral view. Features of the base are used to side metacarpals as outlined in the preceding sections.

10.2.9 Metacarpal Measurements (Figure 10.18)

1. **Maximum metacarpal length** (Bush et al., 1983: 667, #1): With a sliding caliper kept parallel to the long axis of the diaphysis, determine the maximum length of the metacarpal.
2. **Metacarpal biomechanical (or articular) length** (Martin, 1928: 1031, #2): With a sliding caliper, measure the distance from the center of the carpal articular surface to the distalmost point on the metacarpal head.
3. **Midshaft dorsopalmar height** (Bush et al., 1983: 667, #7): First, determine the location at midshaft using 50% of biomechanical length. At this location, use a sliding caliper to measure the greatest dorsopalmar dimension.
4. **Midshaft mediolateral breadth** (Bush et al., 1983: 667, #6): Measuring from the midshaft location (50% of biomechanical length), use a sliding caliper to measure the greatest mediolateral dimension.

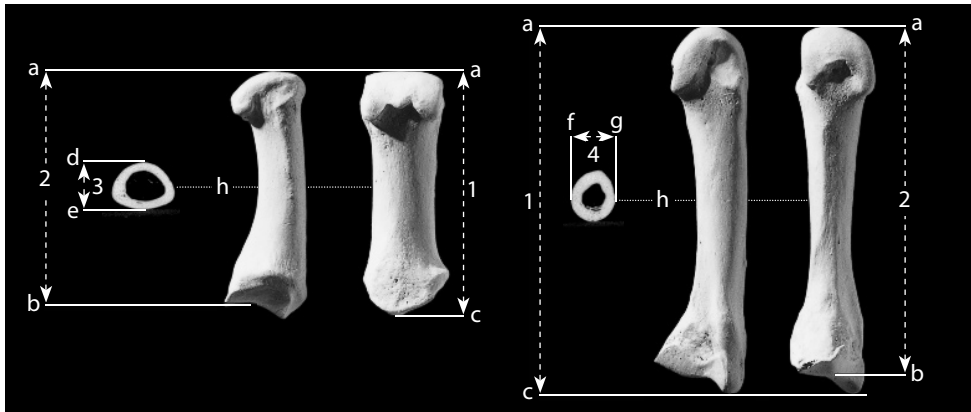


Figure 10.18 Metacarpal measurements. First and third metacarpals. Distal is up for bones; for scans, palmar is up. Two-thirds natural size.

Locations: a) distalmost point on metacarpal head; b) center of carpal articular surface; c) proximalmost point on metacarpal; d) palmarmost point at midshaft; e) dorsalmost point at midshaft; f) lateralmost point at midshaft; g) medialmost point at midshaft; h) location of midshaft.

Measurements: 1) maximum metacarpal length; 2) metacarpal biomechanical (or articular) length; 3) metacarpal midshaft height; 4) metacarpal midshaft breadth.

10.2.10 Metacarpal Nonmetric Traits

- No metacarpal nonmetric traits or significant anatomical variants have been noted for metacarpals.

10.3 Hand Phalanges (Figures 10.12–10.14, 10.19–10.21)

The hand phalanges are all shorter than metacarpals, lack rounded heads, and are anteroposteriorly flattened in their shafts. The pollical (thumb) phalanges are shorter and squatter than the others, and the pollex (thumb) lacks an intermediate phalanx. The expanded proximal end of each phalanx is the **base**. The distal end is the **head** (proximal or intermediate phalanges) or the **distal tip** (tuft; distal phalanges only). The distal articular surface of proximal and intermediate phalanges is called the **trochlea**. The nonarticular tubercles adjacent to the metacarpal heads and the phalangeal joints are attachment points for the *collateral ligaments*.

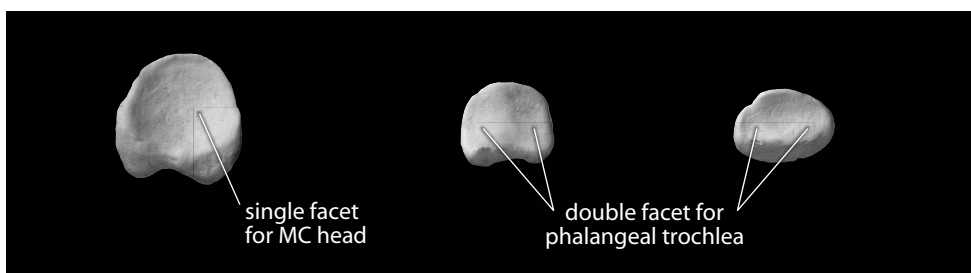


Figure 10.19 Bases of hand phalanges. *Left:* proximal hand phalanx; *center:* intermediate hand phalanx; *right:* distal (or terminal) hand phalanx. All phalanges are from ray 3. Dorsal is up. Natural size.

Dorsal surfaces of the hand phalanges are smooth and rounded. The palmar surfaces, in contrast, are flat and more roughened, especially along either side of the **shaft**, where raised ridges mark attachment sites for the *fibrous flexor sheaths*, tissues that prevent the *flexor tendons* from “bow stringing” away from the bones as the fingers are flexed.

10.3.1 Proximal Hand Phalanges

Each proximal hand phalanx displays a single, concave proximal (basal) articular facet for the metacarpal head. The proximal thumb phalanx is readily recognizable by its short, stout appearance.

10.3.2 Intermediate Hand Phalanges

Each intermediate hand phalanx displays a double proximal articular facet for the head of the proximal phalanx, and each also has a distal articular facet. The thumb ray bears only two phalanges, lacking a morphologically intermediate phalanx.

10.3.3 Distal Hand Phalanges

Each distal (or terminal) hand phalanx displays a double proximal articular facet for the head of the intermediate phalanx. The terminal end of each has a nonarticular pad, the **distal phalangeal tuberosity** (or **distal tuft**). The thumb phalanx is readily recognizable because of its short, stout appearance. The dorsal surfaces of these phalanges are more rounded, and the palmar surfaces are more rugose.

10.3.4 Growth

Distal hand phalanges are the first hand phalanges to begin ossification (at 7–9 weeks *in utero*), and each has a single primary ossification center, found at the distal tip. Proximal and intermediate hand phalanges each ossify from two centers: a primary one for the shaft and distal end, and a secondary one for the base.

10.3.5 Possible Confusion

Hand phalanges have shafts whose palmar surfaces are flattened, forming a semicircle in cross section (Figure 10.20). The shafts of foot phalanges are circular in cross section.

10.3.6 Siding

For siding hand and foot phalanges it is best to work with whole specimens and comparative materials, particularly *in vivo* radiographs.

10.3.7 Manual Phalangeal Measurements (Figure 10.21)

1. **Maximum phalangeal length** (Martin, 1928: 1031, #3; Bush et al., 1983: 667, #1): With the sliding caliper kept parallel to the long axis of the phalangeal diaphysis, determine the maximum length of the phalanx.

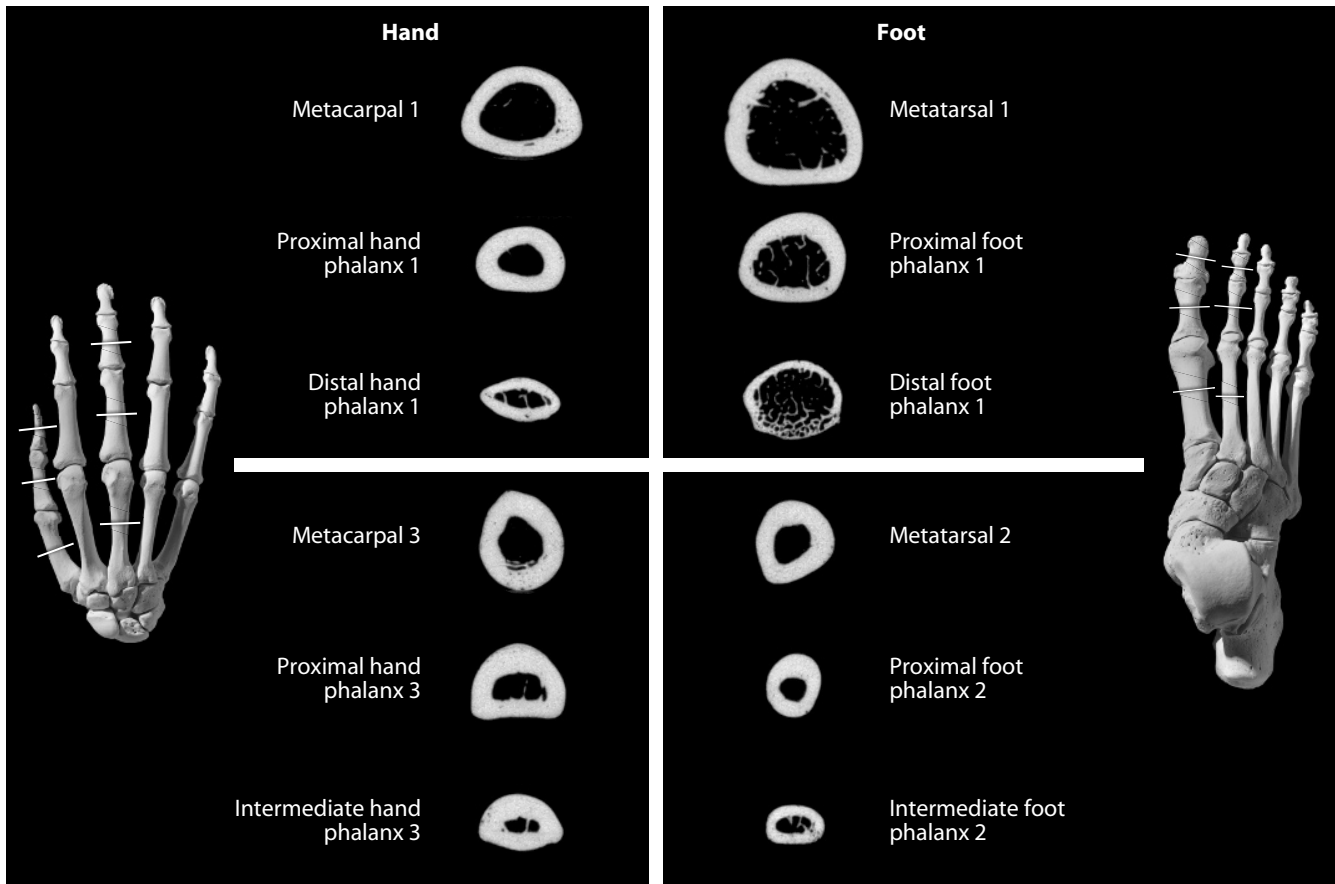


Figure 10.20 Midshaft CT scans of long bones of the foot and hand compared. Shafts of foot phalanges and the hallucal metatarsal have rounder cross sections than those of hand phalanges or the thumb metacarpal. The scans were taken from the bones of the individual used to illustrate postcrania in this book. The positions of the CT sections are illustrated on the articulated hand and foot. Dorsal is up and palmar/plantar is down. Natural size.

2. **Phalangeal biomechanical (or articular) length** (Bush et al., 1983: 667, #2): With a small spreading caliper or a sliding caliper equipped with at least one inside point extension, place the point extension in the depth of the middle of the proximal articular surface and measure the distance to either the proximalmost point on the head of the phalanx (for proximal and intermediate phalanges) or to the distalmost point on the apical tuft (for distal phalanges).
3. **Midshaft anteroposterior (or dorsopalmar) height** (Bush et al., 1983: 668, #6): First, determine the location at midshaft using 50% of biomechanical length. At this location, use a sliding caliper to measure the greatest dorsopalmar dimension.
4. **Midshaft mediolateral breadth** (Bush et al., 1983: 668, #5): Measuring from the midshaft location (50% of biomechanical length), use a sliding caliper to measure the greatest mediolateral dimension.

10.3.8 Manual Phalangeal Nonmetric Traits

- **Brachydactyly**: Some individuals possess phalanges that are uniformly short relative to other long bones in their bodies, an inherited condition called brachydactyly.

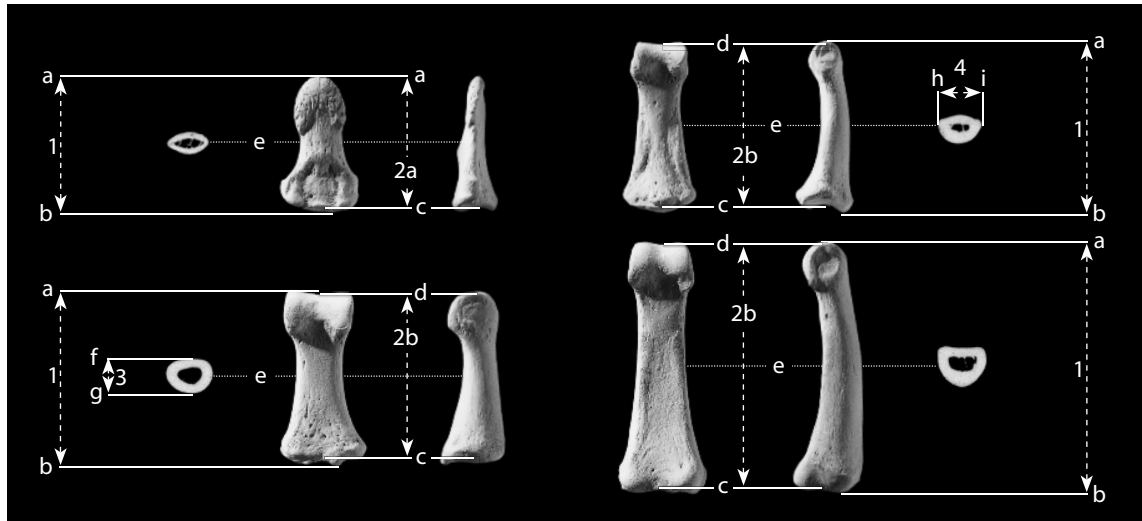


Figure 10.21 Hand phalangeal measurements. Phalanges of first and second manual ray. Distal is up for bones; for scans, palmar is up. Two-thirds natural size.

Locations: a) distalmost point on phalanx; b) proximalmost point on phalanx; c) deepest point of proximal articular surface; d) distalmost point of central sulcus of trochlea; e) location of midshaft; f) dorsalmost point of midshaft; g) palmarmost point of midshaft; h) medialmost point of midshaft; i) lateralmost point of midshaft.

Measurements: 1) maximum phalangeal length; 2a) phalangeal biomechanical length (of distal phalanx); 2b) phalangeal biomechanical length (of proximal or intermediate phalanx); 3) phalangeal midshaft height; 4) phalangeal midshaft breadth.

- **Brachymesophalangy:** In some individuals, fingers may be shorter than normal due to reduced length of just the intermediate phalanx, a condition called brachymesophalangy. This condition occurs most commonly on digits 5 and 2, where it is called brachymesophalangy 5 or brachymesophalangy 2.
- **Clubbed thumb:** In some individuals, the distal pollical phalanx is shortened (either bilaterally or asymmetrically) and rounder in distal cross section than normal.

10.4 Functional Aspects of the Hand

Humans have effectively abandoned the use of their forelimbs as supports during locomotion. Primates in general, and humans in particular, have evolved hands that provide the ability for these organisms to manipulate their environment in complex ways. As noted in section 10.1, forearm muscles operate the digits of the hand via tendons that pass across the wrist. The metacarpal heads form foundations from which the thumb and fingers work. The thumb bears only two phalanges, but the saddle-shaped, sellar joint at the base of its metacarpal allows this digit great mobility and the ability to oppose the other digits. Joints between the phalanges are hinge joints whose extension is checked by a palmar ligament, and whose abduction, adduction, and rotation are checked by collateral ligaments.

Most of the force in the grip or extension of the fingers comes from forearm muscles that send tendons across the wrist to insert on the digits. These forearm muscles are called extrinsic hand muscles. As Cartmill et al. (1987) point out, forearm muscles control much of the hand's movement and, in a functional sense, the forearm is best thought of as an appendage of the hand rather than the other way around. Intrinsic muscles of the hand lie within the palm and produce abduction and adduction of the fingers as well as special movements, particularly of the thumb.

Chapter 11

PELVIS: SACRUM, COCCYX, AND OS COXAE

JUST AS THE BONY STRUCTURE joining the front limbs to the trunk is called the shoulder girdle, so is the bony complex joining the hind limbs to the trunk called the pelvic girdle. The pelvic girdles of terrestrial vertebrates are connected to the vertebral column and are much larger than their homologs in fish. These adaptations are required for weight-bearing and muscle attachment in the terrestrial forms. In early land-dwelling vertebrates, the right and left limb girdles joined dorsally with the sacral vertebrae to form a bony ring around the rear of the trunk. This is still the basic form in the tetrapod pelvis.

The adult human pelvis is composed of four complex elements: the right and left **ossa coxa** (singular: **os coxae**) and the **sacrum** and **coccyx**. The sacrum and coccyx are part of the axial skeleton and are actually variably fused vertebrae. Each **os coxae** represents a fusion of three primitive elements: **ilium**, **ischium**, and **pubis**.

The bony pelvis functions to support and protect the abdominal and pelvic organs. In addition, it anchors muscles of the abdomen and leg. Unlike the shoulder girdle, which is a movable platform, the pelvic girdle is firmly fixed to the axial skeleton via its vertebral element, the sacrum.

11.1 Sacrum (Figures 11.1–11.5)

11.1.1 Anatomy

The sacral vertebrae fuse during adolescence into one immobile, wedge-shaped bone, the sacrum. This bone is typically formed from five segments, but may have as few as four or as many as six. The sacrum is located at the base of the vertebral column. It articulates bilaterally with the two ossa coxa and inferiorly with the small coccyx.

- The **base** of the sacrum is the broad anterosuperior surface of the bone, comprising the tops of both alae and the plateau of the first sacral vertebra.
- The **sacral plateau** is the broad, flat, anterosuperiorly inclined surface of the first sacral centrum that articulates with the terminal, or most inferior, lumbar vertebra (normally L-5).
- The **sacral promontory** is the anterior midline projection of the sacral plateau.
- The **alae**, or “wings,” are those parts of the first sacral element that sweep laterally from the centrum. Each **ala** articulates laterally with the posteromedial surface of an os coxae.

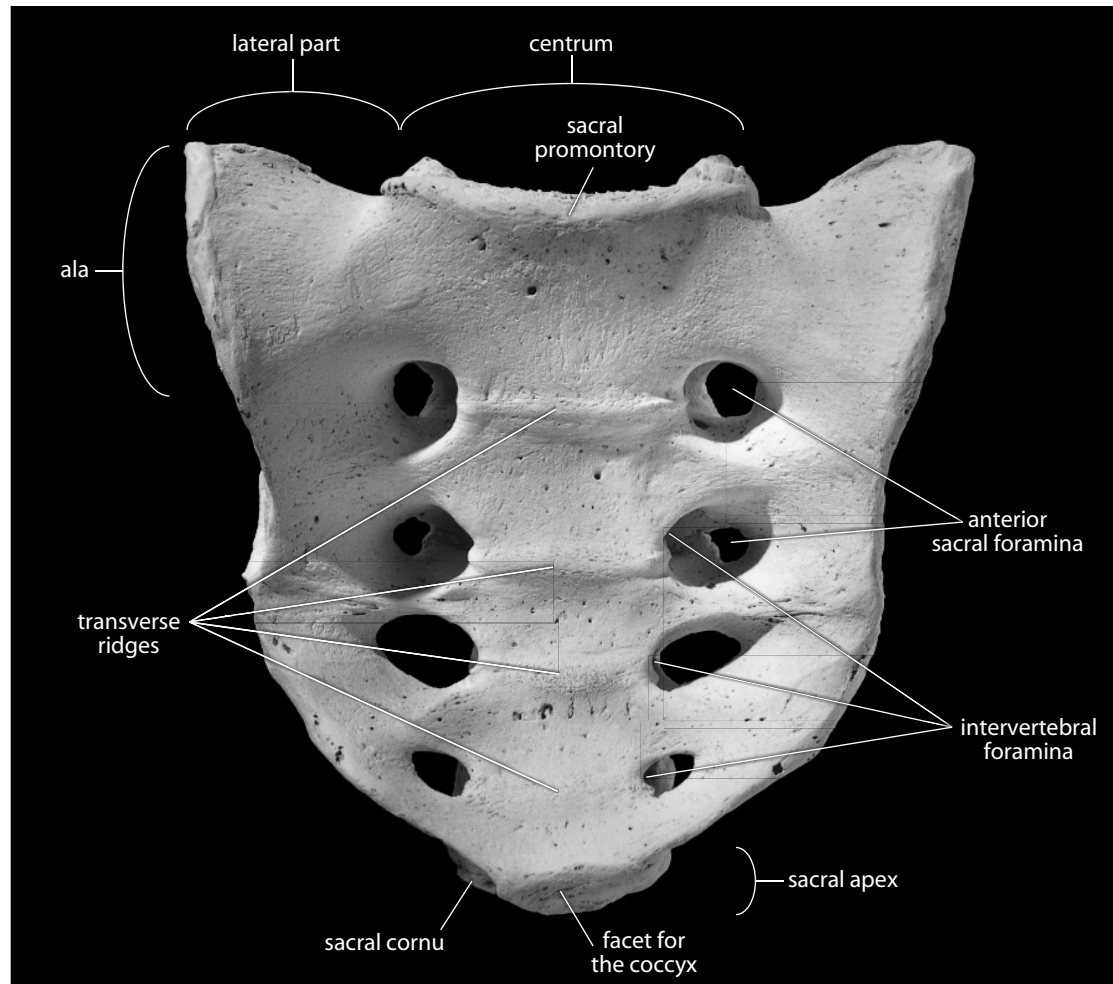


Figure 11.1 Sacrum, anteroinferior view. Natural size.

- e. The **sacral canal** is in inferior continuation of the vertebral canal.
- f. The **pelvic surface** is the smooth, concave surface of the sacrum that faces the pelvic canal.
- g. The **transverse ridges** (or **lines**) along the pelvic surface mark the lines of fusion of the sacral vertebrae.
- h. The **auricular surface** forms the sacral contribution to the articulation between the sacrum and the os coxae (the **sacroiliac joint**). The sacroiliac articulation is the least mobile synovial joint in the body. The auricular (“ear-shaped”) surface of the sacrum articulates with the auricular surface of the os coxae. The sacral auricular surface is best seen in lateral aspect.
- i. The **sacral tuberosity** is the roughened, irregular, nonarticular area behind the auricular surface. The tuberosity is the sacral attachment site of the *sacroiliac ligaments*.
- j. The **lateral part** (or **mass**) of the sacrum is the part of the bone formed by the expanded transverse processes and the vestiges of the sacral ribs. The lateral part includes the auricular surface, the ala, and the sacral tuberosity.
- k. The **anterior** (or **pelvic**) **sacral foramina** are openings in the concave anterior surface of the sacrum through which the *anterior divisions of the sacral nerves* and the *lateral sacral arteries* pass.

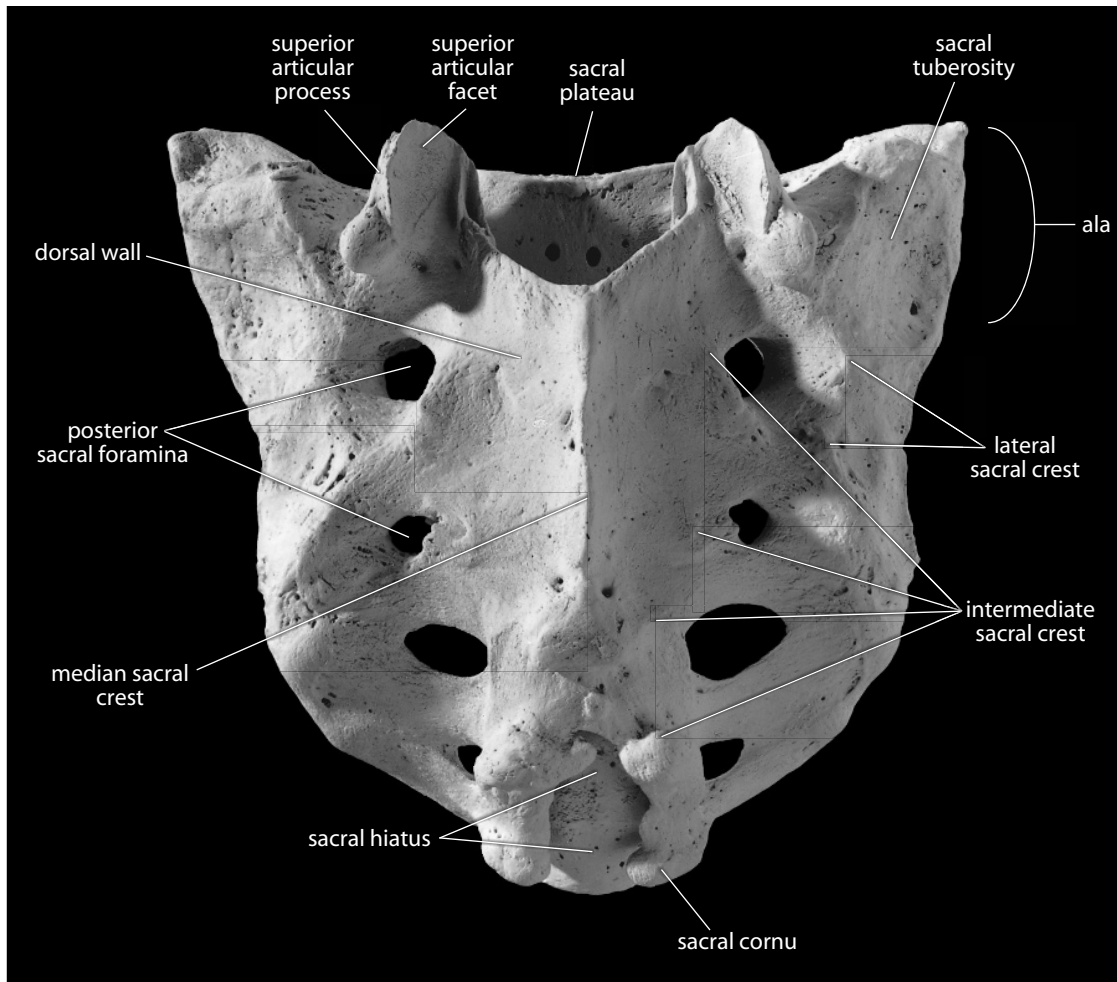


Figure 11.2 Sacrum, posterosuperior view. Natural size

- l. The **superior articular facets** of the sacrum articulate with facets on the inferior articular processes of the most inferior lumbar vertebra.
- m. The **superior articular processes** extend superiorly from the dorsal wall to accommodate the superior articular facets.
- n. The **dorsal surface** is the rough, convex, posterior-facing surface of the sacrum.
- o. The **dorsal wall** of the sacrum is a rough, irregular, variable plate of bone composed of the ossified laminae and articular processes of the fused sacral vertebrae.
- p. The **posterior** (or **dorsal**) **sacral foramina** are openings in the convex posterior surface of the sacrum through which the *posterior divisions of the sacral nerves* pass.
- q. The **intervertebral foramina** are formed by fused superior and inferior notches. These foramina are internal to and medial to both anterior and posterior sacral foramina.
- r. The **median sacral crest** (or **sacral spine**) is the highly variable midline projection of the dorsal wall formed from the fused spinous processes of the sacral vertebrae.
- s. The **intermediate sacral crest** is formed by the fused remnants of the sacral articular processes, and is located just medial to the posterior sacral foramina.
- t. The **lateral sacral crest** is formed by the fused remnants of the sacral transverse processes, and is located just lateral to the posterior sacral foramina.

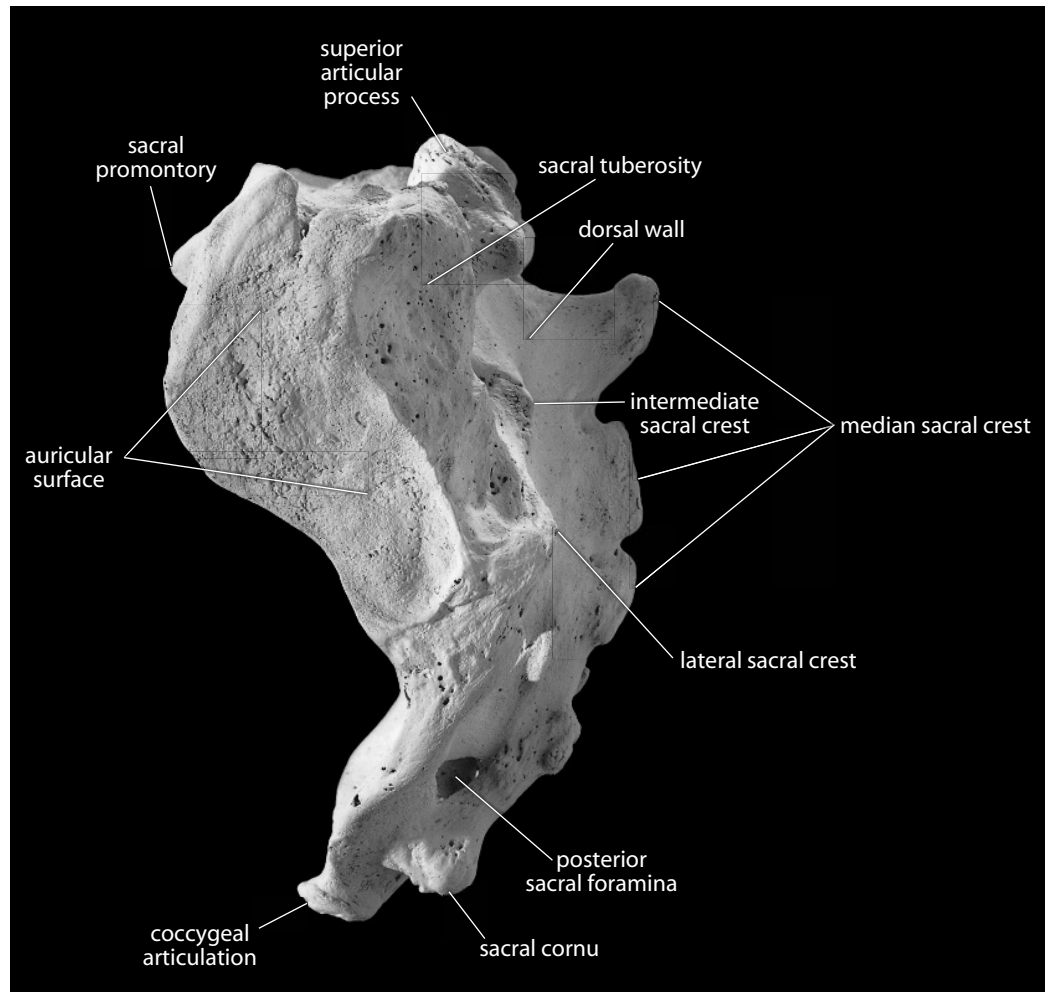


Figure 11.3 Sacrum, left lateral. Anterior is toward the left. Natural size.

- u. The **sacral hiatus** refers to the area usually limited to S-4 and S-5, where the dorsal wall is missing.
- v. The **sacral cornua** (or sacral horns; singular: **cornu**) are two small processes that extend inferiorly from either side of the sacral hiatus.
- w. The **apex of the sacrum** is the narrow, inferior tip of the sacrum that includes the articular facet for the coccyx.
- x. The **facet for the coccyx** comprises the inferior surface of the last sacral vertebra.

11.1.2 Growth (Figure 6.5)

The sacrum ossifies from approximately 21 separate centers in individuals with five sacral vertebrae (although Scheuer and Black (2000) note that this number is highly variable and should be expected to differ between individuals). As with the more cranial vertebrae, each sacral segment has an ossification center in the centrum and two additional centers: one forming each half of the neural arch. Additionally, S-1 through S-3 (or sometimes S-4) have two additional anterolateral

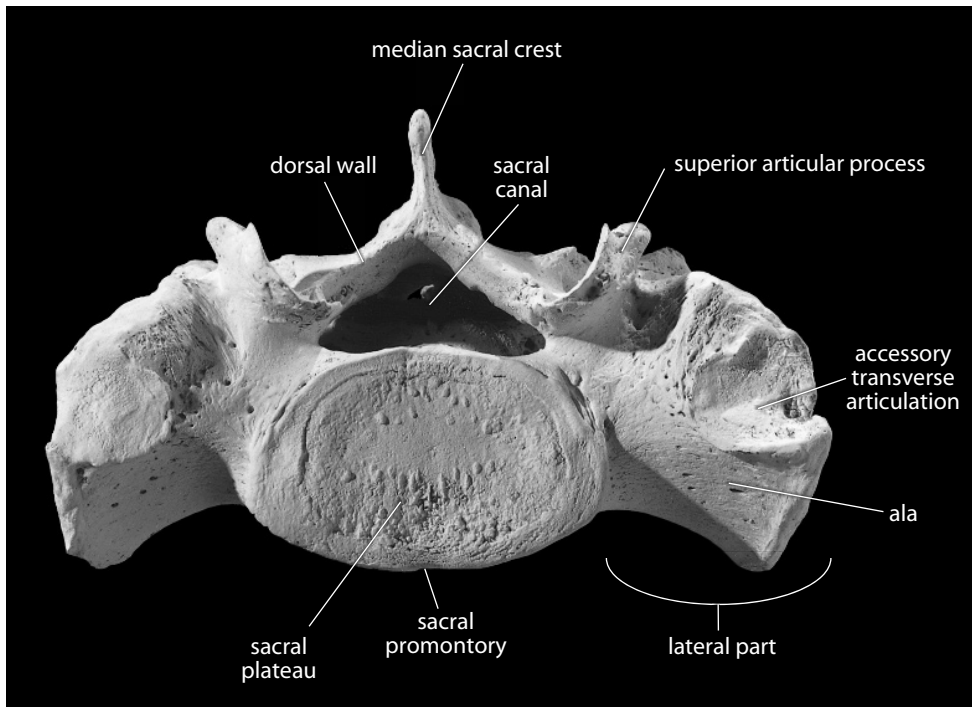


Figure 11.4 **Sacrum, anterosuperior view.** Posterior is up. Note the laterally placed facets for the sacralized L-5 of this individual. Natural size.

centers of ossification that are derived from incorporated costal elements. Additionally, two epiphyseal plates form at each sacroiliac articular region, one forming the auricular surface and one forming the lateral margin inferior to this.

11.1.3 Possible Confusion

- A fragmentary promontory region might be mistaken for a lumbar vertebra. Lumbar vertebrae, however, lack attached alae.
- The sacral auricular surface might be mistaken for the coxal auricular surface in a fragmentary or broken os coxae. However, the sacral auricular surface has virtually no adjacent outer bone surface surrounding it as the os coxae does.

11.1.4 Siding

When fragmentary, parts of the sacrum can be sided as follows:

- The anterior sacral surface is smooth and concave, with transverse ridges.
- The size of sacral vertebrae diminishes inferiorly.
- The auricular surface is lateral, and the apex of this V-shaped feature is anterior.

11.1.5 Sacral Measurements (Figure 11.5)

1. **Maximum anterior height** (or **ventral height**) (Martin, 1928: 1001, #2): Place the stationary jaw of the sliding caliper on the ventral midline point of the sacral promontory, and then extend the other jaw to the midline of the inferoventral midline point of the last sacral vertebral body.
2. **Maximum anterior breadth** (Martin, 1928: 1000, #5; Flander, 1978: 104): Use a sliding caliper to determine the greatest breadth of the first sacral vertebra (including the alae).
3. **Ventral height arc** (Martin, 1928: 1001, #1): Using a flexible cloth tape, measure the surface distance from the ventral midline point of S-1 (the sacral promontory) to the inferoventral midline point of the S-5 body.

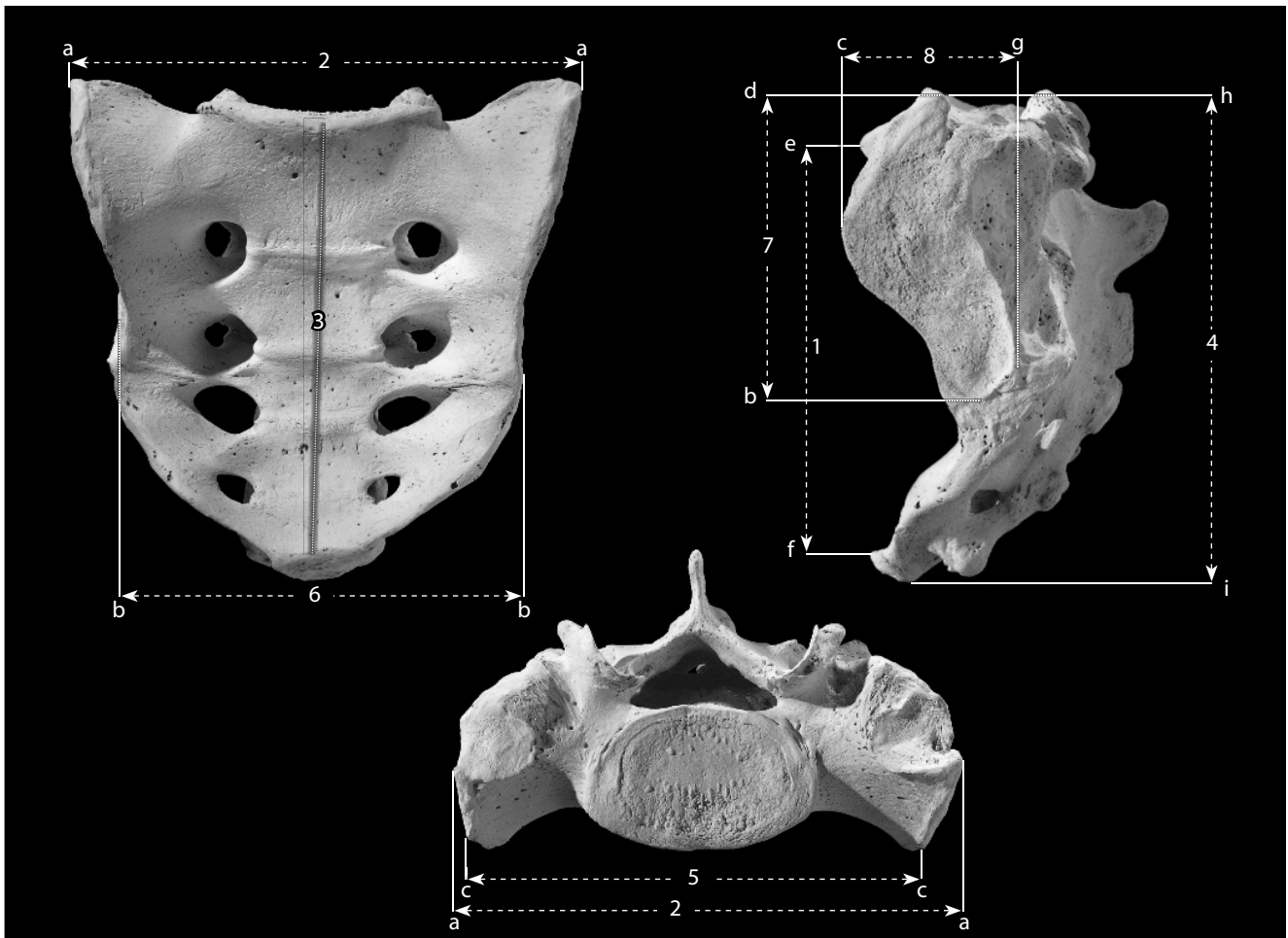


Figure 11.5 **Sacral measurements.** Two-thirds natural size.

Locations: a) most lateral point of S-1 ala; b) inferiormost point of auricular surface; c) most superoventral point of auricular surface; d) superiormost point of auricular surface; e) midline point of sacral promontory; f) inferoventral midline point of last sacral body; g) dorsalmost point of auricular surface; h) superodorsal midline point of S-1 body; i) inferodorsal midline point of S-5 body.

Measurements: 1) maximum anterior height; 2) maximum anterior breadth; 3) ventral arc; 4) dorsal height; 5) anterosuperior breadth; 6) middle breadth; 7) auricular surface height; 8) auricular surface breadth.

4. **Dorsal height** (Martin, 1928: 1001, #3; Buikstra and Ubelaker, 1994: 81, #53): Using a sliding caliper, measure the distance from the superodorsal midline point of the S-1 body to the inferodorsal midline point of the S-5 body.
5. **Anterosuperior breadth** (Martin, 1928: 1001, #5; Buikstra and Ubelaker, 1994: 81, #54): Using a sliding caliper, measure the transverse distance between the most superoventral points of the auricular margins.
6. **Middle breadth** (Martin, 1928: 1001, #9): Using a sliding caliper, measure the transverse distance between the inferiormost points of the auricular margins.
7. **Auricular surface height** (Martin, 1928: 1002, #14): Using a sliding caliper, determine the maximum craniocaudal dimension of the auricular surface.
8. **Auricular surface breadth** (Martin, 1928: 1002, #15): Using a sliding caliper, determine the maximum dorsoventral dimension of the auricular surface.
9. **Sacral index** (Hrdlička, 1939): (maximum anterior breadth ÷ maximum anterior height) × 100.

11.1.6 Sacral Nonmetric Traits

- **Number of sacral vertebrae:** The number of sacral vertebrae can vary due to sacralization of the last lumbar vertebra or of the first coccygeal vertebra.
- **Expanded sacral hiatus:** The sacral hiatus is normally formed by the failure of the lamina of S-5 (and sometimes S-4) to unite dorsally. Note the cranialmost extent of the sacral hiatus. If the hiatus occurs more cranially than S-3, the condition is referred to as an **expanded sacral hiatus**. If the hiatus extends above S-1, the condition is called **spina bifida**.
- **Accessory transverse articulations:** Articular surfaces on the anterosuperior alae for the transverse processes of a (usually sacralized) L-5 (Figure 6.12). The sacrum used to illustrate this chapter has bilateral transverse articulations (most visible in Figure 11.4). These accessory transverse articulations should not be confused with the accessory iliac articulations located posteroinferior to the auricular surface (Section 11.3.6).

11.2 Coccyx (Figure 11.6)

11.2.1 Anatomy

The coccyx, the vestigial tail, is highly variable in shape, with three to five (most often four) variably fused segments. The rudimentary vertebrae of the coccyx have articular and transverse processes superiorly, but they lack pedicles, laminae, and spinous processes. The sacral articulation is via the superior surface of the first coccygeal body (Cx-1) as well as a relatively large pair of tubercles called the **coccygeal cornua** (Figure 11.6). The cornua (singular: **cornu**) are rudimentary articular processes that contact the sacrum via the sacral cornua. The coccyx may fuse with the sacrum late in life.

As with the sacrum, the individual vertebral elements of the coccyx decrease in size inferiorly, and horizontal lines of fusion can be seen between adjacent coccygeal vertebrae. The coccyx serves to anchor pelvic muscles and ligaments.

- a. The **coccygeal cornua** are the vestiges of superior articular facets.
- b. The most lateral portions of the first coccygeal vertebra (Cx-1) are rudimentary **transverse processes**.

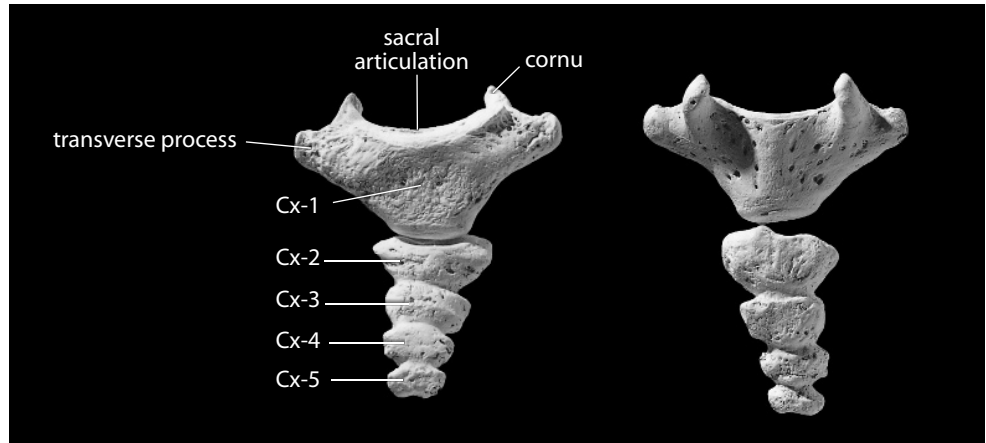


Figure 11.6 Coccyx. *Left*: anterior view; *right*: posterior view. Superior is up. Natural size.

11.2.2 Coccygeal Measurements

Measurements of the coccyx are rarely taken or used.

11.2.3 Coccygeal Nonmetric Traits

- **Number of coccygeal vertebrae:** The number of coccygeal vertebrae is variable (usually 3–5). In rare cases, no coccygeal vertebrae are present, a situation called **coccygeal agenesis**.
- **Fusion with sacrum:** In older individuals, the coccyx may fuse (or synostose) with the sacral apex. Scheuer and Black (2000) note that sacrococcygeal fusion is more common in males.

11.3 Os Coxae (vav–11.12)

11.3.1 Anatomy

Unlike many bones that earned their names due to perceived similarities with common objects, the os coxae resembles no common object and thus has earned the informal name **innominate**—the “bone with no name.” The os coxae differs in males and females, with its anatomy representing a compromise between the demands of locomotion and birthing. The os coxae is a part of the bony pelvis and is formed ontogenetically from three different parts, the **ilium**, **ischium**, and **pubis**, that fuse in early adolescence. Anatomical orientation of the os coxae is accomplished by placing the hip socket laterally and the ilium superiorly; this allows the plane of the **pubic symphysis** (the only place where right and left os coxae nearly meet) to define the sagittal plane.

The features identified here occur on both the surfaces and the edges of the os coxae. Many of the features are visible from different views of the bone. When correctly oriented, the anterior superior iliac spine should be in the same paracoronal plane as the most anterior point on the pubis.

- a. The **ilium** is the thin, blade-like portion superior to the hip socket. The ilium is composed of a stout **body** close to the acetabulum and a large, flattened **ala** (or **blade**) flaring anteriorly, posteriorly, and laterally.
- b. The **ischium** is the massive, blunt, posteroinferior part of the bone that one sits on. The ischium is composed of a **body** and two branches, or **rami**.
- c. The **pubis** is the anteroinferior portion of the bone that approaches the opposite os coxae at the midline. Like the ischium, the pubis is composed of a **body** and two branches, or **rami**.
- d. The **acetabulum** is the laterally facing, hemispherical hollow that forms the socket of the hip and articulates with the head of the femur. It has contributions from all three coxal elements: ilium, ischium, and pubis.
- e. The **acetabular margin** is the prominent lateral edge of the acetabulum, interrupted by the acetabular notch.
- f. The **acetabular fossa** is the nonarticular surface within the acetabulum. It is the attachment point for the *ligamentum teres*—a short, stout, round ligament that binds the femoral head to the depth of the acetabular fossa, guarding against femoral head dislocation but limiting femoral mobility.
- g. The **acetabular notch** is the gap in the lunate surface at the margin of the obturator foramen. It is continuous with the acetabular fossa.
- h. The **lunate surface** is the crescent-shaped articular surface within the acetabulum where the femoral head actually articulates.
- i. The **supra-acetabular groove** is between the acetabular margin and the body of the ilium.
- j. The **gluteal surface** is the outer surface of the iliac blade.
- k. The **gluteal lines** are rough, irregular lines that demarcate the attachment of the *gluteal muscles* on the lateral surface of the ilium. They vary from prominent to imperceptible between individuals and across their paths. The *gluteus minimus muscle* originates between the inferior and anterior lines, and the *gluteus medius muscle* arises between the anterior and posterior lines. The *gluteus maximus muscle* originates posterior to the posterior gluteal line. The first two gluteal muscles, *minimus* and *medius*, are abductors and medial rotators of the femur at the hip, and the *gluteus maximus* is a lateral rotator, an extensor, and an abductor of the femur at the hip.
 1. The **inferior gluteal line** is a horizontal line just superior to the acetabulum.
 2. The **anterior gluteal line** is a line that curves posteroinferiorly through the fossa posterior to the iliac pillar.
 3. The **posterior gluteal line** is more vertically placed, near the posterior edge of the ilium.
- l. The **sacropelvic surface** is the dorsal portion of the internal surface of the iliac blade. It faces the sacrum. The sacropelvic surface comprises:
 1. The **auricular surface** is the ear-shaped sacral articulation on the medial surface of the ilium. The auricular surface has two parts: the **cranial limb** and the **caudal limb**.
 2. The **iliac tuberosity** is the roughened surface just posterosuperior to the auricular surface. It is the attachment site for *sacroiliac ligaments*.
- m. The **spina limitans** is the ridge, often appearing continuous with the superior margin of the cranial limb of the auricular surface, that separates the smooth iliac fossa from the more rugose sacropelvic surface.
- n. The **iliac pillar** (or **acetabulocrystal buttress**) is the bony thickening, or buttress, located vertically above the acetabulum on the lateral iliac surface. This pillar extends to the superior margin of the ilium.
- o. The **tuberculum of the iliac crest** (or **iliac tubercle** or **crystal tubercle**) is the thickening at the superior terminus of the iliac pillar.

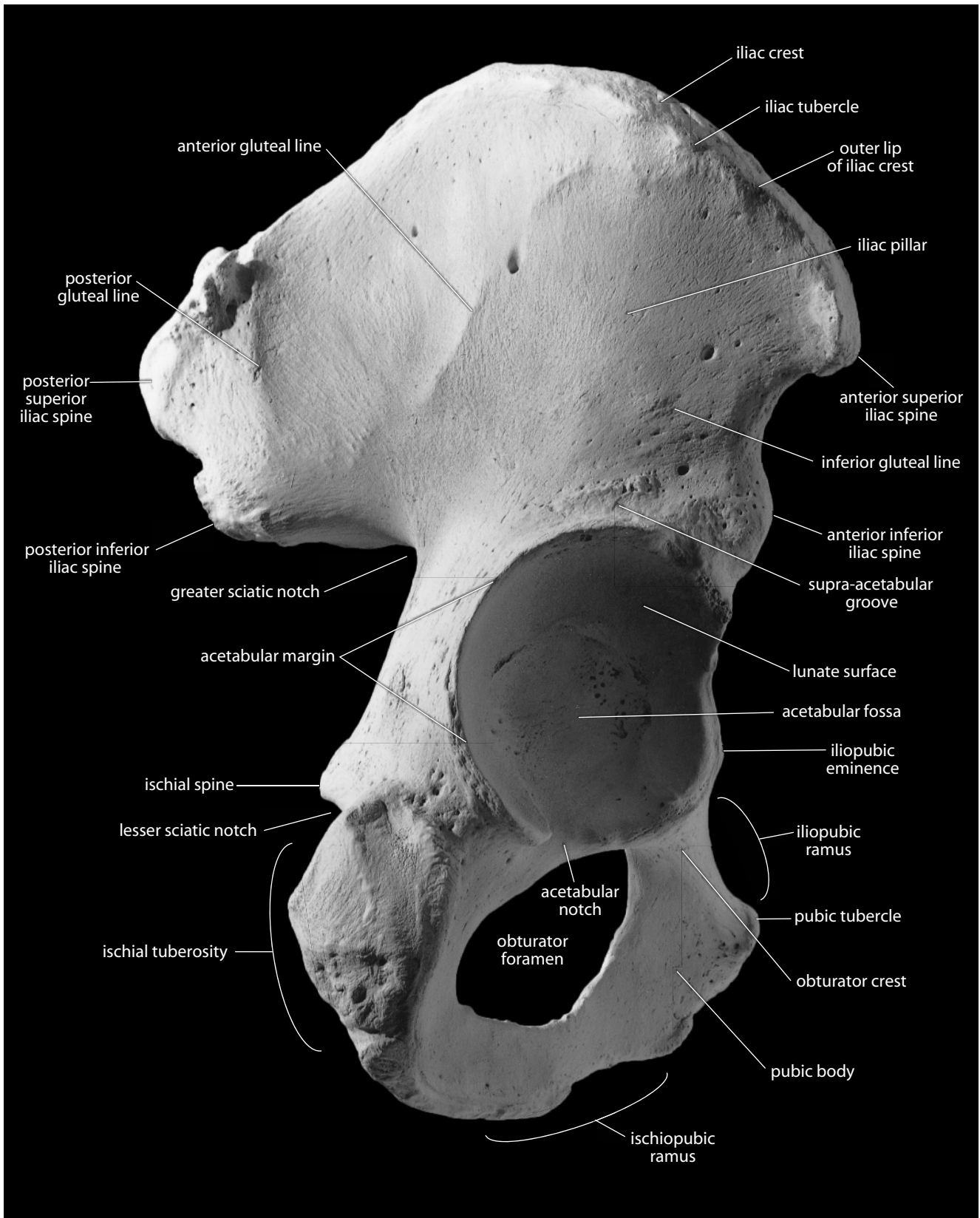


Figure 11.7 Right os coxae, lateral. Superior is up, anterior toward the right. Natural size.

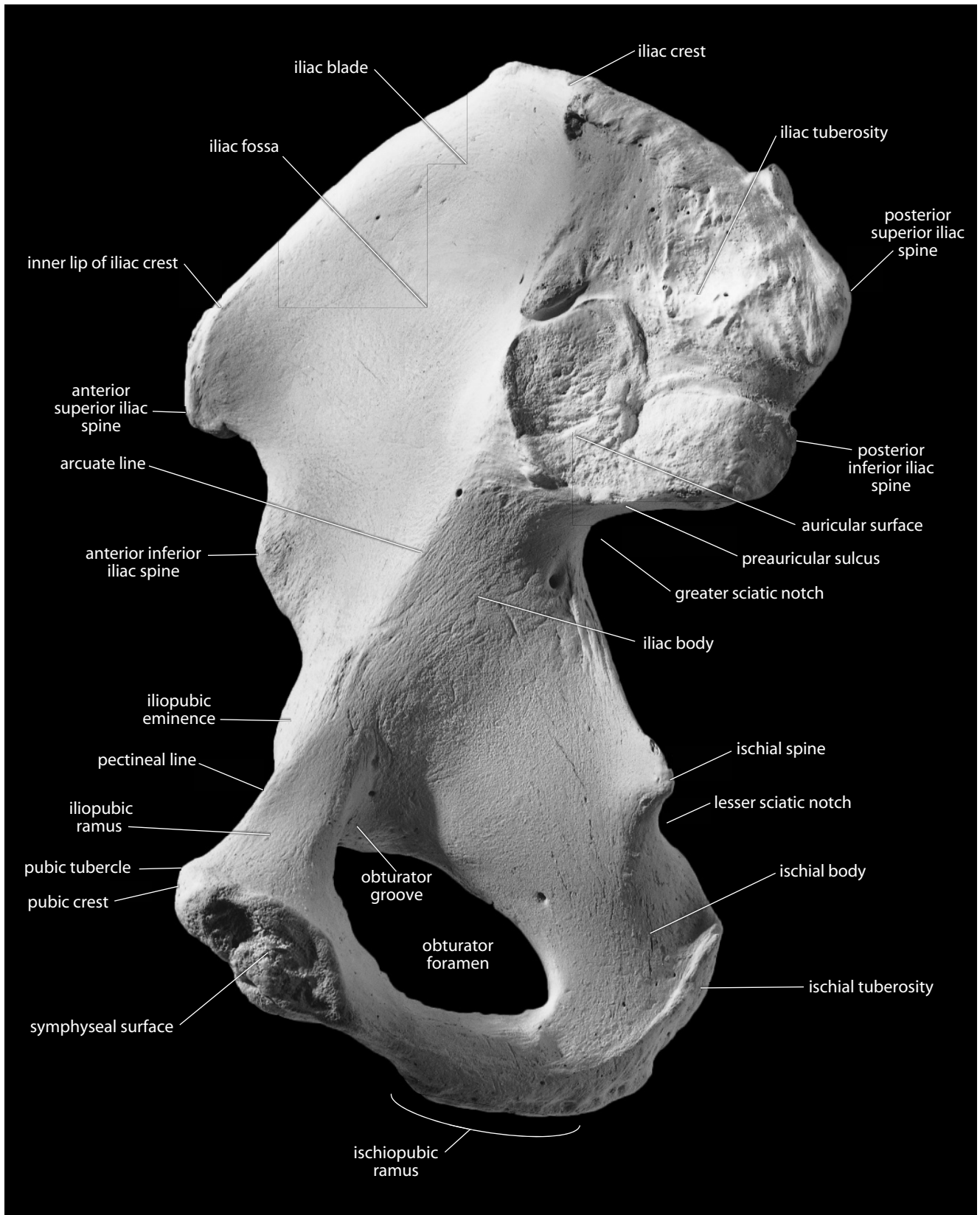


Figure 11.8 Right os coxae, medial. Superior is up, anterior toward the left. Natural size.

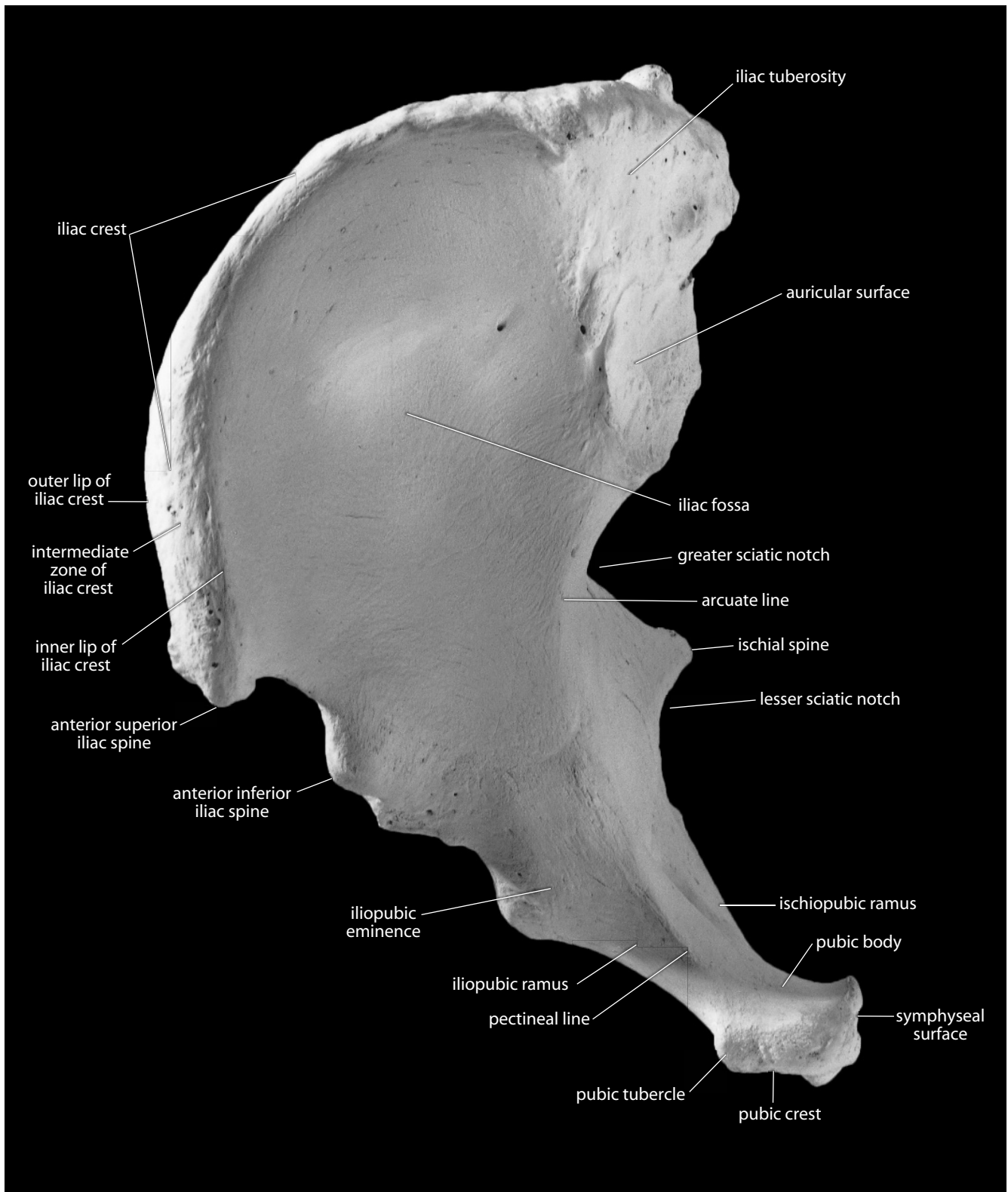


Figure 11.9 Right os coxae, anterosuperior view. Anterior is down. Natural size.

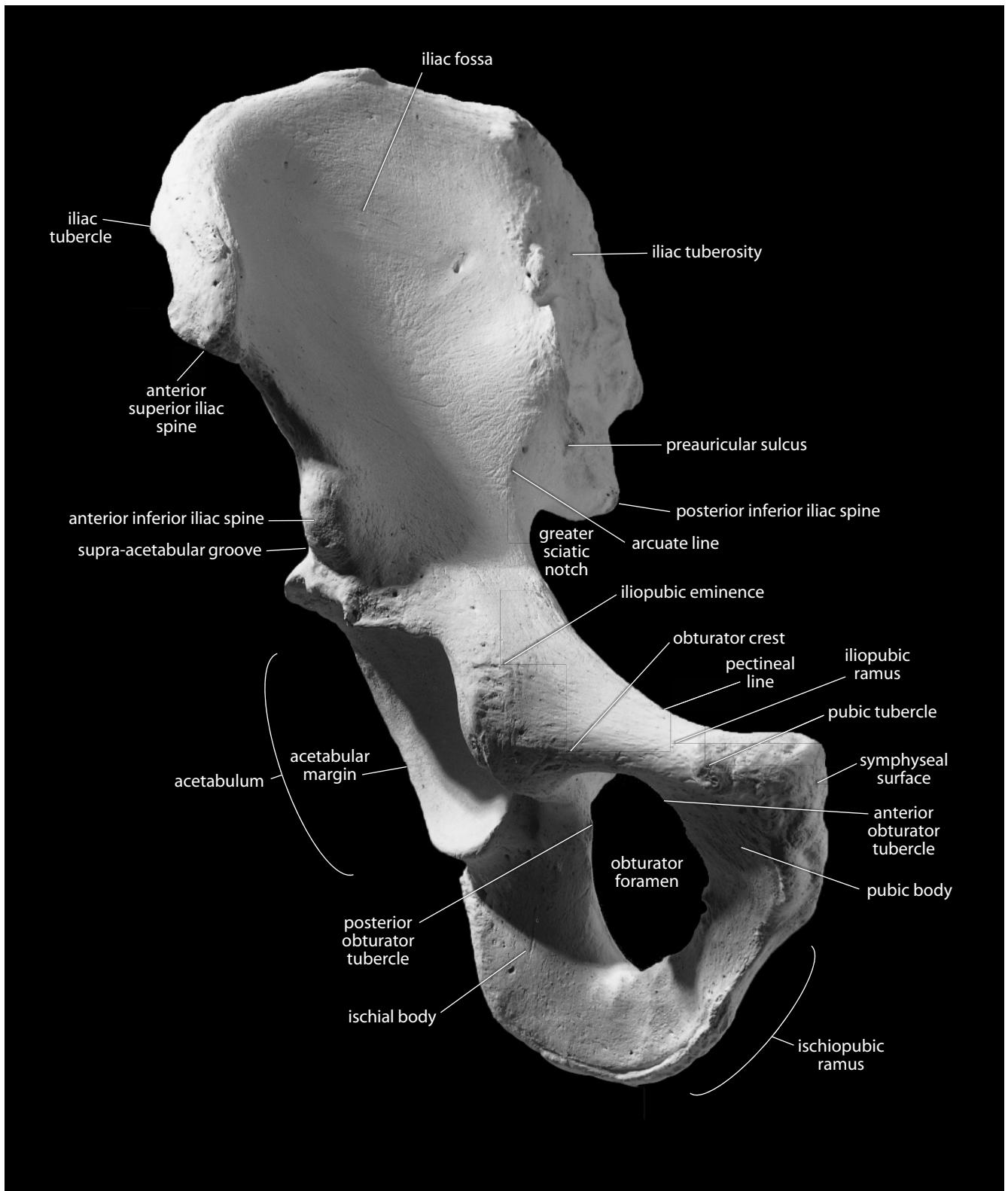


Figure 11.10 Right os coxae, anterior. Natural size.

- p. The **iliac crest** is the superior border of the ilium. It is S-shaped when viewed superiorly. Many of the *abdominal muscles* originate on the crest.
1. The **outer lip of the iliac crest** is the border that serves as the insertion of the *external oblique muscle*.
 2. The **inner lip of the iliac crest** is the ridge on the inner margin of the iliac crest that serves as the origin of the *transversus abdominis muscle*.
 3. The **intermediate zone** is the rugose area between the inner and outer lips of the iliac crest. The intermediate zone serves as the origin of the *internal oblique muscle*.
- q. The **anterior superior iliac spine** is located at the anterior end of the iliac crest. It anchors the *sartorius muscle* and the *inguinal ligament*.
- r. The **anterior inferior iliac spine** is a blunt projection on the anterior border of the os coxae, just superior to the acetabulum. It is the origin of the straight head of the *rectus femoris muscle*, a flexor of the thigh at the hip, and an extensor of the knee. Its lower extent serves as the attachment site for the *iliofemoral ligament*.
- s. The **posterior superior iliac spine** is the posterior terminus of the iliac crest. It is an attachment for part of the *gluteus maximus muscle*, an extensor, lateral rotator, and abductor of the femur at the hip.
- t. The **posterior inferior iliac spine** is a sharp projection just posteroinferior to the auricular surface. It partially anchors the *sacrospinous ligament*, which serves to bind the sacrum to the os coxae.
- u. The **preauricular sulcus** is a variable groove along the anteroinferior edge of the auricular surface.
- v. The **greater sciatic notch** is the wide notch just inferior to the posterior inferior iliac spine. The *piriformis muscle*, a lateral rotator of the thigh at the hip, and the nerves leaving the pelvis for the lower limb pass through this notch. Cortical bone in the os coxae is thickest in this area.
- w. The **ischial spine** for attachment of the *sacrospinous ligament* is located just inferior to the greater sciatic notch.
- x. The **lesser sciatic notch** is the notch between the ischial spine superiorly and the rest of the ischium inferiorly. The *obturator internus muscle*, a lateral rotator and sometimes abductor of the femur at the hip, passes through this notch.
- y. The **ischial tuberosity** is the blunt, rough, and massive posteroinferior corner of the os coxae. It anchors the extensor muscles of the thigh at the hip, including the *semitendinosus*, *semimembranosus*, *biceps femoris (long head)*, and *quadratus femoris*.
- z. The **iliac fossa** is the smooth hollow on the medial surface of the iliac blade.
- aa. The **arcuate line** is an elevation that sweeps anteroinferiorly across the medial surface of the os coxae from the apex of the auricular surface toward the pubis.
- ab. The **pectineal line** (or **pecten pubis**) is the anterior continuation of the arcuate line, often made sharper and more prominent by its role as the origin of the *pectineus muscle*.
- ac. The **iliopubic** (or **iliopectineal**) **eminence** marks the point of union of the ilium and the pubis just lateral to the arcuate line.
- ad. The **pubic crest** is the crest that connects the pubic tubercle to the pubic symphysis, providing the origin for the *rectus abdominis muscle*.
- ae. The **superior pubic** (or **iliopubic**) **ramus** spans the distance between the pubic body and the acetabulum.
- af. The **ischiopubic** (or **inferior pubic**) **ramus** is the thin, flat bridge of bone connecting the pubic body to the ischial body.
- ag. The **pubic tubercle** (or **spine**) is the prominent bump on the anterosuperior aspect of the pubic body. It serves to anchor the *inguinal ligament*.

- ah. The **symphyseal surface** of the pubis is the near-midline surface of the pubis where the two ossa coxae most closely approach. In life, the right and left symphyseal surfaces are covered in hyaline cartilage, separated by fibrocartilage, and bound together by strong *pubic ligaments* to form the **pubic symphysis**.
- ai. The **obturator foramen** is the large foramen encircled by the two pubic rami and the ischium. In life it is nearly occluded by the *obturator membrane*, with only the area of the obturator groove remaining open.
- aj. The **obturator crest** (or **ventral rim**) is the inferior margin of the anterolateral superior pubic ramus. It serves as the origin of the *pubofemoral ligament*.
- ak. The **anterior obturator tubercle** is a small projection on the margin of the obturator foramen, just anterior to the obturator groove.
- al. The **posterior obturator tubercle** is a small projection on the margin of the obturator foramen adjacent to the acetabular notch.
- am. The **obturator groove** (or **sulcus**) is the wide groove on the medial surface of the superior pubic ramus, at the superolateral corner of the obturator foramen. The *obturator vessels* and *nerve* pass through the *obturator canal*, which is roofed by this groove.

11.3.2 Growth (Figure 11.11)

There are three primary and five secondary centers of ossification in each os coxae. The ilium, ischium, and pubis form the primary centers, fusing through the acetabulum in the **triradiate suture**. The ilium has one secondary center at the anterior inferior spine and one across the iliac crest. The pubis has one center at the symphysis (the “ventral rampart”), and the ischium has one at the tuberosity that extends along the ischiopubic ramus. The eighth center (“os cotyledon”) is located in the depth of the acetabulum.

11.3.3 Possible Confusion

- Fragmentary iliac blades might be mistaken for cranial or scapular fragments. The cranial bones are, however, of more uniform thickness. They have cortices of about equal thickness around the diploë.
- Scapular blades are thinner than iliac blades and display subscapular ridges.
- Fragmentary auricular areas could be mistaken for sacra, but in the latter bone there are attached sacral alae, and the adjacent surfaces have no evidence of sacroiliac roughening or sciatic notches.

11.3.4 Siding

When intact, the os coxae is easily sided because the pubis is anterior, the iliac crest is superior, and the acetabulum is lateral. When fragmentary, various parts of the os coxae can be sided as follows:

- For isolated pubic regions, the ventral surface is rough, the dorsal surface is smooth and convex, the symphysis faces the midline, and the superior pubic ramus is more robust than the ischiopubic ramus.
- For isolated ischial regions, the thicker ramus faces the acetabulum. The thinner ramus is therefore anteroinferior. The surface of the ischial tuberosity faces posterolaterally.

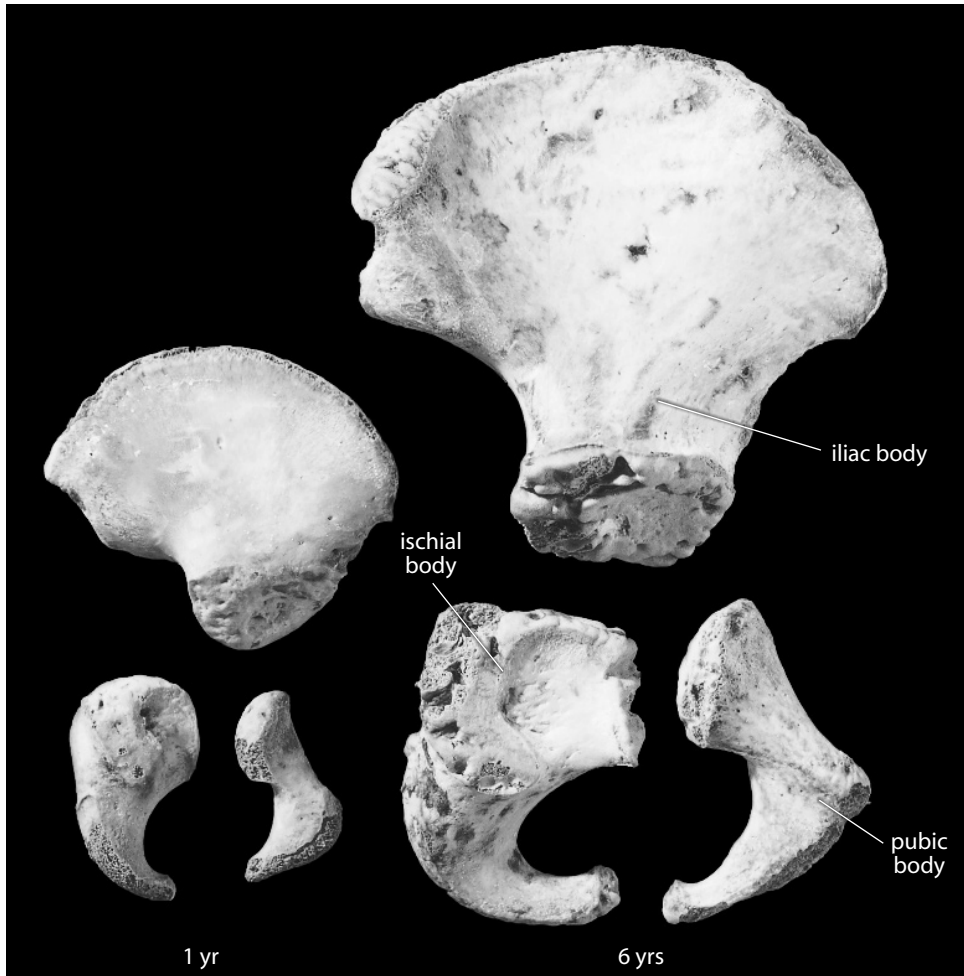


Figure 11.11 Os coxae growth. Natural size. The three elements of the os coxae, shown here in lateral view, are from a one-year-old child (*left*) and a six-year-old child (*right*).

- For isolated iliac blades, the iliac pillar is lateral and is anteriorly displaced. The auricular surface and related structures are posterior and medial.
- For isolated iliac crests, the iliac tubercle is anterior and lateral, and the lateral surface anterior to it is more concave than the surface posterior to it. The crest sweeps posteromedially from this point until it reaches the level of the anterior edge of the auricular surface and turns laterally.
- For isolated acetabula, the acetabular notch is inferior and faces slightly anteriorly. The inferior end of the 'c' made by the lunate surface is broader and more blunt than the superior end. The ischial ramus is posterior, and the superior pubic ramus is anterior. The ilium is superior.
- For isolated auricular surfaces, the auricular surface is posterior on the ilium and faces medially. Its apex points anteriorly, and the roughened surface for the sacroiliac ligaments is posterosuperior. The greater and lesser sciatic notches are posteroinferior.

11.3.5 Coxal Measurements (Figure 11.12)

Measurements of the os coxae are used in formulas for determination of sex and age, and locomotor and obstetric biomechanics, among others.

1. **Os coxae height** (Buikstra and Ubelaker, 1994: 82, #56): Using either a large sliding caliper or an osteometric board, determine the maximum distance between the iliac crest and the ischiopubic ramus.
2. **Superior iliac breadth** (also **os coxae breadth**) (Martin, 1928: 1033, #12; Buikstra and Ubelaker, 1994: 82, #57): Using either a sliding caliper or an osteometric board, measure the maximum distance between the anterior and posterior superior iliac spines.
3. **Immature iliac breadth** (Buikstra and Ubelaker, 1994: 46, #11a): Open the sliding caliper, place the stationary jaw on the unfused anterior superior iliac spine, and carefully narrow the caliper until the second jaw contacts the most distant point on the posterior superior iliac spine.

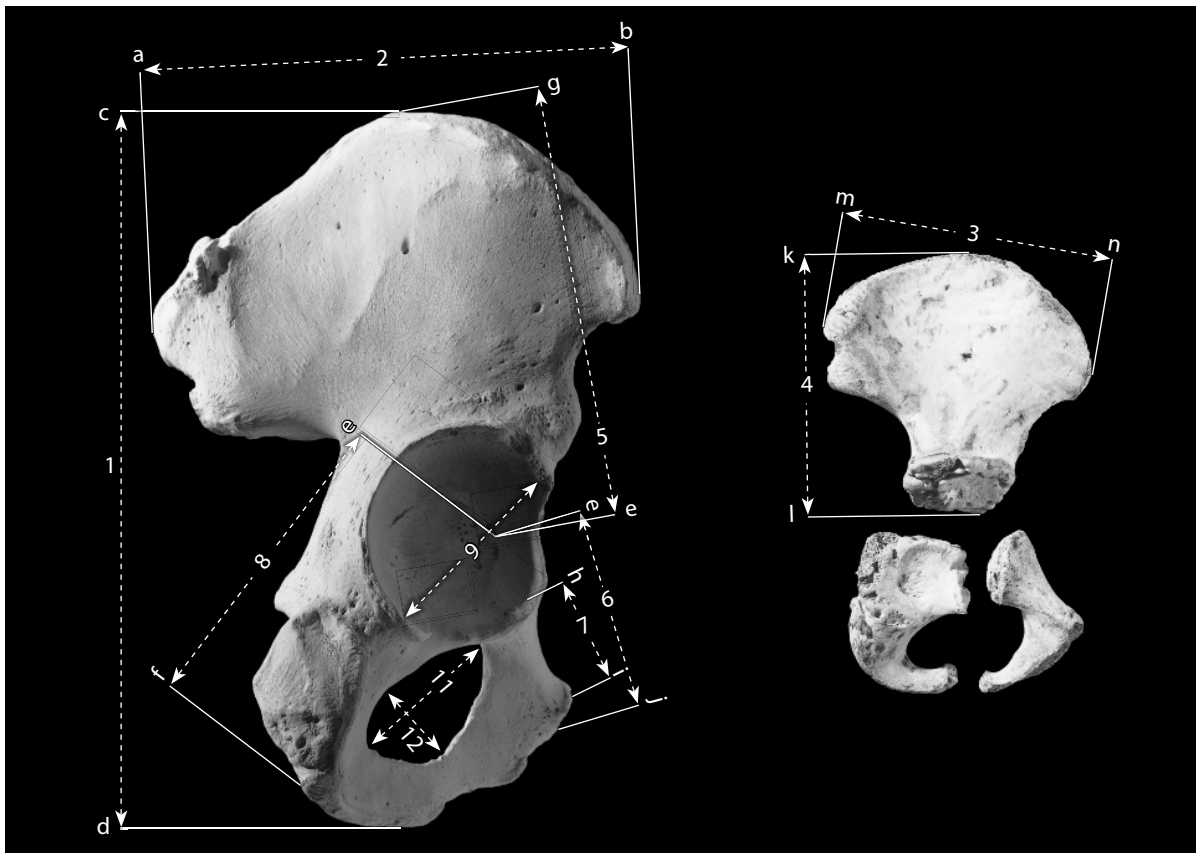

Figure 11.12 Os coxal measurements. One-half natural size.

Locations: a) point on the posterior superior iliac spine farthest from 'b'; b) point on the anterior superior iliac spine farthest from 'a'; c) point on the iliac crest farthest from 'd'; d) point on the ischium farthest from 'c'; e) point on the superior margin of the acetabular notch closest to the triradiate suture; f) point on the ischium farthest from 'e'; g) point on the iliac crest farthest from 'e'; h) point on the lunatic surface closest to the pubic symphysis; i) superiormost point on the pubic symphysis; j) point on the pubis farthest from 'e'; k) point on the ilium farthest from 'l'; l) point on acetabular extremity closest to the center of the triradiate suture; m) point on unfused posterior superior iliac spine farthest from 'n'; n) point on unfused anterior superior iliac spine farthest from 'm'.

Measurements: 1) os coxae height; 2) superior iliac (or os coxae) breadth; 3) immature iliac breadth; 4) immature iliac height; 5) iliac length; 6) pubic length; 7) acetabulosymphyseal length; 8) ischial length; 9) acetabular height; 10) obturator foramen length; 11) obturator foramen breadth.

4. **Immature iliac height** (Buikstra and Ubelaker, 1994: 46, #11b): Open the sliding caliper, place the stationary jaw on the midpoint of the unfused iliac crest, and carefully narrow the caliper until the second jaw contacts the most distant point on the acetabular extremity.
5. **Iliac length** (or **height**) (Martin, 1928: 1032, #9): Spread the sliding caliper fully open, and place the stationary jaw of the caliper at the point along the superior margin of the acetabular notch closest to the center of the triradiate suture. Carefully narrow the caliper until the second jaw contacts the most distant point on the iliac crest.
6. **Pubic length** (Martin, 1928: 1033, #17; Buikstra and Ubelaker, 1994: 82, #58): Spread the sliding caliper fully open, and place the stationary jaw of the caliper at the point along the superior margin of the acetabular notch closest to the center of the triradiate suture. Carefully narrow the caliper until the second jaw contacts the most distant point on the pubic body.
7. **Acetabulosymphyseal length** (McCown and Keith, 1939): Open the sliding caliper, place the stationary jaw on the point on the lunate surface closest to the pubic symphysis, and carefully narrow the caliper until the second jaw contacts the superiormost point on the pubic symphysis.
8. **Ischial length** (Martin, 1928: 1033, #16; Buikstra and Ubelaker, 1994: 82, #59): Spread the sliding caliper fully open, and place the stationary jaw of the caliper at the point along the superior margin of the acetabular notch closest to the center of the triradiate suture. Carefully narrow the caliper until the second jaw contacts the most distant point on the ischium.
9. **Acetabular height** (Martin, 1928: 1033, #22): Using the inside diameter jaws of a sliding caliper, place the stationary jaw on the edge of the lunate surface (not the acetabular margin) immediately beneath the anterior inferior iliac spine. Carefully spread the caliper until the second jaw contacts the most distant point on the lunate surface.
10. **Acetabular depth** (Trinkaus, 2003: 4): Using a coordinate caliper placed at the same two points as used for acetabular height, determine the maximum depth of the acetabular fossa.
11. **Obturator foramen length** (Martin, 1928: 1033, #20): Using the inside diameter jaws of a sliding caliper, place the point of the stationary jaw in the middle of the obturator groove and carefully spread the caliper until the second jaw contacts the most distant point on the inferior margin of the obturator foramen.
12. **Obturator foramen breadth** (Martin, 1928: 1033, #21): Using the inside diameter jaws of a sliding caliper, measure the greatest breadth of the obturator foramen perpendicular to obturator foramen length.

11.3.6 Coxal Nonmetric traits

- **Accessory hip and sacral facets:** The sacrum and ilium may articulate — and form articular facets — at locations other than the auricular surfaces. These facets will always be dorsal to the auricular surfaces. Usually scored as 0 (absent) or 1 (present).
- **Acetabular crease:** Occasionally a groove, crease, or other surface feature penetrates the acetabular lunate surface from the superior margin of the acetabular notch near the trace of the triradiate suture. Usually scored as 0 (absent), 1 (notch), 2 (pit), 3 (groove), 4 (fold), or 5 (other).
- **Preauricular sulcus:** A variable groove, just inferior to the caudal limb of the iliac auricular surface, is observed in some individuals — usually, but not exclusively, in females. Usually scored as 0 (absent), 1 (groove of pregnancy), or 2 (groove of ligament).
- **Underdeveloped acetabulum:** The acetabulum is unusually shallow; present from *in*

utero and often linked to congenital hip dislocation. Usually scored as 0 (absent) or 1 (present).

- **Dorsal pitting:** On the pelvic (superodorsal) surface of the pubic body, eroded areas of bone can be observed in some individuals — usually, but not exclusively, in females. Usually scored as 0 (absent), 1 (small), 2 (medium), or 3 (large).

11.4 Pelvis (Figures 11.13–11.14)

Much like the skull, the pelvis is a complex system that needs to be considered as a unit — its shape, orientation, and function are not as apparent when viewed as a set of isolated constituent elements.

The shape of the articulated pelvis is a hybrid one: it forms both a basin and a canal. The division between these shapes is the **pelvic brim**, the angulated but dull transition between the “false” pelvis above (the basin) and the “true” pelvis below (the canal).

The pelvis is acutely inclined with respect to the pelvic brim. The angle between the brim and a horizontal reference plane (**pelvic inclination**; see Figure 11.14) is usually around 65° (Dauber and Feneis, 2007). A handy way to quickly place the pelvis in approximate anatomical position is to hold the pelvis with the sacrum positioned posteriorly and the sacral promontory facing superiorly. Then imagine a transverse axis passing through right and left auricular surfaces, and rotate the pelvis about this axis (lowering the pubis) until the pubic tubercles and the anterior superior iliac spines are in the same vertical plane (Figure 11.14).

The hominid pelvis is an example of the elegant evolutionary compromises made in biological form as the result of multiple competing selective pressures. The selective pressures on the pelvis are numerous and varied, but two of the most important factors in humans are these:

- **Obstetrics:** the pelvis must be large enough (and/or pliant enough) to allow a large-brained full-term fetus to successfully navigate the birth canal (if not, the condition is called cephalopelvic disproportion. This was, until recent history, a leading cause of both maternal and fetal mortality).
- **Locomotion:** the pelvis must anchor the muscles used to stabilize the trunk during bipedal walking.

11.4.1 Anatomy

- a. **Pelvic surface** is the term for any surface of any pelvic bone that faces the pelvic cavity.
- b. The **pelvic cavity** is the space below the abdomen that is defined by the pelvic bones.
- c. The **pubic arch** is located immediately inferior to the pubic symphysis and is formed by the paired ischiopubic rami. The breadth of the pubic arch is measured as the subpubic angle.
- d. The **greater (or false) pelvis** is that portion of the pelvic cavity above the linea terminalis and between the alae of the ilium.
- e. The **lesser (or true) pelvis** is the portion of the pelvic cavity below the linea terminalis.
- f. The **linea terminalis** is the pronounced line separating the greater and lesser pelvis, formed by the sacral promontory, the arcuate line, the pectineal line, and the pubic crest.
- g. The **iliopectineal line** is that part of the linea terminalis formed by the arcuate line and the pectineal line.
- h. The **pelvic inlet** is the plane defined by the linea terminales. The pelvic inlet is the first of three constrictions that a fetus must navigate during the birthing process.

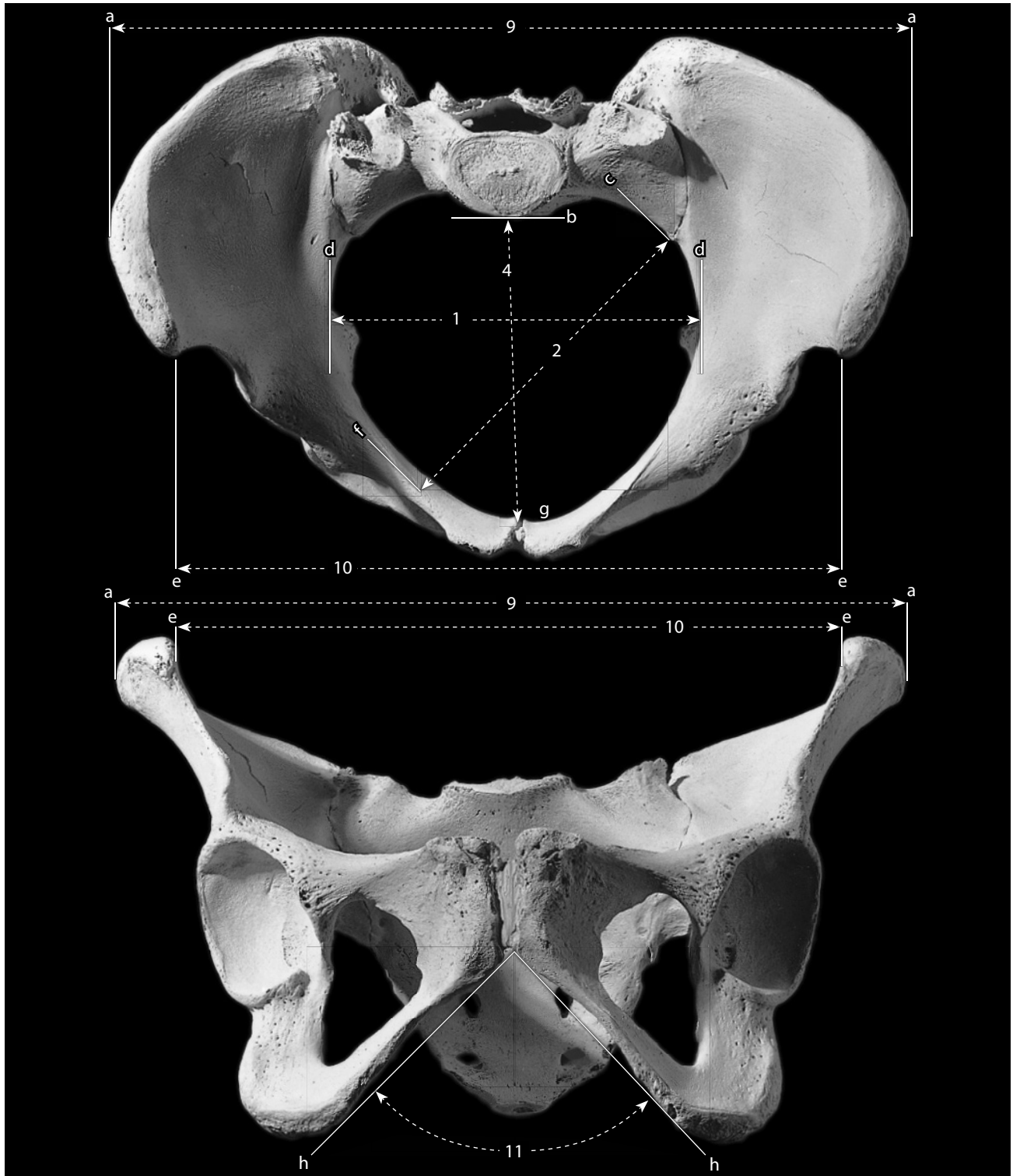


Figure 11.13 Pelvic measurements. One-half natural size.

Locations: a) lateralmost point on iliac crest; b) anteriormost point of sacral promontory; c) intersection of auricular apex and arcuate line; d) lateralmost point on arcuate line; e) anteroinferiormost point of anterior superior iliac spine; f) point on the iliopectineal line farthest from the contralateral 'c'; g) point on the pubic symphyseal margin closest to 'b'; h) line tangent to the inferior edge of the ischiopubic ramus.

Measurements: 1) transverse diameter; 2) oblique diameter; 4) true conjugate; 9) bi-iliac breadth (or intercrystal distance or diameter); 10) interspinous distance (or diameter); 11) subpubic angle.

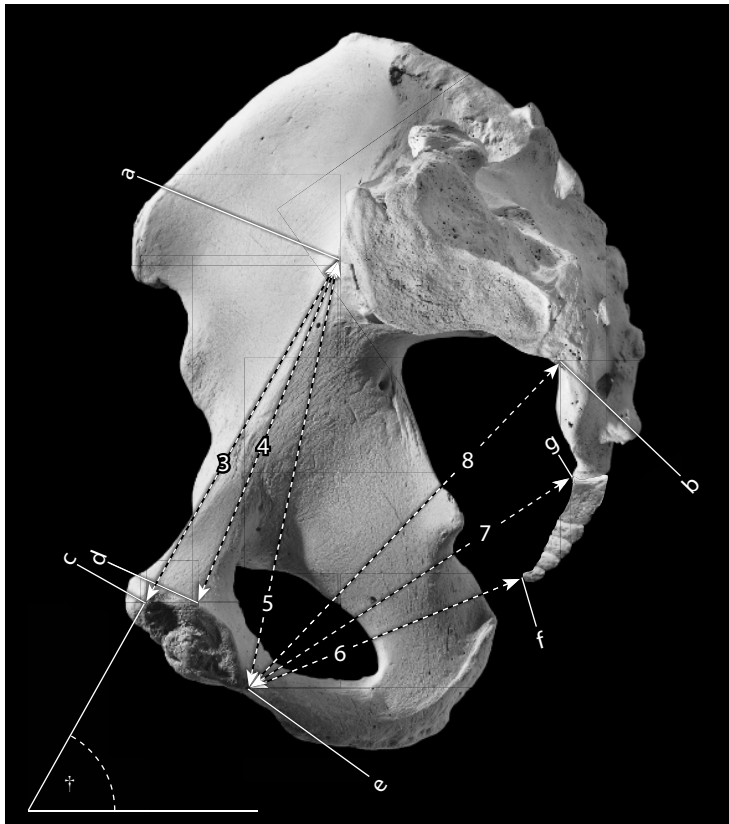


Figure 11.14 Midline pelvic measurements. Pelvic inclination (\dagger) cannot be reliably measured on skeletal remains, but is usually about 65° in humans (Dauber and Feneis, 2007). One-half natural size.

Locations: a) intersection of auricular apex and arcuate line; b) midline point of the line of fusion between S-3 and S-4; c) anterosuperiormost point of symphyseal margin; d) point on symphyseal margin closest to 'a'; e) posteroinferiormost point of symphyseal margin; f) anteroinferiormost point on coccyx; g) ventralmost point on border of coccygeal articulation.

Measurements: 3) anatomical conjugate; 4) true conjugate; 5) diagonal conjugate; 6) straight conjugate; 7) inferior sacropubic diameter; 8) median conjugate.

- i. The **pelvic outlet** is the plane defined by the ischiopubic rami, the ischial tuberosities, and the tip of the coccyx.

11.4.2 Pelvic Measurements (Figures 11.13–11.14)

Measurements of the pelvis are used in biomechanical analyses of locomotion, determinations of trunk shape, posture, and climatic adaptation, and in obstetric determinations like cephalopelvic disproportion.

1. **Transverse diameter** (Martin, 1928: 1034, #24): Using a deep-jawed sliding caliper, determine the greatest mediolateral distance between the right and left arcuate lines.
2. **Oblique diameter** (Martin, 1928: 1034, #25): Using a standard or deep-jawed sliding caliper, measure the distance from where the arcuate line meets the auricular surface of the ilium on one side to the farthest point on the arcuate line on the opposite side.
3. **Anatomical conjugate** (Dauber and Feneis, 2007: 64–65, #26): Using a standard or deep-jawed sliding caliper, determine the shortest distance between the sacral promontory and the anterosuperior margin of the pubic symphyseal surface.
4. **True conjugate** (Martin, 1928: 1033, #23): Using either a deep-jawed or offset-jaw caliper, determine the shortest distance between the sacral promontory and the posterosuperior margin of the pubic symphyseal surface.

5. **Diagonal conjugate** (Martin, 1928: 1034, #23(2)): With a sliding caliper equipped with at least one outside point extension, place the point extension on the posteroinferiormost point of the symphyseal margin, and determine the shortest distance to the sacral promontory. A difficult measurement to take without an extended-point caliper.
6. **Straight conjugate** (Martin, 1928: 1034, #26(1)): Using a deep-jawed sliding caliper, measure the distance from the tip of the coccyx to the inferiormost point of the pubic symphyseal margin.
7. **Inferior sacropubic diameter** (Martin, 1928: 1034, #26): Using a deep-jawed sliding caliper, measure the distance from the ventralmost point on the border of the coccygeal articulation to the inferiormost point of the pubic symphyseal margin.
8. **Median conjugate** (Dauber and Feneis, 2007: 64–65, #30): Using a deep-jawed sliding caliper, determine the minimum distance between the S-3/S-4 line of fusion and the inferiormost point of the pubic symphyseal margin.
9. **Bi-iliac breadth** (or **intercrystal distance** or **diameter**) (Martin, 1928: 1032, #5): Using an osteometric board or large sliding caliper, measure the maximum distance between right and left iliac crests while the pelvic bones are held in articulation (there should be a gap of up to a centimeter between symphyseal surfaces to account for the hyaline cartilage and fibrocartilage of the living symphysis).
10. **Interspinous distance** (or **diameter**) (Martin, 1928: 1032, #5(1)): Using a spreading or sliding caliper, determine the distance between the anteroinferiormost points of both anterior superior iliac spines. As with bi-iliac breadth, this measurement is most accurately determined while the pelvic bones are held together in proper articulation.
11. **Subpubic angle** (Martin, 1928: 1034–1035, #33): Using a protractor or goniometer, measure the angular distance between the lines that are tangent to the inferior edge of the ischiopubic rami. As with the previous two measurements, this metric is most accurately determined while the pelvic bones are held together in proper articulation.

11.5 Functional Aspects of the Pelvic Girdle

The human pelvis is the distinctive foundation for a unique locomotor mode among primates, habitual bipedality. As this locomotor mode was adopted over six million years ago, most muscle groups attached to the pelvis altered their function. The bony architecture of the pelvis shows the effects of these mechanical changes (Lovejoy, 1988).

The three axes and six possible directions of rotation at the hip joint are the same as those in the shoulder joint — abduction and adduction, medial and lateral rotation, and flexion and extension. Like the *deltoideus muscle* of the shoulder, the major hip abductors *gluteus medius* and *gluteus minimus* form a hood across the top of the joint. Pulling between the iliac blade and the femur's greater trochanter, these muscles perform the key role of stabilizing the pelvis and superincumbent trunk during walking. The largest muscle in the human body by mass, *gluteus maximus*, is defined as a hip extensor, and in humans this muscle's primary role is to keep the trunk from pitching forward during running. The forward swing of the leg during walking is produced by the *iliopsoas muscle*, and the leg is decelerated by the *hamstring muscles*. These and other muscles that control the movements of the hip joint take their origin from various surfaces and projections of the os coxae.

Chapter 12

LEG: FEMUR, PATELLA, TIBIA, AND FIBULA

THE EVOLUTION OF the tetrapod leg from pelvic fin structures mirrors that of the arm as described in Chapter 9. As with the arm, there is a single proximal limb element and two distal limb elements. The single thigh bone, the **femur**, is the serial homolog of the upper arm bone, the humerus. Likewise, the lower bones of the leg, the **tibia** and **fibula**, are serial homologs of the radius and ulna. The general structural layout of leg elements differs from that of the arm in one notable way: the largest sesamoid bone in the body, the **patella**, lies at the knee joint. The patella is functionally analogous to, if not a serial homolog of, the olecranon (now fused to the ulna, but in some earlier tetrapods it was a separate bone, the ulnar sesamoid). The bipedal mode of locomotion practiced by hominids has resulted in major specializations of the leg bones.

12.1 Femur (Figures 12.1–12.8)

12.1.1 Anatomy

The femur is the longest, heaviest, and strongest bone in the body. It supports all of the body's weight during standing, walking, and running. Because of its strength and density, it is frequently recovered in forensic, archaeological, and paleontological contexts. The femur is a particularly valuable bone because of the information it can provide on the stature of an individual (Chapter 19).

The femur articulates with the acetabulum of the os coxae. Distally, it articulates with the patella and the proximal tibia. The leg's actions at the hip include medial and lateral rotation, abduction, adduction, flexion, and extension. At the knee, motion is far more restricted, confined mostly to flexion and extension. Although the main knee action is that of a sliding hinge, this joint is one of the most complex in the body.

- a. The **femoral head** is the rounded proximal part of the bone that fits into the acetabulum. It constitutes more of a sphere than the hemispherical humeral head.
- b. The **fovea capitis** is the small, nonarticular depression near the center of the head of the femur. It receives the *ligamentum teres* from the acetabular notch of the os coxae.
- c. The **femoral neck** connects the femoral head with the shaft and the greater trochanter.
- d. The **greater trochanter** is the large, blunt, nonarticular prominence on the lateral, proximal part of the femur. It is the insertion site for the *gluteus minimus* (anterior aspect of the trochanter) and *gluteus medius muscles* (posterior aspect), both major abductors of the thigh

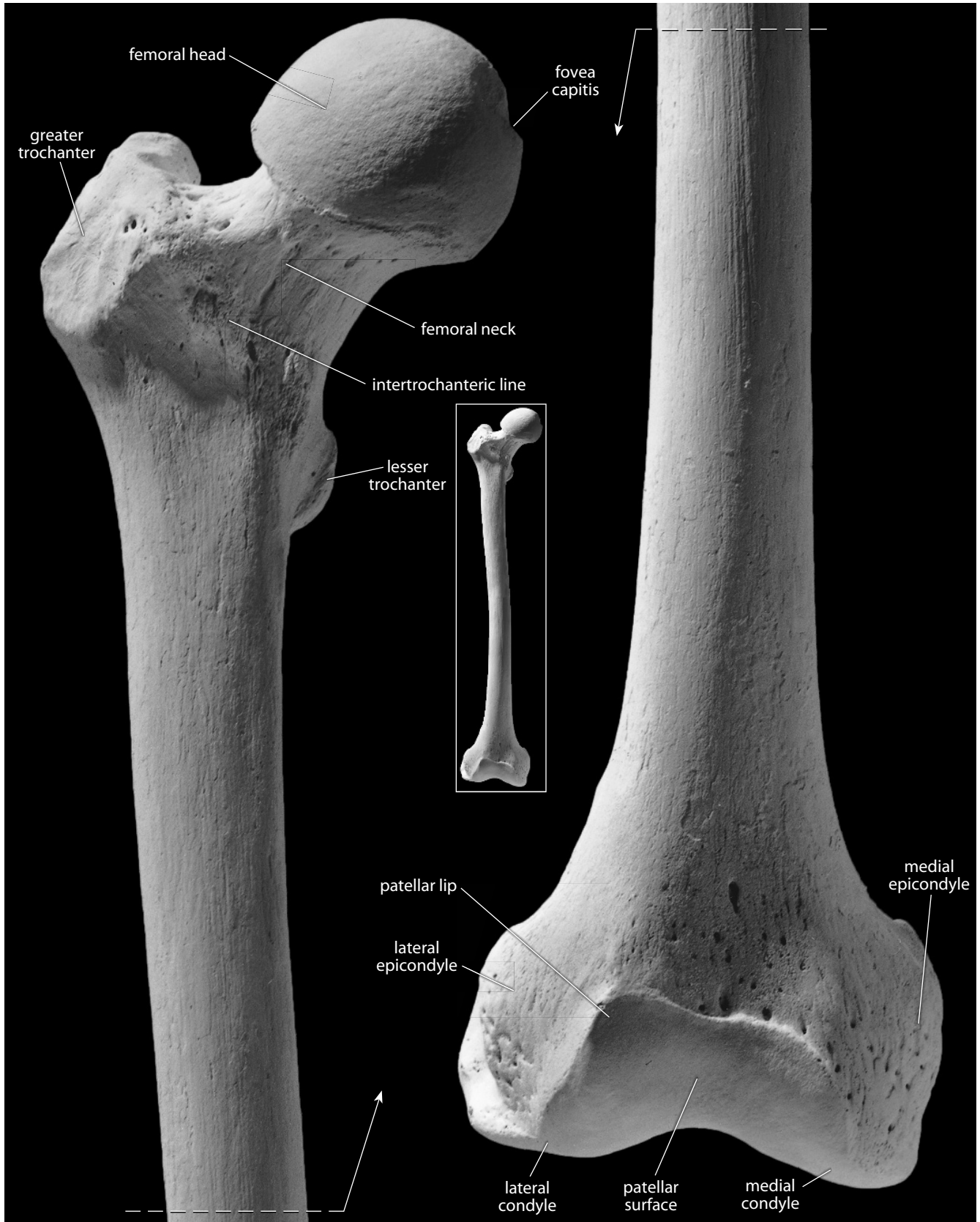


Figure 12.1 **Right femur, anterior.** *Left:* proximal end; *right:* distal end. Natural size.

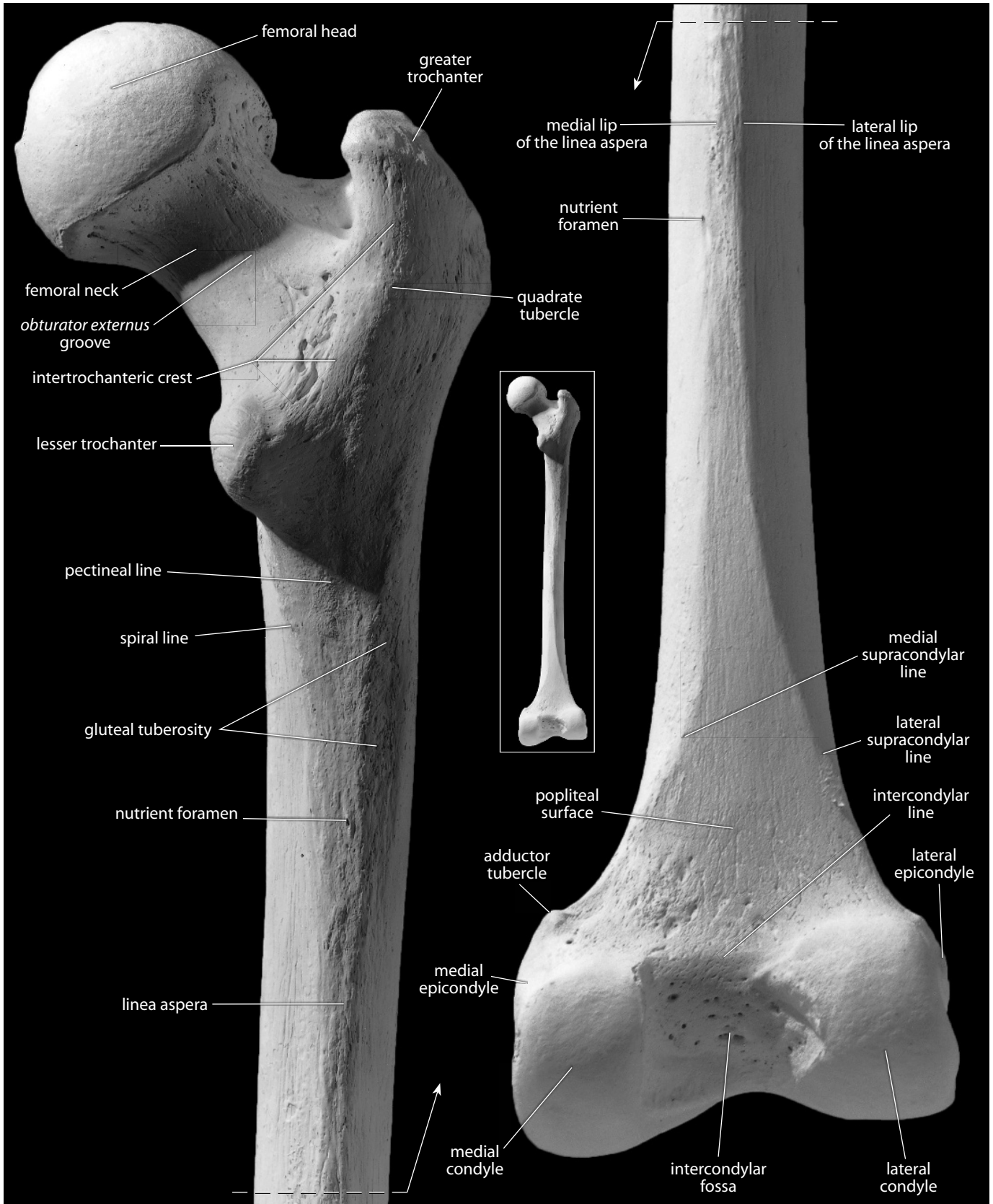


Figure 12.2 Right femur, posterior. *Left:* proximal end; *right:* distal end. Natural size.

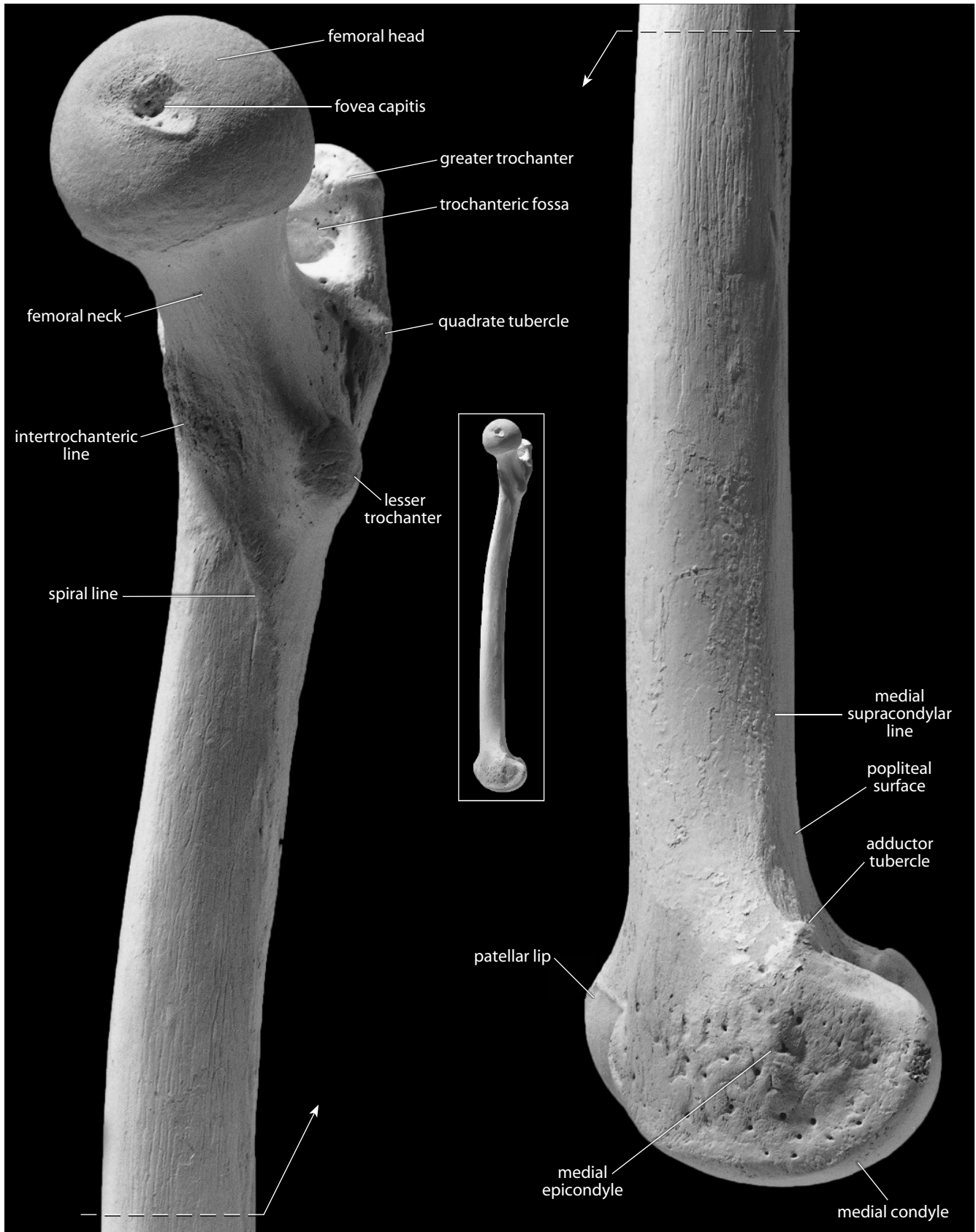


Figure 12.3 Right femur, medial. *Left:* proximal end; *right:* distal end. Natural size.

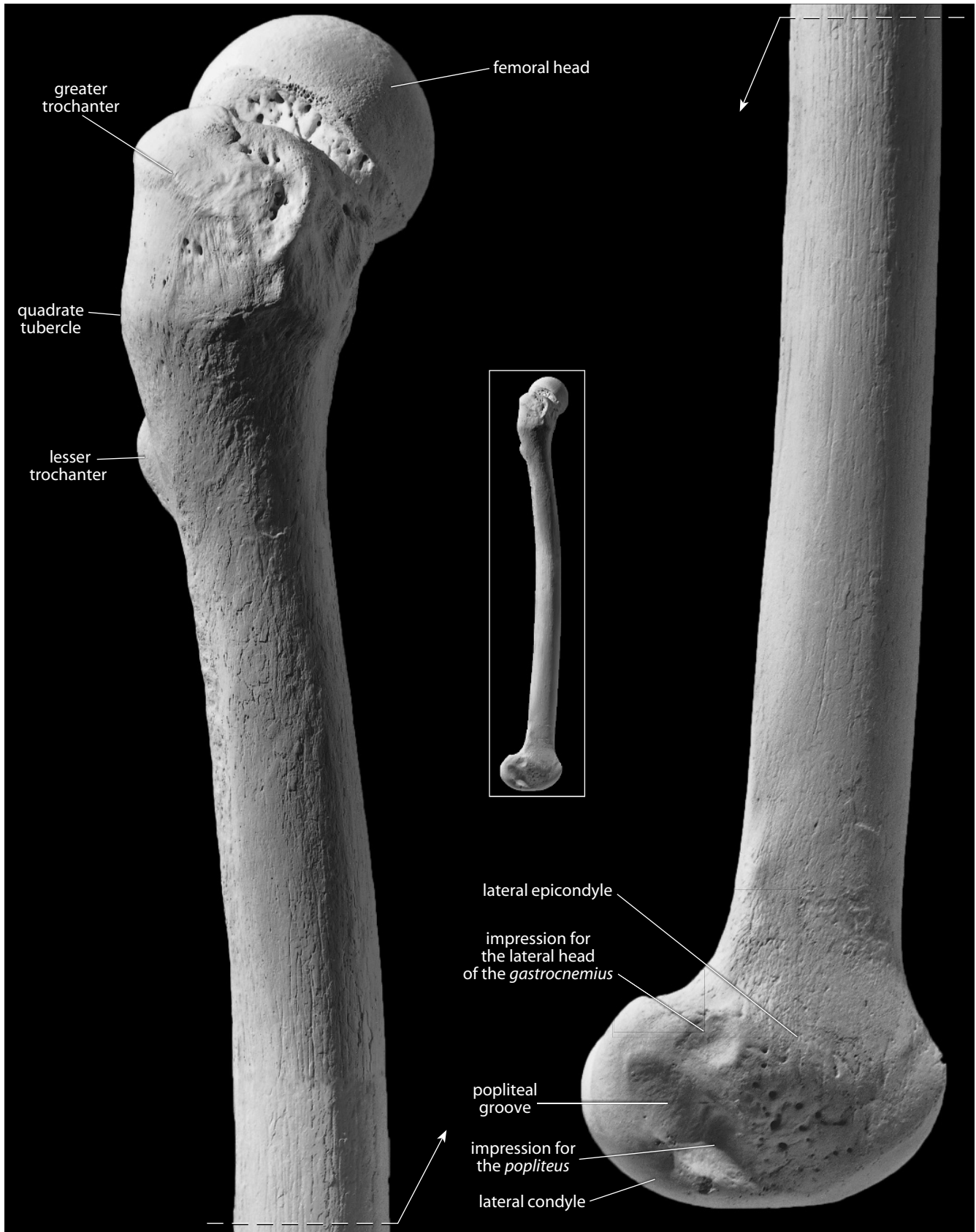


Figure 12.4 Right femur, lateral. *Left*: proximal end; *right*: distal end. Natural size.

and stabilizers of the hip. Their origins are on the broad, flaring iliac blade of the os coxae. These muscles are crucial in stabilizing the trunk when one leg is lifted from the ground during bipedal locomotion.

- e. The **intertrochanteric line** is a variable, fairly vertical, roughened line that passes between the lesser and greater trochanters on the anterior surface of the base of the neck of the femur. Superiorly, this line anchors the *iliofemoral ligament*, which is the largest ligament in the human frame. It acts to strengthen the *joint capsule* of the hip.
- f. The **trochanteric fossa** is the pit excavated into the posteromedial wall of the greater trochanter. This pit is for insertion of the *tendon of obturator externus*, a muscle that originates around and across the membrane that stretches across the obturator foramen of the os coxae. This muscle acts to rotate the thigh laterally at the hip. Just above its insertion, the medial tip of the greater trochanter receives several hip muscles: the *superior* and *inferior gemelli*, the *obturator internus*, and the *piriformis*. The latter two are important abductors, and all of these muscles can rotate the femur laterally.
- g. The **obturator externus groove** is a shallow depression aligned laterally and superiorly across the posterior surface of the femoral neck. In hominids, erect posture brings the *tendon of the obturator externus muscle* into contact with the posterior surface of the femoral neck, creating the groove.
- h. The **lesser trochanter** is the blunt, prominent tubercle on the posterior femoral surface just inferior to the point where the neck joins the shaft. This is the point of insertion of the *iliopsoas tendon* (the common *tendon of the iliacus muscle*, originating in the iliac fossa, and the *psaos major muscle*, originating from the lumbar vertebrae and their disks). These muscles are major flexors of the thigh at the hip.
- i. The **intertrochanteric crest** is the elevated line on the posterior surface of the proximal femur between the greater and lesser trochanters. It passes from superolateral to inferomedial. Just above its midpoint is a small tubercle (the **quadratus tubercle**), which is the site of insertion of the *quadratus femoris muscle*, a lateral rotator of the femur.
- j. The **gluteal tuberosity** (or **line, crest, or ridge**) is a long, wide, roughened, posterolaterally placed feature that extends from the base of the greater trochanter to the lateral lip of the *linea aspera* (see 12.1.1o). It can be a depression or it can assume the form of a true tuberosity. If the latter is present, it is often referred to as the **third trochanter**. It is the insertion for part of the *gluteus maximus muscle*, an extensor, abductor, and lateral rotator of the thigh at the hip that originates on the posterior half of the os coxae, the sacrum, and the coccyx.
- k. The **spiral line**, spiraling inferior to the lesser trochanter, connects the inferior end of the intertrochanteric line with the medial lip of the *linea aspera*. It is the origin of the *vastus medialis muscle*, a part of the *quadriceps femoris muscle*, a knee extensor that inserts on the anterior tibia via the patella.
- l. The **pectineal line** is a short, curved line that passes inferolaterally from the base of the lesser trochanter, between the spiral line and gluteal tuberosity. It is the insertion of the *pectineus muscle*, which originates from the pubic part of the os coxae and acts to adduct, laterally rotate, and flex the thigh at the hip.
- m. The **femoral shaft** is the long section between the expanded proximal and distal ends of the bone.
- n. The **linea aspera** is the long, wide, roughened, and elevated ridge that runs along the posterior shaft surface. It collects the spiral line, pectineal line, and gluteal tuberosity proximally and divides into the medial and lateral supracondyloid ridges distally. The *linea aspera* is a primary origin site for the *vastus muscles* and the primary insertion site of the adductors (*longus, brevis, and magnus*) of the hip.
- o. The **medial lip of the linea aspera** marks the medial extent of the *linea aspera* and serves as the site of insertion of *adductor magnus*, and *adductor longus*.

- p. The **lateral lip of the linea aspera** marks the lateral border of the linea aspera and serves as the site of insertion of *vastus lateralis*, and the *short head of biceps femoris*.
- q. The **nutrient foramen** is located about midshaft level on the posterior surface of the bone, adjacent to or on the linea aspera. This foramen exits the bone distally.
- r. The **medial supracondylar line** (or **ridge**) is the inferior, medial extension of the linea aspera, marking the distal, medial corner of the shaft. It is fainter than the lateral supracondylar line.
- s. The **lateral supracondylar line** (or **ridge**) is the inferior (distal), lateral extension of the linea aspera. It is more pronounced than the medial supracondylar line.
- t. The **popliteal surface** is the wide, flat, triangular area of the posterior, distal femur. It is bounded by the condyles inferiorly and by the supracondylar lines medially and laterally.
- u. The **lateral condyle** is the large, protruding, articular knob on the lateral side of the distal femur.
- v. The **lateral epicondyle** is the convexity on the lateral side of the lateral condyle. It is an attachment point for the *lateral collateral ligament* of the knee. Its upper surface bears a facet that is an attachment point for one head of the *gastrocnemius muscle*, a flexor of the knee and plantarflexor of the foot at the ankle.
- w. The **popliteal groove**, a smooth hollow on the posterolateral side of the lateral condyle, is a groove for the *tendon of the popliteus muscle*. This muscle originates from the impression just anteroinferior to the groove, and it inserts on the posterior tibial surface. *Popliteus* is a medial rotator of the tibia at the knee.
- x. The **medial condyle** is the large, articular knob on the medial side of the distal femur. Its medial surface bulges away from the axis of the shaft. The medial condyle extends more distally than the lateral condyle.
- y. The **medial epicondyle** is the convexity on the medial side of the medial condyle. It is a point of attachment for the *medial collateral ligament* of the knee.
- z. The **adductor tubercle** is a variable, raised tubercle on the medial supracondylar line just superior to the medial epicondyle. It is an attachment point for the *adductor magnus*, a muscle originating on the lower edge of the ischiopubic ramus and ischial tuberosity. This muscle adducts the thigh at the hip.
- aa. The **impression for the lateral head of the gastrocnemius** is a shallow depression on the superior edge of the posterior projection of the lateral epicondyle.
- ab. The **impression for the popliteus** is a shallow depression on the posterolateral side of the lateral condyle, adjacent to the anteroinferior limit of the popliteal groove.
- ac. The **intercondylar fossa, or notch**, is the nonarticular, excavated surface between the distal and posterior articular surfaces of the condyles. Within the fossa are two facets that are the femoral attachment sites of the *anterior* and *posterior cruciate ligaments*, a pair of crossed ligaments linking the femur and tibia. These ligaments strengthen the knee joint.
- ad. The **intercondylar line** is on the posterior surface of the distal femur, running between the superolateral corner of the medial condyle and the superomedial corner of the lateral condyle. It delineates the boundary between the popliteal surface and the intercondylar fossa (or notch).
- ae. The **patellar surface** is a notched articular area on the anterior surface of the distal femur, over which the patella glides during flexion and extension of the knee. The lateral surface of this notch is elevated, projecting more anteriorly than the medial boundary of the notch. This helps prevent lateral dislocation of the patella during full extension of the knee.
- af. The **patellar lip** is the raised lateral margin of the patellar surface. The elevated patellar lip of hominids helps to prevent the dislocation of the patella during bipedal locomotion.

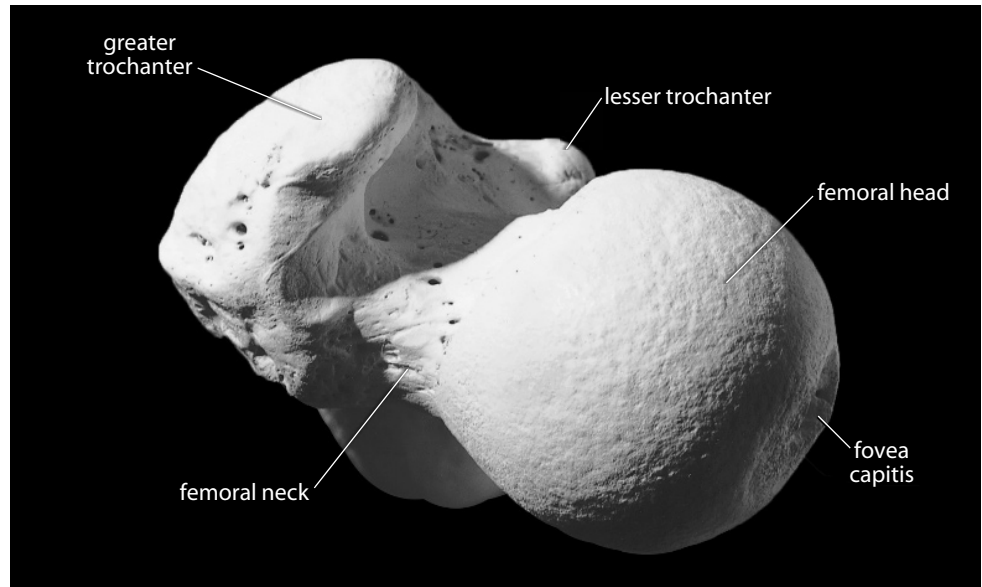


Figure 12.5 **Right femur, proximal.** Posterior is up, lateral is toward the left. Natural size.

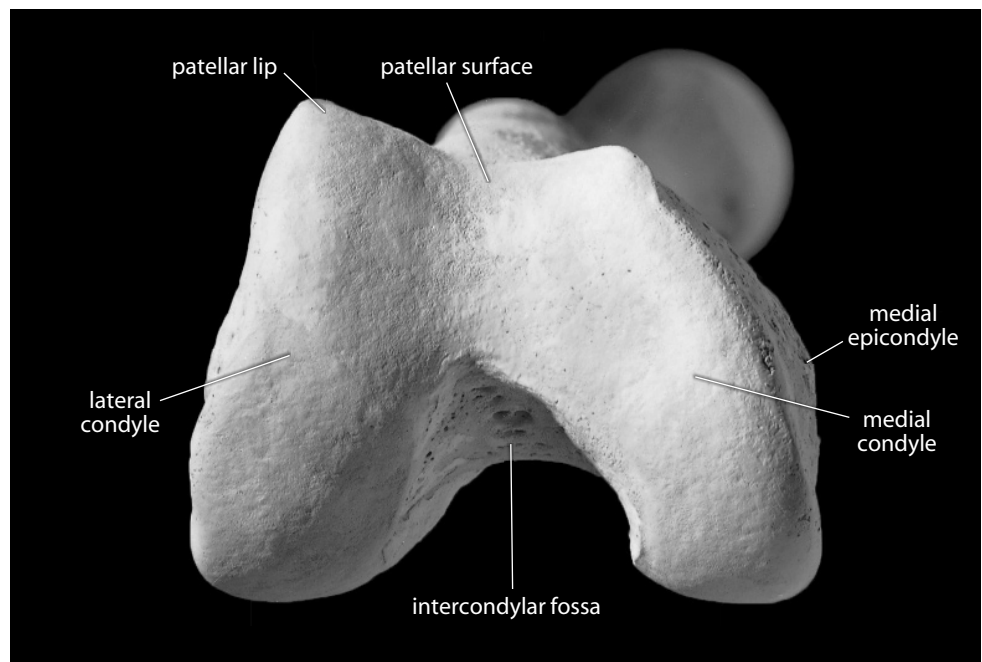
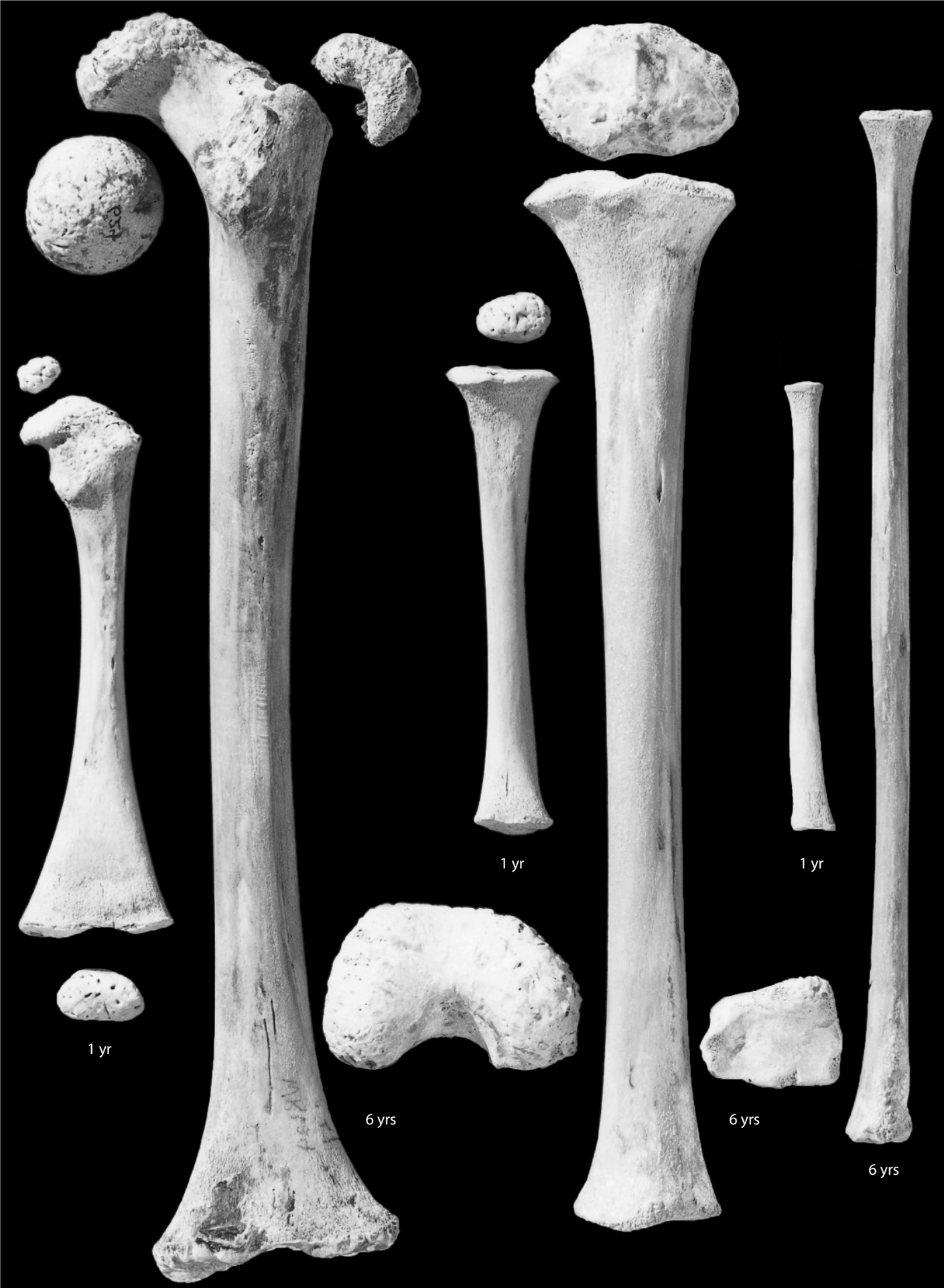

Figure 12.6 **Right femur, distal.** Anterior is up, lateral is toward the left. Natural size.

Figure 12.7 **Femoral, tibial, and fibular growth (opposite).** The pairs of immature femora (*left*), tibiae (*middle*), and fibulae (*right*), shown here in posterior view, are from a one-year old and a six-year-old. Natural size.



1 yr

1 yr

1 yr

6 yrs

6 yrs

6 yrs

12.1.2 Growth (Figure 12.7)

The femur ossifies from five centers: the shaft, the femoral head, the distal end, the greater trochanter, and the lesser trochanter. The femoral head appears at about 6 months to a year. It begins to fuse to the diaphysis at 14–19 years in males, and at about 12–16 years in females. The greater trochanteric epiphysis appears between ages 2–5. It then begins to fuse at 16–18 years in males, and at 14–16 years in females. The lesser trochanteric epiphysis appears between ages 7–12 and then begins to fuse at 16–17 years in both sexes. The distal epiphysis appears just before birth. It begins to fuse with the shaft at about 16–20 years in males, and at about 14–18 years in females (Scheuer and Black, 2000).

12.1.3 Possible Confusion

Neither intact femora nor femoral fragments are easily confused with other bones.

- The femoral head has a fovea and is a more complete sphere than the humeral head.
- The femoral shaft is larger, has a thicker cortex, and is rounder in cross section than any other shaft. It has only one longitudinal feature with sharp edges, the linea aspera (see cross sections in Chapter 14).

12.1.4 Siding

- For intact femora or proximal ends, the head is proximal and faces medially. The lesser trochanter and linea aspera are posterior.
- For isolated femoral heads, the fovea is medial and displaced posteriorly and inferiorly. The posteroinferior head–neck junction is more deeply excavated than the anterosuperior junction.
- For proximal femoral shafts, the nutrient foramen opens distally, and the linea aspera is posterior and thins inferiorly. The gluteal tuberosity is superior and faces posterolaterally.
- For femoral midshafts, the nutrient foramen opens distally, the bone widens distally, and the lateral posterior surface is usually more concave than the medial posterior surface.
- For distal femoral shafts, the shaft widens distally and the lateral supracondylar ridge is more prominent than the medial. The medial condyle extends more distally than the lateral.
- For femoral distal ends, the intercondylar notch is posterior and distal, and the lateral border of the patellar notch is more elevated. The lateral condyle bears the popliteal groove, and the medial condyle bulges away from the line of the shaft. Relative to the shaft axis, the lateral condyle extends more posteriorly than the medial. The medial condyle extends more distally than the lateral because in anatomical position the femur angles beneath the body.

12.1.5 Femoral Measurements (Figure 12.8)

Measurements of the femur are used for stature estimation, age estimation, sex determination, gait reconstruction, biomechanical load calculations, and other analyses.

1. **Maximum femoral length** (Martin, 1928: 1037, #1; Buikstra and Ubelaker, 1994: 82, #60): The maximum length that can be measured between the top of the femoral head and the bottom of the farthest condyle. Measured with an osteometric board.

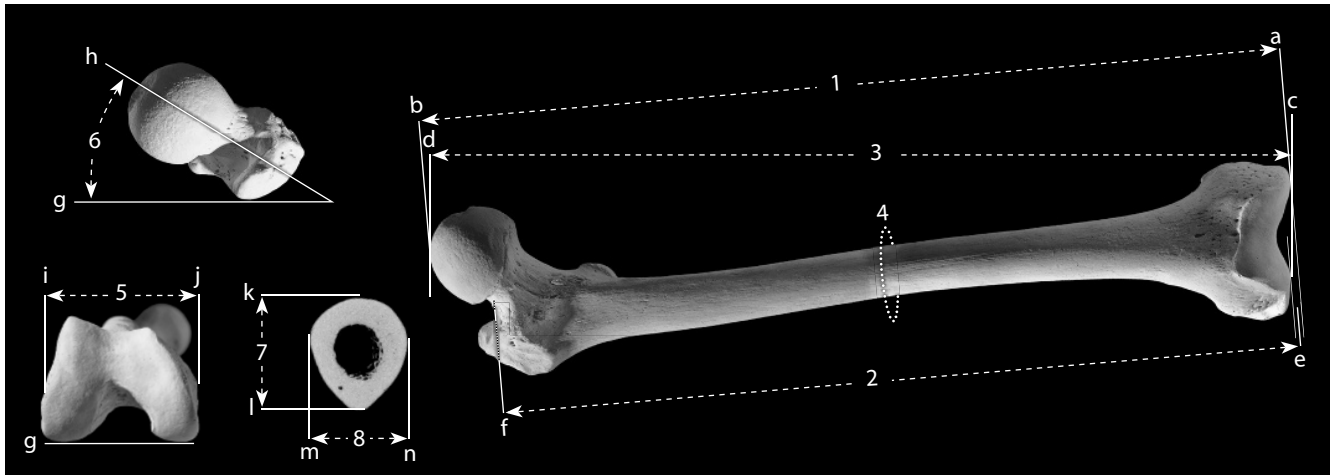


Figure 12.8 Femoral measurements. One-fourth (bone) and one-half (CT scan) natural size.

Locations: a) line through inferiormost points of both condyles; b) superiormost point of femoral head; c) point on either condyle that is farthest from 'd'; d) point on femoral head that is farthest from 'c'; e) average of the distance of both condyles from 'f'; f) inferiormost point of superior femoral neck; g) line through posteriormost points of both condyles (*note: condyles are not visible in top left image*); h) longitudinal axis of femoral head and neck; i) lateralmost point on lateral epicondyle; j) medialmost point on medial epicondyle; k) anteriormost point at midshaft; l) posteriormost point at midshaft; m) medialmost point at midshaft; n) lateralmost point at midshaft.

Measurements: 1) maximum femoral length; 2) femoral biomechanical length; 3) femoral bicondylar (or physiological) length; 4) femoral midshaft circumference; 5) femoral epicondylar breadth; 6) femoral torsion; 7) femoral anteroposterior midshaft diameter; 8) femoral mediolateral midshaft diameter.

2. **Femoral biomechanical length** (Trinkaus et al., 1999: 757): Using a large sliding caliper, place the stationary jaw on the inferiormost point of the superior femoral neck, and then measure the distances to: 1) the distalmost point of the medial condyle; and 2) the distalmost point of the lateral condyle. Biomechanical length is the average of these two distances.
3. **Femoral bicondylar (or physiological) length** (Martin, 1928: 1037–1037, #2; Buikstra and Ubelaker, 1994: 82, #61): Place both condyles firmly against the stationary end of an osteometric board and, while keeping the shaft of the femur parallel to the surface of the board, measure the distance to the furthest point on the femoral head.
4. **Femoral midshaft circumference** (Martin, 1928: 1040, #8; Buikstra and Ubelaker, 1994: 83, #68): Determine the location of midshaft (preferably using 50% of femoral biomechanical length) and use a flexible cloth tape to determine the minimum circumference at that location.
5. **Femoral epicondylar breadth** (Martin, 1928: 1041, #21; Buikstra and Ubelaker, 1994: 82, #62): With a sliding caliper or an osteometric board, measure the distance between the medialmost and lateralmost points on the epicondyles.
6. **Femoral torsion** (Martin, 1928: 1043, #28): Place the femur posterior-side-down on a flat table so that it rests stably on three points: the posteriormost points of each condyle and the posteriormost point of the greater trochanter. Using a goniometer or protractor, measure the angle formed between the longitudinal axis of the femoral neck (and head) and the table.
7. **Femoral anteroposterior (or sagittal) midshaft diameter** (Martin, 1928: 1039: #6; Buikstra and Ubelaker, 1994: 83, #66): Determine the location of midshaft (preferably 50% of femoral biomechanical length) and use a sliding caliper to determine the anteroposterior dimension at that point (including the linea aspera).

8. **Femoral mediolateral (or transverse) midshaft diameter** (Martin, 1928: 1039: #7; Buikstra and Ubelaker, 1994: 83, #67): At the same midshaft location as above, use a sliding caliper to determine the mediolateral dimension at that point (the caliper should be perpendicular to the position used to measure the anteroposterior diameter).
9. **Platymeric index** (Martin, 1928: 1045): (anteroposterior midshaft diameter \div mediolateral midshaft diameter) \times 100.

12.1.6 Femoral Nonmetric Traits

- **Third trochanter:** In some individuals a rounded tubercle (often resembling the lesser trochanter in form) develops above, or instead of, the gluteal tuberosity. This feature is usually scored as 0 (absent), 1 (present), or 2 (ridge).
- **Fovea capitis shape:** Examine and record the shape of the margins of the fovea capitis. The scoring possibilities are 0 (absent), 1 (round), 2 (oval), 3 (triangular), or 4 (irregular).
- **Femoral bowing:** Note the presence and degree of lateral bowing in the femoral shaft. Usually scored as 1 (straight), 2 (slight), 3 (medium), or 4 (marked).
- **Allen's fossa and Poirier's facet (or extension):** Allen's fossa, Poirier's facet, and plaque formation are all defects of the margin of the femoral head. Allen's fossa is found anterosuperiorly, and requires that underlying trabeculae be visible to be scored as present. Poirier's facet is a slight lateral bulging of the articular surface of the femoral head on the anterosuperior neck. The surface of a Poirier's facet is smooth, while that of an Allen's fossa is rough. Plaque formation (or extension) is a bony overgrowth or scar extending from the area of a Poirier's facet. This complex of interrelated features is usually scored as 0 (absent), 1 (fossa), 2 (porous), 3 (ulcer), 4 (plaque), 5 (Poirier's facet), 6 (Allen's fossa and Poirier's facet), or 7 (Allen's fossa and Poirier's facet and plaque). The main individual used to illustrate this book has a slight Poirier's facet (visible in Figures 12.1, 12.4, and 12.5).
- **Anterior femoral neck torsion (or femoral anteversion):** Measure the degree of femoral torsion as defined above and score as follows: 0 ($< 10^\circ$), 1 ($10^\circ\text{--}15^\circ$), 2 ($16^\circ\text{--}25^\circ$), or 3 ($>25^\circ$).

12.2 Patella (Figures 12.9–12.10)

12.2.1 Anatomy

The patella, the largest sesamoid bone in the body, articulates only with the patellar surface of the distal femur (patellar notch). The patella rides in the *tendon of the quadriceps femoris*—the largest muscle of the thigh and the primary extensor of the knee. The patella functions to protect the knee joint, to lengthen the lever arm of the *quadriceps femoris*, and to increase the area of contact between the *patellar ligament* and the femur.

- a. The **apex** of the patella is the nonarticular tip of the bone. It points distally.
- b. The **lateral articular facet** for the distal femur faces posteriorly and is the largest part of the large articular surface of the patella.
- c. The **medial articular facet** for the distal femur faces posteriorly and is smaller than the lateral articular facet.
- d. The **base** of the patella is the blunt, nonarticular proximal end of the bone, opposite the apex.

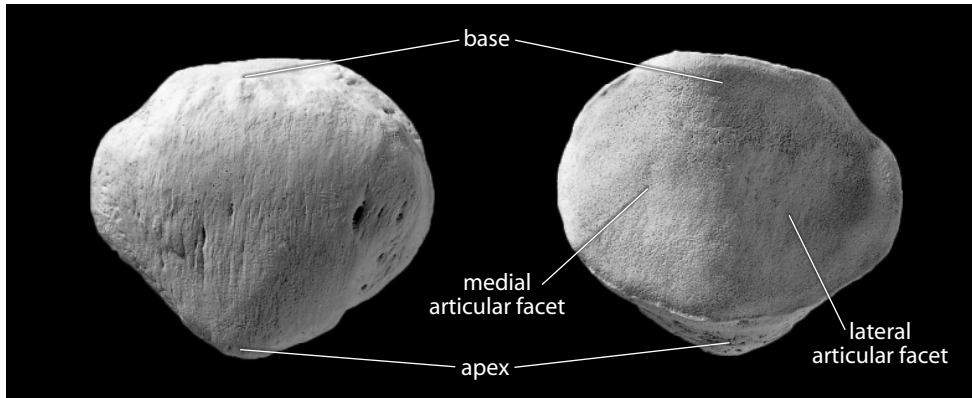


Figure 12.9 Right patella. *Left:* anterior view; superior is up, lateral is toward the left. *Right:* posterior view; superior is up, lateral is toward the right. Natural size.

12.2.2 Growth

The patella ossifies from a single center that generally first appears at about 3–6 years (Scheuer and Black, 2000).

12.2.3 Possible Confusion

This bone might be mistaken for an os coxae fragment, but only in a very fragmentary state. The acetabulum of the os coxae is strongly hollowed, as opposed to the much flatter articular surface of the patella.

12.2.4 Siding

- **Anatomical siding.** The patella is triangular in shape. Its thin, pointed apex is distal, and the thicker, blunter end is proximal. The lateral articular facet, which articulates with the lateral condyle of the femur, is the larger of the two facets.
- **Positional siding.** Place the apex away from you and the articular surface on the table. The bone falls toward the side from which it comes.

12.2.5 Patellar Measurements (Figure 12.10)


Measurements of the patella are infrequently used in biomechanical analyses of the patellofemoral joint.

1. **Maximum patellar height** (Martin, 1928: 1048, #1): Using a sliding caliper or an osteometric board, determine the maximum distance between the base and the apex of the patella.
2. **Maximum patellar breadth** (Martin, 1928: 1048, #2): Using a sliding caliper or an osteometric board, determine the maximum breadth of the patella, perpendicular to maximum patellar height.

Figure 12.10 Patellar measurements. Two-thirds natural size.

Locations: a) point on base farthest from apex; b) point on apex farthest from base; c) point on medial edge farthest from the maximum height chord, \overline{ab} ; d) point on lateral edge farthest from 'c,' keeping \overline{cd} perpendicular to \overline{ab} .

Measurements: 1) maximum patellar height; 2) maximum patellar breadth.



12.2.6 Patellar Nonmetric Traits

- **Vastus notch:** There may be a small notch on the superolateral margin of the patella. This vastus notch should only be scored as present when its borders are smooth. If the borders are rough, as if the missing bone had been torn away, the notch is considered emarginate. Usually scored as 0 (absent), 1 (present), or 2 (emarginate). The patella shown in Figures 12.9 and 12.10 has a vastus notch.
- **Vastus fossa (or facet):** Along the superolateral margin of the anterior patella, there may be a small depression (either just anterior to the vastus notch or appearing without a vastus notch). This trait is usually scored as 0 (absent), or 1 (present).
- **Cleft patella (or patella partita):** In some individuals, the patella is divided into two or more portions during life, possibly as a result of trauma or an overuse injury.
- **Patellar spurs:** Note whether the patella has any bony spurs. Usually scored as 0 (absent), or 1 (present). It appears that spur formation may be associated with a rupture of the *quadriceps tendon* (Hardy et al., 2005).

12.3 Tibia (Figures 12.11–12.17)

12.3.1 Anatomy

The tibia is the major weight-bearing bone of the lower leg. It articulates proximally with the distal femur, twice laterally with the fibula (once proximally and once distally), and distally with the talus.

- The **tibial plateau** is the proximal tibial surface on which the femur rests. It is divided into two articular sections, one for each femoral condyle. In life there are fibrocartilaginous rings around the periphery of these articular facets, the *medial* and *lateral menisci*.
- The **medial condyle** is the medial part of the tibial plateau. Its femoral articulation is oval, with the long axis oriented anteroposteriorly. Its lateral edge is straight.
- The **lateral condyle** is the lateral part of the tibial plateau. Its femoral articulation is smaller and rounder than the medial articulation.
- The **intercondylar eminence** is the raised area on the proximal tibial surface between articular facets.
- The **medial intercondylar tubercle** forms the medial part of the intercondylar eminence.

- f. The **lateral intercondylar tubercle** forms the lateral part of the intercondylar eminence. The *anterior* and *posterior cruciate ligaments* and the anterior and posterior extremities of the *menisci* insert into the nonarticular areas between the condyles, which are just anterior and posterior to the medial and lateral intercondylar tubercles, respectively.
- g. The **anterior intercondylar area** is the nonarticular area on the tibial plateau anterior to the intercondylar eminence. It serves as an attachment site for the *anterior cruciate ligament* and the anterior ends of both *menisci*.
- h. The **posterior intercondylar area** is the nonarticular area posterior to the intercondylar eminence. It serves as an attachment site for the *posterior cruciate ligament* and the posterior ends of both *menisci*.
- i. The **superior fibular articular facet** is located on the posteroinferior edge of the lateral condyle.
- j. The **groove for the semimembranosus** is an anteroposteriorly elongated hollow on the medial side of the medial condyle.
- k. The **tibial tuberosity** is the rugose area on the anterior surface of the proximal tibia. Its superior part is smoothest and widest. The *patellar ligament* of the *quadriceps femoris muscle*, a major lower leg extensor at the knee, inserts here.
- l. The tibial **shaft (or body)** is the fairly straight segment of the tibia between the expanded proximal and distal ends. The shaft is divided into three named surfaces by three named borders (or margins).
- m. The **medial surface** of the shaft forms the medial edge of the “shin” of the lower leg. This subcutaneous, anteromedially facing surface is the widest tibial shaft surface.
- n. The **posterior surface** runs along the entire length of the shaft. The broad, flat area/ portion of the posterior surface closest to the knee is often called the **popliteal surface**, although it is still part of the posterior surface. The soleal (or popliteal) line runs across the popliteal surface.
- o. The **lateral (or interosseous) surface** of the shaft lies opposite the fibula. It is the most concave of the three tibial surfaces.
- p. The **medial border (or margin or crest)** is the blunt edge running along the medial side of the shaft. It is the one of the three crests that give much of the tibial shaft its prismatic outline, and it serves as the attachment site of the *deep transverse fascia*.
- q. The **anterior border (or margin or crest)** of the shaft forms the anterior edge of the “shin.” It is the most prominent of the three crests that give much of the tibial shaft its distinctive prismatic (triangular) outline.
- r. The **interosseous border (or margin or crest)** is the lateral crest of the shaft, which faces the fibula. It is the last of the three main crests of the tibial shaft, and it is the attachment area for the *interosseous membrane*, a sheet of tissue that functions to bind the tibia and fibula together and to compartmentalize lower leg muscles into anterior and posterior groups, just as its serial homolog does in the forearm.
- s. The **soleal (or popliteal) line** crosses the proximal one-third to one-half of the posterior tibial surface from superolateral to inferomedial. The line demarcates the inferior boundary of the *popliteus muscle* insertion. This muscle is a flexor and medial rotator of the tibia and originates from the popliteal groove on the lateral femoral condyle. The line itself gives rise to the *popliteus fascia* and *soleus muscle*, a plantarflexor of the foot at the ankle.
- t. The **nutrient foramen** is just inferolateral to the popliteal line. It is a large foramen that exits the bone proximally.
- u. The **vertical line** arises just inferior to the soleal (or popliteal) line and divides the posterior surface roughly in half. It marks the boundary between the origins of the *tibialis posterior* and *flexor digitorum longus muscles*.

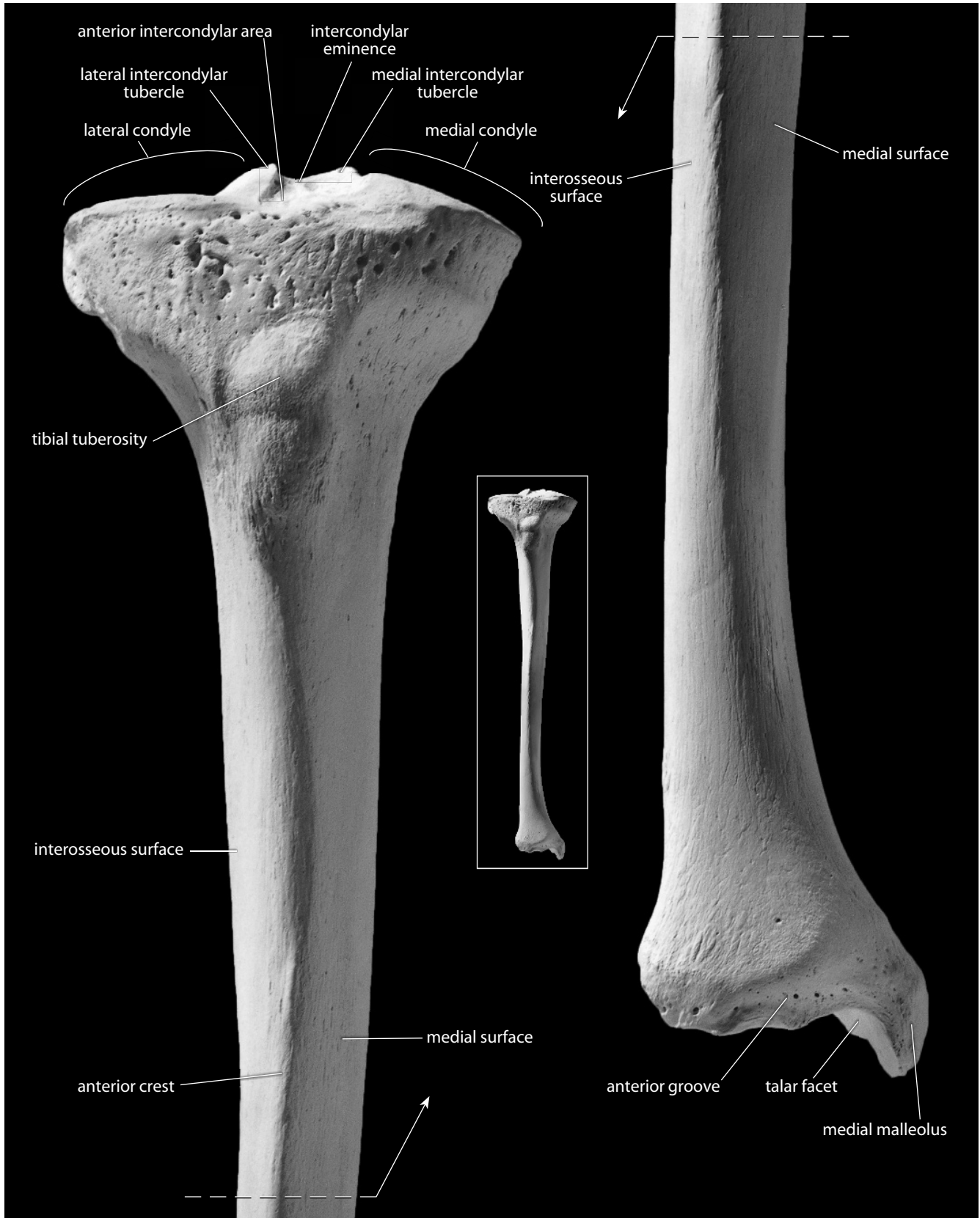


Figure 12.11 Right tibia, anterior. *Left:* proximal end; *right:* distal end. Natural size.

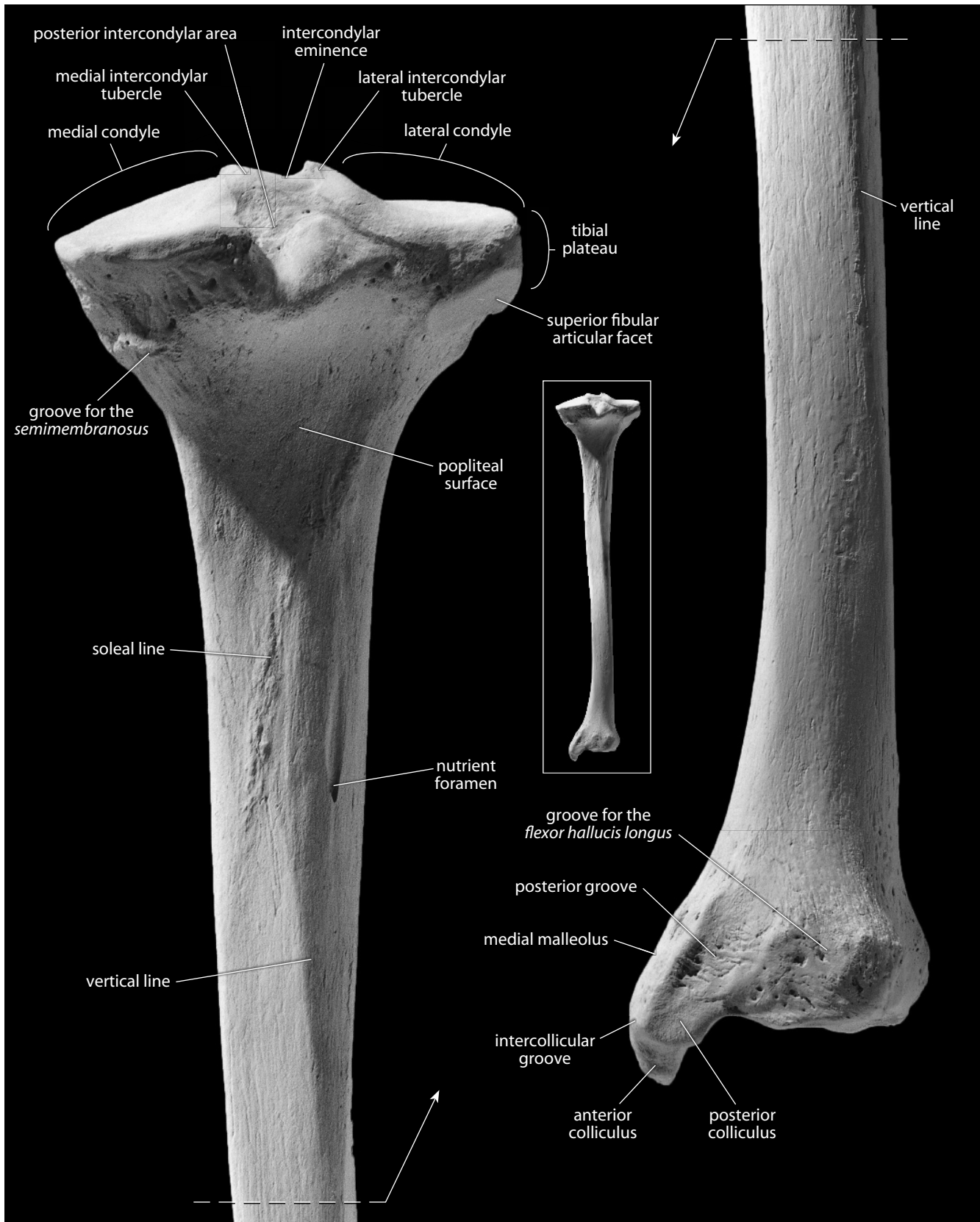


Figure 12.12 Right tibia, posterior. *Left*: proximal end; *right*: distal end. Natural size.

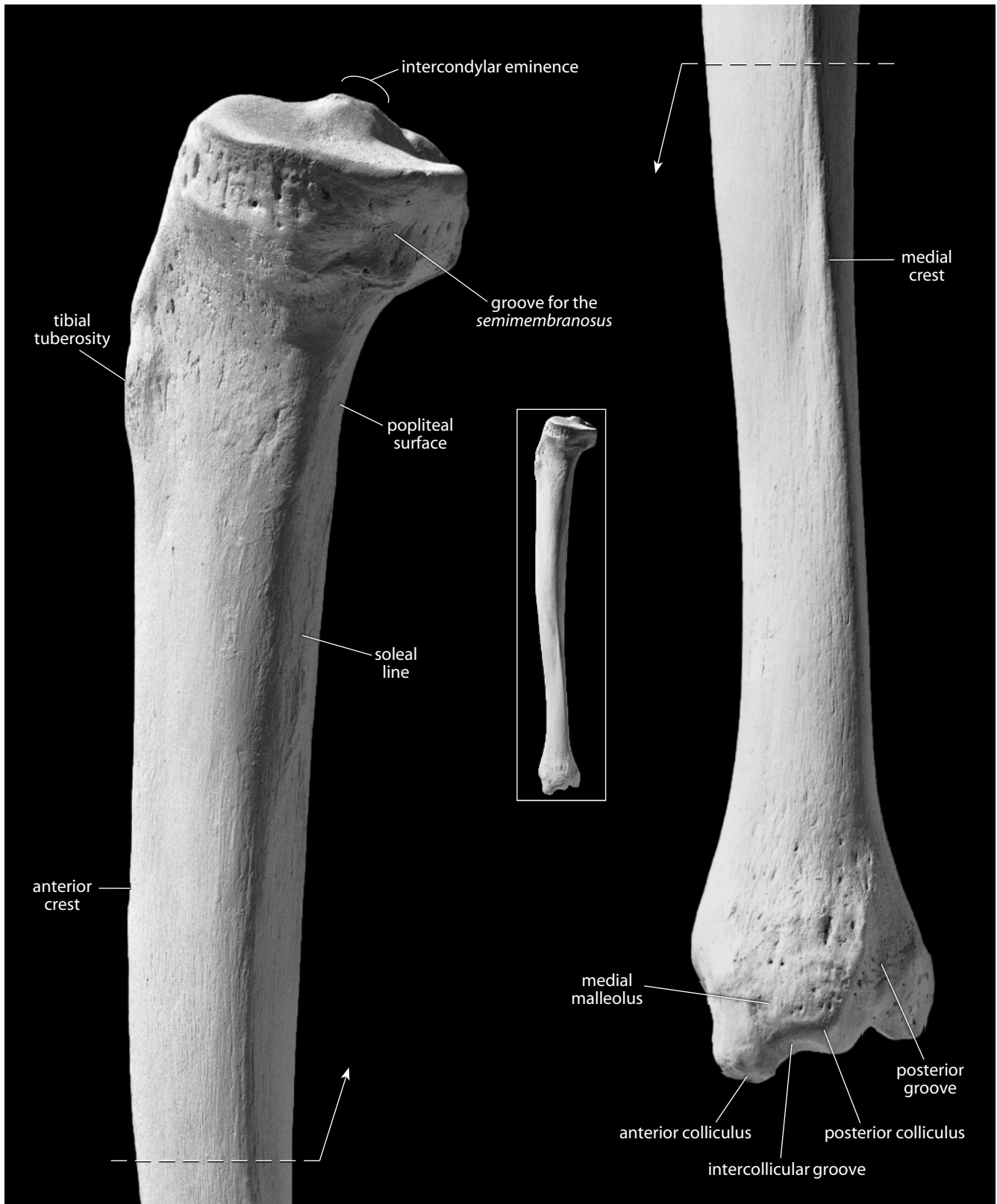


Figure 12.13 Right tibia, medial. *Left*: proximal end; *right*: distal end. Natural size.

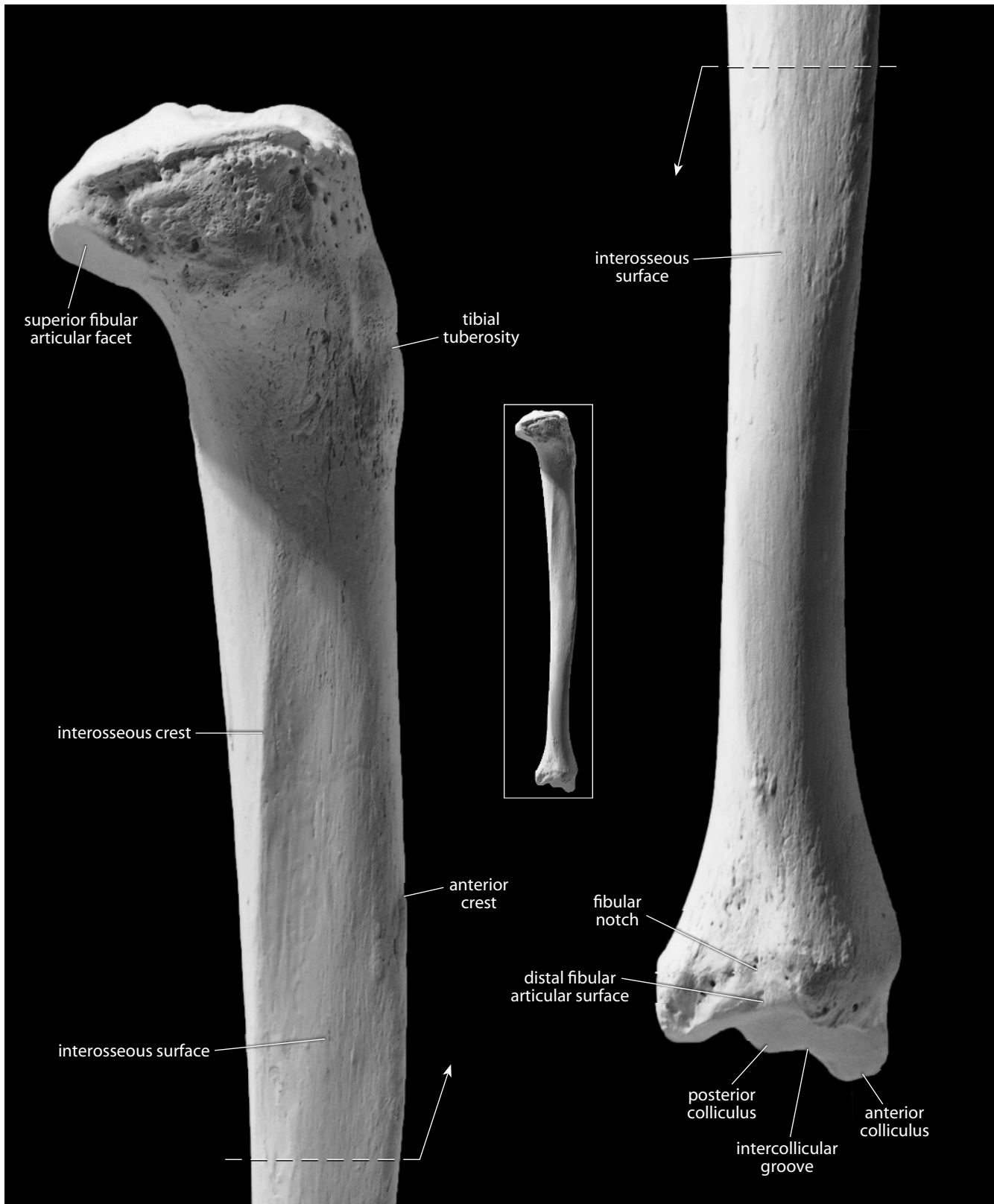


Figure 12.14 Right tibia, lateral. *Left:* proximal end; *right:* distal end. Natural size.

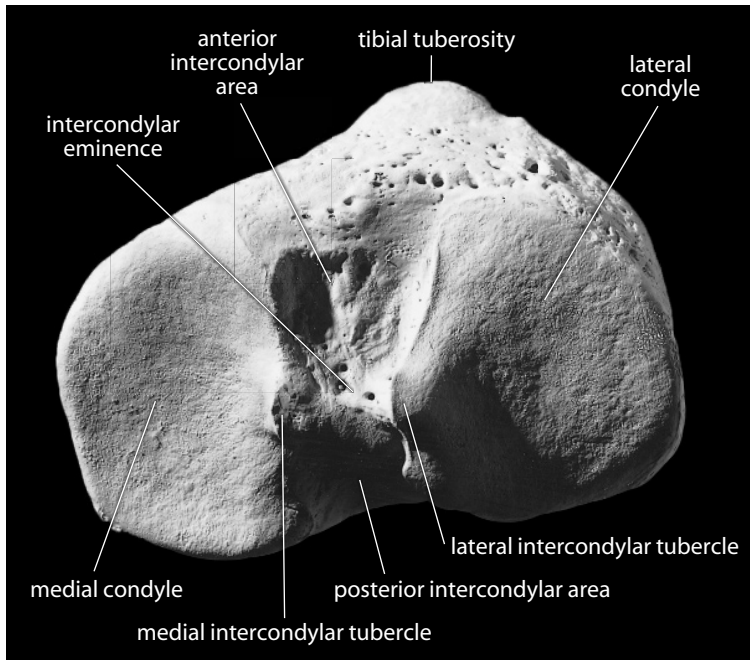


Figure 12.15 **Right tibia, proximal.** Anterior is up, lateral is toward the right. Natural size.

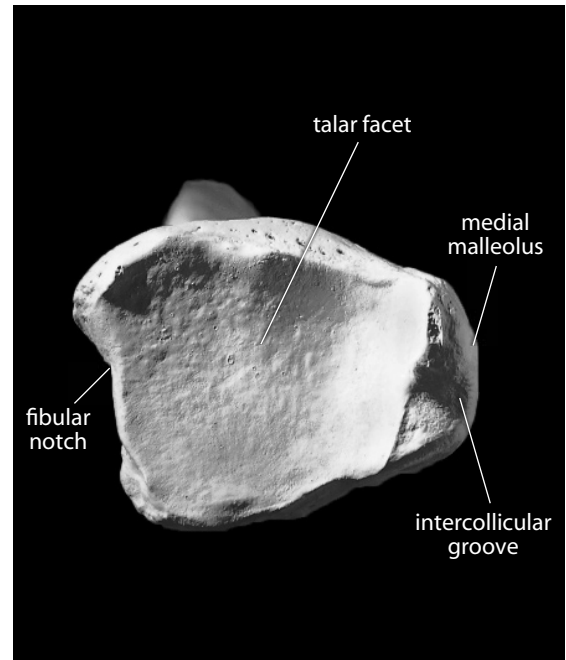


Figure 12.16 **Right tibia, distal.** Anterior is up, lateral is toward the left. Natural size.

- v. The **medial malleolus** is the projection on the medial side of the distal tibia that forms the subcutaneous medial knob at the ankle. Its lateral surface articulates with the talar body. The medial malleolus is comprised of two rounded, hill-like prominences: the larger **anterior colliculus** and the smaller **posterior colliculus**.
- w. The **intercollicular groove** separates the anterior and posterior colliculi. The groove and both colliculi serve as attachment sites for the apex of the *deltoid ligament*.
- x. The **anterior groove** is a short but pronounced horizontal groove on the anterior aspect of the distal shaft, immediately superior to the talar articular surface.
- y. The **fibular notch** is the distolateral corner of the tibia. It is a triangular nonarticular area for the thick, short interosseous *tibiofibular ligament*. This ligament binds the distal tibia and fibula together as a unit at this syndesmosis. The proximal ankle, or **talocrural**, joint is formed by the tightly bound distal tibia and fibula, which articulate with the superior, medial, and lateral talar surfaces.
- z. The **distal fibular articular surface** is a thin articular surface for the fibula, which faces laterally at the base of the fibular notch.
- aa. The **posterior (or malleolar) groove** on the posterior aspect of the medial malleolus transmits the *tendons of the tibialis posterior* and *flexor digitorum longus* muscles, both plantarflexors.
- ab. The **groove for the flexor hallucis longus** is a shallow groove found on the distalmost portion of the posterior tibia. It is less pronounced than the posterior (or malleolar) groove.
- ac. The **talar articular surface** is composed of both the saddle-shaped, inferior-facing (superior) talar surface and the much smaller medial talar surface.

12.3.2 Growth (Figure 12.7)

The tibia ossifies from three centers: the diaphysis, the proximal epiphysis (including the tibial tuberosity), and the distal epiphysis. The primary center of ossification in the diaphysis appears at about 7–8 weeks (*in utero*). The secondary ossification center in the proximal epiphysis appears at 36 weeks (*in utero*) to 2 months (postnatal). It begins to fuse to the diaphysis at 13–17 years in females, and at about 15–19 years in males. The ossification center in the tibial tuberosity appears at 8–12 years in females and at about 9–14 years in males. The tibial tuberosity begins to fuse to the proximal epiphysis at about 12–14 years in both sexes. The secondary ossification center in the distal epiphysis appears at 3–10 months. It begins to fuse to the diaphysis at 14–16 years in females and at about 15–18 years in males (Scheuer and Black, 2000).

12.3.3 Possible Confusion

- The triangular tibial cross section differentiates fragments of this bone from the femur or the much smaller humerus (see cross sections in Chapter 14). The tibial shaft is much larger than radial or ulnar shafts.
- Proximal and distal ends of the tibia are diagnostic, and the only possibility of confusion arises in mistaking a segment of the proximal articular surface for the body of a vertebra. The articular surface of the tibia is much denser and smoother than the articular surface of a vertebral body.

12.3.4 Siding

- For an intact tibia, the tibial tuberosity is proximal and anterior. The medial malleolus is on the distal end and is medial.
- For the proximal tibia, the tibial tuberosity is anterolateral, the fibular articulation is placed posterolaterally, and the lateral femoral articular surface is smaller, rounder, and set laterally. The intercondylar eminence is set posteriorly, and the axis of the nonarticular strip on the plateau runs from anterolateral to posteromedial. This strip is wider anteriorly than posteriorly. The intercondylar eminence has a more concave medial border and a more evenly sloping lateral border.
- For fragments of the shaft, the entire shaft tapers distally, and the interosseous border is lateral and posterior. The medial surface is the widest surface and faces anteriorly. The lateral surface is the most concave surface. The nutrient foramen is posterior and exits proximally. The cortex is thickest at midshaft.
- For the distal end, the malleolus is medial and its distalmost projection is anterior. Grooves for the plantarflexor tendons are posterior. The fibular notch is lateral, and the interosseous border runs toward its anterior surface. The margin of the articular surface for the superior talus is grooved on the anterior surface but not the posterior surface. The anterior colliculus is larger than the posterior colliculus.

12.3.5 Tibial Measurements (Figure 12.17)

Measurements of the tibia are used for stature estimation, age estimation, sex determination, gait reconstruction, biomechanical load calculations, and other analyses.

1. **Maximum tibial length** (Martin, 1928: 1049, #1a; Buikstra and Ubelaker, 1994: 83, #69): The maximum length that can be measured between the top of the intercondylar eminence and the bottom of the medial malleolus. Measured with an osteometric board.

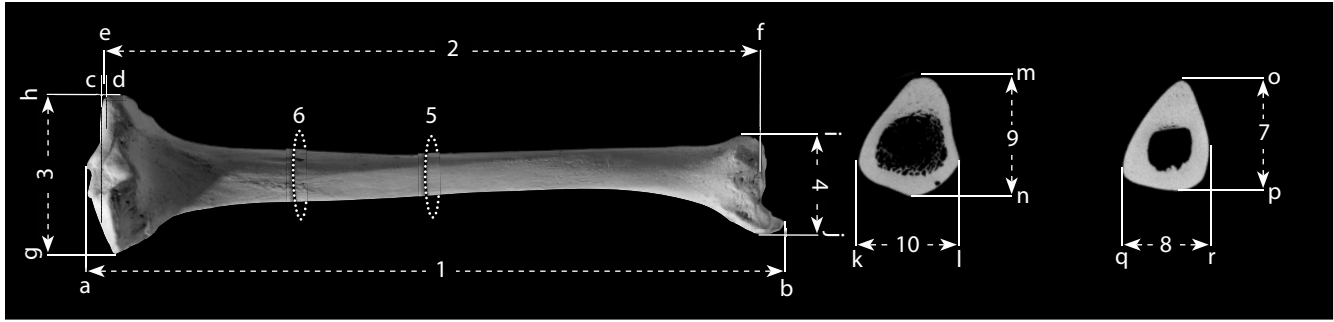


Figure 12.17 Tibial measurements. One-fourth (bone) and one-half (CT scan) natural size.

Locations: a) superiormost point of intercondylar eminence; b) inferiormost point of medial malleolus; c) centerpoint of medial condyle; d) centerpoint of lateral condyle; e) average of the distance of both condyle centerpoints from 'f'; f) centerpoint of talar articular surface; g) medialmost point of tibial plateau; h) lateralmost point of tibial plateau; i) lateralmost point of distal epiphysis; j) medialmost point of medial malleolus; k) medialmost point of shaft at level of nutrient foramen; l) lateralmost point of shaft at level of nutrient foramen; m) anteriormost point of shaft at level of nutrient foramen; n) posteriormost point of shaft at level of nutrient foramen; o) anteriormost point at midshaft; p) posteriormost point at midshaft; q) medialmost point at midshaft; r) lateralmost point at midshaft.

Measurements: 1) maximum tibial length; 2) tibial biomechanical length; 3) tibial maximum proximal epiphyseal breadth; 4) tibial maximum distal epiphysis breadth; 5) tibial midshaft circumference; 6) tibial circumference at nutrient foramen; 7) tibial anteroposterior midshaft diameter; 8) tibial mediolateral midshaft diameter; 9) tibial maximum shaft diameter at nutrient foramen; 10) tibial mediolateral (or transverse) shaft diameter at nutrient foramen.

2. **Tibial biomechanical length** (Trinkaus et al., 1999: 757): Using a large sliding caliper, place the tip of the stationary jaw on the centerpoint of the talar articular surface, and then measure the distances to: 1) the centerpoint of the medial condyle; and 2) the centerpoint of the lateral condyle. Biomechanical length is the average of these two distances.
3. **Tibial maximum proximal epiphyseal breadth** (Buikstra and Ubelaker, 1994: 83, #70): Using sliding calipers or an osteometric board, determine the maximum distance between the medialmost and lateralmost points of the tibial plateau.
4. **Tibial maximum distal epiphyseal breadth** (Buikstra and Ubelaker, 1994: 83, #71): Using sliding calipers or an osteometric board, determine the maximum distance between the medialmost point on the medial malleolus and the lateralmost point on the distal epiphysis.
5. **Tibial midshaft circumference** (Martin, 1928, 1050, #10): Determine the location of midshaft (preferably using 50% of tibial biomechanical length) and use a flexible cloth tape to determine the minimum circumference at that location.
6. **Tibial circumference at nutrient foramen** (Martin, 1928, 1050, #10a; Buikstra and Ubelaker, 1994: 83, #74): With a flexible cloth tape, measure the minimum circumference at the level of the nutrient foramen.
7. **Tibial anteroposterior midshaft diameter** (Martin, 1928, 1050, #8): Determine the location of midshaft (preferably using 50% of tibial biomechanical length) and use a sliding caliper to determine the anteroposterior diameter at that location.
8. **Tibial mediolateral (or transverse) midshaft diameter** (Martin, 1928, 1050, #9): Determine the location of midshaft (preferably using 50% of tibial biomechanical length) and use a sliding caliper to determine the mediolateral diameter at that location.
9. **Tibial maximum shaft diameter at nutrient foramen** (Martin, 1928, 1050, #8a; Buikstra and Ubelaker, 1994: 83, #72): With the bone in anatomical position and the sliding caliper in a parasagittal plane, measure the greatest distance from the anterior border to the posterior surface at the level of the nutrient foramen.

10. **Tibial mediolateral (or transverse) shaft diameter at nutrient foramen** (Martin, 1928, 1050, #9a; Buikstra and Ubelaker, 1994: 83, #73): With the bone in anatomical position and the sliding caliper in a paracoronal plane, measure the maximum mediolateral dimension of the shaft at the level of the nutrient foramen.
11. **Platycnemic index** (Martin, 1928: 1052): (mediolateral shaft diameter at nutrient foramen \div maximum shaft diameter at nutrient foramen) \times 100.

12.3.6 Tibial Nonmetric Traits

- **Tibial squatting facet:** In individuals who habitually spend time in an extremely dorsiflexed position (*eg*, sitting in a deep squatting position), a pair of conforming facets may form on the approximated anteroinferior tibia and anterosuperior talus. The tibial facet is usually scored as 0 (absent) or 1 (present).
- **Platycnemia (or saber shins):** In some individuals, the tibia may be noticeably flattened mediolaterally, a condition called platycnemia. A platycnemic tibia is one which has a platycnemic index of less than 63 (Bass, 2005).
- **Tibial bowing:** There are three types of tibial bowing, each characterized by the direction to which the apex of the bowing points: anterolateral, anteromedial, and posteromedial. Note the direction of the most severe degree of bowing and score it as 1 (straight), 2 (slight), 3 (moderate), or 4 (marked).

12.4 Fibula (Figures 12.18–12.23)

12.4.1 Anatomy

The fibula is a long, thin bone that lies lateral to the tibia, articulating twice with it and once with the talus. Although this bone plays only an indirect role in the knee joint, serving to anchor ligaments, it plays a key role in forming the lateral border of the ankle joint. The fibula bears very little weight, not even touching the femur at its superior end.

- a. The **fibular head** is the swollen proximal end of the fibula, more massive and less mediolaterally flattened than the distal end. It is the attachment point for the *biceps femoris muscle* (a flexor and lateral rotator at the knee) and the *lateral collateral ligament* of the knee.
- b. The **styloid process (or apex)** is the most proximal projection of the bone, forming the posterior part of the head.
- c. The **proximal fibular articular surface** is a round, flat, medially oriented surface that corresponds to a similar surface on the lateral proximal tibia.
- d. The **fibular neck** extends from the shaft and flares proximally to meet the fibular head.
- e. The fibular **shaft** is the long, thin, fairly straight segment of the bone between the expanded proximal and distal ends. The shaft is divided into three named surfaces by three named borders (or margins).
- f. The **anterior border (or margin or crest)** lies between the medial and lateral surfaces.
- g. The **lateral surface** faces laterally and somewhat anteriorly. The lateral surface lies between the anterior and posterior borders.
- h. The **posterior border (or margin or crest)** faces posterolaterally and lies between the lateral and posterior surfaces.

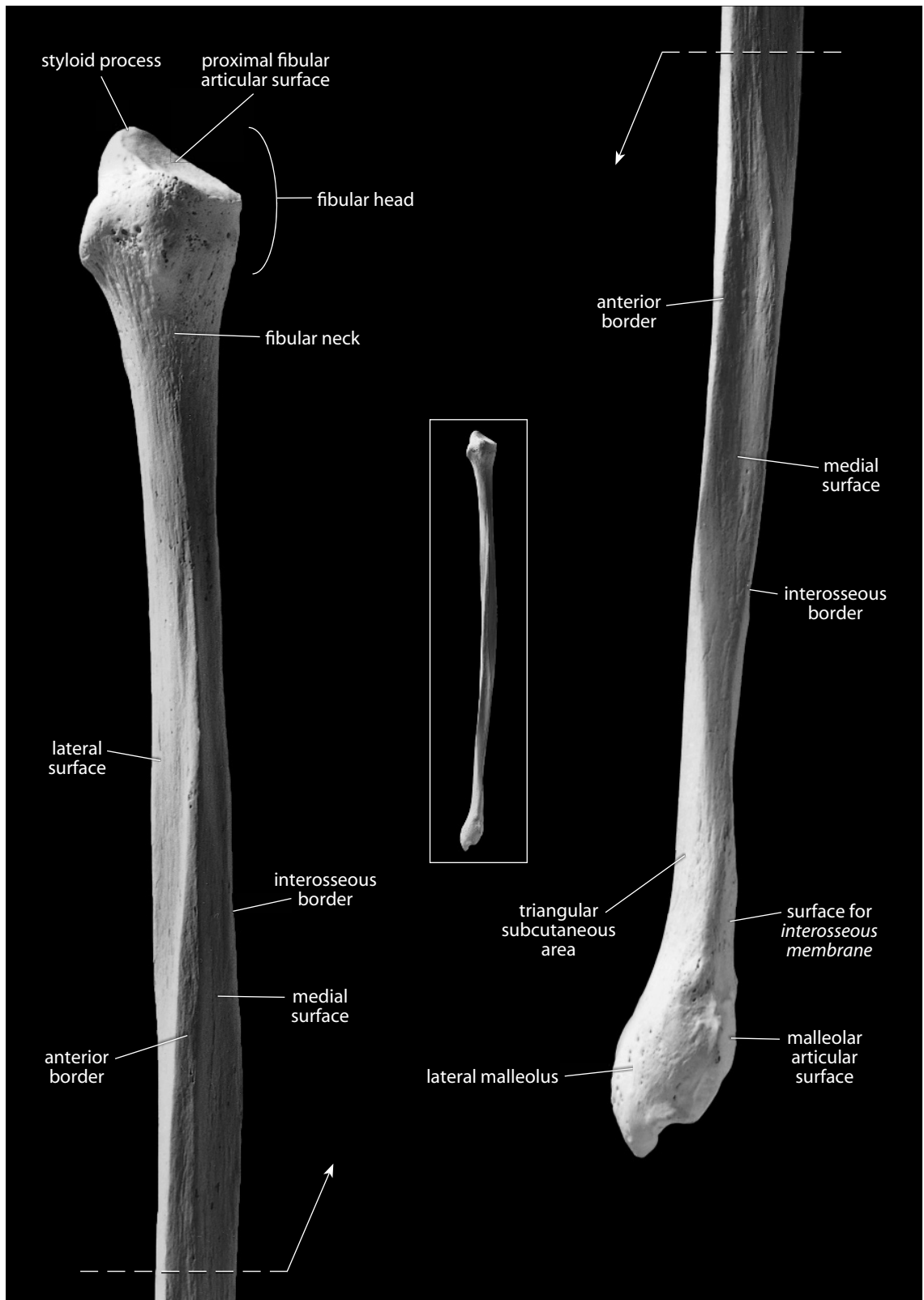


Figure 12.18 Right fibula, anterior. *Left*: proximal end; *right*: distal end. Natural size.

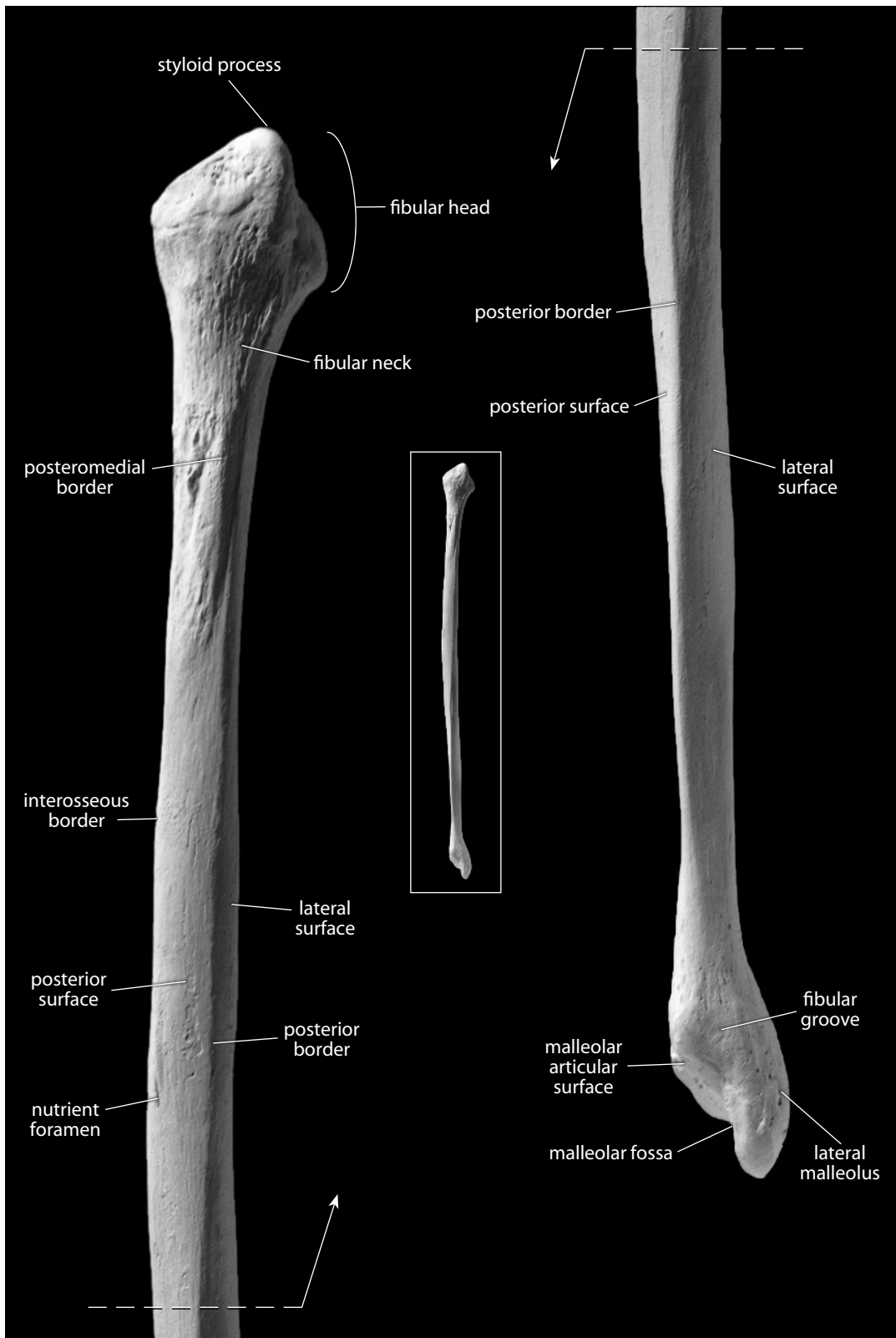


Figure 12.19 Right fibula, posterior. *Left*: proximal end; *right*: distal end. Natural size.

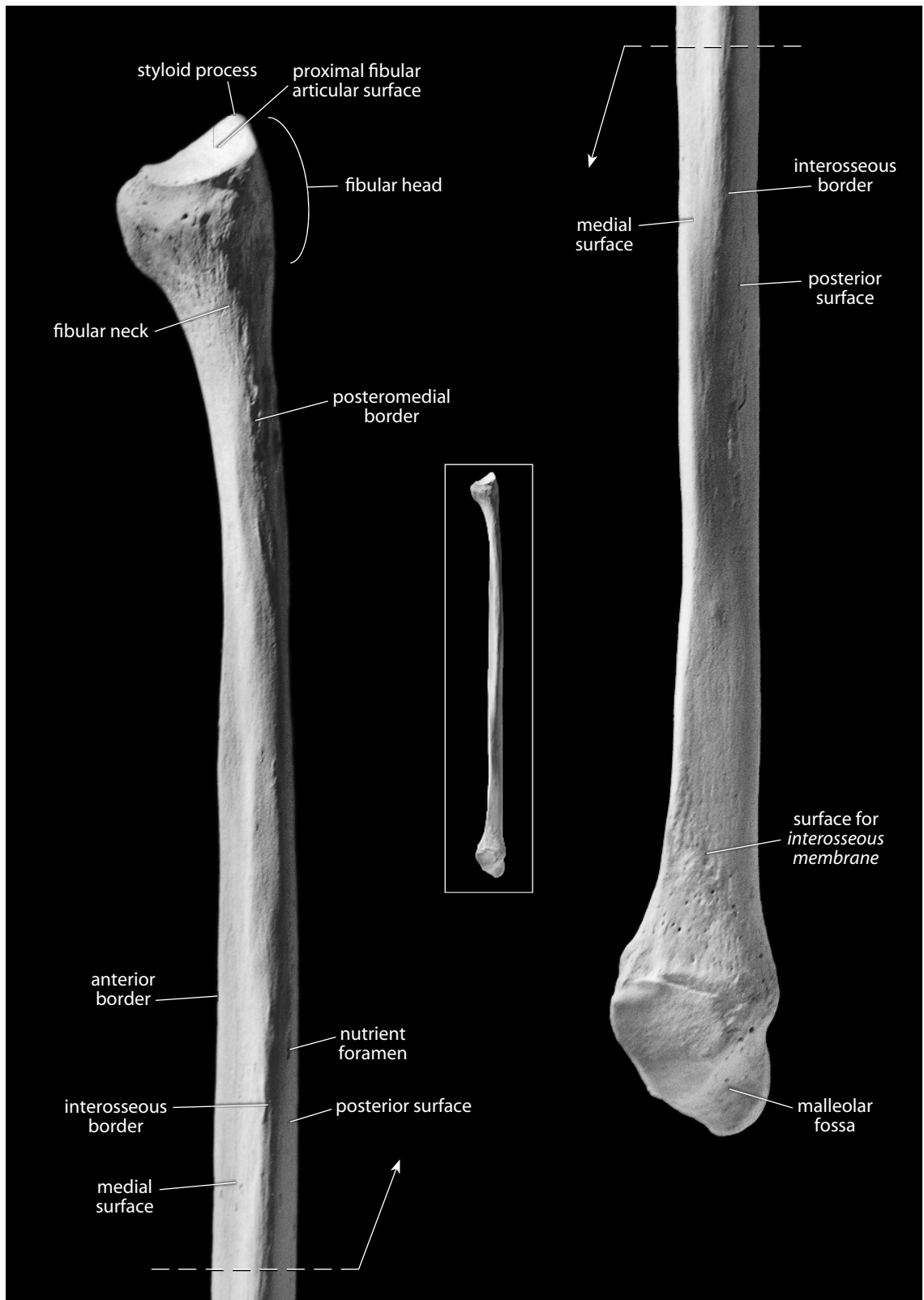


Figure 12.20 Right fibula, medial. *Left:* proximal end; *right:* distal end. Natural size.

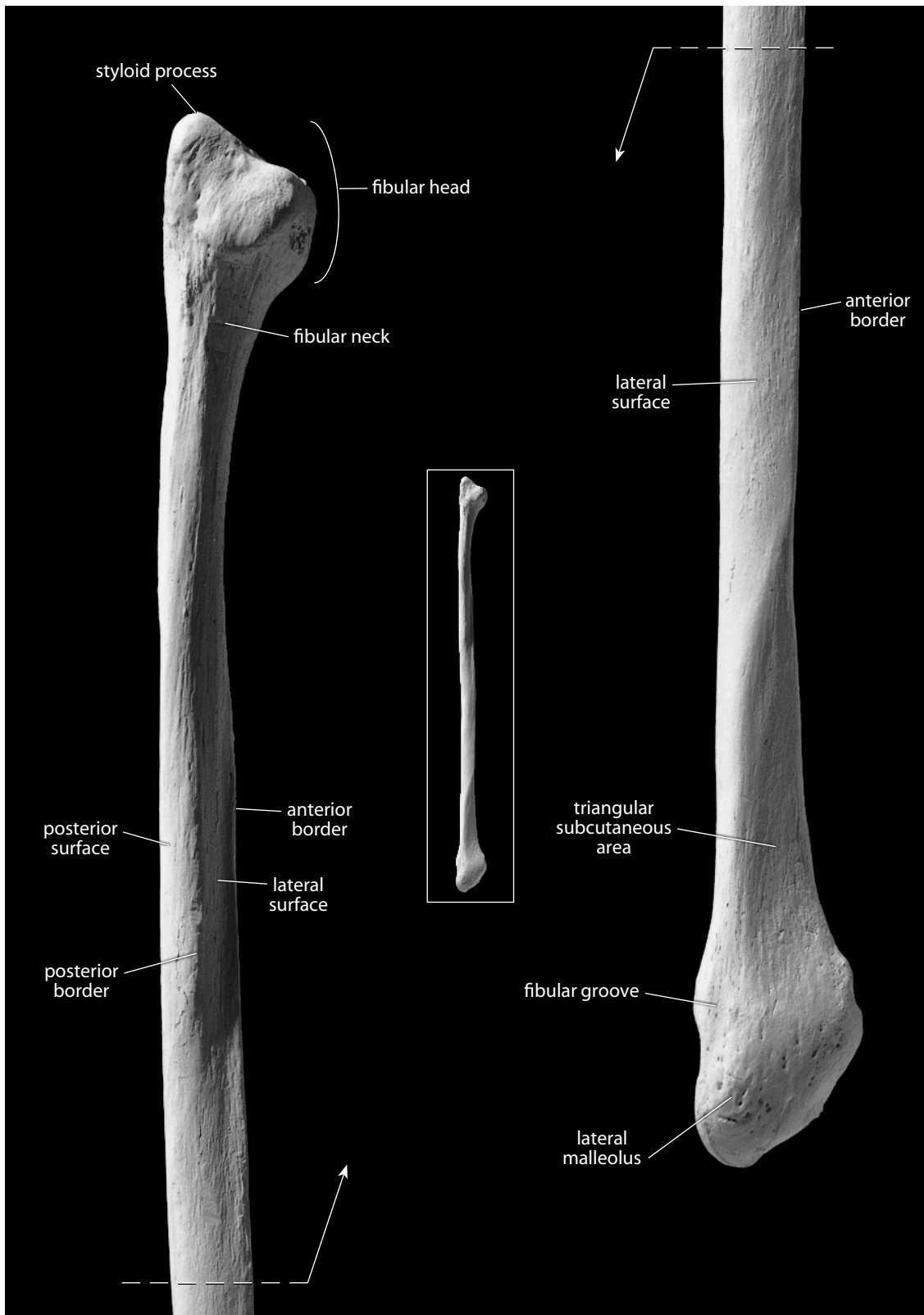


Figure 12.21 Right fibula, lateral. *Left:* proximal end; *right:* distal end. Natural size.

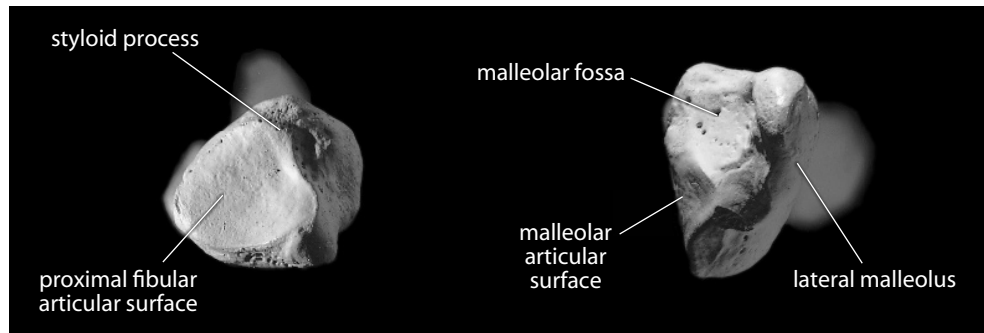


Figure 12.22 **Right fibula.** *Left:* proximal view; anterior is up; lateral is toward the right. *Right:* distal view, posterior is up; lateral is toward the right. Natural size.

- i. The **posterior surface** lies between the interosseous border and the posterior border. The **medial crest**, the origin of the *tibialis posterior* and *flexor hallucis longus* muscles, is located on the posterior surface.
- j. The **posteromedial border** (or **margin** or **crest**) (or **oblique line**) begins below the medial side of the fibular head, arcs laterally, then spirals medially across the posterior surface of the bone, finally merging with the interosseous border inferiorly. It marks the separation between the *tibialis posterior* muscle and the *soleus* and *flexor hallucis longus* muscles.
- k. The **medial surface** is the slightly anteriorly facing surface between the anterior and interosseous borders.
- l. The **interosseous border** (or **margin** or **crest**) is an elevated crest that runs down the medial surface of the shaft. Attached to it is the *interosseous membrane*, a fibrous sheet that binds the fibula and tibia and divides the lower leg musculature into anterior and posterior compartments.
- m. The **surface for the *interosseous membrane*** is the broad, flat area on the medial aspect of the distalmost shaft.
- n. The **nutrient foramen** opens proximally on the posteromedial surface, at about midshaft level. The cross section of the fibular shaft can be extremely variable in this region.
- o. The **triangular subcutaneous area** is located distally, immediately above the lateral malleolus. The lines forming the two vertical sides of the triangle converge to become the anterior border at the apex of the triangle.
- p. The **lateral malleolus** is the inferiormost (distalmost) projection of the fibula. Its lateral, nonarticular surface is subcutaneous, forming the lateral knob of the ankle.
- q. The **malleolar** (or **distal**) **articular surface** is a flat, medially facing, triangular surface whose apex faces inferiorly. The surface articulates with the lateral surface of the talus.
- r. The **malleolar fossa** is located just posterior to the distal articular surface. It is the attachment site of the *transverse tibiofibular* and *posterior talofibular ligaments*, which strengthen the ankle joint.
- s. The **fibular groove**, for *tendons of the fibularis (peroneus) longus* and *fibularis (peroneus) brevis* muscles, marks the posterior surface of the distal fibula. These muscles plantarflex and evert the foot at the ankle, originating in the leg and inserting at the bases of the first (*longus*) and fifth (*brevis*) metatarsals.

12.4.2 Growth (Figure 12.7)

The fibula, like the tibia, ossifies from three centers: one for the shaft and one for each end. The primary center of ossification in the diaphysis appears at about 8–9 weeks (*in utero*). The secondary ossification center in the proximal epiphysis appears at 3–4 years in females, and at about 4–5 years in males. The proximal epiphysis begins to fuse with the diaphysis at 12–17 years in females, and at 15–20 years in males. The ossification center in the distal epiphysis appears at 9–22 months in both sexes. It begins to fuse to the diaphysis at 12–15 years in females, and at about 15–18 years in males (Scheuer and Black, 2000).

12.4.3 Possible Confusion

The proximal and distal fibular ends are distinctive and are rarely confused with other bones.

- The distal end is flattened along the plane of the articular facet, whereas the proximal end of the fifth metatarsal, for which a distal fibular end might be mistaken, has two facets and is flattened perpendicular to the planes of each.
- Fibular shafts are thin, straight, and usually quadrilateral (sometimes triangular), with sharp crests and corners. Thus, they are thus more irregular in cross section than either radial or ulnar shafts (see cross sections in Chapter 14).

12.4.4 Siding

- For an intact fibula, the articular surfaces for the tibia are medial, the fibular head is proximal, the flattened end is distal, and the malleolar fossa is posterior.
- For the proximal end, the styloid process is lateral, proximal, and displaced posteriorly. The articular surface faces medially and is also displaced posteriorly. The neck is roughest laterally.
- For the shaft, try to use intact specimens for comparison. The nutrient foramen opens proximally. The sharpest crest on the triangular proximal end is the interosseous border. This expands downshaft to a rough, flattened surface. The distal aspect of the shaft is marked by a line diverging from the trend of the interosseous border in the direction of the side from which the bone comes.
- For the distal end, the malleolar fossa is always posterior, and the articular facet is always medial, with its apex pointed inferiorly.

12.4.5 Fibular Measurements (Figure 12.23)

Measurements of the fibula are infrequently used for stature estimation, age estimation, and other purposes.

1. **Maximum fibular length** (Martin, 1928: 1052, #1; Buikstra and Ubelaker, 1994: 84, #75): The maximum length that can be measured between the top of the styloid process and the bottom of the lateral malleolus. Measured with an osteometric board.
2. **Maximum fibular midshaft diameter** (Martin, 1928: 1052, #2; Buikstra and Ubelaker, 1994: 84, #76): Determine the location of midshaft using 50% of maximum length. Using a sliding caliper, determine the greatest diameter of the shaft at midshaft.
3. **Fibular midshaft circumference** (Martin, 1928: 1053, #4): Determine the location of

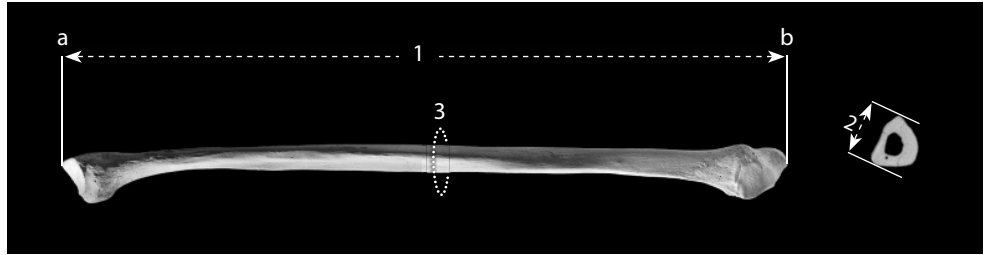


Figure 12.23 Fibular measurements. One-fourth (bone) and one-half (CT scan) natural size.

Locations: a) superiormost point of styloid process; b) inferiormost point of lateral malleolus.

Measurements: 1) maximum fibular length; 2) maximum fibular midshaft diameter; 3) fibular midshaft circumference.

midshaft using 50% of maximum length). Use a flexible cloth tape to determine the minimum circumference at that location.

12.4.6 Fibular Nonmetric Traits

- The cross-sectional shape of the fibular shaft is highly variable. The shaft may appear smooth or angular, and its cross section can be triangular, rectangular, or even oval.

12.5 Functional Aspects of the Knee and Ankle

The knee joint is the most complex joint in the human body, whereas the ankle joint is considerably more simple. The main actions at both the knee and ankle joints are flexion and extension. Knee extension is accomplished primarily by the quadriceps muscles. This group of muscles originates from the os coxae and proximal femur and inserts on the tuberosity of the tibia via the tendon in which the patella is embedded. Flexion at the knee is primarily accomplished by the hamstring muscles. These also originate from the os coxae and proximal femur but insert on the proximal tibia and fibula, just distal to the knee joint.

In walking and running, propulsion of the body is created by contracting muscles of the lower limb. Muscles in the anterior and posterior compartments of the lower leg (separated by the interosseous membrane) act to move the skeleton of the foot, much as forearm muscles move the hand. Plantarflexors occupy the posterior compartment, and dorsiflexors are found anterolateral to the tibia. Plantarflexor muscles, originating on the posterior side of the lower leg and attaching to the calcaneus via the Achilles tendon, contract at the same time that the quadriceps, the primary extensor of the lower leg, contracts. The coordinated action of these two muscle groups straightens the leg and plantarflexes the foot at the ankle, producing a strong ground reaction force and propelling the body forward. A comparison of the bony anatomy of the human pelvic girdle and leg with that of our closest living relatives, the African apes, reveals profound evolutionary changes related to the acquisition of bipedality more than six million years ago.

Chapter 13

FOOT: TARSALS, METATARSALS, AND PHALANGES

THE BONES OF THE FOOT are obvious serial homologs of the hand bones. The deep evolutionary history of foot elements is similar to that described for those of the hand in Chapter 10. There are a total of 26 bones in each human foot, one less than in each hand. Of the seven tarsal bones, two occupy a proximal row, four occupy a distal row, and one is centered between rows. The tarsals are followed distally by a single row of five metatarsals. Farther distally, there is a single row of five proximal phalanges, a single row of four intermediate phalanges, and a single row of five distal, or terminal, phalanges.

In addition to these 26, as with the hand, there are small sesamoid bones that lie within tendons of the foot. In the foot, a pair of sesamoids is usually found below the head of the first metatarsal. Figures 13.1–13.5 summarize and illustrate articulations within the foot. Elements of the foot skeleton can be divided into three segments: the **tarsals**, **metatarsals**, and **phalanges**.

It is convenient to apply specific directional terms to the foot. **Plantar** refers to the sole of the foot, its inferior surface in standard anatomical position. **Dorsal** is the opposite surface, superior in humans. **Proximal** (posterior) is toward the tibia, **distal** (anterior) is toward the toe tips, and the distalmost phalanges are referred to as “terminal.” In addition, the big toe is sometimes called the **hallux**, and its ray is identified as ray 1. Other rays are numbered as in the hand.

The human foot has changed dramatically during its evolution from a grasping organ to a structure adapted to bipedal locomotion. Most of the mobility, flexibility, and grasping abilities of the foot have been lost in humans as the foot adapted to shock absorption and propulsion.

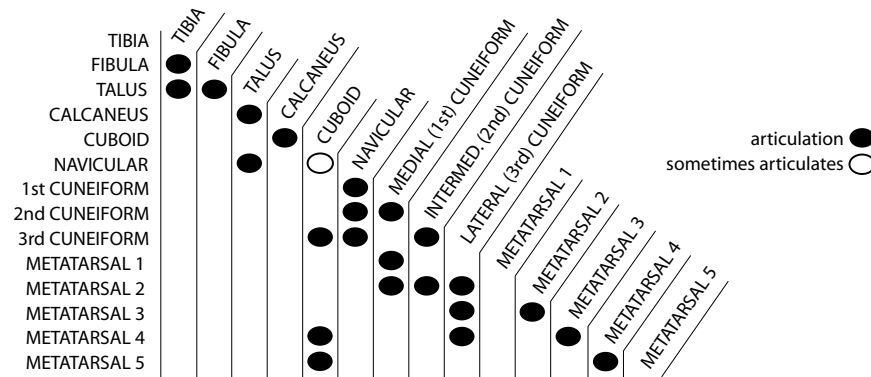


Figure 13.1 Articulatioin of bones in the adult human ankle and foot.

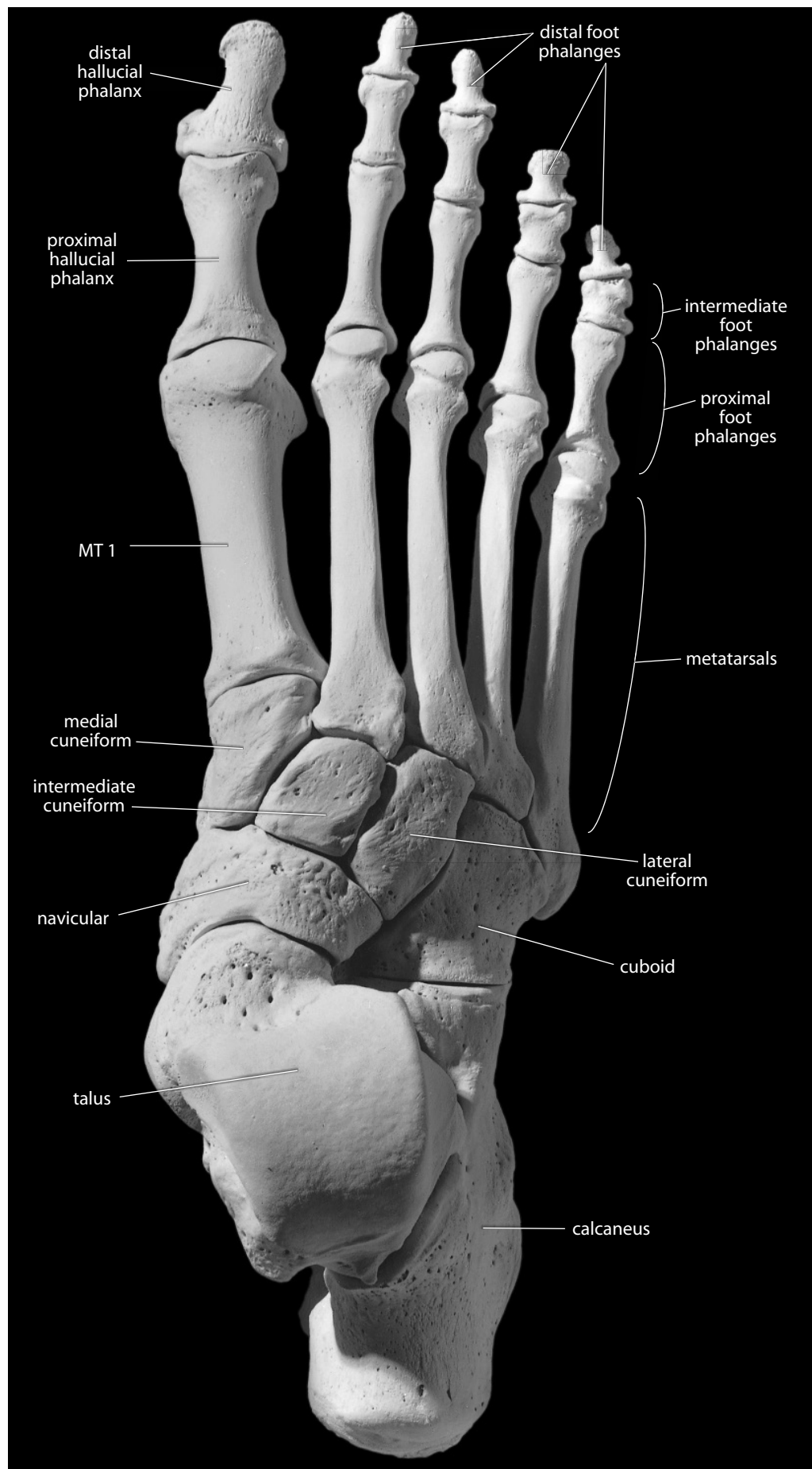


Figure 13.2 Right foot, dorsal (superior). Sesamoid bones not included. Natural size.

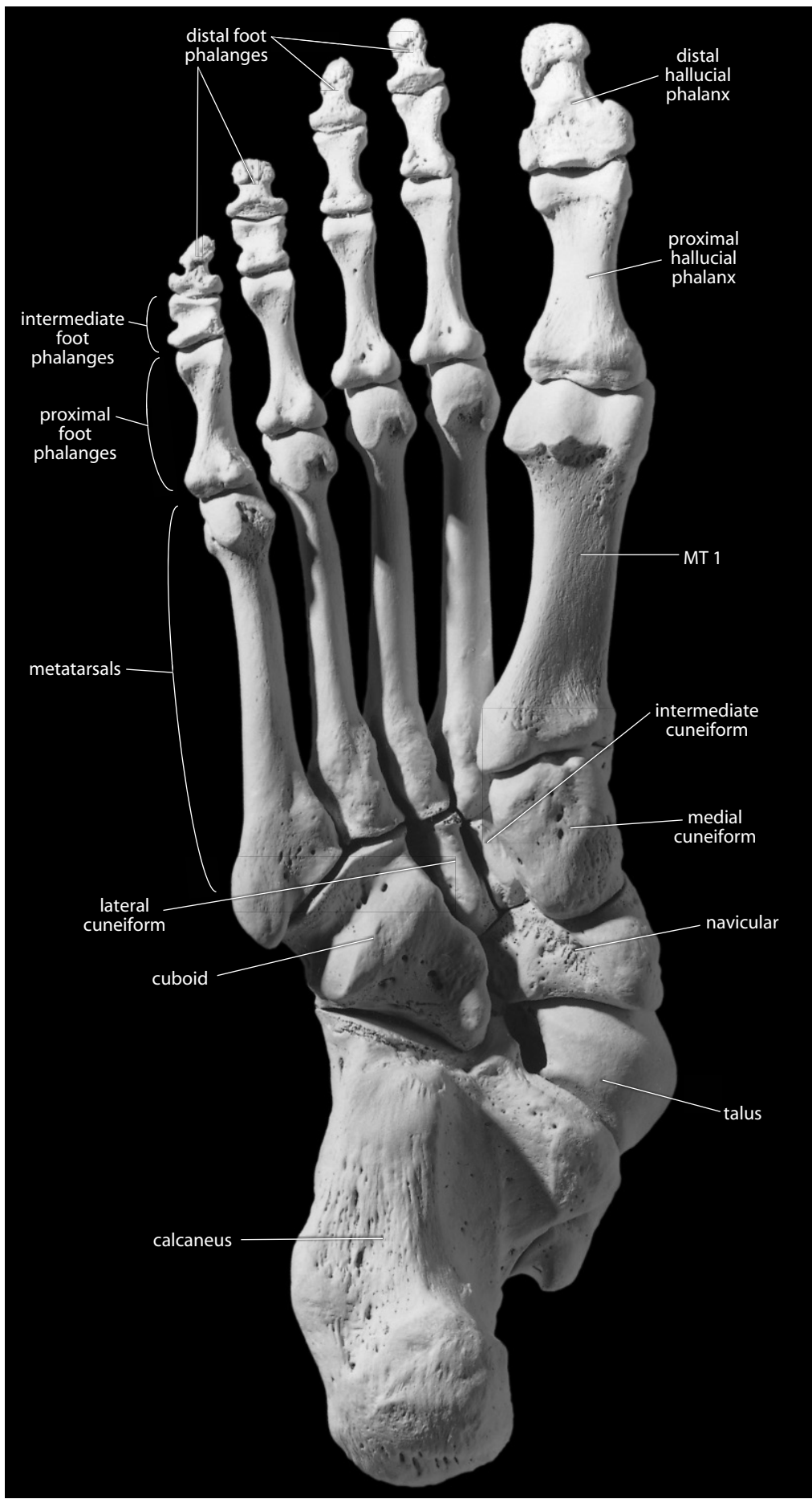


Figure 13.3 Right foot, plantar (inferior). Sesamoid bones not included. Natural size.

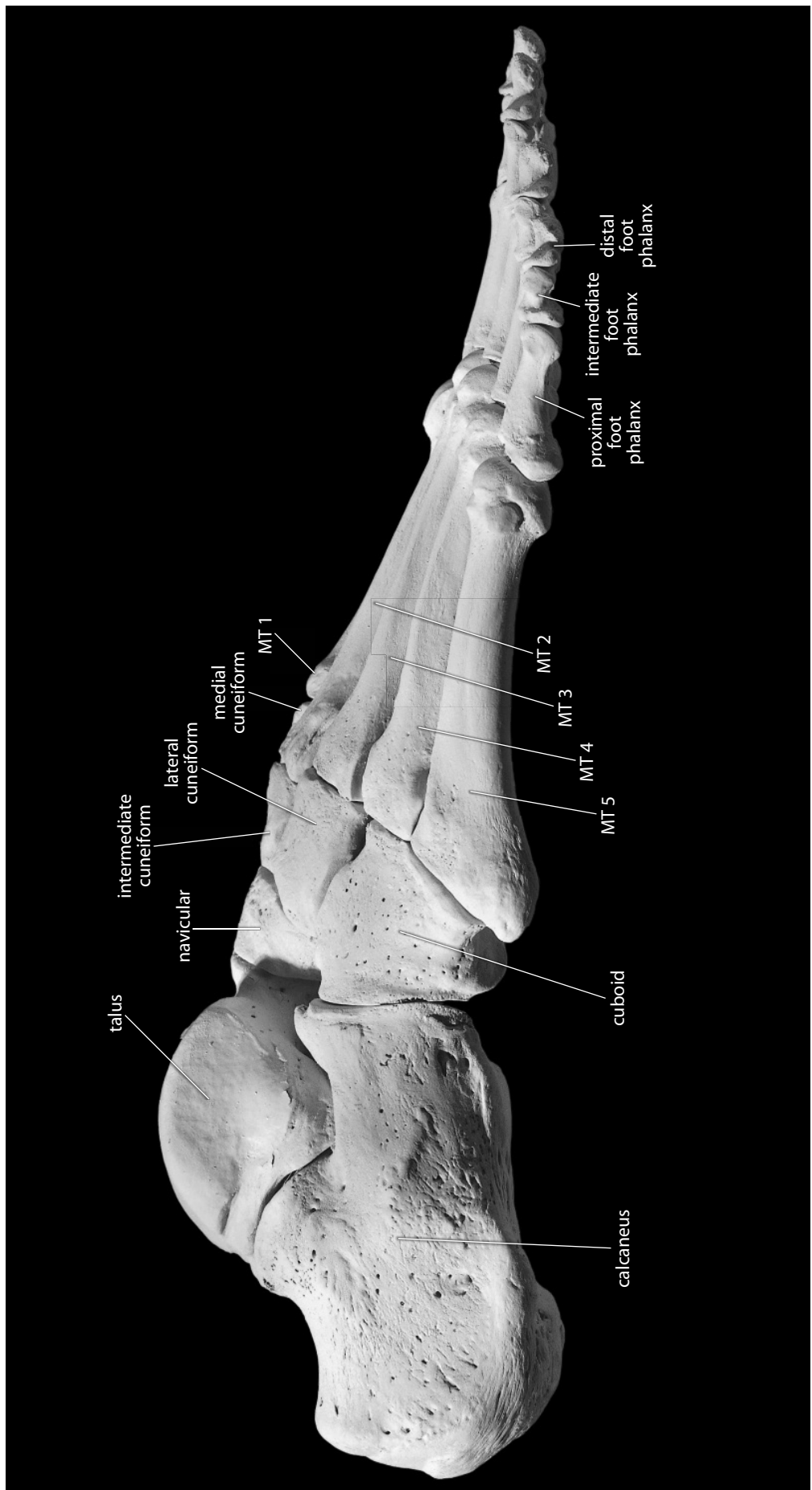


Figure 13.4 Right foot. Lateral view. Natural size.

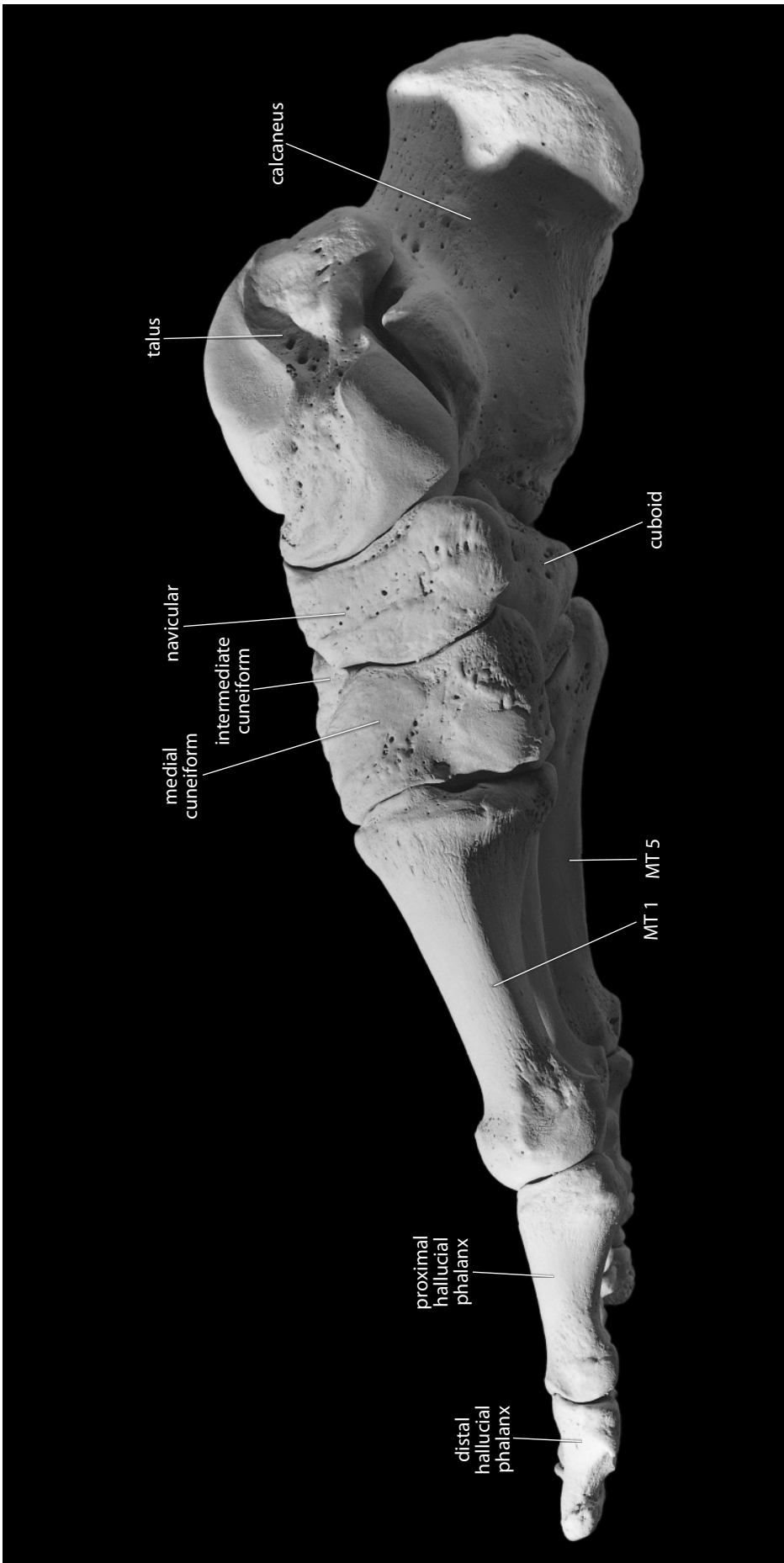


Figure 13.5 **Right foot.** Medial view. Sesamoid bones not included. Natural size.

13.1 Tarsals

The seven tarsals combine with the five metatarsals to form the longitudinal and transverse arches of the foot. The **talus** articulates superiorly with the distal tibia and fibula at the ankle joint. The **calcaneus** forms the heel of the foot, supports the talus, and articulates anteriorly with the **cuboid**, the third largest tarsal bone. The metatarsals articulate proximally with the cuboid and three **cuneiforms**. The seventh tarsal, the **navicular**, is interposed between the head of the talus and these cuneiforms.

13.1.1 Talus (Figures 13.6–13.7, 13.17)

The talus is called the **astragalus** in other animals. It is the second largest of the tarsals and is situated between the tibia and fibula superiorly and the calcaneus inferiorly. No muscles attach to this bone. It rests atop the calcaneus and articulates distally with the navicular. It forms the lower member of the **talocrural joint**. Talar variation is illustrated in Figure 3.1 of Chapter 3.

- The **head** is the rounded, convex, distal articular surface of the talus. It fits into the hollow of the navicular.
- The **body** is the squarish bulk of the bone posterior to the talar neck.
- The **trochlea** is the saddle-shaped articular surface of the body. Its sides are the **lateral** and **medial malleolar surfaces** (or **facets**), which articulate with the fibula and tibia, respectively.
- The **neck** connects the head of the talus to the body. Occasionally there are small articular facets on the neck, formed by contact with the anterior surface of the distal tibia during strong dorsiflexion of the foot at the ankle (or talocrural) joint. These facets are called **squatting facets**.

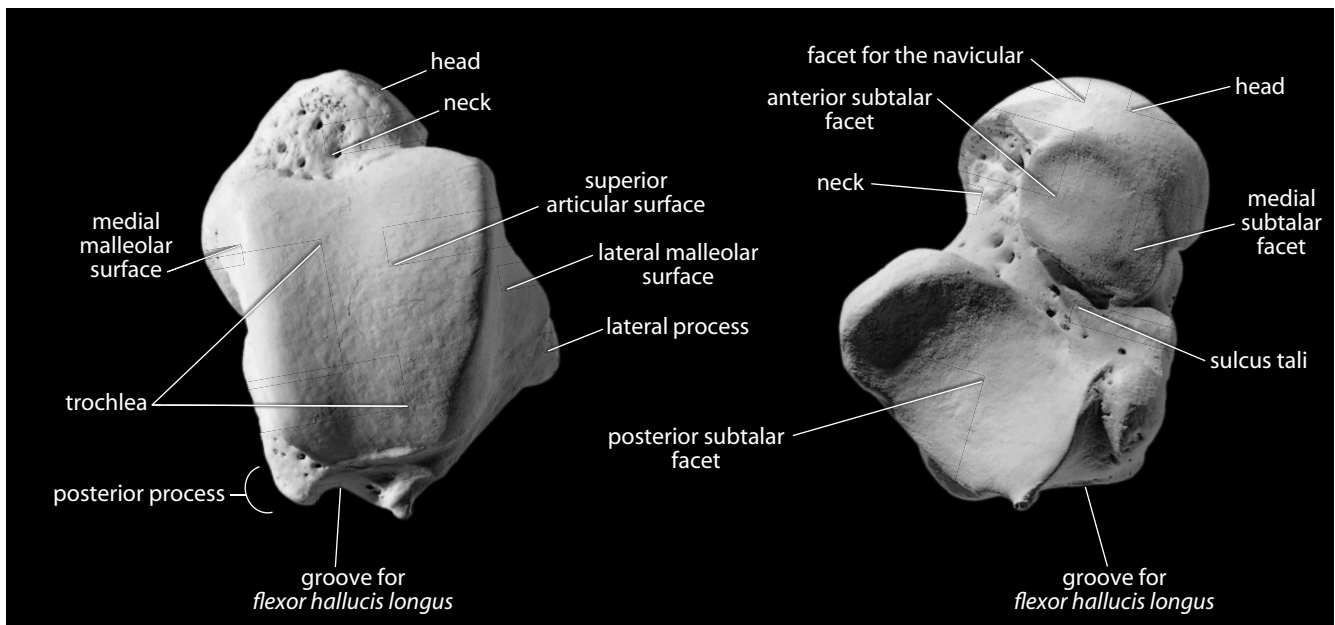


Figure 13.6 **Right talus**. *Left*: dorsal (or superior) view; *right*: plantar (or inferior) view. Distal is up. Natural size.

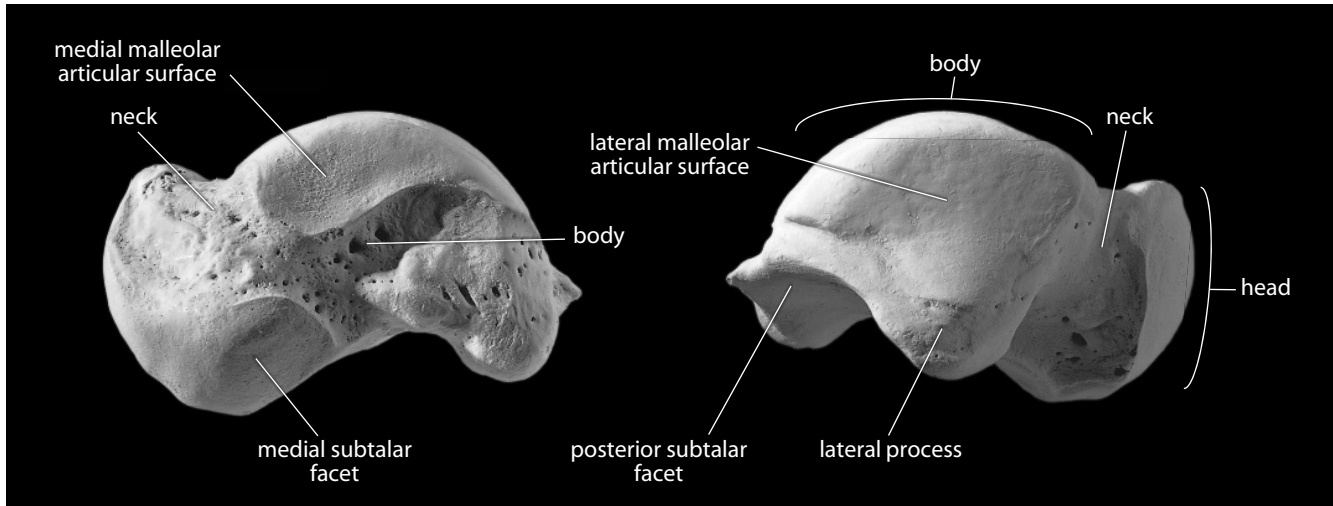


Figure 13.7 **Right talus.** *Left:* medial view; *right:* lateral view. Dorsal is up. Natural size.

- e. The **groove for *flexor hallucis longus*** is the short, nearly vertical groove on the posterior surface of the talar body. It is so named because it transmits the tendon of this muscle, a calf muscle that plantarflexes the foot and hallux.
- f. The **subtalar (or calcaneal) facets** on the inferior aspect of the talus are usually three in number and variable in shape.
 1. The **anterior subtalar (or calcaneal) facet** is the most anterior facet on the plantar (inferior) surface of the talus, often somewhat continuous with the articular surface of the talar head.
 2. The **medial subtalar (or calcaneal) facet** is highly variable, sometimes separated from — but often merging to a greater or lesser extent with — the anterior subtalar facet (see Figure 3.1 for examples).
 3. The **posterior subtalar (or calcaneal) facet** is the largest facet on the plantar surface of the talus. It is concave and obliquely oriented (posteromedial to anterolateral).
- g. The **sulcus tali** is the deep groove between the posterior and middle subtalar facets.
 - **Anatomical siding:** The saddle-shaped articular surface for the distal tibia is superior, and the talar head is anterior. The larger malleolar surface (for the fibula) is lateral.
 - **Positional siding:** The head is medial when viewed from above and aligns with the hallux.

13.1.2 Calcaneus (Figures 13.8–13.10, 13.17)

The calcaneus, or “heel bone,” is the largest of the tarsal bones and the largest bone of the foot. It is located inferior to the talus and articulates anteriorly (distally) with the cuboid.

- a. The **calcaneal tuberosity** is the large, blunt, nonarticular, posterior process of the heel. It is the insertion point of the *calcaneal (or Achilles) tendon*. Contraction of the *gastrocnemius* and *soleus muscles* of the calf causes plantarflexion of the foot, with the calcaneal tuber serving as a lever arm that uses the talar body as its fulcrum.

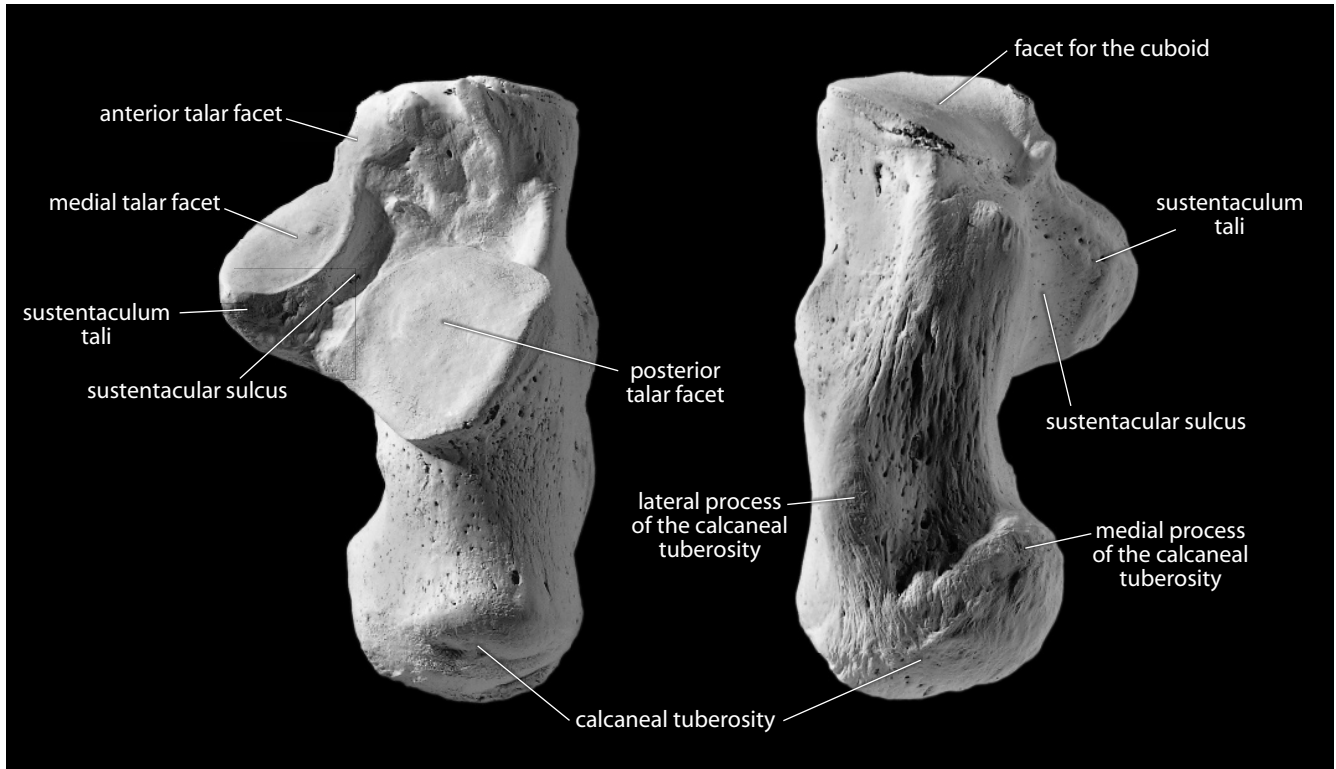


Figure 13.8 Right calcaneus. *Left*: dorsal (or superior) view; *right*: plantar (or inferior) view. Distal is up. Natural size.

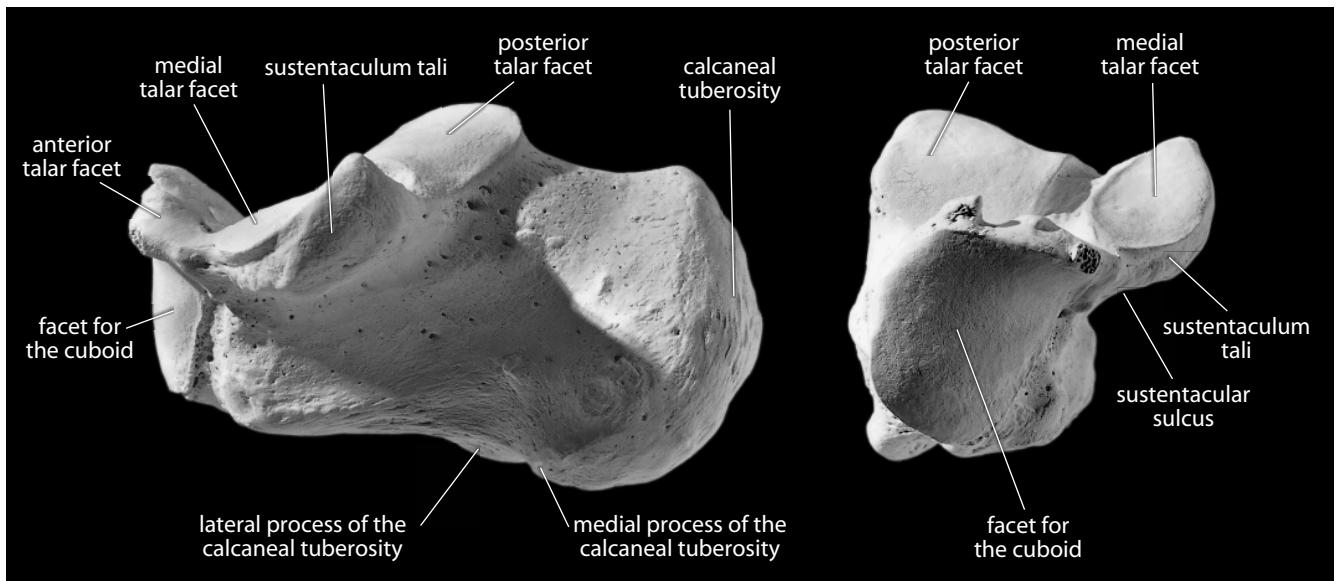


Figure 13.9 Right calcaneus. *Left*: medial view; *right*: anterior view. Dorsal is up. Natural size.

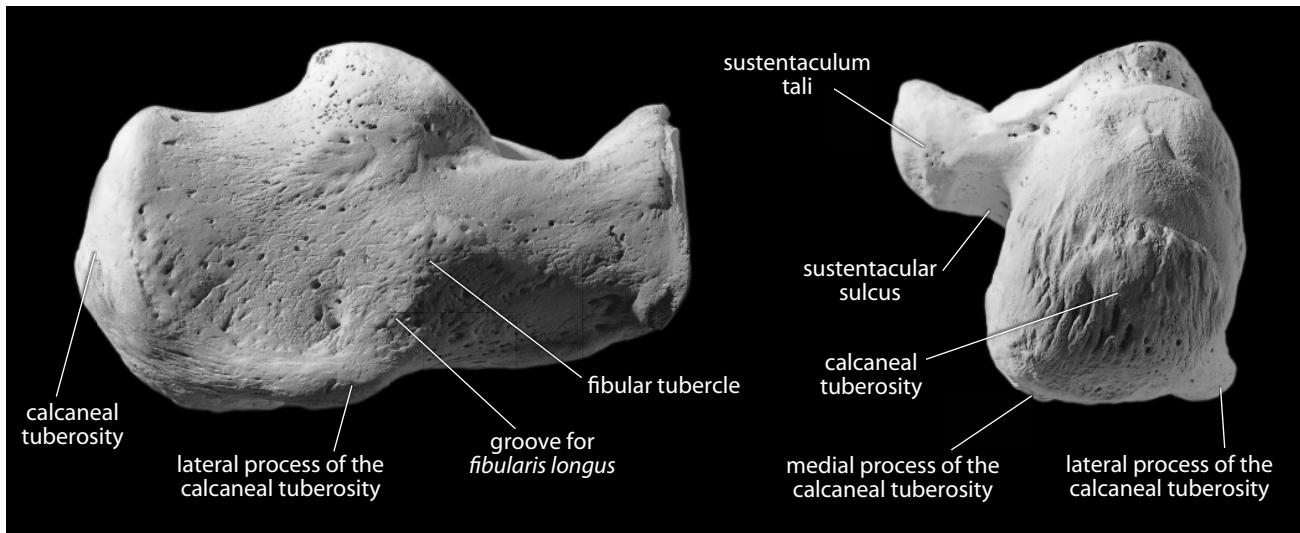


Figure 13.10 Right calcaneus. *Left*: lateral view; *right*: posterior view. Dorsal is up. Natural size.

- b. The **lateral** and **medial processes**, on the plantar portion of the calcaneal tuberosity, serve to anchor several *intrinsic muscles* of the foot. The lateral process is much smaller than the medial.
 - c. The **sustentaculum tali** is the shelf on the medial side of the calcaneus. It supports the talar head.
 - d. The **sustentacular sulcus** (or **groove**), just inferior to the sustentaculum, is a pronounced groove. The *tendon of the flexor hallucis longus muscle*, a plantarflexor of the big toe, travels through this groove. It is continuous posterosuperiorly with the groove on the posterior extremity of the talus.
 - e. The **fibular tubercle** is a rounded projection low on the lateral surface of the calcaneal body. It is closely associated with *tendons of the fibularis (peroneus) longus* and *brevis muscles*. These muscles plantarflex and evert the foot, inserting on the base of the first and fifth metatarsals, respectively.
 - f. The **groove** (or **sulcus**) for *fibularis (peroneus) longus* is located immediately inferior to the fibular tubercle.
- **Possible confusion:** It is not possible to confuse an intact calcaneus with another bone. A broken calcaneal body might sometimes be mistaken for a section of femoral greater trochanter, but the only articular surface on the proximal femur is the spherical head.
 - **Anatomical siding:** The tuberosity is posterior, and the inferior surface is nonarticular. The sustentaculum tali projects medially, inferior to the talar head.
 - **Positional siding:** With the heel away from you and the articular surfaces up, the shelf projects to the side from which the bone comes.

13.1.3 Cuboid (Figures 13.11–13.12)

The cuboid bone sits on the lateral side of the foot, sandwiched between the calcaneus and the fourth and fifth metatarsals, articulating with the navicular and third cuneiform. It is recognized by its large size and projecting, pointed, proximal articular surface. It is the most cuboidal, or cube-shaped, of the tarsal bones.

- a. The **cuboid tuberosity** (Figure 13.12) is a large tuberosity on the inferolateral surface of the bone.
 - b. The *tendon for the fibularis (peroneus) longus muscle* enters the foot via the **groove** adjacent to this tuberosity.
- **Anatomical siding:** The wide, flat nonarticular surface is superolateral, and the pointed calcaneal facet is proximal. The tuberosity is inferolateral. There is an articulation on the medial, but not on the lateral surface.
 - **Positional siding:** Look directly at the flat nonarticular surface. With the calcaneal facet toward you, the tuberosity projects laterally on the side from which the bone comes.

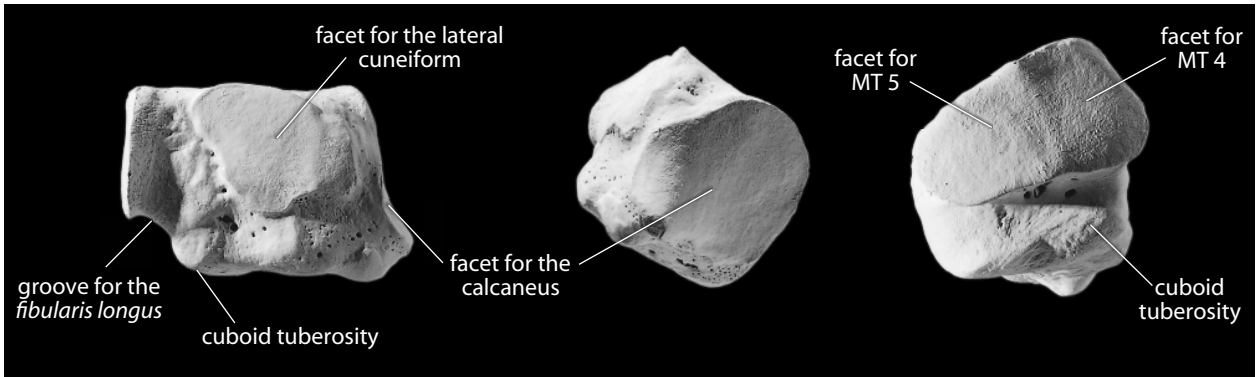


Figure 13.11 **Right cuboid.** *Left:* lateral view; *middle:* proximal view; *right:* distal view. Dorsal is up. Natural size.

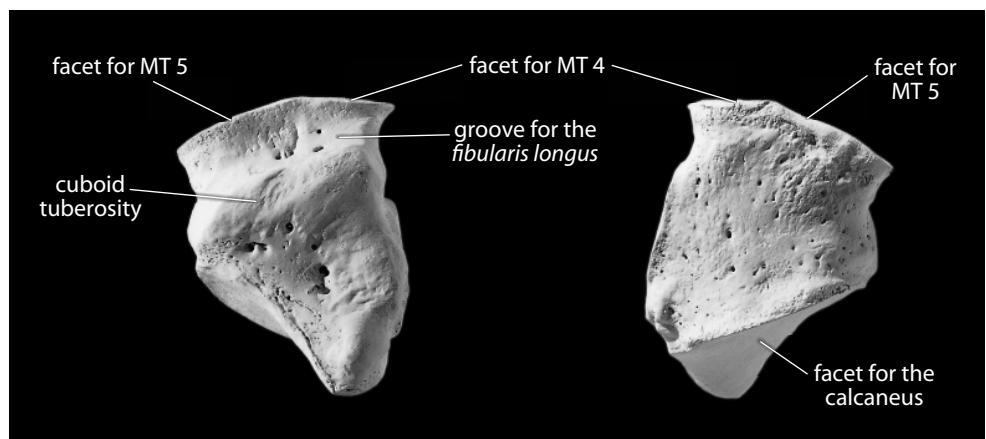


Figure 13.12 **Right cuboid.** *Left:* plantar (or inferior) view; *right:* dorsal (superior) view. Distal is up. Natural size.

13.1.4 Navicular (Figure 13.13)

The navicular is named for the strongly concave proximal surface that articulates with the head of the talus. On the distal surface, the navicular has a large facet divided by two ridges. These demarcate the articular planes of the three cuneiforms. In addition, the navicular often articulates with a corner of the cuboid.

- a. The **tubercle** (Figure 13.13) of the navicular is a large, blunt projection on the medial side of the bone. This tubercle is the main insertion of the *tibialis posterior muscle*, a plantar-flexor of the foot and toes.
 - **Possible confusion:** Although generally similar in gross shape, this bone is much larger than the scaphoid and has a flat side with three facets.
 - **Anatomical siding:** The concave talar facet is proximal. The large, flat nonarticular surface is dorsal, and the tubercle is medial.
 - **Positional siding:** Hold the bone by the base of the tubercle, with the concave articular surface facing you and the flat nonarticular side up. The tip of the tubercle points toward the side from which the bone comes.

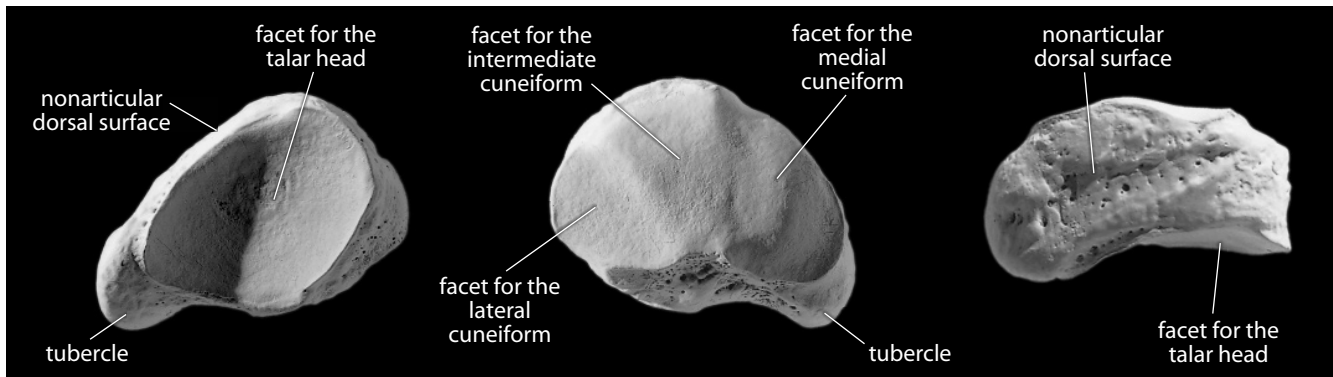


Figure 13.13 Right navicular. *Left:* proximal view, dorsal is up; *middle:* distal view, dorsal is up; *right:* superomedial view, distal is up. Natural size.

13.1.5 Medial (First) Cuneiform (Figure 13.14)

The medial cuneiform is the largest of three cuneiforms. It sits between the navicular and the base of the first metatarsal, articulating with these as well as with the second cuneiform and the base of the second metatarsal (MT 2). It is less wedge-shaped than the other cuneiforms and is distinguished by the kidney-shaped facet for the base of the first metatarsal.

- **Anatomical siding:** The longest, kidney-shaped articular surface is distal, its long axis vertical. The broad, rough, nonarticular surface is medial, and the lateral facet for the intermediate cuneiform is superior. The proximal facet for the navicular is concave.
- **Positional siding:** Place the large, kidney-shaped articular facet away from you and orient its long axis vertically, with the smaller, more concave navicular facet toward you. With the bone resting on its blunter end, the only other facet is near the top (superolateral) and faces toward the side from which the bone comes.




Figure 13.14 Right medial (first) cuneiform. *Left*: medial view; *middle*: lateral view; *right*: proximal view. Dorsal is up. Natural size.

13.1.6 Intermediate (Second) Cuneiform (Figure 13.15)

The intermediate cuneiform is the smallest of three cuneiforms. It is located between the navicular and the second metatarsal. In addition, it articulates on either side with the first and third cuneiforms.

- **Anatomical siding:** The nonarticular dorsal surface of the bone is broadest, and the bone wedges inferiorly, participating in the transverse arch of the foot. The proximal articular surface is usually the most concave (for the navicular). The lateral edge of this facet (proximal, lateral corner of the bone) is concave in profile. The lateral facet can be double or bilobate.
- **Positional siding:** Place the flat, nonarticular surface up and the concave facet away from you. The outline of the superior (dorsal) surface is a square whose most projecting corner points towards the side from which the bone comes.

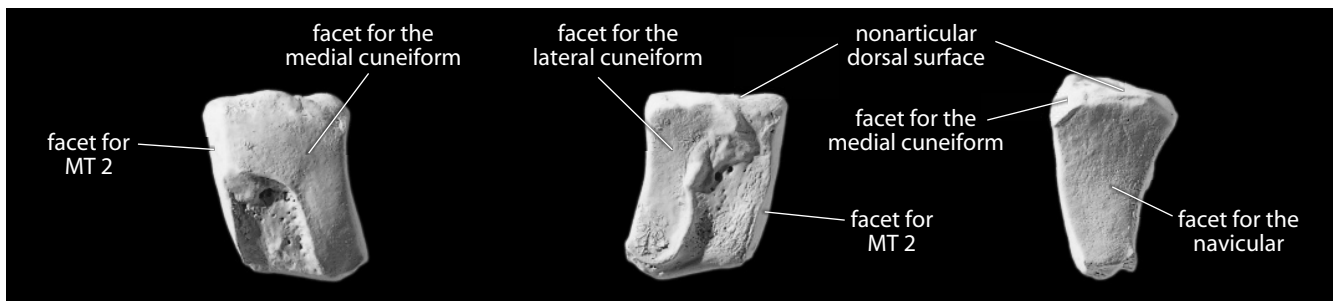


Figure 13.15 Right intermediate (second) cuneiform. *Left*: medial view; *middle*: lateral view; *right*: proximal view. Dorsal is up. Natural size.

13.1.7 Lateral (Third) Cuneiform (Figure 13.16)

The lateral cuneiform is intermediate in size between the other cuneiforms. It is located in the center of the foot, articulating distally with the second, third, and fourth metatarsals. Medially it contacts the intermediate cuneiform, laterally the cuboid, and proximally the navicular.

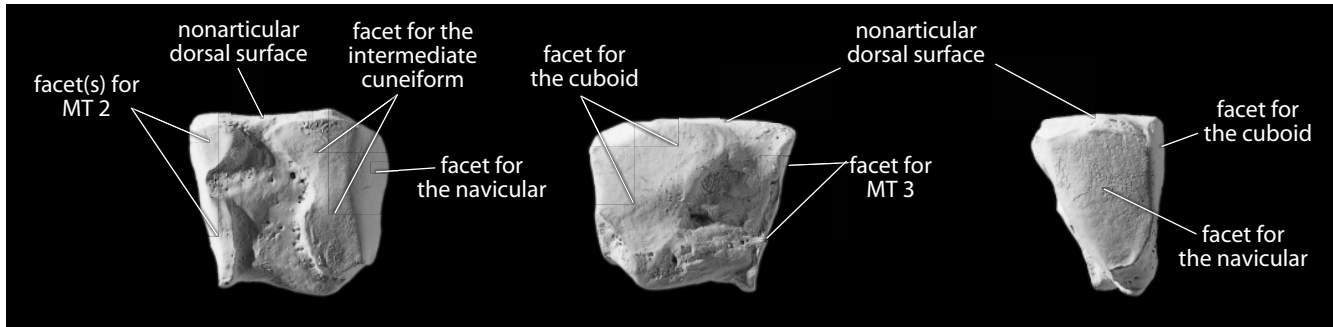


Figure 13.16 Right lateral (third) cuneiform. *Left*: medial view; *middle*: lateral view; *right*: proximal view. Dorsal is up. Natural size.

- **Anatomical siding:** The dorsal surface is a rectangular, nonarticular platform, and the bone wedges inferiorly to this. The proximal (navicular) articulation is wider but smaller than the elongate, wedge-shaped distal MT 3 facet. The border between the navicular and the cuboid facets projects in a V-shape as the base of the third cuneiform wedges between these two bones.
- **Positional siding:** Place the flat, nonarticular surface up (wedge down), with the smaller end facet toward you. The Africa-shaped facet is away from you. The longest boundary of the upper surface is on the side from which the bone comes.

13.1.8 Growth

The tarsals each ossify from a single center, with the exception of the calcaneus, which has an epiphysis at its posterior end.

13.1.9 Possible Confusion

As with the carpals, most of the tarsals are compact and robust structures. Identification of fragmentary tarsals is therefore not usually required. The exception to this is the calcaneus, which is less dense and is often broken in its nonarticular areas. Because most of the tarsals are larger than carpals, they are more often recovered from archaeological contexts. Siding of tarsals, as with carpals, is facilitated by positional techniques. Some of the techniques presented here are adopted from Bass (2005).

13.1.10 Tarsal Measurements (Figure 13.17)

The largest two tarsals, the talus and calcaneus, are the most often measured, and the measurements most often taken are indicated here (there are many others that have been defined and employed, depending on the particular research question being asked).

1. **Maximum calcaneal length** (Martin, 1928: 1058, #1; Buikstra and Ubelaker, 1994: 84, #77): Keeping the measuring axis of the sliding caliper parallel to the long axis of the bone, measure the greatest anteroposterior distance on the calcaneus.
2. **Posterior calcaneal length** (Martin, 1928: 1059, #5): Use a sliding caliper to measure the distance between the posteriormost point on the tuberosity and the anteriormost point on the posterior talar facet.




Figure 13.17 Tarsal measurements. Two-thirds natural size.

Locations: a) anteriormost point on calcaneus; b) posteriormost point on calcaneus; c) anteriormost point on the posterior talar facet; d) anteriormost point on talar head; e) deepest point in sulcus for *flexor hallucis longus*; f) posteriormost point on talus.

Measurements: 1) maximum calcaneal length; 2) posterior calcaneal length; 3) talar length; 4) maximum talar length.

3. **Talar length** (Martin, 1928: 1053–1054, #1): With a sliding caliper, measure the distance between the sulcus for *flexor hallucis longus* and the anteriormost point on the talar head.
4. **Maximum talar length** (Martin, 1928: 1054, #1a; Steele, 1976: 582): Similar to talar length, but is instead measured between the anteriormost point on the talar head and the posteriormost point on the talus (usually the posterior tubercle).

13.1.11 Tarsal Nonmetric Traits

- **Talar squatting facet(s):** In individuals who habitually spend time with their ankles in a extreme dorsiflexed position (*eg.*, sitting in a deep squatting position), a pair of conforming facets sometimes forms on the approximated anteroinferior tibia and anterosuperior talus. The talar facet is usually scored as 0 (absent), 1 (medial facet), 2 (lateral facet), 3 (central [neck] facet), 4 (medial and lateral facet), 5 (medial and neck facet), or 6 (lateral and neck facet).
- **Trochlear (or talar) extension(s):** Using an imaginary line drawn in a paracoronal plane and intersecting the anterosuperior margin of the lateral malleolar surface of the talus as a reference, observe the medial and/or lateral talar trochlear margins extend anteriorly beyond this line. Usually scored as 0 (absent), 1 (medial extension), 2 (lateral extension), or 3 (medial and lateral extension).
- **Anterior calcaneal facet:** Occasionally the anterior and medial subtalar (or calcaneal) facets of the talus are discontinuous, either completely or partially separated by a non-articular zone. Usually scored as 1 (one facet), 2 (two facets), or 3 (waisted or hour-glass facet).
- **Fibular (previously peroneal) tubercle:** Sometimes the fibular tubercle is present, sometimes it is absent, and sometimes it is indistinguishable from the attachment area of the calcaneofibular ligament. When the fibular tubercle can be clearly defined, it is scored as present. Usually scored as 0 (absent), or 1 (present).

13.2 Metatarsals (Figures 13.18–13.22)

The metatarsals, like the metacarpals, are numbered from MT 1 (the hallux, or big toe) through MT 5, according to the five rays of the foot. They are all tubular bones with round distal articular surfaces (**heads**) and more squarish proximal ends (**bases**). As with metacarpals, metatarsals are identified and sided most effectively according to the morphology of their bases.

The plantar metatarsal **shaft** surfaces are always more concave in lateral view than their dorsal shaft surfaces. The bases of nonhallucial metatarsals all articulate with adjacent metatarsals. Each of the tarsals in the distal row articulate with at least one metatarsal base.

13.2.1 First Metatarsal

The first metatarsal is the shortest but most massive metatarsal. It articulates at its base with the medial cuneiform. The **sesamoid grooves** at the base of the head correspond to sesamoid bones (Figure 13.25) in the *tendons of flexor hallucis brevis*, a short plantarflexor of the big toe.

- **Siding:** The basal facet has a convex medial profile and a straight lateral profile.

13.2.2 Second Metatarsal

The second metatarsal is the longest and narrowest metatarsal. It has two lateral facets at the base, each articulating with the lateral cuneiform and MT 3. It articulates proximally with the intermediate cuneiform and medially with the medial cuneiform. Its base has slightly more of a “styloid” appearance than the base of MT 3.

- **Siding:** The most proximal point on the base is lateral to the main shaft axis.

13.2.3 Third Metatarsal

The third metatarsal is very similar to MT 2, but its base has two medial basal facets that are smaller than MT 2 lateral facets. The lateral basal facet is single and large. The base is squarer than the MT 2 base, and there is a large, bulging tubercle distal to the lateral articular facet. The base articulates with MT 2 and MT 4 and with the lateral cuneiform.

- **Siding:** The most proximal point on the base is lateral to the main shaft axis.

13.2.4 Fourth Metatarsal

The fourth metatarsal is shorter than MT 2 or MT 3. It has single medial and lateral basal facets for articulation with MT 3 and MT 5. The proximal facet for the cuboid is fairly oval.

- **Siding:** The most proximal point on the base is lateral to the main shaft axis.

13.2.5 Fifth Metatarsal

The fifth metatarsal bears a large **styloid process**, a distinctive, blunt, nonarticular basal projection. It is lateral, opposite the MT 4 facet, and projects proximally. It is the insertion point for the *tendon of the fibularis (peroneus) brevis muscle*, a calf muscle that acts to plantarflex and evert the foot

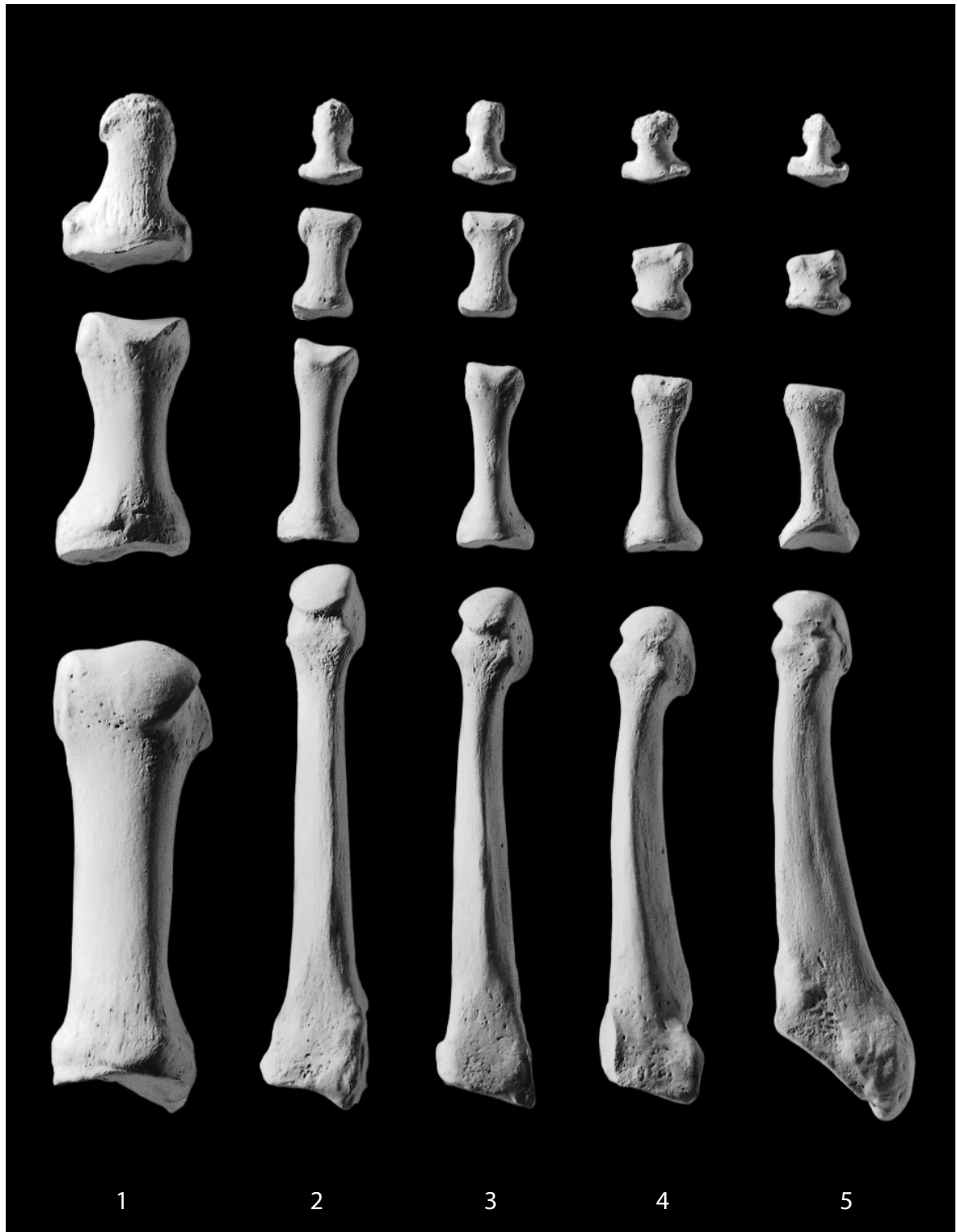


Figure 13.18 **Right foot, dorsal (superior)**. Rays 1–5, showing the metatarsals and the proximal, intermediate, and distal foot phalanges. Distal is up; lateral is toward the right. Natural size.

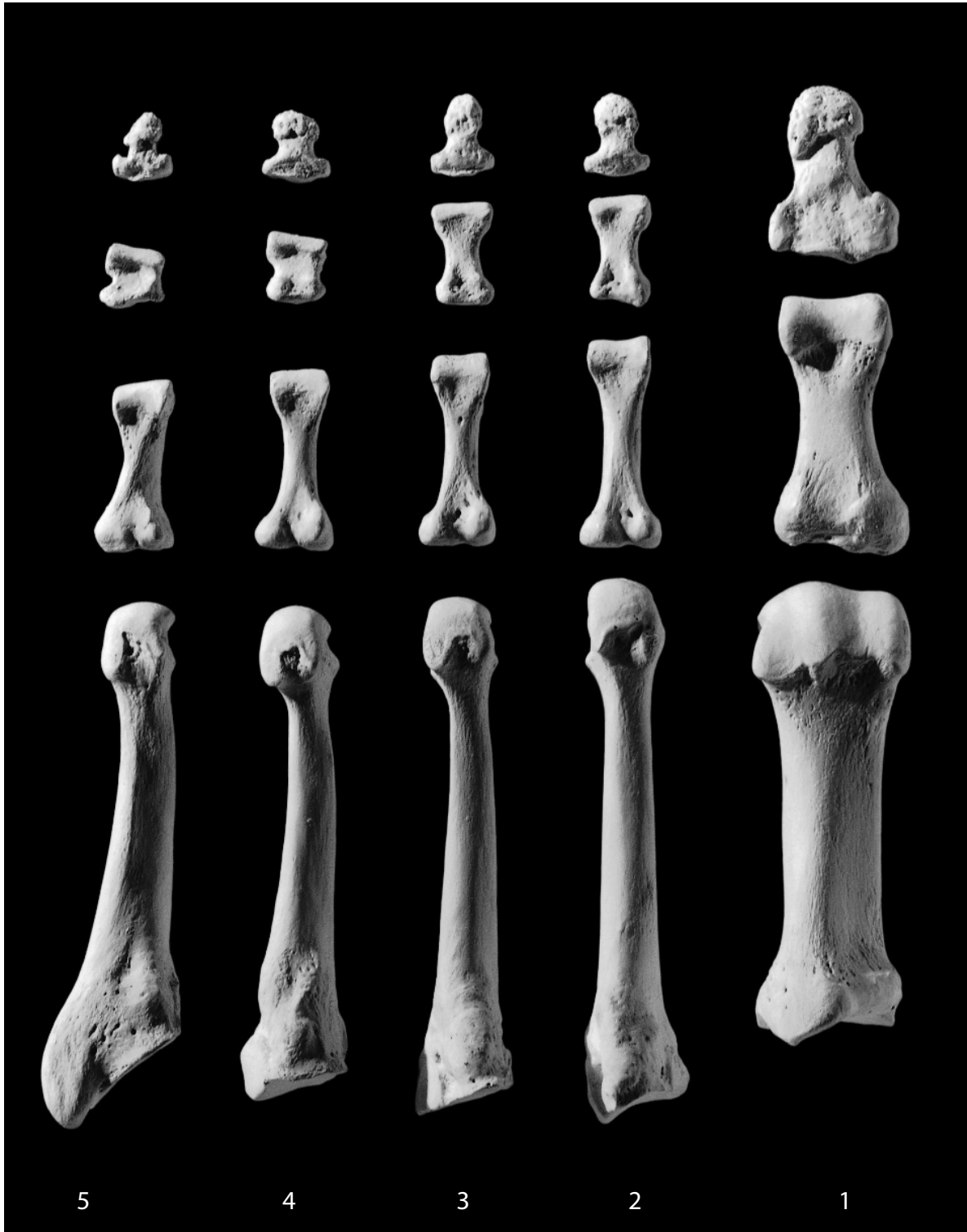


Figure 13.19 **Right foot, plantar (inferior)**. Rays 1–5, showing the metatarsals and the proximal, intermediate, and distal foot phalanges. Distal is up; lateral is toward the left. Natural size.

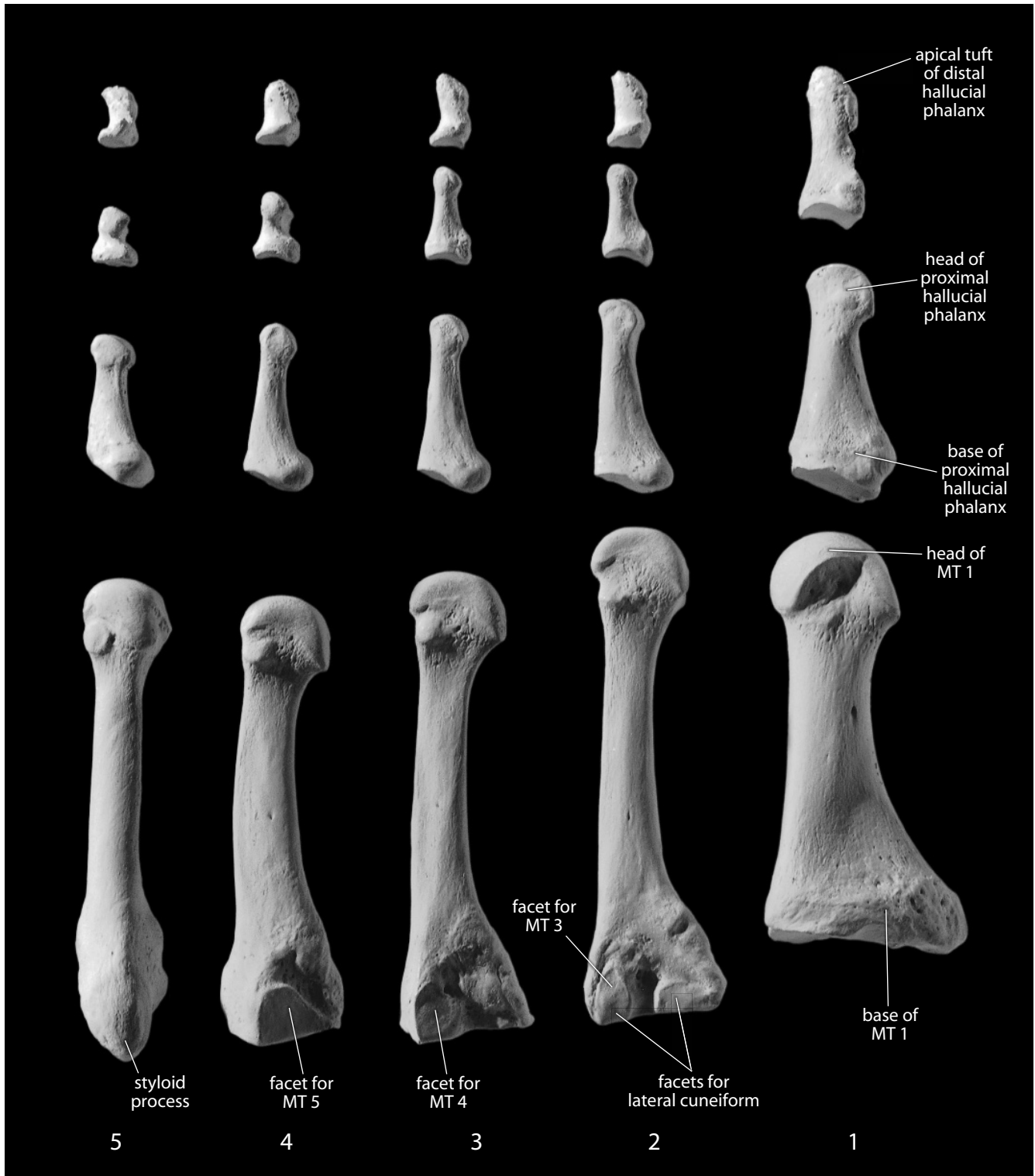


Figure 13.20 **Right foot, lateral.** Rays 1–5, showing the metatarsals and the proximal, intermediate, and distal foot phalanges. Distal is up; plantar is toward the right. Natural size.

at the ankle. On the plantar side of the styloid process is a groove marking the route of the *flexor digiti minimi* muscle. The proximal basal articulation is for the cuboid.

- **Siding:** The styloid process is lateral. Groove on the base of the tubercle is inferior.

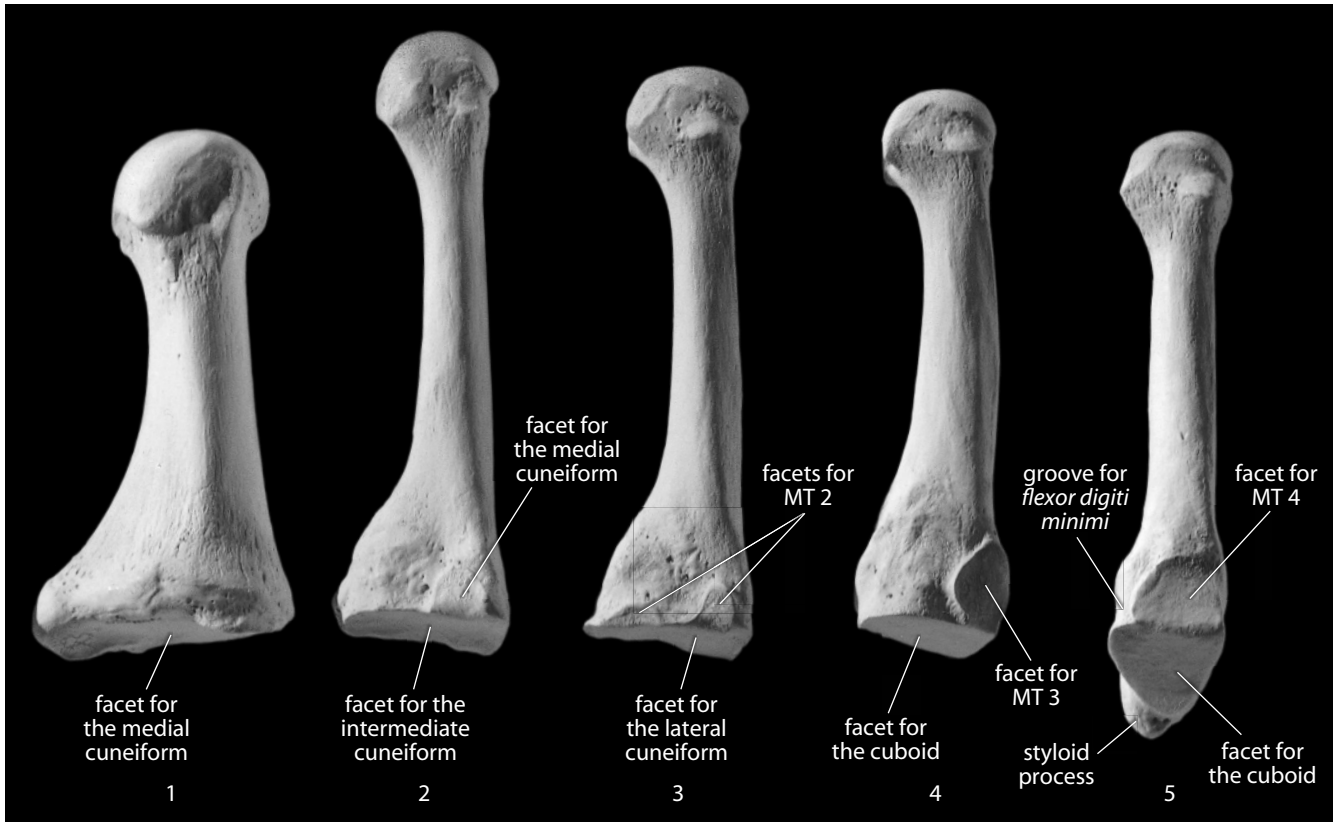


Figure 13.21 Right metatarsals, medial. Distal is up. Natural size.

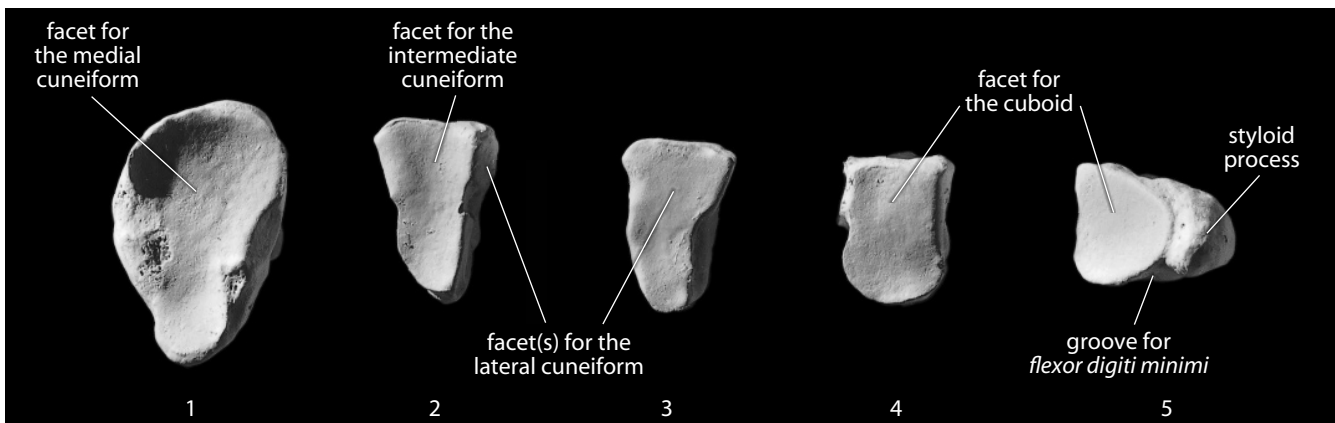


Figure 13.22 Right metatarsal bases, proximal. Dorsal is up. Natural size.

13.2.6 Growth (Figure 13.23)

Metatarsals each ossify from two centers. For MT 2, MT 3, MT 4, and MT 5 there is one center for both the base and shaft and a second for the distal end. For the MT 1, there is one center for the shaft and one for the proximal end.

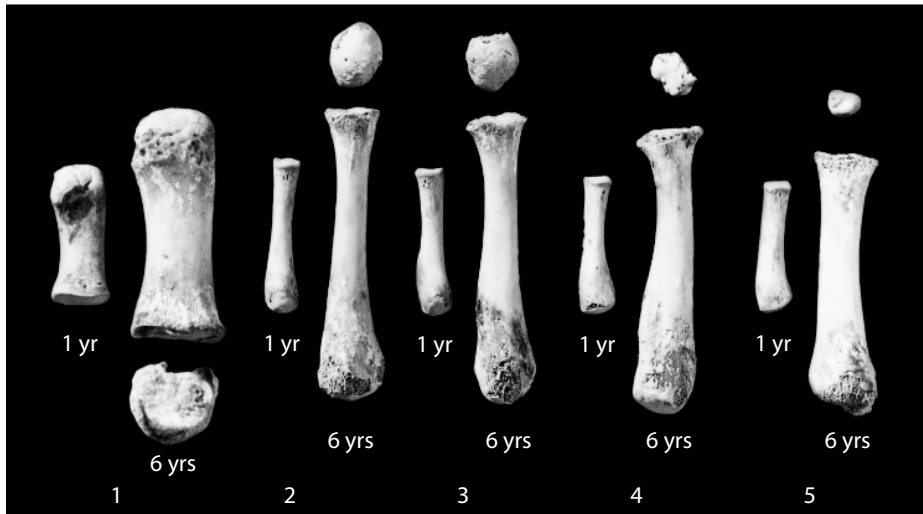


Figure 13.23 Metatarsal growth. The pairs of immature metatarsals are shown here in plantar view, with ray 1 on the left and ray 5 on the right. They are from one-year-old and six-year-old individuals. Natural size.

13.2.7 Possible Confusion

Metatarsals and metacarpals are similar in gross size and shape but are easily distinguished from each other. Metatarsals 2, MT 3, MT 4, and MT 5 are longer than metacarpals 2, MC 3, MC 4, and MC 5, with straighter and narrower shafts. Metatarsal heads are compressed more mediolaterally and are smaller relative to their bases than metacarpal heads.

13.2.8 Siding

Metatarsal bases are always proximal, and the most proximal part of the base is always lateral on MT 2, MT 3, MT 4, and MT 5.

13.2.9 Metatarsal Measurements (Figure 13.24)

1. **Maximum metatarsal length** (Cordeiro et al., 2009: 131.e2; Zipfel et al., 2009: 534, #2): Keeping the sliding caliper parallel to the long axis of the diaphysis, determine the maximum length of the metatarsal.
2. **Metatarsal biomechanical (or articular) length** (Martin, 1928: 1064, #1 [for MT 1], #2 [for MT 2–5]): With a sliding caliper (or for MT 1, a small spreading caliper or a sliding caliper equipped with at least one inside point extension), measure the distance from the center of the tarsal articular surface to the distalmost point on the metatarsal head.
3. **Midshaft height** (Martin, 1928: 1064, #4): First, determine the location at midshaft using 50% of biomechanical length. At this location, use a sliding caliper to measure the greatest dorsoplantar dimension.
4. **Midshaft breadth** (Martin, 1928: 1064, #3): Measuring from the midshaft location (50% of biomechanical length), use a sliding caliper to measure the greatest mediolateral dimension.

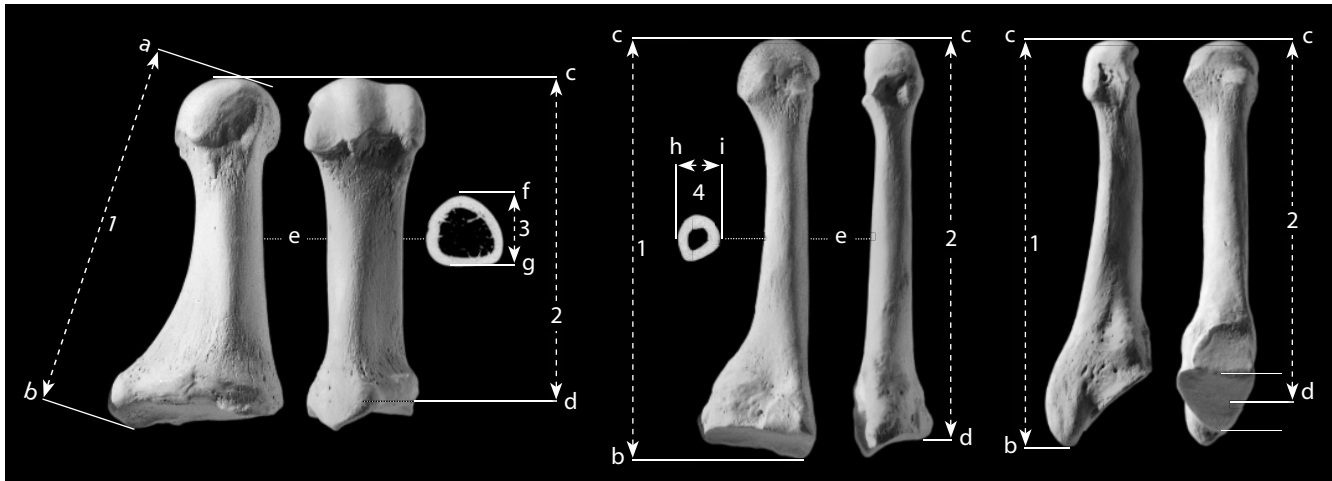


Figure 13.24 Metatarsal measurements. Distal is up for bones; for scans, plantar is up. Two-thirds natural size.

Locations: a) point on metatarsal head farthest from 'b'; b) proximalmost point on metatarsal; c) distalmost point on metatarsal head; d) center of tarsal articular surface; e) location of midshaft; f) plantar most point at midshaft; g) dorsal most point at midshaft; h) lateralmost point at midshaft; i) medialmost point at midshaft.

Measurements: 1) maximum metatarsal length; 2) metatarsal biomechanical (or articular) length; 3) metatarsal midshaft height; 4) metatarsal midshaft breadth.

13.2.10 Metatarsal Nonmetric Traits

- There are no commonly cited nonmetric traits of the metatarsals, and variation in discrete traits seen in these elements is rarely noted.

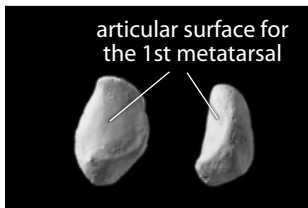


Figure 13.25 Sesamoid of the right foot. *Left:* superior (or dorsal) view; *right:* lateral view. Natural size.

13.3 Foot Phalanges (Figures 13.18–13.20, 13.26–13.27)

Foot phalanges are all shorter than metatarsals, and they lack the rounded heads of metatarsals. The hallucial (big toe) phalanges are shorter and squatter than the others, and the hallux lacks an intermediate phalanx. The expanded proximal end of each phalanx is the **base**. The distal end is the **head** (in proximal or intermediate phalanges) or the **distal tip** (or tuft; in the distal phalanges). The distal articular surface of proximal and intermediate phalanges is called the **trochlea**. Unlike hand phalanges, both dorsal and plantar surfaces of foot phalanges are smooth and rounded. Foot phalanges are much shorter than hand phalanges in humans.

13.3.1 Proximal Foot Phalanges

Each proximal foot phalanx displays a single, concave proximal facet for the metatarsal head, and a spool-shaped, or trochlear, surface distally. The hallucial proximal phalanx is larger and stouter than the others.

13.3.2 Intermediate Foot Phalanges

Each intermediate foot phalanx displays a double proximal articular facet for the head of the proximal phalanx. Each also has a trochlear distal articular facet. These phalanges are “stunted,” squat versions of their analogs in the hand.

13.3.3 Distal Foot Phalanges

Each distal foot phalanx displays a double proximal articular facet for the head of the intermediate phalanx, but the terminal tip of the bone is a nonarticular pad, the **distal phalangeal tubercle** (or **tuft**). These distal foot phalanges are very small and stubby compared to distal hand phalanges.

13.3.4 Growth (Figure 13.23)

Foot phalanges each ossify from two centers: one for the shaft and distal end, and one for the base.

13.3.5 Possible Confusion

Hand and foot phalanges are easily distinguished, even when isolated. Foot phalanges are all much shorter than their analogs in the hand.

- Proximal foot phalanges are the only ones that might be mistaken for hand phalanges.
- Phalangeal shafts in the hand are compressed dorsoventrally, forming a D-shape in cross section, whereas those in the foot are more circular in cross section (Figure 13.27). Therefore, the shafts of foot phalanges will roll easily between your fingertips, and the shafts of hand phalanges will not.
- Foot phalanges display more constriction at midshaft than hand phalanges.
- The hallux has only a proximal and a morphologically distal phalanx, and these squat, massive bones are very distinctive.

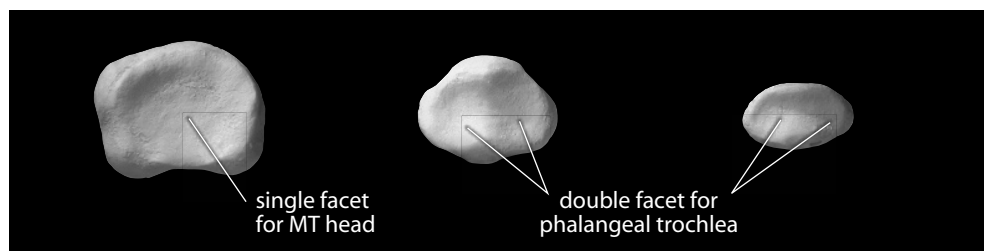


Figure 13.26 **Bases of foot phalanges.** *Left:* proximal foot phalanx; *center:* intermediate foot phalanx; *right:* distal (or terminal) foot phalanx. All phalanges are from ray 2. Dorsal is up. Natural size.

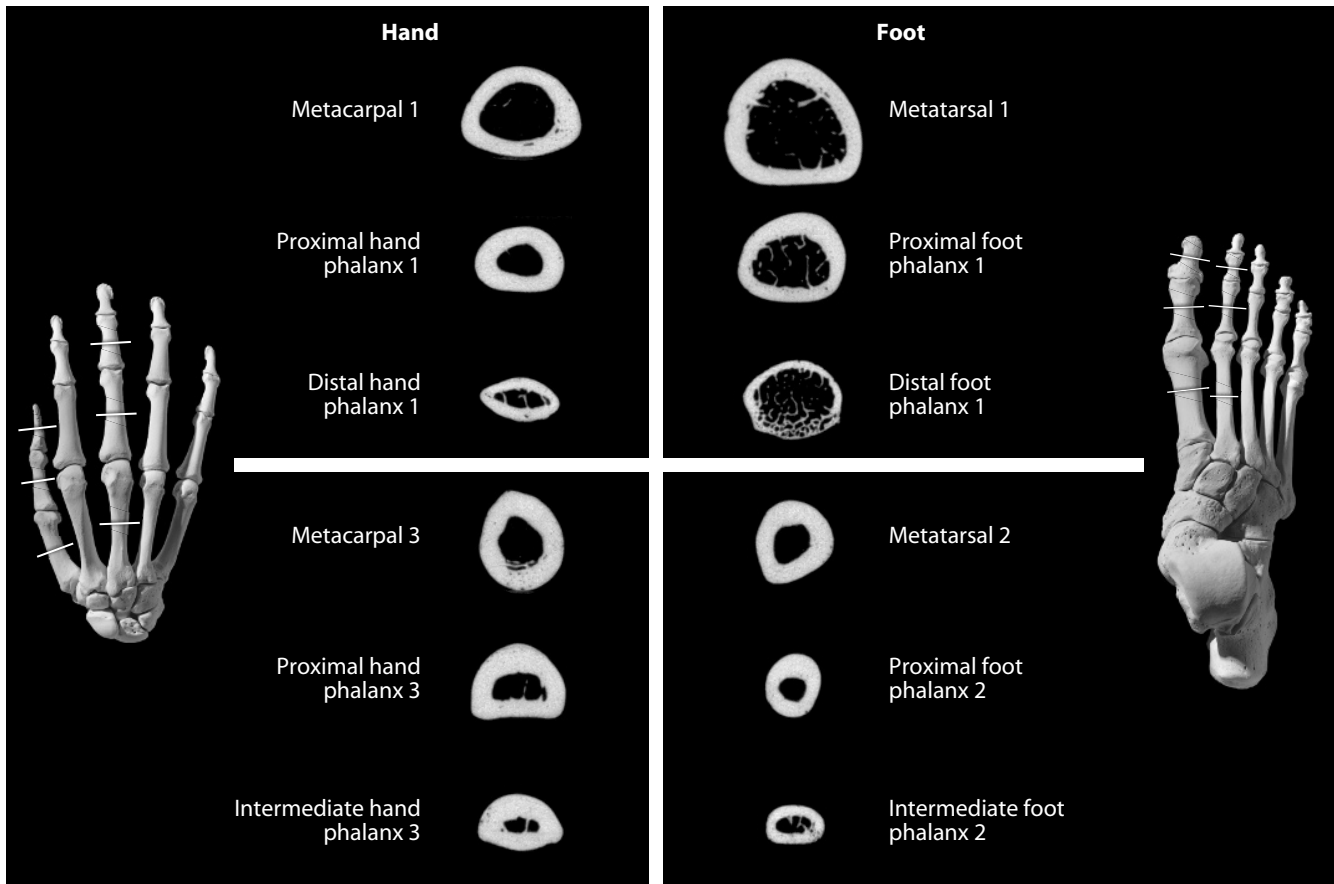


Figure 13.27 Midshaft CT scans of long bones of the foot and hand compared. Shafts of foot phalanges and the hallucal metatarsal have rounder cross sections than those of hand phalanges or the thumb metacarpal. The scans were taken from the bones of the individual used to illustrate postcrania in this book. The positions of the CT sections are illustrated on the articulated hand and foot. Dorsal is up and palmar/plantar is down. Natural size.

13.3.6 Siding

It is best to work with whole specimens and comparative materials for siding hand and foot phalanges. The head is distal, and the base is proximal. The dorsal phalangeal shaft surfaces are smooth and straight, whereas the plantar surfaces are more irregular and curved.

13.3.7 Pedal Phalangeal Measurements (Figure 13.28)

1. **Phalangeal length** (Martin, 1928: 1065, #1): Keeping the sliding caliper parallel to the long axis of the phalangeal diaphysis, determine the maximum distance between the distal trochlea or tuft to the proximalmost point on the plantar surface of the phalanx.
2. **Phalangeal biomechanical (or articular) length** (Martin, 1928: 1065, #1a): With a small spreading caliper or a sliding caliper equipped with at least one inside point extension, place the point extension in the depth of the middle of the proximal articular surface and measure the distance to either the proximalmost point on the head of the phalanx (for proximal and intermediate phalanges) or to the distalmost point on the apical tuft (for distal phalanges).

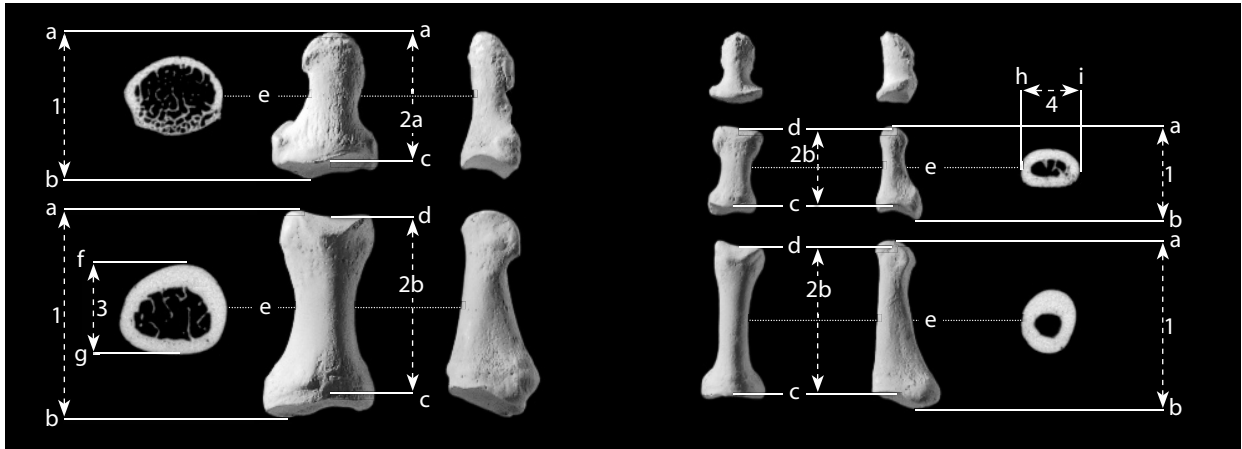


Figure 13.28 Foot phalangeal measurements. Phalanges of first and second pedal ray. Distal is up for bones; for scans, dorsal is up. Natural size (CT sections) and two-thirds natural size (bones).

Locations: a) distalmost point on phalanx; b) proximalmost point on phalanx; c) deepest point of proximal articular surface; d) distalmost point of central sulcus of trochlea; e) location of midshaft; f) dorsalmost point of midshaft; g) plantar most point of midshaft; h) medialmost point of midshaft; i) lateralmost point of midshaft.

Measurements: 1) phalangeal length; 2a) phalangeal biomechanical length (of distal phalanx); 2b) phalangeal biomechanical length (of proximal or intermediate phalanx); 3) phalangeal midshaft height; 4) phalangeal midshaft breadth.

3. **Midshaft anteroposterior (or dorsoplantar) height** (Martin, 1928: 1065, #3): First, determine the location at midshaft using 50% of biomechanical length. At this location, use a sliding caliper to measure the greatest dorsoplantar dimension.
4. **Midshaft mediolateral breadth** (Martin, 1928: 1065, #2): Measuring from the midshaft location (50% of biomechanical length), use a sliding caliper to measure the greatest mediolateral dimension.

13.3.8 Pedal Phalangeal Nonmetric Traits

- There are no commonly cited nonmetric traits of the foot phalanges, and variation in these elements is rarely specifically categorized as discrete traits.

13.4 Functional Aspects of the Foot

The rigid, transversely and longitudinally arched form of the human foot is a radical departure from the grasping appendage that characterizes the other living primates. Hominid anatomy evolved to meet the peculiar demands of habitual, striding, bipedal locomotion. Cartmill, Hylander, and Shafland (1987) note that anatomy of the human foot is best appreciated by considering it as a hand in which the thumb is tied to the second digit, the metacarpals elongated to form a longer lever, the phalanges shortened, and the serial homolog of the triquetral (the foot's calcaneus) enlarged into a massive lever arm. Foot phalanges have fingerlike movements, but these are comparatively restricted. Extrinsic foot muscles in the foreleg, like those of the forearm, move the foot and toes. These are compartmentalized, with plantar flexors posteriorly and dorsiflexors anterolaterally. These muscles operate mostly via tendons across the ankle. As in the hand, there are also intrinsic foot muscles.

Chapter 14

ANATOMICAL AND BIOMECHANICAL CONTEXT

IN THE PRECEDING CHAPTERS, MORPHOLOGY was introduced and a myriad of named features of individual bones were detailed as a means of identifying isolated and/or fragmentary skeletal remains. Some of the relationships that these features have with the “soft” anatomical structures attached to the bones in the once-living individual were considered. Here we continue that exploration, offering visualizations of the relationships among bones and the soft tissues that link them during life. The forces that these “soft” tissues (such as muscles and ligaments) exert can influence the overall shapes of the bones as well as their surface morphology.

The “soft” anatomical structures illustrated in this chapter were included when they met certain criteria: 1) the anatomical structure directly attaches to the illustrated bone or its periosteum; 2) at least one of the attachment sites of the anatomical structure is visible on at least one view of the bone; 3) the anatomical structure exerts a tensile force on the bone (*i.e.*, it is not a blood vessel, nerve, fat deposit, bursa, etc.). Periosteum is not illustrated because it is ubiquitous. Because of space constraints, some cranial ligaments and all of the intrinsic muscles of the eye and ear are not illustrated. Note that the soft tissue attachment maps are only inferred approximations of what the actual original soft tissue attachments were during life.

Because of space limitations, only selected elements are illustrated in this chapter. The six major long bones of the upper and lower limbs were included, as was the clavicle. Each of these long bones is distinguished by possessing both a complex surface topography and a complex cross-sectional architecture. In addition, the skull and the os coxae were included due to the complexity and number of soft tissue attachments on each.

14.1 Anatomical Conventions

Skeletal muscles act to produce movement of the body. Muscles and their tendons often extend across joints. When the muscle contracts, it exerts a tensile force that causes the bones to move relative to one another, using the joint between them as a fulcrum.

In general, muscles have a fleshy belly that sits between two tendinous (or sometimes fleshy) ends. The **origin** of a muscle is the end attached to the more stable or inertial side of a joint (usually the side closest to the body’s axis). A muscle’s **insertion** is the end attached to the more movable side of a joint. For example, the *biceps brachii* spans both the shoulder (glenohumeral) joint and the elbow (cubital) joint. When the *biceps brachii* contracts, as when doing a dumbbell curl,

the elbow joint is flexed. Because of the relative mass of the forearm versus the rest of the body, it is the forearm that moves the most. Thus, anatomists call the radial end of the *biceps brachii* the insertion, and the humeral and scapular ends are called the origins. In anatomical illustrations, sites of muscular origins are traditionally colored red, and sites of muscular insertions are blue. Articular surfaces are shown in yellow on the figures in this chapter. These conventions have been followed in the figures in this chapter.

Ligaments are cords, bands, or sheets of tough, fibrous tissue that, like muscles, typically cross joints and have attachment sites on bones. Unlike muscles, ligaments are entirely passive. Instead of contracting to produce movement at a joint (like muscles), ligaments typically remain slack until the bones of a joint are closer to being dislocated. Ligaments resist tension, thereby strengthening the joint and permitting only movements compatible with the function of the joint.

The anatomical terminology used in this chapter is in accordance with the latest international standards for such terminology, as expressed in the *Terminologia Anatomica* (FCAT, 1998). Because adoption of the new terminology standard has been uneven in North America (Martin et al., 2009, 2010; Vogl, 2009), synonymous older terminology is also presented where it may prove helpful.

14.2 Biomechanical Conventions

The long bones in this chapter (clavicle, humerus, radius, ulna, femur, tibia, fibula) were micro-CT scanned at the five standard sections: 20%, 35%, 50%, 65%, and 80% of biomechanical length. By convention, section locations are measured from the *distal* end of the long bone (*i.e.*, the distalmost of these sections is called the 20% section). These micro-CT scans were taken from the same bones used to illustrate Chapters 4–13. Details of the scanning methodology can be found in Appendix 1.

In addition to the rich visual information CT scans provide concerning the internal morphology of a bone, they are a valuable source of data that can be used to calculate approximations of a bone's mechanical properties. The total amount of bone (in cross section), the distribution of that bone around the central axis of the bone, the microstructure of the bone, and the material properties of the bone all contribute to these mechanical properties.

Biomechanists model long bones as beams in order to better understand their mechanical properties. The **bending strength** (*i.e.*, rigidity, or resistance to bending) of a beam is the product of two quantities: E (**Young's modulus**), and I (the **second moment of area**, usually called the "**moment of inertia**"). Young's modulus, E , describes how a material responds (usually in terms of how much it changes in length) when stressed by a force applied over a given area of that material. It is convention to assume that variation in Young's modulus is negligible within hominids (Jungers and Minns, 1979; Lovejoy and Barton, 1980; Ruff, 1992; Ruff et al., 1993), an assumption supported by the discovery that the material properties of bone have been conserved over the last 475 million years (Erickson et al., 2002). With Young's modulus held constant, the second moment of area can be used alone as an accurate indicator of the relative bending strength of a bone.

The moment of inertia of a beam is a description of the distribution of material around the neutral axis of the beam (the longitudinal axis that is neither compressed nor stretched when the beam is bent). Since the exact location of the neutral axis cannot be determined on dry bone specimens, the location of the neutral axis in any dry bone cross section is conventionally assumed to coincide with the centroid of the cross section.

With the help of calculus and specialized image analysis software, all bone in the cross section can be broken into infinitesimally small portions. The area of these infinitesimally small portions can be determined mathematically, and the distance of each of these areas from an arbitrary line passing through the neutral axis can be determined. The summation of the products of these areas and their squared distances yields the moment of inertia with respect to the arbitrary line. If these calculations are done for every orientation of the arbitrary line (from 0° to 180°), the greatest sum will represent I_{max} , which is effectively a measure of the bone's greatest resistance to

bending. *Theta* (θ) indicates the orientation of the greatest resistance to bending, I_{min} , which is always perpendicular to I_{max} , is the bone's lowest bending resistance. The sum of I_{max} and I_{min} is J , the **polar moment of inertia**, a measure of the bone's resistance to twisting (or axial torsion).

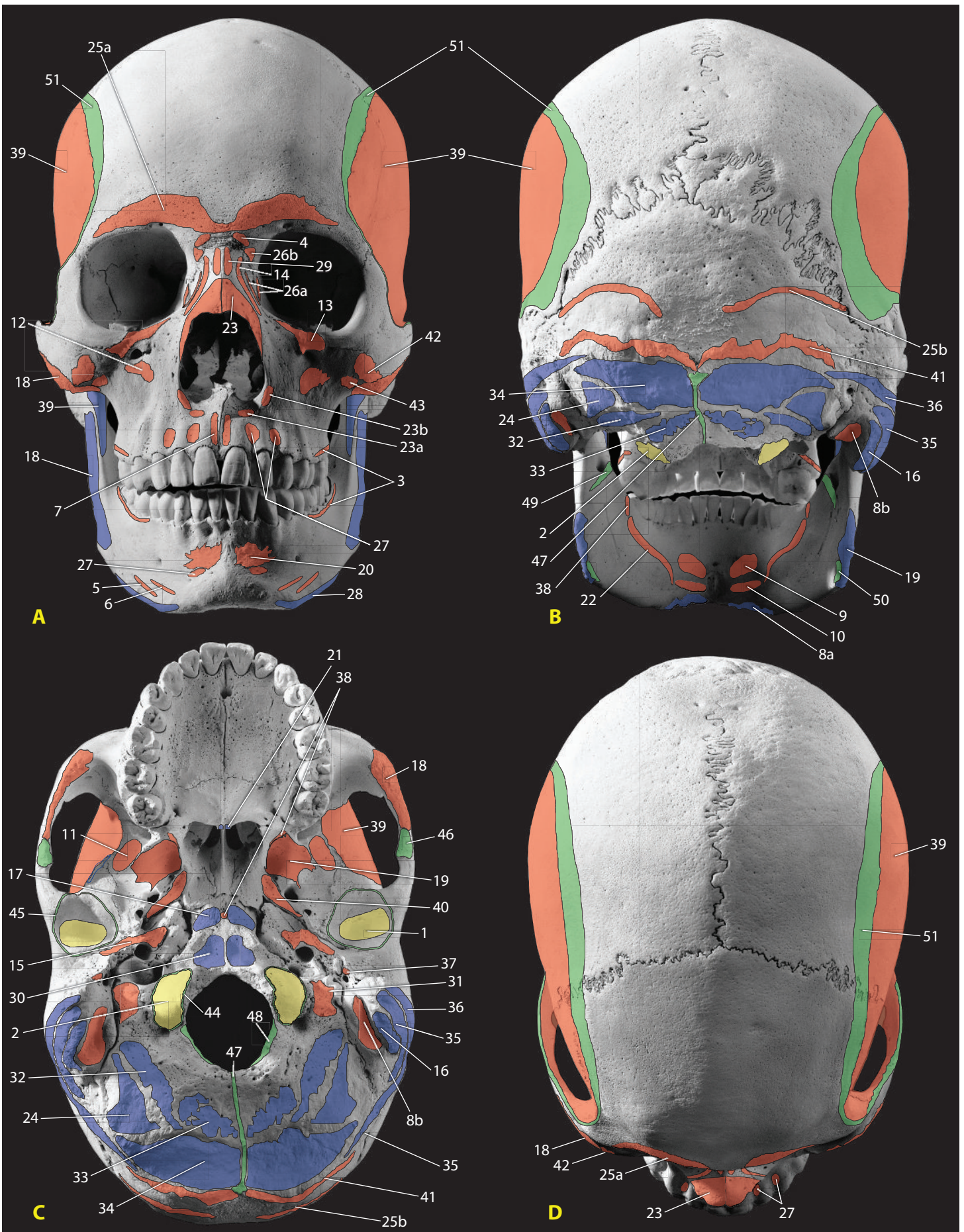
Newton's **Third Law of Motion** states that for every action, there is an equal but opposite reaction. The Third Law applies to living systems as well as inanimate objects. In walking and running, propulsion of the body is produced by contracting muscles of the lower limb. Plantarflexor muscles, originating on the posterior side of the lower leg and attaching to the calcaneus via the Achilles tendon, contract at the same time as the quadriceps, the primary extensor of the lower leg. The coordinated action of these two muscle groups straightens the leg and plantarflexes the foot at the ankle, producing a strong force that is delivered backwards to the ground through the toes. As predicted by Newton's Third Law, this "action" force is met by an equal but opposite **ground reaction force**, and forward motion results. The same type of interaction of forces continues upwards through the body, with the talus exerting a force on the tibia (and being met by a reaction force), the tibia exerting a force on the femur (and being met by a reaction force), and so on. These reaction forces across joints are called **joint reaction forces**.

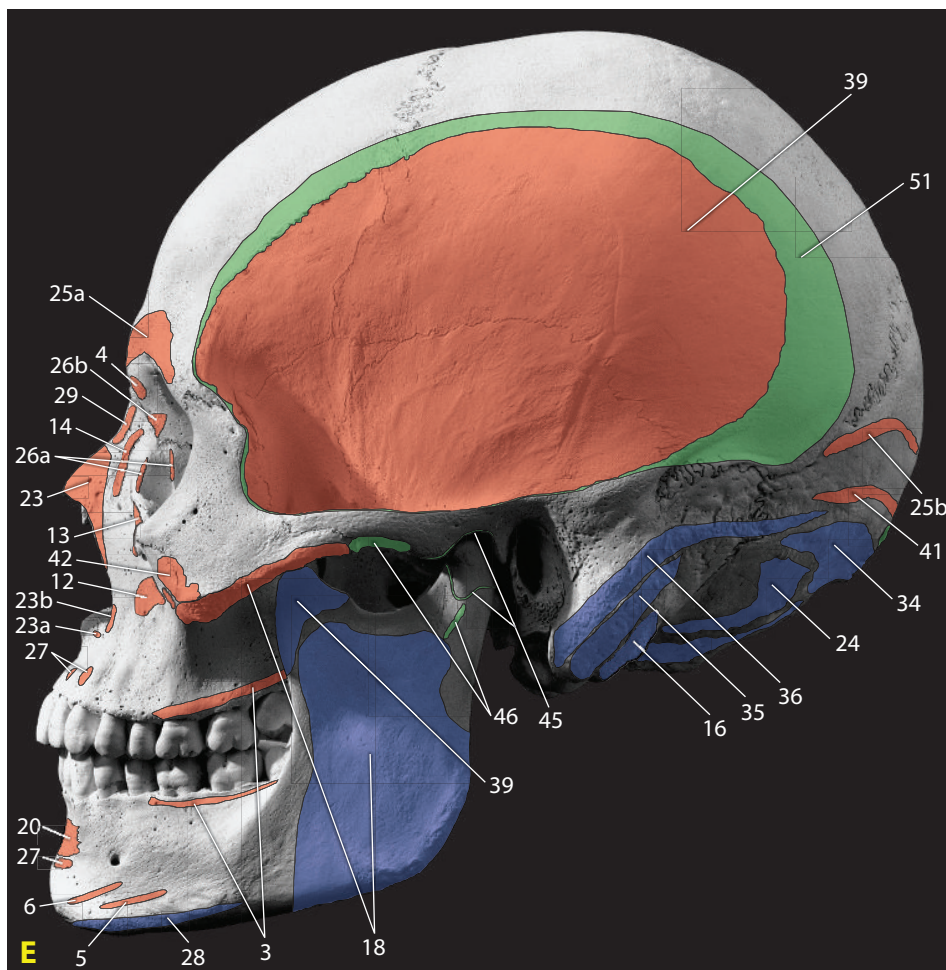
For joints that experience high (or repetitive) joint reaction forces (e.g., the knee), the articular ends are expanded, providing additional area across which the forces are distributed. These articular ends are thin-shelled structures, maintaining their strength and rigidity through a complex network of reinforcing rods and plates—the trabeculae of cancellous bone. Consult the longitudinal section shown in Figure 3.6 to see the relationship between trabeculae and an expanded articular end of a bone with high joint reaction forces.

14.3 Interpreting the Figures

For the elements on the following pages, the locations of all muscular, tendinous, and ligamentous attachments, and of all articulations with other elements are given specifically for the same individual whose postcrania were used to illustrate Chapters 3–13. The hand and foot are not presented for reasons of space, but students are encouraged to use these conventions and imagine how soft tissue attachments would map onto Figures 10.2–10.3 and 13.2–13.5 for the hand and foot (and Figure 6.1 for the hyoid, Figures 8.6–8.9 for the scapula, Figure 7.1 for the sternum, Figures 7.3–7.5 for the ribs, Figures 6.2–6.3 and 6.7 for the vertebrae, Figures 11.1–11.4 and 11.6 for the sacrum and coccyx, and Figure 12.9 for the patella). When there is sufficient surface evidence of original extent, the soft tissue attachments are rendered as accurately as possible. In many cases, however, at least part of the extent of an attachment had to be estimated.

For each soft anatomical structure illustrated, numerous anatomical atlases (Abrahams et al., 2007; Agur and Dalley, 2008; Clemente, 2010; Dauber and Feineis, 2007; Gilroy et al., 2008; Netter, 2006, 2010; Rohen et al., 2006, 2010; Schünke et al., 2006) were consulted to ascertain the range of attachment locations and sizes considered typical and/or anatomically normal. This range of typical locations and extents was then reconciled with the specific landmarks, morphology, and surface characteristics of the particular element being illustrated. This work was done on high-resolution digital images of the element, usually at magnifications of 600% to 4000% of natural size, to be able to precisely locate the boundaries of each attachment site. The attachment sites illustrated in this chapter are not necessarily typical or even anatomically normal. They correspond to the specific anatomy of this one individual. For illustrations of typical anatomy, refer to any of the modern anatomical atlases listed in the Suggested Further Readings at the end of this chapter.





17. Longus capitis
18. Masseter
19. Medial pterygoideus
20. Mentalis
21. Musculus uvulae
22. Mylohyoid
23. Nasalis
 - a. Alar part
 - b. Transverse part
24. Obliquus capitis superior
25. Occipitofrontalis
 - a. frontal belly (frontalis)
 - b. occipital belly (occipitalis)
26. Orbicularis oculi
 - a. lacrimal parts
 - b. orbital part
27. Orbicularis oris
28. Platysma
29. Procerus
30. Rectus capitis anterior
31. Rectus capitis lateralis
32. Rectus capitis posterior major
33. Rectus capitis posterior minor
34. Semispinalis capitis
35. Splenius capitis
36. Sternocleidomastoideus
37. Stylopharyngeus
38. Superior pharyngeal constrictor
39. Temporalis
40. Tensor veli palatini
41. Trapezius
42. Zygomaticus major
43. Zygomaticus minor

14.4 Cranium and Mandible

Views shown: A) anterior/ norma frontalis, B) posterior/ norma occipitalis, C) inferior/ norma basilaris, D) superior/ norma verticalis, and E) lateral/ norma lateralis, presented at 80% of natural size. Due to space constraints, many cranial ligaments are not shown. Additionally, attachments of the muscles of the eye and of the ear, and some of the muscles of the styloid process are not shown.

Articular surfaces (yellow)

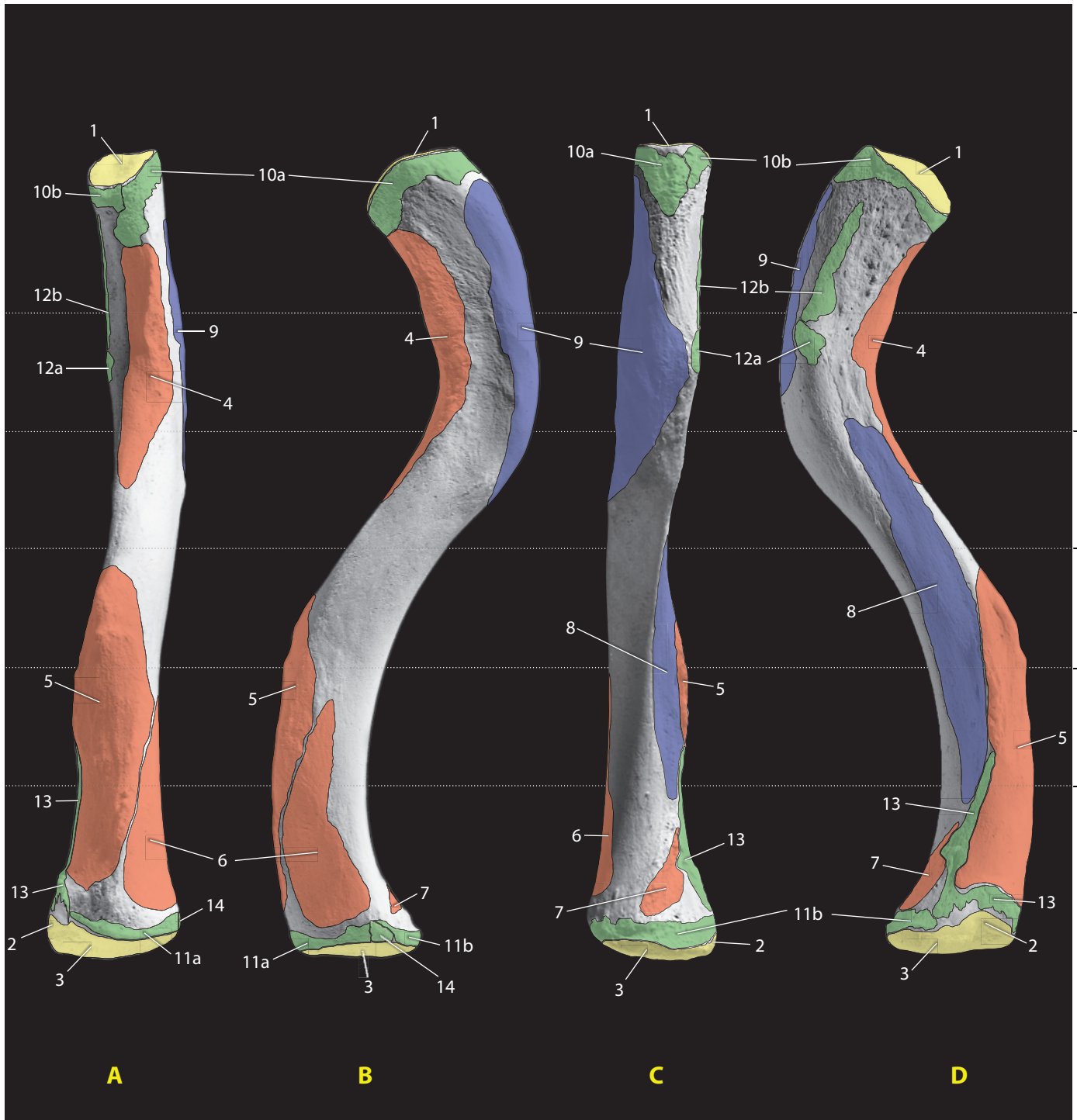
1. Glenoid fossa (for mandible)
2. Occipital condyle (for C-1)

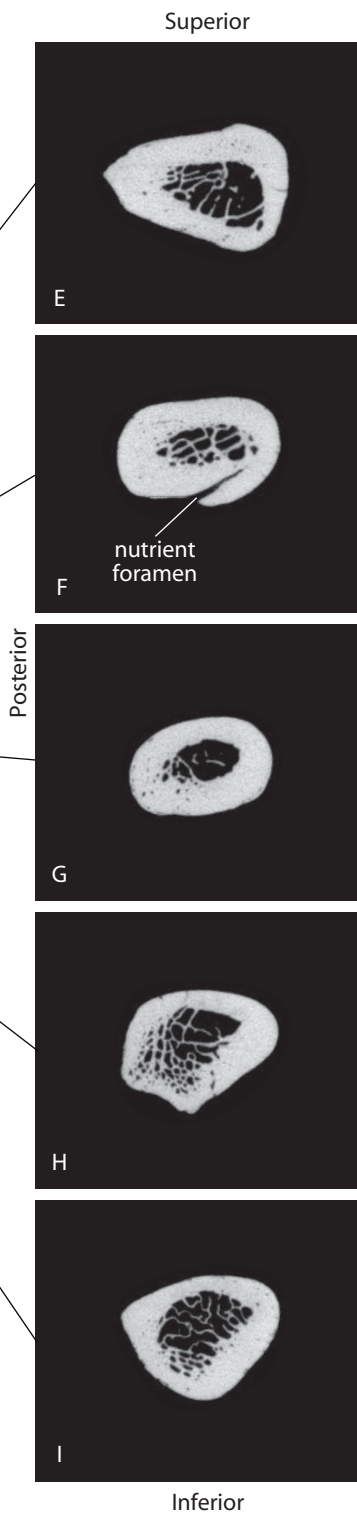
Muscular attachments (origins: red, insertions: blue)

3. Buccinator
4. Corrugator supercilii
5. Depressor anguli oris
6. Depressor labii inferioris
7. Depressor septi nasi
8. Digastric
 - a. Anterior belly
 - b. Posterior belly
9. Genioglossus
10. Geniohyoid
11. Lateral pterygoideus
12. Levator anguli oris
13. Levator labii superioris
14. Levator labii superioris alaeque nasi
15. Levator veli palatini
16. Longissimus capitis

Other attachments (green)

44. Joint capsule (atlanto-occipital joint)
45. Joint capsule (temporomandibular joint)
46. Lateral ligament
47. Nuchal ligament
48. Posterior atlanto-occipital membrane
49. Sphenomandibular ligament
50. Stylomandibular ligament
51. Temporal fascia





14.5 Clavicle

Views shown: A) anterior, B) superior, C) posterior, and D) inferior, presented at natural size. The CT sections are shown at approximately 1.25× natural size.

Articular surfaces (yellow)

1. Acromioclavicular articulation
2. First costal cartilage
3. Manubrioclavicular articulation

Muscular origins (red)

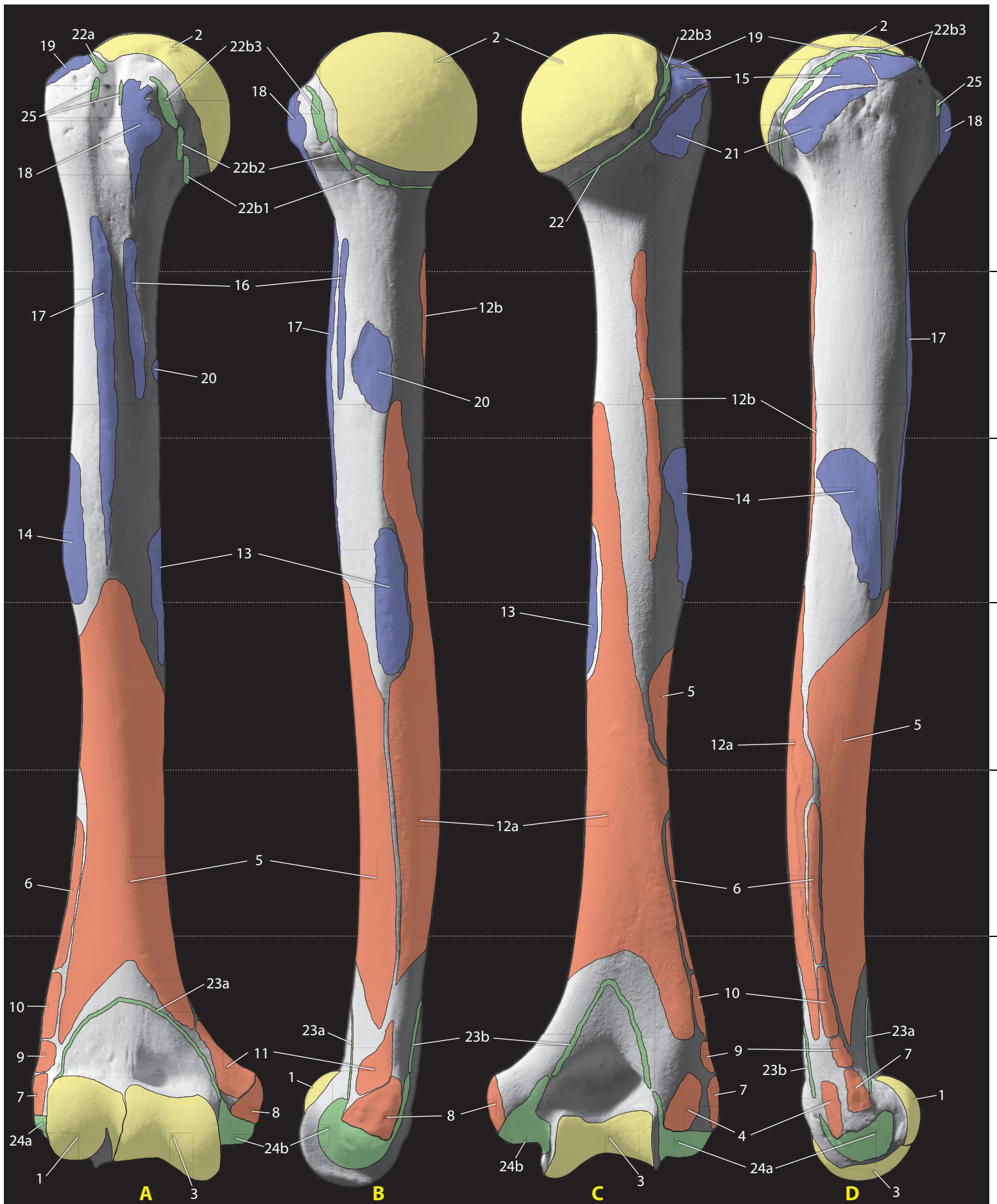
4. Deltoideus
5. Pectoralis major
6. Sternocleidomastoideus
7. Sternohyoid

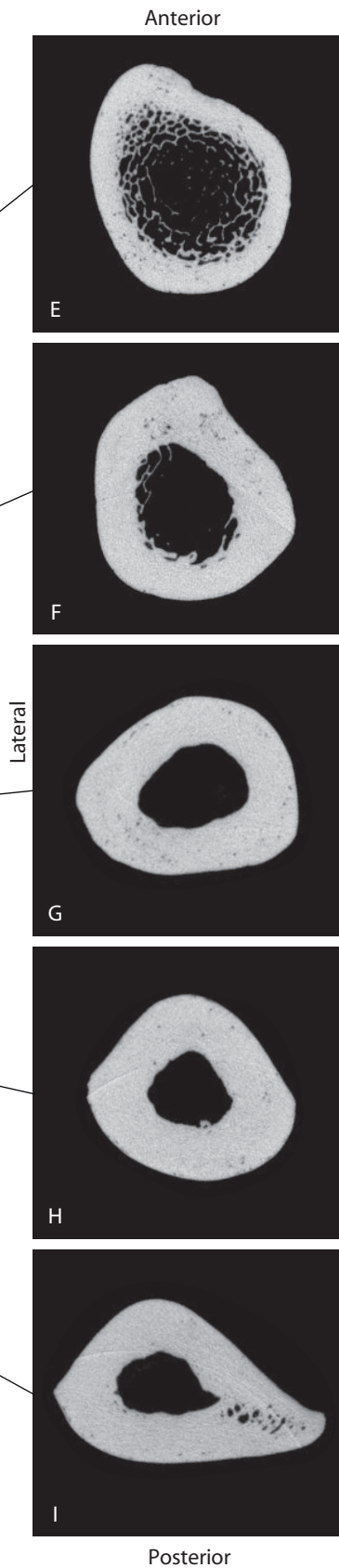
Muscular insertions (blue)

8. Subclavius
9. Trapezius

Other attachments (green)

10. Capsular ligaments (acromioclavicular joint)
 - a. Superior acromioclavicular ligament
 - b. Inferior acromioclavicular ligament
11. Capsular ligaments (sternoclavicular joint)
 - a. Anterior sternoclavicular ligament
 - b. Posterior sternoclavicular ligament
12. Coracoclavicular ligament
 - a. Conoid ligament
 - b. Trapezoid ligament
13. Costoclavicular (rhomboid) ligament
14. Interclavicular ligament





14.6 Humerus

Views shown: A) anterior, B) medial, C) posterior, and D) lateral, presented at 80% of natural size. The CT sections are shown at approximately 1.25 × natural size.

Articular surfaces (yellow)

1. Capitulum (for radial head)
2. Head (for scapular glenoid fossa)
3. Trochlea (for ulnar semilunar notch)

Muscular origins (red)

4. Anconeus
5. Brachialis
6. Brachioradialis
7. Common origin of extensors
8. Common origin of flexors
9. Extensor carpi radialis brevis
10. Extensor carpi radialis longus
11. Pronator teres
12. Triceps brachii
 - a. medial head
 - b. lateral head

Muscular insertions (blue)

13. Coracobrachialis
14. Deltoideus
15. Infraspinatus
16. Latissimus dorsi
17. Pectoralis major
18. Subscapularis
19. Supraspinatus
20. Teres major
21. Teres minor

- b. Glenohumeral ligaments
 - b1. inferior glenohumeral lig.
 - b2. middle glenohumeral lig.
 - b3. superior glenohumeral lig.

23. Capsular ligaments (elbow)

- a. anterior
- b. posterior

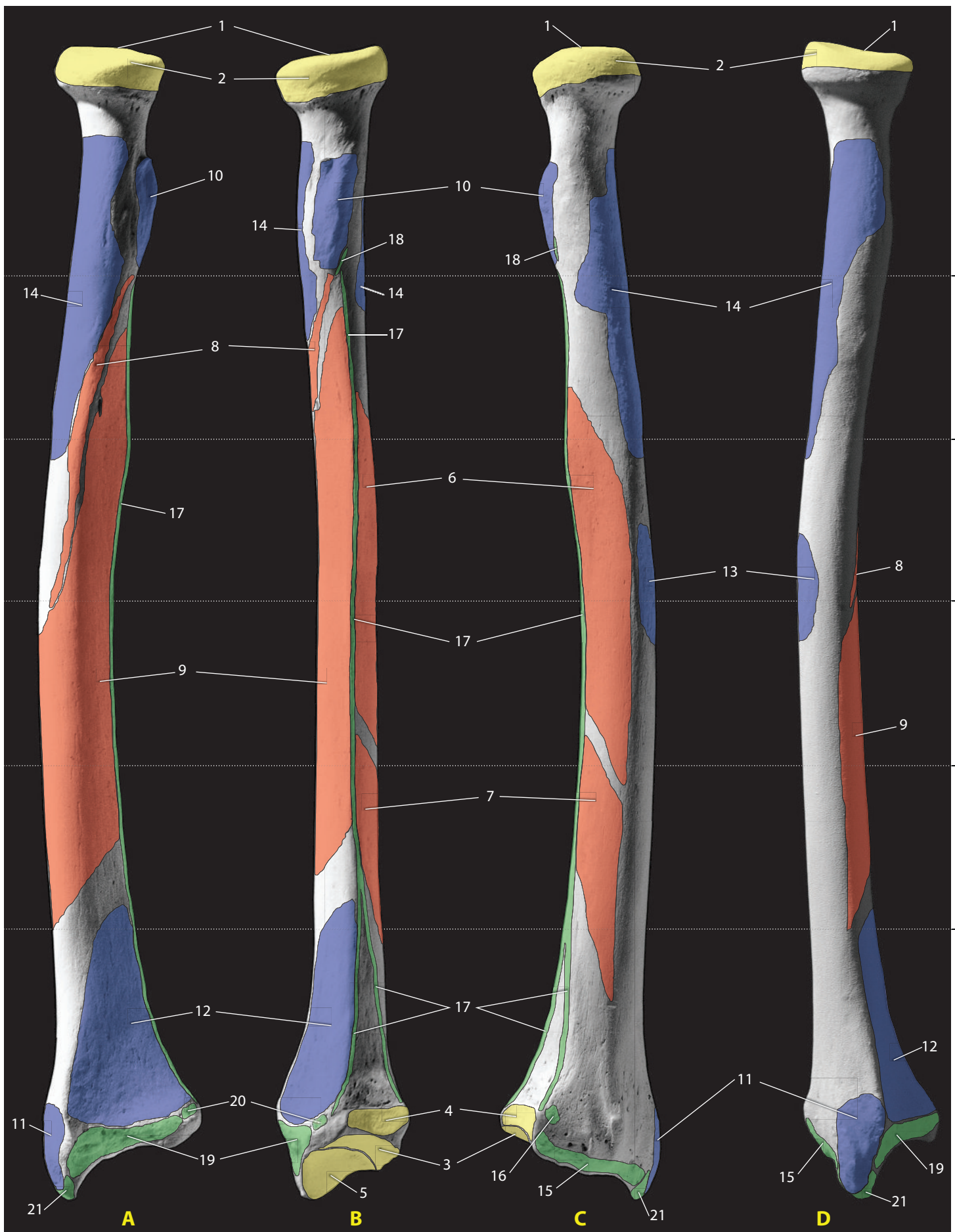
24. Collateral ligaments


- a. Radial (lateral) collateral ligament
- b. Ulnar (medial) collateral ligament

25. Transverse humeral ligament

Other attachments (green)

22. Capsular ligaments (shoulder)
 - a. Coracohumeral ligament





14.7 Radius

Views shown: A) anterior, B) medial, C) posterior, and D) lateral, presented at 90% of natural size. The CT sections are shown at approximately 1.25× natural size.

Articular surfaces (yellow)

1. Articular fovea (for humerus)
2. Articular circumference (for ulna)
3. Lunate facet (for lunate)
4. Ulnar notch (for ulna)
5. Scaphoid facet (for scaphoid)

Muscular origins (red)

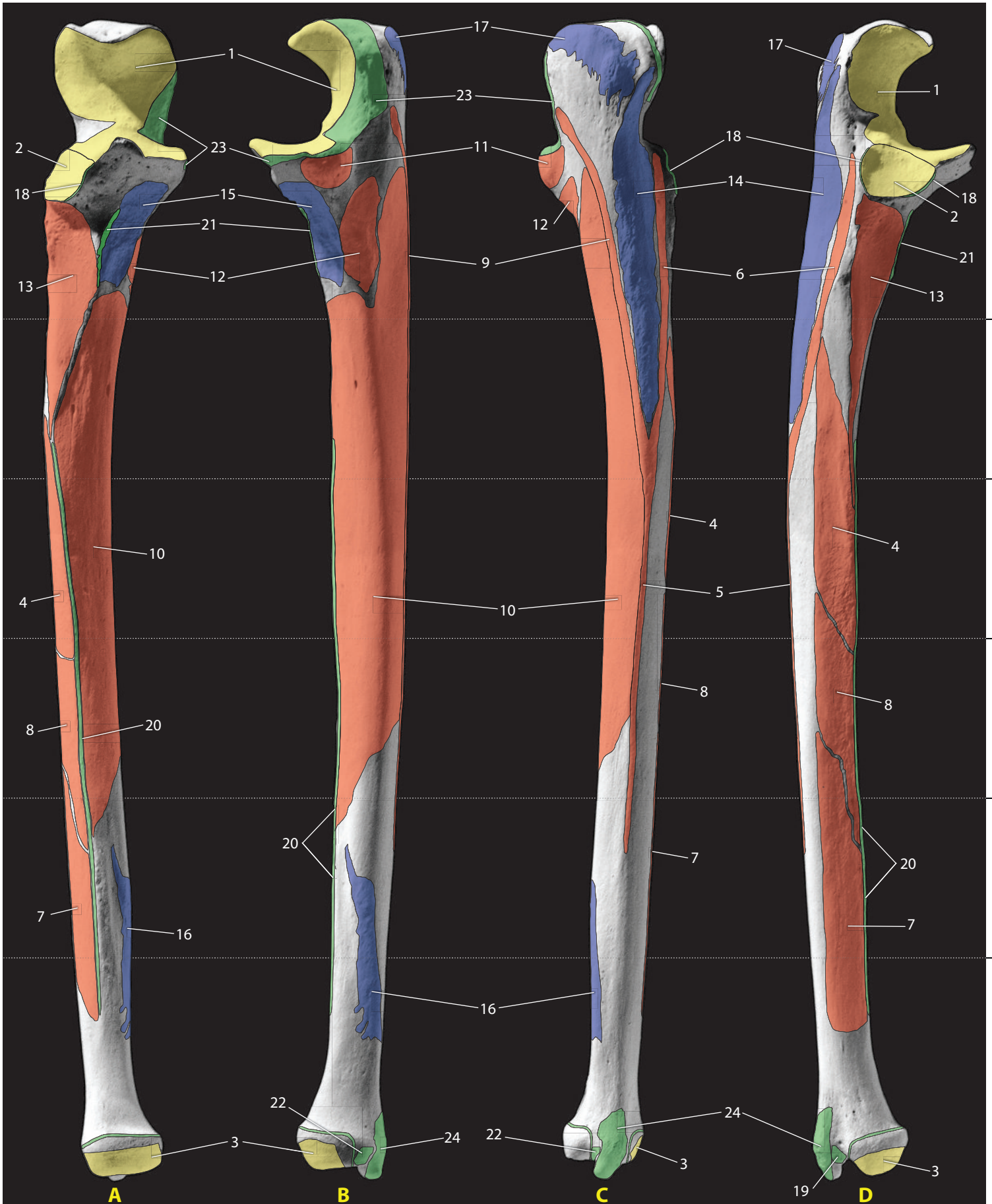6. Abductor pollicis longus
7. Extensor pollicis brevis
8. Flexor digitorum superficialis
9. Flexor pollicis longus

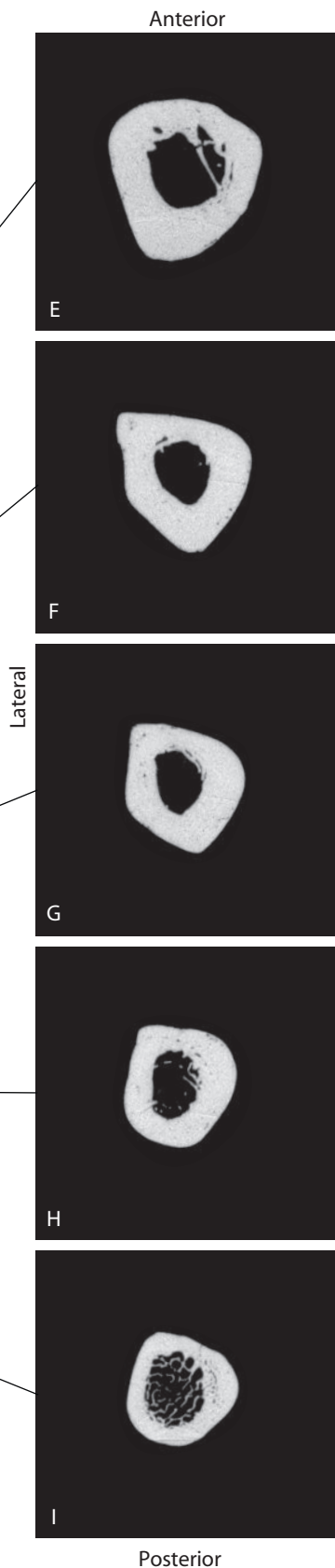
Muscular insertions (blue)

10. Biceps brachii
11. Brachioradialis
12. Pronator quadratus
13. Pronator teres
14. Supinator

Other attachments (green)

15. Dorsal radiocarpal ligament
16. Dorsal radioulnar ligament
17. Interosseous membrane
18. Oblique cord
19. Palmar radiocarpal ligament
20. Palmar radioulnar ligament
21. Radial collateral ligament





14.8 Ulna

Views shown: A) anterior, B) medial, C) posterior, and D) lateral, presented at 85% of natural size. The CT sections are shown at approximately 1.25× natural size.

Articular surfaces (yellow)

1. Trochlear surface (for humerus)
2. Radial notch (for radius)
3. Articular circumference (for radius)

Muscular origins (red)

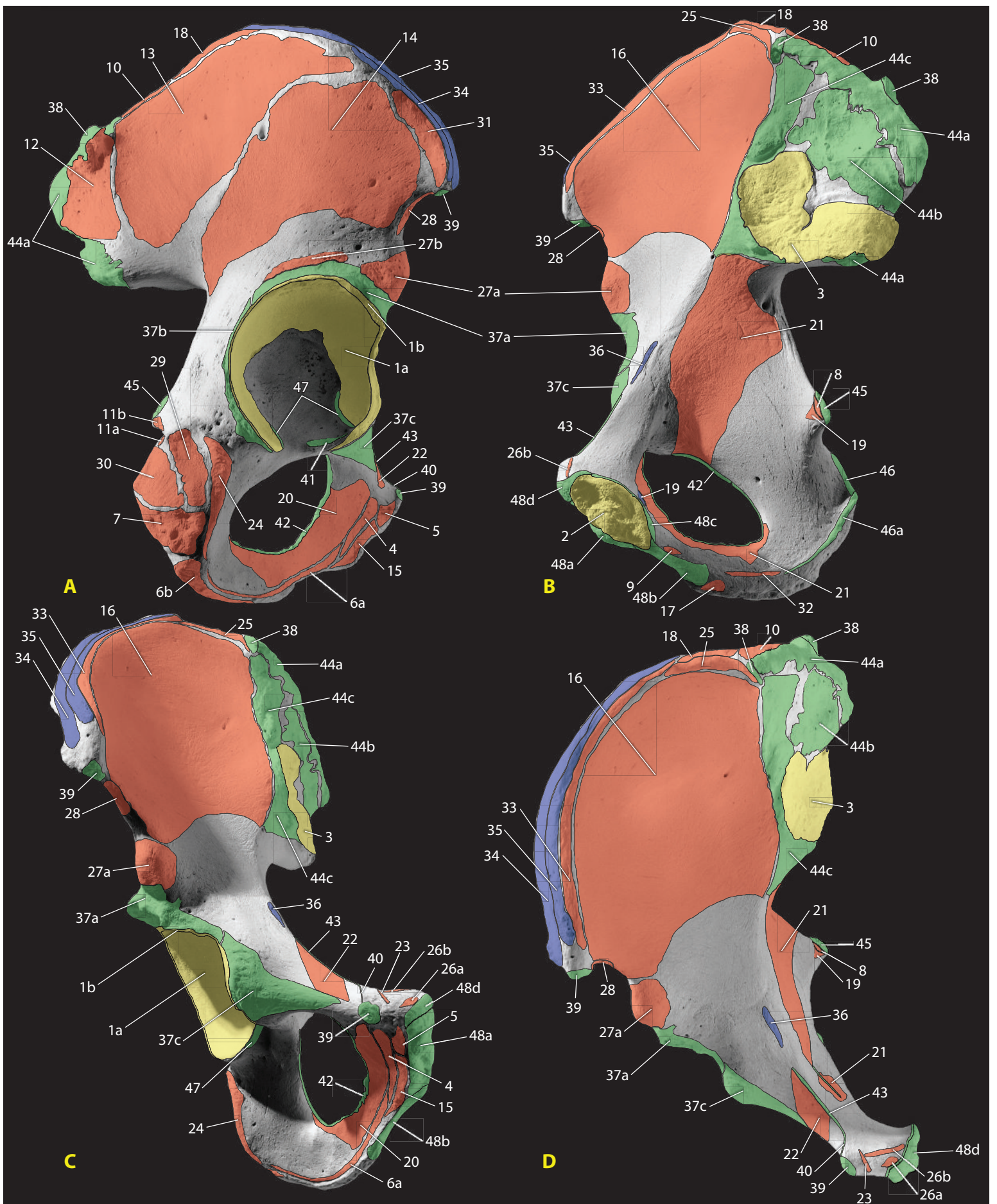
4. Abductor pollicis longus
5. Common origin (aponeurosis) of flexor digitorum profundus, flexor carpi ulnaris, and extensor carpi ulnaris
6. Extensor carpi ulnaris
7. Extensor indicis
8. Extensor pollicis longus
9. Flexor carpi ulnaris
10. Flexor digitorum profundus
11. Flexor digitorum superficialis
12. Pronator teres (ulnar head)
13. Supinator

Muscular insertions (blue)

14. Anconeus
15. Brachialis
16. Pronator quadratus
17. Triceps brachii

Other attachments (green)

18. Anular ligament
19. Dorsal radioulnar ligament
20. Interosseous membrane
21. Oblique cord
22. Palmar radioulnar ligament
23. Ulnar (medial) collateral lig. (prox.)
24. Ulnar (medial) collateral lig. (dist.)



14.9 Os Coxae

Views shown: A) lateral, B) medial, C) anteroinferior, and D) anterosuperior, presented at 60% of natural size.

Articular surfaces (yellow)

1. Acetabulum (for femur)
 - a. Lunate surface
 - b. Acetabular labrum
2. Pubic symphysis (for os coxae)
3. Auricular surface (for sacrum)

Muscular origins (red)

4. Adductor brevis
5. Adductor longus
6. Adductor magnus
 - a. Adductor portion
 - b. Hamstring portion
7. Biceps femoris (long head)
8. Coccygeus
9. Compressor urethrae
10. Erector spinae
11. Gemelli
 - a. Gemellus inferior
 - b. Gemellus superior
12. Gluteus maximus
13. Gluteus medius
14. Gluteus minimus
15. Gracilis
16. Iliacus
17. Ischiocavernosus
18. Latissimus dorsi
19. Levator ani
20. Obturator externus
21. Obturator internus
22. Pectineus
23. Pyramidalis
24. Quadratus femoris
25. Quadratus lumborum
26. Rectus abdominis
 - a. Medial head
 - b. Lateral head
27. Rectus femoris
 - a. Straight head

b. Reflected head

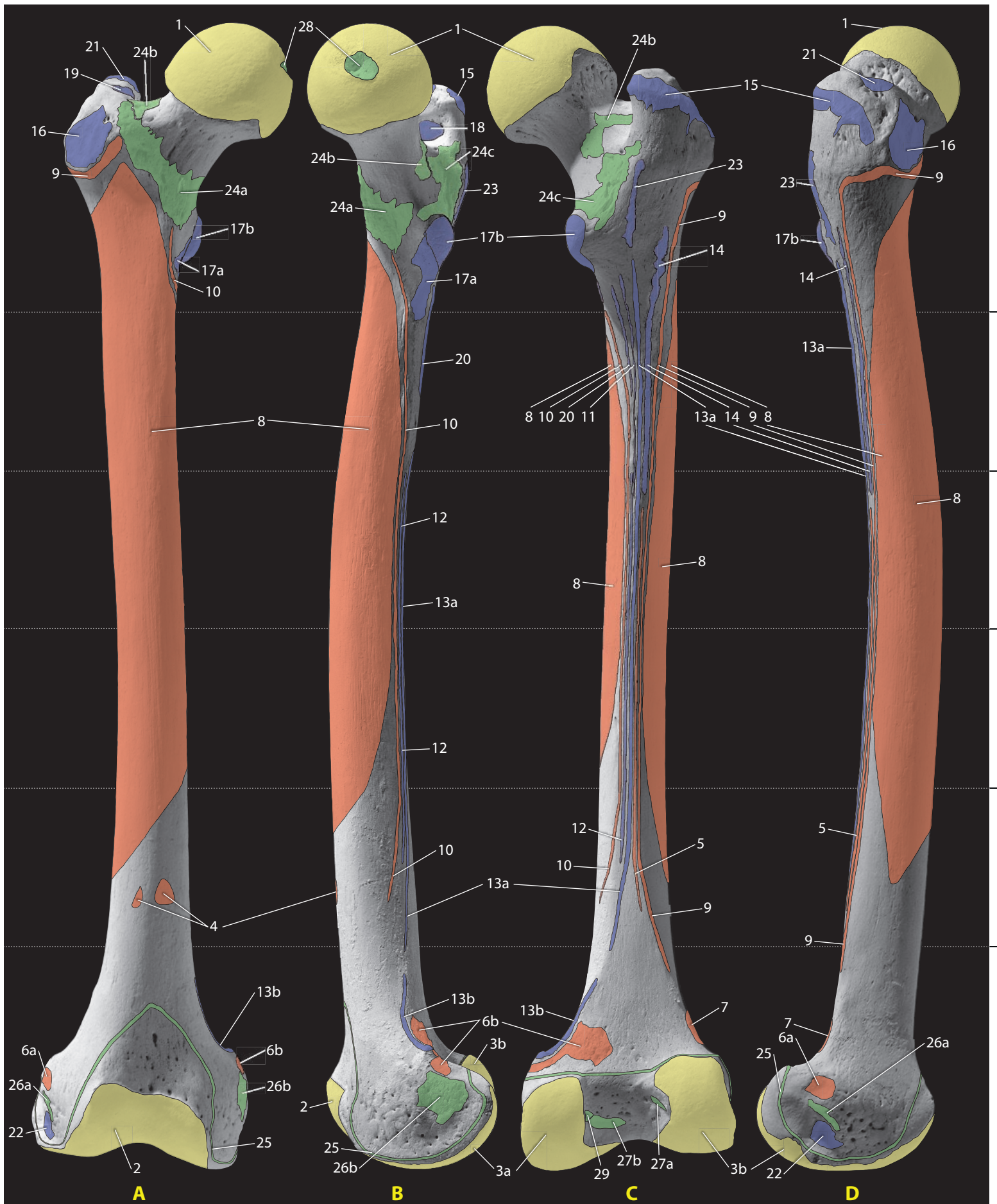
28. Sartorius
29. Semimembranosus
30. Semitendinosus
31. Tensor fascia latae
32. Transverse perinei
33. Transversus abdominis

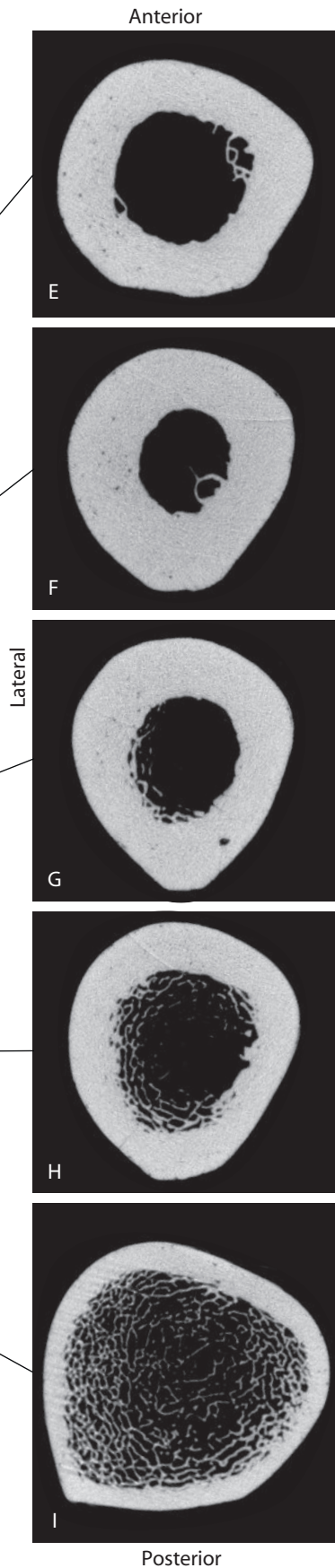
Muscular insertions (blue)

34. External oblique
35. Internal oblique
36. Psoas minor

Other attachments (green)

37. Capsular ligaments (hip)
 - a. Iliofemoral ligament
 - b. Ischiofemoral ligament
 - c. Pubofemoral ligament
38. Iliolumbar ligament
39. Inguinal ligament
40. Lacunar ligament
41. Ligamentum teres
42. Obturator membrane
43. Pectineal ligament
44. Sacroiliac ligaments
 - a. Dorsal sacroiliac ligament
 - b. Interosseous sacroiliac ligament
 - c. Ventral sacroiliac ligament
45. Sacrospinous ligament
46. Sacrotuberous ligament
 - a. Falciform process of ligament
47. Transverse acetabular ligament
48. Symphyseal ligaments
 - a. Anterior symphyseal ligament
 - b. Inferior (arcuate) pubic ligament
 - c. Posterior symphyseal ligament
 - d. Superior pubic ligament





14.10 Femur

Views shown: A) anterior, B) medial, C) posterior, and D) lateral, presented at 40% of natural size. The CT sections are shown at approximately 1.25× natural size.

Articular surfaces (yellow)

1. Head (for os coxae)
2. Patellar surfaces (for patella)
3. Femoral condyles (for tibia)
 - Lateral condyle
 - Medial condyle

Muscular origins (red)

4. Articularis genu
5. Gastrocnemius
 - a. Lateral head
 - b. Medial head
6. Plantaris
7. Vastus intermedius
8. Vastus lateralis
9. Vastus medialis

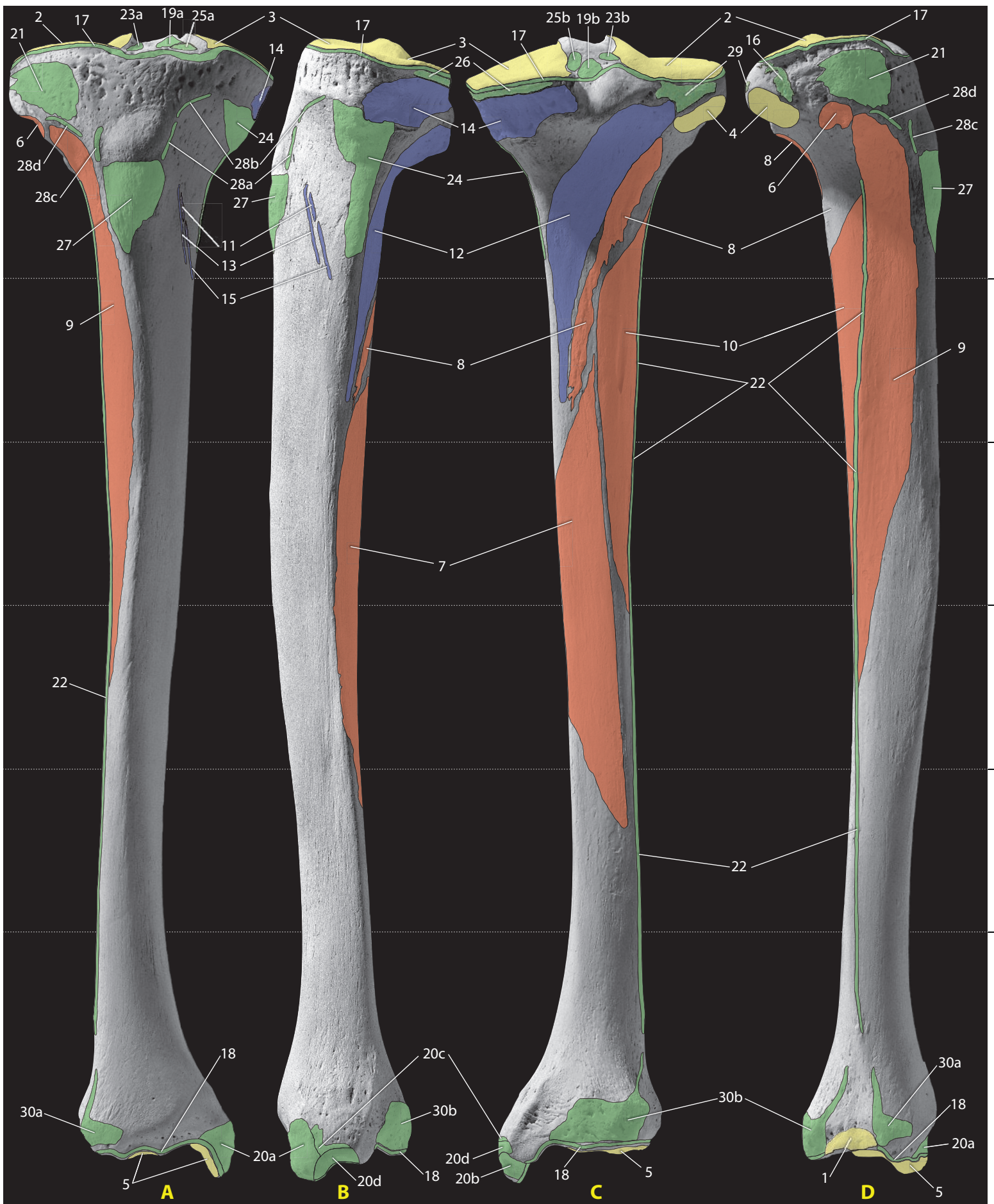
Muscular insertions (blue)

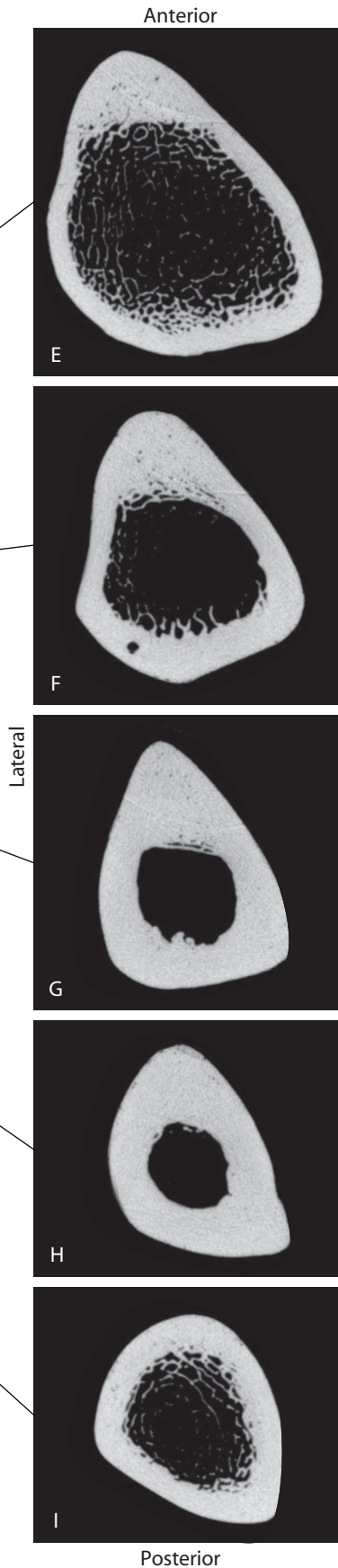
10. Adductor brevis
11. Adductor longus
12. Adductor magnus
 - a. Adductor portion
 - b. Hamstring portion
13. Biceps femoris
14. Gluteus maximus
15. Gluteus medius
16. Gluteus minimus
17. Iliopsoas
 - a. Iliacus
 - b. Psoas major
18. Obturator externus
19. Obturator internus and gemelli
20. Pectineus

21. Piriformis
22. Popliteus
23. Quadratus femoris

Other attachments (green)

24. Capsular ligaments (hip)
 - a. Iliofemoral ligament
 - b. Ischiofemoral ligament
 - c. Pubofemoral ligament
25. Capsular ligaments (knee)
26. Collateral ligaments
 - a. Fibular (lateral) collateral ligament
 - b. Tibial (medial) collateral ligament
27. Cruciate ligaments
 - a. Anterior cruciate ligament
 - b. Posterior cruciate ligament
28. Ligamentum teres
29. Posterior meniscofemoral ligament





14.11 Tibia

Views shown: A) anterior, B) medial, C) posterior, and D) lateral, presented at approximately 80% of natural size. The CT sections are shown at approximately $1.25\times$ natural size.

Articular surfaces (yellow)

1. Distal fibular art. surface (for fibula)
2. Lateral condyle (for femur)
3. Medial condyle (for femur)
4. Superior articular facet (for fibula)
5. Talar articular surface (for talus)

Muscular origins (red)

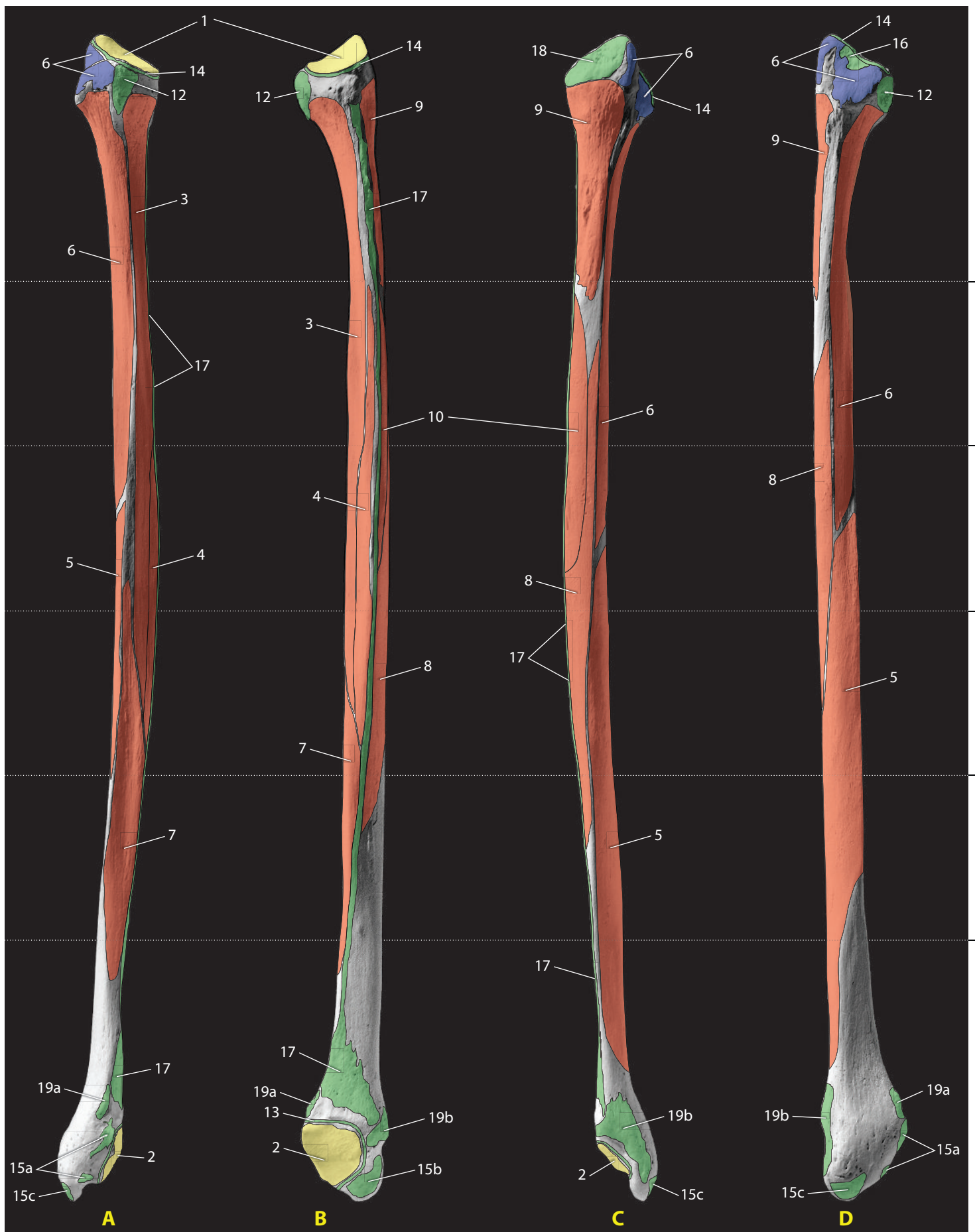
6. Extensor digitorum longus
7. Flexor digitorum longus
8. Soleus
9. Tibialis anterior
10. Tibialis posterior

Muscular insertions (blue)

11. Gracilis
12. Popliteus
13. Sartorius
14. Semimembranosus
15. Semitendinosus
21. Iliotibial tract
22. Interosseous membrane
23. Lateral meniscus
 - a. Anterior attachment
 - b. Posterior attachment
24. Medial (tibial) collateral ligament
25. Medial meniscus
 - a. Anterior attachment
 - b. Posterior attachment

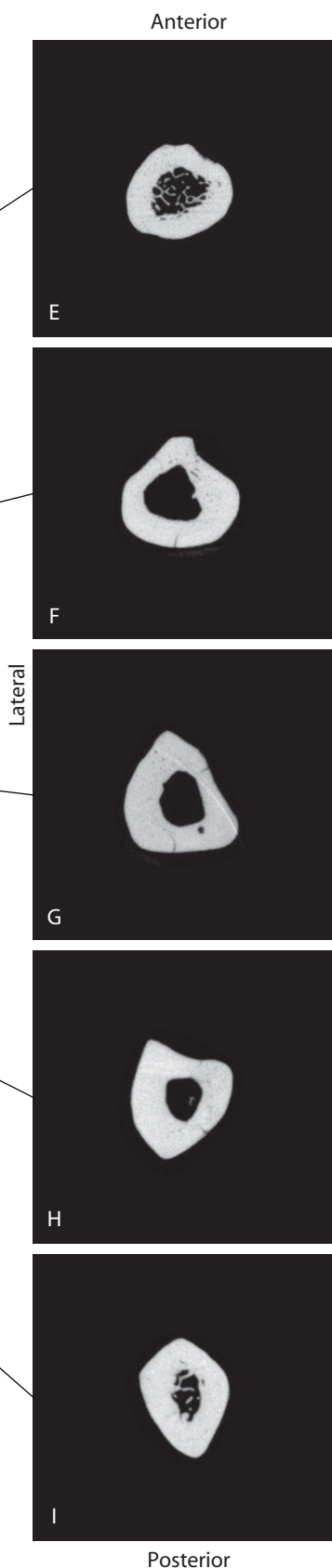
Other attachments (green)

16. Anterior ligament of fibular head
17. Capsular ligaments (knee)
18. Capsular ligaments (ankle)
19. Cruciate ligaments
 - a. Anterior cruciate ligament
 - b. Posterior cruciate ligament
20. Deltoid ligament
 - a. Anterior tibiotalar part
 - b. Posterior tibiotalar part
 - c. Tibiocalcaneal part
 - d. Tibionavicular part
26. Oblique popliteal ligament
27. Patellar ligament
28. Patellar retinacula
 - a. Medial longitudinal patellar retinaculum
 - b. Medial transverse patellar retinaculum
 - c. Lateral longitudinal patellar retinaculum
 - d. Lateral transverse patellar retinaculum
29. Posterior ligament of fibular head
30. Syndesmotic ligaments of ankle
 - a. Anterior tibiofibular ligament
 - b. Posterior tibiofibular ligament



14.12 Fibula

Views shown: A) anterior, B) medial, C) posterior, and D) lateral, presented at 50% of natural size. The CT sections are shown at approximately 1.25× natural size.



Articular surfaces (yellow)

1. Head (for tibia)
2. Malleolar artic. surface (for tibia)

Muscular origins (red)

3. Extensor digitorum longus
4. Extensor hallucis longus
5. Fibularis (peroneus) brevis
6. Fibularis (peroneus) longus
7. Fibularis (peroneus) tertius
8. Flexor hallucis longus
9. Soleus
10. Tibialis posterior

Muscular insertions (blue)

11. Biceps femoris

Other attachments (green)

12. Anterior ligament of head of fibula
13. Capsular ligaments (ankle)
14. Capsular ligaments (knee)
15. Fibular (lateral) collateral ligaments (ankle)
 - a. Anterior talofibular ligament
 - b. Posterior talofibular ligament
 - c. Calcaneofibular ligament
16. Fibular (lateral) collateral ligament (knee)
17. Interosseous membrane
18. Posterior ligament of head of fibula
19. Syndesmotic ligaments of ankle
 - a. Anterior tibiofibular ligament
 - b. Posterior tibiofibular ligament

Suggested Further Readings

Many guides to musculoskeletal anatomy are available. Some of the best of these are listed here.

Abrahams, P. H., Boon, J. M., Spratt, J. D., Hutchings, R. T., and McMinn, R. M. H. (2007) *McMinn's clinical atlas of human anatomy* (6th ed.). St. Louis, MO: Mosby/Elsevier. 386 pp. + DVD.

An atlas based on color photographs of careful cadaveric dissections.

Agur, A. M. R., and Dalley, A. F. (2008) *Grant's atlas of anatomy* (12th ed.). Philadelphia, PA: Lippincott Williams & Wilkins. 834 pp.

A classic medical school atlas to accompany dissection. Uses full-color drawings and schematic illustrations.

Clemente, C. D. (2010) *Anatomy: A regional atlas of the human body* (6th ed.). Baltimore, MD: Lippincott Williams & Williams. 752 pp.

An atlas based on color illustrations. Not a comprehensive atlas, but valued for its clarity and clinical orientation.

Dauber, W., and Feneis, H. (2007) *Pocket atlas of human anatomy, founded by Heinz Feneis* (5th ed.). New York, NY: Thieme. 545 pp.

A comprehensive pocket reference to anatomical terminology. Each two-page spread has one page of shaded line drawings with numeric labels and a one-page key to the labeled structures. Terminology is aligned with the latest international standards.

Federative Committee on Anatomical Terminology. (1998) *Terminologia Anatomica: International anatomical terminology*. New York, NY: Thieme. 292 pp + CD-ROM.

The latest international standard for anatomical terminology.

Gilroy, A. M., MacPherson, B. R., and Ross, L. M. (2008) *Atlas of anatomy*. New York, NY: Thieme. 656 pp.

A comprehensive reference atlas with highly detailed, full-color illustrations, as well as many tables and charts. Its detail, clarity, and coverage make this a must-have atlas. Terminology is aligned with the latest international standards.

Moeller, T., and Reif, E. (2009) *Atlas of sectional anatomy: The musculoskeletal system*. New York, NY: Thieme. 300 pp.

Presents MRI scans alongside colored interpretive diagrams of those sections.

Netter, F. H. (2010) *Atlas of human anatomy* (5th ed.). Philadelphia, PA: Saunders/Elsevier. 624 pp.

A popular medical school atlas using full-color drawings and schematic illustrations, and valued for its ease of use and accessibility.

Putz, R., and Pabst, R. (Eds.) (2009) *Sobotta atlas of anatomy* (14th ed.). Munich, Germany: Urban & Fischer Verlag/Elsevier. 842 pp.

An atlas based on color illustrations and supplemented by radiographs, CT scans, and MRI scans. Terminology is aligned with the latest international standards.

Rohen, J. W., Yokochi, C., and Lütjen-Drecoll, E. (2010) *Color atlas of anatomy: A photographic study of the human body* (7th ed.). Philadelphia, PA: Lippincott Williams & Wilkins. 556 pp.

An atlas based on color photographs of careful cadaveric dissections, supplemented by MRI, CT, and endoscopic images, and by schematic drawings.

Schünke, M., Ross, L. M., Lamperti, E. D., Schulte, E., Schumacher, U., Rude, J., Voll, M., and Wesker, K. (2006) *Thieme atlas of anatomy: General anatomy and musculoskeletal system*. New York, NY: Thieme. 560 pp.

Beautifully illustrated volume focusing on neuromusculoskeletal anatomy.

Chapter 15

FIELD PROCEDURES FOR SKELETAL REMAINS

HUNDREDS OF STUDIES about human osteology are published each year, ranging from announcements of fossil discoveries (*eg.*, White et al., 2009) to comprehensive treatments involving multiple populations (*eg.*, Larsen, 2006). All these studies begin with fieldwork. This chapter introduces procedures useful in recovering skeletal material. The chapter is organized in an approximately chronological manner. We first review aspects of discovery, involving techniques of retrieval and excavation. Then we discuss the transport of skeletal material. Laboratory procedures and reporting are covered in Chapter 16.

Common sense is critical in every aspect of osteological analysis, whether in the field or in the laboratory. If there is any one overriding rule, it is this: *think twice before you act*. There is no single formula, recipe, or procedure to apply in every field situation. There are simply too many different discovery contexts, and there is too much variation in preservation involving osteological remains. Cemetery excavation is different from isolated skeleton excavation; fossil bones are different from modern ones; forensic cases are different from archaeological projects; and waterlogged burial conditions are different from mummified remains in the driest deserts. There are, however, some general principles that apply in most instances where skeletal remains are concerned.

In forensic investigations involving osteological remains, there are usually official government protocols that must be followed. For example, the Joint POW/MIA Accounting Command (JPAC, known until November, 2003, as CILHI, the Central Identification Laboratory, Hawaii), the Armed Forces Medical Examiner (Armed Forces Institute of Pathology; AFIP), and the Federal Bureau of Investigation all use written guidelines for the handling of human remains. Often called “SOPs,” these are Standard Operating Procedures that govern how osteological materials are treated by personnel. Usually these remains (usually defined as any human biological tissue that is not normally or voluntarily shed) constitute evidence. The purpose of formalized procedures is to ensure the integrity, maintenance, and security of that evidence. The procedures often included in SOPs relate to scenes, sampling, laboratories, reporting, storage, equipment, and safety. The osteologist should become familiar with these official protocols and procedures whenever involved in a forensic investigation. Skinner and colleagues (2003) provide very useful and comprehensive guidelines for osteological work in modern forensic settings, particularly those involving mass graves, and Blau and Ubelaker’s (2009) book provides a wide overview of osteological forensics.

15.1 Search

Osteological remains may be discovered in forensic, archaeological, or paleontological contexts either as a result of intentional professional or amateur survey, or as a result of accidental discovery. Intentional search methodologies vary widely, from paleontological expeditions to murder or missing person investigations. Sometimes the search is large-scale, aimed at recovery of scattered hominid remains in large fossil fields such as Ethiopia's Middle Awash study area (see Chapter 28). Other times, the search can be very localized, as in the charred rubble of the Branch Davidian Compound in Texas (Owsley et al., 1995), or on a larger scale, as in the search for military MIAs within decades-old craters created by high-speed military aircraft impact (Hoshow, 1998). The application of a variety of remote-sensing technologies to forensic investigations is reviewed by Davenport (2001) and Buck (2003), archaeological survey methods are reviewed by Banning (2002), and Parker Pearson (2001) gives a cross-cultural overview of the archaeology of death and burial. The edited volume by Adams and Byrd (2008) presents a wide variety of case studies and protocols involved with recovery, analysis, and reporting of commingled human remains in different contexts.

Sometimes remains from archaeological or historical cemetery contexts may be brought to the attention of law enforcement agents or medical examiners as a result of vandalism or natural causes (Berryman et al., 1991). Other times, forensic osteologists are involved in the search for clandestine graves using methods ranging from aerial photographs to trained scent-detection dogs (France et al., 1992, Komar, 1999). Of course, not all searches result in discovery, and many paleontologists return empty-handed. Garrison (2003) provides a useful, broad overview of geoarchaeological contexts in which virtually all osteological remains might be recovered, and Connor and Scott (2001), Haglund (2001), Crist (2001), and Owsley (2001) review the ways in which archaeology can assist in forensic investigation. Steadman (2009) provides an overview of searching in forensic anthropology. Search methods will vary widely in osteology depending on the unique context of each case, but once discovery is made, a general series of steps in the assessment, documentation, extraction, and transport of the remains is set in motion.

15.2 Discovery

Skeletal remains are often found by accident. For example, hikers and construction crews often find osteological material. When they do, they usually report it to local law-enforcement authorities. There are many more dog, horse, cow, and goat bones than human bones on the surface of most landscapes, and these are often mistaken for human bones by laypersons and amateurs. A general rule for the practicing human osteologist is to assume that law-enforcement personnel who often first encounter such remains (including, in some cases, coroners) are not qualified to render accurate opinions on isolated, fragmentary skeletal remains. For example, we have seen cases in which a pet rabbit that perished in a trailer home fire was identified by the official coroner as a human infant, or where a portion of a melted fiberglass shower enclosure was identified as a charred human 'hip bone.' Forensic human osteologists usually encounter situations in which morphological identification is easily accomplished (for an exception, see Ubelaker et al., 1991). However, a coordinated effort between physical anthropologists and law-enforcement specialists at a crime scene is absolutely essential for the recovery of all available clues (Wolf, 1986; Maples and Browning, 1994; Dirkmaat and Adovasio, 1997).

Upon being introduced to skeletal material, the osteologist is faced with three critical questions:

- Is the material human?
- How many individuals are represented?
- Of what antiquity is the material?

Experience is the most valuable commodity in answering the first two questions. When in any doubt, consult comparative skeletal material or the illustrations in this volume.

The third question is usually more difficult to answer accurately, particularly if contextual information is not available. It is almost always necessary to engage in some detective work to give an accurate answer. The condition of bones themselves does not tell very much because the physical condition of the bones is largely controlled by the physical environment in which they were deposited or exposed. Bone weathering and deterioration are accelerated by direct sunlight, high heat, fluctuating temperature and humidity, biotic influences, and soil acidity. When these variables are held to a minimum, bone deterioration can progress very slowly.

To assess the antiquity of skeletal remains (not individual age at death), it is necessary to give primary consideration to their context. Has the skeleton been recently disturbed? What kinds of artifacts appear with the remains? False teeth, dental fillings, coins, beads, pottery, coffin nails, and other evidence of material culture (if real association can be established with the skeletal remains) may be critical in determining the antiquity of the remains. Wear of the teeth can sometimes provide clues to the origin of the skeletal material; in many parts of the world, the teeth of recently deceased individuals usually show far less wear than that seen in remains of people aboriginal to the area. Because contextual information is so critical to the accurate determination of the antiquity and origin of skeletal remains, the osteologist should always make every effort to visit the discovery site and make a firsthand assessment and record of the depositional history and associations of osteological material.

15.3 Excavation and Retrieval

Proper evaluation of any skeletal remains normally requires collection of the bones and subsequent laboratory analysis. Research parameters should be established prior to fieldwork in a well-thought-out research plan that covers as many contingencies as possible. The plan should incorporate the following steps that proceed from discovery:

- It is critical to establish which authorities to contact as well as to prepare a list of additional experts that may be consulted (*e.g.*, geologists, soil specialists, and conservators).
- Excavation and field recording methods should be thought out ahead of time. The research plan should outline both the short-term and long-term disposition of any recovered remains: will the remains be taken to a museum, laboratory, or other repository?
- Are there any legal requirements concerning the reburial of any remains found? In cases where reburial may be required, information sharing and negotiations should be undertaken very early — before any remains are found — to work out the details concerning potential joint curatorship arrangements, and/or any limits to be placed on analysis.

Upon discovery, the osteologist's natural inclination (particularly when the remains were the object of a search and especially if they are hominid fossils) is to collect them. This immediate separation of the specimen from its context should be the choice of last resort. There is no need to rush the removal; the bones can no longer “walk away” on their own. Before disturbing the context, move away from the site and carefully develop a strategy for recording and recovery. If celebration of a paleontological discovery is called for, hold it away from the site. Keep nonessential personnel off-site. On the site, it is advisable to show patience and restraint, while thoughtfully devising an appropriate strategy to extract the remains and all contextual information. Writing impressions down in the form of field notes is necessary and helps in this planning.

After the thrill and excitement of discovery have abated, it is time for serious, objective assessment of the situation. The following questions should be carefully considered before further excavation is undertaken.




Figure 15.1 A pioneer burial from near the historic Bordeaux Trading Post, southeastern Wyoming. The grave, which seemed to be associated with the trading post, or the nearby Oregon Trail, was found in 1980 by a field archaeology crew under the direction of George Zeimans and George Gill. *Left*: oblique view of the grave, outlined by the perimeter of the darker infilling soil. The right ulna is exposed near the upper end of the grave filling. *Right*: the grave after excavation (from Gill et al., 1984). Seen in this photograph are the remains of boots and a wide-brimmed black hat over the face. A displaced fragment of right radius is pedestaled next to the right patella. Artifacts found with the skeleton include a wedding ring, an adjacent black ring of mourning, and three coins.

- What are the political and legal constraints under which recovery must proceed? Goldstein (1995) provides an illuminating case study in this regard. Osteologists should confer with project management to ensure that all applicable laws are followed and all concerned parties are informed. In some archaeological and some forensic investigation scenes, hazardous materials will play a role in conditioning how the excavation and retrieval proceeds.
- In what condition is the bone?
- What has happened to the bone as it has been exposed? How has natural or human-induced erosion uncovered and scattered the bone across the landscape?
- What contextual information is available?
- What options are there for recovering the bone? Consider the available time, labor, and equipment. As Hoshower (1998) notes, flexible excavation strategy is a key component of successful recovery.

Figures 15.1 through 15.12 illustrate some aspects of skeletal recovery in archaeological situations. Mays (2010) and Ubelaker (1999), are good sources of additional illustrations, and Chapters 23–28 present case studies that involve the recovery of skeletal parts. Chapter 22 reviews special considerations involving preservatives, biomolecular sampling, and precautions.

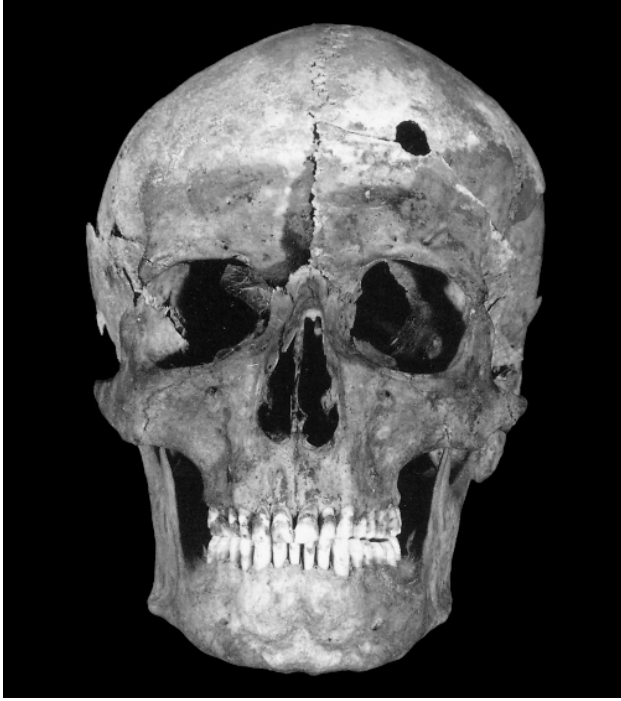

Figure 15.2 Frontal view of the frontiersman's skull excavated from the grave shown in Figure 15.1. Note the cranial gunshot wound caused by a .44- or .45-caliber weapon. A second perimortem gunshot wound to the hip and at least three healing rib fractures were noted by the investigators. This individual, a male who probably lost his wife prior to his own death (indicated by the black ring next to the wedding band), most likely was shot in 1869 or 1870 (from Gill et al., 1984).

The following general steps should be taken in the recovery of skeletal material:

- If skeletal parts have been scattered by erosion, mark each with a pin flag and assess the distribution to predict where more pieces might be found.
- The overriding concern in all work subsequent to the discovery of the specimen is to allow no further damage to occur. Damage of osteological remains due to improper excavation and extraction techniques is common, but it can be avoided. Steps should be taken to stabilize fragile bone *in situ* (in place) with **consolidants**, if necessary.
- Lose as little information as possible, especially concerning **context**. The remains, whether in a forensic or an archaeological context, are one-of-a-kind. They are nonrenewable resources. There is only one such bone, individual, burial, or cemetery, which means that there is only one chance to extract the remains completely and correctly. Actions taken during recovery have consequences that long outlive any investigator, rendering the osteologist's responsibility a weighty one.
- For articulated primary interments, it is often advisable to take samples of matrix from the chest and abdominal areas to retrieve incompletely digested foodstuff and/or evidence of gallstones or invertebrate infestations.
- Obtain proper equipment for recovery. Table 15.1 is a supply and equipment checklist that osteologists may find useful to consult before heading into the field. Provided that the bones and their context are not immediately jeopardized, recovery should be delayed until the proper tools are available. Use your judgment about how precarious the situation is.
- Before disturbing the scene, make comprehensive written and photographic records of the remains, their distribution, and their context. Never rely on memory. You should establish a site datum (a permanent reference point from which measurements are made) to control a grid laid out with stakes and cord across the surface. All recovered objects can be related to the grid. Manhein et al. (2006) and Listi et al. (2007) consider Global Positioning System (GPS) and Geographic Information System (GIS) approaches to recording

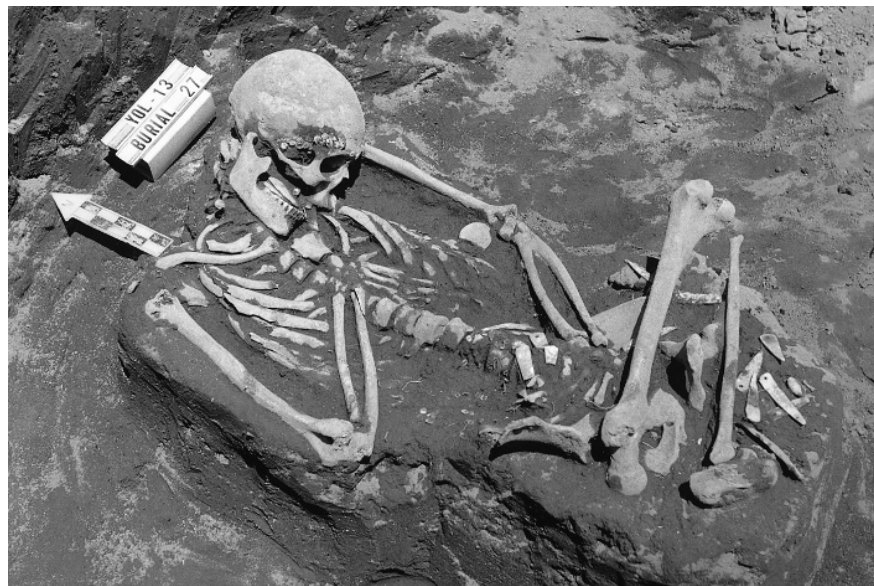

Figure 15.3 Prehistoric archaeological site in northern California, before and after excavation. *Left:* the outlines and darker infillings of circular grave pits can be seen on the floor of the excavation trench. The scales are in inches. *Right:* flexed burials were revealed within the slightly superimposed grave pits of Burial 2. Here, the two individuals in this burial are shown, both flexed. The same large stone appears in the lower left corners of the two photographs.

human skeletal remains, concluding that traditional techniques and photographs are still indispensable for mapping scattered remains. As Differential GPS becomes more available and replicability improves, these electronic tools will have an increasingly prominent role. Wolf's (1986) advice on approaching a crime scene with scattered material as if you were clearing a minefield is appropriate in this regard. In the past, a Polaroid® camera and 35-mm black-and-white film were practical and common solutions. However, digital imaging has largely replaced film in such situations (see Section 16.7). Whether using film or digital photography, or tape or digital recording, always create a backup in case of equipment failure or operator mistake. Small, portable, USB hard drives with large storage capacities are inexpensive and provide ideal primary and backup storage. A scale and directional arrow should be included in all drawings and photographs. Subsequent stages of the excavation should be photographed from as many angles as appropriate. Remove all tools, obscuring roots, and lumps of earth before photographing.

- The key to successful photography is the control of light (see Section 16.7.3). If lighting is a problem, particularly in an excavation, use a white sheet, aluminum foil on cardboard, or a flash attachment to illuminate the specimen. If a specimen is of critical importance, it is good to make a video record of it for teaching, lecturing, curatorial, and forensic purposes.
- Begin stabilization measures if necessary (for information on consolidants, see Section 16.2).
- Collect all bone exposed on the surface, even fragments that do not seem to be hominid. Remove your shoes if necessary and get down on your belly for a close look. Make sure the light is adequate before doing this. It is to your advantage that rains have washed the bone surface clean; as you disturb the soil it becomes more difficult to recognize small bone fragments. Move slowly and carefully, not trampling remains or artifacts underfoot.
- Screen earth from the abdominal region of all skeletons to recover dietary or fetal skeletal

Figure 15.4 Flexed burial of an adult accompanied by associated funerary objects. Shell beads adhere to the cranium, stones are in the mouth, and other beads and pendants are seen around the postcranial skeleton. Prehistoric, northern California. The scale is in inches.



remains. Screen all of the loose surface earth left over from each skeleton. A 1.0-mm mesh size (window screen) will recover most important fragments. Water wash excavated material through a screen to make the small fragments more visible and easier to recover. Flotation for paleobotanical remains will be called for in some cases.

- For burials, or other articulated *in situ* material, expose the bones one at a time. In an archaeological context it is important to recognize that there is a very large culturally determined and ethnographically observed range of variation in human mortuary practice. In most cases, however, there are some general kinds of burials to which the osteologist should be alert: a **primary interment** is a burial in which all of the bones are in an anatomically “natural” arrangement. Such burials are sometimes classified according to whether the extremities are extended or flexed. There are no neat categorizations here, and one photograph is worth many words of description. A **secondary interment** is a burial in which the bones of a skeleton are not in a “natural” anatomical relationship, but have been gathered together some time after complete or partial disarticulation of the skeleton and then buried. A **multiple interment** is a burial in which more than one individual is present. These burials include **ossuaries**, burial urns containing more than one individual, and a variety of other possibilities. **Cremation** is a mortuary practice involving the intentional burning of the body. Cremations can often be informative—the less efficient the fire, the more informative the specimen. For more information on burned human remains in a forensic and archaeological contexts, see Schmidt and Symes (2008). Micozzi (1991) reviews mortuary practices worldwide.
- In exposing burials, use appropriate tools and use them carefully. Dental picks are sharp and efficient, but they can easily damage the bone. Wooden or bamboo tools may sometimes be suitable, and a range of brushes of various sizes and stiffness is indispensable. Work from the rib cage outward where possible. Do not use the trowel in a sweeping motion unless you are doing exploratory work. Try to leave bones supported as you clean, exposing the foot and hand bones last. Watch for soil color and texture changes, rodent and root disturbance, mat impressions, rotted vegetation, wood, insect remains, charcoal, and associated artifacts such as lip plugs or beads. Be alert to all soft tissue that might remain, including hair, skin, fingertips (for prints), and ligaments. Write or otherwise record your notes; memory will not suffice. Record angles of flexion, the orientation of the body

Table 15.1 Equipment and Supplies for Osteological Fieldwork

<u>TEAM SUPPLIES & EQUIPMENT</u>	Digital audio (or tape) recorder	Hygiene
Travel and excavation permits	Media	Solar sunshower
Communications equipment	Audio and video tapes	Towel
Satellite phone	Film	Toiletries
Two-way radios	Digital media	Soap and shampoo
Detection equipment	General purpose equipment	Toothbrush and toothpaste
Aerial photographs	Tools	Medical, prophylactic equipment & supplies
Stereo photo viewer	Pliers	Sunglasses
Ground-penetrating radar	Carpenter's hammer	Sunscreen, lip balm
Metal detector (forensic cases)	Wrenches	Medicines
Locational equipment	Cutters, files	Water purifier
GPS unit and download cable	Tape (masking, gaffer's, transparent)	Insect repellent
Compass (set to local declination)	Extra batteries (rechargeable & standard)	Extra glasses or lenses
Excavation equipment	Solar charger for rechargeable batteries	Gloves
Site preparation equipment	Glue	Clothing
Shovels	Wire	Hat (washable)
Picks, axes, and saws	Conservation and curation equipment	Bandana
Bush clippers	Portable tables and chairs	Rain gear
Wheelbarrows	Preservative	Weather-appropriate clothing
Grid layout equipment	Solvent for preservative	Needle and thread
Line levels	Labeling pens	Eating and Drinking
Twine (yellow or white)	Labeling ink	Canteen
Nails or stakes	Packing material	Plate
Geological hammer	Containers (boxes, bags, vials)	Cup
Tape measures	Aluminum foil	Eating utensils
Controlled excavation equipment	Tissue paper	Personal excavation equipment & supplies
Trowels	Wrapping paper	Digging instruments
Buckets and dustpans	Notebooks	Pocket knife
Digging probes (dental and bamboo)	Writing utensils (waterproof)	Personal photographic equipment & supplies
Brushes (various sizes and stiffness)	Acetate sheets	Camera
Screens	Acryloid B-72	Camera media (or film)
Pin flags	Irrigation syringes	Camera batteries
Tweezers	Jacketing supplies	Flash attachment
Site shelter and protective equipment	Polyethylene cling film	Lenses
Tarpaulins	Orthoplast® bandages	Photo background
Ropes	Plaster	Remote (or cable) release
Field umbrellas	Water & mixing bowl	Photographic scale
First aid kits	Analytical equipment	Camera strap
Documentary equipment	Munsell color chart	Small photo mirrors
Photographic equipment	Laptop computer(s)	Lens cleaning fluid and papers
Cameras	Copy of <i>The Human Bone Manual</i>	Personal analytic equipment & supplies
Digital video	Food & water, if not available locally	Hand lens
Digital still	<u>PERSONAL SUPPLIES & EQUIPMENT</u>	Caliper(s)
35-mm film still (as backup)	Travel and Administrative needs	Measuring tape
Camera tripod	Money	Small preparation kit
Flash attachment	Institutional letterhead and envelopes	Laptop computer
Lenses	Travel documents	Notebook
Remote release (or cable release)	Passport	Writing utensils
Photo information board (dry erase)	Tickets	Calculator and batteries
Photo scales (metric)	Health certificate	Paper clips
Neutral (18% gray) card	Insurance forms	Permanent ink marking pens
Film and protective film bags	Permission letters	Rubber bands
Digital media (CF cards, memory sticks)	Letters of introduction	Miscellaneous personal equipment
Directional arrow	Shelter	Plastic bags
Step ladder	Tent, stakes, and guy lines	Scissors
Puffer (or canned air)	Sleeping bag and pad	Radio
Gaffer's tape		Flashlight, extra bulbs and batteries



Figure 15.5 Prehistoric cremation exposed by an archaeological excavation. Associated with the cremation are obsidian artifacts. The cremated bone fragments are seen in the area above the site name (CA-LAS-7) indicator. Prehistoric, northern California. The scale is in inches.

and head, the depth of the bones from the surface or the datum, and any other contextual details. Take soil samples where appropriate. Photograph and videotape liberally. Remember that all details of context should be retained in an archaeological or forensic excavation. In archaeological situations, context often yields the greatest amount of behavioral information. Excavation of a site destroys it, and contextual data left unrecorded are lost forever.

- Samples for biochemical analyses and histology (see Chapter 22) should be taken at the earliest time, with clean tools and gloves, and in sterile containers, to avoid contamination. See Nielsen-Marsh et al. (2000) for a review of how bone degrades chemically. In order to reduce the amount of “contaminant” DNA (resulting from handling by field and lab workers), some fieldworkers have begun to adopt “clean room” methodology in excavating relatively undisturbed cave sites such as El Sidrón cave in Spain (Pennisi, 2006).
- The actual removal of the bones themselves is one of the last steps of recovery, after exposure, photography, and drawing. To aid in their hardening, let the exposed bones dry completely in an area shaded from the sun. Free each bone gently—do not use force. Matrix (soil or other material that previously encased the bone) may remain on the thin parts (scapula, pelvis) to avoid damage during transport. Do not attempt fine cleaning in the field; this should be performed in situations where light, tools, water, comfort, advice, comparative material, and time are in greater supply—in other words, in the laboratory. Take each bone out individually and place in labeled bags or containers as you go along, particularly the ribs and vertebrae. Keep right and left hands, feet, and rib bones in separate containers. Keep unfused epiphyses with their associated bones. Be observant as you remove the elements, watching for fetal bones, sesamoid bones, kidney and gall bladder stones, and small artifacts. Save everything, even if you think that it might not be human. It is easier to do accurate identification in the laboratory. Do not disregard immature skeletal parts or disturbed burials; such disregard will skew the cemetery representations and ultimately have an adverse effect on any demographic reconstruction.

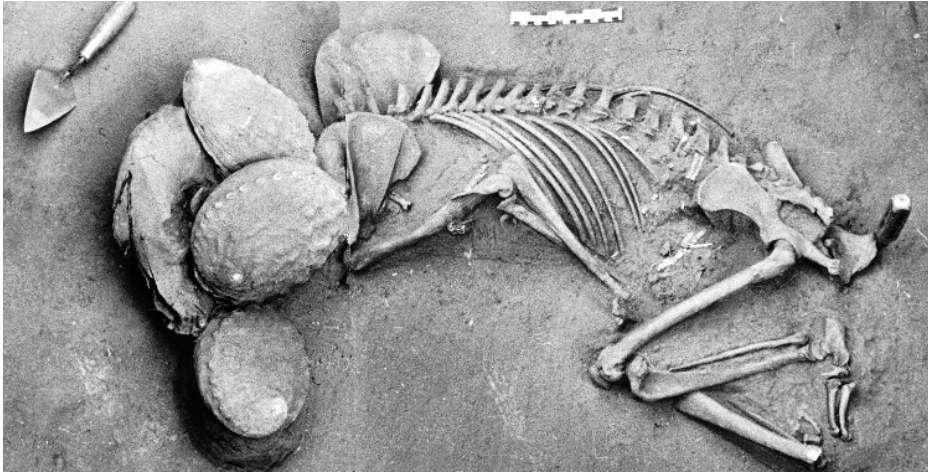
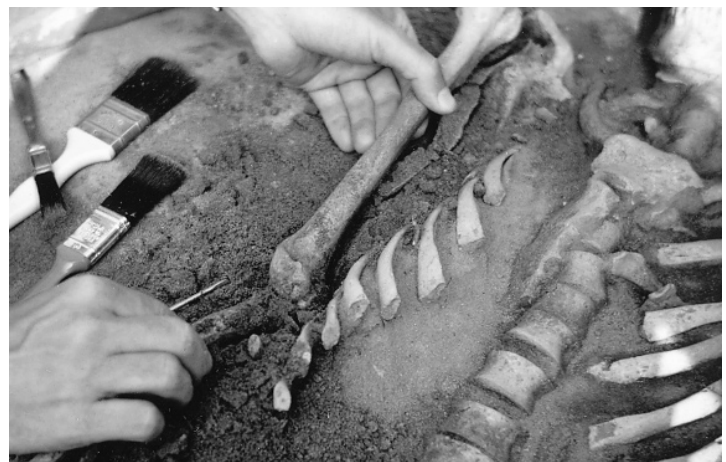

Figure 15.6 Ceremonial bear burial. Three large abalone shells cover the skull of the bear. Because the bones of large mammals were usually exploited for their nutritive value, large mammal bones from archaeological refuse deposits are usually very fragmentary; this case is an obvious exception. Prehistoric, northern California. The scale is in inches and centimeters.

- Bag remains as they are found, either in clearly labeled paper bags or in ventilated plastic bags.
- After removal, if the bone is still wet, let it dry completely in the shade. Never mix the specimens during washing or packing at the site. Screen all earth that remains at the spot of the burial, watching for beads, teeth, and other items that may have been missed as the larger bones were removed.
- Decisions about the cleaning of material at the recovery site are best left to the judgment of the investigator. As Brothwell (1981) notes, there is generally no problem in deciding about bone strength; bones are not generally deceptive in this regard. It is usually evident during recovery whether they are likely to disintegrate when handled.
- If the bones need to be cleaned, avoid the once-commonplace act of washing them with water, especially in the field. Water washing bones dissolves and degrades DNA (Pruvost et



Figures 15.7 and 15.8 An extended burial from a prehistoric site in Ohio. *Left:* the excavator, having cleared the central part of this burial, carefully exposes the hand phalanges with a dental probe. *Right:* after full recording, the archaeologist carefully removes the ulna and humerus. The ribs have been exposed for photographic recording and drawing, but they were not endangered by undercutting during excavation.



Figure 15.9 Mass grave at a prehistoric site containing the skeletal remains of four children and an adult. The legs and feet of a later extended adult burial protrude into the excavation from the bottom of the photograph. Such superimposition of different burial events is commonly encountered in aboriginal cemeteries, usually because graves were not marked with recognizable, surviving surface markers.



Figure 15.10 Extended burial of an immature individual from a prehistoric site. Great care must be taken with such young individuals to recover the many unfused bones.



Figure 15.11 Bones of a fetus were found within the pelvic cavity of this female skeleton from a prehistoric site in Ohio. The humerus, ribs, and scapula of the fetus are just anterior to the sacroiliac articulation.

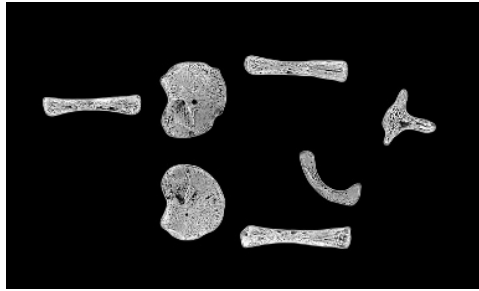
al., 2007), may initiate chemical reactions within the bone, and is generally an irreversible, invasive action that should only be done sparingly, after careful consideration, and with proper documentation (Odegaard and Cassman, 2007). If you feel the bones need to be washed, it is best to wait until back in the laboratory.

- It is often best to remove the earth from the cranial cavity and orbits while the soil is still damp. Do not try to reconstruct bones in the field — just keep them together.
- Decisions about the application of preservatives (see Section 16.2) must be made during exposure, and this application will often be necessary before removal is possible.
- Aluminum foil is an inexpensive but very effective material that can be used to stabilize, protect, and keep bones and their parts in place during lifting and transport. Press the foil firmly around all the bone and matrix irregularities.
- Burial recording forms, such as those found in Buikstra and Ubelaker's (1994) Standards volume, should be used. These can be useful, provided that caution is used in determining sex, age, and other features often prompted by such forms. Be sure to mark these determinations of identity as preliminary when they are made under field conditions.

15.4 Transport

When exposure, stabilization, photography, and drawing are complete, the skeletal remains may be removed from the archaeological context. In a forensic context, the decision to remove is made by the chief of the crime scene. This begins a “**chain of custody**,” a formal process in which the osteologist must participate, and should also document in writing (Melbye and Jimenez, 1997). If the bone is well-preserved, the elements can be lifted individually. Once bones have been extracted and field-cleaned, they are ready for packing and transport to the laboratory. Available

Figure 15.12 This fetal skeletal material from a prehistoric site in Ohio represents one of the smallest burials ever recovered. Good preservation combined with great concern for detail during excavation made the skeletal collection from this archaeological site one of the best available for the study of prehistoric demography (see Chapter 21). Natural size.



vehicles and packing materials for transport vary greatly. However, under all conditions, one primary rule should always be observed: *Do not let any further damage, contamination, or mixing occur.*

Occasionally it is necessary to remove the burial or its parts as a unit, in a supporting block of matrix, for study or display. To remove an entire burial, employ the paleontological technique of jacketing. To do this, first isolate the specimen on a pedestal of earth. Cover the exposed areas with tissue paper or polyethylene cling film to protect the bones and to act as a moisture barrier. Next, soak Orthoplast® bandages in water and then use them to form a cast or jacket around the specimen. Reinforce this jacket as necessary with additional plaster and, if necessary, strengthening rods of metal or wood. After the plaster has hardened, undercut the specimen and lift it out. This is an expensive operation in terms of material, time, and personnel. It requires experience and should be used only when necessary.

Once the burial has been removed, cleaned, and dried, the hands, feet, and ribs should be bagged by side, and the vertebrae by type. Labeling these elements at the time of removal greatly facilitates later sorting in the laboratory. Fine cleaning and gluing should be left for the laboratory. Label all bags and boxes used for collection with waterproof ink. Paper bags are prone to deterioration if used for long-term storage, but they breathe moisture, and are therefore better than plastic bags for post-excavation sorting, and for transport of skeletal material that retains residual moisture. In transport, keep the bones away from water. It is very important to carefully label and maintain organization when the bones are extracted from their context and moved to the laboratory.

When packing bones, pack firmly with lots of padding (plastic bags, bubble wrap, or newsprint) to avoid movement in the container. Pack heavier, denser bones at the bottom of containers and the more fragile bones such as scapula, pelvis, and crania at the top. Be sure that all bones stay in their assigned containers during the jostling that inevitably accompanies transport. Be particularly careful with the cranium, which is fragile in the facial regions. The cranium and mandible should each be packed separately, and care should be taken to ensure that teeth do not dislodge from their sockets during transport.

Suggested Further Readings

Some additional published sources describing skeletal recovery in archaeological and forensic contexts are provided here. Note that there is no written substitute for experience; the inexperienced osteologist charged with retrieving skeletal remains should always enlist the aid of more experienced colleagues, particularly archaeologists.

Adams, B. J., and Byrd, J. E. (Eds.) (2008) *Recovery, analysis, and identification of commingled human remains*. Totowa, NJ: Humana Press. 374 pp.

This edited volume presents many of the methodological approaches that can be used when dealing with commingled remains.

- Blau, S., and Ubelaker, D. H. (Eds.) (2008) *Handbook of forensic archaeology and anthropology*. Walnut Creek, CA: Left Coast Press. 800 pp.
A large volume containing over 40 chapters and covering the history, current practice, and future directions of forensic anthropology from a global perspective.
- Brothwell, D. R. (1981) *Digging up bones* (3rd ed.). Ithaca, NY: Cornell University Press. 208 pp.
A classic in the field; chapter 1 discusses excavation of skeletal material in archaeological context.
- Connor, M. A. (2007) *Forensic methods: Excavation for the archaeologist and investigator*. Lanham, MD: AltaMira Press. 272 pp.
Chapters 3–12 (and the appendices) are useful for their coverage of methodology.
- Dupras, T. L., Schultz J. J., Wheeler, S. M. and Williams, L. J. (2005) *Forensic recovery of human remains: Archaeological approaches*. Boca Raton, FL: CRC Press. 232 pp.
A guide to the application of modern archaeological field techniques to forensic excavation and recovery of human remains and associated evidence.
- Haglund, W. D., and Sorg, M. H. (Eds.) (1997) *Forensic taphonomy: The postmortem fate of human remains*. Boca Raton, FL: CRC Press. 636 pp.
An excellent edited volume with reviews and case studies covering a wide array of topics.
- Hunter, J., and Cox, M. (Eds.) (2005) *Forensic archaeology: Advances in theory and practice*. New York, NY: Routledge. 256 pp.
An introduction to the history and methodology of forensic archaeology, including its relationship to forensic anthropology.
- Killam, E. W. (2004) *The detection of human remains* (2nd ed.). Springfield, IL: C. C. Thomas. 268 pp.
The most comprehensive guide available; even has a chapter on “parapsychological methods.”
- Kipfer, B. A. (2007) *The archaeologist’s fieldwork companion*. Malden, MA: Wiley-Blackwell. 488 pp.
This handy guide serves as an introduction to the forms, procedures, and terminology common in North American archaeology. Chapter 4 (“Mapping, Drawing, and Photographing”) and the many checklists are particularly helpful.
- Komar, D. A., and Buikstra, J. A. (2007) *Forensic anthropology: Contemporary theory and practice*. New York, NY: Oxford University Press. 384 pp.
An up-to-date guide to practicing forensic anthropology in the U.S. Includes case studies, a comprehensive bibliography, and an extensive glossary.
- Leiggi, P., and May, P. J. (Eds.) (1994) *Vertebrate paleontological techniques: Volume 1*. Cambridge, UK: Cambridge University Press. 344 pp.
A guide to a variety of standard field and laboratory techniques used by vertebrate paleontologists.
- Schmidt, C. W., and Symes, S. A. (Eds.) (2008) *The analysis of burned human remains*. Burlington, VT: Academic Press. 296 pp.
A guide to the changes seen in bones and teeth as a result of being subjected to fire.
- Williams, E. (Ed.) (2001) *Human remains: Conservation, retrieval and analysis*. Oxford, UK: Archaeopress. 281 pp.
The papers in this edited volume comprise a diverse set of viewpoints on the appropriate scientific and educational use of archaeological human remains. The numerous case studies from around the world illustrate ways of balancing the tension inherent in work involving these remains.

Chapter 16

LABORATORY PROCEDURES AND REPORTING

ANALYSIS BEGINS IN THE FIELD and extends to the laboratory. The procedures discussed in Chapter 15 are related primarily to the exposure and recovery of skeletal remains. There, we traced remains from their point of discovery into the laboratory. Now we introduce laboratory procedures commonly applied to human osteological material and consider the elements of effective reporting of analytical results. It is important to note, particularly for forensic settings, that Standard Operating Procedures (SOPs) for agencies involved in cases with evidentiary human remains must be followed very closely (see Chapter 15). The chain of custody must always be rigorously respected and documented, and security of the remains vigilantly maintained.

16.1 Setting

Sound procedures, an appropriate setting, and careful use of the proper equipment are essential in osteological analysis, not only to ensure accurate results but also to safeguard the skeletal remains. Of primary importance is that work be conducted over a padded surface. Care should be taken to prevent specimens from contacting hard surfaces or rolling onto the floor. Even well-preserved bones that seem sturdy may be fragile when compared to the instruments used to measure them. The osteologist must therefore be careful not to crush, pierce, scratch, or otherwise damage the specimen with the instruments. Poking or prodding the skeletal material with the fingers can also easily damage the bone, especially the more fragile parts of the cranium.

The study of bones is best done in a well-lit laboratory (Figure 16.1). Lighting is critical. Overhead fluorescent lights are poor for osteological work because they tend to fill the room with diffuse light. Observation of osteological detail depends on the control of incident light on the specimen, and for this reason a swing-arm fixture with an incandescent, halogen, compact fluorescent, or LED light source is recommended for osteological analysis. A unidirectional light source makes it possible for the researcher to highlight subtle bony features or modifications by angling the light to enhance the visibility of surface detail.

It must be noted that there may be several biological and chemical hazards involved with recovery and analysis of skeletal remains, particularly in forensic contexts (Galloway and Snodgrass, 1998). The fungal spores that cause Valley Fever (coccidioidomycosis), commonly found in the soil of southwestern North America and parts of Central and South America, may adhere to archaeological remains (Petersen et al., 2004; Lacy and Swatek, 1974; Werner et al., 1972). Arsenic and organic pesticides may also be present, derived either from soil associated with the remains or from museum pest management practices (Arriaza and Pfister, 2007).

Figure 16.1 Osteological labwork. In the laboratory, osteological specimens are fully labeled and restored. Here the osteologist checks for joins. When joins are found, the bones are glued together and temporarily supported in a sandbox while the glue sets. Comparative material should be accessible during these operations. The washing and drying of additional specimens proceeds in the background.



16.2 Stabilization

The strengthening of bones can be accomplished in several ways during and after recovery. Various consolidants (or “hardeners”) are available. These are usually either water- or acetone-soluble; they include polyvinyl acetates (PVAs, such as Vinac, soluble in acetone), Paraloid B-72, polymethylmethacrylate (PMM) resins such as Bedacryl 122x (which can be purchased in hard chunks that are then dissolved in an organic solvent), Butvar B-76 (a powder mixed in solvent), and many others. Cyanoacrylate glues of various viscosities are strong, fast-setting, and difficult to remove, but may be necessary to apply before the removal of remains, particularly heavily burned or ashed tooth crowns in forensic contexts (Mincer et al., 1990; Fairgrieve, 2008). Kres and Lovell (1995) and Johnson (2001) review modern consolidants used in osteological work and Rossi et al. (2004) consider these in relation to fragile cremated remains and thin sectioning. Odegaard and Cassman (2007: 85) warn, “a consolidation treatment on inherently fragile material is a decision that cannot be taken lightly since it comes with permanent repercussions. It should not be considered a reversible procedure.” Consult with the conservator of the institution that will house the osteological material about the kind of consolidant preferred.

The key to using any consolidant is correct dilution. The most frequent failure in consolidant use is the failure to dilute the solution enough. This results in poor penetration and the formation of a hard outer “skin” on the specimen but a lack of internal hardening. Impregnation with a consolidant having the consistency of water is recommended, usually about a 5–10% solution.

It is usually best to dip whole specimens into the solution and then let them dry on a wire screen. In the case of more fragile remains that will not stand up to immersion, drip the solution onto the specimen. Use organic solvents (“thinners”) with extreme caution. Many of these chemicals are dangerous; avoid breathing their fumes and remember that they are often extremely dangerous because of their flammability.

A record of any treatments done to a bone — from the simple (*eg.*, washing) to the more complex (*eg.*, consolidation) should be carefully recorded. Note the exact chemical composition of the products used, and on which portion(s) of the remains the treatment was applied. This information should then be filed with the permanent records at the final repository for the remains. This information is vital for future research, as some treatments may detrimentally affect the ability to use methods such as ^{14}C dating (D’Elia et al., 2007) and DNA analysis (Nicholson et al., 2002; Vuissoz and Gilbert, 2007).

16.3 Preparation

Techniques used in skeletal preparation vary according to the condition of the bone and the context of its discovery. Archaeological bones, bones from forensic cases, and fossilized bones are all prepared differently. The preparation of any of these types of remains has its own requirements and is subject to specific restrictions. Preparation of all of these types of remains will be considered below.

16.3.1 Preparing Archaeological Bones

Washing bones in water dissolves and degrades DNA (Pruvost et al., 2007), may initiate chemical reactions within the bone, and is generally an irreversible, invasive action. It should only be done sparingly, after careful consideration, and with proper documentation (Odegaard and Cassman, 2007).

If you determine that the bone must be washed, be sure it is well-preserved and verify that no adhering substances valuable for later analysis, such as textile, ochre, pollen, or metal residues, are present. Wash bones in lukewarm water (without detergents or any other additives) using soft brushes, wooden probes, and spray bottles. Never wash more than one skeleton at a time. Use a screen in all washing, field and laboratory, to keep small bones from being lost. As the washing water becomes muddy, small fragments may detach and become lost in the sediment at the bottom of the basin or disappear down the drain. Clean the basin and screen frequently, making sure that both are checked between processing each burial. Depending on humidity, the washed bones dry in 24 to 48 hours on wire racks in the shade. In the laboratory, you can speed this up by using a fan to gently blow air across racks of drying bones. Never use a heat source due to the danger of bone surface exfoliation.

Whereas the washing of bones should be minimized, there are many good reasons to remove adhering soil from archaeological bones. Soil and other adhering matrix obscures morphology and can make analysis difficult or impossible. Large clumps of soil, if left attached to a bone, can unexpectedly detach, exfoliating the surface of the bone. They can also scratch or damage other bones when moved during storage and transport.

Bone can be cleaned without water using soft-bristle brushes. Before cleaning, set out a large sheet of paper to catch removed material. After cleaning, roll the paper into a funnel shape and decant the shed material into an appropriate labeled container (if the material is dry, a zip-lock plastic bag is commonly used) to be kept with the bone(s), preserving it for potential future research. Large clumps of hardened soil may need to be lightly moistened in order to be gently removed from the bone.

16.3.2 Preparing Forensic Bones

Forensic bones will sometimes have adhering flesh and other tissues that make direct observation of the bone difficult, if they are not removed. The process of removing soft tissue remnants from bone is called **maceration**. Before undertaking maceration of forensic remains, there are three important factors to consider: future DNA testing, the possible evidentiary value of the tissue to be removed, and the chain of custody.

To preserve the possibility of downstream DNA testing, traditional defleshing techniques such as those used for building comparative mammalian skeletal collections (*eg*, Hildebrand, 1968; Mori, 1970) are not recommended. Rennick et al. (2005) note that the use of bleach or prolonged exposure to boiling water has a degradative effect on bone DNA, but found that the use of milder agents such as powdered detergent or sodium carbonate was less damaging. Fenton et al. (2003) and Steadman et al. (2006) found that shorter duration exposure to slightly lower temperature (90° C) water was less destructive to bone DNA than many traditionally “conservative” maceration techniques.

Tissues of any kind should be regarded as potential evidence in forensic cases. Be sure to consult a soft tissue pathologist before removing soft tissues. When possible, select a maceration technique that will allow the removed tissue to be preserved. In many cases this will mean physically macerating the bulk of the tissues by removing them carefully with appropriate dissecting tools. Never destroy evidence of any kind; even insect larvae contained in these tissues may provide important clues in a forensic case.

Finally, the chain of custody must be maintained with all physical evidence in a forensic case. Melbye and Jimenez (1997) discuss the implications of chain of custody in forensic osteology. As stated by Komar and Buikstra (2008: 99), maintaining the chain of custody requires that:

- the investigator is aware of the exact location of the evidence at all times;
- the evidence is maintained in a secure location;
- the evidence is sealed to prevent tampering;
- access to the evidence is restricted to the responsible investigator or authorized designates;
- any handling, transport, analysis, or examination of the evidence is acknowledged in a written log.

16.3.3 Preparing Fossilized Bones

For fossils, more specialized preparation techniques are often called for. Fossils are sometimes encased in a very hard **matrix** (surrounding material) that may be even harder than the bone itself. Sometimes the matrix can be softened with solvents such as acetone, paint thinner, or even water. Very important fossil specimens should be molded (see Section 16.10) before cleaning to make a record of pre-preparation status. When cleaning, matrix samples should be kept so that future investigators might be able to establish **provenience**, the stratigraphic and spatial position of the specimen.

Some commonly used fossil preparation tools and techniques include the following:

- **Hammer and chisel.** This technique has a long history, and many fossils have the scars to prove it. Speed is an asset, but the shock imposed on the specimen and the lack of fine control are negative points.
- **Dental drill.** This fast but dangerous technique has been used for many years. Positive points include good cutting power, more control than a hammer and chisel, and lack of shock to the specimen. However, extreme care must be taken to keep the surface of the grinder from drilling into the surface of the object being cleaned.

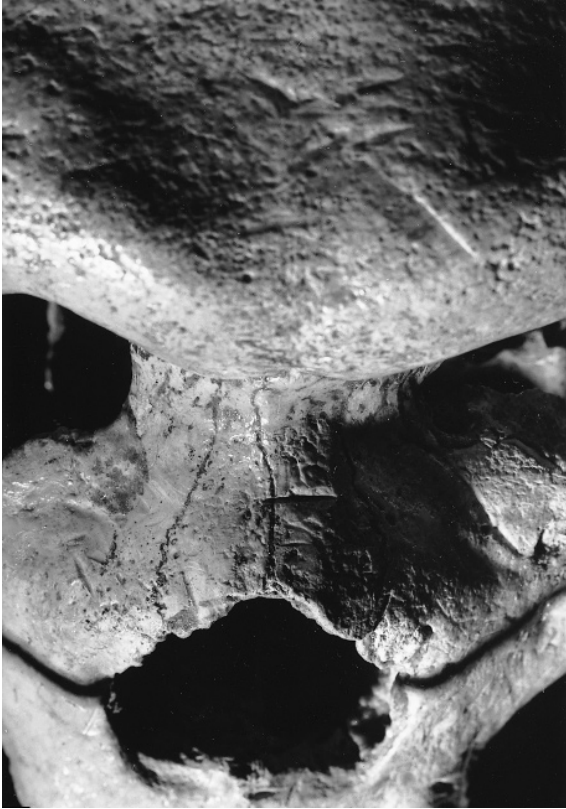

Figure 16.2 Preparation-related damage on the Pleistocene fossil *Homo* cranium from Petralona, Greece. Removal of matrix by a high-speed grinding wheel has produced damage on the original surfaces of the left nasal bone, and chiseling marks are seen above the left orbit. Natural size.

- **Dental pick (or needle held in vise) under binocular microscope.** This is often the most effective way to clean a fossil; it gives the preparator much control and limits potential damage to tiny areas. However, this work requires an enormous amount of time and patience.
- **Acid treatment.** Dilute acetic, formic, or hydrochloric acids can be used to dissolve matrix holding some fossils. Excellent detail may be obtained by this technique, but it calls for patient, extended monitoring to keep the acid from attacking the specimen itself, etching its surface, or weakening its structural integrity. Take all standard laboratory precautions when using acids. Use this method only after consulting an experienced preparator or conservator.
- **Air abrasion.** This preparation technique uses a tool that shoots a stream of particles at the matrix like a miniature sandblaster. This provides speed and control without shock. However, the abrasive particles may obscure detail and “frost” the bone and tooth surfaces. In addition, it is difficult to control the abrasive stream as it ramifies through cracks below the surface of a specimen.

The most essential ingredients in successful fossil preparation are patience and experience, but help and advice from skilled preparators are crucial. Note that all of the techniques discussed here carry with them hazards for the bones or fossils. It is better to be safe than sorry in preparing important specimens. Preparation trauma that is readily observable on previously cleaned bones and fossils shows that many past workers were not careful enough (Figures 16.2–16.3).




Figure 16.3 Taphonomic or preparation damage? Frontal view of an immature Neanderthal cranium from Engis, Belgium (A). The superficial scratches along the midline were made by a diagraph instrument needle, and those along the broken edge of the left frontal were made by sandpaper used to smooth the previously plaster-reconstructed area behind. These marks were interpreted as evidence of Neanderthal mortuary practice (Russell and LeMort, 1986). This interpretation was shown to be mistaken by White and Toth (1989). Scanning electron micrographs (B–D) show the sandpaper striations. Note the “doubling back” at the end of each sandpaper grain’s path as the end of the sanding stroke was reached. These figures illustrate the utility of the scanning electron microscope in investigating bone modification at magnification.

16.4 Restoration

Restoration involves putting pieces of broken bones back together. A detailed knowledge of osteology greatly simplifies this process; the ability to identify the side and position of fragments allows the quick identification of joins. The restoration of fragmentary bones is often described as more difficult than doing a jigsaw puzzle. This is an exaggeration. A broken skeleton has one more dimension and far more information than a picture puzzle of a polar bear in a snowstorm. Restoration is often quick and easy for the competent osteologist (see Figure 16.1 for an illustration of restoration in progress). The following are valuable guidelines for restoration:

- Use a glue that may be dissolved later. This ensures future workers the ability to correct any unintentional mistakes of restoration.
- Do not hurry. As in preparation, patience and experience are essential in good skeletal restoration.

- Restore the face and vault separately before joining them. Use the mandibular condyles as a guide to restoring the correct cranial breadth when this is in doubt.
- Be sure the bones to be glued together are dry, unless a water-soluble glue is being used.
- Do not glue until you are positive of a good join. Check under the microscope if necessary.
- Make sure the joining surfaces are clean of debris. Adhering grit, consolidant, and flakes of bone can result in misalignment of broken pieces.
- Use color, texture, and — most importantly — anatomy to match the pieces.
- Never glue teeth into their sockets until you are absolutely positive that they belong there. Interproximal contact facets provide an invaluable guide to accurate tooth placement.
- Do not glue yourself into a corner by leaving unfilled gaps between bones. Instead, use removable painter's masking tape to make temporary joins. Do not leave the masking tape on for more than a couple of months and be careful that the bone surface can release the tape without exfoliating. When satisfied that the joins are correct, progressively remove the tape and glue the broken surfaces together.
- Reconstruct only where necessary. Use soft plaster or a 50:50 mixture of paraffin wax and dry plaster heated to a liquid in a saucepan on a hotplate (not an open flame). Do not ignite the paraffin. This restoration material is easy to work with and remove. In contrast, modeling clays (plasticine) tend to be more greasy and should generally not be used, except as temporary props. After the restoration is complete, be sure to demarcate the reconstructed from the real surfaces. Reconstruction (as opposed to restoration) is rarely justifiable for an original specimen because it is subjective and it obscures valuable cross-sectional information.
- Use a sandbox and gravity to position pieces while rebuilding them. Anchor one piece in the sand and balance the other piece on top of it, perhaps temporarily supporting the glue join with removable painter's masking tape (Figure 16.1). Be sure to let the glue completely harden before removing the piece from the sandbox.
- Where contacts are limited and weak, brace the parts by using struts made of wooden or glass rods.
- Do not use glues, consolidants, or reconstruction material that will inhibit molding rubbers that may be used on the specimen at a later time. Check any such substances for compatibility with molding rubber before applying them to the specimen.
- For some specimens, complete restoration is extremely difficult; some distortion is the result of warping rather than fracture. Such warping is impossible to correct.

16.5 Sorting

The osteologist is often faced with the challenge of sorting a collection of bones that contains more than one skeletal individual. Of primary importance in this sorting are age, size, and sex differences as well as bilateral, nonmetric traits. Matching articular or interproximal facets often provides clues about association. Preservational factors such as bone color, weathering, or integrity are of secondary importance, but are sometimes useful in sorting individuals.

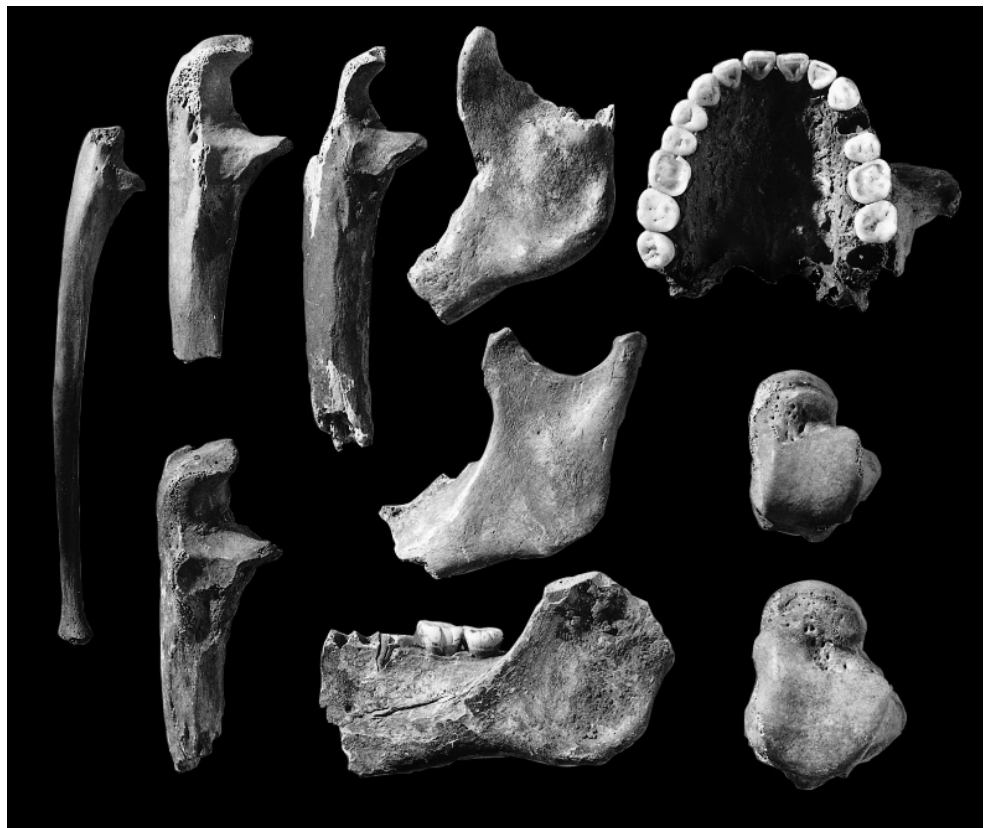
The **minimum number of individuals (MNI)** in any assemblage of bones is the minimum number of individuals necessary to account for all of the elements in the assemblage. A very simple example might be an assemblage consisting of two specimens, a fragment of left humeral head and a fragment of left distal humerus. These two specimens, even though the intervening shaft is missing, *could* represent the same individual (unless they are of patently different individual ages). Even though there might be two individuals involved, the MNI value would, in this case, be one.

This basic logic is used to determine the MNI value for any assemblage of human remains by following these procedures:

- Remove all nonhuman elements.
- Separate the bones according to element and side.
- Within each right-side element category, count the minimum number of individuals—not pieces—represented. Consider all possible joins between fragments and assess the age-at-death of each fragment.
- Perform the same minimum number count for left-side bones within each element category and then check for individuals represented by left-side bones that either do match, or possibly belong, to those from the right. These do not increase the count.
- Left-side bones that do not match corresponding right-side ones in age or morphology are added to the minimum number count.

After this is done for all paired and unpaired elements, the greatest minimum number of individuals has been determined. Consider, for example, an assemblage consisting of two right maxillae with full adult dentitions, three left femora of adults, one right femur of an infant, two sacra, four adult right calcanei, and three permanent right upper central incisors. The MNI in this assemblage is six—the infant plus five adults (determined by two right central incisors in maxillae, and three isolated upper right central incisors). The maximum number of individuals is determined by counting all nonjoining, nonmatching elements—in this case, a total of 15. For another example, see Figure 16.4. Note that the MNI is not equal to the “most likely number of individuals” (MLNI), a statistical construct proposed by Adams and Konigsberg (2004, 2008). Outram et al. (2005) discuss the benefits of parallel and integrated analyses of both human and nonhuman bones, especially from sites with highly fragmented remains.

Figure 16.4 Minimum Number of Individuals (MNI). To determine the minimum number of individuals for this sample of ten specimens (shown one-half natural size), first note that there are no nonhuman pieces. Sort the pieces by skeletal element and side. There are two right tali, three left mandibles, one maxilla, and four right ulnae. One of the ulnae is immature. The MNI is thus equal to at least four people. Because no pieces join or are antimeres (opposite sides of the same individual), it is possible that each piece represents a different individual, so the maximum number of individuals indicated for this sample is ten.



16.6 Metric Acquisition and Analysis

Because osteological work is part of the scientific enterprise, it is necessary to communicate results to other researchers in an unambiguous and precise manner. One of the most convenient and effective ways to communicate osteological observations is to quantify them—to express them as numbers. Thus, to inform colleagues and others about a particular tooth, it is a simple matter to measure and count characteristics of that tooth.

16.6.1 Traditional Osteometric Tools (Figure 16.5)

Many measuring tools have been invented and developed for osteological analysis. Figure 16.5 illustrates some of the most common of these. Devices for orienting crania are also available, and instruments called diagraphs are used to trace certain profiles of crania held in these devices. Most of these precision instruments are made of steel and are expensive. They are also sharp. Care should be exercised to see that the instruments are not damaged during use. More importantly, because bone is softer than steel, these instruments can scratch or perforate bone surfaces, and care should be taken to see that such damage does not occur during analysis.

- a. **Sliding calipers:** The sliding caliper is the most frequently used measuring tool in the osteologist's toolkit. It has a pair of jaws whose variable gape is measured via a dial, a scale, or a digital readout on the caliper shaft.
 1. **Vernier caliper** (Figure 16.5f): Vernier calipers use a combination of a large primary (or fixed) linear scale and a smaller nonlinear (or vernier) sliding scale to measure distances to the nearest 0.1 mm (*i.e.*, they have a measurement error of 0.05 mm). Whole millimeters are read from the primary scale, and fractional millimeters are read from the relative position of the linear and nonlinear scales. As they have no gears, pinions, or dials that may wear or otherwise slip out of alignment, they are very reliable. On the other hand, a certain amount of skill and practice is required, as they take some getting used to. Care must be taken to avoid possible parallax errors on most models.
 2. **Dial caliper** (Figure 16.5g): Dial calipers are a refinement of vernier calipers, replacing the secondary nonlinear sliding scale with a graduated dial. Dial calipers can be used to measure distances to the nearest 0.02 mm (*i.e.*, they have a measurement error of 0.01 mm). Whole millimeters are still read from the primary scale, but fractional millimeters are read from a large dial. Regular alignment (“zeroing”) of the dial is a necessary but simple task. Most models of dial caliper are also susceptible to parallax errors (due to the differing heights of the dial arm and the graduated marks on the dial), but these can be overcome with practice and consistent dial-reading technique.
 3. **Digital caliper** (Figure 16.5a, b): Digital calipers are a further refinement of dial (and vernier) calipers, replacing the dial with an electronic digital display from which the entire measurement can be read. Digital calipers can be used to measure distances to the nearest 0.01 mm (*i.e.*, they have a measurement error of 0.005 mm) and, as with dial calipers, regular alignment (“zeroing”) of the dial is necessary and simple. Unlike vernier and dial calipers, there is no risk of parallax errors when reading measurements. One particularly useful feature of some digital calipers is the ability to directly interface the caliper with a computer using a built-in RS-232 data port and cable.
 4. **Dental caliper** (Figure 16.5b, f): Dental calipers are specialized versions of the more typical sliding calipers. The primary difference is the replacement of larger, sturdier jaws with either narrower, pointed jaws (Figure 16.5f) or needle points (Figure 16.5b) capable of fitting into small interproximal gaps.
- b. **Spreading caliper** (Figure 16.5e): A spreading caliper is usually used for work on cranial anatomy. Spreading calipers consist of two recurved, hinged jaws, often with an integrated




Figure 16.5 Tools for osteometric measurement. Key: a) digital sliding caliper with standard points; b) digital sliding needle-point caliper; c) cloth measuring tape; d) osteometric board; e) spreading caliper; f) vernier dental caliper; g) dial caliper with standard points; h) mandibulometer.

- graduated scale from which measurements can be directly read. Spreading calipers are used to measure distances on large, irregular bones (*e.g.*, cranium and articulated pelvis) that are difficult or impossible to measure with sliding calipers or osteometric boards.
- c. **Osteometric board** (or **bone board**) (Figure 16.5d): The osteometric board is second only to sliding calipers in its utility, versatility, and applicability. Osteometric boards are useful in measuring lengths and angles of postcranial elements. An osteometric board is composed of a long, sturdy metal or wooden horizontal plate with an attached perpendicular endplate. A graduated scale extends from the fixed endplate, and there is a second, movable endplate whose position can be read from the graduated scale.
 - d. **Cloth measuring tape** (Figure 16.5c): A simple cloth tape, graduated in millimeters, is the standard tool used to measure the circumferences of long bones. Care must be taken to find a tape that does not stretch, and some practice is required to get reliable measurements.
 - e. **Mandibular goniometer**: The mandibular goniometer is a simple device for measuring the angle between two planes. It typically consists of two pieces of wood (or plates of metal), hinged together and connected with a protractor. A mandible is set on the fixed horizontal plate (to which the protractor is fixed), and the movable plate is adjusted so that it contacts the posteriormost points of the condyle and ramus. The mandibular angle is read as the angle between the two plates.
 - f. **Mandibulometer** (Figure 16.5h): The mandibulometer is an extension of the mandibular goniometer. In addition to mandibular angle, the mandibulometer also measures mandibular length and maximum ramal height.

16.6.2 Analysis

Recent advances in computerized tomographic (CT) and laser scanning technologies have made it possible for osteologists to acquire metrics digitally, and to display them via a computer screen remote to the specimen(s) under study. At first glance, this technological capability brings with it the prospect of fast, easy, and accurate data acquisition and distribution. Rare or valuable specimens can now be digitized by laser, CT scans, and 3-D digitizers (Mafart et al., 2004; Mafart and Delingette, 2002; Ousley and McKeown, 2001; Zollikofer et al., 1998). So alluring are the siren songs of these new capabilities that some have even suggested that they obviate the need to curate original specimens (see also Chapter 17). This is a mistaken and extremely dangerous philosophy in osteology.

History provides a relevant lesson here. When it became possible to “capture” morphology of fossil specimens via flexible rubber molds and accurate plastic casts, replicas of the fossil originals were distributed throughout the world. These casts are immensely valuable as teaching and preliminary research tools, but experience has shown that they are no substitute for the originals. Distortion, matrix cover, and internal morphology are all lost in a cast. Workers unfamiliar with originals can be badly misled by such features, features only visible with reference to the original. Misinterpretations based on inaccurate observations and measurements on photographs and casts are an embarrassing part of the published literature of human paleontology. See Clarke and Howell (1972) for an analysis of problems inherent in observations and measurements from photographs and casts.

With either two- or three-dimensional digital images scanned from original osteological specimens, these problems are compounded dramatically as the investigator moves another step away from the original. Color, texture, internal anatomy, matrix cover, consolidant cover, preparation damage, erosions, and distortions of all kinds may be faithfully recorded by such imaging of the original, but for the osteologist looking at a computer monitor on the other side of the planet, these features may not be digitally distinguishable from actual bony anatomy. Humans routinely make mistakes, and relying on these technologies risks increasing the number and impact of these mistakes in human osteology. For obvious reasons, osteologists should always refer to the original specimen, even when acquiring metric data from digital sources.

Figure 16.6 A three-dimensional laser-scanning unit at the University of California, Berkeley. The machine accurately measures three-dimensional surface topography and sends these data to a computer where measurements, restorations, and other manipulations are possible.



The popular image of an osteologist at work is one of a person in a white laboratory coat, measuring instrument in hand, manipulating some bone (usually a cranium). The role of the professional osteologist is far broader than this. In the formative days of osteology, quantification of bony anatomy was the focus of most work. Elaborate sets of measuring points were defined, and vast quantities of metric data were compiled. Just because a certain measurement has been reported, however, does not mean that it is either useful or even reproducible (Stirland, 1994). Conversely, new metrics are routinely developed to quantify morphological observations. The traditional days in which measurement was done for measurement's sake are thankfully over now, but metric analysis does continue to play a primary role in osteology. Howells (1969a) provides an interesting background for the selection of skeletal metric points.

All scientific measurements, including those in osteology, should be taken in the metric system. This system expresses linear osteological measurements in millimeters, centimeters, and meters. Some observations are possible to quantify even though they are difficult or inappropriate to record as actual measurements. For example, traits such as the Carabelli's cusp on upper molars may be recorded as absent or present. Variables recorded in this way are called **discontinuous** (or **discrete**) **variables**, as opposed to **continuous variables** such as linear measurements.

Metric analysis in osteology requires more than simply measuring a given element. It is critically important to provide precise definitions of each measurement. Furthermore, the degree to which measurements can be reproduced is important in metric analysis. Tables 16.1 and 16.2 demonstrate the proper way to calculate and report measurements and their associated errors. Lyman and VanPool (2009), Buikstra and Ubelaker (1994), and Heathcote (1981) provide further details on measurement error in osteology.

Metric data in osteology are usually compiled as a result of measuring arcs, chords, or volumes. Indices are made by combining these values. For example, the Cranial Index is the product of the maximum cranial breadth (*bi-eyron*) and 100, divided by the maximum cranial length (*glabella* to *opisthocranium*). Indices are convenient because they express shape as a single variable. For

Table 16.1
Measurements: Estimates of Real Dimensions

It is important to understand the difference between the actual dimension you wish to determine and any measurement you take of that dimension. While it may seem straightforward to take a caliper, measure the distance between the two orbits as 41.0 mm, and then state that the interorbital distance is 41 mm, such a methodology is flawed and may result in inaccurate estimations of the actual dimension and/or improper levels of precision in those estimates. Such an approach ignores several factors that must be taken into account:

- The exact definition of the standardized metric—measurements must be taken exactly as defined to be useful in any comparative or descriptive context.
- The precision of the instrument used to take the measurement—generally defined as one-half of the smallest increment the instrument is capable of measuring.
- The effect of random error, an unavoidable factor which is present in all measurements.
- The effect of any systematic error(s), such as improperly zeroed or calibrated calipers, or individual differences in the way a measurement is taken.
- The conventions for presenting the best estimate of the actual metric and the estimated error in that estimate.

You should present your estimates of dimensions in the following form:

$$X = x_{best} \pm \sigma_M$$

where X is the metric being measured, x_{best} is the best estimate of that metric (in practice, a simple average of all measurements taken of that metric), and σ_M is the estimate of the error present in x_{best} . To obtain σ_M , square the differences (**deviations**) of each of the individual measurements from x_{best} (the average of all the individual measurements), and add all of these squared deviations together (this is often referred to as the **sum of squares**). Divide this sum by the number of individual measurements minus 1, and then take the square root of the result. The result is known as the **standard deviation**, or σ . Divide the standard deviation by the square root of the number of individual measurements taken to get σ_M , referred to as the standard error of the mean or, more simply, the **standard error**. See Table 16.2 for an example of how to calculate the standard error.

To convey the correct precision of your estimate, make sure the number of significant digits in your estimate does not exceed the smallest number of significant digits of any of the component measurements. For instance, if you had the following five measurements of the dimension ‘Y’:

23.25 mm 23.5 mm 23.34 mm 22.97 mm 23.30 mm

your raw calculations for mean and standard error would yield 23.272 and 0.086336551, respectively. The first figure has five significant digits, and the second figure has eight, but your original measurements had either three or four significant digits. As a result, the final statement of your best estimate of the dimension’s true size should have only three significant digits:

$$Y = 23.3 \pm 0.0863 \text{ mm}$$

A note for users of digital calipers: As the example above demonstrates, you must exercise caution when recording measurements from your caliper’s digital display. If the measurement is given as 50.00 mm, do not abbreviate this to 50.0 mm or 50 mm, as these latter figures do not contain or convey the precision actually obtained in your measurement.

A note for users of nondigital calipers: Users of nondigital calipers should also exercise caution when recording measurements from their calipers. If the dial or scale points to 50.0 mm, do not abbreviate this to 50 mm, as this figure does not contain or convey the precision actually obtained in your measurement. Likewise, do not express a measurement of 50.0 mm as 50.00 mm unless 1) the caliper is intended for this level of precision, and 2) you are confident that you can distinguish 50.00 mm from both 49.99 mm and 50.01 mm.

Table 16.2
Worked Example: Calculating an Estimate and its Standard Error

- A. An osteologist measures the buccolingual diameter of a tooth and gets a reading of 10.9 mm. **Measurement A = 10.9 mm**
- B. Time is allowed to pass (best if a few days) so that knowledge of the original measurement does not influence the remeasurement.
- C. The same investigator then remeasures the same tooth at 11.0 mm. **Measurement B = 11.0 mm**
- D. Time is again allowed to pass (best if a few days).
- E. The same investigator measures the tooth at 11.4 mm. **Measurement C = 11.4 mm**
- F. There are now three measurements. For the best estimate of the actual dimension of the tooth (x_{best}), calculate the mean (average) of these:
- add the three measurements **A + B + C = 33.3 mm**
 - divide this total by the number of measurements taken (n) **33.3 ÷ 3 = 11.1 mm**
- G. To assess the degree of error associated with your estimate of the metric, calculate the standard error of the mean:
- calculate the deviation of each measurement from the mean
- deviation of the first measurement from the mean **11.1 mm – 10.9 mm = 0.2 mm**
 - deviation of the second measurement from the mean **11.1 mm – 11.0 mm = 0.1 mm**
 - deviation of the third measurement from the mean **11.1 mm – 11.4 mm = – 0.3 mm**
- square each deviation
- square of the first deviation **(0.2 mm)² = 0.04 mm²**
 - square of the second deviation **(0.1 mm)² = 0.01 mm²**
 - square of the third deviation **(–0.3 mm)² = 0.09 mm²**
- calculate the sum of these squared deviations (the “sum of squares”) **0.14 mm²**
- calculate the standard deviation (σ)
- divide the sum of squares by ($n - 1$) **0.14 mm² ÷ 2 = 0.07 mm²**
 - σ is the square root of this quotient **$\sqrt{0.07 \text{ mm}^2} = 0.264575 \text{ mm}$**
 - the standard error of the mean (σ_M) is σ divided by \sqrt{n} **0.264575 mm ÷ $\sqrt{3}$ = 0.152752 mm**
 - report σ_M rounded to the proper number of significant digits **0.153 mm**

These results are then presented in the following form:

$$\text{Buccolingual diameter} = 11.1 \pm 0.153 \text{ mm}$$

By calculating and reporting the values in this way, the osteologist conveys a clear and unambiguous statistical message about what the actual value of the dimension is likely to be, how accurate (or repeatable) the measurements were, and what degree of precision was used in taking the measurements. Because the results are presented in an accepted, standardized, statistically meaningful way, the values can be plugged into other standard statistical equations. For instance, if we want to know with 95% certainty what the actual value is (assuming that the measurements taken have a normal distribution), we can easily calculate the 95% confidence intervals using the equations:

$$\begin{aligned} \text{upper 95\% limit} &= x_{best} + (\sigma_M \times 1.96) \\ \text{lower 95\% limit} &= x_{best} - (\sigma_M \times 1.96) \end{aligned}$$

Thus, we are able to say with 95% certainty that the actual value of the metric lies between 10.8 and 11.4 mm.

example, a short or “broad” skull has a higher index than a long, narrow skull. A selection of useful measurements and indices are listed in the “Measurements” sections in Chapters 4–13. In addition, Bass (2005) provides a concise guide to standard measurements and indices most widely used in human osteology, and Buikstra and Ubelaker (1994) recommend a set of 34 cranial and 44 postcranial measurements to be taken on intact skeletons.

Expression of skeletal element shape, or morphology, can be examined by univariate (single measurement), bivariate (two measurements), or multivariate (three or more measurements) statistics. The successes and failures of multivariate analyses in human osteology and paleontology are examined by Lovejoy (1978), Howells (1973), Frayer (1985), Reyment et al. (1984), and Corruccini (1978, 1987). The use of measurements such as linear distances, angles, and indices is commonly referred to as traditional morphometrics. Geometric, or modern, morphometrics is a collection of methods for acquiring and analyzing data that more fully retain geometric information about the shapes or structures under study; *eg.*, the Cartesian coordinates of landmark point locations. These data are most easily obtained via 3-D digitizers or scanners, or in two dimensions from dimensionally accurate digital photos. Bookstein (1991) and Rohlf and Bookstein (1990) provide introductions to the techniques of traditional morphometrics, and Dryden and Mardia (1998) offer an in-depth examination of the mathematical and statistical foundations of geometric morphometrics. Richtsmeier et al. (1992, 2002) provide a review of anthropological morphometrics. Lawing and Polly (2010) offer a good introduction to the modern application of geometric morphometrics to broader questions. Robb (2000) provides a good introduction to the tools that human osteologists will need to do more than just *acquire* data. The thoughtful and appropriate *analysis* of those data is not a trivial endeavor.

16.7 Photography

Osteologists use photography to provide an **archive** (record) of bony material and its context as well as to communicate information in publications and presentations. Maximizing the utility of photography in osteology assumes an understanding of the medium that goes beyond the abilities of the casual photographer.

The advent of digital photography has changed the face of scientific imaging and has all but supplanted the use of film. Digital imaging brings with it many benefits as well as a number of important considerations. Understanding the technology and the differences between digital and film photography is important. However, an adequate discussion of this is beyond the scope of this book. Trussel and Vrhel (2008) and Sedgewick (2008) provide comprehensive overviews of the fundamentals of digital imaging and digital image processing. Offered here are a few general considerations regarding photography in osteology.

16.7.1 Equipment

Several kinds of still-image cameras exist (*eg.*, point and shoot, single-lens reflex, rangefinder), but a single-lens reflex camera (SLR, or its digital equivalent, DSLR) will satisfy most situations in osteology. Unlike point-and-shoot cameras, SLR cameras feature interchangeable lenses, minimal shutter lag, and give the photographer full control over aperture, shutter speed, and focus.

DSLR cameras that use “full-frame” digital image sensors (similar to the 24×36 mm active area of 35 mm film) are referred to as “35-mm-equivalent” cameras. The focal lengths of lenses mentioned in this book apply to 35-mm-equivalent cameras. Users should note that many DSLR camera bodies use sensors that are smaller than “full frame” sensors, thus the effective focal length of these lenses will be greater than on a 35-mm-equivalent body. The effective focal length of a 35-mm-equivalent lens can be calculated by multiplying the focal length of the lens by the “crop factor” of the image sensor. Many high-quality DSLRs have crop factors of about 1.5×, giving an 85 mm lens an effective focal length of ~130 mm.

The ideal lenses for photographing osteological specimens are “flat-field” lenses — those with focal lengths about twice that of “normal” (70–120 mm). The optical qualities of these lenses produce a flat field of focus without the characteristic linear distortions of wide-angle lenses or the depth compression of telephoto lenses. A 105 mm macro lens is ideal for general-purpose osteological photography.

Lenses with macro-focusing capabilities (also called “close-up” lenses) are useful in documenting small specimens. These lenses allow the focal point of a lens to extend farther from the film plane, effectively enlarging the subject. For example, macro lenses with a 1:1 capability can record a tooth life-size on the film, thus maximizing detail.

High-definition (HD) digital video is becoming common in the field as camcorders get smaller and more affordable. Video tape has been the common recording media, but solid-state “flash” cards are increasingly found on video cameras.

Camcorders with progressive scan capability also have a single-shot mode that can serve as an emergency back-up for stills. Capturing a single video frame for use in print or still-image presentation from progressive scan is easier and at a higher quality than is possible from interlaced video. Single frame captures from interlaced video benefit from the application of a special ‘de-interlace’ filter in Adobe Photoshop™.

Equipment maintenance is extremely important in the field. Environmental considerations are often neglected until it is too late. Heat, sand, cold, and moisture all wreak havoc on camera equipment. Fungal growth on internal lens elements is common in very humid environments. Dry and windy conditions require diligent protection from blowing sand and the harsh effects of heat on equipment and media. Extreme cold can defeat batteries quickly in electronic cameras. Lithium and other specialized batteries may be difficult to find away from cities. All of these concerns are exacerbated in digital photography. There is no mechanical backup solution in digital photography. For workers involved primarily in remote field work, a mechanical film camera is still necessary, at least for backup.

16.7.2 Exposure and Film (or other Recording Media)

The sensitivity of film and digital sensors to light is rated by an ISO number — a higher number means it is more light-sensitive. In film photography, one chooses a film with a particular ISO according to anticipated conditions. If conditions change, one is constrained by the limits of that film until the entire roll is exposed and developed. In digital photography there is no developing. The desired ISO for the conditions can be dialed in and adjusted at any time.

The interrelationship of ISO, lens aperture, and shutter speed matters in a correct exposure. Good photographers are aware of this three-item juggling act at all times, even with the sophisticated metering schemes in many cameras. The “sunny 16” rule serves as a practical starting point. It means that on a clear sunny day with a lens aperture of $f/16$, the shutter speed will equal the ISO rating of the film.

- **Lens aperture** controls how much of the subject closer to or farther from the camera is in focus (depth of field), as well as the *amount* of light that reaches the film. Small apertures create a greater depth of field, but less light gets through. Large apertures cause more of the foreground and background to be out of focus. Because the aperture (or f-stop) is expressed as a ratio of the diameter of the hole to the focal length of the lens, $f/22$ is smaller (less light) than $f/4$.
- **Shutter speed** controls how the motion of the subject is recorded and the *duration* of the exposure. A bone in the sand affords a slow shutter speed in order to achieve a small aperture for greater depth of field. However, hand-holding the camera at a slow shutter speed can cause camera shake and a blurred image. The rule is: hand-hold only with a shutter speed number larger than the focal length of the lens. This means 1/125 sec. with a 105 mm lens. Slower shutter speeds require the use of a tripod to insure a sharp image.

- **ISO** is all about the *sensitivity* of the media. Cloudy days and photographing in shadows require higher sensitivity. Low-ISO films contain finer grains of light-sensitive crystals that produce sharper images with higher contrast, but require longer exposures, wider apertures, or both. High-ISO films are faster, but can be grainy, flat in contrast, and preserve less detail. In digital photography, lower ISOs are optimal. Highest-ISO settings only amplify the signal from the sensor. This can produce digital “noise”—undesired random pixels scattered about an image. Most professional cameras have an ISO range up to 1600 or 3200, then offer a couple of higher settings referenced as H1 and H2. It is in these additional settings where the camera sensor’s abilities are “pushed” and digital artifacts can be introduced into the image.
- The marked full steps of aperture, shutter speed, and ISO on most cameras and lenses double or halve the exposure with each step. From f/16 to f/11 doubles the light through the lens; from 1/125 sec. to 1/250 sec. the duration of the exposure is cut in half; and a film rated at ISO400 is twice as sensitive to light as ISO200.
- Use of a **gray card** (18% reflectance) is the best way to set a proper exposure in most conditions. Light meters are calibrated to this standard. You can meter from the camera filling the viewfinder with the gray card or you can point a hand-held light meter at an evenly-illuminated card (devoid of shadows or glare). Gray cards are available at any camera store catering to the professional and can be cut down to a convenient pocket size.

Digital photography offers huge advantages over film while traveling. Film — of any ISO, exposed or unexposed — should never be x-rayed despite what signs may say on the machines at security check points. Exposure to airport x-rays are cumulative and affect faster ISO films the most. Do not leave film in checked luggage as x-ray machines used to scan checked luggage often use higher doses of x-radiation. Always have film hand-checked at security. X-rays do not affect digital images or storage media, though strong magnetic fields may corrupt some digital media.

Lower-end digital cameras record images only in JPEG format, usually with an option of high-, medium-, or low-quality compression ratios. JPEG is a “lossy” algorithm that discards information as it compresses files. It can introduce artifacts into an image which are compounded with each compression/decompression. Though not meaningful in snapshots, these can have ramifications in critical science photography, particularly images used as forensic evidence. The universal workhorse TIFF format is available on many cameras, but produces larger files. Professional cameras can record in 12-bit “camera RAW” format that produces huge files. This uncompressed format contains all the information captured by the camera without in-camera image processing. It includes time, date, frame number, lens, and exposure information. It can be customized to include other information such as distance to the subject and GPS latitude/longitude data.

Pristine image data in RAW files provide the greatest flexibility. However, RAW files require processing down the line, including sharpening and adjusting contrast and color levels. It takes some practice to get the technique correct. Nikon, Canon, and other professional lines offer proprietary software designed to simplify processing RAW images. Similar results are obtainable using Adobe Photoshop and Apple’s Aperture. Good cameras have the option of recording a RAW image and a processed JPEG image at the same time. This is the best of both worlds. It captures the maximum amount of image data while providing an immediately usable image.

A variety of capture media exist including Memory Sticks™, Microdrives®, and wireless connections to computer hard drives. CompactFlash (or CF) cards are proving to be robust and safe storage devices. CF card capacity keeps expanding each year. They range from 2 MB to 128 GB. As media technology advances, the high-capacity cards become increasingly faster at recording and downloading. This is important for large image files or a “burst” exposure sequence. A slow media card can pause shooting at critical moments as it accepts data from the camera’s processor.

Images on memory devices in a camera are easily downloaded to a computer hard drive directly from the camera, typically using a USB cable, or via a separate multi-format card reader. It is important to archive digital images on CDs or DVDs at their maximum quality before editing.

Slides and negatives should be stored in polypropylene sleeves. Metal boxes for slides and glassine envelopes for negatives are acceptable. Avoid using vinyl slide sheets as the off-gassing of

the vinyl will destroy dyes on film. Rare and valuable images, both prints and slides, should be duplicated and/or scanned and then locked away under archival conditions. Repeated projections of slides and exposure of all film and prints to the elements degrades their quality over time.

16.7.3 Lighting and Setup

Proper orientation and lighting separate the professional-looking photograph from snapshots. Tripods and electronic flashes are fundamental for good photographs. Field photography primarily relies on available natural light, but the quality of light changes with weather and time of day. Photographs taken very early or late in the day often involve shadows that can be mitigated with an electronic flash. Fill flashes can reveal detail in deep mid-day shadows and reduce harsh image contrast. White cards, T-shirts, and crumpled aluminum foil can be used to bounce softer light into dark shadows. Manipulating light to come from the side of a subject will emphasize detail and texture. An off-camera flash sync cord is convenient for this purpose. A straight-on flash will “flatten” an image by eliminating most shadows. Ring flashes are used in forensic and medical photography for flat, even illumination.

A little thought about setting up shots will improve their value. Backgrounds should contrast with the subject. Spraying water lightly on the matrix around fossil bones *in situ* helps create contrast. In the lab, black or gray velvet or felt backgrounds improve color accuracy. Specimens can be stabilized and presented in a proper plane of reference with things as simple as a set of rubber washers. Avoid oil-based clays that contaminate specimens. A reference scale should appear with all specimens. Geological hammers, coins, and lens caps are poor substitutes for an easy-to-read metric scale. A scale is most useful when raised to the focal plane of the important part of the subject.

16.7.4 Legal and Ethical Considerations

Photography can be a powerful tool when an osteologist is called upon to serve as an expert witness (see Section 17.3). All photographic evidence presented in court is subject to cross-examination, including the manner in which it was acquired, archived, and reproduced. “Admissibility” of evidence is different from “weight” of the evidence. Some jurisdictions question the admissibility of digital photography due to the ease of manipulating the image, preferring film-based images instead. Others simply consider that all photography goes to the “weight” of the evidence.

If it is expected that your photography will be used to support opinions in a legal context, the best practice is to shoot film to establish a basic record and then take advantage of the flexibility and convenience of digital photography. A “throw-away camera” is often sufficient in this regard, constituting inexpensive insurance. As attorneys and courts become more aware that forensic image analysis can identify manipulated digital images, they are less likely to challenge digital pictures when they are initially captured in RAW format and backed up with conventional film.

Concerns have been raised in both academia and government about the manipulation of digital images and how it relates to data integrity. Image manipulation is not the same thing as image falsification—sharpening an image or making tonal adjustments are important parts of basic image processing. However, the ease of manipulating and recomposing images with image editing software like Photoshop has raised serious concerns among science ethicists and journal editors (Pearson, 2005). In 1989–1990, prior to the introduction of Photoshop, the U.S. Office of Research Integrity (ORI) reported that only 2.5% of investigated allegations involved images (Krueger, 2002). The percentage of image-involved cases steadily increased through the 1990s, reaching 14.3% in 1999–2000. The absolute and relative frequency of image manipulation cases continued to grow in the 2000s, hitting 30.3% in 2001–2002, 44.1% in 2005–2006, and reaching 68% in 2007–2008 (Krueger, 2008, 2009; Gilbert, 2009).

The editors of *The Journal of Cell Biology* examined the images in every paper submitted from 2002 to 2006 (NAS, 2009). They found that over 25% of all received manuscripts contained at

least one inappropriately manipulated image, although 95% of these were determined to be innocent of fraudulent intent.

The growing epidemic of inappropriate image manipulation has led many journal editors to develop image manipulation guidelines (e.g., Scott-Lichter et al., 2009). The editors at Rockefeller University Press (Rossner and Yamada, 2004) established four basic guidelines which have subsequently been adopted by many other journals (Scott-Lichter et al., 2009):

1. No specific feature within an image may be enhanced, obscured, moved, removed, or introduced.
2. Adjustments of brightness, contrast, or color balance are acceptable if they are applied to the whole image and as long as they do not obscure, eliminate, or misrepresent any information present in the original.
3. The grouping of images [from different parts of the image or from different images] must be made explicit by the arrangement of the figure (e.g., dividing lines) and in the text of the figure legend.
4. If the original data cannot be produced by an author when asked to provide it, acceptance of the manuscript may be revoked.

In addition, several major journals have adopted a fully digital workflow in order to be able to examine all submitted images for signs of improper manipulation (Gilbert, 2009; NAS, 2009). For readers of journals that have not yet implemented image verification procedures, ORI offers free forensic tools for detecting manipulated images at <http://www.ori.dhhs.gov/tools/>. Due to the nature and scope of the problem of image manipulation, Krueger (2008) notes that manuscript review now essentially “extends to all, includes the public, and lasts indefinitely!”

Archiving unaltered RAW digital images (or even taking a few film shots) is a necessary measure should you ever need to defend the integrity of images used to tell an important story. Suffice it to say, immense caution is warranted when one chooses to modify an image to enhance a scientific point. See Gilbert and Richards (2000) for a discussion of digital imaging of bone modification and the ethical question of digital alteration.

16.8 Radiography

Analysis of bones in the living individual is usually accomplished by exposing a film to x-rays passed through the body part. The bone tissue blocks some x-rays, resulting in a negative image on the film called a **radiograph**. Because bones, including internal parts of bones, block some of the rays, the radiograph can be a valuable aid in diagnosing bone conditions in medicine.

Standard radiography is also a valuable tool for the osteologist. Because there is no risk to a dry bone specimen, various exposures and orientations may be made to show the internal architecture of a bone or the developmental status of an unerupted dentition. Osteologists often use fully enclosed x-ray devices within shielded, benchtop cases with external controls (Faxitron® or other). The specimen should be oriented so that the x-ray beam passes through the center of the area of interest and so that this area is perpendicular to the beam and parallel with the film plane. The specimen and film should be as far as practical from the x-ray source and as close to one another as possible. Computer-assisted enhancement of radiographs may be useful after processing (Odwak and Schulting, 1996). The development of computed tomography (CT) scanning adds a potent bone-sectioning tool to the osteologist's kit. Medical (or clinical) CT scanners are usually only found in dedicated rooms in hospital radiography departments, and their use requires collaboration with personnel therein.

Radiographic technologies originally developed for industrial purposes have even better resolution and can be used in a variety of settings. As these technologies and methodologies mature, the potential applications of radiographic analyses are increasing. The ability to take accurate measurements from radiographic images or their derivatives is one example. With industrial CT

scanning (also called microfocal CT or micro-CT scanning), accuracies of less than one tenth of a millimeter are routine. Spoor et al. (1993) discuss applications and problems involved in the derivation of osteometric data from CT scans. Olejniczak and Grine (2006) examine enamel thickness measurements from micro-CT scans and find them accurate except when the enamel is less than 0.1 mm thick and/or in heavily fossilized teeth. Suwa and Kono (2005) caution that buccolingual locations of enamel thickness measurements must be carefully selected, and molar position carefully controlled, to ensure accurate results. Olejniczak et al. (2007) verify that dental measurements taken with different types of micro-CT scanners are comparable unless the teeth are heavily fossilized.

Rühli et al. (2007) compare the utility of micro-CT scanning to traditional histological sectioning for pathological diagnosis. They conclude that micro-CT has several advantages over sectioning, but because of the difficulty inherent in differentiating woven from lamellar bone with micro-CT scans, both techniques should be used for best results. Robinson et al. (2008) explore the forensic and research potential of taking osteological measurements from 3-D reconstructions of undefleshed remains, and find the accuracy comparable to traditional measurements of the same bones, once defleshed. Recently, even more powerful synchrotron-based scanning has provided microscopic resolution on osteological and dental remains. The biological effects of such scanning on tissues with residual organic molecules have only recently begun to be assessed, but it is already clear that the more ionizing radiation a specimen receives, the more damage it will incur. The fact that damage assessment is coming only after so many rare specimens have already been subjected to high radiation loads is of considerable concern in an era when more and more can be learned from the molecules at risk from such procedures.

When possible it is always better to make observations and take measurements directly from the specimen. This is because measuring from a radiograph or CT scan greatly increases the chance that matrix, clothing, distortion, or erosion will be overlooked and inaccurate measurements generated. To use any of these techniques in investigating human skeletal material, consult a specialist in radiography. See Ortner (2003), Hillson (1996), and Bruwelheide (2001) for discussions of radiography in osteological and dental analyses, and Mafart and Delingette (2002) and Mafart et al. (2004) for applications of three-dimensional imaging in paleoanthropology and prehistoric archaeology.

16.9 Microscopy

Fine details on the surface of a bone or tooth may be best investigated with a binocular dissecting microscope. Intense, unidirectional light sources can be used to emphasize microscopic detail. For discriminating between various kinds of surface alteration on bones (root marks, cut marks, pathology), the binocular microscope is a most valuable aid. To photograph microscopic structure or trauma on the surface of a bone, the scanning electron microscope (SEM) can provide excellent images with great depth of field. For large specimens that do not fit in the vacuum chamber of the microscope, or for specimens housed in institutions without SEM facilities, it may be necessary to replicate the surface of the object by molding it with dental impression rubbers and pouring an epoxy positive for use in the analysis. For work on bone or tooth surfaces at high magnification, the SEM has been the traditional tool of choice (and, unfortunately, expense), but alternative digital imaging technologies may change this (Ungar et al., 2003; Gilbert and Richards, 2000).

Standard histological microscopic techniques, micro-CT, or synchrotron scans are used to study the microscopic structure of bone below the surface or the internal structure of teeth (Hillson, 1996). Schultz (1997a, b) provides two reviews of how microscopy can be applied in human osteological studies. Mahoney (in press) illustrates the richness of growth data available through a microscopic examination of deciduous molar enamel. Histological age determination using light microscopy is becoming a reliable tool in the osteologist's toolkit (Section 18.3.11). The diagnostic value of microscopy in paleopathology is well-established (see Chapter 19).

16.10 Molding and Casting

Casts of skeletal material are used in osteology and paleontology for several purposes. They provide a good three-dimensional archival record of the object under study (Mann and Monge, 1987; Smith and Latimer, 1989). In addition, they are useful in communicating findings with colleagues and for slicing into cross sections for comparative purposes. Specialized techniques and materials used in molding and casting teeth are outlined in Hillson (1992, 1996). Several molding methods may be used for bones, depending on the needs of the investigator. Some of the more common molding methods and materials are listed here:

- **Alginate impression material.** Powders mixed with water form material that dentists use to make impressions of teeth. Alginates are good for making quick, one-sided molds and are widely available, inexpensive, and easy to use. They are not recommended for holding very fine detail or for the production of more than one or two casts. The molds deteriorate within days even when kept moist.
- **Latex rubber molds.** This material gives higher resolution and the ability to make two-part molds. The material is more expensive than dental impression compounds but lasts much longer.
- **Silicone molds.** Silicone elastomers come in three basic varieties: alcohol-based evaporative cure silicone, tin-catalyzed condensation cure silicone, and platinum-catalyzed addition cure silicone. Platinum-catalyzed silicones like Dow Corning's Silastic are the material of choice for mold detail and longevity. This material, however, is the most costly and can be time-consuming to use.
- **Polyvinylsiloxane impression materials.** Quick-setting, auto-mixing, injectable, flowable impression materials widely used in dentistry and in making void-free, high-fidelity, long-lasting molds. Commonly used for making molds for epoxy casts to be used in the scanning chamber of scanning electron microscopes.
- **Dental putties.** Two-part putties that are kneaded together by hand (parts are usually differently colored to aid in mixing) and used to make quick-setting impressions of small portions of bone surfaces.

Once removed from the original specimen, the resulting mold represents a three-dimensional "negative" of the original. If a self-hardening material is introduced to the mold and allowed to set or cure, the flexible mold can be carefully peeled away from the hardened cast to reveal a three-dimensional replica (or cast) of the original specimen. With a little care, the mold can be reused to make numerous additional casts.

As with molds, many kinds of materials can be used to make casts. The easiest casting material to use is plaster, which comes in many varieties. Some of the most common casting materials include the following:

- **Plaster of Paris.** Common Plaster of Paris is ubiquitous and inexpensive but it is soft and easily scratched, and it does not capture detail well.
- **Dental stones.** High-strength, fine-grained gypsum cements (dental stones) are harder, especially when mixed with hardeners instead of water. The resulting casts are quite hard, but also brittle, and can shatter if dropped. Detail on casts in these materials can be excellent, shrinkage is minimal, and the material is inherently stable once set.
- **Polyurethane plastics.** Polyurethane plastics are made by mixing two monomers together, usually in equal volumes. The monomers react by cross-linking, a process which ends in a hard plastic cast. Polyurethanes are not as stable as dental stones, and can degrade when exposed to direct sunlight or to organic solvents.
- **Epoxyes.** Epoxyes are thermosetting plastics that are activated by combining a resin and a hardener. Depending on the formulation, they can set quickly (generating a lot of heat)

or very slowly (producing minimal heat). Epoxies are commonly used for making casts of teeth for use in scanning electron microscopy.

There are various techniques for coloring casts of all materials to bring out detail. Most involve a vehicle such as alcohol for dissolving and spreading artists' pigments. Artists' fixatives and spray lacquer add a long-lasting, appealing, and protective finish to the final product.

Both computerized tomographic (CT) scanning and 3-D laser scanning can be combined with stereolithographic output to allow osteologists to perform "digital molding and casting" of hard tissue specimens, with the added benefit of revealing internal structure (Mafart et al., 2004; Mafart and Delingette, 2002).

16.11 Computing

The computer revolution continues to impact all areas of science, including human osteology. Satellites communicate with hand-held GPS (Global Positioning System) receivers to determine precise location (increasingly expressed in UTM or MGRS coordinates or in conventional latitude and longitude as decimal degrees or degrees and decimal minutes). Ruggedized laptop computers connected to electronic distance-measuring devices allow laser-precision in plotting specimens in the field. Desktop computers receive, process, and output our thoughts, our data, and our images. 3-D laser scanners connected to computers allow the external form of objects to be imaged in three dimensions, imported to the computer, and manipulated digitally in many ways (Figure 16.6). Computerized medical imaging allows us to peer deep within osseous structures to see formerly hidden evidence of ancient pathology. The exploding global communications network makes it possible to exchange ideas and data rapidly across international frontiers and between field and laboratory. As a result of all of these developments, it is impossible to think of working in human osteology without the aid and working knowledge of computer technologies.

In addition to basic word-processing skills and the programs necessary for scholarly communication, all osteologists should learn the basics of database and spreadsheet programs that allow for the rapid and easy manipulation of large osteological data sets. Unfortunately, human osteologists have not been immune to the false hope that computers and technology can replace real specimens and real expertise. The current high-tech craze has created some interesting exercises. For example, bones have been imaged by CT and laser scans, input to desktop and mainframe systems, manipulated therein (with attendant beautiful colors and bones floating and rotating in space), and then copied by sculpting the digitized bony form into plastic with stereolithography. Some such exercises are useful to surgeons customizing prosthetic devices and to investigators assessing fragile remains in matrix (Lynnerup et al., 1997). However, some of this high-tech wizardry applied to archaeological and paleontological specimens leaves the observer to conclude, "That was really awesome, but so what?" Computers can do incredible things, but they are tools that help us investigate, organize, and document. They do not substitute for our own imagination or critical judgment when assessing osteological remains.

16.12 Reporting

After the usually unpublished initial field reports are submitted to granting agencies and various governmental regulatory agencies, published reporting of hominid osteological remains from paleontological contexts often occurs in three stages: first, announcement in a prominent international journal such as *Science* or *Nature*, followed by anatomical description in a more specialized journal such as the *American Journal of Physical Anthropology*, and finally, usually years later, full monographic treatment. Basic metric, preservational, and contextual data are reported, along with interpretations, in all three publication venues.

In forensic human osteology, the reporting of skeletal remains usually follows a different series of steps. Here, because of the rigorous procedures adopted by law enforcement agencies and medical examiners (Komar and Buikstra, 2008), the osteologist's report becomes part of the legal record instead of moving straight toward publication. Whereas brevity and conciseness are required for the publication of osteological reports, clarity and thoroughness are of primary importance for the final reports of forensic anthropologists.

There is not a single format for forensic reporting in the United States, but such reports typically follow the standards set forth in Buikstra and Ubelaker (1994), are written in a narrative style, and usually follow the format of the JPAC Central Identification Laboratory (JPAC-CIL, 2008). In the analysis of a single set of remains, a forensic anthropologist may generate 10–20 pages or more of inventorial, observational, osteometric, and diagnostic data, usually on forms (data sheets) similar to those reproduced in the Appendix of Buikstra and Ubelaker (1994). These data sheets, along with a 3–5 page narrative summary, comprise the final report of the forensic anthropologist. The cases included in Steadman (2009) provide a good overview of the range of cases in which a forensic osteologist might be asked to participate.

In a forensic setting, the pressure for accurate and immediate reporting is sometimes very intense. Osteologists may be forced to conduct their examinations in suboptimal conditions—at morgues, in criminal laboratories, and even in refrigerated trucks or warehouses at the disaster scene. Pressure may come from the sensitivity of the case, from relatives wishing to conduct funerary rites, or from law enforcement agents requiring quick answers to pursue their investigations or hold their suspects. Under these conditions of inadequate facilities (including inadequate comparative materials) and intense pressure, osteologists are more prone to make mistakes. Suffice it to say that there is no tolerance for such mistakes in a forensic context, whatever the conditions. The osteologist should always state only what is defensible in a court of law, keep speculation to a minimum, and work closely with others on the multidisciplinary investigation team.

In archaeological osteology, the collaborating archaeologist and osteologist usually work out a reporting procedure in advance of the excavations and determine what information should be made available in reports or publications. The publication of the volume *Standards for Data Collection from Human Skeletal Remains* is a milestone in the standardization of data collection for osteological remains from archaeological contexts. This 1994 volume, realized only under the pressure of federal legislation forcing imminent destruction of osteological collections (see Chapter 17), contains a series of chapters and appendices (inventory forms for adult and immature remains) that provide a framework for the observation and recording of osteological attributes. It is an invaluable resource for the osteologist practicing in an archaeological context.

The following points are offered as a general guide to reporting on human osteological material. Most osteological reports, particularly in forensic settings, cover the points outlined here:

- **Introduction.** The osteologist should note when and how first contact was made regarding the case. The nature of the materials received or observed should be noted here. Any steps taken by the osteologist to preserve or otherwise alter the material should be outlined.
- **Bones present.** This is simply a listing of what bony remains were analyzed, sometimes with MNI determinations and their explanations included.
- **Context and condition of the remains.** This is particularly important in forensic and archaeological work. Note should be made of the context in which the bones were found. Remember that all of the remains received for analysis constitute evidence, often crucial and always irreplaceable. In particular, any cultural or biological remains associated with the bones should be noted. Soft tissue adhering to the bones should be described. Before removal of any soft tissue remains, check with a forensic pathologist about sampling of this material. Any soft tissue present should be radiographed extensively before removal to check for objects within (bullets, clothing, etc.). Never dispose of any associated material without consulting the officials involved in the investigation.

- **Pathology.** Assessment should be limited to the hard tissue. Note any evidence of bony pathology and leave the soft tissue to other experts. Note healed fractures and other osteological manifestations of disease.
- **Anomalies.** Report anything unusual about the skeletal remains, such as supernumerary digits or other nonmetric traits. These facts may help in individuation. In assessing radiographs, note any features that might be compared to antemortem films and thereby establish identity.
- **Trauma.** Report any signs of osteological trauma, ranging from healed fractures to excavation-related fractures. Try to determine how recent the fractures are by noting evidence of healing, color differences, or root-mark etching on broken surfaces. Express an opinion on whether the bone was fresh when broken (perimortem fracture) or dry (postmortem or 'nonvital'). Distinguish between pre- and post-depositional trauma when possible (Maples, 1986).
- **Age, sex, race, stature, and weight.** For these, be as specific as possible, but do not give estimates whose precision is not warranted. Give the appropriate limits of confidence in all determinations. Tell what methods were used to make the estimates and why these methods were used.
- **Time and cause of death.** Osteologists are almost never able to make these estimates with certainty. Whereas experienced investigators may speculate on time of death by using odor, grease, tissue, or bone weathering, these attributes all vary according to temperature, humidity, and cover. And how can the osteologist examining a gunshot through the head know that the victim was poisoned before being shot? For these reasons, the osteologist must work closely with a professional forensic pathologist and strictly avoid speculations about death based on bony evidence in isolation. By studying healed lesions the osteologist can sometimes say whether a person survived a skeletal trauma, but unhealed lesions often do not, by themselves, indicate the cause of death. The osteologist's legal contribution is usually limited to identification, sometimes including individuation. The skeleton itself gives little evidence relevant to questions about the time and cause of death.
- **Personal Identification.** This is the determination of the personal identity of the remains. The best hope for individuation, without soft tissue indicators such as fingerprints, is in dental records. For skeletal material lacking dental evidence for individuation, it is often possible to match pathological lesions or antemortem photographs or radiographs with postmortem images of the bone. Positive identifications may be based on old fractures or discrete trabecular or sinus patterns (Webster et al., 1986). See Wilkinson (2004) and Reichs and Craig (1998) for discussions of techniques used in facial "reproduction" (approximation) from a dry skull. Techniques for digital facial reconstruction are explored in Clement and Marks (2005). Individuation is often important in legal and insurance matters.
- **Metrics and nonmetrics.** Report standard dental, cranial, and postcranial measurements, as well as observations of nonmetric traits.
- **Summary.** Simply summarize the most significant conclusions reached for the sections given here.

Osteological findings of general interest are usually reported in a scientific publication that makes data available to the scientific community as a permanent record. In describing the results of osteological analysis, communication must be unambiguous. The osteologist should specify exactly what materials were analyzed, what procedures were used in the analysis, and what results were achieved. Most scientific publications have basic sections of "Introduction," "Materials and Methods," "Results," "Conclusions," and "Bibliography." Scientific papers on human osteology are found frequently in book or monograph form as well as in journals such as the *American Journal of Physical Anthropology*, the *International Journal of Osteoarchaeology*, *Forensic Science International*, and the *Journal of Forensic Sciences*.

16.13 Curation

During the initial processing of skeletal material, it is advisable to label all bones individually with a prefix designating the site and a number representing the skeletal individual. For example, ARA-VP-1/1 is a specimen number for the first vertebrate paleontological specimen from the first locality collected in the Aramis area of Ethiopia in 1992. It is crucial that this labeling be legible, with numerals that anyone can read. Be very careful not to confuse 9s with 2s or 1s with 7s. Specimen numbers should be written in permanent, waterproof ink and protected with a layer of B72 once the ink is completely dry. For softer bones, it may be necessary to let a drop of consolidant dry and harden on the bone surface before putting the label on the bone. This treatment prevents the ink from diffusing into an illegible blob. Specimen numbers are essential; they represent the critical links between bones and information on their original context. Mixing of labeled material is very bad practice in the laboratory, but mixing of unlabeled material is often irreversible, and therefore unforgivable. Labels should be put on bones early in the curatorial process.

There are two main objectives of curation. The first, as in other steps outlined earlier, is to prevent loss of information. Information loss can come in the form of actual physical destruction of the bones and teeth, in the mixing of unlabeled elements in the collection, or in the loss or destruction of the records (paper or digital) for the skeletal material. Almost all simple breakage of bones can be repaired with glue. The objective of curation, however, is to prevent breakage in the first place by handling and storing bony material properly. Untrained or unqualified persons should not handle osteological material without supervision. Metric or photographic analysis of material should not be allowed to damage the specimens. Bones are fairly tolerant of a range of storage conditions, but their containers (boxes, trays, bags, padding) should be composed of a nondeteriorating, acid-free material. Bones should be stored in areas in which humidity, incident light, and extreme temperatures are kept to a minimum. Steps should be taken to see that insects and rodents are kept away from stored skeletal material and records. To prevent accidental loss of records from flooding, fire, or theft, it is advisable to make a copy of all skeletal records (either digitally or as a hard copy) and to store this copy in a separate location.

The second major role of curation is the provision of research access to the collection. To provide this access, it is necessary to impose and maintain a high degree of organization in the skeletal collection. A researcher should be able to move quickly and efficiently between the bony remains and their records. Computer databases are important, not only for collection organization, but also as a means of enhancing research access. Cassman et al. (2007) and Caffell et al. (2001) provide overviews of curatorial procedures and problems in human osteology.

Suggested Further Readings

Adams, B. J., and Byrd, J. E. (Eds.) (2008) *Recovery, analysis, and identification of commingled human remains*. Totowa, NJ: Humana Press. 374 pp.

This edited volume covers techniques used in MNI determinations and forensic individuation. Methodologies covered include contextual analysis, sorting, statistics, GIS, radiology, and DNA analysis. The volume focuses on forensic contexts but includes several archaeological case studies.

Buikstra, J. E., and Ubelaker, D. H. (Eds.) (1994) *Standards for data collection from human skeletal remains*. Fayetteville, AR: Arkansas Archaeological Survey Report No. 44. 206 pp.

The essential osteological standards volume in North America.

- Chhem, R. K., and Brothwell, D. R. (2008) *Paleoradiology: Imaging mummies and fossils*. New York, NY: Springer. 163 pp.
Six chapters cover the current developments and history in the field of radiology and CT imaging of both paleohuman and nonhuman subjects. Includes advice on protocols, techniques, expected error, and interpretation of radiographic data.
- Hillson, S. (1996) *Dental anthropology*. Cambridge, UK: Cambridge University Press. 373 pp.
Appendix A provides a good guide to field and laboratory methods used to extract, dissect, replicate, image, section, and preserve dental remains.
- Katzenberg, M. A., and Saunders, S. R. (Eds.) (2008) *Biological anthropology of the human skeleton* (2nd ed.). Hoboken, NJ: John Wiley and Sons. 680 pp.
Introduces numerous osteological subspecialties, illustrates their methods and presents case studies for each. Covers the history, new directions, and tools for each field.
- Mead, E. M., and Meeks, S. (1989) Photography of archaeological and paleontological bone specimens. In: R. Bonnicksen and M. H. Sorg (Eds.) *Bone modification*. Pp. 267–281. Orono, ME: Center for the Study of the First Americans.
This paper has a special orientation to the photography of bones and is therefore of value to the osteologist.
- Morton, R. A. (Ed.) (1984) *Photography for the scientist* (2nd ed.). London, UK: Academic Press. 542 pp.
A complete guide to the subject, with many advanced techniques.
- Reichs, K. J. (Ed.) (1998) *Forensic osteology: Advances in the identification of human remains* (2nd ed.). Springfield, IL: C. C. Thomas. 567 pp.
Trauma analysis is covered in Section VI, and Section V covers aspects of building a biological profile. There are also chapters on facial approximation and the use of statistics in forensic anthropology.
- Schwartz, J. H. (2006) *Skeleton keys: An introduction to human skeletal morphology, development, and analysis* (2nd ed.). New York, NY: Oxford University Press. 416 pp.
General textbook for osteology. Includes a CD-ROM with photographs of skeletal elements, growth series, and examples of peri- and post-mortem trauma.
- Slice, D. E. (Ed.) (2005) *Modern morphometrics in physical anthropology*. New York, NY: Kluwer Academic/Plenum Publishers. 384 pp.
An introduction to anthropological morphometrics and its potential applications, as well as a review of 20 years of methodological improvements.
- Smith, J., and Latimer, B. (1989) A method for making three-dimensional reproductions of bones and fossils. *Kirtlandia: Journal of the Cleveland Museum of Natural History* 44:3–16.
A good introduction to molding and casting techniques used with modern and fossil osteological material.
- Steadman, D. W. (Ed.) (2009) *Hard evidence: Case studies in forensic anthropology* (2nd ed.). Upper Saddle River, NJ: Prentice Hall. 360 pp.
An engaging and well-illustrated collection of 25 case studies, presenting a wide range of forensic situations addressed with current and often innovative approaches.
- Urdan, T. C. (2010) *Statistics in plain English* (3rd ed.). New York, NY: Routledge. 223 pp.
An approachable introduction to statistical principles and methodology.

Chapter 17

ETHICS IN OSTEOLOGY

ETHICS IS THE STUDY OF STANDARDS OF CONDUCT and moral judgment. Ethics also refers to any system of values that specifies a code of conduct. There are multiple human value systems, however, each with its own notions of what is considered right and wrong. These notions are cultural constructs, so what might be ethical for a scientist, for example, might be unethical for a religious leader, and vice versa. Different ethical systems collide across the spectrum of osteological endeavors—from the forensic, to the archaeological, to the paleontological. Historical perspectives on the subject of ethics in human osteology are provided by Walker (2008a), Alfonso and Powell (2007), Turner (2005), and Ubelaker (2000).

Professionals who study human skeletal remains are frequently called on to make judgments about ethics. For some osteological issues there are no easy answers and no prescribed codes of conduct to guide the practitioner. For most issues, however, ethical guidance can be found. This chapter examines some of the ethical standards particular to osteology.

Human osteologists are routinely called on to practice in the glare of the media spotlight and within legal, political, social, and economic arenas where science may be misconstrued and misrepresented. Whether the issue is the number of perished individuals in the Branch Davidian compound at Waco (Owsley et al., 1995), the nature of trauma to the soldiers who died with Custer at the Little Big Horn (Scott et al., 2002), or the ancestry of an individual who died thousands of years ago at Kennewick (Burke et al., 2008), the human osteologist is obliged to be guided by facts and the scientific approach rather than by speculation, superstition, economics, preconception, or political expediency.

17.1 Ethics and the Law

Ethical behavior and legal or law-abiding behavior are not necessarily synonymous. However, because of the often high social costs of unethical behavior and the potential social benefits of ethical behavior, guidelines for ethical behavior often overlap with the legal dictates. The student of osteology is advised to become familiar with osteologically relevant laws. For instance, for an osteologist working in the United States, in the state of California, these laws include:

- NAGPRA: the Native American Graves Protection and Repatriation Act of 1990.
- ARPA: the Archaeological Resources Protection Act of 1979.
- CEQA: the California Environmental Quality Act.

Laws offer general guidance as to what must — *at a minimum* — be done, as well as what must definitely *not* be done in a given situation. Laws offer institutions and individuals a neatly specified minimum course of action which, when followed, allows the individual (or institution) to stay on the right side of the law and to claim that they have done everything legally required of them. Keep in mind that laws usually specify minimal requirements, not ideal courses of action or even best practices. Laws often fall short of specifying what the ethically (or professionally) most appropriate course of action should be.

To illustrate this point, we can take an example from archaeology. When archaeologists working for a cultural resource management (CRM) firm encounter human remains during excavation in California, they are legally obligated to contact the “Most Likely Descendent” (or MLD) as defined in California statute. The archaeological team may also be guided by ethics, such as those outlined in Walker (2008a), and may wish to go beyond the law and create working relationships with the MLD or other interested or potentially impacted parties prior to any excavation. Incorporation of multiple viewpoints before or after the discovery of skeletal remains may not be required by law, but it is an ethically, politically, economically, and logistically advantageous approach, and one that may also bring benefits ranging from continued research in the region to the integration of ethnohistorical data into the interpretive process.

17.2 Respecting the Dead: Appropriate Individual Behavior

The most elemental and most controversial part of working with the dead involves the physical handling and care of their remains. Many cultures, such as the Navajo and Maori, have taboos against their members even touching the dead. Other cultures, such as Orthodox Jews and traditional Chinese, prohibit the dissection of the whole body. For hundreds of years Western Medicine was held back by the Christian belief that the body must remain whole and uncut in preparation for the Resurrection.

Each human, each student, and each professional will bring with them their own beliefs about how bones relate to what was a once-living person. Respect is a subjective concept and one which can be difficult to define when applied to multicultural collections of human remains. Even when the identity and cultural background of the remains are unknown, there are commonly accepted ethical ways of approaching how they are treated. Chief among these is comporting oneself in a respectful manner when in the presence of the dead. Any conduct that is disrespectful in a graveyard will be just as offensive in the presence of the remains you are working with.

Some cultures request the use of gloves to create a barrier between the bones and those who handle them. Covering and/or placing the remains into storage when they are not in use is both respectful and a safe practice. Markers used during analysis can be temporary, for example — teflon ribbon and polytetrafluoroethylene (PTFE) tape both make use of static cling rather than adhesives (Cassman and Odegaard, 2007).

17.3 Speaking for the Dead: Ethics in Forensic Osteology

Human skeletal remains often figure prominently in legal matters. Osteologists are routinely asked to identify skeletal remains — to determine whether they are human and, if so, to determine the age, sex, identity, and antiquity of the remains. Information is provided on how these determinations may be made for bony remains in Chapter 18. Sometimes the osteologist is asked by law-enforcement representatives to make identifications, a report is filed (Chapter 16), and the matter ends there. On occasion, however, the osteologist becomes more deeply enmeshed in the legal system.

In many countries, law is practiced in an adversarial system in which prosecuting and defense

attorneys and their teams square off in courts of law. There are often serious questions of criminality or inheritance involving identification of the deceased. The stakes may be high. In such legal affairs, osteologists may be retained for their expertise and testimony by either side. For these and other reasons, the American Academy of Forensic Sciences has recognized physical anthropology as one of its 11 primary disciplines and provides ethical guidelines required to be adhered to by its members.

17.3.1 Boundaries of Evidence

In all osteological work, but particularly in forensic osteology, it is important for the analyst to keep two things clearly in mind at all times. First, any conclusion drawn in an osteological report must be defensible. In other words, the osteologist must prepare for a challenge by employing the most sound and up-to-date analytical methods available. Second, the osteologist should always avoid stepping beyond the boundaries set by the osteological evidence itself. In other words, he or she is an expert in osteology and not necessarily an expert in criminalistics, pathology, toxicology, engineering, or detective work.

The forensic osteologist must always report and testify within the bounds of the bony evidence and according to the principles of the scientific discipline that he or she represents. The osteologist should explicitly draw the attention of all concerned parties to limitations of the evidence itself and to the uncertainties associated with the identifications that have been performed.

One example illustrates the tragic toll that can be taken by a failure to observe these basic rules. The Vietnam War and the associated conflict in Southeast Asia resulted in the deaths of hundreds of thousands of people, among whom were American military personnel. The Americans who never returned, and whose bodies were not accounted for, were listed as MIA (missing in action). Thirteen men aboard an American AC-130 gunship shot down over Laos in 1972 were counted among the MIAs. Over ten years later an excavation at the crash site recovered 50,000 pieces of bone; the largest bone was 13 cm long, and most fragments had a maximum dimension of around 1 cm. After analysis by the U.S. Army, it was announced that positive identifications had been made on anatomy alone, and that all 13 men had been accounted for by these bone fragments. The skeletal remains were then forwarded to the families for burial. Relatives of the crew members pressed the issue of identification, and an independent investigation of these bones was made. It became clear that the analysis, although done by professional osteologists, had made conclusions about age, sex, race, and individuation that went far beyond the evidence (Getlin, 1986).

Science, fortunately, is self-correcting. In cases like this one the evidence can be examined by several investigators and faulty analysis is thereby exposed. In the meantime, however, the lives of many people can be deeply affected by the conclusions of the osteologist, who clearly has a responsibility to respect the limits of the hard evidence.

17.3.2 The Expert Witness

Witnesses in most court proceedings are sworn to tell the truth, the whole truth, and nothing but the truth. Expert witnesses, including forensic osteologists, must also adhere to these rules. See Komar and Buikstra (2008), Feder and Houck (2008), and Steadman (2009; Section II, Legal Considerations of Forensic Anthropology Casework in the United States) for further details on expert testimony, and Haack (2003) for an overview of science in the courts. Testimony by expert witness scientists is valued by courts of law throughout the world, although different judicial systems handle experts in different ways. For example, in Germany the expert witness is called by the court, whereas in the United States expert witnesses are often retained by lawyers on either side of a case. Testimony by scientists may have dramatic impact on the outcome of a judicial proceeding, particularly when their testimony is seen as ethical and articulate, and the testimony is given by a person expert in his or her discipline. Hollien (1990) observes that several major

problems surround scientists serving as expert witnesses. Among the most important are the lack of training of most scientists for the courtroom setting, the great variance in the qualifications of “experts” admitted into the courtroom, and the pressures upon the scientist, both overt and subtle, to adopt an advocacy position for the side paying the bills. For individual osteological expert witnesses who are ethical, well-trained, experienced, and who stay within the boundaries imposed by the evidence, none of these problems should be significant. Unfortunately, history has shown that not all experts have demonstrated these attributes. Hiss et al. (2007) discuss the damage that can be done by scientists who agree to serve as expert witnesses despite lacking the requisite education, training, and/or practice. Giannelli and McMunigal (2007) review the damage that has been done by expert witnesses with prosecutorial biases.

Different courts rely on different standards for admitting scientific evidence. For 70 years, U.S. state and federal courts relied primarily on the “*Frye* test” for determining the admissibility of opinions by expert witnesses. That test was named after a landmark 1923 decision that held that expert testimony must be based on a well-recognized scientific principle or discovery that is “sufficiently established to have gained general acceptance in the particular field in which it belongs.” In 1993, the U.S. Supreme Court ruled, in the *Daubert v. Merrill Dow Pharmaceuticals* decision, that the *Frye* test was superseded by Rule 702 of the 1975 Federal Rules of Evidence (FRE). At the time of the *Daubert* decision, FRE Rule 702 stated that,

If scientific, technical, or other specialized knowledge will assist the trier of fact to understand the evidence or determine a fact in issue, a witness qualified as an expert by knowledge, skill, experience, training, or education, may testify thereto in the form of an opinion or otherwise.

In the 1993 *Daubert* decision, the Court stated that an opinion or conclusion qualifies as “scientific knowledge” if it is the product of sound scientific methodology. The Court provided a five-point test (the “*Daubert* standard”) for determining the soundness of scientific methodology and the admissibility of expert testimony (Table 17.1).

Since the original 1993 *Daubert* decision, two additional cases on expert witnesses have been decided by the U.S. Supreme Court. Together with the *Daubert* decision, these decisions form the “*Daubert* standard” (or “*Daubert* trilogy”). The 1997 *General Electric v. Joiner* decision requires that scientific expert witnesses must explain how their methodology bridges the gap between evidence and conclusions, and the 1999 *Kumho Tire v. Carmichael* decision addressed the lack of distinction in FRE Rule 702 between scientific and technical knowledge (Grivas and Komar, 2008). While the *Daubert* standard is followed in all U.S. federal courts and more than half of the states, the *Frye* test is still the legal standard in many states, including California, Florida, Illinois, New York, Pennsylvania, and Washington (Giannelli and Imwinkelried, 2007).

The late American physical anthropologist and expert witness Dr. Louise Robbins (Hansen, 1993) serves as an example of why courts need to have an objective standard such as the *Daubert* standard against which the validity of expert scientific testimony can be judged. Robbins was a self-appointed “expert” in footprint identification who testified at numerous trials about her abilities to individuate people based on impressions left by their shoes, socks, or bare feet. She claimed that her techniques allowed her to tell whether a person made a particular print by examining any other shoes belonging to that individual. She stated that footprints were better indicators for identifying people than fingerprints. Other expert witnesses testified on her behalf, and against her, during a forensic career that spanned a decade and that resulted in many convictions. Only years later, after her death, were her techniques and conclusions exposed. Physical anthropologist Owen Lovejoy of Kent State University noted, “She may well have believed what she was saying, but the scientific basis of her conclusions was completely fraudulent” (Hansen, 1993: 66).

To her own eyes, and to the eyes of the attorneys who retained her, Dr. Robbins was acting in a professional and ethical manner. In the eyes of other scientists, she was unethical. In the end, her conclusions were shown to be unreliable, but years of litigation were involved, and years of incarceration resulted from convictions aided by her interpretations.

Forensic experts often disagree, and not always because one of them is unethical or untrained. Nordby (1992: 1116) asks, “How can we understand the grounds for genuine disagreement between two honest, qualified forensic experts?” He argues that we must distinguish between

seeing and observing. We all see, but we observe different things based on the contexts of our knowledge, beliefs, values, and goals. Nordby argues convincingly that it is the role of the expert witness to refine the context of observation based on expert understanding, always examining hidden observational expectations that may influence supplied interpretations. The expert must always be self-critical and always ready to defend what may turn out to be the only supportable conclusion—the conclusion of “I don’t know.” The expert supplies good reasons to support that opinion. Nordby (1992: 1124) concludes: “Both knowing and not knowing are informed positions reached by careful application of scientifically defensible methods. When the results of those methods do not allow us to rationally prefer one conclusion over an alternative, we must settle for knowing *why* we do not know.”

<u>Guidelines from the <i>Daubert</i> decision</u>	<u>Guidance from the <i>Kumho</i> decision</u>
Content of testimony must:	
1. Be testable and have been tested through the scientific method.	1. Expert witnesses can develop theories based on their observations and experience and then apply those theories to the case before the court.
2. Have been subject to peer review.	2. All forms of expert witness testimony should be evaluated with the same level of rigor.
3. Have established standards.	3. The <i>Daubert</i> standards are flexible guidelines that may not be applicable in every instance of expert witness testimony.
4. Have a known or potential error rate.	
5. Have widespread acceptance by the relevant scientific community.	

Table 17.1 U.S. standards for the admissibility of expert testimony. From Grivas and Komar (2008).

17.4 Caring for the Dead: Considerations in the Curation of Remains

The concept of respectful curation is not new to museums, but the respectful storage of human remains within a nonreligious space is something that is relatively new in the scope of human history. As a result, numerous social, cultural, and political groups are still adjusting to this new reality. Guidelines for respectful long- and short-term storage of human remains in nonreligious, institutional settings are now beginning to be formulated at the state, national, and international levels, as well as by museums, universities, and tribal groups. As inflammatory rhetoric is gradually eclipsed by thoughtful discussion of the issue from a more comprehensive set of viewpoints, the importance of accommodating both scientific investigation and traditional belief systems is becoming clear. As Larsen and Walker (2005: 116) note, “Crucial in the discussion is the fact that there are no *inherent* conflicts between the keeping of skeletal collections and respect for the dead.” The issue is far from resolved, but several points of agreement are emerging.

Human remains should be kept in a secure facility, out of the public eye. Access should be restricted, limited to museum staff or institutional caretakers, tribal representatives, and scholarly researchers. All research conducted on human remains should be carried out in accordance with the highest professional standards. When possible, accommodations should be made for the spiritual needs of descendant communities. Offerings by these communities of food, herbs, or pollen are common, and may occur as part of ceremonies that can involve smudging (the burning of herbs). These offerings and ceremonies are best performed in a separate, ventilated room to minimize the impact on other remains.

For some cultures, keeping all parts of an individual’s remains together is important. In any case, remains from only one individual should be kept in a unit of storage (*eg*, tray or drawer); do not commingle the remains of different individuals. Maintain, to the extent possible, the interconnected nature of an individual’s burial: keep grave goods together with the remains of the individual where possible, and ensure easy access to the excavation records that document the details of the burial.

When labeling remains or applying any sort of consolidant or preservative to the remains (Chapter 16), be sure to use methods and materials that can be reversed. The potential for removability is important not only to future research, destructive testing, and conservation work, but it may also become important to descendant communities if there comes a time that the remains are returned to them.

In what is perhaps the best example of cooperation and mutual accommodation to date, the Chumash Indians of southern California and the late Phillip Walker worked together to forge a mutually beneficial solution. Walker (2008a) describes the building of a separate facility—a subterranean ossuary—to house Chumash ancestors' remains. The ossuary provides a safe resting place for the remains within ancestral Chumash territory, and gives the Chumash control over their own dead, within the scholarly context of a university. The ossuary also provides for the long-term care and preservation of the remains, and scientific research on the remains is allowed to continue under the supervision of their descendants. Larsen and Walker (2005) describe a similar arrangement with the Stillwater Marsh remains from Nevada. From the very outset of the work there, all stakeholders (local, state, and federal authorities; archaeologists; physical anthropologists; Fallon-Paiute Shoshone, the local tribe; and the Nevada State Museum) worked together to determine the proper treatment, study, and final disposition of the remains. The agreement that was forged by this cooperation allowed for the scientific study of the remains prior to their repatriation to the tribe. The agreement also made provisions for future scientific study of the remains, by specifying that a subterranean concrete burial chamber should be built to provide for long-term storage and access.

17.5 Custody of the Dead: “Repatriation” and the U.S. Native American Graves Protection and Repatriation Act

There is a stark contrast between the widely accepted and easily delineated ethical and legal guidelines for the osteologist working in a forensic setting and the ambiguities of ethics and law that involve the osteologist working in an archaeological setting. Evidence, logic, reason, and the scientific method are all held in high esteem in the forensic realm. Normally, when claims of entitlement enter the legal system, there is rarely any attempt to “balance” scientific and spiritual evidence—the former takes precedence. This was traditionally the case in the realm of scientific archaeology. Now, however, the situation involving human remains from archaeological contexts throughout the world has become complex, fluid, ambiguous, politicized, and confusing due to the promulgation of laws that aim to redress what are seen as religious injustices undertaken in the name of science. It is necessary to examine the causes for this situation and to consider some of its implications for osteological research involving human remains.

17.5.1 Ethics in Collision: Respecting the Living

Research in human osteology necessarily involves the study of hard tissues that are the tangible remains of once-living individual people. It comes as no surprise, then, that this practice stirs deep emotions in many living people, causing them to take objection to osteological excavation and research. This is nothing new—anatomical study of the deceased has been controversial from its very inception. Early anatomists were forced to retrieve and dissect their cadavers in secrecy. Today, as every first-year medical student knows, remains of the dead are vital resources for teaching the living. So it is in osteology.

Death has a high emotional value, as indicated by the fact that both modern and prehistoric humans have developed a wide range of customs and rituals for dealing with it—customs and rituals that change through time. Archaeologists and physical anthropologists have learned, and continue to learn, about past human mortuary practices by excavating skeletal remains. As out-

lined elsewhere in this book, careful analysis of the bones themselves has led to insights into the diet, living conditions, population structure, genetic relationships, health, and evolution of humans in both the recent and remote past. Thus, the emotive power of death is combined with the informational potential of human bones to form a combustible mix in the modern world, resulting in debates over human skeletal remains, and posing ethical dilemmas for practicing osteologists and archaeologists.

In North America and Australia, large populations of indigenous people met European explorers several hundred years ago. Subsequent to this contact, both continents saw the decline — and sometimes the extinction — of native peoples and their cultural heritage as European colonization proceeded. Native Australian and American survivors of these invasions suffered and continue to suffer great injustices. A callous disregard for surviving native people has sometimes been demonstrated by developers, museum workers, government officials, and anthropologists in the recovery and disposition of the skeletal remains of these aboriginal peoples. A double-standard has sometimes been applied in the disturbance and subsequent treatment and disposition of European versus indigenous skeletal remains (McGuire, 1989; Hubert, 1989).

In Israel, ultraorthodox Jews have sought to restrict archaeological research. In New York, African-Americans have insisted that skeletal remains of slaves only be studied by African-American osteologists. Archaeological excavation and analysis of skeletal remains have been seriously curtailed and even stopped at the insistence of some Native American and Australian groups who have used the issue as a forum from which to express their far more wide-ranging grievances. The question of excavation and post-excavation handling and disposition of osteological remains has rapidly gathered considerable symbolic importance to many people. In some regions, research into prehistory has suffered setbacks, with excavations being halted, cultural and skeletal material reburied. There is no better way to illustrate and explore the ethical issues of excavation, analysis, and reburial of human skeletal remains than to present a case history (for additional views, see Meighan, 1992; Klesert and Powell, 1993; Goldstein and Kintigh, 1990; Jones and Harris, 1998; Webb, 1987; Williams, 2001; and Zimmerman, 1987a, b, 1989, 1997).

Just over 600 years ago, long before Columbus explored the “New World,” a fortified village site at Crow Creek, on what is now the Sioux Indian Reservation in South Dakota, was inhabited by nearly 1,000 Native Americans. This prehistoric, probably Arikara, village was attacked by a neighboring tribe, probably a Siouan group, and nearly 500 of the inhabitants killed. Although there is no historic record of this event, human skeletal remains documenting the massacre were discovered eroding out of the site in 1978 (Willey and Emerson, 1993). After three years of negotiations, an agreement was reached among the Sioux (Lakota, Dakota, and Nakota tribes on whose land the site was located), the U.S. Army Corps of Engineers, the project archaeologists, and the Arikara (the most likely descendents of the inhabitants of the village).

Analysis of the huge skeletal sample excavated at Crow Creek was limited by the amount of time available before the remains were placed in gold-painted, concrete coffins and reburied. While these were seriously suboptimal conditions for scientific research, the alternative was no excavation at all. The project osteologist, P. Willey of the University of Tennessee, summarized the situation as follows:

Only five months were permitted for the analysis, and I and the other physical anthropologists did as complete a job as we could. As the analysis proceeded, however, research questions came up which we could not pursue answers to within the period of time designated for the study. Continuing analyses of the information obtained from our study of the bones have pointed us in even more productive directions, yet the bones were returned to the Sioux Tribal Council as required by contract. Crow Creek is a unique site. The massacre offers an extremely rare opportunity to study the sample of a population at one point in time. Few other collections exist that are so potentially revealing as the one from Crow Creek concerning the diseases a prehistoric people lived with. Crow Creek is also a crucial site for studies of prehistoric stress and biological affinities with other populations.

Indians living today stand to benefit from our conclusions. Additional study of the remains might aid Native Americans further. Examples of the applications of our analyses include determina-



Figure 17.1 The Crow Creek massacre bone bed.

tions of biological relationships which support Indian land claims and understandings of prehistoric disease which could alleviate suffering among present-day Native Americans. If our studies of disease could result in understandings which saved just one child's life, then surely retaining skeletons for complete study is warranted. When we all stand to benefit, the interests of one ethnic group should not be permitted to stand in the way. We must be able to do the most complete and comprehensive study of all human skeletons of all human groups. (Willey, 1981:26)

The issue of excavation, analysis, and reburial stands out clearly at Crow Creek, but it goes far beyond this one occurrence. Some Native Americans have claimed that all archaeological research is racist and in violation of the sacred nature of prehistoric sites. Some archaeologists have responded by reburying excavated remains, or not excavating at all, as a means of lessening tensions or securing contracts. Several archaeologists and physical anthropologists have gone so far as to sign binding legal agreements to rebury any bone material (including nonhuman bones) on the spot without analysis, to bury all photographs and negatives made during the research, and to rebury any artifacts found in the vicinity of the skeletal remains. Skeletal samples have been taken from museum collections and reburied, a practice some physical anthropologists have likened to the destruction of single-copy manuscripts.

Many physical anthropologists have actively opposed efforts to rebury skeletal material, probably because these scientists are most aware of the potential information in these remains and are most sensitive to how this information is lost through reburial. Jane Buikstra, a physical anthropologist, has addressed several misconceptions that have characterized the issue (Buikstra, 1981a, 1983, 2006). European-American archaeologists have been accused of “never digging up their own ancestors,” in effect practicing a kind of archaeological apartheid. As Buikstra notes, the fact that a mostly white set of professional archaeologists study a set of mostly aboriginal bones in North America and Australia is not a manifestation of racism. From the excavation of remains of white frontiersmen in Wyoming (Gill et al., 1984; see Chapter 15) to the analysis of remains from

17th- and 18th-century graves of European whalers on Spitsbergen (Maat, 1981, 1987), archaeologists and physical anthropologists routinely work on skeletal remains associated with recent Western culture. In fact, the largest and best-studied skeletal series in use by physical anthropologists (the Hamann-Todd collection) is composed of mostly European-American and African-American individuals from medical school dissections at Case Western Reserve University. Many of these skeletons come from known, named, specific individuals whose religion is often recorded. Furthermore, some of the skeletal sexing and aging techniques used most widely by osteologists were developed, in part, from analysis of the remains of primarily white Americans killed in the Korean War (Chapter 18). The misconception that holds that continued curation of remains does not help living people has been addressed repeatedly. For example, Ubelaker's (1990) success in positively identifying Native American murder victims from the Pine Ridge Reservation was a direct result of his use of comparative collections of Native Americans. The work by Hughes et al. (in press) on differentiating prehistoric and historic Native Californian remains from more recent (and, therefore, possibly forensically significant) Native American remains and from remains of Latin American U.S. immigrants of indigenous ancestry is another example.

17.5.2 NAGPRA: Context, History, and Intent

In North America, some Native Americans argued during the 1970s and 1980s that because some contemporary Indian people have a descendant relationship with some skeletal remains housed in museum collections, the disposition of these remains should be controlled exclusively by modern Native Americans. Numerous state laws addressed the issue, and on November 16, 1990, President George H. W. Bush approved Public Law 101–601, the Native American Graves Protection and Repatriation Act (NAGPRA), an act of Congress that directed all museums and laboratories within the United States that receive federal funding (except the Smithsonian Institution) to inventory all human remains and associated funerary objects, to determine which among them can be linked ancestrally to existing federally recognized tribes, to consult with those affected tribes, and to follow the wishes of the tribes regarding those collections. Contrary to popular assumption, NAGPRA does not require reburial but rather gives control over the final disposition of remains to the most appropriate, federally recognized Native American or Hawaiian claimant. Groups are free to choose other options, such as long-term co-curation agreements or the transfer of objects to a tribal museum. The law attempted to set up a process of consultation whereupon these options, among others, might be considered.

The NAGPRA legislation came at a time when large numbers of American anthropologists were questioning the rationalist and empiricist roots of their discipline. As Zimmerman (1994: 65) notes, “Part of the rift between archaeologists and Native Americans stems from a fundamentally different conception of the past. To Native Americans, the idea that discovery is the only way to know the past is absurd.” Indeed, many contemporary anthropologists are sympathetic to “spiritually oriented,” culturally relativist, and even anti-scientific viewpoints.

The NAGPRA statute is based on something known as “cultural affiliation.” The law instructs institutions and potential claimants for “repatriation” to assess “cultural affiliation” by a “preponderance of the evidence,” where evidence is defined as “geographic, kinship, biological, archaeological, linguistic, folklore, oral tradition, historic, or other information or expert opinion.” How should the relative weights of these disparate lines of evidence be determined? Remains may only be returned after such cultural affiliation is established. Because of the vagueness of the NAGPRA legislation, some feared that it would subject institutional skeletal collections to potential claims by nondescendants who merely felt a spiritual connection to the remains.

Important case law was established by the Kennewick decision (Jelderks, 2002), which states that the law allows “tribes and individuals to protect and claim remains, graves, and cultural objects to which they have some relationship, but not allowing them to take custody of remains and cultural objects of persons and people to whom they are wholly unrelated” (2002: 27–28). Furthermore the subsequent Appeals Court decision (Gould, 2004) actually weighted the evidence

pertinent to the question of “cultural affiliation:” “We cannot give credence to an interpretation of NAGPRA advanced by the government and the Tribal Claimants that would apply its provisions to remains that have at most a tenuous, unknown, and unproven connection, asserted solely because of the geographical location of the find” (III: 41) and, “As the district court observed, 8340 to 9200 years between the life of Kennewick Man and the present is too long a time to bridge merely with evidence of oral traditions” (IV: 48). Another important part of the original Kennewick decision was the conclusion that: “NAGPRA does not mandate that every set of remains be awarded to some tribe, regardless of how attenuated the relationship may be” (Jelderks, 2002: 57). The 2010 regulatory ruling (see below) of the Department of Interior appears to run counter to these judicial opinions, and will almost certainly be challenged in the U.S. courts, particularly in light of the Appeals Court’s conclusion that “Congress’s purposes would not be served by requiring the transfer to modern American Indians of human remains that bear no relationship to them” (Gould, 2004, III: 32) and that “Congress enacted NAGPRA to give American Indians control over the remains of their genetic and cultural forebearers, not over the remains of people bearing no special and significant genetic or cultural relationship to some presently existing indigenous tribe, people, or culture” (Gould, 2004, III: 40).

The NAGPRA law is administered under the National Park Service of the Department of the Interior. The law, as written, does not require institutions to return all skeletal remains to Native Americans, just those remains which are “culturally affiliated.” It took more than 20 years after passage of the law for the first administrative regulations regarding the disposition of “culturally unidentifiable” human remains to be promulgated. The constitutionality and other aspects of these latest administrative regulations have not yet been tested in court (Seideman, 2009). To add to the uncertainty, some states are starting to pass repatriation laws of their own, such as California’s Assembly Bill 978 (“CalNAGPRA”).

The intent of Congress was to redress documented injustices and to provide a means by which aggrieved parties could obtain information about, and custodianship of, ancestral skeletal remains. The law is intentionally vague on how ancestral/descendant status is to be ascertained. Unfortunately, the implementation of the legislation has created bureaucracies that are now determined to extend their own existence by broadening the scope of the law. Even professional osteologists have jumped on this bandwagon, joyously proclaiming that “NAGPRA is forever!” (Rose et al., 1996). It was never the intent of the legislation to create permanent bureaucratic positions for archaeologists and physical anthropologists and their students at the federal, state, and local levels. Neither was it the intent of the law to pump funds into museums for out-of-work archaeologists to conduct further research with collections or to create positions for osteologists. However, these have been among the effects of the law’s implementation.

The law required that formal inventories of all remains be reported by 1995 (within five years of the NAGPRA legislation’s passage). That intent was subverted by blanket extensions of the reporting deadline to any institution that asked for one — awarded by the very government agency charged with regulating the law. In its slick, expensive, and politically correct *Common Ground* magazine, this very agency (the National Park Service’s Departmental Consulting Archaeologist and Archaeology and Ethnography Program) even published an article on a new Boy Scout merit badge for archaeology. In this example of political correctness run amok, one of the “ethical responsibilities” of Boy Scout counselors under this program was described as follows: The counselor “avoids all osteological research (in the field and in the lab)” (Skinner et al., 1998).

Human osteologists interested in continuing to curate and study human skeletal remains have been marginalized and demonized within their own intellectual settings and denied access to the very collections they once curated. Curators of human osteological collections have literally been locked out of collections by their own anthropologist colleagues and isolated from the NAGPRA consultation process with Native Americans. Meanwhile, untrained, formerly unemployed archaeologists have lined their pockets with federal and institutional money under the guise of conducting inventories of remains required by NAGPRA and under bogus extensions to the NAGPRA deadline granted by the National Park Service. No wonder this unforeseen and unfortunate turn of events has resulted in the widespread abandonment of skeletal biology by museums and other institutions of higher learning, and a parallel exodus of researchers and stu-

dents from human osteology. One unintended result has been the shift to osteological analyses in more recent cemeteries (Grauer, 1995; Saunders and Herring, 1998). And all this has come with virtually no legal challenges. Unfortunately, for reasons of economics and politics, many museums and other institutions have followed the National Park Service's lead in extending NAGPRA beyond the intent of Congress. With no one to regulate regulators who are bent on reburial, only a few institutions have had the courage to challenge the law in court.

Like any law, NAGPRA has been tested, and will continue to be tested, in the judicial system as claimants and institutions disagree over the ultimate disposition of remains. One of the most visible and important cases in the first 20 years of NAGPRA was that of the ancient remains found eroding out of the bank of the Columbia River in 1996 (Table 17.2).

17.5.3 The Future

A common misconception about the analysis of skeletal remains from archaeological contexts has to do with what constitutes adequate analysis. As Buikstra (1983) notes, the notion that continued curation of human skeletal collections is unimportant for scientific studies is simply false. She illustrates this by noting the amount of information that would have been lost if collections made before 1952 had been reburied after one year of analysis. Questions concerning demography and disease were not answerable or remained unasked just a few decades ago. Radiographic technology was inadequate to fully analyze bones. To rebury skeletal remains is to assume that no more questions will be asked and that no further developments in analytical techniques or instruments will occur. These are poor assumptions. A review by physical anthropologist C. Turner is worth citing as a summary of the foregoing considerations:

Scientific information about past peoples and their lifeways will be lost with reburial of human skeletons. This is because even a single skeletal series has more kinds of information than one worker can reliably extract, and because new techniques for skeletal research are constantly being devised. I explicitly assume that no living culture, religion, interest group, or biological population has any moral or legal right to the exclusive use or regulation of ancient human skeletons since all humans are members of a single species, and ancient skeletons are the remnants of unduplicable evolutionary events which all living and future peoples have the right to know about and understand. (Turner, 1986:1)

For science to be self-correcting, the scientific databases, whether they are composed of one discovery like Piltdown or a large series like that from Crow Creek, must continue to be available to the scientific community (for example, see Chapters 16 and 19 for a discussion of how inter- and intra-observer error in osteology can influence the results of any study). To rebury skeletons is to bury whatever future information they may yield as well as to deny future researchers the possibility of assessing the work of their predecessors. In short, it is to deny future generations the ability to know their past. Meighan puts it this way: "Reburying bones and artifacts is the equivalent of the historian burning documents after he has studied them" (1994: 68).

The imminent threat of reburial has led many osteologists to abandon the idea of keeping original specimens for posterity and instead to turn to alternatives. The compilation of the Standards volume (Buikstra and Ubelaker, 1994; see Section 16.12) represents such a desperate move. Some have rejoiced in the thought that the inventory and repatriation process has "increased the number of skeletons studied from about 30% to nearly 100%" (Rose et al., 1996), but both the numbers and the sentiment are poorly based. Even the "removing books from a library" analogy breaks down with original osteological specimens. These remains defy accurate and adequate copying. The bones comprise not just external morphology but internal form and chemical composition as well. No cast, no image, no measurement, no description can adequately record the information potential held by an original bone, and to suggest that this is not the case is to take false comfort in the face of permanent destruction. One thing that sets science apart from other areas of human endeavor is the character of self-correction. As new techniques and new observers allow evidence to be examined in new ways, old errors can be corrected and the truth can be better approximated.

Sidebar: The case of the Kennewick skeleton (the Ancient One)

One of the first major legal challenges to NAGPRA was the case of the skeleton found in Kennewick, in eastern Washington state, along the Columbia River. Before discussing the outcome of the case, it may be helpful to review a timeline of some of the more important events and developments in the case:

July 28, 1996: Two students (Will Thomas and David Deacy) were wading in the shallow water along the Columbia River near Kennewick, Washington, after watching the annual hydroplane races held there. About ten feet from shore, they noticed a human cranium in the water.

July 28, 1996: Thomas and Deacy notify the police, who in turn call Coroner Floyd Johnson to the scene.

July 28, 1996: Coroner Johnson contacts archaeologist James Chatters and asks him to report to the scene.

July 28, 1996: The police, coroner Johnson, and Chatters recover much of the skeleton from the river.

July 28, 1996: Based on the completeness of the skeleton, the good condition of the remains, the lack of definitive Native American characteristics, the presence of Caucasoid characteristics, the presence of 19th-Century artifacts, and the proximity to an early homestead site, Chatters tells the coroner he suspects the bones are from an early European-American settler.

July 28, 1996: Upon seeing a healed injury around a gray stone object embedded in the ilium, Chatters starts to question his initial suspicions and requests radiographic analysis.

July 29, 1996: The U.S. Army Corps of Engineers (COE), who have jurisdiction over—and own—all navigable waterways in the U.S., is notified of the discovery.

July 29, 1996: The bones are x-rayed and CT-scanned at Kennewick General Hospital. The gray stone object turns out to be the 20 × 54 mm base of a leaf-shaped, serrated Cascade point that was typical of Southern Columbian Plateau assemblages between 8500 B.P. and 4500 B.P.

July 29, 1996: The coroner orders radiocarbon and DNA analyses to be performed on the remains.

July 29 – August 29, 1996: Under an ARPA permit, Chatters finds additional bones.

July 29, 1996: News of the discovery is made public when the story (“Skull Found on Shore of Columbia”) was published in the Tri-City Herald, a local newspaper in eastern Washington state.

July 30, 1996: Upon learning of the news story, a representative of the Umatilla tribe contacts authorities about the discovery.

August 5, 1996: A fragment of metacarpal is sent to the University of California, Riverside, for destructive AMS ¹⁴C testing.

August 26, 1996: A tentative date of 8,400 B.P. is returned for the fragment.

August 31, 1996: Douglas Owsley, head of Physical Anthropology at the Smithsonian, arranges for Chatters to bring the remains to the Smithsonian for further study.

September 9, 1996: A coalition of five Native American tribes from Eastern Washington (the Umatilla, the Nez Percé, the Yakima, the Wanapum, and the Colville Confederation) claims the remains under NAGPRA.

September 10, 1996: The remains are seized by COE shortly before they could be transported to the Smithsonian. COE orders an immediate halt to DNA testing being done on a portion of the sample taken for ¹⁴C testing.

September 17, 1996: COE accepts the tribal claim and publishes a “Notice of Intent to Repatriate” as required by NAGPRA.

October 16, 1996: A group of eight anthropologists (Robson Bonnicksen, Douglas Owsley, Dennis Stanford, D. Gentry Steele, Richard Jantz, George Gill, C. Loring Brace, and C. Vance Haynes, Jr.) files suit in U.S. Magistrate Court in Portland, Oregon, to prevent the repatriation of the remains, and to allow further study of the remains.

October 24, 1996: The U.S. Magistrate Court case begins.

December 1, 1997: Further research is conducted at the Kennewick site.

March 24, 1998: COE enters into an agreement with the U.S. Department of the Interior (DOI) for the DOI to determine whether the remains are “Native American” under NAGPRA, and to determine the proper disposition of the remains.

April 1, 1998: COE gives the remains to the DOI.

Table 17.2 A timeline of events in the case of the Kennewick skeleton (the Ancient One) and the law.

April 6, 1998: Despite the site's status as a registered national landmark, despite the bipartisan passage of a federal site preservation bill and against the advice of COE's own archaeologist, COE "stabilizes" the Kennewick site by dumping 500 tons of rock and gravel on the site by helicopter, tops it with 300 tons of soil and logs, and then plants 3700 fast-growing trees on top.

May 12, 1998: The first of six consultation meetings is convened by the DOI to discuss repatriation of the remains with representatives of five tribes.

June 17, 1998: Both sides in the case begin out-of-court mediation.

September 3, 1998: Pending resolution of the legal dispute, U.S. Magistrate John Jelderks orders the remains moved to the Burke Museum at the University of Washington, a neutral location that both tribes and scientists agree upon.

October 29, 1998: The remains are transferred to the Burke Museum pending a final decision.

February 27, 1999: A team of government-selected anthropologists present their preliminary findings (using only nondestructive analyses).

July 27, 1999: The National Park Service (NPS), against the wishes of the tribes, announces that it will conduct additional destructive analyses to confirm the antiquity of the bones.

September 8–9, 1999: NPS scientists select a bone sample to use for the destructive dating analysis.

October 15, 1999: A DOI report concludes that the remains are more closely related to the Ainu of northern Japan than they are to the tribes claiming the remains (or any Native American tribe).

January 11, 2000: The DOI determines that the remains are "Native American," according to DOI's interpretation of the NAGPRA definition.

January 12, 2000: Radiocarbon results are announced, confirming an age for the remains of about 9,300 years B.P.

September 25, 2000: Secretary of the Interior Bruce Babbitt announces that the remains should be given to the tribal coalition based on their claim of ancestry for the remains.

August 30, 2002: Judge Jelderks rules that the remains should not be turned over to the tribal coalition for reburial, but should instead be made available to a team of scientists for study.

October 28, 2002: Four of the tribes in the coalition (the Yakima, Umatilla, Colville, and Nez Perce of Idaho) file notice to appeal the ruling.

February 4, 2004: The 9th Circuit Court of Appeals rejects the appeal from the tribes, and finds that the Kennewick Man skeleton is not Native American according to the NAGPRA definition, thus upholding the District Court's Opinion in full, and allowing the scientific community to study the remains.

April 19, 2004: The 9th Circuit Court of Appeals denies the request for a rehearing *en banc* of the Bonnicksen decision.

August 17, 2004: Judge Jelderks rules that the tribes have no right to further participation in this litigation. This order validates the scientists' belief that the tribes' participation in the proceedings ended with the 9th Circuit Appeals Court decision.

September 9, 2004: The tribes file a new motion to intervene in the case.

March 7, 2005: Senator John McCain introduces a measure to Congress that would amend "the Native American Graves Protection and Repatriation Act to provide that 'Native American' refers to a member of a tribe, a people, or a culture that is *or was* indigenous to the United States." The measure was not passed.

Conclusion

When are remains and artifacts from the distant past relevant to the history of one or only a few cultural groups, and when do these remains and artifacts become part of the heritage of all humanity? This is a difficult question that may never be fully answered. In the case of the Kennewick remains, however, the U.S. justice system has given us its answer:

Human remains that are 8,340 to 9,200 years old and that bear only incidental genetic resemblance to modern-day American Indians, along with incidental genetic resemblance to other peoples, cannot be said to be the Indians' "ancestors" within Congress's meaning. (Gould, 2004)

The remains of the Kennewick individual are housed in the Burke Museum. All decisions concerning access to the remains continue to be made by COE, as the landowners of the property where the remains were found.

Reproducibility of observation is an essential ingredient of science. This, of course, is lost when skeletal remains are destroyed by reburial. Long-term curation of skeletal remains has repeatedly been demonstrated to be essential to forensic, archaeological, and paleontological investigations. The very understanding of human diversity rests on this continued curation (Tobias, 1991).


Museums are the institutions most often entrusted to act as repositories for human skeletal remains. Yet many museums have deaccessioned skeletal collections in the face of vocal activists demanding reburial, arguably violating the public trust in the process (after all, one of the missions of any museum is the preservation of its collections for posterity). Many reburials have been precipitous, undertaken even before legislation was enacted or tested in court. Reburial is often seen on both institutional and personal levels as an expedient, politically safe, cheap, and therefore easy way for the public and politicians to assuage imagined guilt, and for institutional administrators to escape “negative publicity.” Stanford University, Central Michigan University, the Detroit Institute of Arts, the American Museum of Natural History, the Field Museum, the Cranbrook Institute of Science, and the University of California are just a few of the institutions that have returned culturally unaffiliated and/or unidentifiable remains and burial objects (a practice called “dispositioning” rather than repatriation) to indigenous groups who may or may not be related to the remains in question. Whatever the intent, the costs to scientific knowledge as a result of politically correct reburials are high, and the effects are permanent.

Zimmerman (1997: 105) has argued, “Quite simply, anthropologists must learn to share control over the past.” Surely this is a provocative perspective that contends that the past can be “controlled” by anybody — isn’t the past . . . past? Most of us reckon that the past happened, that there is some evidence of it having happened, and that we should do our best to accurately interpret that evidence and thereby understand what happened. However, Zimmerman’s adoption of the cultural relativist position (or ethic) is widely shared among practicing anthropologists and reflects the ethical dilemmas facing anthropologists of all subdisciplines (Meighan, 1992). How can scientists accommodate explicitly religious viewpoints at odds with the evidence they study? Meighan (1992) and Weiss (2008) both argue that the destruction of skeletal collections by native creationists represents a conflict between religion and science, and when scientists “compromise” in this conflict, by definition, they abandon science itself, with all of the rights and duties inherent to this system of knowing (Moore, 1999).

Skeletons in museum collections represent the remains of only the few individuals who, largely by chance of burial and discovery, have managed to elude the ravages of time and to open windows on the distant past (Figure 17.2). These bones have the potential to inform all people about the past. When reburied, they will join the vast majority of ancestors who have gone missing without a trace. Who looks out for the unborn great-great-grandchildren of contemporary Native Americans or Australians? Who will tell the generations to come that during the late 20th century, some of their relatives decided to deprive them of the best means of knowing the past? The Iroquois had a tradition to guide wise people through troubling times, if wise people were prepared to follow it. They urged wise people to consider the impact of any decision on the seventh future (unborn) generation. The wholesale reburial of archaeological skeletal collections, as advocated and precipitated by activists, politicians, and museums during the last decades of the 20th Century and the first decades of the 21st Century, will most likely be condemned by unborn generations of all people, long before seven generations have passed.

Given the issues involved, what steps can the practicing osteologist or archaeologist take to ensure that osteological science is pursued with scientific vigor and respect for common ethical values? First and foremost, all skeletal remains should be treated with respect and dignity in their excavation, analysis, and curation. Second, potential descendants should be fully informed about any steps being contemplated or undertaken that involve human remains. As a general rule, control of osteological material should be invested in parties who can show direct lineal affinity to the remains in question. In some cases this descent is difficult or impossible to determine accurately. When excavation, study, and curation can be shown to violate traditional values and beliefs of living descendants at the tribal or family level, these values and beliefs should be honored. Most often this occurs in historical archaeological contexts. Prehistoric remains are

24,862,500 TOTAL INDIVIDUALS WHO LIVED



1 icon = 100,000 people

24,862,500 DEAD INDIVIDUALS

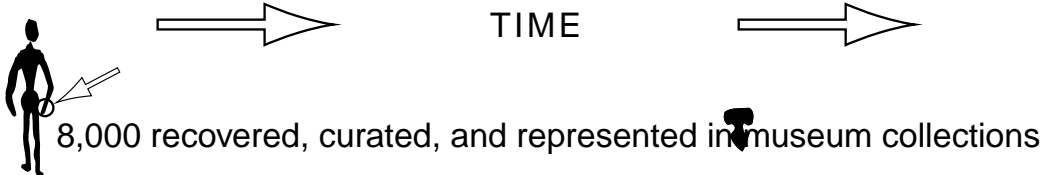
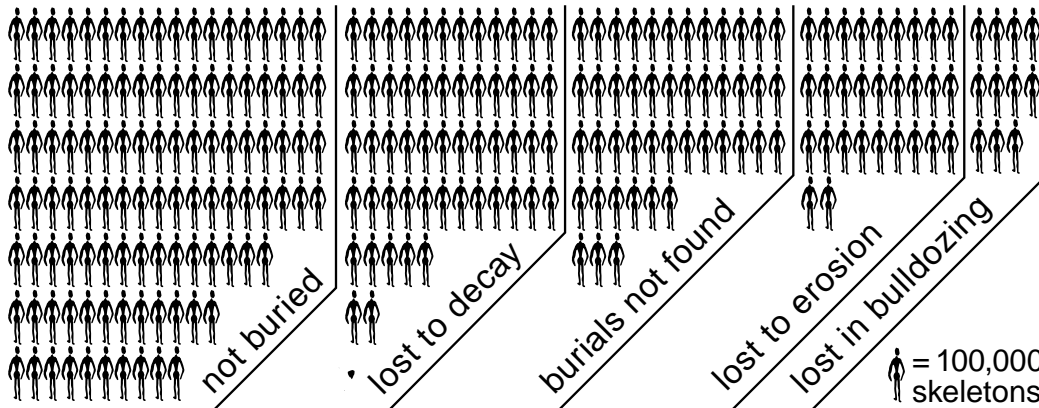


Figure 17.2 The ravages of time. It is often forgotten that the skeletons comprising modern museum collections represent only tiny fractions of once-living populations. These skeletons, ambassadors from the past, represent those few who have miraculously escaped the ravages of erosion, burial, decay, and modern development to reach us and inform us about prehistory. For example, at the time of this writing, U.C. Berkeley's Hearst Museum of Anthropology houses around 8,000 mostly partial prehistoric skeletons representing some 9,000 years of human occupation of the state of California. This is the world's most important collection of human skeletal remains documenting populations of people who subsisted through hunting and gathering rather than agriculture. These archaeologically derived skeletal remains of early Californians have yielded, and continue to yield, an amazing record of human accomplishment, diversification, and adaptation.

This book makes it clear that a great deal of information would be lost if these remains were to be reburied. But what fraction of Native Californians does the Hearst collection really represent? The best estimate for the California Native American population at European contact is 221,000 people (Ubelaker, 1992a). If we make the most conservative estimates on length of occupation (9,000 years), average lifespan (40 years; average life expectancy did not reach 40 years in most world populations until the 19th century), and the most simple, linear estimates of population size increase, a total of about 25 million people died in prehistoric California over 9,000 years. Therefore, even the largest museum skeletal collection in the state comprises a mere three one-hundredths of one percent (0.00032) of the total number (24,862,500) of Native Californians deceased since 7,000 B.C. This tiny, miraculously preserved set of skeletal remains is all that remains to inform us about all the other individuals whose remains were lost to the ravages of time. This precious heritage is what lies in the balance of current legal and ethical debates regarding reburial.

usually more ambiguous in their relationship to modern groups, and the older the specimen, the less likely it is that direct, exclusive descent to any living person is demonstrable. Even when it is, however, all parties should be informed of the important information that may become available as a result of analysis of the skeletal remains. In any case, the results of studies should be presented to the descendants in a timely manner, and the conclusions of (as well as any real or potential benefits from) the research should be clearly stated.

The debate concerning excavation, study, and reburial of human skeletal remains will continue to be heard in the courts, as was the Kennewick case (Gould, 2004). One hopes that the ethical concerns of all the various sides in the debate are reflected in the laws that will continue to be written and tested in such settings. Communication, however, is most effective *outside* the legal system. Professional archaeologists and osteologists bear a great responsibility in education. All groups involved in the debate should be engaged in an ongoing dialogue — with people talking *with* each other instead of *at* or *past* each other. These issues will only be defused through public



Figure 17.3 Vandalism of osteological remains in an archaeological context. (*Above and opposite*): evidence of looting is seen in these two photographs taken at the site of Nuvakwewtaqa, a large (1,000+ room) pueblo in central Arizona occupied between A.D. 1280 and 1425. Vandals have haphazardly discarded the human skeletal remains encountered in their search for grave goods, damaging the bones and forever losing their context. The nonrenewable archaeological record is rapidly disappearing due to such plunder. Photos courtesy of Peter Pilles and the Coconino National Forest.

education and through the long-overdue graduate-level education and participation of Native Americans and Aboriginal Australians in physical anthropology and osteology.

Any group of people, from the smallest family to the entire human species, is best equipped to deal with its present and future only when it fully understands and appreciates its heritage. Prehistoric research, including osteological study, is one way that heritage can be revealed. The great tragedy in the debate over skeletal remains from archaeological contexts is that the issue has sometimes pitted archaeologists against descendants and relatives of the people they wish to study. This has occurred at a time when the very archaeological resources in North America and Australia (which both parties seek to preserve) are disappearing at an unprecedented rate at the hands of developers and looters (Figure 17.3). In the face of this catastrophic and irreversible destruction of the past's only tangible record, the reburial issue constitutes a costly diversion for all parties. The scientific community and native groups need to redirect their energies in a concerted effort to save and protect the heritage of the past before it disappears.



Figure 17.3 (continued)

Phillip Walker (1947–2009), osteologist and outspoken proponent of cooperation and collaboration between Native Americans and physical anthropologists, as well as the museums that hold the skeletal remains that both parties seek so vehemently to protect, summed up the current situation and future prospects:

A counterproductive aspect of this acrimonious debate is the tendency for the stakeholders (political leaders, government bureaucrats, physical anthropologists, archaeologists, museum curators, tribal councils, traditional spiritual leaders, and so on) to resort to divisive “us versus them,” “right versus wrong” rhetoric that oversimplifies the diversity of views present in the scientific, museum, and indigenous communities. This is unfortunate because, in the United States at least, considerable progress has been made toward finding a common ground that balances scientific concerns with those of indigenous people. Much of this has been accomplished through the attempts of museums and Native American tribes to comply with the legal requirements imposed by the Native American Graves Protection Act (NAGPRA). Although NAGPRA is a flawed piece of legislation that can be criticized from a number of perspectives (Goldman, 1999; Rose et al., 1996; Walker, 1998), it nevertheless has provided an impetus for increased communication between Native Americans and Museums. In several instances, this has opened the door to innovative compromises that address the concerns of both scientific and Native American groups. (2004: 13–14)

17.6 Ethics in Human Paleontology

As a general rule, entropy is more and more effective the longer it has to operate. As a result, there is a tendency for the fossilized remains of humans and human ancestors to be rare compared to the skeletons of people who have died during the last several thousand years. There are few places on earth where conditions have been conducive to the deep-time preservation of hominid skeletal remains. Such places must have afforded protection from the nearly ubiquitous presence of continual erosion. Hence, sediments accumulated in protected places such as caves or lake basins are the usual discovery sites of fossil hominids.

Ever since fossil hominids were found in the late 1800s, they have received an inordinate amount of scientific attention and public curiosity. In some ways, it was almost as if these fossilized remains of distant relatives became icons. A good deal of nationalistic fervor was devoted to the recovery of fossils in various parts of the world, and it has been argued that Piltdown’s status as “the earliest Englishman” played a role in blinding the leading scientists of the day to the obvious fraud that the “find” represented. The Taung cranium is a cultural and national icon in South Africa, the Neanderthal skeleton is prominently displayed in Germany, and Ethiopia is known throughout the world as the home of “Lucy.” Today, hominid fossils are viewed as important parts of the cultural heritage of many developing countries.

In many parts of the world where the most important hominid fossils are being found, the academic and scientific infrastructures remain poorly developed. As a result, fossils have often been exported to the nations that had “colonized” these lands, to be studied by foreign experts, and often displayed and curated indefinitely in foreign museums and universities. The demise of colonial rule across Africa and Asia ended this situation, but attention to the development of facilities and personnel to support ongoing human paleontological research in these areas was slow in coming. Today, particularly in Africa, a first generation of indigenous scholars is developing the necessary platform from which to conduct world-class research into human paleontology. There are continued instances of exploitative relationships and hit-and-run fossil hunting by foreigners from the developed world, but there are also several models of international collaboration between local and foreign scholars, in both Africa and Asia.

It is essential for osteologists interested in conducting laboratory and field research in foreign countries to make early and open contact with the governmental administrators and local scholars in any country in which they intend to work. Research must go hand-in-hand with development in these situations, ensuring meaningful, uninterrupted progress and productive science.

17.7 Relevant Codes of Ethics and Ethical Statements

Many organizations, professional associations, and committees with members who work in the fields of osteology, archaeology, and forensic anthropology have drafted codes of ethics or ethical statements as guidance for their members and for others who work with osteological material. The entire texts of these codes and statements are too long to include here; instead, the relevant sections of just one code—that of the American Association of Physical Anthropologists—are presented as an example:

17.7.1 American Association of Physical Anthropologists: Code of Ethics (2003)

A. Responsibility to people . . . with whom anthropological researchers work and whose lives and cultures they study.

1. Anthropological researchers have primary ethical obligations to the people...they study and to the people with whom they work. These obligations can supersede the goal of seeking new knowledge, and can lead to decisions not to undertake or to discontinue a research project when the primary obligation conflicts with other responsibilities, such as those owed to sponsors or clients. These ethical obligations include:

...

- To work for the long-term conservation of the archaeological, fossil, and historical records*
- To consult actively with the affected individuals or group(s), with the goal of establishing a working relationship that can be beneficial to all parties involved*

...

4. Anthropological researchers should obtain in advance the informed consent of persons...owning or controlling access to material being studied, or otherwise identified as having interests which might be impacted by the research. It is understood that the degree and breadth of informed consent required will depend on the nature of the project and may be affected by requirements of other codes, laws, and ethics of the country or community in which the research is pursued. Further, it is understood that the informed consent process is dynamic and continuous; the process should be initiated in the project design and continue through implementation by way of dialogue and negotiation with those studied.... Informed consent, for the purposes of this code, does not necessarily imply or require a particular written or signed form. It is the quality of the consent, not the format, that is relevant.

...

6. While anthropologists may gain personally from their work, they must not exploit individuals, groups, or cultural or biological materials. They should recognize their debt to the societies in which they work and their obligation to reciprocate with people studied in appropriate ways.

B. Responsibility to scholarship and science

1. Anthropological researchers must expect to encounter ethical dilemmas at every stage of their work, and must make good-faith efforts to identify potential ethical claims and conflicts in advance when preparing proposals and as projects proceed.

2. Anthropological researchers bear responsibility for the integrity and reputation of their discipline, of scholarship, and of science. Thus, anthropological researchers are subject to the general moral rules of scientific and scholarly conduct: they should not deceive or knowingly misrepresent (i.e., fabricate evidence, falsify, plagiarize), or attempt to prevent reporting of misconduct, or obstruct the scientific/scholarly research of others.

3. Anthropological researchers should do all they can to preserve opportunities for future fieldworkers to follow them to the field.

4. Anthropological researchers should utilize the results of their work in an appropriate fashion, and whenever possible disseminate their findings to the scientific and scholarly community.

5. Anthropological researchers should seriously consider all reasonable requests for access to their

data and other research materials for purposes of research. They should also make every effort to ensure preservation of their...data for use by posterity.

C. *Responsibility to the public*

1. *Anthropological researchers should make the results of their research appropriately available to sponsors, students, decision makers, and other non-anthropologists. In so doing, they must be truthful; they are not only responsible for the factual content of their statements but also must consider carefully the social and political implications of the information they disseminate. They must do everything in their power to insure that such information is well understood, properly contextualized, and responsibly utilized. They should make clear the empirical bases upon which their reports stand, be candid about their qualifications and philosophical or political biases, and recognize and make clear the limits of anthropological expertise. At the same time, they must be alert to possible harm their information may cause people with whom they work or colleagues.*

Suggested Further Readings

Bray, T. (1995) Repatriation: A clash of world views. *AnthroNotes: National Museum of Natural History Bulletin for Teachers* 17.

A detailed outline of the history of repatriation in the United States, repatriation legislation, Native American and scientific concerns, and repatriation outreach.

Committee on Science, Engineering, and Public Policy (U.S.), National Academy of Sciences (U.S.), National Academy of Engineering, and Institute of Medicine (U.S.). (2009) *On being a scientist: A guide to responsible conduct in research* (3rd ed.). Washington, DC: National Academy Press. 82 pp.

This guide describes a code of conduct for researchers and explores scientific ethical concerns, such as data treatment, error, reporting, safety, authorship, animal subjects, and human participants.

Grauer, A. L. (1995) *Bodies of evidence: Reconstructing history through skeletal analysis*. New York, NY: Wiley-Liss. 247 pp.

An edited volume concerned with the analysis of skeletal remains from historic cemeteries.

Hastings, D. and Sampson, D. (1997) Q: Should scientists be allowed to 'study' the skeletons of ancient American Indians? *Insight on the News* 13:24–27.

An exploration of the issues raised by the Kennewick skeleton and related NAGPRA legislation.

Johnson, G. (2002) Tradition, authority and the Native American Graves Protection and Repatriation Act. *Religion* 32:355–381.

This paper reviews NAGPRA legislation and explores Native American appeals to the “traditional” in establishing claims to remains.

Jones, D. G., and Harris, R. J. (1998) Archaeological human remains. *Current Anthropology* 39:253–264.

A global view of the issues surrounding reburial, by anatomists.

Krogman, W. M., and İşcan, M. Y. (1986) *The human skeleton in forensic medicine* (2nd ed.). Springfield, IL: C. C. Thomas. 551 pp.

A comprehensive look at forensic applications in osteology.

Larsen, C. S., and Walker, P. L. (2005) The ethics of bioarchaeology. In: T. R. Turner (Ed.) *Biological anthropology and ethics: From repatriation to genetic identity*. Pp. 111–119. Albany, NY: State University of New York Press.

This chapter details ethical motivations and responsibilities for research on human skeletal remains.

Layton, R. (Ed.) (1994) *Conflict in the archaeology of living traditions* (2nd ed.). New York, NY: Routledge. 276 pp.

An edited volume with a wide range but a skewed collection of contributions that address ethics as it relates to archaeology, particularly the reburial issue.

Lynott, M. J. (1997) Ethical principles and archaeological practice: development of an ethics policy. *American Antiquity* 62:589–599.

A revised description of clear ethical guidelines for bioarchaeologists developed around 8 core principles.

Mihesuah, D. A. (1996) American Indians, anthropologists, pothunters, and repatriation: Ethical, religious, and political differences. *American Indian Quarterly* 20:229–237.

This paper lists and explores Native American positions on repatriation, NAGPRA legislation, and notions of “desecration.”

N.A.P.A. (1988) *Ethical guidelines for practitioners*. National Association for the Practice of Anthropology.

Ethical guidelines for practitioners in all anthropological sub-disciplines.

Ochani, S. C., Ahmad, A. M., and Malik, F. R. (2004) Modern grave robbers. *Student BMJ* 12:466–467.

This article describes the theft of human remains from grave sites for use in medical school study.

Ousley, S. D., Billeck, W. T., and Hollinger, R. E. (2005) Federal repatriation legislation and the role of physical anthropology in repatriation. *Yearbook of Physical Anthropology* 41:2–32.

A thoughtful argument for the unique and important role physical anthropologists play in the repatriation process.

Richman, J. R. and Forsyth M. P. (Eds.) (2004) *Legal perspectives on cultural resources*. Walnut Creek, CA: Altamira Press. 284 pp.

This volume highlights the legal perspective of cultural affiliation, repatriation, and precedence.

Salmon, M. H. (1997) Ethical considerations in anthropology and archaeology, or relativism and justice for all. *Journal of Anthropological Research* 53:47–60.

This paper deals with the conflict presented by relativism and ethical judgements and explores the role of the anthropologist in the promotion of respect for cultural belief, practice, and values.

Seidemann, R. M. (2009) Altered meanings: The Department of the Interior’s rewriting of the Native American Graves Protection and Repatriation Act to regulate culturally unidentifiable human remains. *Temple Journal of Science, Technology, & Environmental Law* 28:1–47.

This article covers the legislative history of NAGPRA and provides an overview of recent efforts by the Department of the Interior to undermine the original intent of the law.

Springer, J. W. (2006) Scholarship vs. Repatriationism. *Academic Questions* Winter 2005–06:6–36.

The author examines repatriationism as an ideology that "... has attacked the entire basis of natural science and genuine scholarship, and sought to replace it with a combination of racial collectivism, animistic religion and postmodernist ideology." (p. 6)

Turner, T. R. (Ed.) (2005) *Biological anthropology and ethics: From repatriation to genetic identity*. Albany, NY: State University of New York Press. 327 pp.

A compilation of essays on 15 ethical topics in the various fields of biological anthropology.

Ubelaker, D. H., and Grant, L. G. (1989) Human skeletal remains: Preservation or reburial? *Yearbook of Physical Anthropology* 32:260–287.

A comprehensive review of the issue from the perspective of human osteologists at the Smithsonian. Scientific, legal, political, and ethical issues are discussed.

Vitelli, K. D., and Colwell-Chantthaphonh, C. (Eds.) (2006) *Archaeological ethics* (2nd ed.). Walnut Creek, CA: AltaMira Press. 234 pp.

An updated compilation of articles from *Archaeology* magazine, covering looting, reburial, and professional behavior; with article summaries, discussion questions, and further readings presented for each article.

Walker, P. L. (2004) Caring for the dead: Finding a common ground in disputes over museum collections of human remains. In: G. Grupe and J. Peters (Eds.) *Documenta archaeobiologiae 2: Conservation policy and current research, Yearbook of the state collection of anthropology and palaeoanatomy*. Pp. 13–27. Rahden, Germany: Verlag Marie Leidorf.

This paper summarizes the content, interpretation, and impact of NAGPRA legislation.

Walker, P. L. (2008) Bioarchaeological ethics: A historical perspective on the value of human remains. In: M. A. Katzenberg and S. R. Saunders (Eds.), *Biological anthropology of the human skeleton* (2nd ed.). Pp. 3–39. New York, NY: Wiley-Liss, Inc.

A comprehensive exposition of bioarchaeological ethics, this chapter reviews the multiple issues surrounding work on human remains, advocates an ethical approach to their study, and outlines several potential sources of conflict.

Watkins, J. (2004) Becoming American or becoming Indian? NAGPRA, Kennewick and cultural affiliation. *Journal of Social Archaeology* 4:60–80.

This paper investigates the immediate impact of the Kennewick decision and NAGPRA and speculates on the effect of the decision on Indian-archaeologist relationships.

Weiss, E. (2008) *Reburying the past: The effects of repatriation and reburial on scientific inquiry*. New York, NY: Nova Science Publishers. 137 pp.

A book that provides a wide-ranging examination of ethical issues in human osteology, and comes down firmly on the side of science, pursuing the implications of the book's first sentence: "As scientists, it is our ethical obligation to study and try to explain the world around us. NAGPRA and other repatriation laws obstruct the process of scientific endeavors."

Chapter 18

ASSESSMENT OF AGE, SEX, STATURE, ANCESTRY, AND IDENTITY OF THE INDIVIDUAL

WHEN OSTEOLOGICAL REMAINS are recovered from forensic and archaeological situations, the osteologist is often called on to make more than just a determination of whether the remains are human. Human skeletal remains frequently reach the osteologist without any documentation about their individual sex, age, stature, or ancestry. The bulk of the literature on human osteology is composed of thousands of books and articles describing the development of methods to allow accurate and precise identification of individual traits in skeletal remains. This research continues today, even after more than a century of intensive study. All of this research and publication has been driven by the need for basic biological information about skeletal material from forensic and archaeological contexts. In archaeology, individual biological attributes of a skeleton become the fundamental components of work in the investigation of mortuary practices, paleopathology, and paleodemography. In forensic osteology, these individual biological attributes are important in narrowing the field of investigation to certain subsets of people and in **individuating** (establishing the individual identity of) the remains. This chapter is an introduction to the techniques that are used in determining the sex, age, stature, ancestry (biological/geographic/populational affinity or “race”), and individuation of human skeletal remains.

Our focus on the human skeletal elements in Chapters 4–13 was aimed at recognition, providing a guide to diagnostic aspects of human bones. Size and shape characteristics usually allow for the unambiguous sorting of human from nonhuman bone, even in very fragmentary material. Although the determination of sex from skeletal remains may appear to be an analogous binary decision, only a few skeletal characters allow the osteologist to make this choice. Furthermore, the other characteristics discussed in this chapter—individual age, stature, and ancestry—do not lend themselves to such easy and simple divisions as human/nonhuman or male/female. Rather, they grade continuously from pre-natal to elderly, from short to tall, and from one geographic group to another. For this reason, it is often best to consider determination of these characteristics as estimations (ideally, probabilistic estimations of facts) rather than as facts themselves.

18.1 Accuracy, Precision, and Reliability of Determinations

Accuracy is the degree to which a determination conforms to reality. Precision is the degree of refinement with which a determination is made. Aging a mandible as subadult might be accurate, for example, but it would still be imprecise. How accurately and precisely can an osteologist determine the sex, age, stature, and ancestry of human skeletal remains? There is no simple answer to the question. Any identification of a biological parameter such as sex, age, stature, or ancestry is, in effect, a probability statement. The likelihood that a given identification is accurate depends on a number of different factors that are worth general consideration before we turn to the analytical methods themselves.

- The accuracy and precision of determinations of sex, age, and ancestry depend on the broader age category to which the individual belongs. Younger individuals can, in general, be aged more precisely than older individuals. For example, tooth formation and eruption are well-documented, although somewhat variable, and the timing of epiphyseal formation and fusion is likewise well-established. As these growth processes taper off at maturity, there is little continuing skeletal change to monitor. Subsequent changes in the adult skeleton are often degenerative and task- or health-specific, and therefore not as well-correlated with age. Although precise skeletal aging becomes more difficult with adults, establishing the sex of an individual becomes easier. This is because many sexual characteristics of the skeleton become most pronounced only once an individual begins to sexually mature. Most of the criteria established for deducing ancestry are only useful in comparisons between adults. Krogman and İşcan (1986) provide a more detailed overview of these concerns in their text on forensic osteology.
- The accuracy and precision of determinations depend on available skeletal elements. Different elements have different developmental stages. Some criteria, such as dental eruption sequence, correspond more closely to chronological age than others, such as cranial suture closure. Some skeletal elements, such as the pubis, display sexually diagnostic characteristics, whereas others do not. Some elements, such as the femur, show high correlations with stature, whereas others do not. Some bones of the cranium are useful in discriminating between modern human groups, and others are not.
- The accuracy and precision of determinations depend on sample composition. Accuracy of identification diminishes when the osteologist is forced to identify isolated individuals by means of age and sex standards derived from other populations. The most accurate and precise sexing and aging estimates are obtained when it is possible to arrange many skeletal specimens in a series (to *seriate*) and to compare within a single biological population. For estimating sex, age, or ancestry, it is always a great advantage to work with populations of skeletons rather than with isolated finds. This is sometimes the case in archaeological settings, but forensic settings rarely provide the opportunity to work with large unknown samples.
- The accuracy and precision of determinations depend on the analytical methods used. Different methods yield determinations of sex and age that have different reliabilities. For example, sexing a pubis with the Phenice technique (Section 18.4.4) is highly reliable, whereas using the width of the sciatic notch is far less reliable.
- The accuracy and precision of determinations depend on the suitability of the analytical methods to the unknown individual or sample. Most standards used for sexing and aging skeletal remains have been established on the basis of modern European and American skeletal series. These standards have not been shown to apply equally to human populations in other parts of the world or from prehistoric contexts (see Mensforth and Lovejoy, 1985; Ubelaker, 1987; King et al., 1998), and some studies have suggested that interpopulational differences limit their utility (Schmitt, 2004). Not only is there variation within single populations in the rate of skeletal maturation, but there is also significant variation

between populations (Lampl and Johnson, 1996). This factor is significant due to the limited number of populations on which the currently used methods have been based (Section 18.2).

- The accuracy and precision of determinations depend on research context. The degree of accuracy needed in a particular analysis depends on the questions being asked and the problems being investigated. If the problem involves merely sorting subadult mandibles from adult mandibles, accuracy should be 100%. However, if the investigation necessitates separation of 35-year-old from 36-year-old mandibles, no known method will be accurate.

18.2 From Known to Unknown: Using Standard Series

To determine the biological attributes of sex, age, stature, or ancestry for skeletal remains, the osteologist must proceed by comparing—directly or indirectly—the unknown skeletal elements to a standard series of population- and age-appropriate skeletal individuals with reliably known ages, sexes, statures, and ancestries. Where do such series exist? Not in many places—certainly not in archaeological cemeteries that lack written records. Radiographic studies of modern human development have proven important in establishing aging standards for use by osteologists. Unfortunately, many features of bones are not easily visible by plane (*i.e.*, two-dimensional) radiography. Some interesting work is being done using three-dimensional volume-rendered CT scans as comparative series (*eg.*, Ramsthaler et al., 2010), but the technique is not widely accepted and there are currently no 3-D data sets of complete series of known individuals.

What osteologists have done when attempting to solve for the unknown biological qualities of skeletal material is to make intensive use of any of several major skeletal collections in which there are more-or-less adequate records of sex, age, stature, and ancestry (see Table 18.1 for a detailed listing of these collections). Standards and methods developed from these collections all suffer some limitations. In North American collections, racial categories are, for the most part, “black” and “white,” which are legal and social terms based on local custom rather than biological ancestry. Admixture is unaccounted for. Those collections that originate from dissection rooms are often biased towards those of below-average socioeconomic status, and males significantly outnumber females. In most cases, the ages of death recorded in the collection records are not self- or family-reported, but are only estimates made by the coroner, often rounded to the nearest five years in adults.

To summarize, the accuracy and precision of an osteologist’s attributions of sex, age, or stature to a skeleton for which these variables are unknown always depend on standards derived from a series of skeletons originally accompanied by independent records of these same biological attributes. There are significant problems involved with assessing the biological attributes of archaeologically derived skeletal material using these and other collections of modern human bones. The most important among these problems is that few series contain nonmodern individuals and fewer still contain people who lived under aboriginal, non-Western subsistence conditions. The effects of different lifestyles on individuals that make up skeletal series can be dramatic. For example, the rate and degree of tooth wear are higher in aboriginal populations, as is the amount of muscular stress and osteological reaction to that stress. It is critical to keep the limitations of skeletal collections in mind when using them (or the data derived from them) to assist in making determinations of age, sex, stature, or ancestry.

18.3 Estimation of Age

Individual age determination in skeletal remains involves estimating the individual’s age at the time of death (as opposed to the amount of time that has elapsed since death). Ubelaker (1989: 63) succinctly encapsulates the procedures and problems inherent in aging skeletal remains:

Collection, Location	Individuals	Dates of death	Sex bias?	Age bias?	Ancestry	Available for research?
Hamann-Todd coll., Case Western Reserve Univ. Cleveland, OH	3713	1912–1938	80% male (2979 ♂:700 ♀) (34 unknown sex)	most 20–80 (range: 0–105)	61% “white” 38% “black”	Yes
Korean War dead, U.S. Army Quartermaster Corps	450	1950–1953	primarily male	most 17–25 (range: 17–50)	primarily “white”	No: reburied 1956–1958
Terry collection, Washington, DC	1728	1920–1965	59% male (1018 ♂/713 ♀)	most ≥ 45 (range: 14–102)	45% “white” 54% “black”	Yes
Huntington collection, Washington, DC	4054	1892–1920	75% male		about 70% “white”	Yes
Chief Medical-Examiner’s office, Los Angeles, CA	1225	1977–1979	60% male (739 ♂/486 ♀)	range: 14–99		
W. Montague Cobb coll., Washington, DC	634	1932–1969	70% male (684 ♂/287 ♀)	most > 25 (only 13 ≤ 25)	84% “black” 19% “white”	Yes
NMNH Fetal collection, Washington, DC	320	1904–1917	54% male (152 ♂/129 ♀)	Fetal–neonate only	43% “white” 54% “black”	Yes
Maxwell collection Albuquerque, NM	257 and growing	1975–present		range: 0–80+		Yes
Bass collection, Knoxville, TN	669	1981–present	71% male (491 ♂/170 ♀)	80% adult (536/669)		Yes
Univ. of Iowa/Stanford coll. Iowa City, IA	1100	1910s–1920s				Yes
St. Thomas’ cemetery, Ontario, Canada	579	1821–1874			European-Amer.	No: reburied
J.C.B. Grant collection, Toronto, Ontario, Canada	202	1928–early 1950s	87% male (176 ♂/26 ♀)	73% are over 40 years old	European-Amer.	Yes
Christ Church, Spitalfields, London, UK	968	1729–1859		81% adult (782/968)	European	Yes
St. Bride’s Church, London, UK	244	1761–1851		94% ≥ 18 (range: 0–91)	European	Yes
Universiteit Leiden, Netherlands					European	
Museu Bocage collection, Lisbon, Portugal	1692 and growing	1880–1975	“sexes equally represented”	“adults and juveniles”	European	Yes
Coimbra cemetery coll., Portugal	570	1904–1938	63% male (357 ♂, 213 ♀)		European	Yes
Dart collection, Johannesburg, SA	2605	1920s–present	71% male (1840 ♂, 756 ♀)	94% ≥ 20 (range: 1–100)	71% “SA African” 18% “white”	Yes
Cape Town Univ., South Africa	ca. 200	1980–1999		most ≥ 50	African	Yes
Pretoria bone collection, South Africa	290 skeletons 704 skulls 541 postcrania	1943–present		range: 0–100	African	Yes

Table 18.1 Documented skeletal collections. Some of the major collections of identified individuals from which standards for aging, sexing, stature, and ancestry have been, and continue to be, formulated.

Documentation	References
Individuals from low socioeconomic status, collected from area hospitals. Only about 16% of the individuals in this collection have sufficiently reliable ages at death to be used in skeletal aging studies.	Thompson (1982) CMNH (n.d.)
A large set of skeletons of American military personnel killed in the Korean War. The set consisted primarily of male individuals with a limited age distribution. Data have seen wide use in estimating age for bony remains.	McKern and Stewart (1957) Coleman (2008)
From Washington University's Anatomy Department, now housed at the Smithsonian Institution's National Museum of Natural History.	Hunt and Albanese (2005)
European immigrants, NYC residents. Curated at the Smithsonian Institution's National Museum of Natural History.	NMNH (n.d.)
Pubic bones gathered from autopsied individuals in Los Angeles County.	Brooks and Suchey (1990)
Remains of individuals used as cadavers in anatomy classes at Howard University. African-Americans from the Washington, DC, area.	Watkins (in press)
Individuals are from spontaneous abortions and still births. Most are from Washington, DC, and Baltimore, MD, but collection includes some from Germany.	Huxley (2005)
	Komar and Grivas (2008)
Bodies are donated and used for decomposition research before being skeletonized.	Wilson <i>et al.</i> (2007)
Individuals from diverse ethnic groups who died in the San Francisco area, originally curated at Stanford University.	Schermer <i>et al.</i> (2000)
Historic cemetery site in Belleville, Ontario, Canada. Approximately 37% of the total of 1564 interments were recovered, 80 of which are positively identified.	Saunders <i>et al.</i> (1993a)
Individuals originally received by the Anatomy Department from local hospitals and welfare institutions. Now curated at the Dept. of Anthropology.	
Historic cemetery site in England.	Cox (1996, 1998) Molleson and Cox (1993)
19th Century lead-coffin burials recovered from the crypt of St. Brides Church in England. The crypt was discovered after the church was destroyed in 1940.	Ivanhoe (1982) Scheuer and Bowman (1995)
	MacLaughlin and Bruce (1986)
Individuals recovered from three cemeteries in Lisbon. 699 individuals have specific biographic data associated, including sex, age at death, cause of death, etc.	Cardoso (2005, 2006)
Historic cemetery site in Lisbon.	MacLaughlin (1990b) Cunha (1995)
Most of the collection derives from unclaimed bodies in regional South African hospitals. Identified to ethnic group.	Saunders and DeVito (1991) Dayal <i>et al.</i> (2009)
	Robinson and Bidmos (2009)
The collection is derived from the nearly 6500 cadavers accepted for use in teaching medical anatomy. Only individuals with known sex, age, and ancestry become part of the research collection.	L'Abbé <i>et al.</i> (2005) Robinson and Bidmos (2009)

Estimation of age-at-death involves observing morphological features in the skeletal remains, comparing the information with changes recorded for recent populations of known age, and then estimating any sources of variability likely to exist between the prehistoric and the recent population furnishing the documented data. This third step is seldom recognized or discussed in osteological studies, but it represents a significant element.

However, many of the attributes that are used to determine biological age do not seem to be environmentally plastic. The degree to which age standards derived from modern osteological collections may be applied to prehistoric populations is a matter of continuing debate (Hoppa, 2000), but available studies indicate that individual variation often swamps populational differences.

Over the course of a lifetime, elements of the skeleton undergo sequential chronological change. In infancy these changes primarily involve the appearance of various skeletal elements. During childhood and adolescence, bones and teeth continue to appear, and epiphyses form and fuse. Even after age 20, bones continue to fuse, metamorphose, and degenerate. This progression forms the foundation for studies of skeletal aging. However, it is important to note that even normal development of the infant is discontinuous and saltatory (Lampel et al., 1992), and that there is substantial variation among different individuals in the rate and timing of developmental changes. Pathology can also play a role (Sherwood et al., 2000).

Whereas sex identification in skeletal remains is dichotomous, determination of the age-at-death of an individual is more complex because it involves arbitrarily dividing the continuum of growth. Individuals of the same chronological age can show different degrees of development. This is true for skeletal anatomy as well as for behavior. Thus, even when osteological standards based on known samples are perfect, there is always a degree of imprecision in aging skeletal remains. What is the magnitude of this imprecision?

As noted earlier, whether dealing with cranial bones, teeth, or postcranial elements, an already-established “system” is used for osteological aging; criteria for aging are identified based on a population whose individuals have known ages. It is possible, for example, to use radiographs of people in living populations to establish that human permanent molars erupt at about 6, 12, and 18 years of age. This control series can then be used to age each individual in an unknown skeletal series, under the assumption that dental eruption followed the same periodicity in both groups.

One drawback in such an approach to an unknown skeletal series is that age assignments are made on an individual basis, without reference to other individuals in the unknown series. Such assignments place individuals into an **age range** (for instance, 12–18 years) or an **age class** (for instance, “young adult”—see Figure 18.1). This aging is not as precise as assigning an absolute age, for example, of 15 years. In other words, the more coarsely you divide a continuum, the more imprecise the aging. As Lovejoy and colleagues (1997) note, there are two major sources of error in any estimate of age-at-death. These are the inherent variation within the biological process of aging itself, and the investigator’s skill in estimating the biological age of the unknown specimen. Furthermore, as Falys and Lewis (in press) point out, there are alarming discrepancies in the use of even broad age classes, such as “adult.”

An approach that should always be taken with a large sample of unknown individuals to help overcome these imprecisions is **seriation**. Prior to estimating each unknown individual’s age, all of the individuals represented by the skeletal element under analysis in the unknown series are arranged in a sequence of increasing age. This approach has many benefits (Lovejoy et al, 1985): seriation may be done quickly, with little fatigue; there is no observer error due to time-shift effects (e.g., having to stop in the middle of the analysis because the work day ends); there is constant monitoring of results, with ability to correct observer errors; and there is no loss of accuracy as a result of pooling individuals into age categories. Once the sample under analysis is seriated, at least the individuals have been aged *relative to each other*.

Seven age classes commonly used to segregate human osteological remains are as follows: **fetus** (before birth), **infant** (0–3 years), **child** (3–12 years), **adolescent** (12–20 years), **young adult** (20–35 years), **middle adult** (35–50 years), and **old adult** (50+ years) (Buikstra and Ubelaker, 1994; see Figure 18.1). Scheuer and Black’s volumes (2000, 2004) represent excellent resources for work involving the aging of immature human skeletal remains.

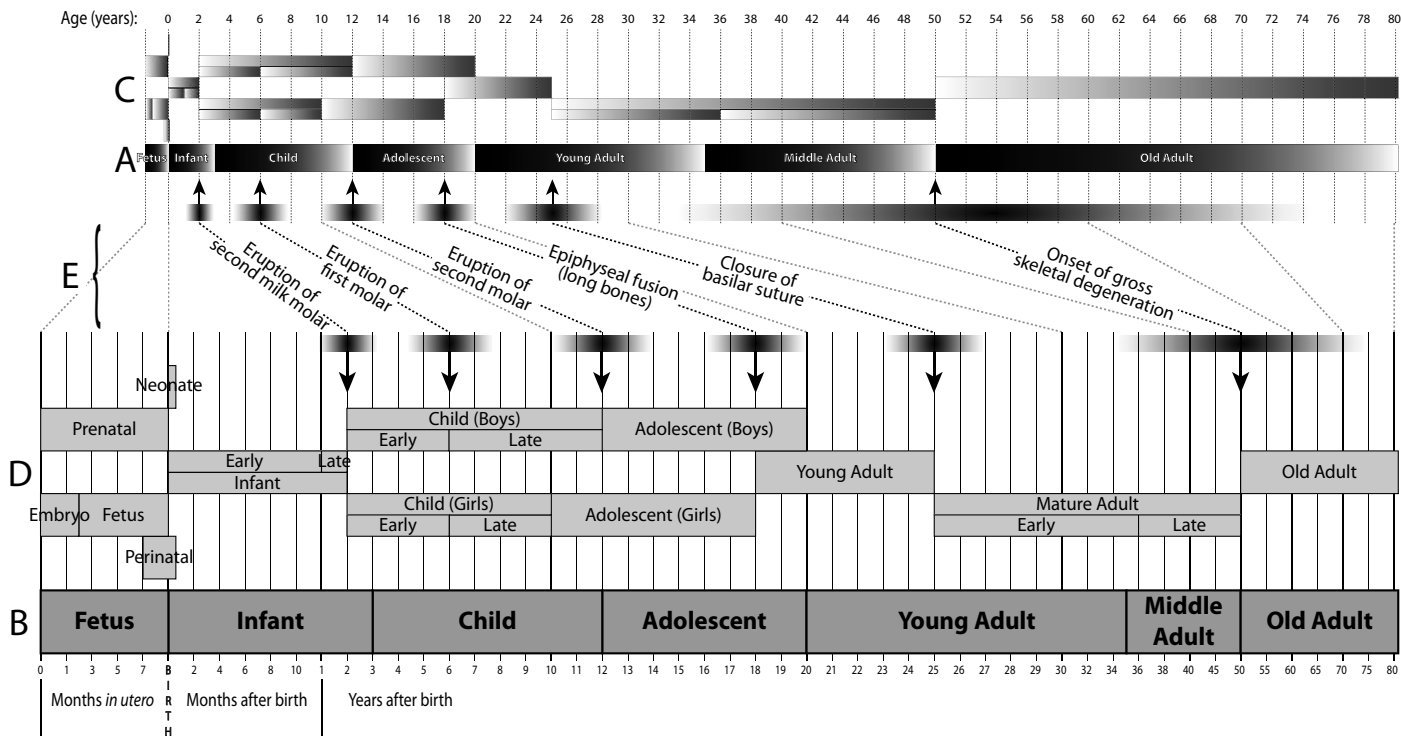


Figure 18.1 Age classes. The seven age classes proposed in Buikstra and Ubelaker’s (1994) Standards volume (A, B), and some alternative age classification terms (C, D) that are more closely tied to developmental milestones (E). **A**) The seven proposed age classes presented on a linear scale. Age-related changes do not occur at a uniform rate throughout life, but rather occur rapidly in the first third of life, then become increasingly slow through the remainder of an individual’s lifetime. **B**) The same seven proposed age classes presented on a nonlinear scale. The classification terms shown at C and D are likewise identical, presented on the two scales. The nonlinear scale gives more emphasis to periods of life that witness more age-related changes, and less emphasis to periods of life with fewer age-related changes. This nonlinear scale will be used in similar diagrams (Figures 18.3, 18.5, 18.8, 18.9, 18.10, 18.14, 18.16, 18.17, 18.18, and 18.19) throughout the rest of this chapter. Because the meanings of terms such as “Young Adult” and “Child” can vary between age classification systems, it is important to specify which system you are using.

18.3.1 Estimating Subadult Age from Teeth

Eruption and wear of the teeth have been used extensively in aging the human skeleton. Tooth development is more closely associated with chronological age than is the development of most other skeletal parts, and it seems to be under tighter genetic control. Because of the regular formation and eruption times for teeth and because these elements are the remains found most commonly in forensic, archaeological, and paleontological contexts, dental development is the most widely used technique for aging subadult remains. Smith (1991) provides a review of the various techniques available. It is important to note that “regular” does not mean “constant.” For example, some infants erupt their teeth earlier in their lives, and different individuals erupt their teeth in different orders (Smith and Garn, 1987). It has been shown that some African-Americans and European-Americans differ in both rate and sexual dimorphism of tooth mineralization (Harris and McKee, 1990).

Tooth formation begins in the embryo a mere 14–16 weeks after conception (Hillson, 1996). There are four distinct periods of emergence of the human dentition. First, most deciduous teeth emerge during the second year of life. The two permanent incisors and the first permanent molar usually emerge between 6 and 8 years. Most permanent canines, premolars, and second molars emerge between 10 and 12 years. Finally, the third molar emerges around 18 years. Of course, there is idiosyncratic variation in all tooth development and eruption.

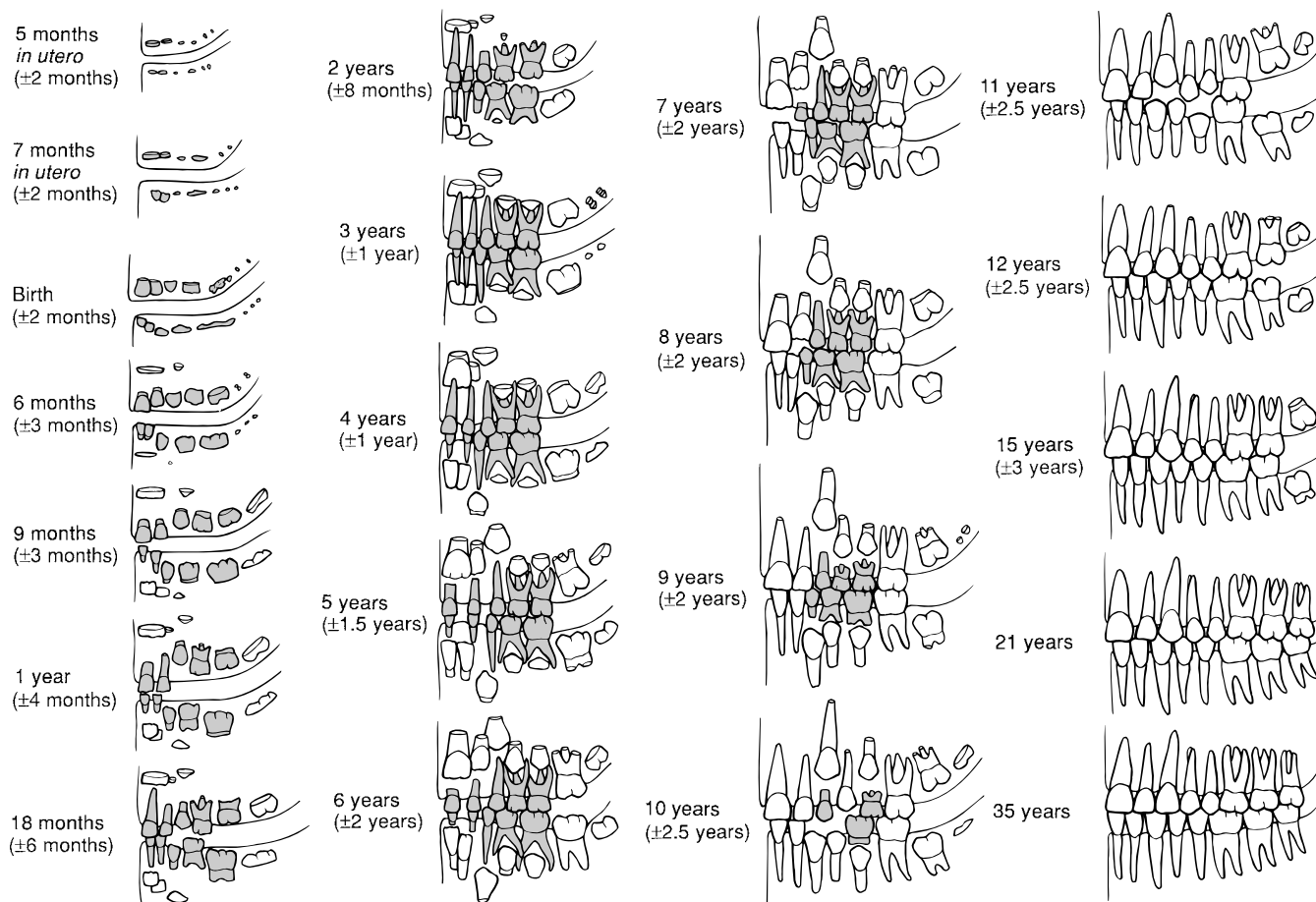


Figure 18.2 Dental development in Native Americans. Adapted from Ubelaker (1999); note that data on the deciduous teeth come from non-Native Americans.

Age may be determined from developing teeth in several ways. One means is by comparing the unknown individual with a chart or atlas showing the mean stage of development of the entire dentition (Figures 18.2 and 18.3). Another is through comparison of the stages of formation with each individual tooth (Table 18.2). Liversidge (1994) discusses the pros and cons of these methods and recommends the atlas approach for both accuracy and ease of use. Hillson (1996) provides an excellent review of all methods of aging the skeleton through use of dental development. The third molar is the most variable tooth in formation and eruption. Mincer et al. (1993) provide data on the formation of this tooth and its use in age estimation.

Ubelaker (2008) provides a graphic summary of data on dental development in Native Americans, which we reproduce in Figure 18.2. Note the possible ranges associated with each stage in the diagram. Figure 18.3 shows the source of these errors. Sex-based variation in development and eruption of teeth is most apparent at the canine position, and this tooth should be afforded less attention when aging erupting dentitions. When assessing the age of a subadult individual based on teeth, note all aspects of development, including the completeness of all crowns and roots (**formation**) and the place of each tooth relative to the alveolar margin (**eruption**). When using published standards, be sure to discriminate between emergence through the alveolar margin (bone) or through the gum (soft tissue). Also note that dental development is sensitive to sex and population differences (İşcan, 1988). For more details on dental development and eruption, see Trodden (1982) and Smith (1991).

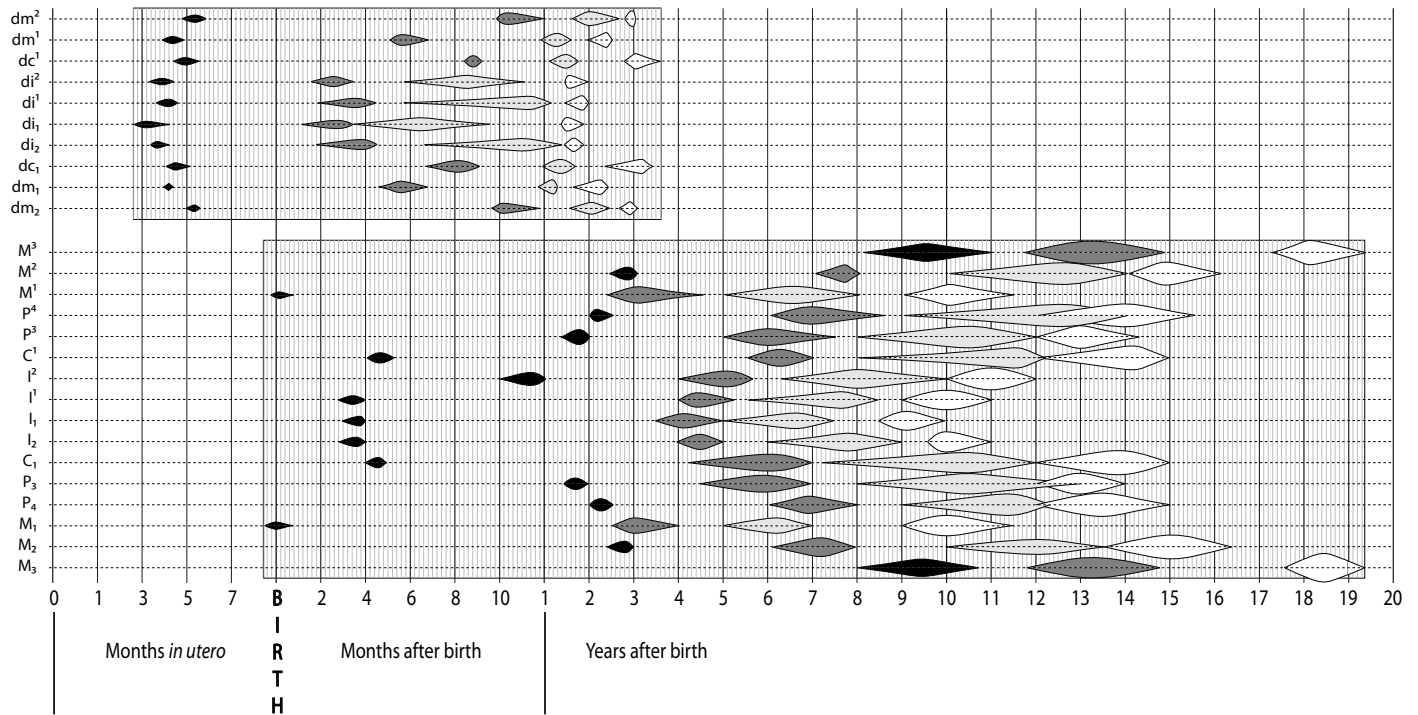


Figure 18.3 Variation in the timing of dental development. Range values are ± 1 SD for the third molars. *Key:* black: crown mineralization begins; dark gray: crown completion; light gray: eruption; white: root completion. For explanation of the nonlinear scale used here, see the caption to Figure 18.1. Based on data from Gustafson and Koch (1974), with third molar data from Anderson *et al.* (1976).

18.3.2 Estimating Adult Age from Teeth

Once a permanent tooth erupts, it begins to wear. Rate and patterns of wear are governed by tooth developmental sequences, tooth morphology, tooth size, internal crown structure, tooth angulation, nondietary tooth use, the biomechanics of chewing, and diet (McKee and Molnar, 1988; Walker *et al.*, 1991). If the rate of wear within a population is fairly homogeneous, it follows that the extent of wear is a function of age. This fact can be used in assigning dental ages to adult specimens. Where this has been tested on modern populations, correlations between known age and tooth wear have been shown to be good (Lovejoy *et al.*, 1985; Richards and Miller, 1991). However, the osteologist should always be on the lookout for cases of accelerated wear due to pathology or use of the teeth as tools (Milner and Larsen, 1991).

The first step in assessing age by dental attrition is application of a seriation of all dentitions based on development and wear. Miles (1963) was the first to establish a scale of attrition based on development. The basics of the technique are as utilized in the following example: A first molar accumulates about 6 years of wear before the second molar of the same individual erupts (assuming eruption at 6 and 12 years, respectively). When a similar amount of wear (6 years' worth) is found on a third molar of another individual (a molar assumed to have erupted at age 18), the age of that individual can be estimated as $18 + 6 = 24$ years. Miles uses 6.0, 6.5, and 7.0 years between successive molar eruption. The technique underestimates individuals over 50 years of age (Miles, 2001). A variety of other techniques have been applied to the quantification of tooth wear (Molnar, 1971; Scott, 1979; Brothwell, 1989; Walker *et al.*, 1991; Dreier, 1994; Mayhall and Kageyamu, 1997).

Lovejoy (1985) has concluded, for the prehistoric Libben skeletal population, a large human osteological series from the midwestern United States, that dental wear assessed by seriation pro-

Table 18.2 Average age (in years) of a skeletal individual based on an assessment of dental development at each crown position^a

		di1	di2	dc	dm1	dm2	I1	I2	C	P3	P4	M1	M2	M3
A. MALES														
Ci	Cusp initiation	—	—	—	—	—	—	—	0.6	2.1	3.2	0.1	3.8	9.5
Cco	Cusp coalescence	—	—	—	—	—	—	—	1.0	2.6	3.9	0.4	4.3	10.0
Coc	Crown outline complete	—	—	—	—	—	—	—	1.7	3.3	4.5	0.8	4.9	10.6
Cr ½	Crown one half	—	—	—	—	—	—	—	2.5	4.1	5.0	1.3	5.4	11.3
Cr ¾	Crown three-fourths	—	—	—	—	—	—	—	3.4	4.9	5.8	1.9	6.1	11.8
Crc	Crown complete	0.15	0.2	0.7	0.4	0.7	—	—	4.4	5.6	6.6	2.5	6.8	12.4
Ri	Root initiated	—	—	—	—	—	—	—	5.2	6.4	7.3	3.2	7.6	13.2
Rcl	Root cleft present	—	—	—	—	—	—	—	—	—	—	4.1	8.7	14.1
R ¼	Root one-fourth	—	—	—	—	—	—	5.8	6.9	7.8	8.6	4.9	9.8	14.8
R ½	Root one-half	—	—	—	—	—	5.6	6.6	8.8	9.3	10.1	5.5	10.6	15.6
R ⅔	Root two-thirds	—	—	—	—	—	6.2	7.2	—	—	—	—	—	—
R ¾	Root three-fourths	—	—	—	—	—	6.7	7.7	9.9	10.2	11.2	6.1	11.4	16.4
Rc	Root complete	1.5	1.75	3.1	2.0	3.1	7.3	8.3	11.0	11.2	12.2	7.0	12.3	17.5
A ½	Root apex half closed	—	—	—	—	—	7.9	8.9	12.4	12.7	13.5	8.5	13.9	19.1
B. FEMALES														
Ci	Cusp initiation	—	—	—	—	—	—	—	0.6	2.0	3.3	0.2	3.6	9.9
Cco	Cusp coalescence	—	—	—	—	—	—	—	1.0	2.5	3.9	0.5	4.0	10.4
Coc	Crown outline complete	—	—	—	—	—	—	—	1.6	3.2	4.5	0.9	4.5	11.0
Cr ½	Crown one half	—	—	—	—	—	—	—	2.5	4.0	5.1	1.3	5.1	11.5
Cr ¾	Crown three-fourths	—	—	—	—	—	—	—	3.5	4.7	5.8	1.8	5.8	12.0
Crc	Crown complete	0.15	0.2	0.7	0.3	0.7	—	—	4.3	5.4	6.5	2.4	6.6	12.6
Ri	Root initiated	—	—	—	—	—	—	—	5.0	6.1	7.2	3.1	7.3	13.2
Rcl	Root cleft present	—	—	—	—	—	—	—	—	—	—	4.0	8.4	14.1
R ¼	Root one-fourth	—	—	—	—	—	4.8	5.0	6.2	7.4	8.2	4.8	9.5	15.2
R ½	Root one-half	—	—	—	—	—	5.4	5.6	7.7	8.7	9.4	5.4	10.3	16.2
R ⅔	Root two-thirds	—	—	—	—	—	5.9	6.2	—	—	—	—	—	—
R ¾	Root three-fourths	—	—	—	—	—	6.4	7.0	8.6	9.6	10.3	5.8	11.0	16.9
Rc	Root complete	1.5	1.75	3.0	1.8	2.8	7.0	7.9	9.4	10.5	11.3	6.5	11.8	17.7
A ½	Root apex half closed	—	—	—	—	—	7.5	8.3	10.6	11.6	12.8	7.9	13.5	19.5

^aThe data are from Smith's (1991) compilation of published studies.

cedures is an important and reliable indicator of adult age-at-death. He found, on the populational level, that dental wear was very regular in form and rate. As Lovejoy notes, the assessment of a single individual in a forensic setting based on dental wear allows only a gross approximation of age, but if an entire biological population is seriated, tooth wear can yield precise results. In fact, Lovejoy and colleagues (1985a) concluded that dental wear is the best single indicator for determining the age of death in skeletal populations. They found dental wear as an age indicator to be accurate and consistently without bias. Figure 18.4 illustrates the wear standards used by these workers. Mays (2002) has also found dental wear to be a reliable indicator in a very different historical Dutch skeletal collection.

Hillson (2005) and Whittaker (2000) discuss methods useful in assessing individual age based on microscopic analysis of the permanent teeth. As teeth age, formation of secondary dentine reduces the coronal height of the pulp cavity. Drusini et al. (1997) used this to age radiographs of adult individuals to ±5 years on 78% of teeth assessed. Other studies have shown that apical translucency of tooth roots correlates with adult age, but applications of the technique have shown it to be less useful than other methods (Kvaal et al., 1994). In some forensic cases, a combination of gingival regression and root transparency may allow aging of adults over 40 and under 80 years of age with a mean error of estimation of ± 10 years (Lamendin et al., 1992). Soomer et




Figure 18.4 Modal tooth-wear patterns of a prehistoric Native American population from Libben, Ohio. Wear is divided into phases for right maxillary (*left*) and left mandibular (*right*) dentitions. Exposed dentine is shown in black. Age in years for the various phases are as follows: A, 12–18; B₁, 16–20; B₂, 16–20; C, 18–22; D, 20–24; E, 24–30; F, 30–35; G, 35–40; H (maxillary), 40–50; H (mandibular), 40–45; I, 45–55. See Lovejoy (1985) for a full description.

al. (2003) provide a comparative overview of various methods applied in forensic work. Amino acid racemization of dentin-derived collagen has become an effective estimator of age in forensic remains (Ohtani and Yamamoto, 1991, 1992, 2005). Griffen et al. (2009) apply this method to archaeological enamel and report that diagenesis of the enamel makes this a poor age indicator in archaeological remains.

18.3.3 Estimating Adult Age from Cranial Suture Closure

It has been appreciated since the 1500s that sutures between various cranial bones fuse progressively as the individual ages. In the early 1900s suture closure enjoyed widespread use in skeletal aging, but the false promise of one or two accurate indicators of adult skeletal age during the

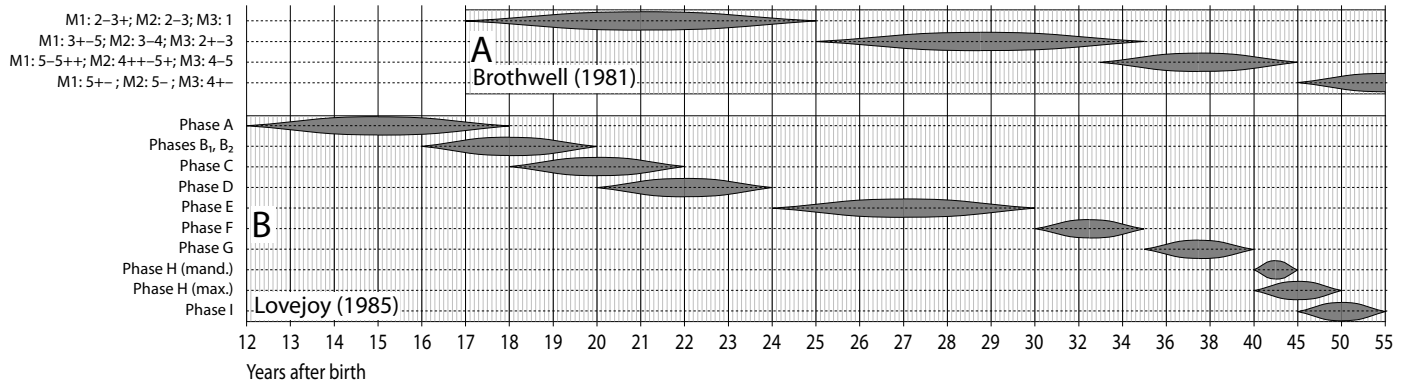


Figure 18.5 Estimates of age that can be obtained through analysis of dental attrition. A) Age estimates that can be obtained with the Brothwell system, based on a Neolithic to Medieval British sample; B) age estimates that can be obtained using the Lovejoy system. The gray spindles illustrate the published range. For explanation of the nonlinear scale used here, see the caption to Figure 18.1. Data for A are taken from stated ranges in Brothwell (1981), and data for B are derived from Lovejoy (1985).

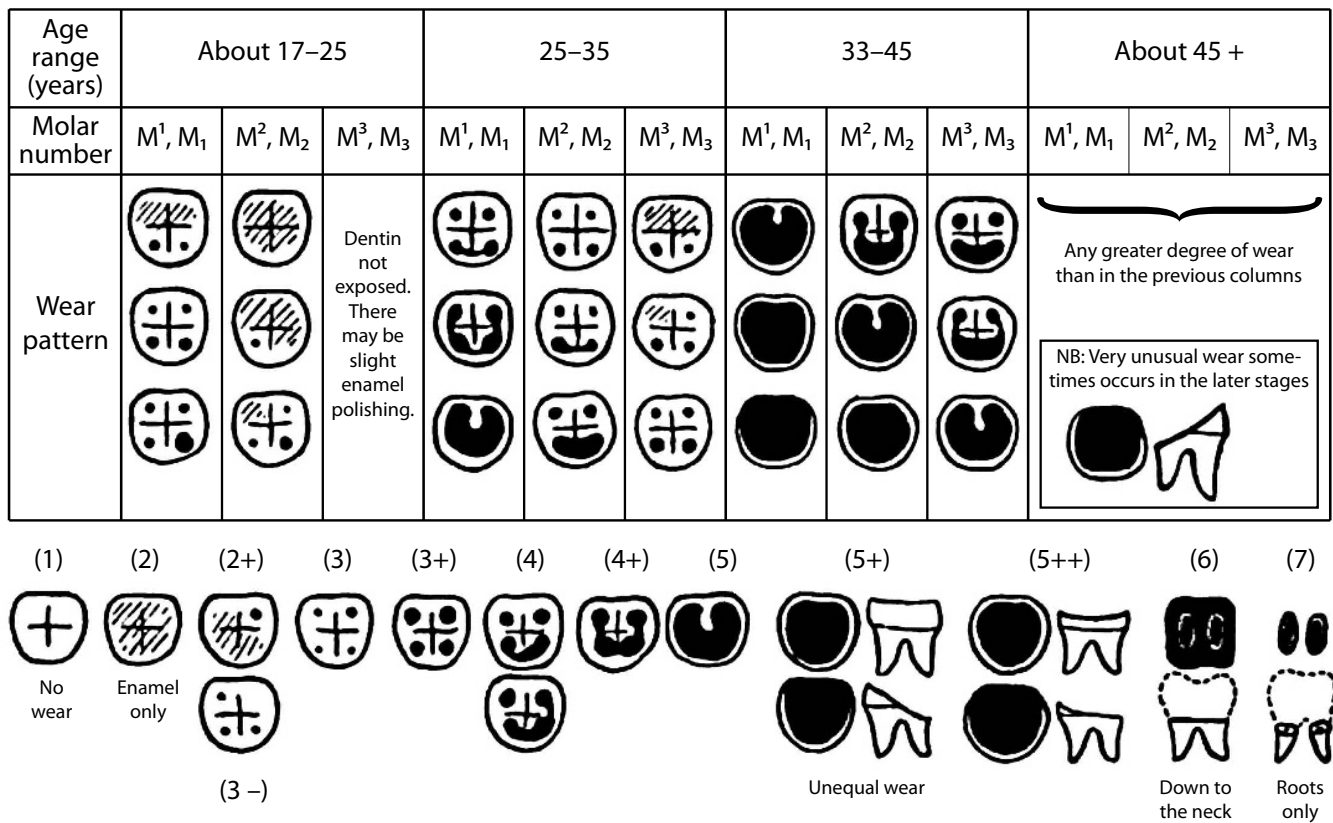


Figure 18.6 Tooth-wear patterns derived from a sample of prehistoric to medieval English skeletons. Top: typical patterns of wear characteristic of four broad age ranges. Below: numerical wear scores for molars. Exposed dentine is shown in black, and worn enamel is hatched. Adapted from Brothwell (1981).

1950s (such as metamorphosis of the pubic symphysis) led to disuse of the technique. Meindl and Lovejoy (1985), however, reinvigorated the study of cranial suture closure. They chose a series of 1-cm segments of ten sutures or suture sites and scored these on a scale of 0 (open) to 3 (complete obliteration). The results erased some of the prejudice against suture closure assessment as a means of skeletal aging in the adult and stimulated more research in this area. Galera et al. (1998) provide a comparative analysis of different cranial suture aging methods. One cranial feature, the sphenoccipital synchondrosis, is particularly useful in aging isolated crania because at least 95% of all individuals have fusion here between 20 and 25 years of age, with a central tendency at 23 years of age (Krogman and İşcan, 1986).

Other cranial sutures show more variation in age of closure. The Ley et al. (1994) work on the Spitalfields population from Britain indicates that there may be sexual and interpopulational differences in the rates of suture closure. This study developed yet another technique of scoring suture closure. The Buikstra and Ubelaker Standards volume (1994) recommends that 17 cranial suture segments each be given a numerical score. The score of 0, or **open**, is given when there is no evidence of any ectocranial closure. A score of 1 is given to suture sites with **minimal closure**. A score of 2 is given to sites with **significant closure**, and a score of 3 is given to a **completely obliterated** suture (complete fusion). Figure 18.7 shows the location of the 1-cm sutural sites.

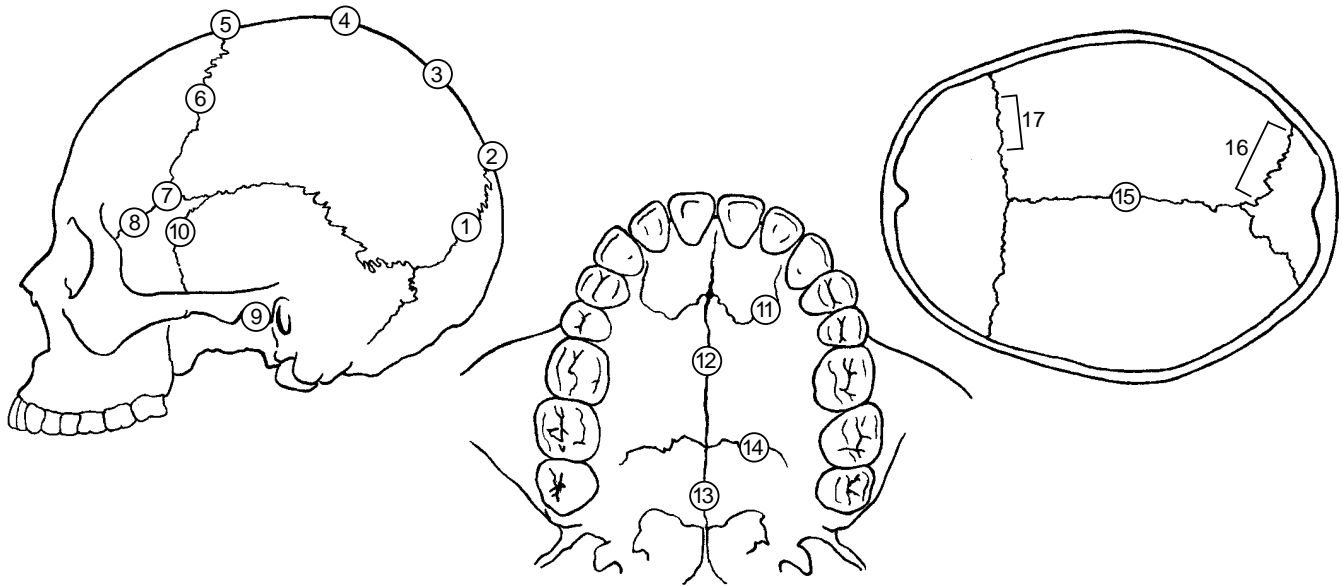
18.3.4 Estimating Subadult Age from Long Bone Length

In the absence of teeth and various epiphyses, subadult individual age may be estimated from long bone length. This procedure of subadult skeletal aging is not as exact as others and should always be done with reference to the same or a closely related skeletal collection. Seriate the growth series and compare the isolated long bone lengths to the series in order to derive ages. In the absence of such series, the data presented in Ubelaker (2008) and Scheuer and Black (2000) are useful for age assessment (Figure 18.9).

18.3.5 Estimating Subadult Age from Epiphyseal Closure

Fusion of a postcranial epiphysis is orderly, and an epiphysis fuses at a known age. However, these ages vary by individual, sex, and population. As Stevenson (1924) points out, the intensity of epiphyseal activity is greatest between ages 15 and 23. Fusion of the epiphysis is progressive and is usually scored as unfused (nonunion), united, or fully fused (complete union). The beginning of epiphyseal union for several elements overlaps the conclusion of tooth eruption, making these aging techniques complementary. Figure 18.11 illustrates the considerable idiosyncratic variation in the chronology of epiphyseal union for several human skeletal elements using data taken from male Korean War dead (McKern and Stewart, 1957). Much of the work on epiphyseal union has been done on long bones, but recent work on vertebrae show the utility of these elements, particularly in aging teenagers and young adults (Albert and Maples, 1995).

It should be noted that union begins earlier in females than in males and that different individuals of the same sex can show very different times of union. The last epiphysis to fuse is usually the medial clavicle, at about 21 years. Late-fusing bones such as the clavicle, however, show wide variation in age at fusion. For example, some medial clavicle epiphyses fuse before 21 years, whereas other individuals show persistent nonfusion at age 30 [for more references, consult Stevenson (1924); Mensforth and Lovejoy (1985); Webb and Suchey (1985); and Krogman and İşcan (1986)]. Growth ends once fusion of all epiphyses occurs, under 28 years of age for the great majority of cases. As a result, fewer age indicators remain for the postcranial skeleton of the adult individual.



Site	Description
1 Midlambdoid	Midpoint of left lambdoid suture
2 Lambda	Intersection of sagittal and lambdoid sutures
3 Obelion	At obelion
4 Anterior sagittal	One-third the distance from bregma to lambda
5 Bregma	At bregma
6 Midcoronal	Midpoint of left coronal suture
7 Pterion	Usually where the parietosphenoid suture meets the frontal
8 Sphenofrontal	Midpoint of left sphenofrontal suture
9 Inferior sphenotemporal	Intersection of left sphenotemporal suture and line between articular tubercles of the temporomandibular joint
10 Superior sphenotemporal	On left sphenotemporal suture 2 cm below junction with parietal
11 Incisive suture	Incisive suture separating maxilla and premaxilla
12 Anterior median palatine	Score entire length on paired maxillae between incisive foramen and palatine bone
13 Posterior median palatine	Score entire length
14 Transverse palatine	Score entire length
15 Sagittal (endocr.)	Entire sagittal suture endocranially
16 Left lambdoid (endocr.)	Score indicated portion
17 Left coronal (endocr.)	Score indicated portion

Meindl and Lovejoy (1985) "vault" sutural ages (add scores for sites 1–7).			Meindl and Lovejoy (1985) "lateral-anterior" sutural ages (add scores for sites 6–10).		
Composite Score	Mean Age	Standard Deviation	Composite Score	Mean Age	Standard Deviation
0	—	—	0	—	—
1–2	30.5	9.6	1	32.0	8.3
3–6	34.7	7.8	2	36.2	6.2
7–11	39.4	9.1	3–5	41.1	10.0
12–15	45.2	12.6	6	43.4	10.7
16–18	48.8	10.5	7–8	45.5	8.9
19–20	51.5	12.6	9–10	51.9	12.5
21	—	—	11–14	56.2	8.5
			15	—	—

Figure 18.7 Cranial suture fusion sites, their scoring, and interpretation. After P. Walker, in Buikstra and Ubelaker, (1994). A score of from 0 (unfused) to 3 (completely obliterated) is assigned to each site. Sites are 1-centimeter ectocranial segments of the sutures as shown. Endocranial segments are slightly larger. In the Meindl and Lovejoy (1985) system, scores are independently summed for vault (numbers 1–7) and lateral-anterior (numbers 5–10) sites. Other suture sites, such as the maxillary suture (Mann et al., 1991), have been used to segregate individuals into even broader age categories, but their use in forensic cases has been questioned (eg, Gruspier and Mullen, 1991).

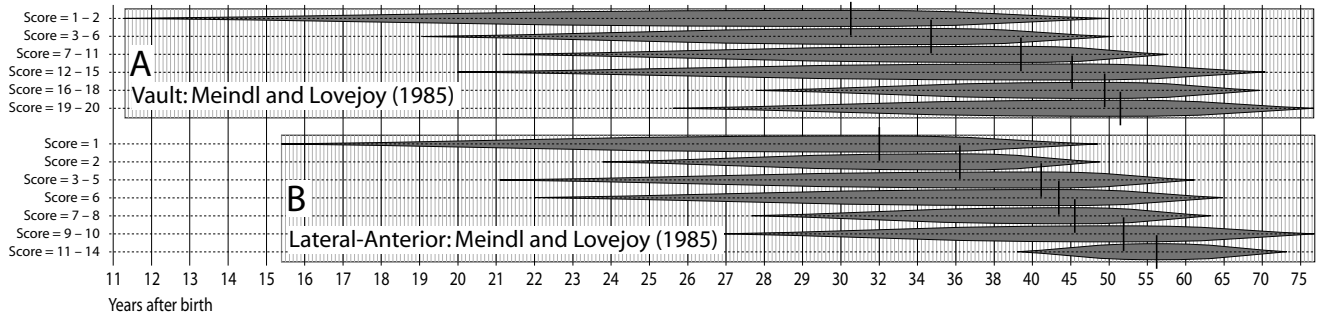


Figure 18.8 Estimates of age that can be obtained through analysis of cranial suture fusion. A) Composite fusion scores for vault sutures; B) composite fusion scores for lateral-anterior sutures. The short black vertical lines represent mean ages for each phase, and the gray spindles represent ± 2 SD ($\approx 95\%$ range). For explanation of the nonlinear scale used here, see the caption to Figure 18.1. Data are derived from Meindl and Lovejoy (1985:63).

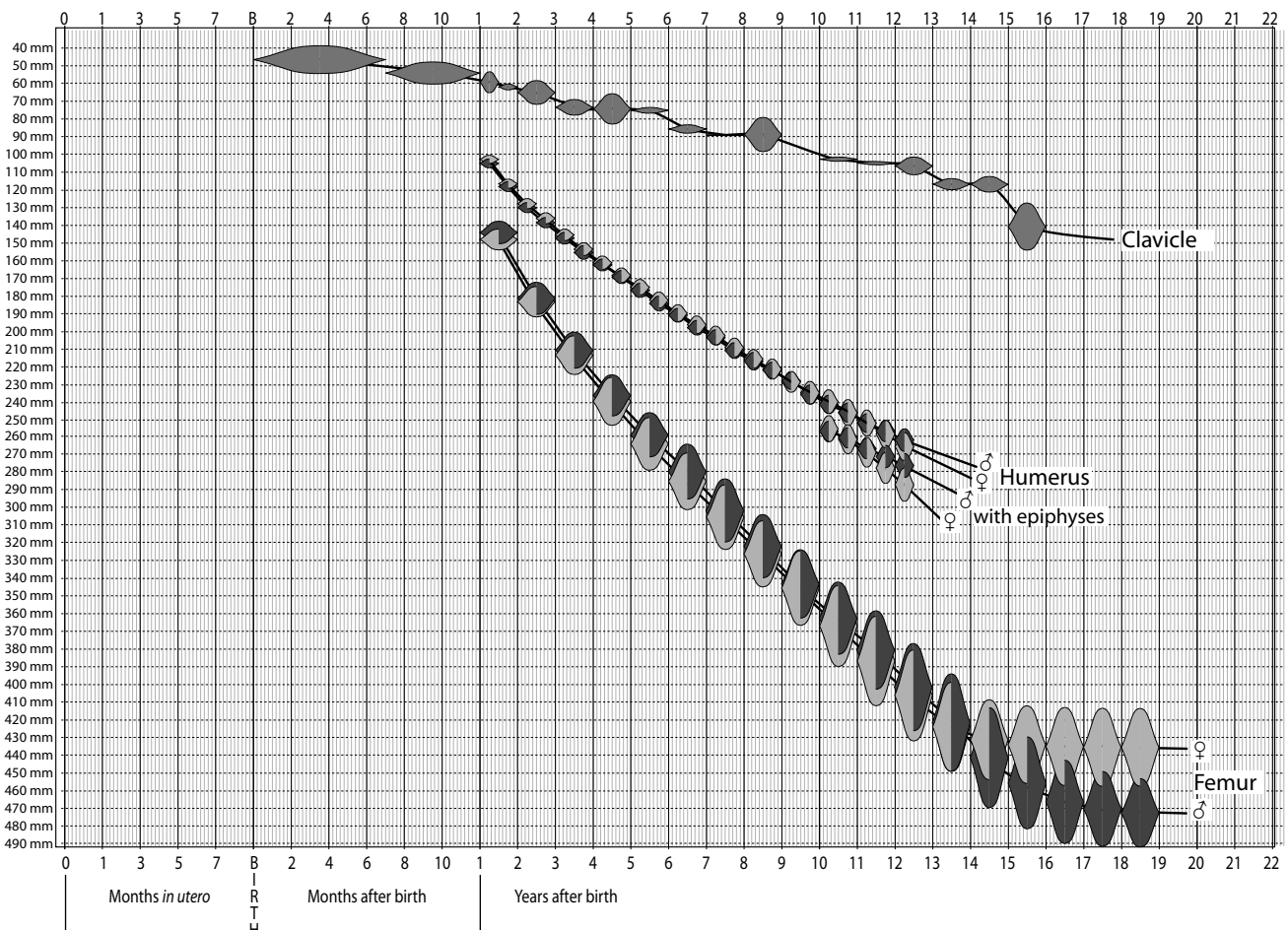


Figure 18.9 Examples of age estimates that can be obtained by measuring long bone lengths. The width of each spindle represents the age range over which data were gathered (e.g., an age of 18 is interpreted as the year beginning on an individual's 18th birthday). Each spindle is vertically centered on the mean length for that age range, and the height of each spindle represents the ± 1 SD range. Key: dark gray: males; light gray: females; medium gray: combined sexes. For explanation of the nonlinear scale used here, see the caption to Figure 18.1. Clavicular data are based on Scheuer and Black (2000:252), humeral data are based on Scheuer and Black (2000:289, citing Maresh, 1970), and femoral data are based on Scheuer and Black (2000:395, citing Anderson et al., 1964).

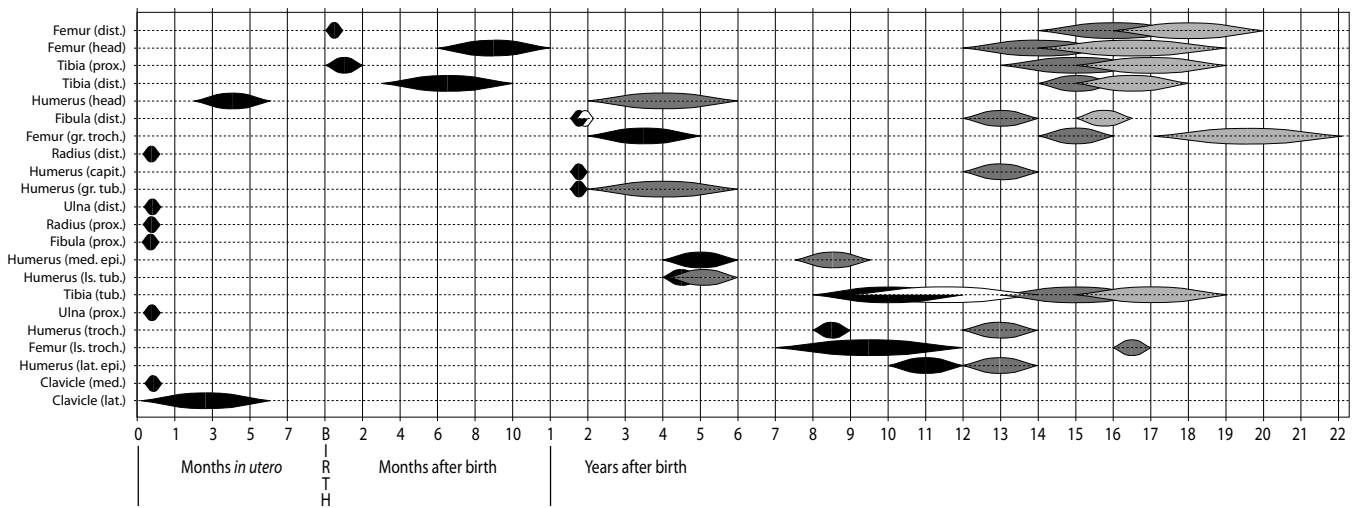


Figure 18.10 Variation in the times of appearance and fusion of secondary ossification centers for the major long bones. Key: black: appearance of secondary center of ossification (in both sexes or, if paired with a white marker, in females); white: appearance of secondary center of ossification in males; dark gray: fusion of the secondary center of ossification (in both sexes or, if paired with a light gray marker, in females); dark gray: fusion of the secondary center of ossification in males. For explanation of the nonlinear scale used here, see the caption to Figure 18.1. Data are derived from Scheuer and Black (2000).

18.3.6 Estimating Adult Age from the Pubic Symphyseal Surface

One of the most widely used indicators of age-at-death has been metamorphosis of the symphyseal surface of the pubis of the os coxae. Age-related changes on this surface continue after full adult stature has been achieved and other epiphyses of the limbs have fused. Pubic symphyses of other primates metamorphose more quickly than human ones and usually synostose with advancing age. In humans, however, changes of the symphyseal surfaces allow them to be used in generating osteologically determined age-at-death estimates. The young adult human pubic symphysis has a rugged surface traversed by horizontal ridges and intervening grooves. This surface loses relief with age and is bounded by a rim by age 35. Subsequent erosion and general deterioration of the surface are progressive changes after this age. Figure 18.12 illustrates these changes.

Age-related changes at the pubic symphysis have been recognized for many years, and the first formal system for using these changes to determine age was developed by Todd (1920), based on a series of 306 males of known age-at-death. Todd identified four basic parts to the pubic symphysis, a surface with an irregular oval shape: (a) the ventral border (rampart), (b) the dorsal border (rampart), (c) the superior extremity, and (d) the inferior extremity. Todd noted evidence of billowing, ridging, ossific nodules, and texture on each part of the symphyseal surface. Using these observations on his sample of known ages, Todd recognized ten phases of pubic symphysis age, ranging from 18/19 years to 50+ years, and noted that these phases were more reliable age indicators between 20 and 40 years than after 40 years. He perceived three major stages in symphysis metamorphosis. His phases I–III comprised the “postadolescent” stage, phases IV–VI were the buildup stage, and phases VII–X represented the degenerative stage. Figure 18.12 illustrates Todd’s original standards; subsequent work on age-based changes in this anatomical region is based on this foundation.

Few tests of this method were made, although the method gained wide acceptance. Brooks (1955) found a tendency of the Todd system to overage, especially in the third and fourth decades. In 1957, McKern and Stewart used skeletal remains of 349 male Korean War dead in an effort to

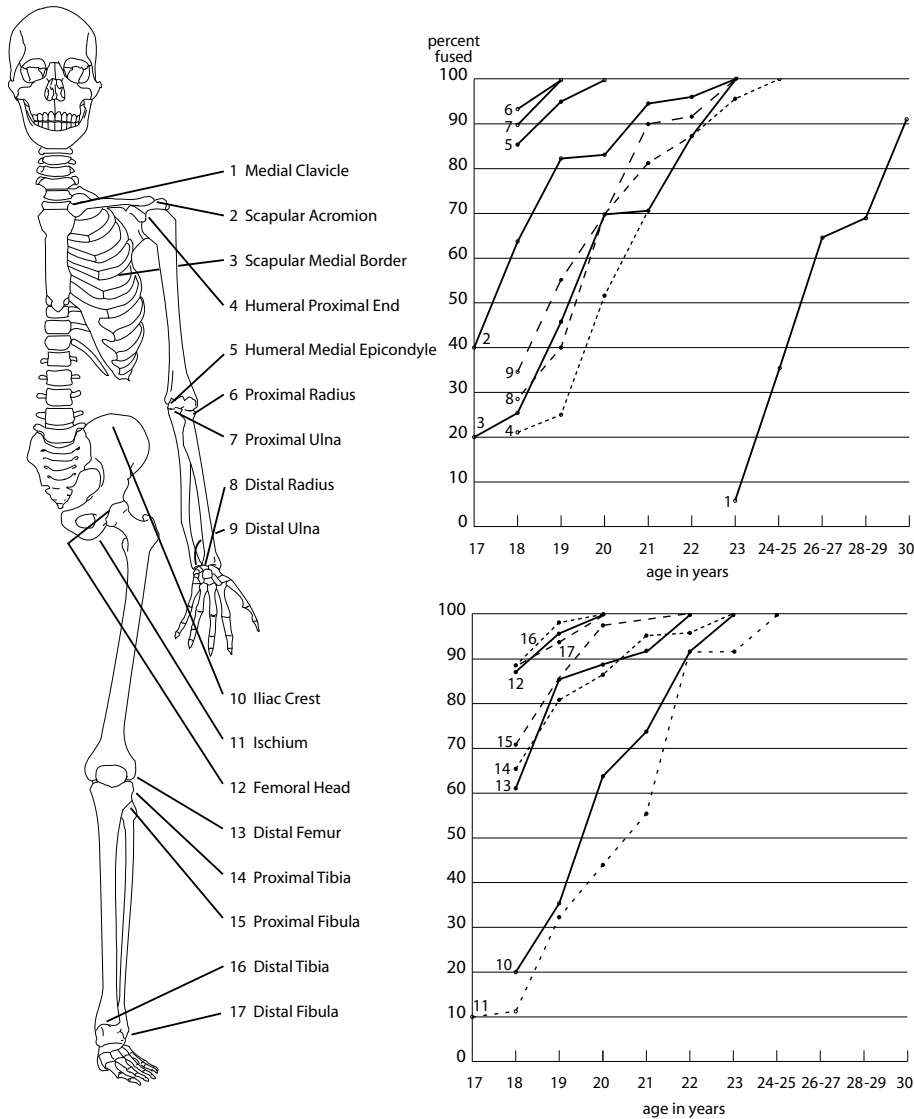


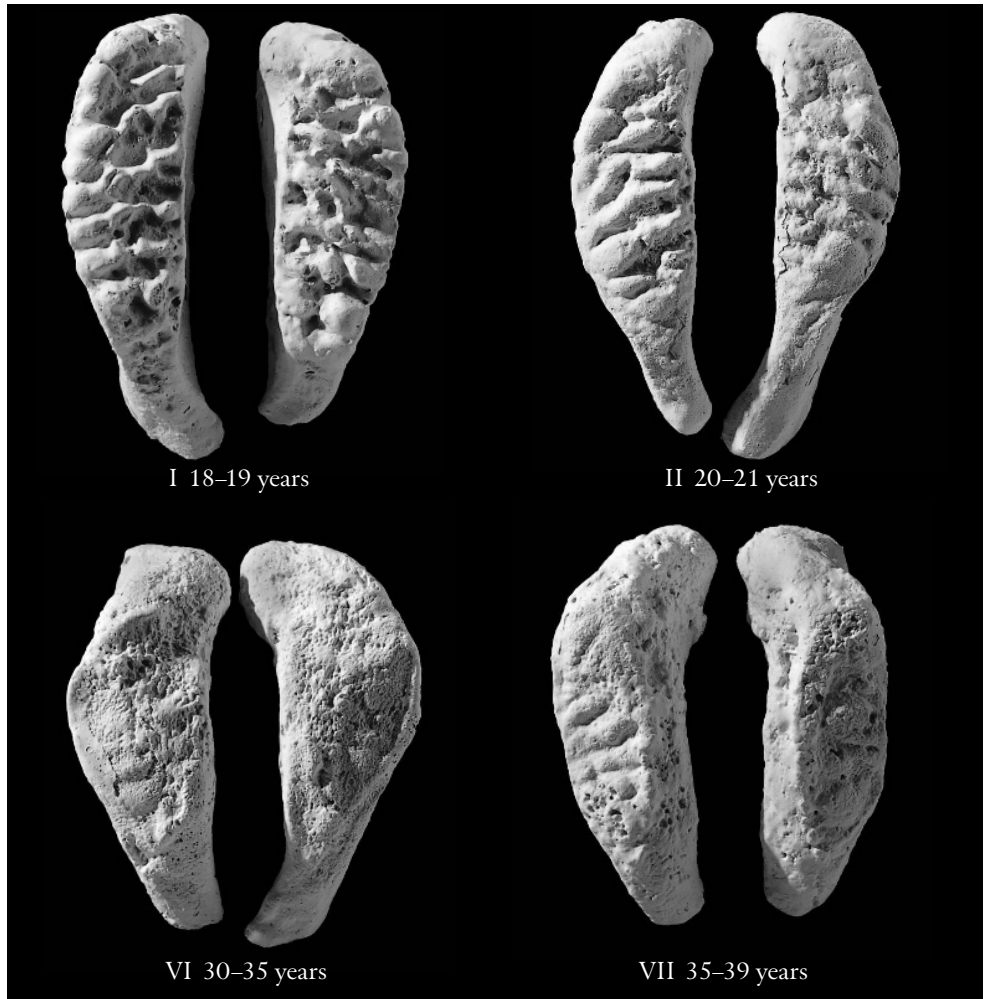
Figure 18.11 Ages of fusion for various male skeletal elements. Data on fusion from McKern and Stewart (1957). These standards, derived from U.S. military personnel who died in the Korean War, show considerable variation in fusion for any given element. For example, in the medial clavicle, McKern and Stewart (1957) found that of 10 individuals aged 17 years, none had fused epiphyses. For the clavicle, the epiphyseal cap begins to unite to the medial end of the clavicle as early as 18 years but can begin to unite at any time between 18 and 25 years. The earliest complete fusion came among some soldiers who died at 23 years, but the study showed that others lived to age 31 before fusion was complete. To use this table, choose a numbered epiphysis from above or below the waist and find its graph to the right of the skeleton. The graph shows what percentage of adult male individuals showed full fusion of each epiphysis at any given age.

refine the Todd method. Their approach was to divide the symphyseal surface longitudinally into two halves, or “components”—the “dorsal demiface” and the “ventral demiface.” The third component of the symphysis was the “symphyseal rim.” Five developmental stages were recognized for each of the three components. In using this system, the osteologist calculates a developmental stage for each component, adds these together, and derives an age of death for the specimen. This system, like that of Todd, was derived from an all-male sample of limited age range.

Gilbert and McKern (1973) used a sample of 103 females of known age to generate a component system for aging female specimens by the pubis. Because female pubic symphyses are subject to trauma during childbearing, there is a potential for premature changes in the bone surface, which could lead to overaging. In 1979, Suchey tested the Gilbert and McKern method for aging the female pubic symphysis by asking 23 professional osteologists to age pubic faces of unrevealed age. Results showed the system to be highly unreliable and prone to inaccurate estimates.

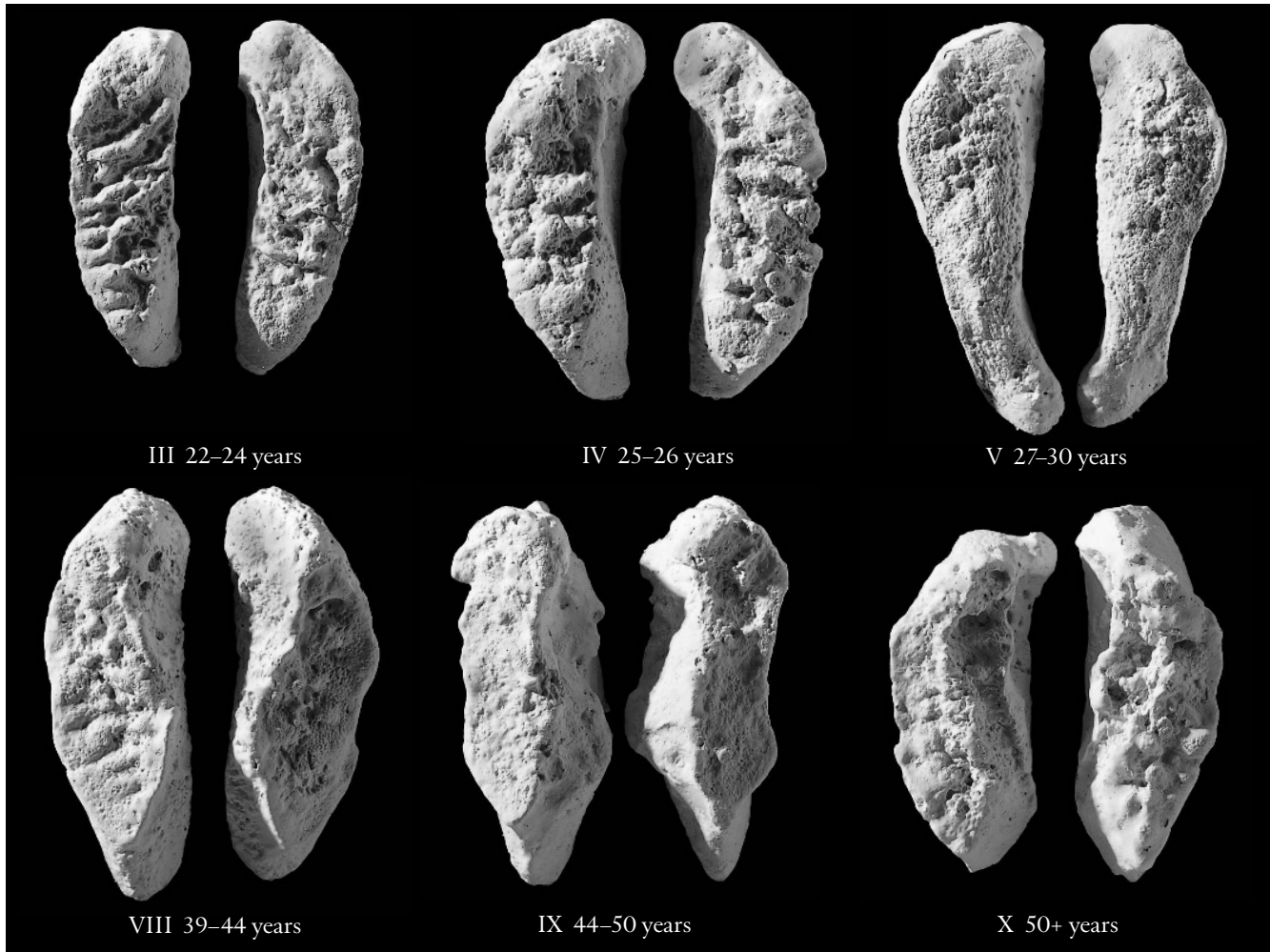
Meindl and colleagues (1985a) tested the accuracy of all these methods in a study of the Hamann-Todd collection. They found that the original Todd method was more reliable than the

Figure 18.12 The Todd system. Todd's (1920) ten age phases of pubic symphysis modification in adult white males. Todd's standard specimens are shown here, natural size. The anterosuperior ends of the pubic symphyses are toward the top of the page, and the ventral margins of each symphysis pair are opposed. In the original Todd study, phases were defined according to topography on the symphyseal surface and the nature of the margins of this surface. Note the wider age ranges for the higher stages. For more details on application of the Todd technique, consult the original 1920 publication. Many newer standards have been published since this first attempt to use changes in the topography of the pubic symphysis to age the skeleton, all relying on the bony changes that correlate with age.



more recent component techniques and that all systems tended to underage. They recognize five major biological phases for the pubic symphysis and provide careful illustrative documentation of their results. They also provide a much-needed biological perspective on the metamorphosis of the pubic symphysis and assess this part of the anatomy from a comparative evolutionary background (see also Lovejoy et al., 1995, 1997).

Suchey et al. (1986) and Katz and Suchey (1986), working on the large Los Angeles County Coroner multiracial sample, examined 739 male individuals between the ages of 14 and 92. These investigators contend that age-at-death data for their skeletal individuals are more accurate and precise than those used to build the Todd, McKern-Stewart, and Meindl et al. standards. The Todd and McKern-Stewart methods were tested on the Los Angeles sample and interobserver error was assessed. As a result, modifications of the earlier techniques of pubic symphysis age estimation were suggested. Katz and Suchey (1986) suggest that Todd's methodology is excellent, but that the collection he used was inadequate. They recommend the use of a modified Todd approach with six phases defined on the entire symphyseal face. Their data clearly show a large amount of variation in ages for any one phase, particularly for older individuals. For example, their Phase V shows a mean age of 51 years, but only 95% of the sample of 241 male pubic symphyses that matched this phase was within the wide age limits of 28 to 78 years.

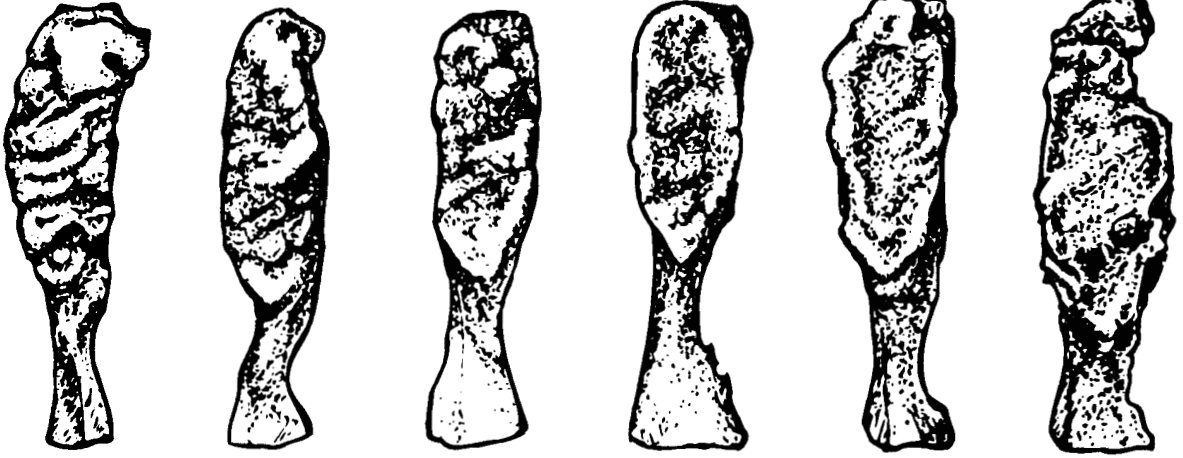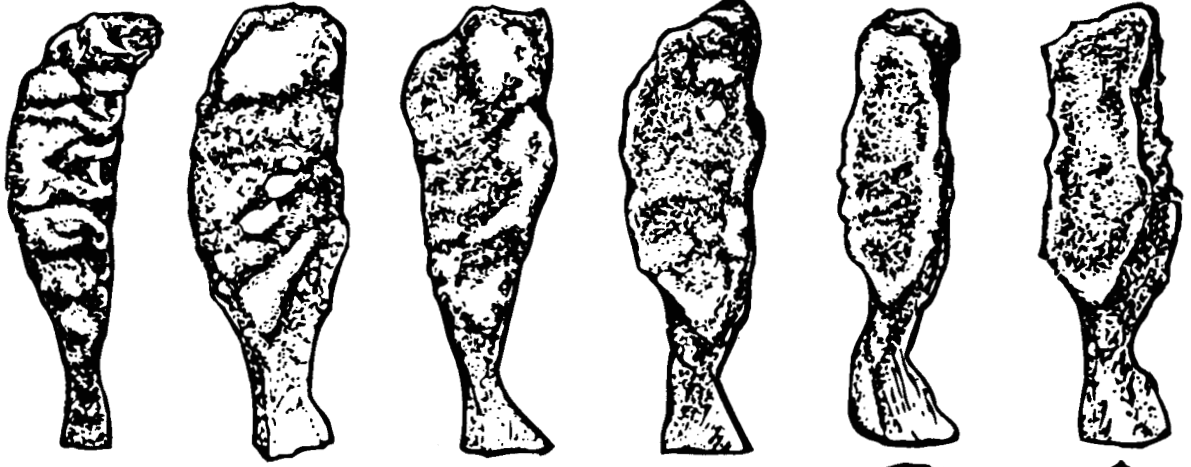


An assessment of “race” differences among 704 of the male pubic bones was undertaken by Katz and Suchey (1989). Following implementation of the six-phase Suchey-Brooks system for male individuals, 273 female pubic bones were studied, and a system analogous to the male system was devised. Refined descriptions of the Suchey-Brooks method are found in Brooks and Suchey (1990) and in Figure 18.13. In a test of this and other pubic symphysis aging methods, Klepinger et al. (1992) concluded “... all the aging methods based on the os pubis proved disappointing in regard to both accuracy and precision.” They recommend that the “racial” refinement of the Suchey-Brooks system be used, that any independent evidence of trauma or debilitation be considered, and that all estimated ages be reported within a standard deviation interval of plus or minus two years.

18.3.7 Parturition Changes at the Pubic Symphysis

Childbirth, or **parturition**, may result in changes on the pubic symphysis (particularly pitting adjacent to the symphysis on the dorsal edge of the pubis), auricular surface, and preauricular area of the female os coxae. To what extent can the osteologist use these changes to assess whether, or

Female



1

2

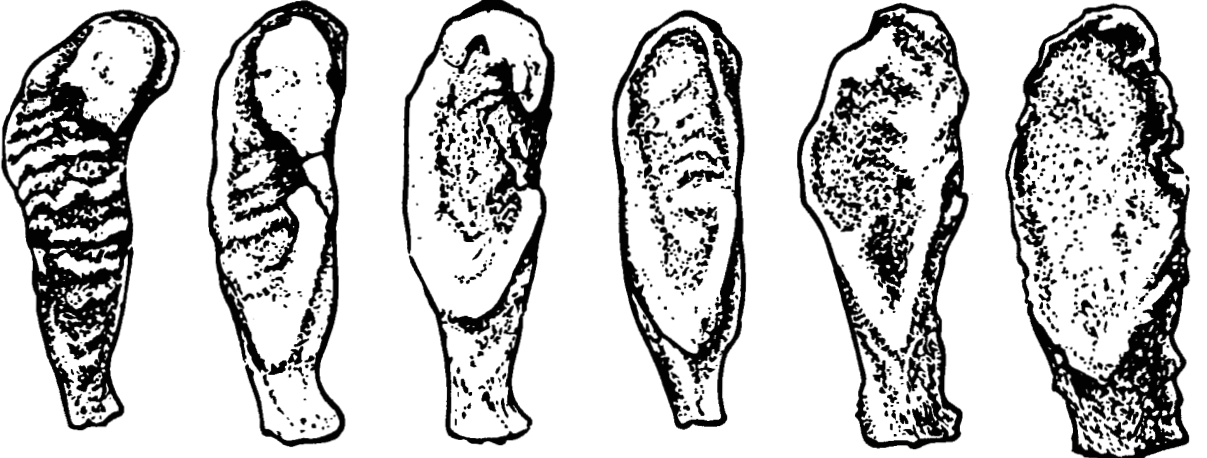
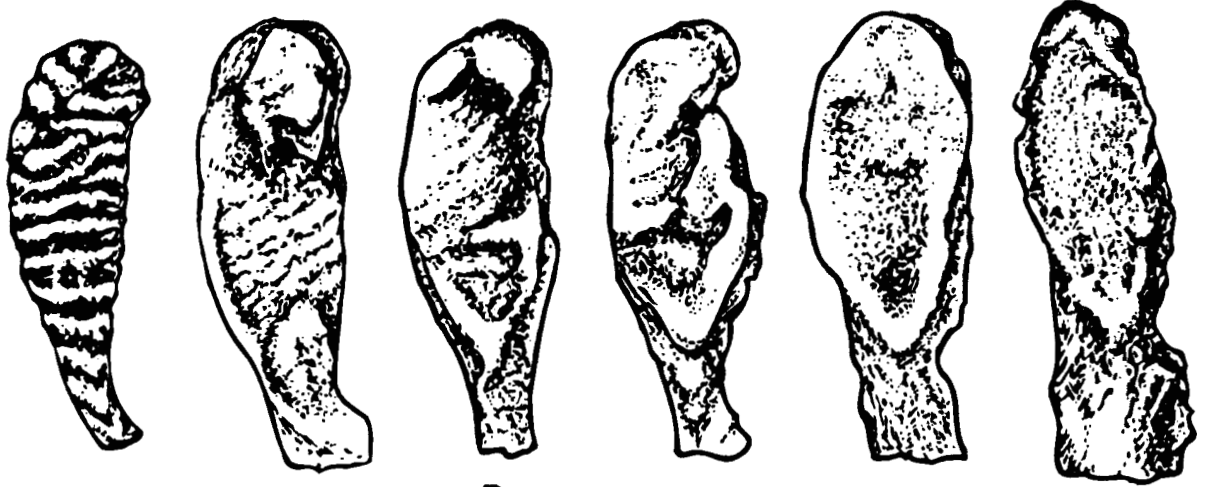
3

4

5

6

Male



how often, an individual has given birth? Studies designed to answer these questions include Kelley (1979) and Suchey et al. (1979). These studies show that up to 20% of nulliparous women display these or related features. Dorsal pitting acquired during pregnancy and childbirth may become obliterated with age. Medium-to-large dorsal pitting can occur without parturition (17 of 148 cases, Suchey et al., 1979), and parturition can occur without dorsal pitting. Four of over 700 male individuals displayed medium-to-large dorsal pitting. In short, there is a correlation between dorsal pitting of the pubis and pregnancy or parturition, but this correlation is far from perfect. The number of pregnancies cannot be predicted by the morphology of the dorsal aspect of the pubis. In a study combining humans and nonhuman mammals, Tague (1988) concludes that the severity of the resorption at the pubis is not significantly related to that of the preauricular area. Furthermore, age-at-death was shown to be significantly associated with resorption of the pubis. Cox and Scott (1992) note that pubic tubercle extension is also associated with childbirth, whereas preauricular sulci and dorsal pitting were not. Tague (1988) calls for further study of the link between estrogen and osteoclastic activity in these areas of the os coxae. Cox (2000b) provides an overview of skeletal studies of parturition, and Snodgrass and Galloway (2003) provide further critical assessment regarding forensic use of dorsal pitting.

Figure 18.13 The Suchey-Brooks pubic symphysis scoring system. The phase descriptions given here may be applied to either male or female symphysis faces, but matches of females should only be made in reference to the female phase types in the upper two rows. Phase descriptions are from Brooks and Suchey (1990, italics therein), and statistics for the Suchey-Brooks phases in females and males follow the descriptions; drawings are adapted by P. Walker in Buikstra and Ubelaker's Standards volume (1994) from drawings by Deborah Gray. It is recommended that these illustrations be supplemented by casts before actual aging is attempted.

Phase 1: Symphyseal face has a billowing surface (ridges and furrows), which usually extends to include the pubic tubercle. The horizontal ridges are well-marked, and ventral beveling may be commencing. Although ossific nodules may occur on the upper extremity, *a key to the recognition of this phase is the lack of delimitation of either extremity (upper or lower).*

Phase 2: The symphyseal face may still show ridge development. *The face has commencing delimitation of lower and/or upper extremities occurring with or without ossific nodules.* The ventral rampart may be in beginning phases as an extension of the bony activity at either or both extremities.

Phase 3: Symphyseal face shows lower extremity and *ventral rampart in process of completion.* There can be a continuation of fusing ossific nodules forming the upper extremity and along the ventral border. Symphyseal face is smooth or can continue to show distinct ridges. Dorsal plateau is complete. Absence of lipping of symphyseal dorsal margin; no bony ligamentous outgrowths.

Phase 4: Symphyseal face is generally fine grained although remnants of the old ridge and furrow system may still remain. *Usually the oval outline is complete at this stage, but a hiatus can occur in upper ventral rim.* Pubic tubercle is fully separated from the symphyseal face by definition of upper extremity. The symphyseal face may have a distinct rim. Ventrally, bony ligamentous outgrowths may occur on inferior portion of pubic bone adjacent to symphyseal face. If any lipping occurs, it will be slight and located on the dorsal border.

Phase 5: *Symphyseal face is completely rimmed with some slight depression of the face itself, relative to the rim.* Moderate lipping is usually found on the dorsal border with more prominent ligamentous outgrowths on the ventral border. There is little or no rim erosion. Breakdown may occur on superior ventral border.

Phase 6: *Symphyseal face may show ongoing depression as rim erodes.* Ventral ligamentous attachments are marked. In many individuals the pubic tubercle appears as a separate bony knob. The face may be pitted or porous, giving an appearance of disfigurement with the ongoing process of erratic ossification. Crenulations may occur. The shape of the face is often irregular at this stage.

Phase	Descriptive Statistics:					
	Female (n = 273)			Male (n = 739)		
	Mean	Standard Dev.	95% range	Mean	Standard Dev.	95% range
1	19.4	2.6	15–24	18.5	2.1	15–23
2	25.0	4.9	19–40	23.4	3.6	19–34
3	30.7	8.1	21–53	28.7	6.5	21–46
4	38.2	10.9	26–70	35.2	9.4	23–57
5	48.1	14.6	25–83	45.6	10.4	27–66
6	60.0	12.4	42–87	61.2	12.2	34–86

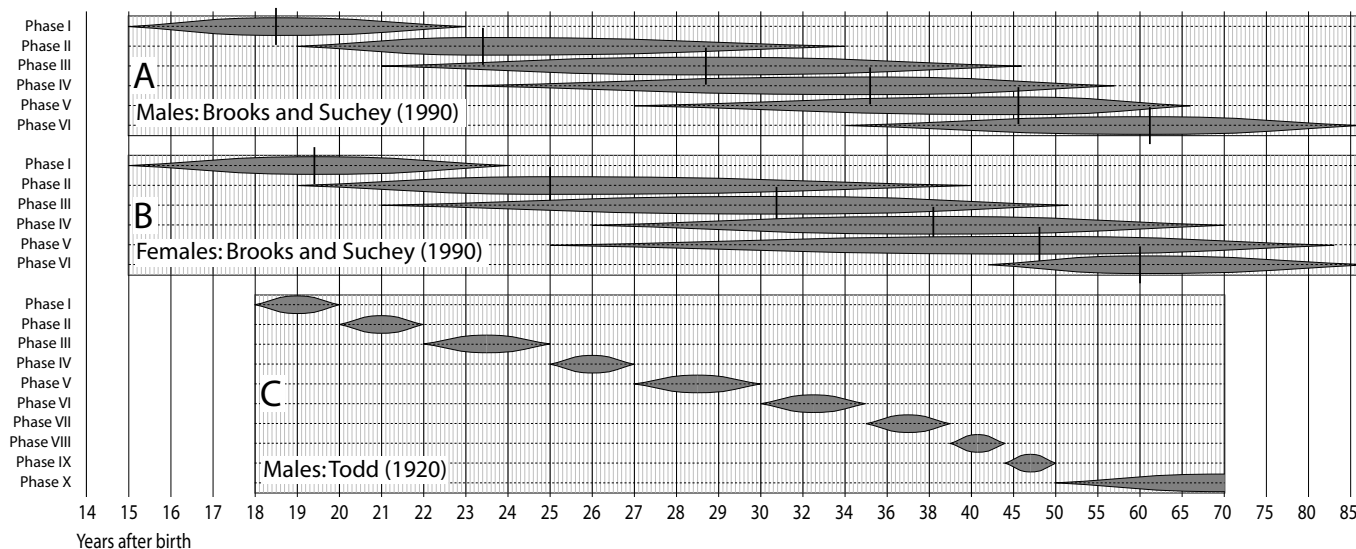


Figure 18.14 Estimates of age that can be obtained through analysis of pubic symphyseal morphology. A) Pubic symphyseal phases of males plotted against implied ages, according to the Suchey-Brooks system; B) symphyseal phases of females plotted against implied ages, according to the Suchey-Brooks system; C) symphyseal phases of males plotted against implied ages, according to the Todd system. The short black vertical lines represent mean ages for each phase (not available for C), and the gray spindles illustrate the 95% range (or, in the case of C, the published range). For explanation of the nonlinear scale used here, see the caption to Figure 18.1. Data for A and B are derived from Brooks and Suchey (1990), and data for C are derived from Todd (1920).

18.3.8 Estimating Adult Age from the Auricular Surface of the Ilium

The auricular surface of the ilium has been shown to be a reliable indicator of age in older individuals, regardless of sex or ancestry. Although it had been recognized since 1930 (Sachin, 1930) that the auricular surface changes with age, its use in predicting age at death went unexploited until 1985. In that year, Lovejoy and colleagues (1985b) published their observations on age-related changes to the auricular surface in the Hamann-Todd collection, along with a method for scoring the changes in order to place an individual in one of eight phases (Figure 18.15).

The use of the iliac auricular surface for aging individual specimens has some advantages, namely that this part of the os coxae is more likely than the pubic symphysis to be preserved in forensic and archaeological cases and that the changes on the auricular surface, unlike those on the pubic symphysis, extend well beyond the age of 50 years. Lovejoy and colleagues describe age-related changes in surface granulation, microporosity, macroporosity, transverse organization, billowing, and striations that are somewhat similar to those described for the surface of the pubic symphysis. These investigators note that auricular surface aging is more difficult to master than

Figure 18.15 (Opposite) Modal changes to the auricular surface with age. Phases described by Lovejoy et al. (1985b) as follows:

Phase 1: Age 20–24; billowing and very fine granularity

Phase 2: Age 25–29; reduction of billowing but retention of youthful appearance

Phase 3: Age 30–34; general loss of billowing, replacement by striae, coarsening of granularity



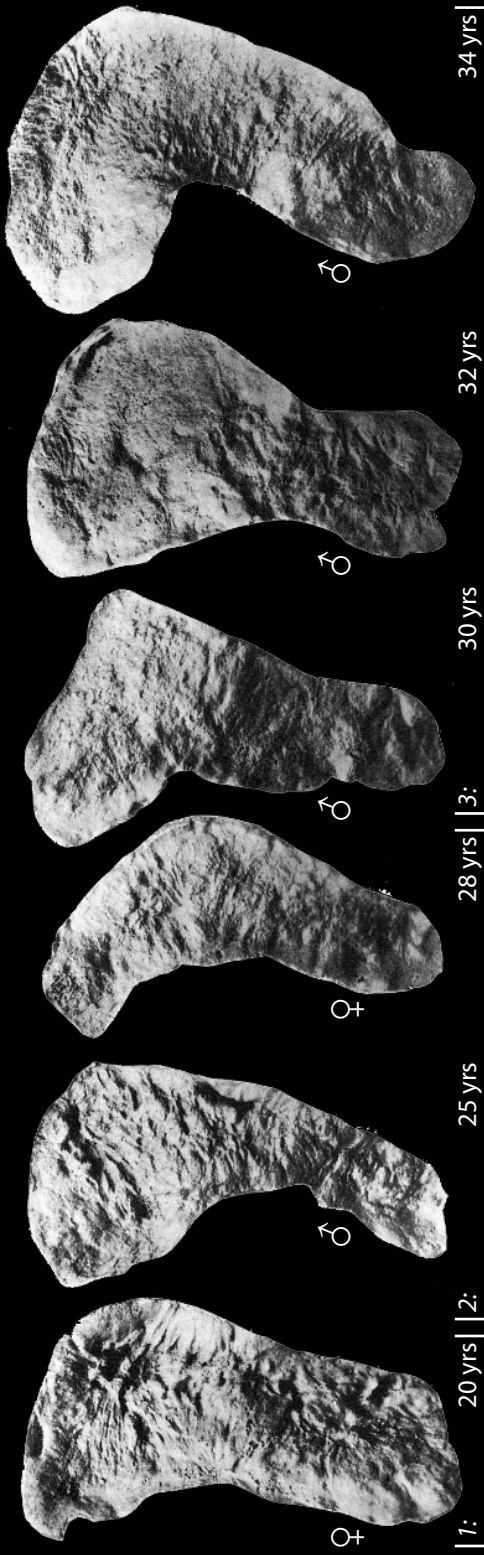
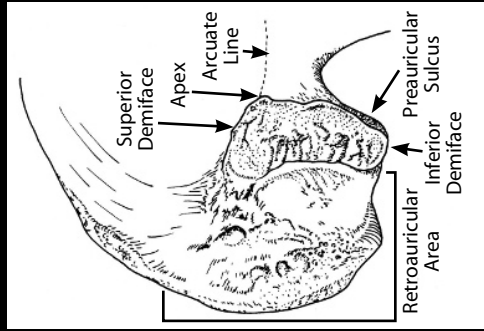
Phase 4: Age 35–39; uniform coarse granularity

Phase 5: Age 40–44; transition from coarse granularity to dense surface; this may take place over islands on the surface of one or both faces

Phase 6: Age 45–49; completion of densification with complete loss of granularity

Phase 7: Age 50–59; dense irregular surface of rugged topography and moderate to marked activity in periauricular areas

Phase 8: Age 60+; breakdown with marginal lipping, microporosity, increased irregularity, and marked activity in periauricular areas



the Todd method for the pubic symphysis, but they state that the potential rewards are worth the extra effort, since the method is independent of symphyseal aging but equally accurate.

The changes described by Lovejoy et al. (1985b) for the auricular surface are as follows. The young auricular surface (Figure 18.15), beginning in the first few years after postcranial epiphyseal fusion, shows a fine-grained surface texture and a pattern of regular, usually transverse surface undulations called billowing. The topography of the surface is very much like the subchondral bone of an unfused epiphysis, although the billowing is not so pronounced. Beginning in adulthood, these features of the sacroiliac joint are modified progressively and regularly as age increases. Granularity of the surface becomes coarser, billowing and striae are reduced dramatically, the original transverse organization of youth is lost, and the surface begins to display perforations of its subchondral bone, a condition known as “microporosity.” In the later stages of life, the surface becomes increasingly dense and disorganized. Larger subchondral defects termed macroporosity progressively increase with age after the fifth decade. By the sixth and seventh decades, the surface has become dense, both microporotic and macroporotic, and has lost all evidence of transverse organization. Lovejoy and colleagues formalized a system of eight phases with which to classify this metamorphosis (Figure 18.15).

Buckberry and Chamberlain (2002) sought to revise the Lovejoy et al., method in order to make it easier to understand and adopt and, thus, to reduce the degree of inter- and intraobserver error that had been noted for this method (Saunders et al., 1992). Using the same features and terminology that Lovejoy et al. (1985a) established, Buckberry and Chamberlain devised a frame-

Table 18.3 Auricular age estimates. Scoring of iliac auricular characteristics according to the revisions of Buckberry and Chamberlain (2002)

Characteristic	Score	Description
Transverse organization	1	90% or more of surface is transversely organized
	2	50–89% of surface is transversely organized
	3	25–49% of surface is transversely organized
	4	Transverse organization is present on less than 25% of surface
	5	No transverse organization is present
Surface texture	1	90% or more of surface is <i>finely granular</i>
	2	50–89% of surface is <i>finely granular</i> ; replacement of finely granular bone by coarsely granular bone in some areas; no dense bone is present
	3	50% or more of surface is <i>coarsely granular</i> , but no dense bone is present
	4	<i>Dense bone</i> is present, but occupies less than 50% of surface; this may be just one small nodule of dense bone in very early stages
	5	50% or more of surface is occupied by <i>dense bone</i>
Microporosity	1	No microporosity is present
	2	Microporosity is present on one demiface only
	3	Microporosity is present on both demifaces
Macroporosity	1	No macroporosity is present
	2	Macroporosity is present on one demiface only
	3	Macroporosity is present on both demifaces
Apical changes	1	Apex is sharp and distinct; auricular surface may be slightly raised relative to adjacent bone surface
	2	Some lipping is present at apex, but shape of articular margin is still distinct and smooth (shape of outline of surface at apex is a continuous arc)
	3	Irregularity occurs in contours of articular surface; shape of apex is no longer a smooth arc

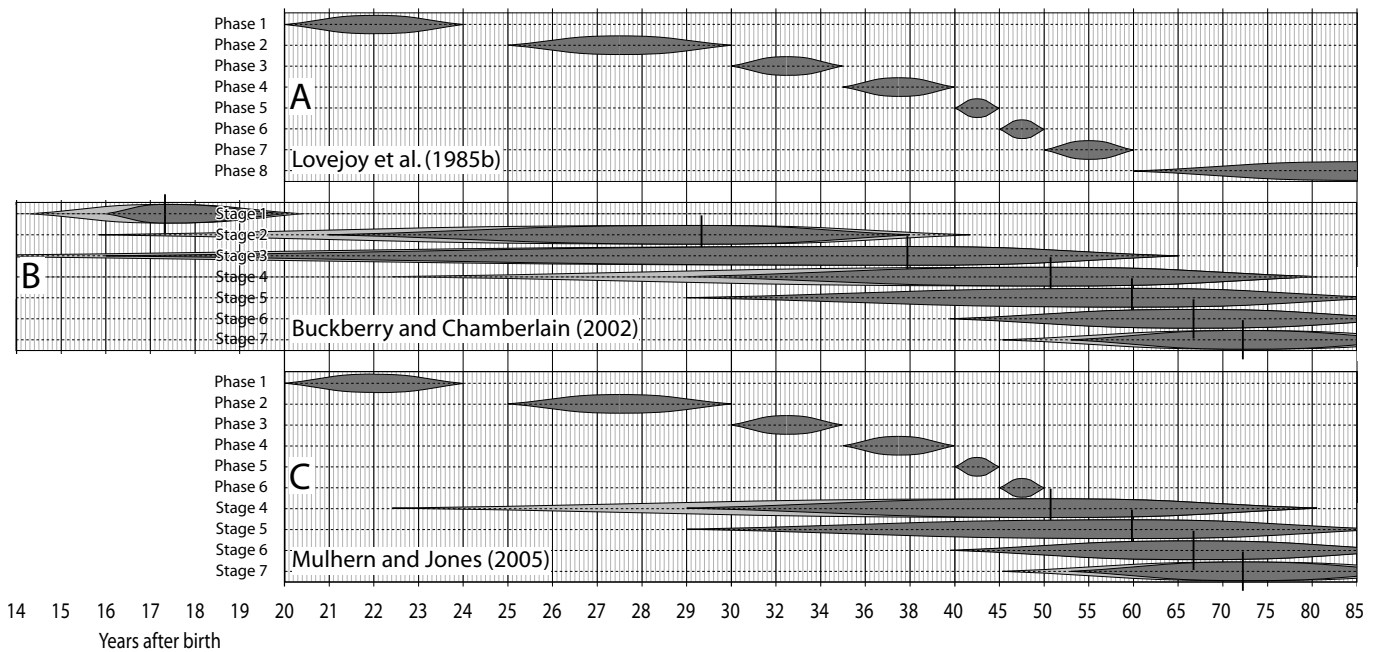


Figure 18.16 Estimates of age that can be obtained through analysis of iliac auricular surface morphology. **A)** Age estimates according to Lovejoy et al. (1985b); **B)** Age estimates according to Buckberry and Chamberlain (2002); **C)** Most accurate combination of these methods according to Mulhern and Jones (2005). The short black vertical lines represent mean ages for each phase, the darker gray spindles illustrate the stated ranges, and the lighter gray spindles represent ± 2 SD ($\cong 95\%$ range). For explanation of the nonlinear scale used here, see the caption to Figure 18.1. Data for A are derived from Lovejoy et al. (1985b), data for B are derived from Buckberry and Chamberlain (2002), and data for C are derived from Mulhern and Jones (2005).

Table 18.4 Age estimates derived from the composite scores of auricular characteristics.
(after Buckberry and Chamberlain, 2002)

Composite score	Stage	Mean age and standard deviation	Median age	Age range
5 or 6	1	17.33 \pm 1.53 years	17 years	16–19 years
7 or 8	2	29.33 \pm 6.71 years	27 years	21–38 years
9 or 10	3	37.86 \pm 13.08 years	37 years	16–65 years
11 or 12	4	51.41 \pm 14.47 years	52 years	29–81 years
13 or 14	5	59.94 \pm 12.95 years	62 years	29–88 years
15 or 16	6	66.71 \pm 11.88 years	66 years	39–91 years
17, 18, or 19	7	72.25 \pm 12.73 years	73 years	53–92 years

work in which each of five characteristics of the iliac auricular surface (transverse organization, surface texture, degree of microporosity, degree of macroporosity, and apical changes) are evaluated independently and given ordinal scores (Table 18.3).

Both the original method of Lovejoy et al. (1985a) and the revised method of Buckberry and Chamberlain (2002) were tested against a subset (309 individuals) of the Terry and Huntington collections at the Smithsonian Institution's National Museum of Natural History (Mulhern and Jones, 2005). Mulhern and Jones agreed with Buckberry and Chamberlain's assertions that the revised method was easier to apply and that the method appeared to be sex- and ancestry-agnostic. They found that the two methods (original and revised) had their own strengths and weaknesses and recommended that they be used only under certain conditions. The original method was found to be more accurate for individuals aged 20–49, but the revised method was found to be more accurate for individuals aged 50–69. Because the accuracy of estimates is reduced for individuals over 60 years, Mulhern and Jones recommended against using auricular surface morphology as the sole indicator of age in older adults.

18.3.9 Estimating Adult Age from the Sternal Rib End

Perhaps no other method of age determination varies so much in terms of the respect it is accorded, the accuracy it is ascribed, and the specific criteria by which it is employed as the method first announced by İşcan, Loth, and Wright (1984a, 1984b, 1985, 1986). İşcan et al. described three components of age-related change at the sternal end of the fourth rib: pit depth, pit shape, and rim and wall configuration. Six numbered stages (0–5) were described for each of these components. İşcan et al. (1984b) claimed that the method was accurate “within about 2 years in the second decade to about 7 years in the fifth and sixth decades of life.”

As it stands now, this potentially important age determination method suffers from a number of problems. The method depends on both the preservation and positive identification of the fourth rib, a situation that is difficult and/or uncertain in many archaeological contexts. Work has since been undertaken on ways to identify the rib number of isolated ribs (e.g., Dudar, 1993; Mann, 1993; Hoppa and Saunders, 1998; Atkas et al., 2004; Owers and Pastor, 2006), as well as assessing how well the method works on other ribs (Loth et al., 1994; Yoder et al., 2001). Other

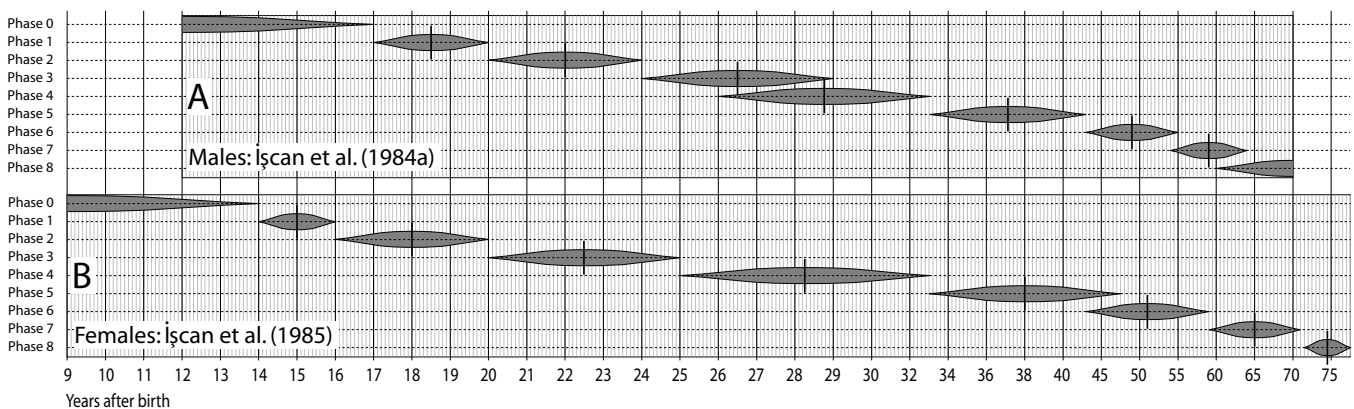


Figure 18.17 Estimates of age that can be obtained through analysis of the morphology of the sternal end of the right fourth rib. A) Phase-to-age relationships for males; B) phase-to-age relationships for females. The short black vertical lines represent mean ages for each phase, and the gray spindles illustrate the published range. For explanation of the nonlinear scale used here, see the caption to Figure 18.1. Data for A are derived from İşcan et al. (1984a), and data for B are derived from İşcan et al. (1985).

researchers have examined the more robust and uniquely identifiable first rib as a potentially better focus for aging work (Kunos et al., 1999; DiGangi et al., 2009)

The criteria used for the method are insufficiently well-defined to allow consistent application between examiners (Fanton et al., 2010), resulting in poor marks for reproducibility and repeatability, and relying heavily on the experience level of the examiner (Saunders et al., 1992). Some advocate revising the original criteria to make them clearer and more accessible to nonexperts (eg, Fanton et al., 2010), while others suggest that the criteria need to be more or less completely replaced (eg, Russell et al., 1993; Hartnett, 2010; Verlezetti et al., 2010).

In addition, the sternal rib method requires the use of separate standards for both race and sex, making application impossible unless both sex and ancestry are known. Furthermore, the applicability of the method is uncertain for individuals of non-“white” and non-“black” ancestry.

While there is much work still to be done before this technique will be of use to beginning osteologists, there is near-unanimous agreement that there is important information about age at death that is conveyed by the morphology of the sternal end of the fourth rib.

18.3.10 Estimating Adult Age by Radiographic Analysis

Changes in cancellous and cortical bone structure at macroscopic and microscopic levels take place throughout life. Walker and Lovejoy (1985) have studied this phenomenon by assessing radiographs from the Hamann-Todd collection and the prehistoric Libben collection. Using seriation, these authors describe progressive, site-specific loss of bone with age in both the clavicle and the femur. Visual seriation of radiographs showed a moderately high and significant correlation between increased age of death and decreased bone density. Macchiarelli and Bondioli (1994) show significant variation in density of the proximal femur, much of it unrelated to age. Jackes (1992) discusses problems with applications to archaeological remains.

18.3.11 Estimating Adult Age from Bone Microstructure

The normal remodeling of bone during adult life has been proposed as a condition useful for aging skeletal material. Microscopic analysis has allowed the relationships between the number of osteons and osteon fragments and the percentages of lamellar bone and non-Haversian canals to be examined. Simmons (1985), Frost (1987), and Robling and Stout (2008) provide excellent summaries of these procedures. It should be noted that these procedures are destructive to the bones under study. Many studies of histomorphometry have been undertaken on the long bones of the postcranial skeleton (for a review, see Stout, 1992). Cool et al. (1995) have shown that

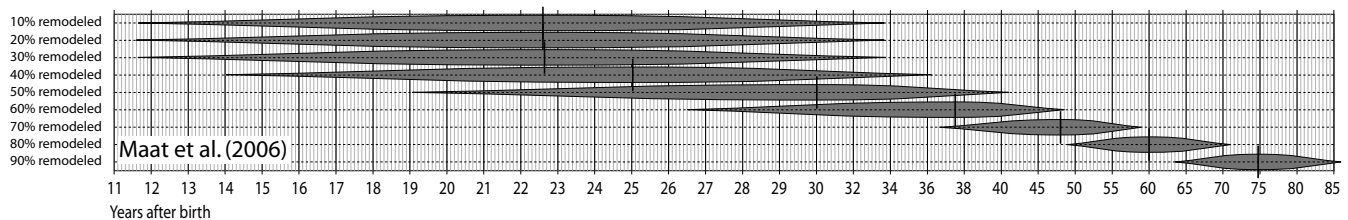


Figure 18.18 Estimates of age that can be obtained through analysis of bone microstructure. The degree to which older lamellar bone has been replaced by newer lamellar bone is determined by counting the number of intact and fragmentary osteons in a given area of bone. The short black vertical lines represent mean ages for each phase, and the gray spindles illustrate the ± 1 SD range. For explanation of the nonlinear scale used here, see the caption to Figure 18.1. Data are derived from regression equation (for mixed sex sample) from Maat et al. (2006: 233).

histomorphological variables of the human occipital were less reliable than those of the long bones for estimating age.

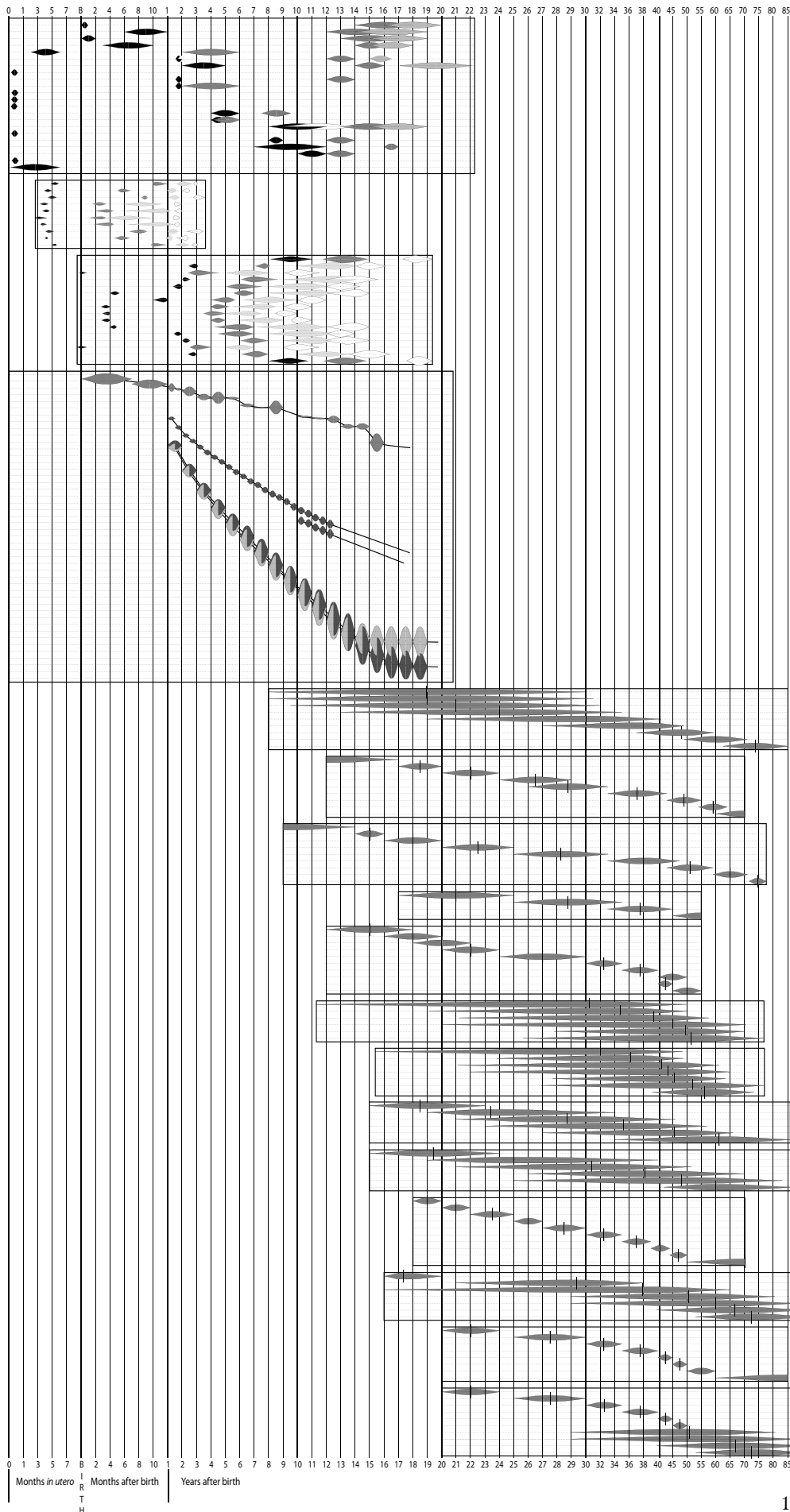
All of these methods are quantitative and depend on osteonal remodeling of bone and accumulated osteon populations. Many factors can influence this process and its products, including sex, hormones, mechanical strain, and nutrition. Remodeling is the sequential removal and replacement of older lamellar bone with newer lamellar bone. It takes place throughout the life span. Histological analysis of tissue from selected sites on the skeleton (including the ribs and clavicle: Stout and Paine, 1992; Stout et al., 1994, 1996) has shown an association between age-at-death and the number of observable osteons per unit area in a cross-section. The number of intact and fragmentary osteons per unit area is calculated for each bone (normally for at least two slices of each bone), and the result is put into regression equations that calculate the age. Stout (1992) identifies a variety of problems with the technique as applied by different investigators, and calls for more research in the forensic setting. Pfeiffer et al. (1995) and others have found that histological profiles vary by sample location, something that must be controlled for in application of these techniques. As Ericksen (1991) notes, it is critical that osteologists using bone microstructure to age archaeological specimens be very cautious about pre-analysis exfoliation of unremodeled peripheral lamellae on bones. Jackes (1992) notes other complicating factors for the use of these techniques on archaeological remains. Aiello and Molleson (1993) compared pubic symphyseal aging to microscopic aging techniques and found neither to be more accurate. Wallin and colleagues (1994: 353) have found that their determination of age-at-death through microscopic bone morphometry resulted in standard deviations of over 12 years and was “considerably less precise than generally stated in the literature.” Paine and Brenton (2006) found that poor nutritional health significantly retards osteonal remodeling, resulting in the under-aging of individuals by an average of 29.2 years.

18.3.12 Multifactorial Age Estimation

Given the variety of techniques available for assessing skeletal age-at-death (for another review, see Cox, 2000a), what techniques should be used by the osteologist? In Todd’s original 1920 work on the changes he had classified in the pubic symphysis, he took great pains to point out that the most accurate estimate of age can only be made after examination of the entire skeleton. However, due to the sometimes fragmentary nature of skeletal remains and the history of development of aging techniques, his advice has often been subsequently forgotten by human osteologists. All osteologists use dental development, eruption, epiphyseal appearance, and fusion when aging immature skeletal material. For aging adult skeletal remains, however, osteologists are sharply divided on the question of technique. This controversy provides an important arena for the continued testing and refinement of the techniques outlined earlier.

Some osteologists, particularly those working in forensic contexts, favor the use of the pubic symphysis and assign other anatomical regions a lesser role in age analysis. Lovejoy et al. (1985a) note that this traditional forensic orientation to aging has led to problems when skeletons from large populations are aged by different observers using established methods. Furthermore, the value of skeletal age indicators has been judged on the basis of accuracy (differences between predicted and actual ages) without due regard to bias (the tendency of a given technique to over- or under-age).

Figure 18.19 (*Opposite*) **A visual comparison of age estimates based on various techniques.** Refer to the individual figures for additional details and data sources. For explanation of the nonlinear scale used here, see the caption to Figure 18.1.



Appearance and fusion of secondary centers of ossification (Figure 18.10)

Development and eruption of deciduous and permanent dentition (Figure 18.3)

Long bone lengths (Figure 18.9)

Bone microstructure (Figure 18.18)

Sternal end of R. rib 4 (Figure 18.17)

Dental attrition (Figure 18.5)

Cranial suture closure (Figure 18.8)

Pubic symphysis (Figure 18.14)

Auricular surface of ilium (Figure 18.16)

If more than one criterion is available for assessing skeletal age-at-death, all criteria should be employed (Baccino et al., 1999). One immediate objection to this recommendation arises because of the marked differences in the reliability between different age indicators. For example, many investigators are hesitant to alter a determination of age-at-death based on the pubic symphysis given additional data from cranial suture closure because of the perceived unreliability of the latter (see Meindl and Lovejoy, 1985). In forensic aging of single individuals, such caution may be advisable (depending on the assessed age). However, cranial suture closure is correlated with increasing age, and in the analysis of populations the addition of data on age-at-death from the sequential addition of other age indicators should improve the accuracy of determination.

18.4 Determination of Sex

The terms “sex” and “gender” have increasingly become conflated in the anthropological and medical literature. They do not refer to the same thing, they are not synonyms, and they should not be used interchangeably. Gender is an aspect of a person’s social identity, whereas sex refers to a person’s biological identity. This distinction is important for biological anthropologists to preserve in general, and particularly important to retain in human osteology (Walker and Cook, 1998). In the archaeological context, it is often possible to determine sex through analysis of skeletal remains, and gender roles through studies of material culture (artifacts) and context.

With a sample of 50 lowland gorilla males and 50 lowland gorilla females, even the untrained observer could sort skeletal elements by sex using size and shape. For this primate, 100% accuracy in sorting is obtained easily. The same applies to orangutans. With chimpanzees, the differences are not as marked, but when the canine teeth rather than the overall size of the cranium are examined, perfect accuracy can still be approached. Moving to a sample of 50 male and 50 female modern humans, there is far less sexual dimorphism in canine size, and sorting accuracy is therefore reduced. For some elements, such as the pelvis or the cranium, training and experience can often allow correct sorting about 80–90% of the time. Because of the uncertainties involved in the determination of sex from human skeletal remains, a vocabulary of terms (Table 18.5) which express both the determination of sex and the analyst’s confidence in the determination will prove useful.

Table 18.5 Terminology and abbreviations used in determinations of sex

Term and symbol		Should be read as	Meaning
Female	♀	Female	Analyst has full confidence in the determination of sex for the remains.
Male	♂	Male	
(Female)	(♀)	Probably female	Analyst does not have full confidence in the determination, but feels the remains are probably the stated sex.
(Male)	(♂)	Probably male	
Female ?	♀ ?	Possibly female	Analyst does not have confidence in the determination, but feels the available evidence hints at the stated sex.
Male ?	♂ ?	Possibly male	
indet.		sex indeterminate	The remains have been analyzed, but are lacking sufficient diagnostic morphology for a determination of sex.
unk.		unknown sex	The remains have not been analyzed; no determination of sex has been attempted.

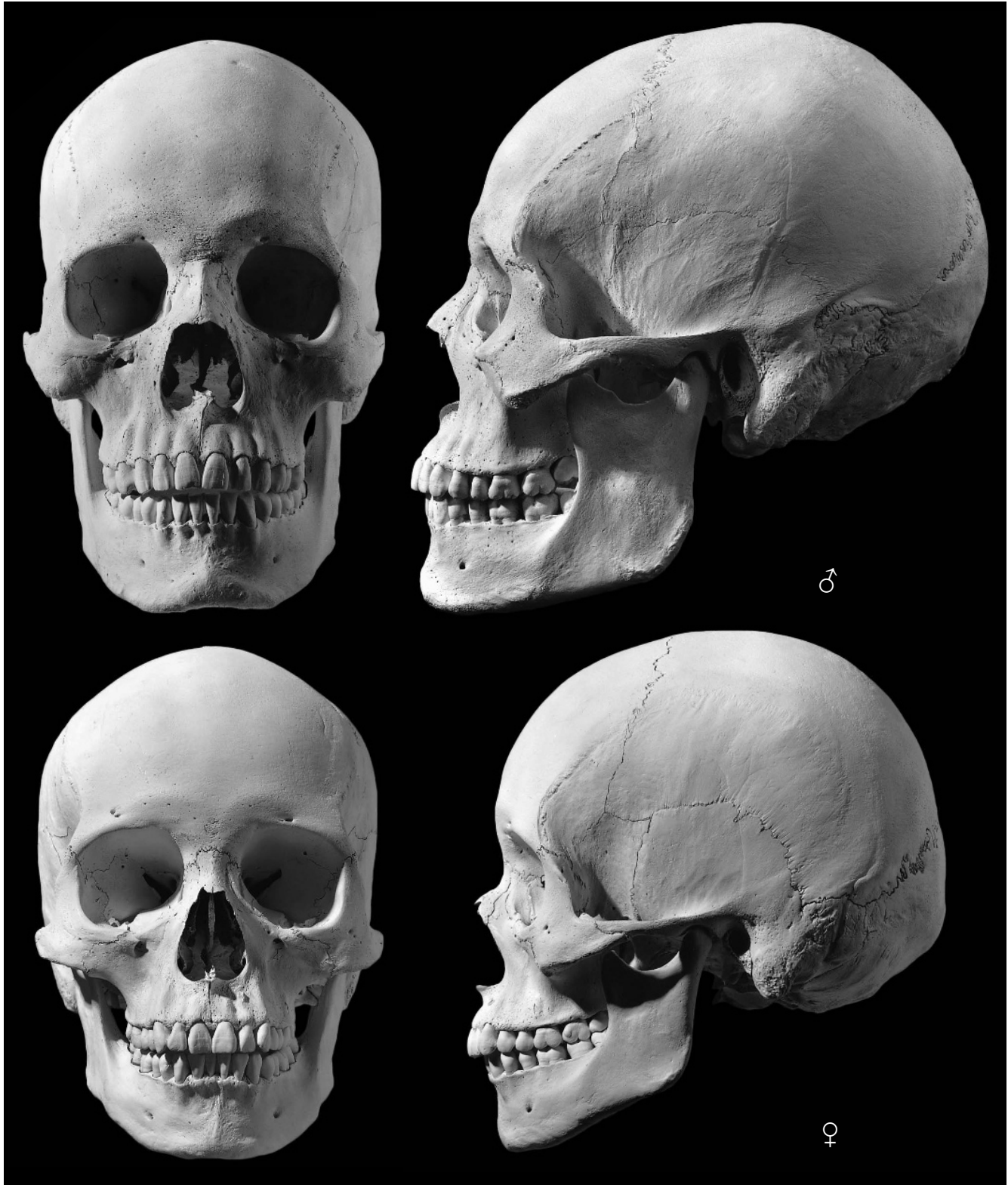


Figure 18.20 Male (*top*) and female (*bottom*) adult skulls in frontal and lateral views. The female skull chosen for this illustration was taken from the hyper-feminine end of the female range. The male is the same individual used to illustrate the cranium in Chapter 4. This comparison illustrates the differences between male and female skulls discussed in the text. It should *not* be taken as a representation of the difference between *average* male and female skulls, but rather as an indication of how much sexual variation is seen in the human skull. One-half natural size.

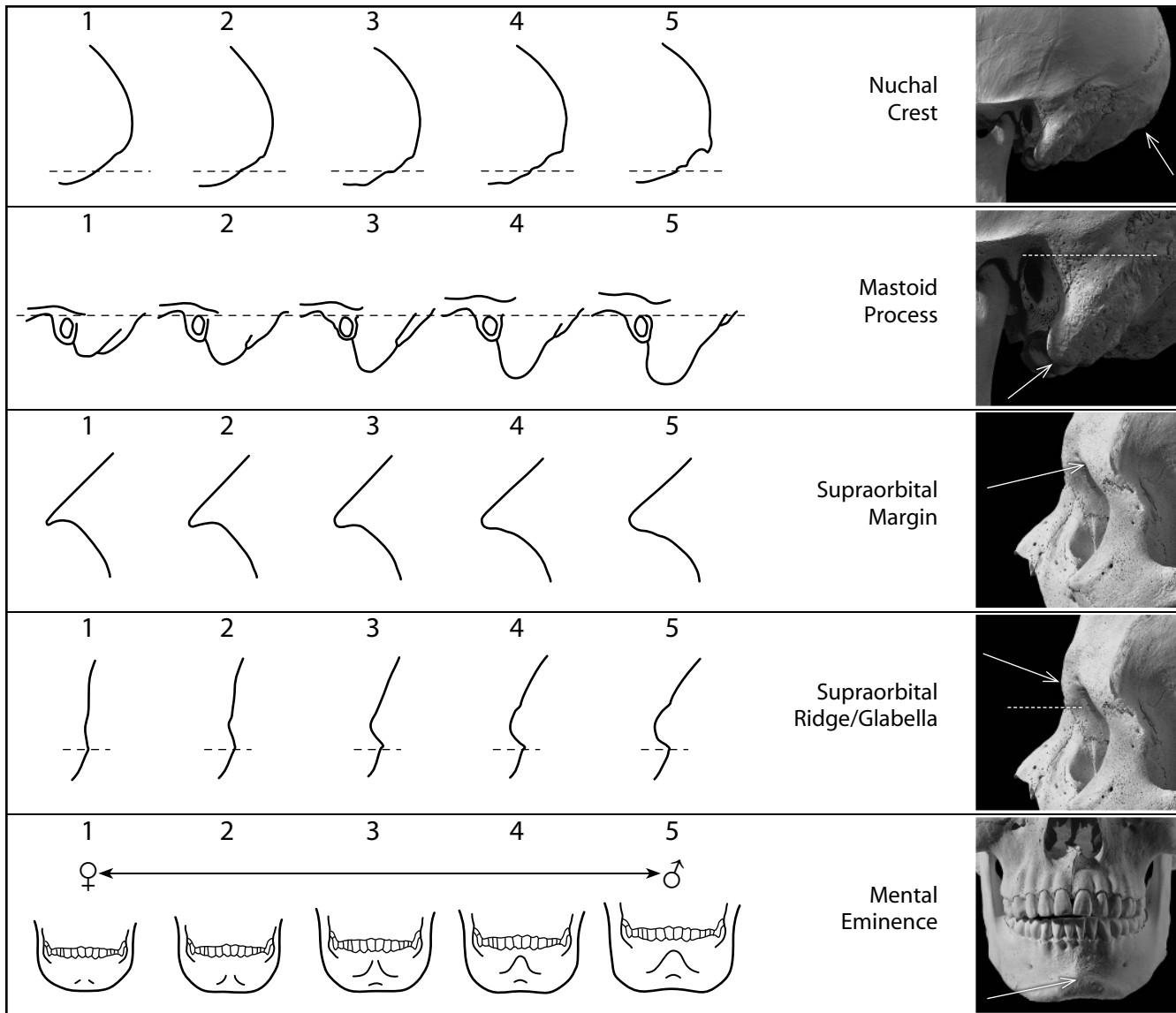


Figure 18.21 Cranial sexing. A qualitative scoring system for sexually dimorphic cranial features from Walker in Buikstra and Ubelaker (1994). In recording the features, optimal results are obtained by holding the cranium or mandible at arm's length, a few inches above the appropriate portion of this figure, oriented so that the features can be directly compared with those illustrated. Move the bone from diagram to diagram until the closest match is obtained. Score each trait independently, ignoring other features. A specific procedure is described to the right of each trait (revised after Walker, 2008). *Key:* 1 = hyperfeminine, 2 = feminine; 3 = indeterminate; 4 = masculine; 5 = hypermasculine.

Human sexual dimorphism is complex, with behavioral, physiological, and anatomical dimensions. Anatomical differences are more pronounced in some soft tissue areas, but much more limited in the skeleton. Nevertheless, skeletal differences between male and female humans do exist and can be useful to the osteologist. It is important to keep in mind that determinations of sex for human skeletal remains are most accurate after the individual reaches maturity. Buikstra and Mielke (1985) summarize in helpful tabular form the accuracy of a variety of skeletal sexing techniques, and Mays and Cox (2000) provide a review of techniques for mature and immature remains.

Nuchal Crest: View the lateral profile of the occipital and compare it to the diagrams. Feel the surface of the occipital and note any rugosities on its surface. The important feature to consider in scoring this trait is the development of bone on the external surface of the occipital associated with the attachment of the nuchal muscles. Ignore the contour of the underlying bone (*eg.*, the presence or absence of an occipital bun) in scoring this trait.

Minimal expression (score = 1): The external surface of the occipital is smooth with no bony projections visible from when the lateral profile of the occipital is viewed.

Maximal expression (score = 5): A massive nuchal crest that projects considerable distance from the bone and forms a well-defined ledge or hook of bone.

Mastoid Process: Score this feature by comparing its size with that of surrounding structures such as the external acoustic meatus and zygomatic process of the temporal bone. Mastoid processes vary considerably in their proportions. The most important variable to consider in scoring this trait is the volume of the mastoid process, not its length.

Minimal expression (score = 1): A very small mastoid process that projects only a small distance below the inferior margins of the external acoustic meatus and the digastric groove.

Maximal expression (score = 5): A massive mastoid process with lengths and widths several times that of the external acoustic meatus.

Supraorbital Margin: Hold your finger against the margin of the orbit in the area lateral to the supra-orbital foramen. Look at each of the diagrams to determine which matches most closely.

Minimal expression (score = 1): Extremely sharp, border feels like the edge of a dull knife.

Maximal expression (score = 5): A thick rounded margin with a curvature that approximates that of a pencil.

Glabella/Supraorbital Ridge: View the cranium from its lateral side and compare the profile of the glabella/supra-orbital area with the profiles in the diagrams.

Minimal expression (score = 1): The contour of the frontal is smooth with little or no projection in the glabellar area.

Maximal expression (score = 5): The glabella and/or supra-orbital ridge are massive and form a rounded loaf-shaped projection.

Mental Eminence: Hold the mandible between your thumbs and your index fingers with your thumbs on either side of the mental eminence. Move your thumbs medially so that they delimit the lateral borders of the mental eminence.

Minimal expression (score = 1): Area of the mental eminence is smooth. There is little or no projection of the mental eminence above the surrounding bone.

Maximal expression (score = 5): A massive mental eminence that occupies most of the anterior portion of the mandible.

In general and within a given population, female skeletal elements are characterized by smaller size and lighter construction. For this reason, in a large, seriated, mixed-sex collection of elements, the largest, most robust elements with the heaviest rugosity are male. Males can be, on average, up to 20% larger in some skeletal dimensions, whereas in other dimensions there may be no dimorphism. The smallest, most gracile elements are normally female. Normal individual variation, however, always produces some small, gracile males and some large, robust females who fall toward the center of the distribution where sorting sex is difficult. In other words, the sexes overlap near the center of the distribution. For this reason, osteologists have traditionally concentrated on elements of the skull and pelvis in which sex differences in humans are the most extreme.

In addition to the complications of individual variation within the population, incorrect sex identifications are sometimes made because of variation among populations. Some populations are, on average, composed of larger, heavier, more robust individuals of both sexes, whereas other populations are characterized by the opposite tendency. Because of such interpopulational differences in size and robusticity, males from one population are sometimes mistaken for females in other populations and vice versa. The osteologist should always attempt to become familiar with the skeletal sexual dimorphism of the population from which unsexed material has been drawn. As it is with aging, seriation can be a helpful approach in determining the sex of skeletal remains from a population.

All of the morphological techniques used in sexing skeletal remains depend on the preservation of sexually dimorphic elements. All of them share a nontrivial error rate, even for adult remains. However, if DNA can be recovered from osseous remains, the sex of any individual (regardless of individual age) can be determined with high accuracy. This is true even for highly fragmentary remains. Sexing of osteological specimens in a forensic context, therefore, has been changed fundamentally by the introduction of molecular techniques to human osteology (Stone et al., 1996; Stone, 2000, 2008).

18.4.1 Sexing the Skull Using Overall Robusticity

Determination of sex based on parts of the skull follows the observation that males tend to be larger and more robust than females. In addition to size, tendencies such as those outlined here provide useful indications for determining the sex of isolated skulls. These characteristics are the traditional ones used by osteologists. Figure 18.20 illustrates them.

Relative to female crania, male crania are characterized by greater robusticity. Male crania typically display more prominent supraorbital ridges, a more prominent glabellar region, and heavier temporal and nuchal lines. Male frontals and parietals tend to be less bossed than female ones. Males tend to have relatively large, broad palates, squarer orbits, larger mastoid processes, larger sinuses, and larger occipital condyles than females. When compared to female mandibles, male mandibles are characterized by squarer chins, more gonial eversion, deeper mandibular rami, and more rugose muscle attachments (*eg*, see Gülekon and Turgut, 2003).

The relative strength of these cranial tendencies can be summarized by the following: Where associated postcranial material is available, always use the pelvis for sex determination. When sexing only skulls, always use the entire population under study. Seriate this population according to the criteria you use and then sort. If you are sexing only one or a few individuals, try to use comparative populations that are genetically and temporally close to the ones from which your sample derives.

Walker, in the Buikstra and Ubelaker Standards volume (1994), provides five aspects of skull morphology that are useful in determining sex. These are shown in Figure 18.21. In all cases, a five-point scale is used, to be interpreted as follows: 1 = hyperfeminine, 2 = feminine; 3 = indeterminate; 4 = masculine; 5 = hypermasculine. Graw et al. (1999) present another scoring system focused only on the supraorbital margin and Walrath et al. (2004) warn that the degree of reliability for such methods is closely linked to the clarity and quality of the definitions provided for scoring the characteristics.

In an attempt to go beyond the traditional methods outlined earlier, Giles and Elliot (1963) used discriminant functions based on nine standard cranial metrics to diminish the subjectivity involved in sexing the skull. However, a study by Meindl et al. (1985b) has shown that subjective assessment of the skull compared favorably to the discriminant functions of Giles and Elliot. In tests on Hamann-Todd crania, Meindl et al. (1985b) found that older individuals show increasingly “masculine” morphology. Whereas 10.2% of the males in their sample of 100 were sexed incorrectly, only 4.9% of the females were misidentified. Given these facts, Meindl et al. (1985b) suggest that overall sex ratios and age class sex ratios in prehistoric cemeteries should only be estimated from adult burials with fully preserved pelvises.

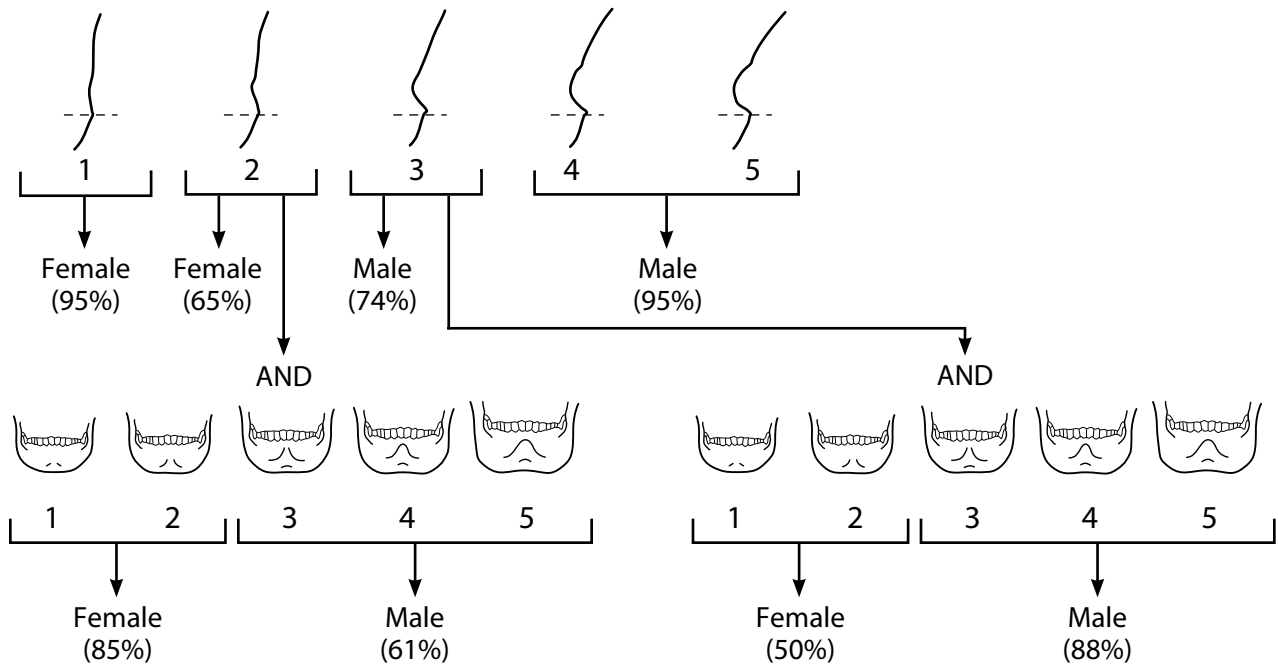
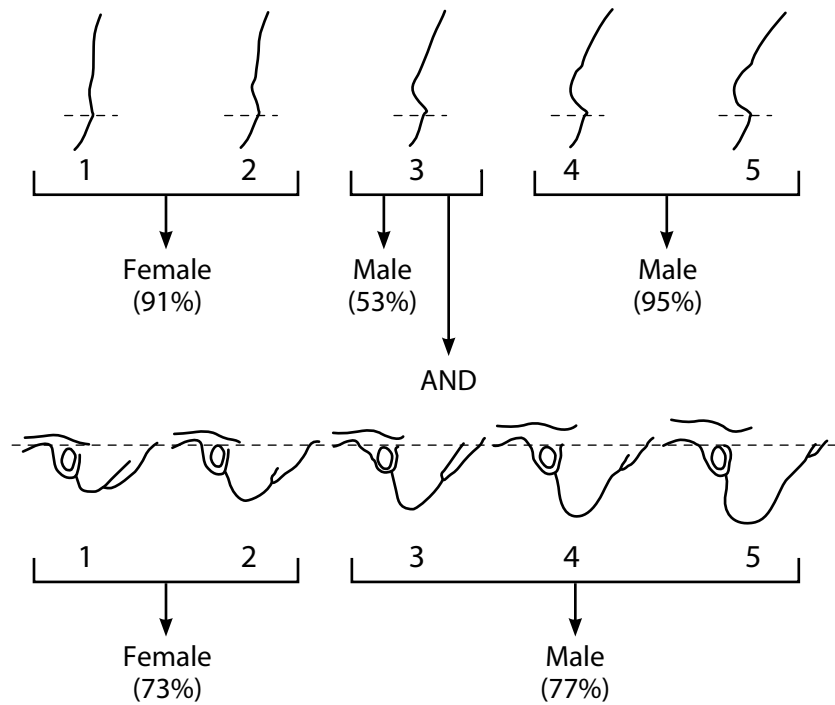


Figure 18.22 CHAID analysis decision tree. Two examples demonstrating the use of decision analyses in probabilistic sex determination (Stevenson et al., 2009). *Top*: the classification tree shown on the top is for European Americans crania which preserve both glabella (*above*) and mastoid process (*below*). *Bottom*: the classification tree on the bottom is for a mixed sample of Europeans, European Americans, and African Americans which preserve both glabella (*above*) and the mental eminence (*below*). Based on data from Stevenson et al. (2009).

A promising new technique has been introduced which can be used with ordinal data such as that obtained when scoring cranial traits according to Walker's system, discussed above. Using Chi-squared automatic interaction detection (CHAID), Stevenson et al. (2009) were able to produce classification trees that are easy to use and result in a probabilistic determination of sex (see Figure 18.22 for two examples of such decision trees).

18.4.2 Sexing the Mandible

In addition to the robusticity of the mental eminence discussed above, there are other sexually dimorphic traits that can be used to determine the sex of isolated mandible. Males tend to have gonial angles that are rugose and often everted, both as a consequence of having larger masseter muscles (Acsádi and Nemeskeri, 1970; Novotný, et al., 1993; Kemkes-Grottenthaler et al., 2002). Females and immature individuals of both sexes have more gracile gonial angles that are not everted.

Loth and Henneberg (1996, 1998) proposed that the posterior border of the mandibular ramus could be used to sex unknowns with a predictive accuracy of about 90.6%–99.0%. They noted that mandibles of adult males have a distinct angulation of the posterior border of the mandibular ramus at the level of the occlusal surface of the molars, and that females lacked flexure at that level (Figure 18.23). The technique was scrutinized by Koski (1996), Donnelly et al. (1998), Haun (2000), Hill (2000), and Kemkes-Grottenthaler (2002), and was found to yield results with much lower accuracy (59%–80.4%); but more recently, Balci et al. (2005) reexamined the method and found a base level of 90.6% accuracy that was higher in males (95.6%) than in females (70.6%).

Balci et al. (2005) noted that all previous tests of the method had not followed Loth and Henneberg's caution against including mandibles with excessive tooth loss (ETL), and they proposed that any mandible missing more than two molars should be excluded on the basis of ETL. Balci et al. were able to increase the accuracy of the method even further when they broadened the definition of "sex indeterminate" from just a score of 0 to a score of -1, 0, or +1. With these ambiguous mandibles removed from the analysis—thereby limiting the analysis to only those mandibles having either bilateral flexure (score = +2) or bilateral nonflexure (score = -2)—the accuracy of the modified method *on the remaining mandibles* rose dramatically (to 100% in their

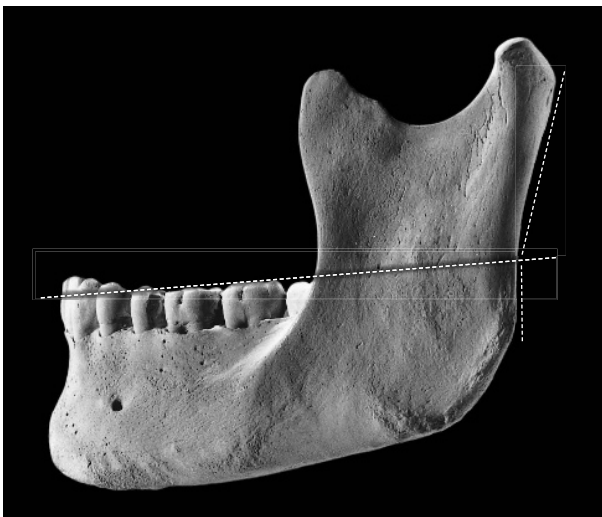


Figure 18.23 Ramal flexion. Flexure of the posterior border of the mandibular ramus in a young male individual. In contrast to males, who have a pronounced flexure of the posterior ramal border at the level of the occlusal surface of the molars, females tend to have either a straight posterior ramal border or a flexure that is close to the condylar neck. The individual shown here is the same one used to illustrate Chapter 4. Two-thirds natural size.

sample). It should be noted that the trade-off for such high accuracy is a substantially reduced applicability—of the 120 mandibles Balci et al. examined, sex could be assigned to only 69 or 57.5% (males: 67.4%, females: 20.0%). As their sample is taken from a modern study collection, one could expect that the applicability would be even lower for archaeological remains.

Loth and Henneberg (2001) also claimed that their posterior ramal flexure method could be used to determine sex in juveniles with 81% accuracy, but in a blind test of the method on juvenile mandibles, Scheuer (2002) found the accuracy to only be 64%.

18.4.3 Sexing the Teeth

Because teeth are often better preserved than other skeletal elements, there have been efforts to sex the skeleton using the teeth. The degree of sexual dimorphism in human crown sizes varies between populations. Human dental dimorphism centers on the canines, but it is not nearly so pronounced as it is in the great apes. Human lower canines show the greatest dimorphism, up to 7.3% (Hillson, 1996, 2005), followed by the upper canines. Deciduous teeth are also dimorphic, with molars and canines up to 7%. Accuracy of sexing unknowns based on dental metrics, either univariate or multivariate, varies from 60% to 90% and usually lies between 75% and 80%. Because the average difference in size between sexes at any individual tooth position is very small, about half a millimeter on average, these dimensions must be measured carefully and with precise instruments, to avoid intra- and interobserver error. De Vito and Saunders (1990), Bermúdez de Castro et al. (1993), Beyer-Olsen and Alexandersen (1995), and Hillson (1996, 2005) provide reviews of the use of dental dimensions to sex human teeth.

18.4.4 Sexing the Postcranial Skeleton

As for the cranium, sexually diagnostic traits in the postcranial skeleton are difficult to identify and assess before puberty. Numerous metric studies of the postcranial skeleton have examined sexual dimorphism in the size of different adult elements. Bass (2005) provides an excellent review of these. Results on the most dimorphic limb bones can be summarized by noting that single measurements, or combinations of measurements, have usually been found to correctly identify the sex of between 80% and 90% of all individuals. Incorrect identification within any population is a consequence of size overlap between males and females in the center of the overall range (Figure 18.24). Many studies have been conducted on known-sex samples to derive functions capable of classifying sex accurately more than 85% of the time for a variety of elements ranging from the metacarpals (Falsetti, 1995; Stojanowski, 1999; but see Burrows, 2003) to the metatarsals (Robling and Ubelaker, 1997), humerus (Rogers, 1999), ulna (Purkait, 2001), and calcaneus (Introna et al., 1997). Because these functions are often not tested beyond (or independent of) the skeletal population on which they were based, claims of accuracy are sometimes questionable. For instance, Rogers (1999) has claimed 92% accuracy based on four characters of the distal humerus, but testing on a wider sample will be required.

The skull was the first, most traditional focus of sexing studies, but a number of methods of sexing have also been applied to the pelvis. There are dramatic functional differences between male and female pelvic anatomy. These extend to the bony skeleton and represent differences found in all modern human groups. The pelvis is of vital importance in locomotion and parturition. During human evolution, selective pressures associated with these and other roles led to the sexual dimorphism seen in the modern human pelvis.

Traditional methods used to determine sex on the pelvis or its parts are based on the following tendencies: The sacra and ossa coxae of females are smaller and less robust than those of males. Female pelvic inlets are relatively wider than male ones. The greater sciatic notches on female ossa coxae are relatively wider than those on male bones (Figure 18.25). Females have relatively longer pubic portions of the os coxae, including the superior pubic ramus, than males. The subpu-

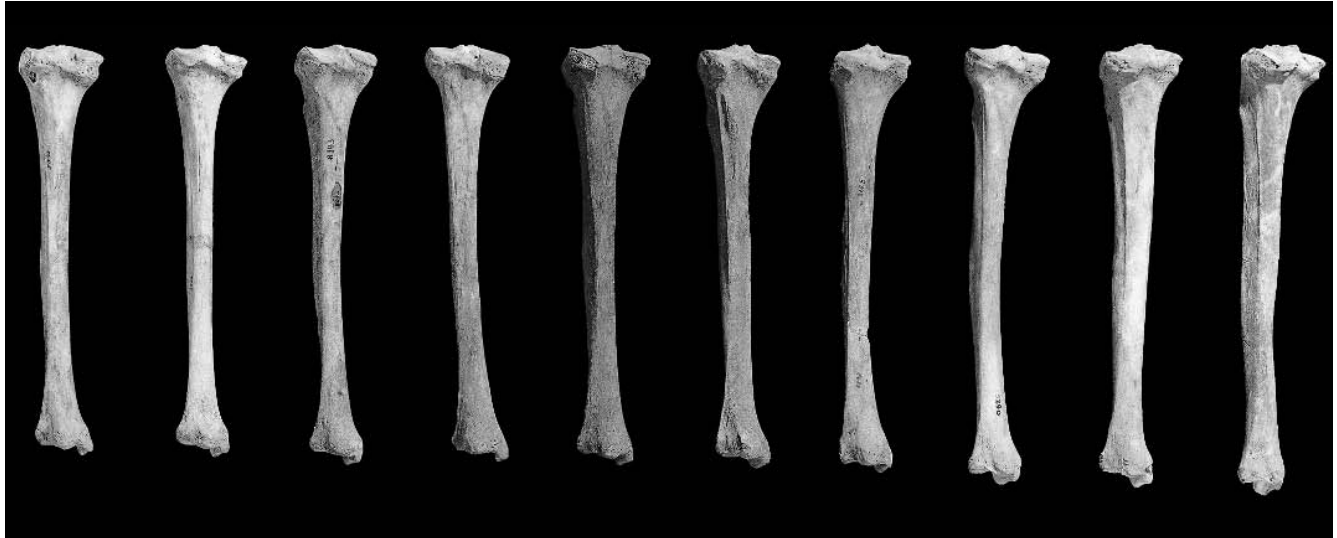
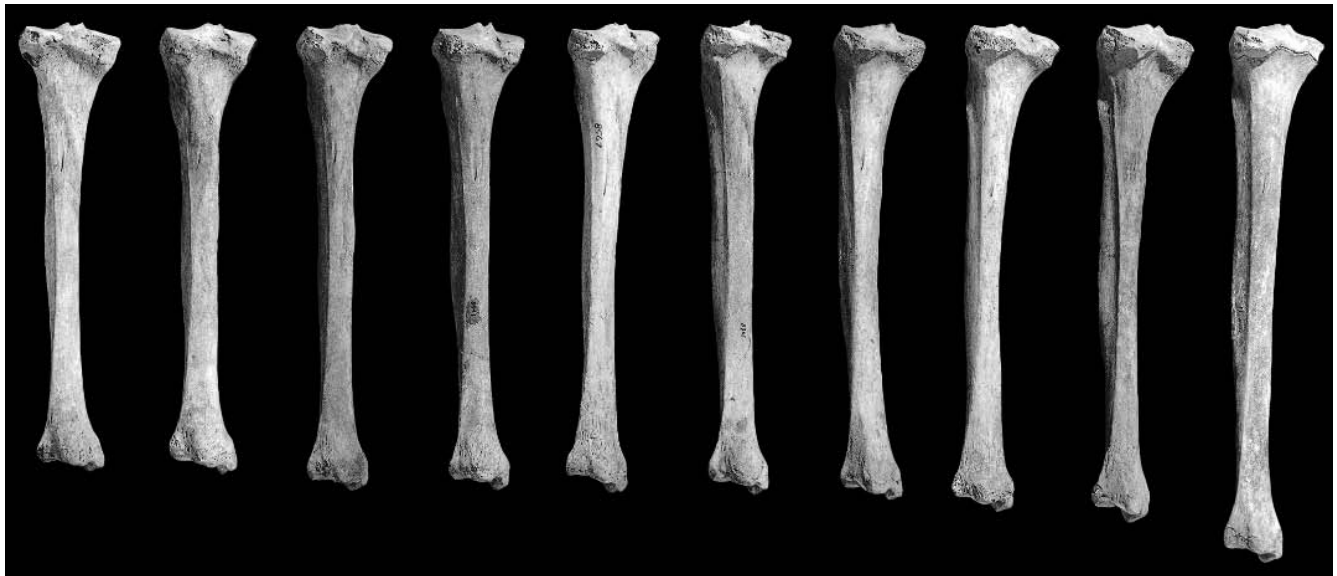
Figure 18.24 Variation in tibial size and shape among ten females (*above*) and ten males (*below*). Tibiae were selected at random from a single-site, sex-balanced sample of 100 prehistoric Californian skeletons. This sample, 20% of the total population, gives an indication of the normal sexual dimorphism encountered in modern human skeletal remains. One-sixth natural size.



bic angle, formed between the lower edges of the two inferior pubic rami, is larger in females than in males. The preauricular sulcus is present more often in females than in males. A corollary is that the auricular surface is more elevated from the female ilium than from the male ilium, even though sexual dimorphism in the auricular surface itself is insufficient for accurate sexing (Ali and MacLaughlin, 1991). The acetabulum tends to be relatively larger in males (Figure 18.26).

A variety of metric techniques have been developed to express these relationships. Washburn's attempt to quantify the relative proportion of the pubic part of the os coxae is the most famous and effective of these. Washburn (1948) measured the length of the pubis relative to the length of the ischium via an index that discriminated between male and female ossa coxae. Rogers and Saunders (1994) provide a review of metric and morphological traits used to sex the pelvis, and

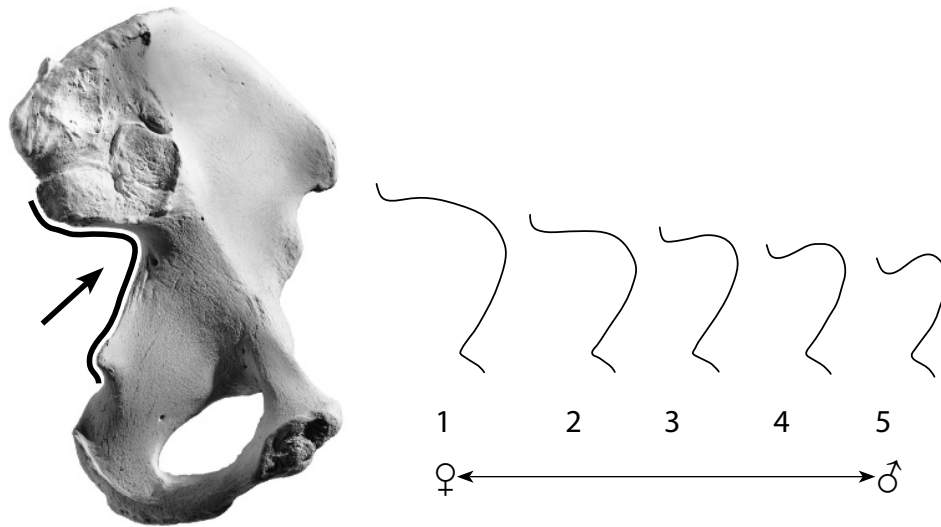


Figure 18.25 Sex differences in the greater sciatic notch. From P. Walker in Buikstra and Ubelaker's Standards volume (1994). The greater sciatic notch tends to be broad in females and narrow in males. These shape differences are not as reliable as those in the subpubic region and should be thought of as secondary indicators. The best results for scoring are obtained by holding the os coxae above this figure so that the greater sciatic notch has the same orientation as the outlines, aligning the straight anterior portion of the notch that terminates at the ischial spine with the right side of the diagram. While holding the bone in this manner, move it to determine the closest match. Ignore any exostoses near the preauricular sulcus and the inferior posterior iliac spine. Configurations more extreme than 1 or 5 should be scored as 1 and 5, respectively. The illustration numbered 1 shows typical female morphology, whereas the higher numbers are male conformations.

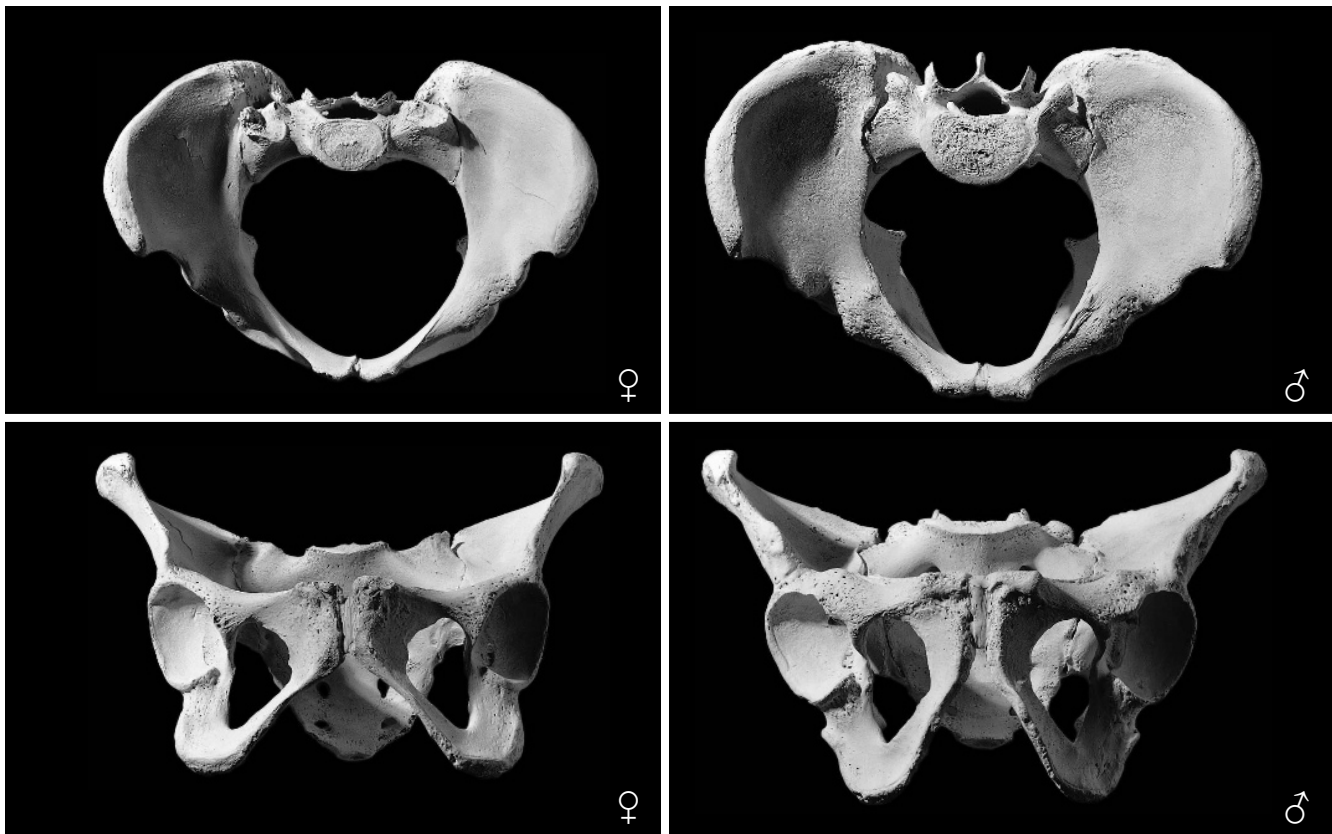


Figure 18.26 Sexual dimorphism in the bony pelvis showing differences in size and shape. *Left:* female; *right:* male. One-fourth natural size.

Brůžek (2002) provides a more current assessment. Walker's (2005) analysis of age and population variation in sciatic notch form is a valuable review.

In 1969, T. W. Phenice published an important new method for sexing the pelvis. This paper, "A newly developed visual method of sexing the os pubis," described the most accurate method yet known for determining sex of an individual from the skeleton. Until the publication of the Phenice paper, the osteologist's success at using traditional visual methods of sexing the pelvis depended, in large part, on experience—decisions were more-or-less subjective. The application of metric criteria was difficult because many pelvises were not intact enough for reliable measurement, and even the simplest techniques were time-consuming. Phenice's method (Figure 18.27) changed the situation, allowing more accurate, quicker sexing on any pelvis bearing an intact pubic region.

In employing the Phenice method to sex an os coxae, note that not every specimen is a "perfect" male or female. When there is a criterion that does not obviously sex the specimen, discard that criterion. When there is some ambiguity concerning one or two of the criteria (most often in the medial aspect of the ischiopubic ramus, and least often in the ventral arc), usually one of the remaining criteria will clearly attribute the specimen to a sex. After sexing the specimen with this procedure, observe the more traditional features outlined earlier to see if they correspond to (corroborate) your diagnosis. For any case in which they do not confirm, recheck your observations. Remember that female individuals are most likely to be intermediate in displaying the Phenice features.

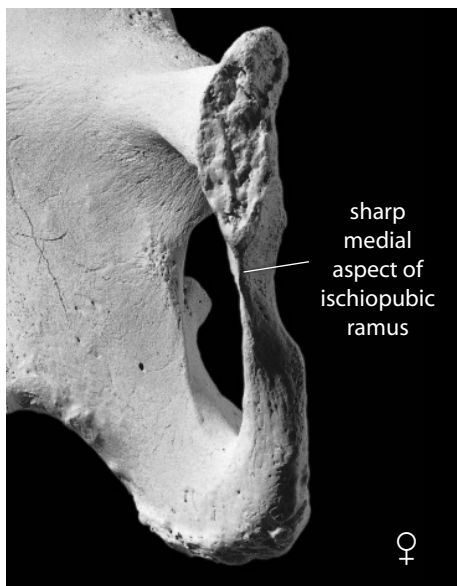
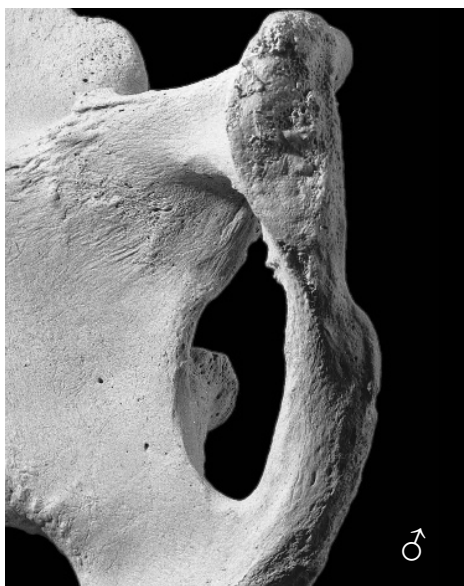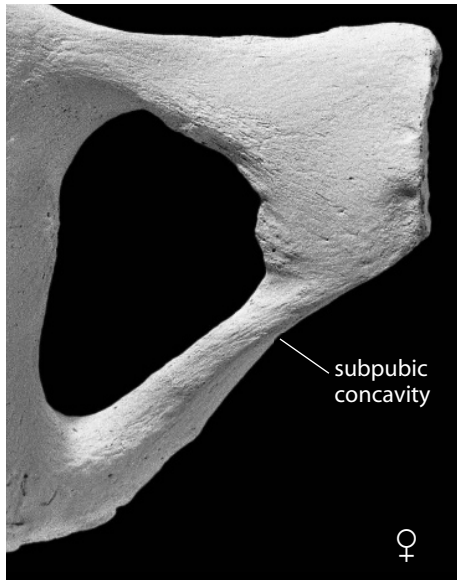
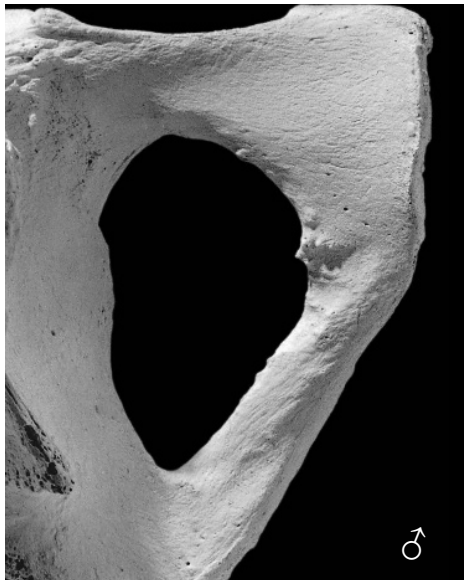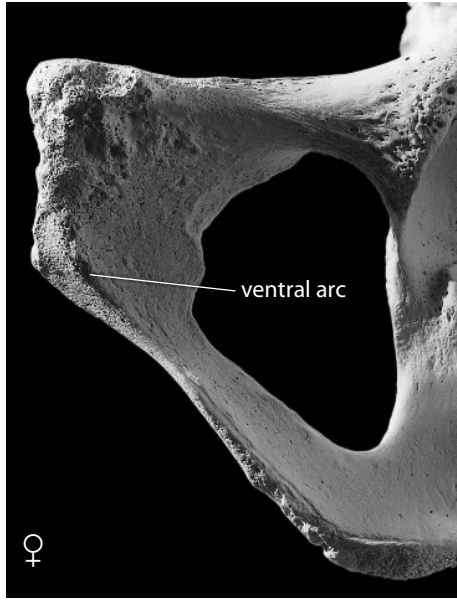
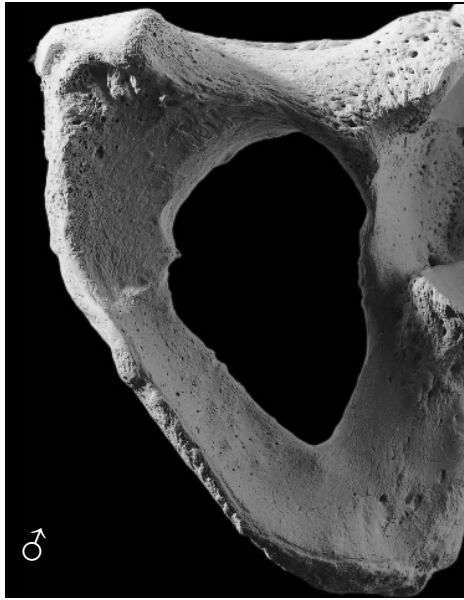
The Phenice method should only be used for fully adult material. Accuracy of sexing based on this method ranges from 96% to 100%, the highest ever achieved in the skeleton, but Lovell (1989) has suggested that accuracy might be reduced in the case of older adult specimens. In 1990, MacLaughlin and Bruce tested the Phenice characters for accuracy of sex identification on skeletal series from London, Leiden, and Scotland. They were unable to confirm the accuracy obtained by Phenice and others, achieving success on only 83% of the English, 68% of the Dutch, and 59% of the Scottish. They found the subpubic concavity to be the single most reliable indicator. Using 1,284 pubic bones from the Los Angeles County Coroner's collection, Sutherland and Suchey (1991) reported that they achieved 96% sexing accuracy using the ventral arc alone. They note that this feature first appears at age 14 but does not become marked until age 20. The discrepancy between these two major tests of the Phenice technique remains unexplained, but Ubelaker and Volk (2002) note that experience plays a role in conditioning results from the use of this technique. The best advice for sexing of the os coxae, as for aging the skeleton, is to use all of the available data.

18.5 Estimation of Stature

Estimating individual stature from bone lengths has a long history in physical anthropology. The fact that the height (stature) of the human body correlates with limb bone length across all ages allows the osteologist to reconstruct an individual's stature from different skeletal elements. Unfortunately, the correlation is imperfect within living populations and varies between populations. Based on studies of skeletons from individuals of known stature, several investigators have derived regression equations useful in estimating stature in different human populations.

To estimate stature, based on the maximum length of a male femur from a Mesoamerican ar-

Figure 18.27 (*Opposite*) **The Phenice (1969) technique for sexing the pubic portion of the os coxae.** Left ossa coxae shown. In each comparison, the male is on the left and the female is on the right. These ossa coxae are the ones illustrated in Figure 18.24. Approximately two-thirds natural size.



Ventral arc. Orient the pubis so that its rough ventral surface faces you and you are looking down along the plane of the pubic symphyseal surface. The ventral arc is a slightly elevated ridge of bone that sweeps inferiorly and laterally across the ventral surface of the pubis, merging with the medial border of the ischiopubic ramus. Thus, the ventral arc, when present, sets off the inferomedial corner of the pubic bone in ventral view. It is present only in females. Male ossa coxae may have elevated ridges in this area, but these do not take the wide, evenly arching path of the female's ventral arc, nor do they set off the ventral medial quadrant of the pubis.

Subpubic concavity. Turn the pubis over, orienting it so that its smooth, convex dorsal surface faces you and you are once again sighting along the midline. Observe the medial edge of the ischiopubic ramus in this view. Female ossa coxae display a subpubic concavity here; the edge of the ramus is concave in this view. However, males show no evidence of a concavity here. Male edges are straight or very slightly concave.

Medial aspect of the ischiopubic ramus. Turn the pubis 90°, orienting the symphyseal surface so that you are looking directly at it. Observe the ischiopubic ramus in the region immediately inferior to the symphysis. The medial aspect of the ischiopubic ramus displays a sharp edge in females. In males this surface is fairly flat, broad, and blunt.

chaeological site, for example, the osteologist would apply the formula derived by Genovés from modern Mexican samples and published in 1967. This formula is as follows:

$$\text{stature (cm)} \pm 3.417 = 2.26 \times \text{femur length} + 66.379$$

If femur length is known, stature may be calculated with about a 68% probability that the calculated value falls within 3.417 cm of the actual stature of the individual. This formula, of course, can be validly applied only to Mexican samples, but Bass (2005) and Bennett (1993) provide useful tables for stature estimation in different human groups. Most of these formulae are based on the lengths of one or more bones.

Trotter and Gleser (1958) developed formulae for estimating stature based on the Korean War dead, extending their earlier work on World War II remains in an anatomical collection. Formulae were presented for “racial” groups. The Genovés (1967), Trotter and Gleser (1958), and Trotter (1970) formulae for stature estimation are the most frequently used methods in North America. Table 18.5 is taken from the latter publication. As Feldesman and Fountain (1996) note, if the specimen’s ancestry (race) is unknown, it is best to use generic equations of stature. Formicola (1993) evaluated various stature formulae on 66 archaeological skeletons from seven European countries. They found that the Trotter and Gleser formulae for African-Americans worked better than those for European-Americans.

There has been some discussion on how to accommodate old data sets to the modern forensic world (Jantz, 1992, 1993; Giles, 1993). As Jantz (1992) notes, the most commonly used female stature formulae were derived from the Terry Collection, skeletons from people who died in the early 1900s. To what extent should formulae based on those samples be modified to reflect the secular changes in bone length and body height undergone during the last century? Giles (1991)

Table 18.5 Equations used to estimate stature (in cm) from long bone lengths^a of individuals aged 18 – 30^b

European-American Males				African-American Males			
3.08	×	Hum	+ 70.45 ± 4.05	3.26	×	Hum	+ 62.10 ± 4.43
3.78	×	Rad	+ 79.01 ± 4.32	3.42	×	Rad	+ 81.56 ± 4.30
3.70	×	Uln	+ 74.05 ± 4.32	3.26	×	Uln	+ 79.29 ± 4.42
2.38	×	Fem	+ 61.41 ± 3.27	2.11	×	Fem	+ 70.35 ± 3.94
2.68	×	Fib	+ 71.78 ± 3.29	2.19	×	Fib	+ 85.65 ± 4.08
European-American Females				African-American Females			
3.36	×	Hum	+ 57.97 ± 4.45	3.08	×	Hum	+ 64.67 ± 4.25
4.74	×	Rad	+ 54.93 ± 4.24	2.75	×	Rad	+ 94.51 ± 5.05
4.27	×	Uln	+ 57.76 ± 4.30	3.31	×	Uln	+ 75.38 ± 4.83
2.47	×	Fem	+ 54.10 ± 3.72	2.28	×	Fem	+ 59.76 ± 3.41
2.93	×	Fib	+ 59.61 ± 3.57	2.49	×	Fib	+ 70.90 ± 3.80
East Asian Males				Mexican Males			
2.68	×	Hum	+ 83.19 ± 4.25	2.92	×	Hum	+ 73.94 ± 4.24
3.54	×	Rad	+ 82.0 ± 4.60	3.55	×	Rad	+ 80.71 ± 4.04
3.48	×	Uln	+ 77.45 ± 4.66	3.56	×	Uln	+ 74.56 ± 4.05
2.15	×	Fem	+ 72.57 ± 3.80	2.44	×	Fem	+ 58.67 ± 2.99
2.40	×	Fib	+ 80.56 ± 3.24	2.50	×	Fib	+ 75.44 ± 3.52

^a All lengths used are maximum lengths

^b To estimate stature of older individuals, subtract 0.06 (age in years, 30) cm; to estimate cadaveric stature, add 2.5 cm. From Trotter (1970). The tibia is not included; see text for rationale.

makes further comments regarding stature loss in the elderly. Jantz and colleagues (1995) also note that the Trotter and Gleser stature formulae involving tibial length produce stature estimates averaging 2–3 cm too great when used with properly measured tibiae. They show that the original formulae involving tibiae are based on mismeasured tibiae (the malleolus was omitted in maximum length measurements). Finally, Owsley (1995) notes that stature can be defined in several ways, ranging from forensic (*eg.*, from a driver's license) to biological (from cadavers or living individuals). He suggests that biological stature estimations based on long bone lengths are generally less precise than many have assumed. Table 18.6 is from Owsley (1995).

18.6 Estimation of Ancestry

Imagine a sample of 1,000 people—a sample composed of 400 native Nigerians, 300 native Chinese, and 300 native Norwegians. If these people seated themselves randomly at a lecture, the speaker would be able to tell, simply by looking at their faces, whether their ancestry was Asian, African, or European. The sorting accomplished on the basis of soft tissue facial features would correspond perfectly to the geographic origin of the three major components of the sample.

This kind of sorting within the species *Homo sapiens* is usually termed racial sorting. However, there are no “pure” human races (A.A.P.A., 1996). By definition, all members of the same species

Table 18.6 Regression equations for estimating forensic stature from skeletal remains^a

	Factor	Measurement(s) in mm	Constant	90% PI	N
European-American Males	0.05566	Femur Max L + Tibia L	21.64	± 2.5”	62
	0.05552	Femur Max L + Fibula L	22.00	± 2.6”	54
	0.10560	Femur Max L	19.39	± 2.8”	69
	0.10140	Tibia L	30.38	± 2.8”	67
	0.15890	Ulna L	26.91	± 3.1”	62
	0.12740	Humerus L	26.79	± 3.3”	66
	0.16398	Radius L	28.35	± 3.3”	59
European-American Females	0.06524	Femur Max L + Tibia L	12.94	± 2.3”	38
	0.06163	Femur Max L + Fibula L	15.43	± 2.4”	42
	0.11869	Femur Max L	12.43	± 2.4”	48
	0.11168	Tibia L	24.65	± 3.0”	43
	0.11827	Humerus L	28.30	± 3.1”	45
	0.13353	Ulna L	31.99	± 3.1”	40
	0.18467	Radius L	22.42	± 3.4”	38
African-American Females	0.11640	Femur Max L	11.98	± 2.4”	18
African-American Males	0.16997	Ulna L	21.20	± 3.3”	14
	0.10521	Tibia L	26.26	± 3.8”	19
	0.08388	Femur Max L	28.57	± 4.0”	17
	0.07824	Humerus L	43.19	± 4.4”	20

^a Note that the bone measurements should be in millimeters, but that all constants were converted to predict statures and prediction intervals in inches because most North American forensic applications record stature in inches. For example, if the maximum length of the femur from a probable white male is 454mm, the forensic stature is estimated by: $0.10560(454) + 19.39 = 67.33 \pm 2.8$ inches. This person, if a white male, would have a roughly 90% chance of having a forensic stature between 64.5 and 70.1 inches (5 feet 4½ inches to 5 feet 10 inches).

have the potential to interbreed, and hence any subspecific classification is arbitrary. Defining the term “race” has proven difficult in the history of physical anthropology because concepts of race have often been based on composites of biological, social, and ethnic criteria used in a typological fashion. The confusion arising from these difficulties has persuaded some anthropologists to conclude that the very use of the term “race” is counter-productive. In osteological work, particularly work in forensic contexts, the determination of race, or geographic ancestry, is usually an important consideration.

The title of a paper by physical anthropologist Kenneth Kennedy (1995) asked, “But Professor, Why Teach Race Identification if Races Don’t Exist?” Typological race concepts in physical anthropology have gone the way of the dinosaurs, but human populations are routinely divided into separate “races” (African-Americans, European-Americans, Native Americans, and Hispanics) in governmentally mandated programs, the popular media, and the forensic sciences. As St. Hoyme and İscan (1989) note, human osteologists who examine human bones must communicate with law-enforcement personnel, students, and the general public. How people are categorized by others depends on law and custom. The United States government’s bureaucratic approach to “race” is quite specific in this regard, noting that its classifications (American Indian or Alaskan native; Asian or Pacific Islander; Black; Hispanic; White; or other) “should not be interpreted as being scientific or anthropological in nature” (O.M.B., 1997).

Most forensic applications bring the human osteologist into contact with medical examiners, law enforcement, or other government personnel who expect missing and/or found persons to be classified in terms of their bureaucratic “races” as defined by the government. These “racial” categories, of course, mix historical and social phenomena with biology. Gill (1995) provides an example of this by pointing out that in the United States, a person who is of 75% European descent, but has a black African grandparent is considered African-American rather than European-American. Today, it is common for parents of completely different geographic ancestry to have children whose anatomical configurations will defy assessment of ancestry. How does the osteologist deal with these social and biological realities?

The osteologist’s role, particularly in the forensic setting, is often to individualize an unknown’s osteological remains by assessing the sex, age, stature, and ancestry of the individual. The ability to determine the geographic ancestry of a skeletal unknown is useful for narrowing the possibilities and leading to a positive identification in many cases. Yet as a biological scientist, the human osteologist knows that all variation is continuous, not discrete. As Kennedy (1995) notes, there is a paradox in the scientific rejection of “race” and its survival in medico-legal contexts. As Kennedy says (1995: 798), “Forensic anthropologists are keenly aware that neither the medical examiner, the judge, the attorney client nor the sheriff would appreciate a lecture on the history of the race concept in Western thought. These professionals want to learn if the skeleton on our laboratory table is a person of Black, White, Asian or Native American ancestry.” To conduct analysis of ancestral background, the osteologist may use osteological traits known to vary among different human populations in different parts of the world.

As Brace (1995: 172) explains, “Skeletal analysis provides no direct evidence for skin color for example, but it does allow an accurate estimate of original geographical origins. African, eastern Asian, and European ancestry can be specified with a high degree of accuracy. Africa of course entails ‘black,’ but ‘black’ does not entail African.” Marks (1996) notes that the tendency for Americans to classify people into one of three “races” is an artifact of history and statistics—immigrants to North America have come mostly from ports where seafaring vessels in earlier centuries could pick them up. Hence, the American notion of “black” is actually west African, and the notion of “Asian” is actually east Asian. People from south Asia (India and Pakistan—people with darker skins and facial resemblances to Europeans) immigrated in smaller numbers and therefore did not merit as much bureaucratic concern.

A real example of the dilemma facing human osteologists in the area of “racial” identification comes from the work of Katz and Suchey (1989) on their sample of Los Angeles male pubic symphyses. These workers, in a paper entitled “Race Differences in Pubic Symphyseal Aging Patterns in the Male,” assess the Los Angeles County Coroner sample used to generate the Suchey-

Brooks system of symphyseal aging (Section 18.3.6). They segregated the symphyses into “racial” categories. They did not use the California death certificates made out by coroner investigators. As Katz and Suchey note, these examiners used nonuniform mixtures of biological, cultural, and linguistic variables in their determinations. Rather, Suchey divided the autopsied individuals into 486 Whites, 140 Blacks, and 78 Mexicans and noted that her Mexican category is a category showing Mexican ancestry coupled with a strong American Indian racial component. Katz and Suchey found that pubic symphyseal metamorphosis was accelerated in Blacks and Mexicans, but they could not address the issue of causality.

When DNA can be extracted from a subject’s osteological remains, accurate determination of the ancestral population and even familial relationships becomes possible. DNA typing of skeletal remains has the potential to provide the best available information regarding the populational affinity of the individual. Mitochondrial DNA (mtDNA) is a small portion of the human genome that is inherited only from the mother. Mitochondrial DNA evolves about 10 times faster than nuclear DNA, making mtDNA a useful tool for discriminating between even closely related populations (Wallace and Torroni, 2009). See Chapter 22 for more information on molecular techniques in osteology.

Whereas molecular and soft tissue characteristics such as skin color, hair form, and facial features often allow unambiguous attribution of geographic ancestry among living people, the hard tissues display less-reliable signatures of ancestry. There are, in fact, no human skeletal markers that correspond perfectly to geographic origin. The problems in using discrete cranial and dental

Table 18.7 Useful cranial traits for determining ancestry

	Native Americans	European-Americans	African-Americans
<i>Incisors</i>	shovel-shaped	blade-form	blade-form
<i>Zygomatrics</i>	robust, flaring	small, retreating	
<i>Prognathism</i>	moderate	very limited	marked alveolar and facial
<i>Palate</i>	elliptic	parabolic	hyperbolic
<i>Cranial sutures</i>	complex	simple	simple
<i>Nasal spine</i>	medium, “tilted”	long, large	small
<i>Chin</i>	blunt, median	square, bilateral, projecting	blunt, median, retreating
<i>Ascending ramus</i>	wide, vertical		narrow, oblique
<i>Palatine suture</i>	straight	jagged	arched
<i>Zygomatic tubercle</i>	present		
<i>Incisor rotation</i>	present		
<i>Nasal profile</i>	concavo-convex	straight	
<i>Sagittal arch</i>	low, sloping		
<i>Wormian bones</i>	present		
<i>Nasals</i>	low, tented	highly arched, steeplelike	low, flat
<i>Nasal aperture</i>	medium		wide
<i>Zygomatimaxillary suture</i>	angled	curved	curved
<i>Dentition</i>		small, crowded	large molars
<i>Nasal sill</i>		very sharp	very dull or absent
<i>Nasion</i>		depressed	
<i>Cranial vault</i>		high	low
<i>Mandible</i>		cupping below incisors	
<i>Inion hook</i>		present	
<i>Postbregmatic depression</i>		present	

From Rhine (1990) and Gill (1995).

features to determine ancestry are perhaps best appreciated by considering what most osteologists agree is a racial marker: the shovel-shaped incisors seen in high frequency in modern Asian populations. A review and compilation of data on incisor shoveling by Mizoguchi (1985) show wide ranges of expressivity and incidence values in different extant human groups. Suffice it to say that incisors from Asian populations show a high incidence of shoveling, but also that the presence of shoveled incisors is hardly grounds for confident identification of a dentition as Asian.

The skull is the only part of the skeleton that is widely used in estimating geographic ancestry [but see İşcan and Cotton (1985) for a consideration of the pelvis as a racial indicator and Baker et al. (1990), Trudell (1999), and Gill (2001) for femoral techniques. Holliday et al. (1999) provide a discriminant function for multiple elements]. Even with this element, all workers agree that racial estimations are usually more difficult, less precise, and less reliable than estimations of sex, age, or stature. Despite decades of research, much more osteological work on geographic differentiation within *Homo sapiens* remains to be done and is urgently needed. Work on modern skulls of known origin has revealed certain tendencies.

Howells (1995) notes that the human species lacks well-defined subspecies but has clear local tendencies of variation. It is simply not possible to attribute every human cranium to one or another geographically defined group on the basis of its morphology or measurements—populations of the human species are morphologically too continuous for this. Howells conducted exhaustive and long-term studies on a selected sample of 2,504 human crania from around the world. He used 57 measurements on each skull and employed multivariate statistical techniques with a computer to show clearly that human variation in cranial shape, as represented by his measurements, is patterned and that “target” skulls of unknown ancestry could often be unambiguously placed in a parent “population.”

Compared to populations of African or European origin, Asian populations display skulls characterized by narrow, concave nasal bones, prominent cheek bones, circular orbits, and shoveled incisors. Compared to Asians and Europeans, African crania have been characterized as showing wide interorbital distances, rectangular orbits, broad nasal apertures with poor inferior definition, gracile cranial superstructures, and pronounced total facial and alveolar prognathism. European crania have been characterized as displaying narrow nasal apertures with sharp inferior borders (sills), prominent nasal spines, heavy glabellar and supraorbital regions, receding cheek bones, and large, prominent nasal bones.

Given the limitations of using such subjective criteria for recognizing geographical ancestry, some have turned to cranial metric methods for the assessment of racial status (Giles and Elliot, 1962; Howells, 1969b). One such attempt is that of Gill (1984, 1998), which addresses the problem of sorting European from Native American crania.

Gill (1995) provides a compendium of traits useful in assessing ancestry in an American context in his article “Challenge on the Frontier: Discerning American Indians from Whites Osteologically.” He notes that the Giles-Elliot discriminant function approach has been shown to be ineffective at sorting crania, particularly in the Northwestern Plains area where he works in both forensic and archaeological contexts. Gill considers races to be statistical abstractions of trait complexes, not pure entities or rigidly definable types. Table 18.7 is a list of useful traits of the teeth and cranium taken from his paper. See Tyrrell (2000) for another consideration and Edgar (2005) for a consideration of prediction of ancestry from dental anatomy.

The attention now being given to the origin of anatomically modern *Homo sapiens* in the later Pleistocene (Mellars and Stringer, 1989; White et al., 2003) should stimulate more work on skeletal differentiation within geographically separated populations of the species. Meanwhile, all of the techniques noted here, both visual and metric, should be applied only on adult remains and with comparative material. See Krogman and İşcan (1986), İşcan (1988), and Gill (1998) for further discussions on this topic.

18.7 Identifying the Individual

In paleontological and prehistoric archaeological contexts, fossils are sometimes given nicknames like ‘Dear Boy’ or ‘Lucy,’ but we will never know how members of their own species identified them. In historic archaeological contexts, it is possible that skeletal remains may be identified as unique individuals, such as named Egyptian pharaohs or people buried beneath headstones in historic cemeteries. In the forensic realm, the human osteologist is often presented with unidentified skeletal remains. The positive identification of human skeletal remains—the unequivocal matching of teeth, crania, or postcranial remains with unique, named individuals—is often the most important step in the analysis. The identification of sex, age, stature, and ancestry all narrow the windows of possible identification—possible matching—to known individuals (often missing or unaccounted for). The last step in the process of identification sometimes involves matching unique features of the “unknown” skeleton with unique characters of the “known” missing.

DNA analysis is the best method for testing hypotheses about the identity of skeletal remains. The general approach is to compare DNA from the skeleton with the DNA of the presumed relatives. For a number of variable regions of the DNA, the odds of a match between unrelated individuals are extremely low. Exactly how low is a matter of debate for cases involving blood samples from living individuals (Devlin et al., 1994), but in osteological contexts this is rarely, if ever, a concern. DNA typing has been used to identify skeletonized individuals in contexts involving mass deaths (the Branch Davidian incident in Waco, Texas: Houck et al., 1996), mass graves (Guatemala and former Yugoslavia: Boles et al., 1995; Primorac et al., 1996), remains of military personnel (Vietnam: Holland et al., 1993), war criminals (Josef Mengele: Jeffreys et al., 1992), and numerous forensic cases involving murder victims (*eg.*, Hagelberg et al., 1991; Sweet and Sweet, 1995). Even though the determination of familial relationships is most applicable in forensic or historical contexts, archaeological analysis of mortuary rituals and burial practices can often be advanced if the general relationships of the interred individuals can be established (Stone and Stoneking, 1993). Establishing the familial relationships between individuals in the same prehistoric population requires more detailed analysis than is usually attempted.

Fingerprint analysis, of course, is a means by which forensic specialists routinely match criminals with their crimes. As the soft tissue features of the body decay or are incinerated, however, the use of fingerprints, hair, and personal items to individuate the deceased becomes impossible. Teeth, the skeletal structures most resistant to such destruction, are often used to identify people in mass disasters. Such individuation via teeth and their modifications, usually by dentists, has traditionally been accomplished by **forensic odontologists**, specially trained experts accomplished at such identifications. Radiographs and other dental records kept by dentists are matched against modifications on the deceased’s teeth, often resulting in a positive identification (Kogon and MacLean, 1996).

Another means of establishing a positive identification on unknown skeletal remains is the comparison of those remains with medical radiographs taken when the individual was alive. Fractures, of course, can heal, but there are often trabecular and cortical points of identity through which a positive identification can be established. Postcranial skeletal characters (Owsley and Mann, 1992; Kahana et al., 1998) and frontal sinus morphology (Ubelaker, 1984; Kirk et al., 2002; Smith et al., 2002; Christensen, 2004) have been shown to be individually specific. The success of radiographic identification of unknown human remains, like that of many other techniques in human osteology, depends on the experience of the interpreter. Hogge et al. (1994) showed that the most-accurate identifications came from cranial remains and the cervical spine and chest, whereas the least-accurate identifications were made on the lower leg.

More recently, techniques that superimpose the skull of an unknown deceased individual on old photographs, motion pictures, or videotapes have been developed (Işcan and Helmer, 1993). Austin-Smith and Maples (1994) have tested the reliability of such superimposition methods and provide a good review of the techniques, limitations, and successes. When the anterior teeth are recovered with the skull and a smiling photograph with the teeth in focus is available, the shapes

of individual teeth and their relative positions are often distinctive enough for an identification to be made. Using only one photograph, Austin-Smith and Maples found a 9% chance of false identification, but when two photographs representing a difference of about 90° in the angle of the face to the camera were used for superimposition, the chance of false identification dropped to less than 1%.

A final means of personal identification based on skeletal remains involves forensic three-dimensional facial reconstruction. A series of techniques exists for the “restoration” of the soft tissue cover of a human skull (İşcan and Helmer, 1993; Neave, 2000). A recent review of the history of development and current status of such techniques by Tyrrell and colleagues (1997) notes that facial reconstruction still stands on the threshold between art and science. These authors conclude that current methods are useful, but insufficiently reliable to serve as evidence of positive identification in a court of law. Clement and Ranson (1998) provide a broad overview of craniofacial identification in forensic work and DeGreef and Willems (2005) review progress and prospects in this field.

Suggested Further Readings

Adams, B. J., and Byrd, J. E. (Eds.) (2008) *Recovery, analysis, and identification of commingled human remains*. Totowa, NJ: Humana Press. 374 pp.

This comprehensive, edited volume highlights case studies that illustrate individual identification, minimum number of individuals, and other commingling issues at mass-fatality sites using osteometric, radiological, and molecular methodologies.

Baccino, W., Ubelaker, D. H., Hayek, L. A. C., and Zerilli, A. (1999) Evaluation of seven methods of estimating age at death from mature human skeletal remains. *Journal of Forensic Sciences* 44: 931–936.

This paper reviews and evaluates common age estimation methods using 19 French autopsy individuals of known age at death.

Bennett, K. A. (1993) *A field identification guide for human skeletal identification* (2nd ed.). Springfield, IL: C. C. Thomas. 113 pp.

A compilation of tables of data useful in estimating sex, age, stature, and ancestry.

Caldwell, P. C. (1986) New questions (and some answers) on the facial reproduction techniques. In: K. J. Reichs (Ed.) *Forensic osteology: Advances in the identification of human remains*. Pp. 229–255. Springfield, IL: C. C. Thomas.

Discussion of the art and science of facial reproduction.

Gill, G. W., and Rhine S. (Eds.) (1990) *Skeletal attribution of race: Methods for forensic anthropology*. (Anthropological Paper No. 4). Albuquerque, NM: Maxwell Museum of Anthropology. 99 pp.

An edited volume with a variety of articles about identifying ancestry.

Hamilton, M. E. (1982) Sexual dimorphism in skeletal samples. In: R. L. Hall (Ed.) *Sexual dimorphism in Homo sapiens*. Pp. 107–163. New York, NY: Praeger.

A review of the problems and prospects for the use of skeletal material in estimating sexual dimorphism.

İşcan, M. Y. (1988) Rise of forensic anthropology. *Yearbook of Physical Anthropology* 31:203–230.

This review article traces the development of forensic anthropology and provides a wealth of citations.

İşcan, M. Y. (Ed.) (1989) *Age markers in the human skeleton*. Springfield, IL: C. C. Thomas. 359 pp.
This edited volume provides a variety of perspectives on the determination of age, from fetal life through adulthood, from various parts of the human skeleton and teeth. Its chapters, written by primary workers in the field of skeletal biology, summarize the limitations, advantages, and current status of various techniques used to determine skeletal age.

İşcan, M. Y., and Helmer, R. P. (Eds.) (1993) *Forensic analysis of the skull*. New York, NY: Wiley-Liss. 276 pp.
An edited volume with a variety of chapters covering aging, sexing and racing the skull, and principles and techniques of facial reconstruction.

İşcan, M. Y., and Kennedy, K. A. (Eds.) (1989) *Reconstruction of life from the skeleton*. New York, NY: Alan R. Liss. 315 pp.
This edited volume is a valuable sourcebook on a wide range of issues, including the assessment of sex, age, stature, and ancestry.

Krogman, W. M., and İşcan, M. Y. (1986) *The human skeleton in forensic medicine* (2nd ed.). Springfield, IL: C. C. Thomas. 551 pp.
This updated classic is an essential, comprehensive guide to making the estimations discussed above, particularly in forensic contexts.

Lovejoy, C. O., and colleagues. (1985) Eight papers on Todd and Libben skeletal material. *American Journal of Physical Anthropology* 68:1–106.
This collection of research papers illustrates work in both archaeological and forensic contexts.

Scheuer, L. and Black, S. (2000) *Developmental juvenile osteology*. San Diego, CA: Academic Press. 587 pp.
A comprehensive reference that is a must-have when doing any analysis of immature osteological material.

Ubelaker, D. H. (1987) Estimating age at death from immature human skeletons: An overview. *Journal of Forensic Sciences* 32:1254–1263.
A comprehensive review of the methods and limitations of age estimation for immature skeletal remains.

Ubelaker, D. H. (1999) *Human skeletal remains: Excavation, analysis, interpretation* (3rd ed.). Washington, DC: Taraxacum. 172 pp.
A concise guide to identification of the variables covered here, including valuable tables and charts.

Chapter 19

OSTEOLOGICAL AND DENTAL PATHOLOGY

AS WE HAVE LEARNED IN THE PRECEDING CHAPTERS, bones can and do vary greatly between individuals. This variation, as introduced in Chapter 3, stems from four main sources: age, sex, ancestry, and idiosyncrasy. Idiosyncratic variation includes nonpathological variation between individuals (for instance, variation due to stature or to slight differences in developmental timing) as well as nonmetric, nonpathological variations that are essential in reconstructing various biological dimensions of former human populations (see Chapter 21).

This chapter introduces a variety of biological processes that can result in skeletal modifications before death (**antemortem changes**). These processes can be biological (*eg.*, disease, genetic disorders), environmental (*eg.*, trauma, nutritional deficiencies), cultural (*eg.*, intentional deformation, surgery), or a combination of these. Cultural practices that take place just before or after death (**perimortem modifications**) are also examined. While these topics are all included, the discussion of skeletal modifications in this chapter focuses on pathological conditions. Chapter 20 examines some additional modifications, but there we concentrate on changes to the bone that occur after the death of the individual (**postmortem changes**). The most critical step in diagnosing and recording paleopathological conditions is the recognition of true bone abnormalities, as opposed to those within the normal range of variation in immature and adult healthy individuals. It is also vital to be able to distinguish between taphonomic and pathological alterations.

Paleoepidemiology is the study of factors affecting health and the risks of disease in past populations. Paleoepidemiology is concerned with only certain aspects of diseases: the cause(s), frequency, distribution, and transmission of a disease, as well as certain factors associated with the risks of contracting diseases. Waldron (1994) characterized paleoepidemiology as the attempt “to count the dead and their pathological signs in archaeological series, in order to reconstruct the spatial, temporal and social distribution of health and disease in past populations based on biocultural models.”

Paleopathology was defined by one of its pioneers as “the science of the diseases which can be demonstrated in human and animal remains of ancient times” (Ruffer, 1913). Whereas paleoepidemiology examines the ways in which diseases interact with *populations*, paleopathology is primarily concerned with the ways in which diseases interact with *individuals*. The scope of paleopathology has grown considerably since its earliest applications in archaeology (Ruffer, 1913) and paleontology (Shufeldt, 1893). In addition to diseases, paleopathologists also study trauma, antemortem cultural modifications of the skeleton and teeth, degenerative conditions, age-related bone loss, occupational indicators, and nutritional deficiencies and other signs of dietary stress. Paleopathology has had its own professional society for nearly 40 years (the Paleopathology Association), and will have its own international scientific journal, the *International Journal of Paleopathology*, in 2011.

The primary data of paleopathology are fossilized or skeletal remains, preserved soft tissues, and molecular evidence (see Chapter 22). Bones and teeth can be records of events during the life of an individual, including trauma and disease. Indeed, dramatic insights into the health of individuals, and of populations, may be gained from studies in osteological pathology. As Miller and colleagues (1996) note, the objectives of paleopathological research include diagnosing specific diseases in individual skeletal remains and examining the populational and evolutionary effects of these interactions between humans and the diseases that afflict them.

Pathological changes observable in osteological materials result from an imbalance in the normal equilibrium of bone resorption and formation, or from growth-related disorders. This imbalance can arise as a result of many factors, including mechanical stress, changes in blood supply, inflammation of soft tissues, changes brought about by infectious diseases, hormonal, nutritional and metabolic upsets, and tumors (Mensforth et al., 1978). Diagnosing the exact cause of an observed skeletal pathology is, however, not always possible. For example, an individual's growth may be interrupted by a range of factors that include infectious disease, starvation, and/or trauma. This growth arrest may lead to the formation of **Harris lines** in the long bones, lines of increased bone density that represent the position of the growth plate at the time of insult to the organism. The lines are visible radiographically, or in cross section, and may be used to estimate the age at which the individual was stressed.

Radiographic assessment is an essential component of describing and diagnosing disease in skeletal remains. Observations on different individuals may be combined to estimate the degree to which the population was stressed. From the Harris lines themselves, however, only general statements about the variety of possible stressors (including disease and diet) may be made (Maat, 1984; Hummert and Van Gerven, 1985). Furthermore, the lines may be removed by bone remodeling after they form. These Harris lines illustrate yet another problem common to comparative work in paleopathology. Macchiarelli and colleagues (1994) have shown that **interobserver error** may be high in radiographic interpretations, and even the scoring of the same radiographs by the same individual on different occasions (**intraobserver error**) can result in reported differences. Waldron and Rogers (1991) expressed similar concerns based on a study of interobserver variation in coding osteoarthritis in skeletal remains.

19.1 Description and Diagnosis

There are two stages involved in a paleopathological examination: describing the pathological manifestations and diagnosing the cause of these manifestations. Whereas historically an emphasis was placed on diagnosis (*eg.*, Steinbock, 1976), modern practice regards the full, accurate, and unambiguous description of pathological conditions as being of primary importance (Rose et al., 1991; Buikstra and Ubelaker, 1994).

Books by Steinbock (1976), Ortner and Putschar (1981), Ortner and Aufderheide (1991), Aufderheide and Rodríguez-Martín (1998), Ortner (2003), Mann and Hunt (2005), Roberts and Manchester (1995, 2007), Pinhasi and Mays (2008), and Waldron (2009) provide excellent guides to osteological pathology, and Lewis (2000) provides a status report on paleopathology for nonadults. Additional illustrations and techniques are found in Buikstra and Ubelaker (1994) and Lovell (2000). Hillson (2008) provides a review of dental pathology. The reader is urged to consult these sources when working with potentially pathological human skeletal remains. This chapter is intended to supplement these texts and is organized accordingly. It is designed to provide the reader with an introduction to the kinds of dental and osteological pathology encountered most commonly in work with prehistoric skeletal remains. All illustrated examples of osteological pathology are drawn from the Phoebe A. Hearst Museum of Anthropology, most of them from archaeological contexts. After examining 5,000 individuals in this collection, Richards and Antón (1987) note that over one-fifth showed anomalous development or the effects of pathological processes. Their data show that degenerative joint disease, periodontal disease, fracture, and osteomyelitis are the leading changes observed in this mostly prehistoric Californian collection.

19.1.1 Description

The first step in any paleopathological analysis is to establish the envelope of what is normal in size, shape, and topography for a healthy human's skeleton. When skeletal remains fall outside that envelope, pathology is one possible explanation. The basic steps are **description** and **diagnosis**. Diagnosis will rarely approach what is possible in the clinical setting because bone usually responds to insults by either resorbing or depositing, and it may therefore easily respond to different diseases in very similar ways. Description is the most important step in paleopathological work because even if the subsequent diagnosis is incorrect, other workers can come along later and amend or modify the diagnosis.

In any description, identify the nature and distribution of anomalies across the skeleton and observe the pattern of distribution of these anomalies across the population. These anomalies can take the form of lesions or of changes in size or shape. Note the distribution of all lesions, whether single, multiple, diffuse, or concentrated. Note whether bone is eaten away (**lytic**) or deposited (**blastic**). Check all bones of the skeleton for further evidence, and verify that the alteration is not taphonomic (Chapter 20), a nonpathological anatomical variant, or some other example of “**pseudopathology**.”

Pathological conditions have been organized in a number of different ways, according to the type of work being done (*eg.*, data gathering vs. analysis), the type of data examined (*eg.*, gross anatomical vs. histological vs. genetic), the subset of data being examined (*eg.*, skeletal manifestations), and/or the conceptual framework into which the data are placed (*eg.*, evolutionary vs. etiological vs. symptomatological). The World Health Organization's most recent *International Statistical Classification of Diseases and Related Health Problems* (World Health Organization, 2007) is the comprehensive standard for pathology. Paleopathologists usually use much simpler classification schemes. Two particular classifications are of special interest to paleopathologists — one to guide description and data collection, and the other to assist in diagnosis.

Buikstra and Ubelaker (1994: 112–115), building on the work of Rose et al. (1991), advocate the division of paleopathological changes into nine categories for the purpose of data collection: (1) abnormalities of shape, (2) abnormalities of size, (3) bone loss, (4) abnormal bone formation, (5) fractures and dislocations, (6) porotic hyperostosis/cribra orbitalia, (7) vertebral pathology, (8)

1.0.0 General abnormality of shape (long bone)	1.5.4 Lambdoid
1.1.0 Bowed (abnormal curvature)	1.5.5 Other (see narrative)
1.2.0 Angulated	1.6.0 Craniosynostosis, completeness
1.3.0 External outline altered	1.6.1 Partial
1.3.1 Flaring metaphyses	1.6.2 Complete
1.3.2 Uniformly abnormally wide	1.0.0 General abnormality of shape (vertebrae)
1.3.3 Fusiform (spindle) shape	1.7.0 Type
1.3.4 Other (see narrative)	1.7.1 Kyphosis (ant.-post.)
1.4.0 Degree of shape abnormality	1.7.2 Scoliosis, left
1.4.1 Barely discernible	1.7.3 Scoliosis, right
1.4.2 Clearly discernible	1.8.0 Form
1.0.0 General abnormality of shape (skull)	1.8.1 Angular
1.5.0 Craniosynostosis, suture	1.8.2 Gradual change in body height
1.5.1 Metopic	1.9.0 Ankylosis
1.5.2 Coronal	1.9.1 Absent
1.5.3 Sagittal	1.9.2 Present

Table 19.1 Examples of paleopathology data collection codes. From Buikstra & Ubelaker (1994).

arthritis, and (9) miscellaneous conditions. For each of these categories, Buikstra and Ubelaker present a number of clearly defined generic and specific findings. Using this system, every pathological feature is recorded as a combination of one or more observation codes (see Table 19.1) with one or more bone and side codes, with codes for aspect and section used as needed. It is important to note that Buikstra and Ubelaker's system is intended only for description, not for diagnosis.

19.1.2 Diagnosis

When trying to formulate a diagnosis, the osteologist is at a decided disadvantage compared to the forensic pathologist or clinician. Whereas a clinician can monitor progress of a disease in a patient, the paleopathologist is limited to the static appearance of the skeleton at the time of death. Furthermore, in the majority of paleopathology cases, diagnosis is necessarily based on gross appearance and radiology. In contrast, the clinician diagnosing disease in a living patient can assess patient history, soft tissue, chemistry, pathogens, and pain. It follows that paleopathological diagnoses based on skeletal lesions will rarely have the precision routinely encountered in clinical settings. Developments in genetics, biochemistry, and molecular biology, however, are opening new doors for the paleopathologist.

Techniques and methods available for paleopathological diagnosis include (in addition to gross anatomy) histology, radiography, computed tomography, microradiography, scanning electron microscopy, chemical analysis, serology, and genetic sequencing.

A number of diseases are genetic in nature and can potentially be detected in past populations using DNA analysis. Disease processes characterized by long-term infection by substantial densities of viral or bacterial pathogens might also be detected through recovery of the DNA of the pathogen. As yet, very few studies of paleopathology have utilized DNA analysis, in large part due to the difficulty of avoiding contaminant DNA from living humans. Whereas the DNA of ancient humans is difficult to isolate, it is a relatively straight-forward process to isolate the DNA of infectious pathogens, so most genetic analyses have focused there. Most work to date has been done on tuberculosis, amplifying the DNA of *Mycobacterium tuberculosis* (Braun et al., 1998; Donoghue et al., 1998; Fletcher et al., 2003; Hass et al., 2000; Mays et al., 2001; Spigelman et al., 2002), but leprosy (Haas et al., 2000; Montiel et al., 2003; Taylor et al., 2000), malaria (Salares and Gomzi, 2001), plague (Drancourt et al., 1998; Raoult et al., 2000), and syphilis (Kolman et al., 1999) have also received attention. Roberts and Ingham (2008) take a critical look at DNA analysis in paleopathology, finding that a majority of the genetic studies done did not follow established standards for such work. Bouwman and Brown (2005) also express concern over the lack of rigorous validation of results in some DNA analyses in paleopathology.

Unfortunately for paleopathologists, few diseases leave signatures of any kind on the human skeleton, and those that do may cause very similar skeletal reactions. The only real advantage that the osteologist has in studying pathology is the ability to study the entire skeleton at once, without soft tissue cover. For these reasons, Steinbock (1976) suggested that the most rational approach to differential diagnosis in human skeletal pathology is to state the most likely diagnosis followed by a list of possible alternatives in order of decreasing likelihood.

As Miller et al. (1996) note, there are two major impediments to paleopathological diagnoses. First, there is a paucity of well-documented, clinically diagnosed skeletal samples to use as controls against which unknown skeletal samples (forensic, archaeological, or paleontological) may be compared. The second problem lies with the difficulty in finding skeletal abnormalities, or patterns of abnormalities, that are unique to individual disease categories. Miller et al. (1996) suggest that paleopathologies be diagnosed and classified in one of seven categories: (1) anomaly, (2) trauma repair, (3) inflammatory/immune, (4) circulatory (vascular), (5) metabolic, (6) neuro-mechanical, or (7) neoplastic (cancers). In a series of blind tests, however, these authors found that even trained specialists working on skeletal remains only achieved accuracies of about 43% at this broad diagnostic level, while only about 30% of more specific diagnoses were accurate.

19.2 Skeletal Trauma

The most common pathology affecting the skeleton is degenerative change. Trauma occupies second place and affects the skeleton in several ways — fracturing or dislocating the bone, disrupting its blood or nerve supply, or artificially deforming it. For illustrations of trauma to osteological remains, see White (1992) and the FOROST visual metabase and other online resources (Appendix 3). Ortner (2003) divides skeletal trauma into four general types: (1) a partial to complete break in a bone, (2) an abnormal displacement or dislocation of a joint, (3) a disruption in nerve and/or blood supply, or (4) an artificially induced abnormal shape or contour of a bone. Skeletal trauma can be the result of an accident, interpersonal violence, cultural practice, or therapeutic treatment. Martin and Frayer (1997) give examples of how studies of osteological trauma have been employed to investigate violence and warfare in the past. Lovell (2008) provides a recent overview of research on skeletal trauma.

19.2.1 Fracture

Fractures of bones can occur for numerous reasons, most often as a result of sufficiently strong abnormal forces of tension, compression, torsion, bending, or shear applied to a bone. The terms used to describe fractures are equally wide-ranging, especially in the field of medicine. Commonly recognized fracture types and terms are mentioned here. Exploring the myriad of different types of fractures and their causes is beyond the scope of this work. Refer to Table 19.2 for a list of common fractures and brief descriptions of the trauma.

A fracture in which broken ends of a bone become separated is called a **complete fracture**. If the discontinuity does not bifurcate the bone, it is an **infraction**, or **incomplete fracture**. In a **compound** (or **open**) **fracture**, part of the broken bone perforates the skin. The skin remains intact in a **simple** (or **closed**) **fracture**. Additional types of fractures related to these four main categories are listed in Table 19.2.

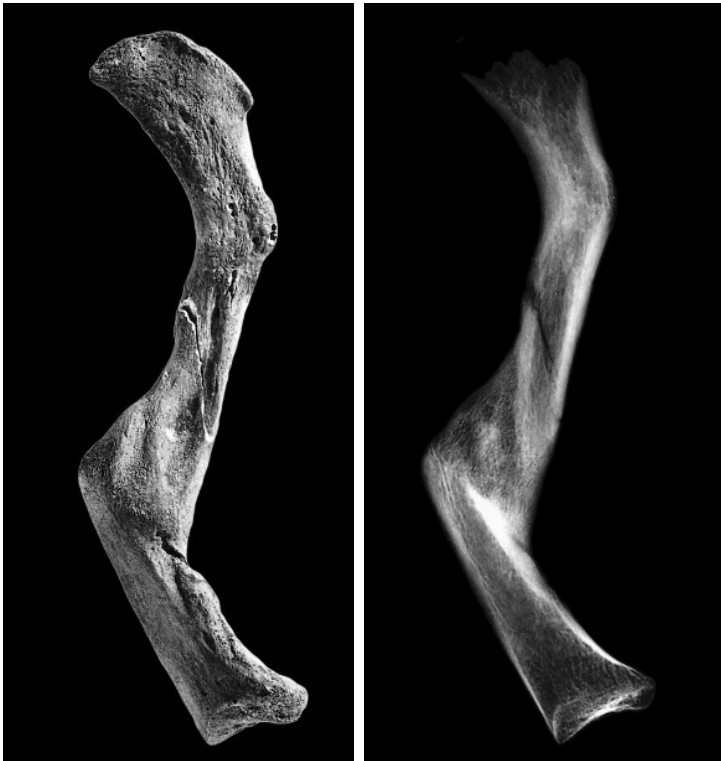

Figure 19.1 Healed fracture. This left clavicle shows a postmortem fracture (the light-colored bone around the crack visible in this inferior view) and a more medial antemortem fracture that has healed. The original shaft surfaces are joined by a bony callus. The radiograph shows that the medial end of this clavicle rotated counterclockwise relative to its lateral end, resulting in a dramatic misalignment of the fractured pieces during and after healing. Prehistoric, California. One-half natural size.

Table 19.2 Useful terms for describing fractures

Forces	
tension	stress that produces elongation, stretching
compression	pressed together, typically affecting the spine
torsion	twisting
bending	deformation from a normally straight condition, but not to the point of breaking
shearing	forced applied to the side of an immobilized bone segment
dynamic	sudden stress with power and velocity
static	slowly applied stress
narrow focus	stress applied at a point or line
wide focus	stress applied over a large area
Fractures (main categories)	
complete	a bone breaks into separate pieces
transverse	a clean, square break perpendicular to the bone's long axis
linear	a fracture along the bone's long axis.
oblique	clean break diagonal to the bone's long axis
displaced	broken ends are separated producing a fracture gap, often left at an angle from normal (angulation)
nondisplaced	a complete fracture with the broken bone remaining in its normal position and alignment
compressed	bone tissue collapses (common in vertebrae)
incomplete (infracture)	a crack, bend, or break with fragments remaining partially joined, but not a complete break (no separation)
greenstick	the bone bends on one side and breaks on the other like a bent green tree branch (most common in children)
torus (buckle) fracture	the bone bends producing a raised buckle on one side, but no break on the other side.
compound (open)	the break goes through the skin (and may recede back)
closed	the fracture does not pass through the skin
Other Fracture Types	
pathological	when bone is weakened or made brittle by disease (osteoporotic, infection, cancer, noncancerous tumor)
fatigue	when bone is exposed to [intermittent] stress over a long period.
stress	cracks in the bone caused by repeated strain and overuse
avulsion	small piece of bone detaches where ligaments and tendons attach
simple (single)	a single discontinuity along one line produces two bone segments
segmental	a long bone broken in two or more places
comminuted (multi-fragmentary)	the break produces several (three or more) pieces of bone or fragments
spiral	a torsion fracture caused by twisting
depressed	pushed in with fragments of bone depressed below the adjacent surface
diastatic	a widening or separation of the cranial bones at the sutures
basilar	a bone break at the base of the skull
hinge	a peeling or flap of bone, still attached at one side, caused by a sharp force across the cortical surface of bone
impacted/compacted	broken fragments are embedded into each other
cleft	a V-shaped notch caused by a near vertical force applied by a heavy instrument with a sharp edge
fracture lines:	
radiating	fracture lines spreading outward from an impact point where a force was applied
concentric (hoop)	fracture lines occurring in concentric rings around the area of applied force
LeFort fractures of the face	
I	separation of the alveolar part of the maxilla between the alveolar ridges and the frontal processes
II	separation of the mid-face from the rest of the cranium
III	the entire face is separated from the braincase
Types of Trauma	
blunt force (BFT)	injury due to a force with a wide area of impact
sharp	a compressing or shearing dynamic strike with a narrow focus
projectile	a combination of blunt and sharp characteristics
sawing	cutting bone with a toothed instrument
heat	discontinuities caused by the effects of heat on tissue
chemical	physical damage caused by toxic substances; immediate as in a chemical burns, or poisoning over time

Fractures of bones are often described by the features of the break itself: **comminuted** when there is shattering of bone; **compressed** when the bone is squeezed; or **depressed** when bone fragments are depressed below the adjacent surface. Pathological or metabolic conditions such as osteoporosis and cancer weaken bone and can lead to a **pathological fracture**. Several possible types of gross fracture in a bone may result from this abnormal stress (Figures 19.1 and 19.2).

Characteristics of bone trauma caused by a striking object vary depending on the type of bone involved and the features of the object. Fracture margins may reveal information regarding the nature of the force that caused the fracture. The result of a blunt object impacting bone is different from a fracture caused by a stabbing action with a sharp object. Some fractures are caused by forces applied in one location that radiate or become concentrated elsewhere. For example, diastatic fractures occur along cranial sutures and may be caused by stress dissipating across the skull due to forces applied at a different location.

Fracture healing is described in Chapter 3. Antemortem fracture may be differentiated from postmortem fracture only when a **callus**, the hard tissue formed at the site of a broken bone during the healing process, is present. All other fractures that occur at or around the time of death should be diagnosed as perimortem. Complete fracture healing can completely remove any gross signs of fracture, even in a radiograph. The rate of fracture repair depends on fragment alignment, the amount of movement at the site of fracture, and the health, age, diet, and blood supply

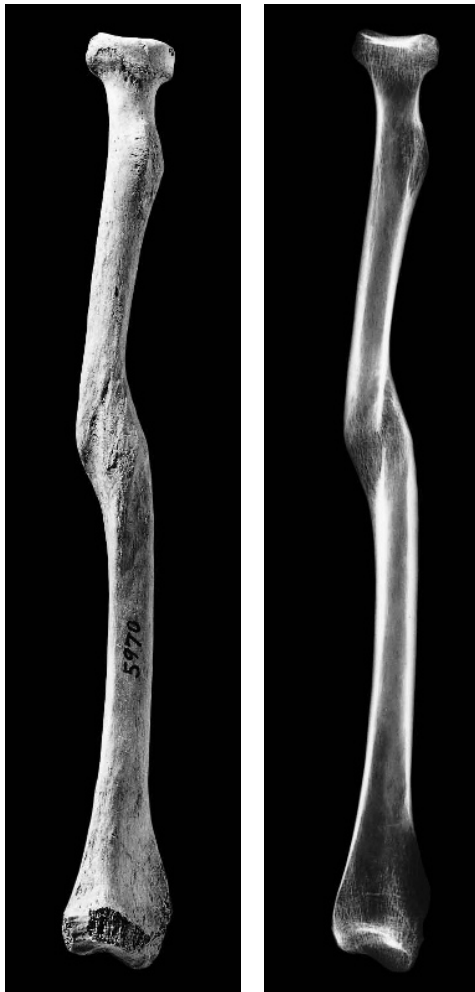

Figure 19.2 Healed fracture. (*Left*) This left radius has a healed midshaft fracture. The radiograph shows that the fracture offset is about equal to the width of the bone. The proximal part of the bone is offset posteriorly. Prehistoric, California. One-half natural size.



Figure 19.3 Pseudarthrosis. (*Right*) This left humerus was broken just above the midshaft. The fracture failed to heal (a nonunion), resulting in continued movement, which formed the false joint. Prehistoric, California. One-half natural size.

of the individual. Some fractures never heal because of continued movement at the broken surface. Nonunions develop most frequently in the appendicular skeleton. It is possible that a new “joint,” or **pseudarthrosis**, will form at the fracture site (see Figure 19.3).

Trauma such as sword cuts or arrow perforations to bones constitute special kinds of fractures. Such wounds are capable of healing through the same processes described in Chapter 3. In any kind of fracture, adjacent bone is susceptible to subsequent pathological complications such as infection, tissue death, deformity, and arthritis brought on by the initial trauma.

The analysis of fractures at the populational level can be very informative in addressing questions of prehistoric behavior. For example, Lovejoy and Heiple (1981) assessed the Libben population and found that the overall fracture rate was high. The low incidence of fractures in children suggested that traumatic child abuse was not practiced. The results of their analysis also suggested that fracture risk was highest in the 10–25 and 45+ age categories and that the care of patients was enlightened and skillful among this Native American group. Andrushko et al. (2005) investigate the practice of trophy-taking by means of partial dismemberment. Jurmain et al. (2009) examine the skeletal evidence for interpersonal violence in prehistoric California, finding craniofacial trauma and projectile injury more reliable indicators than forearm injury.

19.2.2 Dislocation

In addition to causing bone fracture, trauma to the skeleton can also involve movement of joint participants out of contact with the simultaneous disruption of the joint capsule. If the bones participating in the joint remain dislocated, the result may be diagnosed osteologically (Figure 19.4). When the joint is dislocated, the articular cartilage cannot obtain nourishment from the synovial fluid, the cartilage disintegrates, and arthritic changes occur. Osteological manifestations of dislocation are usually confined to adults. The violent trauma necessary for dislocation usually separates the epiphyses in subadults, and slipped femoral epiphyses are common in juveniles. In the elderly, the more brittle bone usually gives way, fracturing prior to dislocation. The two joints most often displaying osteological manifestations of dislocation are the shoulder and hip joints.

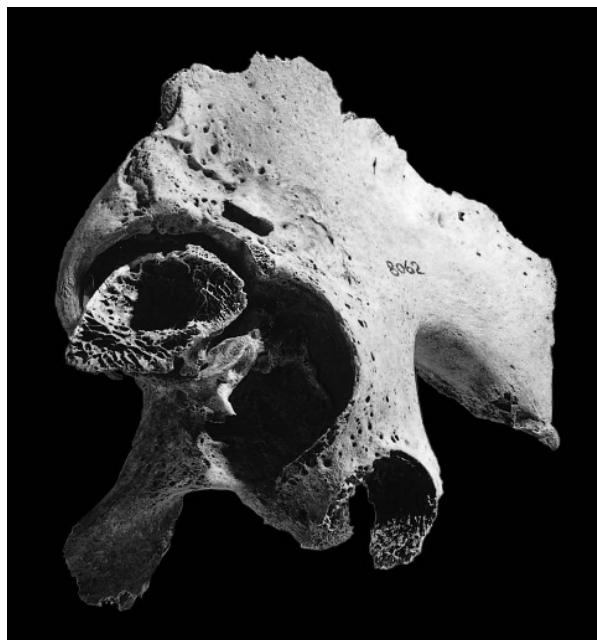


Figure 19.4 Dislocation. This left hip joint shows that the femoral head dislocated anterosuperiorly from its original place within the acetabulum. The cross section of the femoral neck is seen in the postexcavation break, which faces the viewer. Osteoarthritis secondary to the trauma is evident. Prehistoric, California. One-half natural size.

19.2.3 Vascular Disruption

When the blood supply to a bone is upset by trauma or other diseases, a variety of bony manifestations can occur, including death of bone tissue (**osteonecrosis**). See Section 19.4 for examples of pathologies that can result from vascular disruption.

19.2.4 Artificially Induced Shape Changes

In addition to accidental trauma, there are also several types of intentional trauma. Bone shapes can be modified by the application of long-term compressive forces, as with artificial cranial deformation and foot binding. Certain therapeutic procedures can also modify a bone's shape, as can some punitive measures.

- a. **Artificial Deformation.** Fracture and dislocation described earlier result from sudden trauma to the skeleton, but sustained mechanical stresses can also modify the shape of a bone. Deformities of this kind are induced most often as a result of cultural practices such as cradleboarding, massaging, or binding the crania of infants. Another example is the foot-binding practiced by Chinese women of high status. The most common manifestations of artificial deformation of the skeleton are those of the cranium. Cultures around the world have, for cosmetic reasons, altered the shape of the adult head by placing abnormal pressures on the developing skull. Ortner and Putschar (1981) describe this practice by people on every continent except Australia, but Brown's (1981) work there suggests that the practice was continentally ubiquitous. Both cultural and biological information can come from the analysis of intentionally deformed crania. For example, Antón (1989)

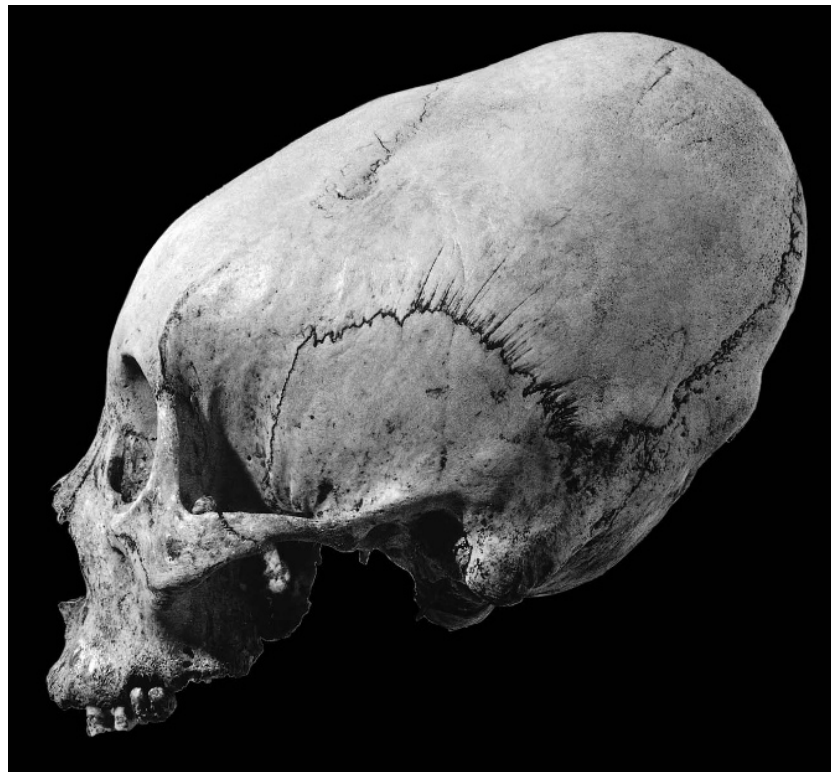

Figure 19.5 Artificial cranial deformation. Circumferential deformation is produced by wrapping the rear of the cranial vault. Prehistoric, Peru. One-half natural size.

has used intentional anteroposterior and circumferential cranial vault deformation in a Peruvian sample to study the relationship between the cranial vault and the base in the development of the craniofacial complex. O'Loughlin (2004) notes the effect of cranial deformation increasing wormian bone number. Some examples of artificial cranial deformation are illustrated in Figures 19.5 and 19.6.

- b. **Trephination.** Ortner and Putschar (1981) describe **trephination**, or **trepanation**, as perhaps the most remarkable trauma encountered by the paleopathologist (Figure 19.7).

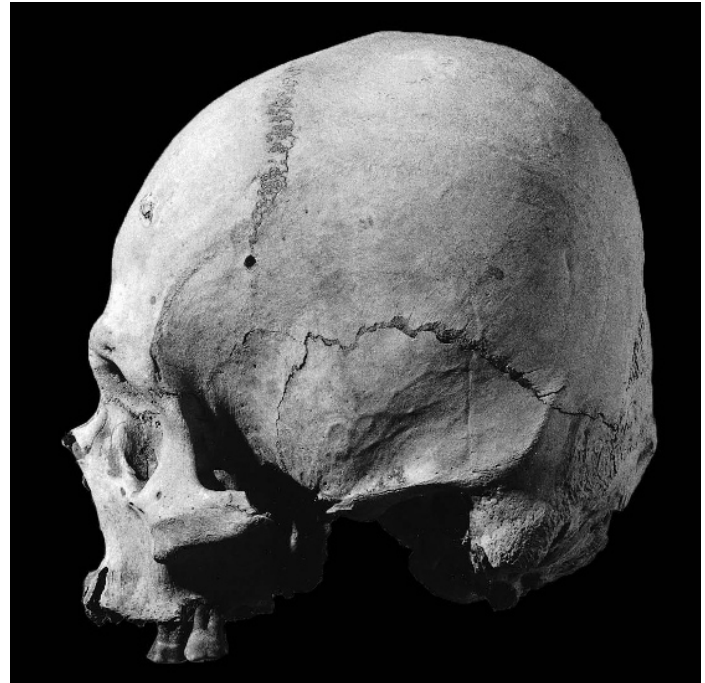

Figure 19.6 Artificial cranial deformation. Anteroposterior deformation is caused by the application of pressure from behind. Prehistoric, Peru. One-half natural size.

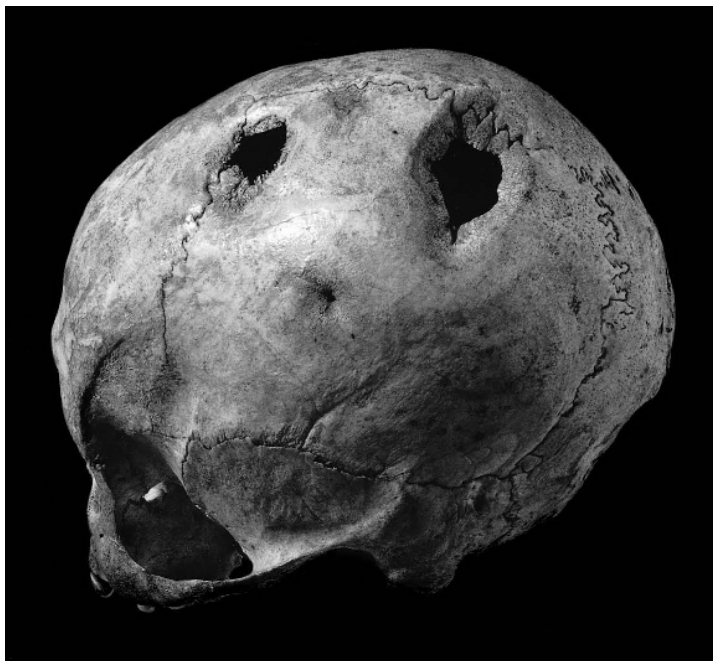

Figure 19.7 Trephination. Three artificially produced holes are evident on this three-quarter view of a cranium. The hole closest to the parietal boss is nearly completely obliterated by healing. The other holes also show substantial bony healing, indicating that the individual survived the operations. Prehistoric, Peru. One-half natural size.

Written accounts documenting this practice extend to the ancient Greeks, but archaeological work has traced it even more deeply into the past. The practice is known from Europe, the Pacific, both Americas, Africa, and Asia. Several techniques have been used to make an artificial hole in the cranial vault, including scraping a patch of bone away, cutting a bone patch out by cutting grooves through the vault, and drilling small holes around the plug of bone to be removed. The practice was probably undertaken to yield relief from intracranial pressure (especially from compressive fractures of the skull vault) and to relieve headaches, cure mental illness, or let out evil spirits. The success rate for this prehistoric surgery, as judged by subsequent healing around the hole, was often surprisingly high. Some postmortem trephination was done to fashion amulets for the adornment of survivors. Arnott et al. (2003) provide an overview of trephination, and Andrushko and Verano (2008) examine trephination in ancient Peru.

- c. **Amputation.** Evidence of amputation may be observed on the skeleton in the form of missing appendages or parts of appendages. Distinguishing antemortem from perimortem amputation, again, depends on the presence of healing or infection of the bone tissue at the point of trauma. Andrushko et al. (2005, 2010) investigate the practice of perimortem amputation and dismemberment in the context of trophy-taking.

19.3 Congenital Disorders

Congenital disorders result from developmental anomalies in, or damage to, a fetus. Causes of congenital disorders vary: genetic or chromosomal abnormalities, *in utero* environmental variables, and errors of morphogenesis are some of the possible factors.

19.3.1 Cranial Malformations

- a. **Craniosynostosis.** Craniosynostosis is a general term that refers to the premature fusion of one or more cranial sutures. The resulting shape of the cranium depends on the sutures involved as well as the order in which the sutures fuse. There are several specific, named types of craniosynostosis. **Plagiocephaly** results from asymmetric suture closure and results in a “lopsided” appearance for the cranium. **Scaphocephaly** is the most common form of craniosynostosis (Aufderheide and Rodríguez-Martín, 1998), resulting from premature fusion of the sagittal suture.
- b. **Microcephaly.** Microcephaly refers to an abnormally small neurocranium. In individuals with microcephaly, an abnormally low brain volume relaxes the need for a large endocranial space, resulting in a small neurocranium with a normal-size face. Richards (1985) describes a microcephalic child from prehistoric California.
- c. **Hydrocephaly.** Hydrocephaly is a consequence of chronically increased intracranial pressure during childhood, resulting in a large, globular cranium, thin cranial vault bones, and bulging fontanelles. Richards and Antón (1991) describe a case of hydrocephaly from prehistoric California.

19.3.2 Vertebral Malformations

- a. **Spina bifida.** When the two halves of the neural arch fail to fuse, the vertebral canal is left exposed, a condition called spina bifida. Spina bifida can occur at any level of the vertebral column, but is most common in the sacrum. Non-fusion of the lower sacral vertebrae is considered normal; only non-fusion of S-3 or any superior vertebra is considered spina bifida.

- b. **Scoliosis.** Scoliosis refers to a lateral deviation of the vertebral column from the midsagittal plane. Scoliosis usually involves two abnormal curvatures, allowing the head to remain vertical and close to the midline.
- c. **Kyphosis.** Kyphosis is an abnormal increase in the anterior curvature of the thoracic spine. Kyphosis can be primary (changes in the geometry of the intervertebral disks) or secondary (changes in the geometry of the vertebral bodies themselves). Kyphosis can occur as a result of any of a number of conditions, including osteoporosis, tuberculosis and other infectious diseases, multiple myeloma, osteomalacia, and acromegaly (Ortner, 2003).

19.3.3 Other Congenital Malformations

In addition to the cranial and vertebral malformations just listed, there are many other congenital conditions that affect the skeleton: absences of elements (aplasias), and incompletely developed elements (hypoplasias), clefts (*eg.*, cleft palate, bipartite patella), abnormal geometries (*eg.*, coxa vara), and supernumerary elements (*eg.*, cervical ribs, polydactyly), are congenital conditions affecting the skeleton. Chapter 4 of Aufderheide and Rodríguez-Martín (1998) provides a good review of these and other congenital anomalies.

19.4 Circulatory Disorders

When the blood supply to a bone is disrupted, whether by trauma or other diseases, a variety of bony manifestations can occur. If the blood supply to a bone is gradually reduced, the bone will atrophy but will usually survive. If the blood supply is suddenly cut off, the affected bone tissue will become necrotic. **Osteochondroses** are joint diseases involving interruption of the blood supply (usually to an epiphysis), localized necrosis, and subsequent regrowth of the bone.

19.4.1 Osteochondritis Dissecans

In younger adults, localized trauma to long bone joint surfaces can result in the avulsion of small areas of subchondral bone. Osteochondritis dissecans is most commonly observed on the distal femur (especially the medial condyle), proximal talus, distal humerus (especially the capitulum), proximal ulna, humeral head, and patella. After the trauma, localized necrosis sets in, eventually causing the affected subchondral bone to separate. The resulting pit exposes the underlying trabecular bone, but a local sclerotic reaction eventually lines the pit with a new surface of bone.

19.4.2 Legg-Calvé-Perthes Disease

In Legg-Calvé-Perthes (LCP) disease, the blood supply to the femoral head epiphysis is disrupted. Whether this disruption is a result of trauma or of some other cause(s) is currently unknown (Wainwright and Catterall, 2010). While the femoral head atrophies due to necrosis, the femoral head's articular cartilage continues to grow, as its nutrition comes from synovial fluid, not the femoral head. Because of the necrosis, the femoral head becomes flattened and uneven at its margins. Once the blood supply is re-established, the femoral head begins to heal and grow, although usually maintaining its deformed shape. LCP disproportionately affects boys and Caucasians, and appears to be related to poor living conditions (Wainwright and Catterall, 2010). The onset of LCP is usually between 4 and 7 years, but the deformity persists through life.

19.5 Joint Diseases

Diseases of the joints are typically organized into two broad categories: bone-forming joint lesions (*eg.*, osteophytes, syndesmophytes), and bone-eroding joint lesions (*eg.*, eburnation) (Ortner, 2003). These categories, although sometimes useful, can be somewhat misleading, as there are types of bone-forming joint lesions that result in bone erosion and vice versa (Aufderheide and Rodríguez-Martín, 1998).

19.5.1 Osteoarthritis

Arthritis is the inflammation of a joint—a general inflammation that includes soft tissue effects. The inflammation can come as a result of trauma as well as of bone and joint infections (see Rogers et al. [1987] for a summary and classification). **Osteoarthritis**, the most common form of arthritis, is characterized by destruction of the articular cartilage in a joint and formation of adjacent bone, in the form of bony lipping and spur formation (**osteophytes**) around the edges of the joint. A better term for this phenomenon is **degenerative joint disease** (Figures 19.8–19.10). The causes of this disease are, for the most part, mechanical. The disease occurs mostly in load-bearing joints, particularly in the spine, the hip, and the knees. Osteoarthritis is an inherent part of the aging process. For a review of current knowledge about osteoarthritis, consult Epstein (1989), and for a review of prehistoric arthritis in the Americas, see Bridges (1992).

Osteoarthritis is usually classified as either primary, resulting from a combination of factors that include age, sex, hormones, mechanical stress, and genetic predisposition, or secondary, initiated by trauma or another cause such as the invasion of the joint by bacteria (**septic**, or **pyogenic arthritis**—often a complication of osteomyelitis). Studies of the patterning of osteoarthritic lesions of the skeleton at the individual and at the population level can shed light on prehistoric activity patterns. For example, Merbs (1983) was able to show that osteoarthritic changes seen in female Hudson Bay Inuit skeletons correlated with ethnographic accounts and archaeological evidence for scraping and cutting animal hides and sewing, whereas lesions seen in males correlated with harpoon throwing and kayak paddling.

A phenomenon often found associated with osteoarthritis is **eburnation**, the result of subchondral bone being exposed when cartilage is destroyed. Bone affected this way takes on a polished, ivory-like appearance (Figure 19.9). The projecting spicules of bone associated with osteoarthritis are called **osteophytes**. Nearly all individuals older than 60 years exhibit these arthritic features, especially in the lower thoracic and lumbar regions. Rogers et al. (1987, 1989) assess classifications of osteoarthritis, and Bridges (1993) notes that the scoring procedures used to record the disease seriously affect the results of any comparative study.

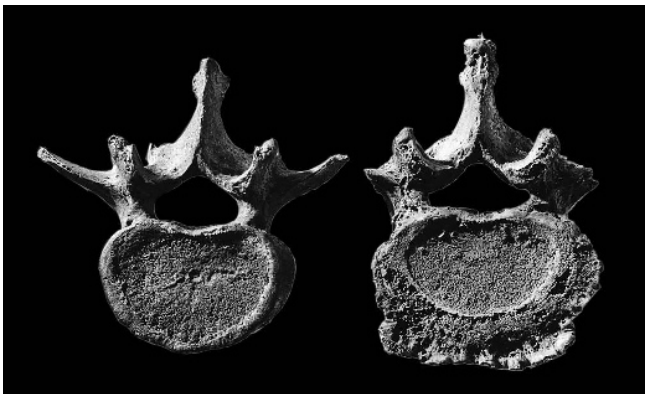


Figure 19.8 Osteoarthritis. The normal lumbar vertebra (left) lacks the osteophyte development seen on the anterior and lateral edges of the vertebra with degenerative arthritis (right). Prehistoric, California. One-half natural size.

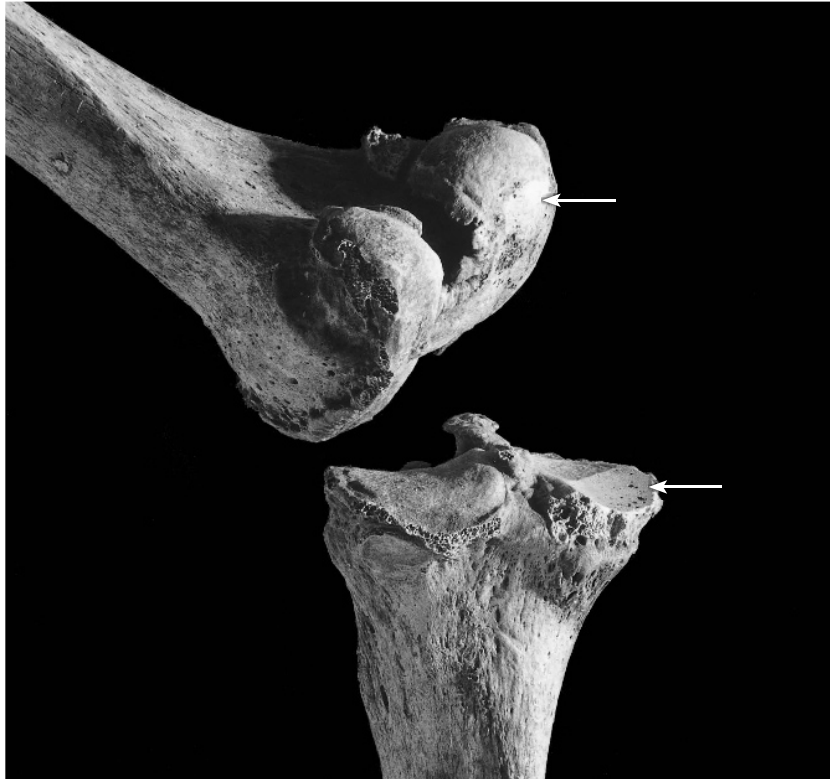

Figure 19.9 Osteoarthritis. Eburnation and marginal lipping are evident on this left knee joint, seen here in posterolateral view and lit from the lower right to show detail. The eburnation is the ivory-like, shiny patch on the medial femoral and tibial condyles. Prehistoric, California. One-half natural size.

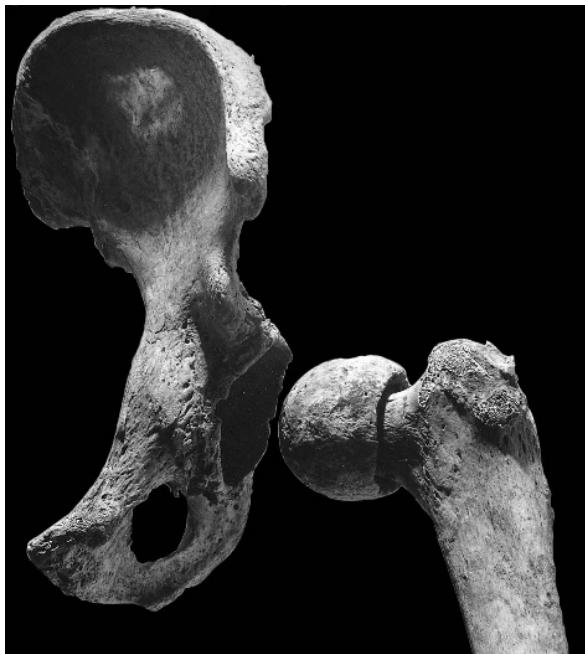

Figure 19.10 Osteoarthritis. Trauma to this left femur produced secondary osteoarthritic changes to the joint, seen here in the form of a bony extension and deformation of the femoral head and a buildup of osteophytes around the perimeter of the acetabulum. Prehistoric, California. One-third natural size.

19.5.2 Diffuse Idiopathic Skeletal Hyperostosis (DISH)

Diffuse idiopathic skeletal hyperostosis (DISH), while not a true joint disease—it doesn't involve any of the intervertebral synovial joints—is usually considered together with joint diseases. DISH involves the ossification of the lateral fibers of the anterior longitudinal spinal ligament. The result is smooth-surfaced bony bridges between adjacent vertebrae that create a “dripping candle wax” appearance. To be considered as DISH, these bony bridges must span at least 4 adjacent vertebrae on their anterolateral aspects. Unlike ankylosing spondylitis (see Section 19.5.4), DISH affects the anterior portions of vertebral bodies and leaves the intervertebral disk spaces and articular facets unaffected.

19.5.3 Rheumatoid Arthritis

Middle-aged women have a predisposition for this arthritis. Its exact cause remains unknown but almost certainly varies with genetic background. In rheumatoid arthritis, the immune system of the body attacks its own cartilage. Bone changes are atrophic and are especially focused in the hands and feet. The lesions are usually bilaterally symmetrical. Rheumatoid arthritis is the least common arthropathy in archaeological skeletal material. Woods and Rothschild (1988) argue that it is evidenced in New World skeletal remains, and Rothschild et al. (1990) propose recognition criteria for skeletal remains.

19.5.4 Ankylosing Spondylitis

An **ankylosis** is an abnormal immobility or fixation of a joint resulting from pathological changes in the joint. **Ankylosing spondylitis** (also called rheumatoid arthritis of the spine) is a chronic and usually progressive disease that affects the vertebral column. Ankylosing spondylitis begins in the region of T-12/L-1 and involves the ossification of the periphery of the annulus fibrosus, forming symmetric **syndesmophytes** (a bony outgrowth at the margin of a joint) between adjacent vertebrae, leading to the eventual immobilization of the intervertebral joints. Ortner (2003) notes that smooth ankylosis of the sacroiliac joint is common, as are syndesmophytes at the articular facets and costovertebral facets. Onset of ankylosing spondylitis can occur at any time from childhood onwards, but usually occurs between 20 and 40 years (Feldkeller et al., 2003).

19.6 Infectious Diseases and Associated Manifestations

Infectious disease has long been a major cause of death in human populations. Unfortunately, dealing with osteological evidence of infectious disease can be frustrating because few infectious diseases leave any direct evidence of their existence in the skeleton. Many of the chronic infectious diseases that *do* leave osteological signs produce morphologically overlapping responses, making differential diagnosis impossible.

Osteitis is a general term for an inflammation of bone tissue caused by infection or injury and is not specific as to cause. The terms **osteomyelitis** and **periostitis** are slightly more confusing because they serve to generally describe osteological conditions as well as to identify specific diseases. Periostitis is a symptom in disease syndromes such as syphilis, but it is also a common condition that can be result from many other diseases, including some that are not infectious diseases (Ortner, 2003). Because of their non-specific nature, caution should be exercised in diagnosing periosteal lesions on incomplete archaeological skeletons (Weston, 2008, 2009).

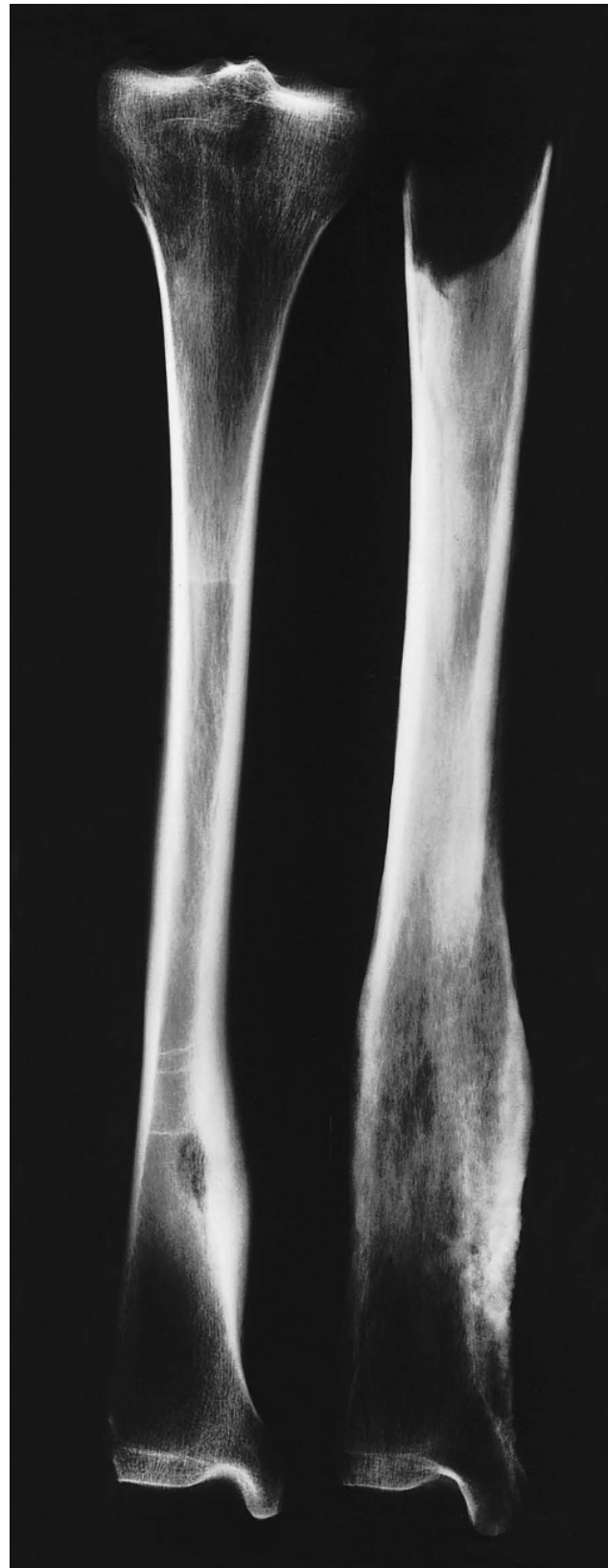19.6.1 Bacterial Infections

There are many bacterial infections which, if left untreated for a sufficiently long period of time, will leave evidence of the infection on skeletal remains. Among the bacterial infections that can be diagnosed from skeletal remains are tuberculosis, leprosy, treponematosi (includes yaws and venereal syphilis), osteomyelitis, pneumonia, salmonellosis, brucellosis, actinomycosis, nocardiosis, cholera, and plague.

- a. **Tuberculosis.** Tuberculosis is a chronic infectious disease that results from a bacterium, *Mycobacterium tuberculosis*. Infection is usually via the respiratory system, but other body parts, including bones, can also be affected. Bone and joint destruction can result from the infection. The presence of pre-Columbian tuberculosis in the New World is assessed by Buikstra (1981b) and Roberts and Buikstra (2003). Molecular work by Salo and colleagues confirmed osteological observations in 1994. A variety of bones can be affected by tuberculosis, but the vertebral column is the most common primary focus. The most common manifestation (when viewed from the side) is the collapse of one or several vertebral bodies causing a sharp angle in the spine (**kyphosis**). Differential diagnoses from osteomyelitis and septic arthritis are often possible because tuberculosis shows destruction and cavitation in cancellous bone, without extensive associated reactive bone. The pattern of element involvement, with the vertebrae and os coxae as foci, marks tuberculosis. In addition, there is no evidence of sequestration, an involucrum, or fusion of the joints. Ortner and Putschar (1981) discuss and illustrate the skeletal effects of tuberculosis.
- b. **Treponemal Infections.** Skeletally significant diseases caused by a microorganism known as a spirochete (in the genus *Treponema*) are yaws (*T. pallidum pertenue*), endemic syphilis (*T. pallidum endemicum*), and venereal syphilis (*T. pallidum pallidum*). These diseases have a worldwide distribution today, but the decades-long controversy over their origins and original distribution is still not settled. Was syphilis (misdiagnosed as leprosy) or other treponemal disease present in the New World before the arrival of Columbus? Did treponemal diseases exist in the Old World before Columbus returned from the New World? Did they exist in both Old and New Worlds prior to 1492? The controversy is well-reviewed by Steinbock (1976), Baker and Armelagos (1988), and Ortner (2003). Evidence for pre-Columbian treponemal infection in the New World is reviewed by Ortner (2003), who states that there are many examples of New World treponemal infection that probably predate European contact, but notes that the dating for none of these is certain because they derive from older, poorly controlled excavations. Recent research by von Hunnius et al. (2006) and Mays et al. (2003) has demonstrated that treponemal disease was almost certainly already present in the British Isles before Columbus' voyage. The scarcity of pre-Columbian Old World examples of treponemal disease (e.g., Schultz et al., 2003; Cardy, 1997; Roberts, 1994; Pálfi et al., 1992; and Stirland, 1991b), has focused attention on Viking merchants as possible culprits in the spread of treponemal disease (Malakoff, 2000).

In syphilis, the microorganisms enter the body through the skin or mucous membrane sites. Tertiary syphilitic skeletal lesions occur progressively, usually beginning between 2 and 10 years after infection. These can be complex, but there is usually an osteological focus of the disease in the frontal and parietals, the facial skeleton, and the tibiae. Individual lesions may not be distinguishable from some cancers, tuberculosis, or other infectious changes. Steinbock (1976), Aufderheide and Rodríguez-Martín (1998), Buckley and Dias (2002), and Ortner (2003) provide further details.
- c. **Osteomyelitis.** Osteomyelitis is bone inflammation caused by bacteria that usually initially enter the bone via a wound. This disease mainly affects the long bones (Figure 19.11) and is defined as an infection that involves the medullary cavity. However, usage in the paleopathology literature has often been imprecise. Osteomyelitis is almost always

Figure 19.11 Osteomyelitis. The tibia on the left shows localized reactive bone and a cloaca, whereas that on the right shows the result of a more extensive reaction to the infection. Radiographs of the two bones show clear involvement of the medullary cavity. Prehistoric, California. One-half natural size.



caused by pus-producing microorganisms (90% of the time by *Staphylococcus aureus*) and is thus called **suppurative**, or **pyogenic osteomyelitis**. The microorganisms can reach the bone directly, as a result of injury at any age, or via the bloodstream (hematogenous osteomyelitis, most often found in children). Characteristic hard tissue manifestations include an **involucrum** of coarsely woven bone around the original long bone cortex and one or more openings for pus drainage called **cloacae** (or **fistulae**). The latter open through the involucrum.

- d. **Periostitis**. Periostitis is a condition of inflammation of the periosteum caused by trauma or infection. It is not a disease; rather, it is a symptom of several diseases. See Mensforth et al. (1978) for a complete review of its various etiologies. These authors demonstrate an age-specific distribution of periosteal reactions that seems to coincide with — and be a response to — infectious disease in infants and children in the prehistoric Libben population. Periostitis involves only the outer (cortical) bone, without involvement of the marrow cavity (as in osteomyelitis). It can be acute or chronic and it occurs any time the inner surface of the periosteum reacts to insult by forming woven bone that sleeves the underlying cortical bone (Figure 19.12).

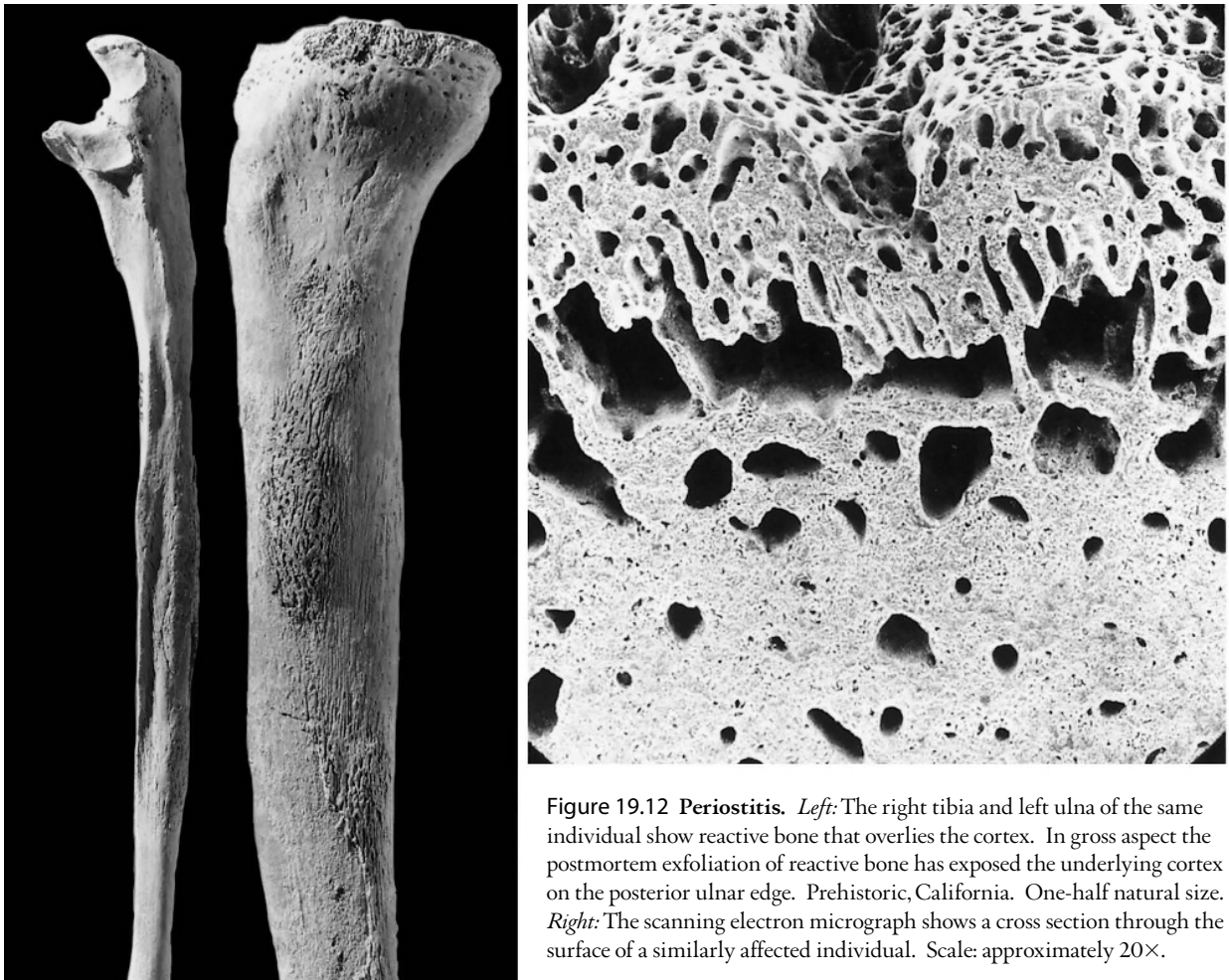


Figure 19.12 Periostitis. *Left*: The right tibia and left ulna of the same individual show reactive bone that overlies the cortex. In gross aspect the postmortem exfoliation of reactive bone has exposed the underlying cortex on the posterior ulnar edge. Prehistoric, California. One-half natural size. *Right*: The scanning electron micrograph shows a cross section through the surface of a similarly affected individual. Scale: approximately 20 \times .

19.6.2 Other Infections

In addition to bacterial infections, several other vectors of infection are known to leave evidence on skeletal remains. These include viral infections, fungal infections, and parasitic infections. Auferderheide and Rodríguez-Martín (1998) and Waldron (2009) provide extensive details on the skeletal manifestations of each of these types of infections.

19.7 Metabolic Diseases

Narrowly defined, metabolic disorders of bone are disorders in which a reduction in bone mass is the result of inadequate osteoid production, or mineralization or excessive deossification of bone. Nutritional deficiencies are usually classified under metabolic disorders. Hormonal disturbances can also lead to dramatic changes in normal skeletal anatomy.

19.7.1 Vitamin-D-related Syndromes

- a. **Rickets.** Rickets is most often a nutritional disease resulting from an insufficient amount of vitamin D in the diet that causes a failure of mineral deposition in the bone tissue of children. As a result, excessive uncalcified osteoid accumulates, and the bone tissue remains soft and flexible. The disease was described in the 1600s, but its nutritional source was not discovered until the 1920s. The osteological effects of rickets are present throughout the skeleton, but they are most pronounced in the limbs, which are usually bent and distorted. The legs are characteristically bowed outward or inward.
- b. **Osteomalacia.** The same lack of sufficient vitamin D in adults (due to either nutritional deficiency or intestinal malabsorption) is called osteomalacia, a disease usually linked to general malnutrition, particularly to deficiencies in protein, fat, calcium, and phosphorus. Osteomalacia is essentially “adult-onset rickets.” The differences between osteomalacia and rickets are due to the fact that rickets is active during the period of skeletal growth, while osteomalacia acts on bones after they have finished growing. Osteomalacia’s greatest effect is on bones in which remodeling is highest (ribs, sternum, vertebrae, and pelvis), making them subject to pathological fracture.

19.7.2 Scurvy

Scurvy is a metabolic disease caused by a long-term insufficient intake of vitamin C, which is essential for the production of collagen and, therefore, osteoid. Skeletal manifestations are most apparent in infants, usually in the form of cortical thinning and pathological fractures in rapidly growing bone areas. Maat (2004) provides a useful review and case study.

19.7.3 Osteoporosis

Osteoporosis, or **osteopenia** in the nonclinical situation, refers to the increased porosity (reduced density) of bone that is most often part of the aging process. It is a consequence of the failure of the organism to maintain the balance between bone resorption and formation. Postmenopausal women are most at risk for osteoporosis because of the cessation of estrogen production. Males are endowed initially with more bone mass than females and so do not become vulnerable to osteoporosis until later in life (in their 70s and 80s). The annual costs associated with osteoporosis in the United States alone are estimated at more than \$19 billion (Burge et al., 2007).

Osteoporosis is associated with more than 2 million bone fractures in the elderly each year. Research into basic bone biology, particularly into the factors that activate and inactivate osteoclasts, has been spurred on by these statistics. Marcus et al. (2008) offer a comprehensive review of research on osteoporosis.

19.7.4 Poisoning

In addition to osteoporosis, scurvy, and vitamin-D-related syndromes, there are several kinds of intoxications and poisonings that are detectable on skeletal remains. See Aufderheide and Rodríguez-Martín (1998) for further details on these and other metabolic disorders that leave traces on skeletal remains.

19.8 Endocrine Disorders

The growth of the skeleton is controlled, in large part, by the secretion of hormones in the pituitary and thyroid. Pathology in these glands can lead to extreme skeletal changes.

19.8.1 Pituitary Disorders

- a. **Gigantism.** Gigantism results from excessive production of somatotrophic hormone and consequent overstimulation of growth cartilages and gigantic proportions of the skeleton.
- b. **Acromegaly.** Acromegaly is similarly caused by an overly productive pituitary, but after the epiphyses are fused. The most dramatic osteological manifestation of acromegaly is growth at the mandibular condyle and a resulting elongation and distortion of the lower jaw.
- c. **Pituitary dwarfism.** Dwarfism is a general term for a variety of disorders that lead to greatly reduced stature and/or body proportions. Pituitary dwarfism results from an underactive pituitary gland, leading to reduced production of growth hormone and resulting in a normally proportioned but abnormally short individual.

19.8.2 Other Glandular Disorders

In addition to disorders of the pituitary gland, there are several other types of endocrine disorders. Disorders of the parathyroids, gonads, pancreas, thyroid, and adrenal glands also have effects on the skeleton. See Aufderheide and Rodríguez-Martín (1998) and Waldron (2009) for further details on these and other endocrine disorders that can be diagnosed on skeletal remains.

19.9 Hematopoietic and Hematological Disorders

19.9.1 Red Blood Cell Disorders (Anemias)

Anemias can affect the gross appearance of bones. Iron deficiencies, sickle cell anemia, and thalassemia all result in the expansion of spaces occupied by hematopoietic marrow within the bones. The result is often visible in the skull, with a widening of the diploë leading to a thickening of the cranial vault. Zimmerman and Kelley (1982) attempt a differential diagnosis of different types of anemias.

Porotic (or spongy) hyperostosis is a condition exhibiting lesions, usually of the cranial vault. These represent a thinning and often complete destruction of the outer table of the cranial vault that results in a sieve-like or “coral-like” appearance of the ectocranial surface. The lesions seem to be caused by anemia-associated hypertrophy of the diploë between the inner and the outer tables. Porotic hyperostosis is most often seen in immature individuals and is recognizable as a porosity of the cranial vault. It is usually bilaterally symmetrical, focused on the parietals and the anterolateral quadrant of the orbital roofs. The orbital lesions are called **cribra orbitalia**, and a similar disturbance of the endocranial surface is called **cribra cranii** (see Figure 19.13).

Causes of this bony reaction have been extensively speculated. Its high frequency in the southwest of North America was once thought to be because of a maize-based, iron-deficient diet. However, work on the phenomenon in a large sample of California skeletons (nonagricultural, fish-dependent) by Walker (1986) suggested that porotic hyperostosis is sometimes due to nutrient losses associated with diarrheal diseases rather than to diet *per se*, a position supported by Kent (1987). Walker et al. (2009) have recently argued that while porotic hyperostosis and cribra orbitalia may be associated with iron-deficiency anemia, they cannot be caused by it. Instead, they suggest that the majority of cases are caused by megaloblastic anemia acquired by infants through ingesting vitamin-B₁₂-depleted breast milk while suffering gastrointestinal infections. They also conclude that cribra orbitalia is likely to have many causes, including a co-deficiency of vitamins C and B₁₂. Wapler et al. (2004), in a histological examination of archaeological examples of cribra orbitalia, found evidence for multiple probable causes for this condition.

In a study of skeletal remains from the prehistoric southwest, Palkovich (1987) suggests that endemically inadequate maternal diet can combine with infection to produce very early onset of iron-deficient anemia with resultant porotic hyperostosis. Research by Stuart-Macadam (1987a, b) stresses the association between osteological manifestations and anemia, a subject further reviewed by Wapler et al. (2004). Using the prehistoric Libben sample, Mensforth et al. (1978) demonstrate that porotic hyperostosis is commonly caused by the normal sequelae of infection.

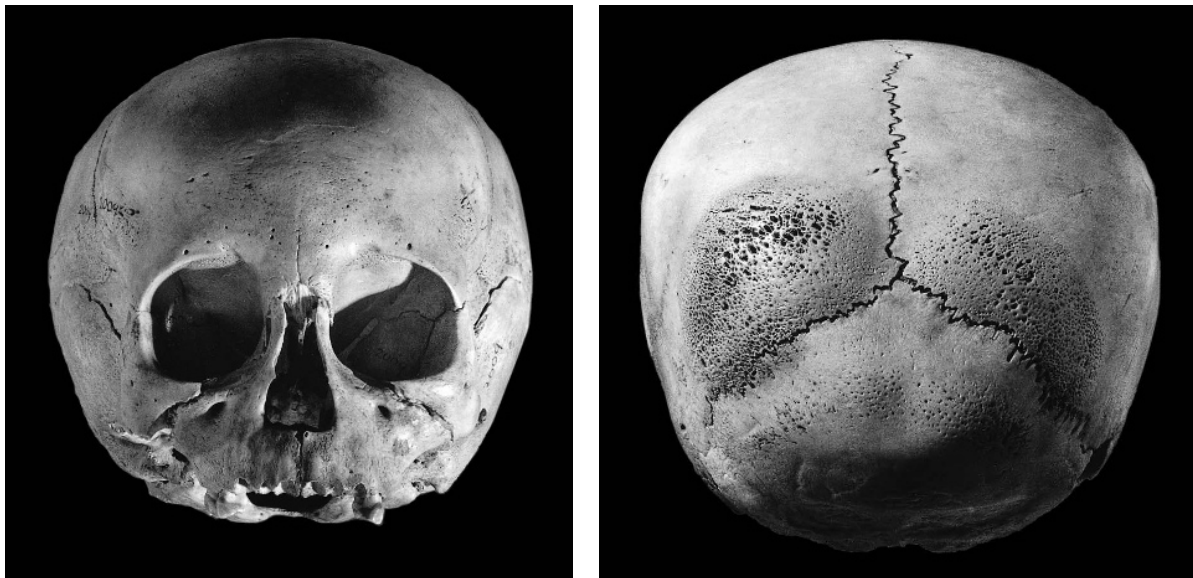

Figure 19.13 Cribra orbitalia, porotic hyperostosis. The skull of a 5-year-old child is shown in anteroinferior and posterior views to display the cribra orbitalia of the frontal (in the roofs of the orbits) and spongy hyperostosis of the parietals and occipital. Prehistoric, Peru. One-half natural size.

As noted earlier, they found a direct relationship between periostitis (infection) and porotic hyperostosis (iron deficiency) in subadults. This is consistent with clinical data that suggest that iron may be sequestered within the body as a defense against infection. Thus, much prehistoric porotic hyperostosis may be the secondary consequence of infectious disease, not of diet. Indeed, Stuart-Macadam (1991) posits that porotic hyperostosis is the result of an interaction among customs, diet, hygiene, parasites, and infectious diseases. She feels that evidence for chronic disease in skeletal material should not be interpreted as an individual's inability to adapt to the environment, but rather as evidence of the individual's fight for health against the pathogen.

19.9.2 White Blood Cell Disorders

- a. **Multiple myelomas.** Multiple myeloma (MM) is a rare primary malignant tumor of hematopoietic tissue. Its effect on bone tissues is a widespread pattern of lytic lesions on various skeletal elements.
- b. **Langerhans Cell Histiocytosis (Histiocytosis-X).** Langerhans cells are histiocytes (macrophagocytic cells responsible for consuming dead or abnormal cells) that can travel throughout the body. There are three types of Langerhans cell histiocytosis (LCH), mostly seen in children under 10: unifocal LCH (eosinophilic granuloma), multifocal unisystem LCH (Hand-Schüller-Christian disease), and multifocal multisystem LCH (Letterer-Siwe disease). While the distribution of lesions differs, the bony lesions are similar for all forms of LCH. Destructive lesions of the cranial vault and orbit are the most common, with undulating, beveled margins and no reactive bone formation. Ortner (2003), Aufderheide and Rodríguez-Martín (1998), and Dorfman and Czerniak (1998) provide further diagnostic information.
- c. **Leukemia.** Manifestations of leukemia can be difficult to differentiate from other hematological malignancies, osteomyelitis, and some infections, and diagnosis usually involves ruling these other diseases out. Rothschild et al. (1997) provide criteria by which Leukemia can be recognized in skeletal remains.

19.10 Skeletal Dysplasias

19.10.1 Achondroplasia

As stated earlier, dwarfism is caused by a variety of conditions. **Achondroplasia** is a hereditary form of dwarfism characterized by limb shortening, almost normal trunk and vault development, and a small face (Figure 19.14). It is a hereditary disease caused by the congenital disturbance of cartilage formation at the epiphyses, and constitutes a skeletal dysplasia rather than an endocrine disturbance (for example, pituitary dwarfism).

19.10.2 Osteogenesis Imperfecta

Osteogenesis imperfecta (OI or brittle bone disease) is the name of a group of pathological conditions characterized by the inability to produce type I collagen, which forms 90% of bone protein (Ortner, 2003). Because collagen forms the matrix into which hydroxyapatite is deposited, individuals with OI can have severely deformed bones prone to fracture. While OI can affect nearly any bone, the most commonly affected are the bones of the legs, the vertebrae, ribs, and clavicles (Aufderheide and Rodríguez-Martín, 1998).

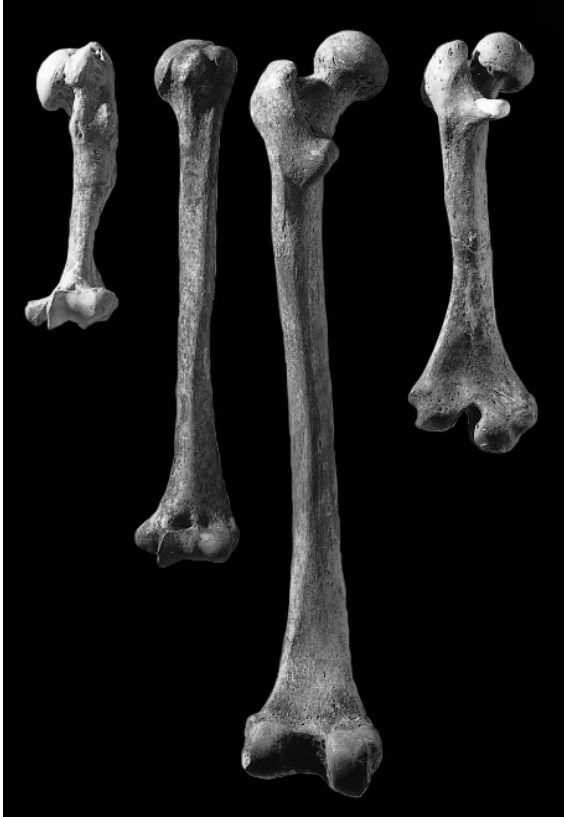

Figure 19.14 Achondroplasia. The left humerus and left femur of an achondroplastic dwarf (*far left* and *far right*) are compared with a normal human humerus and femur from a second individual (*center*). Note the disproportions and fully adult status of the achondroplastic individual. Prehistoric, California. One-fourth natural size.

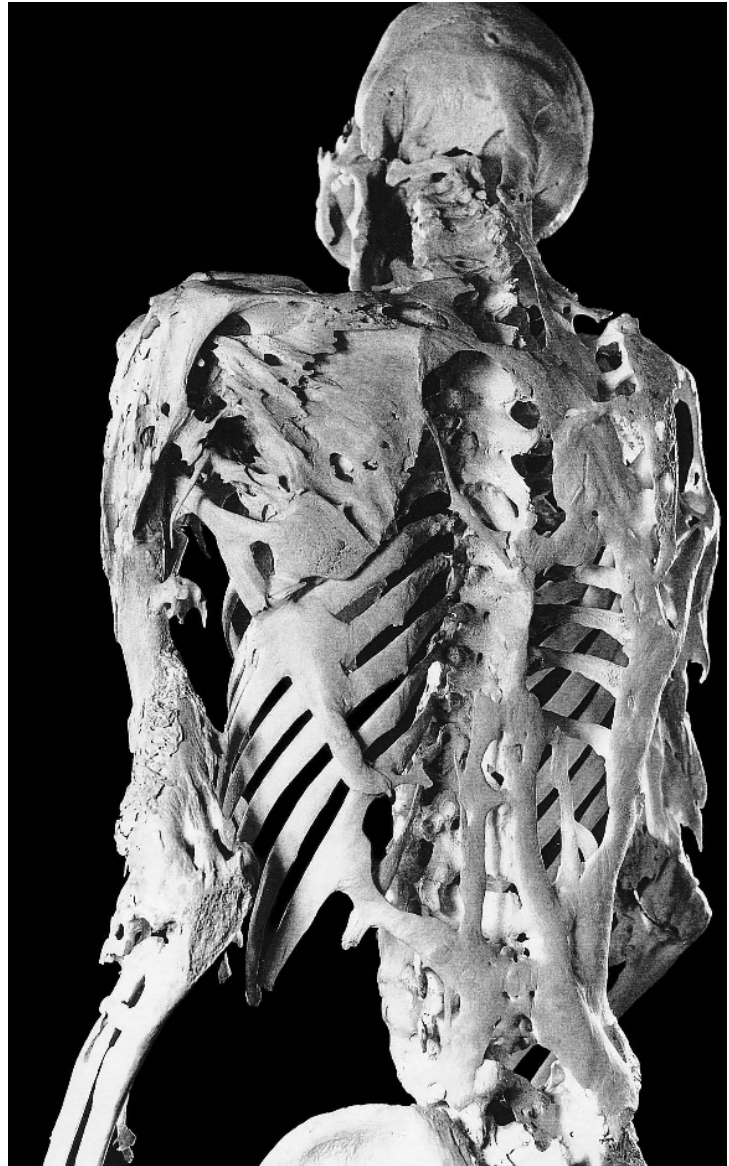


Figure 19.15 Fibrodysplasia ossificans progressiva. Advanced bony manifestations of FOP in a 39-year-old man. Courtesy of Fred Kaplan, Mütter Museum, College of Physicians of Philadelphia (Shafritz et al., 1996).

19.10.3 Fibrodysplasia Ossificans Progressiva

Fibrodysplasia ossificans progressiva (FOP) is a heritable disorder of connective tissue characterized by congenital malformation of the large toes and progressive, disabling endochondral osteogenesis in predictable anatomical patterns. Disease progression brings fusion of adjacent bones of the spine, limbs, thorax, and skull, leading to immobilization (Figure 19.15). The abnormal bone buildup occurs because white blood cells erroneously manufacture BMP-3, triggering inappropriate heterotopic (“other” + “place”) bone growth at sites of injury (Shafritz et al., 1996). See Section 3.9 for further details on the specific metabolic processes involved.

19.10.4 Other Skeletal Dysplasias

The number of named skeletal dysplasias has increased greatly in recent years, due primarily to research in genetics and biochemistry. The most recent classification of skeletal disorders lists 372 distinct dysplasias, with the causative gene identified for nearly 60% (215) of these (Superti-Furga et al., 2007). No single volume in paleopathology has kept up with the pace of this new research, but the most comprehensive reference available is Chapter 12 of Aufderheide and Rodríguez-Martín (1998). An authoritative source for information about disorders with a genetic component is the Online Mendelian Inheritance in Man database (OMIM, n.d.). The online version of the classification of disorders (<http://www.isds.ch/Nosology2006.html>) has links to the relevant OMIM entries.

19.11 Neoplastic Conditions

Neoplasms (or tumors) are localized areas of unregulated cell growth. Neoplastic growths that remain small and localized because they are unable to destroy surrounding tissues or migrate to other areas of the body are called benign growths. Neoplastic growths that can destroy nearby tissues and that can migrate throughout the body and form new growth centers (metastases) are called malignant growths, or cancers. Modern classifications of skeletal tumors name over 40 different tumor types in bone and associated cartilage and fibrous connective tissue. Histological specimens and biochemical data are usually needed to sort these out.

Tumors are classified according to the tissues in which they originate. For example, while it creates a widespread pattern of lytic lesions across multiple skeletal elements, multiple myeloma is considered a primary malignant tumor of hematopoietic tissue. While some tumors found on skeletal remains originate from bone tissue, skeletal tumors usually stem from other tissue sources, and their appearance can be very dramatic.

19.11.1 Osteomata (Osteomas)

An **osteoma** (plural: *osteomata* or *osteomas*) is a solitary, well-defined mound of compact bone, usually less than 10 mm in diameter (Aufderheide and Rodríguez-Martín, 1998). They are benign tumors and are most often found on the cranium and face, but have also been reported on the femur, tibia, humerus, and clavicle. Osteomas on the ectocranial surface of the cranial vault are often called “button” osteomas (Eshed et al., 2002). Button osteomas are hard, dense, and ivory-like in appearance and occur in about 1% of all people. **Auditory exostoses** are osteomata of the inner aspect of the external acoustic meatus.

19.11.2 Primary Malignant Bone Tumors

Primary malignant bone tumors (tumors originating from bones) are uncommon (< 1% of all malignant tumors: Waldron, 2009), and are much less common than metastatic bone tumors (tumors that originate elsewhere and then spread to bone). There are three types of primary malignant bone tumors: osteosarcomas, chondrosarcomas, and Ewing’s sarcomas.

- a. **Osteosarcomas (osteogenic sarcomas)**. Osteosarcoma is the most common primary malignant bone cancer affecting younger individuals, in both modern (A.D.A.M., 2010) and ancient (Aufderheide and Rodríguez-Martín, 1998) populations. The most commonly formed osteosarcomas occur during the growth period, affecting individuals aged 10

to 25 years (A.D.A.M., 2010). Osteosarcoma tends to occur in the distal femur, proximal tibia, and proximal humerus (Ortner, 2003), but has been noted in other bones, such as the mandible (Aufderheide and Rodríguez-Martín, 1998). Osteosarcomas begin inside the bone in the metaphysis, and spread outwards and into the medullary cavity. Osteosarcomas rarely affect the epiphyses or joint surfaces. Depending on the stage and progression of the tumor, lesions may be primarily lytic (Ortner, 2003), or they may present either a layered (“onion skin”) or a radial (“sunburst”) pattern of involvement once beyond the periosteum (Aufderheide and Rodríguez-Martín, 1998).

- b. **Chondrosarcomas.** Chondrosarcomas originate in cartilage, and typically affect older adults (Aufderheide and Rodríguez-Martín, 1998). The most common locations for chondrosarcomas are the os coxae, femur, humerus, ribs, and scapula.
- c. **Ewing’s sarcomas.** Ewing’s sarcoma begins in the medullary cavity and affects men twice as often as women. The tumors typically occur in childhood, but can occur at any point in life. The most common locations for Ewing’s sarcomas are the femur, tibia, humerus, and os coxa. In contrast to osteosarcoma, Ewing’s sarcomas typically develop in the middle of the long bones. Ewing’s sarcomas usually present a perpendicular (“hair on end”) or a layered (“onion skin”) pattern of involvement once beyond the periosteum (Waldron, 2009; Aufderheide and Rodríguez-Martín, 1998).

Waldron (2009), Ortner (2003), Aufderheide and Rodríguez-Martín (1998), and Steinbock (1976) all provide additional information on these rare cancers.

19.11.3 Osteochondromas

The most common tumor of bone and cartilage is an **osteochondroma** (also called an **osteocartilagenous exostosis**). These are benign tumors that are usually asymptomatic. They always arise at epiphyseal lines and protrude at right angles to the long axis of a bone. They can superficially resemble ossified tendons in many cases, but they have a core of trabecular bone that is continuous with the trabecular bone of the metaphysis (Aufderheide and Rodríguez-Martín, 1998). Most develop before 30 years of age, and while they can occur near the metaphysis of any long bone, the most common locations are the distal femur and proximal tibia.

19.11.4 Fibrosarcomas (Fibroblastic Sarcomas)

Fibrosarcomas, like osteosarcomas, begin inside the bone in the metaphysis and spread into the medullary cavity. Unlike osteosarcomas, fibrosarcomas are usually confined to the central portions of the bone, although they do spread beyond the periosteum (Waldron, 2009). Fibrosarcomas typically occur in adults aged 30 to 60 years, and both sexes are equally afflicted (Aufderheide and Rodríguez-Martín, 1998). Fibrosarcomas most often occur in the femur and tibia, followed by the humerus and os coxae; tumors have also been reported in the mandible and maxilla (Waldron, 2009).

19.11.5 Other Neoplastic Conditions

In addition to those listed above, there are several other types of neoplastic conditions affecting bone. See Waldron (2009), Ortner (2003), and Aufderheide and Rodríguez-Martín (1998) for fuller coverage of other benign and malignant tumors that can be found on skeletal remains.

19.12 Diseases of the Dentition

Because the teeth interact directly with the environment, they are susceptible to damage from physical and biological influences not operating on other skeletal elements. An examination of dental pathology can be useful for investigating the health and diets of individuals and populations. Even though tooth wear that is excessive by today's standards has characterized humans and their ancestors for millions of years, it should be noted that tooth wear and artificial tooth modification have been included in this chapter only for convenience. Lukacs (1989) divides dental diseases into four categories: infectious, degenerative, developmental, and genetic. All of these, of course, are interrelated in the dental health of the individual. Tooth wear should be thought of as a pathology only when it is so extreme that the associated bone is affected negatively. Hillson (2002) provides a useful review of dental pathology, with guidelines for assessing and scoring caries and periodontal disease (following his 2001 recommendations). Chapter 18 considers how tooth wear (dental macrowear) may be used to age skeletal material and discusses how such wear can be used to assess prehistoric diets. Figure 19.16 shows how extreme dental macrowear was under many prehistoric conditions.

19.12.1 Periodontal Disease

Periodontitis is the inflammation of tissues around a tooth. It can involve both soft tissues and the bone itself. Periodontal disease in skeletal remains is recognized as a result of infection of the alveolar bone and adjacent tissues. It causes recession of the alveolar bone, as either a horizontal lowering of the crest of the alveolar process or as an irregular lowering of the process, with pockets or wells expanding into the cancellous bone of the jaws. The agents of infection are microorganisms, and the disease is usually due to the combined effects of large, mixed communities of bacteria. An **abscess** is a localized collection of pus in a cavity formed by tissue disintegration. Abscesses are often found as cavities within alveolar bone near the tooth root apices. Figure 19.17 illustrates these features. Clarke and Hirsch (1991) provide a thorough account of factors influencing alveolar bone. Oztunc et al. (2006) question the assumption of low incidence of periodontal disease in archaeological populations. Eshed et al. (2006) examine measures of dental health and wear before and after the transition to agriculture in the Near East, concluding that the differences demonstrate more of a gradient than a dichotomy.

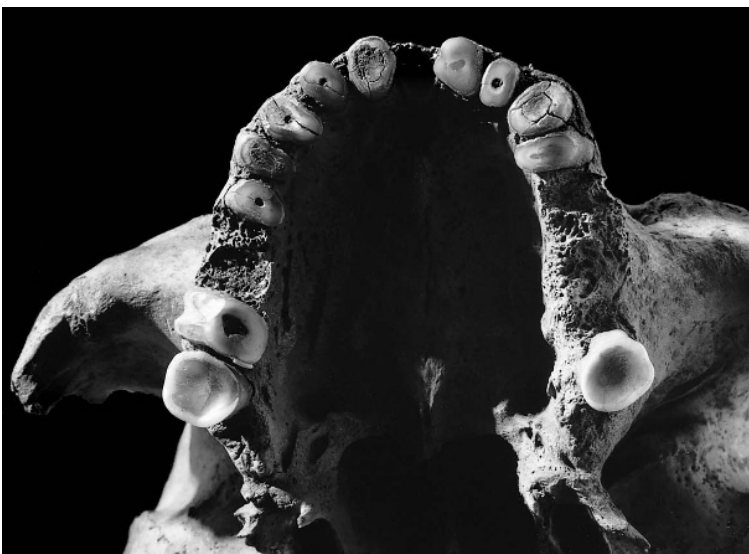


Figure 19.16 Tooth wear. Heavy attrition on dentition of this adult male has eliminated all but the third molar crowns. The individual continued to chew on the stubs of his incisors, canines, premolars, and second molar after the tooth crowns had worn away. Such wear is a normal phenomenon in older individuals from aboriginal populations with grit in the diet. Prehistoric, California. Natural size.

19.12.2 Caries

Dental **caries** is a disease process characterized by the progressive decalcification of enamel or dentine. The macroscopic appearance of caries can vary from opaque spots on the crown to gaping cavities in the tooth. A prerequisite for the formation of dental caries is **dental plaque** and a diet that includes fermentable carbohydrates. Plaque is the matrix and its inhabiting community of bacteria that forms on the tooth. Carious lesions can begin anywhere that plaque accumulates, most often in the fissures of tooth crowns and in the interproximal areas. Figure 19.17 shows a large carious lesion.

Larsen (1983) observed that the prehistoric shift to agriculture on the Georgia coast led to an increase in the frequency of carious lesions, most markedly in females. This finding indicated differing subsistence roles between the sexes and is an example of how archaeological and osteological data can be combined in insightful ways. Walker and Erlandson (1986) saw a similar but inverse shift on the California coast. Here, prehistoric people made a subsistence shift from a cariogenic diet, consisting mostly of plant foods, to an intensive exploitation of fish.

Lanfranco and Eggers (2010) recommend a system for recording the specific location and depth of carious lesions, to be evaluated together with the level of dental macrowear. Lukacs (2008) links the higher incidence of caries in women at the advent of agriculture to pregnancy-associated hormonal and dietary changes, combined with an increase in fertility.

19.12.3 Enamel Hypoplasia

Enamel hypoplasia is a condition characterized by transverse lines, pits, and grooves on the surface of tooth crowns. These disturbances are defects in enamel development. Amelogenesis, or enamel formation, begins at the occlusal apex of each tooth crown and proceeds rootward, ending where the crown meets the root at the cervicoenamel line. During this process, stress to the organism may result in a temporary upset of ameloblastic activity and a consequent enamel defect marking the interruption of development. These enamel hypoplastic defects can take many forms, ranging from single pits to lines to grooves. As Danforth et al. (1993) note, because scoring of these features varies greatly between observers, interobserver and intraobserver bias must be considered in any comparison of results from different studies.

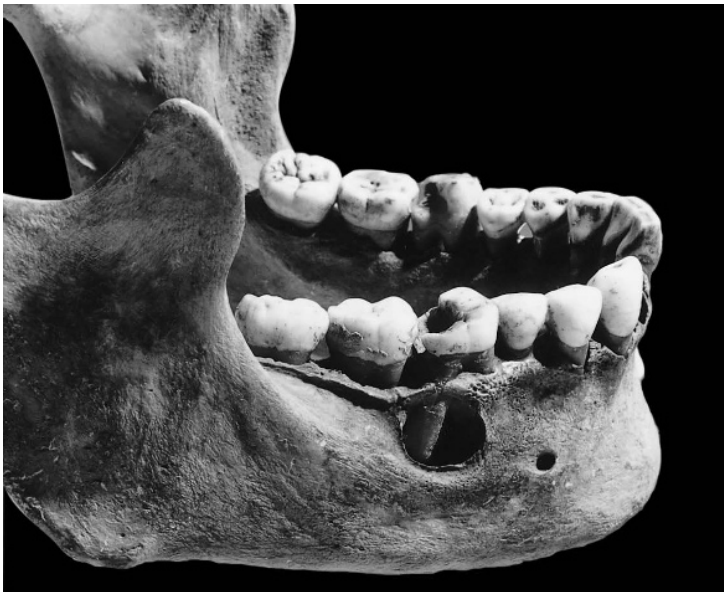

Figure 19.17 Caries and abscess. Bilateral carious lesions of the first molars are evident on this individual. A related abscess around the distal first molar root is seen posterosuperior to the right mental foramen. Prehistoric, California. Natural size.

Several different factors can cause dental hypoplasias (see Goodman and Armelagos (1985), and Skinner and Goodman (1992), for reviews), all of them the result of metabolic insult to the organism. Like Harris lines, hypoplastic bands in individuals can indicate the age at insult. Study of these developmental defects in populations can give insights into patterns of dietary and disease stress in prehistoric groups. Goodman and Rose (1991) provide a fine discussion of enamel hypoplasias as clues about the adequacy of prehistoric diet, and Goodman and Song (1999) provide more detail on estimating ages of hypoplastic defect formation. Figure 19.18 shows heavy hypoplastic banding and pitting on a child's permanent canines.

19.12.4 Dental Calculus

Dental calculus is mineralized plaque on a tooth surface. The fact that calculus can trap food debris has been used by Dobney and Brothwell (1986) as an approach for ascertaining aspects of prehistoric diet. Figure 19.18 shows remnants of calculus buildup.

19.12.5 Artificial Dental Modification

A variety of cultural practices (technically, forms of trauma) impact dentition. People engrave, color, and even intentionally pull out (**evulse**) teeth for cosmetic purposes. Brothwell (1981) illustrates the variety of decorations encountered on dental remains, primarily on the anterior teeth. These artificial incisions should not be confused with hypoplasias. Milner and Larsen (1991) review filing, chipping, inlays, and other alterations, referring to these as **dental mutilations**, whereas purposeful removal of usually anterior teeth is termed **ablation**.

Frayser (1991) and many others have interpreted the interproximal grooves sometimes present between adjacent teeth as grooves left by the use of toothpicks, and such features are even known from fossil hominid teeth of more than two million years in age. Hlusko (2003) infers that these grooves were made by grass stalks used as toothpicks. Fox (1992) reviews literature on cultural striations in the human dentition, noting several studies that have shown handedness based on the directionality of oblique scratch marks on the labial surfaces of upper incisors, particularly among paleolithic hominids. These marks were presumably made because food was secured by using the front teeth as a vise while pieces were cut away with a stone implement that came into contact with the teeth.

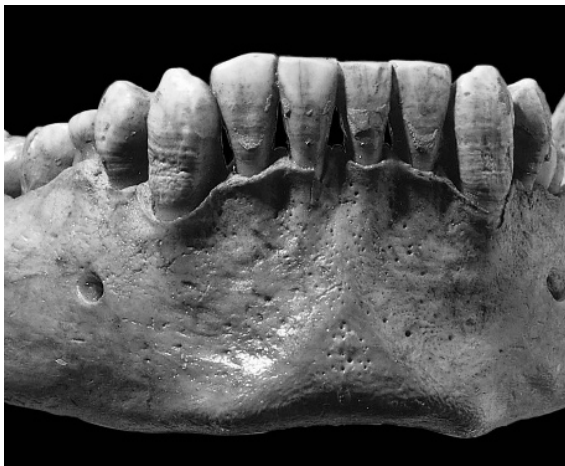

Figure 19.18 Enamel hypoplasia. This 12-year-old child suffered a metabolic upset during the formation of his canines (to see when this occurred, consult Section 18.3.1). This upset recorded itself in the linear hypoplasia seen bilaterally on the labial surface of the canine crowns. Calculus is also seen on the labial surface of the incisor crowns. Prehistoric, California. Natural size.

19.13 Musculoskeletal Stress Markers

In forensic and archaeological contexts, it is important to determine the occupational and social status of individuals now represented by skeletons. It may be possible to gain insight into the activities habitually performed by an individual by examining the patterns of musculoskeletal stress markers on that individual. While musculoskeletal stress markers can only provide basic information on the relative loading of the various muscles on the skeleton, researchers have linked patterns of stress markers to specific activities and by inference, to specific occupations. As a result, musculoskeletal stress markers are often called “occupational markers.” The inferences drawn range from the straightforward, such as determining handedness (Steele, 2000), to the ambiguous, such as fruit-pickers’ cervical spine or dog-walkers’ elbow (Capasso et al., 1998). Kennedy (1989) traces the history of occupational studies in anthropology and medicine. Capasso et al. (1998) examine occupational markers from a functional morphological perspective. Villote et al. (2010) review the evidence for occupational stress markers on the upper limb, and Weiss (2004) similarly reviews the evidence for markers on the lower limb. Waldron’s (1994) call for critical evaluation of claims is apt and enlightening. He notes that in their fervor to deduce as much as possible about the lives of ancient individuals, osteologists have made some extravagant claims about environmental stresses, parity, social status, and occupation. As he notes, some authors have been unable to resist the temptation to deduce an underlying cause for every bony lesion, identifying individuals as horsemen, sling throwers, weavers, and corn grinders based on the presence of bowed limb bones, spinal deformities, and osteoarthritis at various joints.

Perhaps because information regarding occupation and status is so valuable in an archaeological context, not enough attention is paid to the premises that underlie such identifications. Waldron’s (1994) examination of whether patterns of osteoarthritis can be used to identify occupation is a useful departure. Proceeding from known to unknown, he notes that there is a wealth of modern clinical data on osteoarthritis and occupation. He finds no convincing epidemiological evidence of a consistent, coherent relationship between a particular occupation and a particular form of osteoarthritis. Indeed, given the fact that sex, race, weight, movement, and genetic predisposition are all known factors that influence development of the disease, this is not surprising. Waldron (1994) concludes that because we know that occupation is not the sole cause of osteoarthritis, there cannot be any likelihood of being able to deduce the former from the latter. Furthermore, even in cases in which occupationally related activity does seem to be important in determining the expression of arthritis, there are no unique features about this expression—most people who develop arthritis at the finger joints are not mill workers, even though mill workers do develop arthritis at these joints. For single skeletons, therefore, the prospects seem bleak.

On a populational basis, however, the prospects are better. Here, by examining the patterns of osteoarthritis in each skeleton, and among all skeletons, it might be possible to draw conclusions about activity pattern differences on a populational level. This is the underlying basis of the only comprehensive skeletal study of activity-induced pathology, a small populational study of Canadian Inuits in which activity patterns such as kayaking, harpoon throwing, and sewing were related to osteoarthritic patterns on a populational basis (Merbs, 1983). A study by Stirland (1991a) on sailors from King Henry VIII’s A.D. 1545 flagship, *Mary Rose*, is another, smaller, and more limited sample in which an attempt to relate a paleopathological pattern to occupation is made. Even in the best of cases, however, it remains impossible to definitively conclude that any single individual had a particular occupation based on any particular arthritic joint in his or her skeleton. As Waldron (1994: 98) cautions, “There is a perfectly understandable drive to make the most of what little evidence survives in the skeleton and this sometimes has the effect of overwhelming the critical faculties.” The osteologist should be wary of poorly supported claims about diet, disease, demography, and occupation at both the level of the individual skeleton and the level of the population sample.

Suggested Further Readings

Aufderheide, A. C., and Rodríguez-Martín, C. (1998) *The Cambridge encyclopedia of human paleopathology*. Cambridge, UK: Cambridge University Press. 496 pp.

Detailed descriptions and abundant illustrations make this an invaluable reference.

Brickley, M., and Ives, R. (2008) *The bioarchaeology of metabolic bone disease*. Boston, MA: Elsevier/Academic Press. 333 pp.

A comprehensive examination of chemical and age-related bone pathology in paleontological and modern contexts.

Cohen, M. N., and Crane-Kramer, G. M. M. (2007) *Ancient health: Skeletal indicators of agricultural and economic intensification*. Gainesville, FL: University Press of Florida. 432 pp.

This selection of essays traces the osteological effects of technological and economic advances of the late Holocene.

Mann, R. W., and Hunt, D. R. (2005) *Photographic regional atlas of bone disease: A guide to pathologic and normal variation in the human skeleton*. Springfield, IL: C. C. Thomas. 297 pp.

An excellent visual resource delineating normal variation and pathology, this revised edition replaces drawings from past editions with images.

Ortner, D. J. (2003) *Identification of pathological conditions in human skeletal remains* (2nd ed.). San Francisco, CA: Elsevier/Academic Press. 645 pp.

An outstanding text; essential for any work in paleopathology.

Pinhasi, R., and Mays, S. (Eds.) (2008) *Advances in human palaeopathology*. Hoboken, NJ: John Wiley and Sons. 408 pp.

This text presents multi-disciplinary, cutting-edge methods in the field of paleopathology.

Powell, M. L., and Cook, D. C. (2005) *The myth of syphilis: The natural history of treponematosi in North America*. Gainesville, FL: University Press of Florida. 509 pp.

This selection of historical and archaeological essays follows the North American history of endemic and epidemic treponemal infection.

Roberts, C., and Manchester, K. (2007) *The archaeology of disease* (3rd ed.). Ithaca, NY: Cornell University Press. 338 pp.

This revised edition updates its summary of various methods of identifying disease in the archaeological record.

Steinbock, R. T. (1976) *Paleopathological diagnosis and interpretation*. Springfield, IL: C. C. Thomas. 423 pp.

A well-illustrated classic text on paleopathology.

Tyson, R. A. (Ed.) (1997) *Human paleopathology and related subjects: An international bibliography*. San Diego, CA: San Diego Museum of Man. 716 pp.

A guide to the paleopathological literature.

Waldron, T. (2007) *Palaeoepidemiology: The epidemiology of human remains*. Walnut Creek, CA: Left Coast Press. 148 pp.

This volume details quantitative methods employed in paleoepidemiological research and includes advice on designing paleoepidemiological studies.

Waldron, T. (2009) *Palaeopathology (Cambridge manuals in archaeology)*. New York, NY: Cambridge University Press. 279 pp.

Primarily method-oriented in its approach, this book recommends a standardized program of paleopathological diagnosis.

Chapter 20

POSTMORTEM SKELETAL MODIFICATION

BONES CHANGE as the individual grows. This process, **ontogeny**, continues until late in adulthood in some regions such as the pubic symphysis (see Chapter 18). Because bone is living tissue, it can respond to physical stimuli at any time during an individual's life. Individual variation in any human skeletal element, therefore, can be the result of the bone responding to genetic control, to environmental factors, or to both. The morphological changes discussed in Chapter 18 are **antemortem** effects. They include changes brought about by pathology. After death, however, further changes can occur in bone, brought about by biological, chemical, and physical agencies operating on it. **Postmortem modification** alters both the condition of the individual bones and the completeness of the skeleton as a whole.

The study of the processes that operate between the time of death of the organism and the time of study by the osteologist is called **taphonomy**. Taphonomy, from the Greek words for “burial” and “laws,” is a word coined in 1940 by the Russian paleontologist Efremov. Taphonomy is usually described as a subdiscipline of paleontology, but its methods and data are often applied in archaeological and forensic analyses.

Human skeletal remains are recovered from a variety of contexts. These include geological deposits (such as cave floors, alluvial bodies, lacustrine deposits, peat bogs, and volcanic ash), archaeological contexts (such as house floors, wells, battlefields, megalithic structures, plague pits, cemeteries, funeral urns, refuse pits, and even hearths), and forensic settings (such as open-air dump sites, shallow graves, mass graves, or burned structures). Given this variety of contexts, postmortem modification of human skeletal remains can take many forms.

Taphonomy merits the attention of the human osteologist because hominid skeletal remains often bear the traces of past processes and activities useful for inferring past behaviors and events. Human osteologists are often called upon to determine whether the distinctive patterns of damage or element representation (in a skeletal assemblage or an individual) may have resulted from human behavior or natural causes. An understanding of the many processes that alter bones and bone frequencies provides the basis for such interpretations. It is essential that these processes and their effects be understood in order to avoid the mistaken attribution of postmortem modification to antemortem pathological processes (see Chapter 19). In addition to modifying the bones themselves, postmortem processes can dramatically alter the composition of skeletal populations. Several pitfalls of demographic reconstruction involve the differential destruction of skeletal remains due to postmortem processes.

The forensic osteologist working in a crime scene context acts as a member of an investigative team searching for all available clues. However, some physical anthropologists working in archaeological or paleontological contexts have focused exclusively on the retrieval of bones, thereby missing important clues about past behavior. This exclusive focus on the retrieval of

bony specimens has the potential to sacrifice much critical information about the past.

Archaeologists often study burials to understand past cultural activities, particularly mortuary practices. Duday (1978; Duday and Masset, 1987) has consistently called attention to the need for communication between archaeologist and osteologist during every phase of the recovery of skeletal remains. Nawrocki (1995) suggested that this specialized, gap-bridging field of study should be called human taphonomy. It is important to remember that bodies are usually buried, not just the skeletons within them. The disposition of the skeleton therefore provides critical information on how the body was buried. The cultural and taphonomic circumstances surrounding death and the primary burial of the individual both influence the skeleton recovered by the archaeologist. By using all available clues exposed during excavation, the cultural arrangement of the cadaver and the infilling of the burial space may be inferred.

It is most convenient to divide taphonomic agents into two major classes—biological and physical—and to consider human-induced modifications separately. It should be realized, however, that biological agents act to alter human bones through both physical and chemical pathways. This chapter describes and illustrates the effects of the most commonly encountered postmortem alterations of human skeletal remains. The student is referred to Lyman's 1994 volume *Vertebrate Taphonomy* as an excellent extension of much of the subject matter of this chapter, from an archaeological perspective. The same author's *Quantitative Paleozoology* (2008) is an essential companion. Haglund and Sorg's (1997) excellent edited volume *Forensic Taphonomy: The Postmortem Fate of Human Remains* is another valuable resource, as is Section III ("Interpretation of trauma and taphonomy") of Steadman (2003). Chapter 22 considers taphonomic changes to biomolecules. The taphonomy of soft tissues is beyond the scope of this book. A good resource for the study of intentional and unintentional mummification is Aufderheide's (2003) *The scientific study of mummies*. The taphonomy of human hair is discussed by Wilson and Tobin (2010).

20.1 Bone Fracture

In osteological analysis, it is critical to identify deviations of bones from the normal condition and to distinguish between deviations caused by pathological agents and those brought about by taphonomic agents. Assessing bone fracture in an archaeological context is an example of the difficulties of such work. Fracture of a radius, for example, can occur a year before death, an hour before death, immediately after death, or during excavation. The causes of such fracture vary. Antemortem fracture can occur as the individual falls from a tree. Postmortem fracture can be caused by the corpse being forced into a small burial crypt, or by a hyena scavenging the body. Impatient archaeologists also have been known to fracture bones through carelessness. Signs of bony healing around the fracture could identify the fracture as antemortem. Without this healing, however, the osteologist may be forced to identify the fracture as **perimortem** (around the time of death), implying that it is not possible to ascertain whether the fracture occurred just before, during, or after death. Ubelaker (1992b) notes the significance of fracture of the hyoid in a forensic context. Death by strangulation sometimes involves hyoid fracture. However, dissection during autopsy can also fracture the hyoid. Incomplete ankylosis of the horns to the body of the hyoid is sometimes mistaken for fracture. The hyoid can be fractured prior to death and not show significant remodeling at the time of death. The osteologist's most important contribution to a forensic investigation may be to bring all these possibilities to the attention of the investigative team.

The rate at which a bone loses its organic component and becomes "dry" as opposed to "green" or "fresh" varies widely, depending on the environment of deposition. Mineralization or "fossilization" of the bone also depends more on context than on elapsed time. Despite the variations in rate of change, it is often possible to distinguish between ancient (perimortem) fracture of bones that still retained much organic component when broken, and recent (postmortem) fractures of dry bones that occurred during excavation and transport. Discrimination is often facilitated by

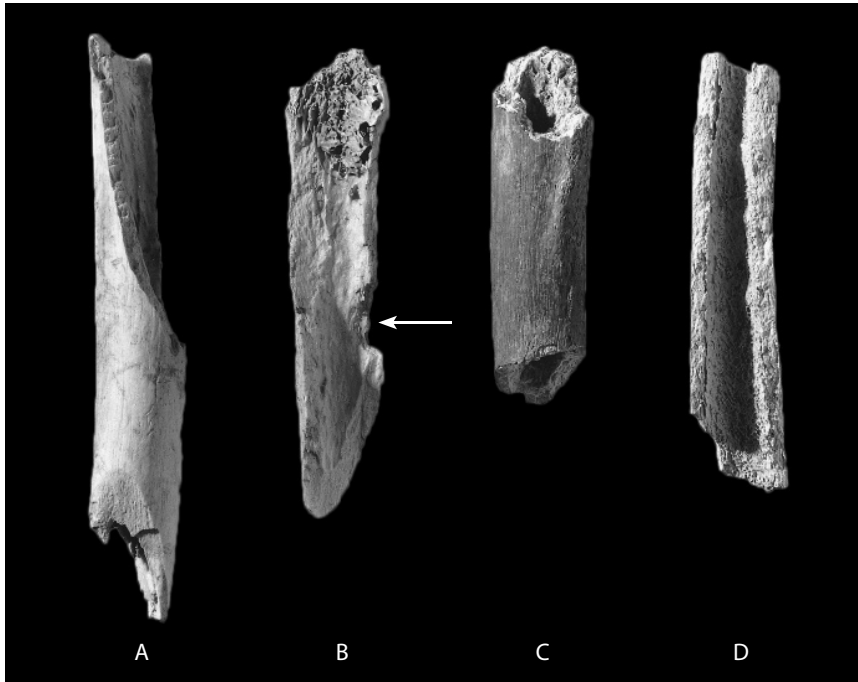


Figure 20.1 Recent versus ancient fractures. Ancient perimortem (A, B) and recent postmortem (C, D) fractures of human femoral shafts. Specimens A and B are from an archaeological context in which the bone was fragmented when fresh, whereas specimens C and D were fractured during retrieval of the elements from the ground. Note the conchoidal impact scar on the internal surface of specimen B (*arrow*). One-half natural size.

reference to the surface color and edge characteristics of the broken surfaces (Figure 20.1). Ancient longitudinal or spiral fractures of the shaft are usually straight, with sharp, linear edges. Because the fracture surface had already formed at the time of burial, this surface is usually the same color as the rest of the bone surface. However, dry or fossilized bones that have been recently broken usually have rougher, more jagged fractures, and the fracture surface is usually a different color (lighter in most unfossilized bone) than the adjacent unbroken surfaces. See Section 19.2.1 for more information on the various kinds of antemortem and perimortem fractures.

As described in Chapters 4–14 and 19, individual bones perform different mechanical and physiological functions. These functions are reflected in the wide variation in size, shape, density, and internal structure of the bones. These characteristics, in turn, affect the potential for postmortem fracture of each element and even parts of elements. For example, human femoral shafts from archaeological collections are far more likely to escape the ravages of biological and physical destruction than the smaller, more fragile sternum. Element representation in excavated skeletal assemblages can therefore be altered significantly from that predicted by element ratios in the intact skeleton. The absence of hand phalanges in an excavated cemetery assemblage usually does not mean that bodies were buried without fingers. Instead, such absence more often indicates that years of postburial rodent tunneling through the site displaced these small elements, or that recovery techniques were not adequate. Imaginative attribution of the disproportion to some ritual activity involving removal of the fingers would be unwarranted in such a case.

The appreciation that patterns of element disproportions in the archaeological record are not all attributable to human intervention has caused archaeologists to look closely at natural bone modification in the modern world. These **actualistic** studies have shown repeatedly that the structure of the bones themselves is often a major determinant of patterning in the archaeological record. For example, the edge of the tibial plateau is often eroded simply because of its prominence and thin cortex, whereas the shaft of this element is rarely damaged.

20.2 Bone Modification by Physical Agents

20.2.1 Chemistry

Postmortem changes in bone range from minor alterations of bone proteins to complete structural and chemical breakdown. As outlined in Chapter 3, the major constituents of bone are protein (mostly collagen) and minerals. The relationship between these constituents involves complex structural features and chemical bonds whose nature is not fully understood (Collins et al., 2000; Nielsen-Marsh et al., 2000; Collins et al., 2002; Denys, 2002; Hedges, 2002; Forbes, 2008). When the organism dies, the once-dynamic bone tissue begins to disintegrate. Soil acidity (pH) and permeability, moisture, temperature, and microorganisms can all dramatically affect the rate of skeletal deterioration. Depositional environments such as the dry Egyptian or Peruvian deserts, and the cold, dry arctic can even preserve soft tissues. Other depositional conditions ensure destruction of even the teeth. Differences in soil conditions, even within a single burial, can result in differential destruction. In general, better bone preservation is present in well-drained areas with low water tables, in soils with a neutral or slightly alkaline pH, in temperate areas,




Figure 20.2 Burning and weathering of bone. The shaft fragments and phalanx on the right show characteristic cracking, degreasing, and exfoliation associated with weathering. These human bones lay exposed on an unprotected surface in Colorado for about 15 years. The femoral shaft fragment and phalanx in the middle show bone deterioration, discoloration, and exfoliation indicative of damage by burning. Note that the contact between damaged and undamaged surfaces is abrupt. Soft tissue protects the deeper bones, whereas subcutaneous bones or bone portions is more susceptible to such damage when fleshed bones are burned, so the pattern of damage provides clues to the amount of soft tissue on the body when burning occurs. The limb-bone shaft splinter and phalanx on the left are unaltered. Bar: 1 cm.

and in deeper burials (Henderson, 1987; Janaway et al., 2009). These generalizations are often violated, however, because preservation is so dependent on unique combinations of these variables in local depositional settings. The color and degree of fossilization are also controlled by the environment of deposition. Under the right conditions, a bone can become completely fossilized in a few thousand years.

When unfossilized bone is exposed to the elements, particularly rain and sun, its surface deteriorates at the same time that its organic content is lost. Weathering bones first display a network of fine, usually parallel surface cracks. These cracks progressively deepen and widen as the bone surface begins to deteriorate (Figure 20.2). The rate of weathering depends on temperature and humidity, but archaeologists have attempted to use bone weathering to estimate how much time some bone assemblages took to accumulate on former land surfaces (*e.g.*, Behrensmeyer, 1978; Todisco and Monchot, 2008), and forensic osteologists use similar observations (*e.g.*, Janjua and Rogers, 2008; Ross and Cunningham, in press). Lyman and Fox (1997) discuss the pros and cons of weathering data in both realms.

20.2.2 Rock, Earth, and Ice

Bones on the surface of caves can be broken and scratched by rockfall. Buried bones can be fractured by earth movement. In colder climates, the freeze-thaw cycle can result in damage to bones. The postmortem alteration caused by these nonhuman physical agencies may include striations and polishing that might be attributed to human intervention. However, in such circumstances the depositional context and configuration of damage can provide important clues for the accurate interpretation of the bone modifications. Tersigni (2007) reviews the effects of freezing on human bone.



Figure 20.3 Burned human bone. Burning here has resulted in splitting, cracking, and discoloration of the specimens, exfoliation of the cranial vault bone (*upper right corner*), and destruction of the subcutaneous surface of the tibial shaft fragment (*bottom*). One-half natural size.

20.2.3 Abrasion

Particles of grit suspended in aerial or aqueous environments can abrade bones, reducing surface relief. Such sandblasting effects are commonly observed in bones exposed on the surface in desert conditions or transported in a river. Many fossil assemblages are recovered from fluvial environments and their elements often show abrasion damage.

20.2.4 Fire

It is possible for bones to become charred by naturally occurring fires, but the effects are usually not as severe as damage caused by mortuary (cremation) or dietary (roasting) practices (Figures 20.2 and 20.3). For many archaeologists and osteologists, an introduction to cremated human bone is the first encounter with burned bones. This is unfortunate because the objective of cremation as a mortuary practice is the destruction of the body. Cremated bones are typically heated to very high temperatures and characteristic color changes and cracking accompanies the loss of the organic portion of the bone tissue. It is necessary to recognize, however, that bone subjected to lower temperatures for shorter periods of time is not so conspicuously altered. In fact, burning of bone tissue may so closely mimic normal bone-weathering processes that microscopic or chemical analysis is necessary to distinguish the two (Taylor et al., 1995). Burning (charring) of bone tissue is also sometimes confused with staining (particularly manganese staining) of bones in some depositional contexts (Shahack-Gross et al., 1997). When analyzing evidence for the burning of human bones, the osteologist should always be attentive to the depth and character of the soft tissue that covered the particular osteological element at death. The molar enamel, for example, is exfoliated less frequently than incisor enamel because when the head is exposed to fire the incisors are exposed to very high temperature, whereas molars are more protected because of coverage by more soft tissue. Pijoan et al. (2007) provide a review of thermal alterations in archaeological bones, and Schmidt and Symes (2008) provide a book on the topic.

20.3 Bone Modification by Nonhuman Biological Agents

20.3.1 Nonhuman Animals

Carnivores such as hyenas, wolves, dogs, leopards, vultures, crocodiles, and even insects can have a dramatic impact on bones and bone assemblages. These animals, particularly the canids and hyenids, are agents of bone destruction because they break bones between their teeth in an effort to retrieve the fat and marrow within. The soft, trabecular portions of bones are favored by these animals, and even a small hyena is fully capable of splintering the shaft of an adult human femur. Carnivore damage to bones is recognized by the signature of the teeth—pitting, scoring, and puncturing of the bone surface (Figure 20.4). Haglund et al. (1988) provide a brief account of forensic cases in which human skeletal remains were ravaged by carnivores. Haglund (1997) reviews canid data. Njau and Blumenschine (2006) report results of crocodile feeding experiments. Haglund (1992) contrasts rodent and carnivore damage, and Faith et al. (2007) consider how carnivore competition and bone density can affect bone destruction in the wild.

Although rodents are generally smaller than carnivores, their gnawing can be just as destructive. Rodents ranging in size from mice to large porcupines chew on bones. Like carnivores, large rodents can move bones around on the landscape, often carrying them over large distances to their dens, where they accumulate and modify them by chewing. The chisel edge of the rodent incisor is used to shave away the surface bone, producing a distinctive, fan-shaped pattern of regular, shallow, parallel or subparallel, flat-bottomed grooves that are usually concentrated on the projecting surfaces of bones. These traces can be patterned and regular (Figure 20.5), but they should not be confused with modifications to bone made by humans. Klippel and Synstelien (2007) review

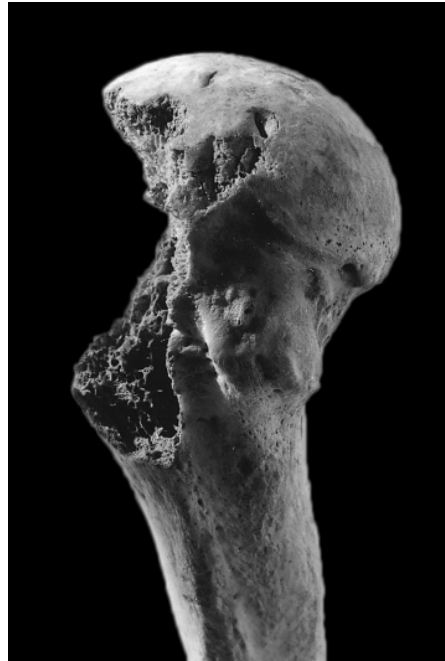



Figure 20.4 Carnivore-gnawing marks on prehistoric human skeletal elements. The femur (*top left*) shows destruction of the spongy bone of the greater trochanter and associated broad horizontal grooves made by carnivore teeth just below the trochanter position. The humerus (*top right*) shows similar destruction of trabecular bone along with small punctures left by gnawing on the articular surface of the head. The os coxae (*bottom*) shows destruction of the iliac crest and adjacent perforations caused by gnawing. California. Natural size.

rodent gnawing and Reeves (2009) considers the effects of vultures.

In addition to displaying traces of chewing by mammals, bones can be scarred by the action of mammalian feet. Trampling by ungulates and polishing by constant passage of carnivores in a lair may scratch and polish bone surfaces. The superficial striations that result from trampling might be mistaken for cut marks until it is appreciated that these marks, unlike cut marks, are usually randomly oriented and concentrated in fields of parallel striae across the most prominent parts of the bone.

Insects can also damage bones. Huchet et al. (in press) discuss the effect of termite gnawing on archaeological human remains, and Kaiser (2000) describes pre-depositional insect damage to fossil bones from the hominid site of Laetoli, Tanzania.

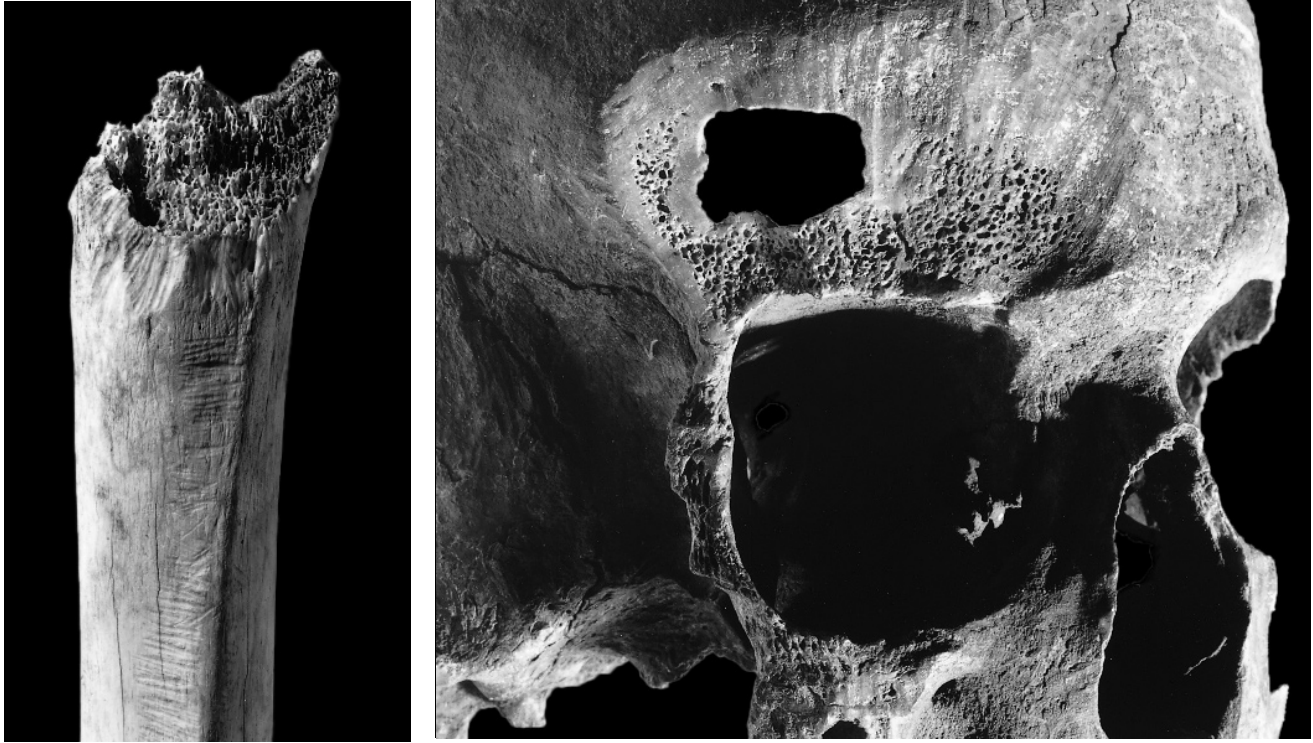


Figure 20.5 Highly patterned rodent gnawing marks on human skeletal elements. The tibia (*left*), from prehistoric California, shows gnawing by a very small rodent. The cranium (*right*), from a prehistoric African site, shows heavy gnawing, with broader gouges left by the incisors of an African porcupine. Natural size.

20.3.2 Plants

Plants send their roots into the ground in search of water and nutrients. These roots secrete acids that can be very effective at etching the surfaces of buried bones. The initial pattern of root damage is usually a reticulate network of shallow grooves that should not be mistaken for the work of prehistoric engravers (Figure 20.6). This root-etched network can become so dense that the entire outer surface of a bone is etched away. Individual root-mark grooves are often whiter in color than the surrounding bone because of decalcification brought about by the acid.

20.4 Bone Modification by Humans

Distinguishing human from nonhuman agents in the modification of skeletal remains continues to preoccupy anthropologists studying human origins in Africa, the peopling of the New World, and many other problems of prehistory. As noted previously, many actualistic studies have been conducted with the goal of discovering diagnostic attributes of human bone modification in archaeological contexts. Most of these studies focus on nonhuman skeletal remains and are referred to as **zooarchaeology**. Their results also apply in cases where human remains are the objects of human modification.

Human mortuary practices may have profound effects on the disposition of a skeleton. For example, the forcing of the corpse into a small space can cause strange anatomical juxtapositions and even fractures. In secondary burials, there are often traces of human activity left on the bones; defleshing can leave cut marks and scraping marks on the bones, and cremation usu-

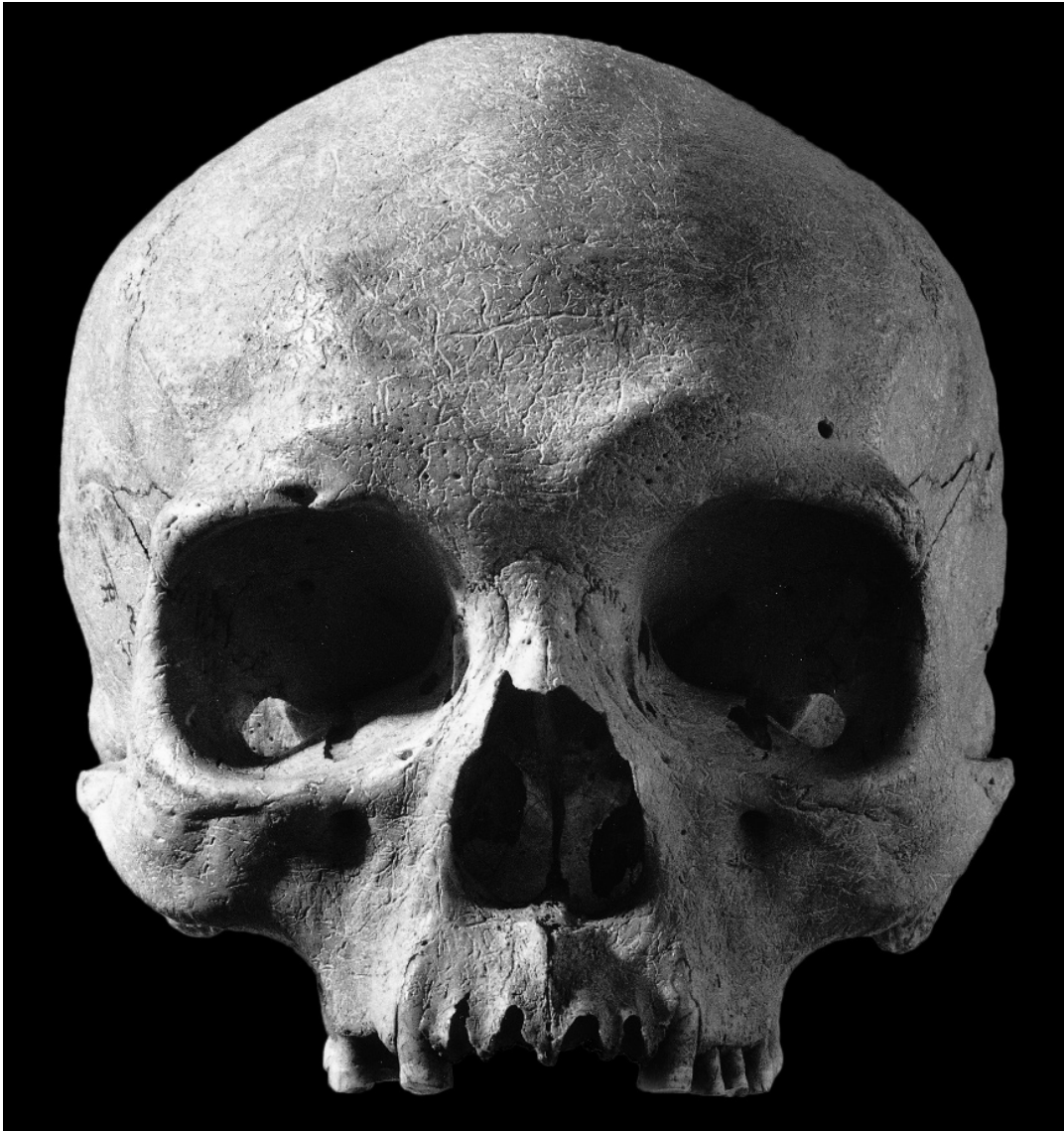

Figure 20.6 Root marking on a human cranium from a prehistoric California site. Such delicate, intricate etching of grooves should not be mistaken for cultural activities. Natural size.

ally causes charring (resulting in white, gray, black, and blue hues) and transverse cracking of the bones. Fortunately for the osteologist, aboriginal cremation may be inefficient, leaving identifiable fragments available for recovery and analysis.

Cannibalism in an archaeological context is a topic of considerable anthropological interest. Humans can fracture long-bone shafts with hammerstones and pulverize long-bone ends to extract nutritious fat. Percussion pits and anvil scars are usually seen under these conditions (see Chapter 26; White, 1992; Turner and Turner, 1999). Cut marks made by stone or metal tools may also appear on skeletal remains in a cannibalized assemblage (Rautman and Fenton, 2005). Burning of the bone associated with roasting is often concentrated on the subcutaneous surfaces of bones such as the cranium, mandible, and tibia. Processing of bones by cooking at lower temperatures generally leaves no obvious signature, but such cooked bones can be identified using transmission electron microscopy (Koon et al., 2003). Study of the patterns of bone destruction

through bone assemblage composition and the actual physical traces left on individual bones often makes it possible to distinguish between human and nonhuman damage to bones.

As noted in Chapters 15 and 16, improper excavation, transport, and cleaning of bones in the field or laboratory can result in damage to skeletal remains. This “preparation,” or cleaning, damage is usually easily discernible from perimortem damage on the basis of its distribution and surface characteristics. Many of the world’s most famous hominid fossils have been damaged in this manner. Metal instruments, including dental picks, electric drills, and even wire brushes, can all leave traces on osteological specimens, but this damage should never be mistaken as evidence for prehistoric human behavior. The osteologist should take precautions to avoid inflicting such damage on skeletal remains. These excavation- and preparation-related defects are often easily diagnosed based on their color. Ancient surficial defects in a bone usually accumulate soil, matrix, stains, or other residues that darken them relative to the adjacent bone. Recently made defects are usually lighter in color and free of staining and microscopic and macroscopic foreign debris.

Discrimination between taphonomic agents or “agencies” that anciently caused surface modifications to bones is often thought to be a more difficult task. For example, some have advocated the use of scanning electron microscopy to choose between diagnoses of carnivore chewing marks or humanly induced cut marks. Blind tests in a study by Blumenschine et al. (1996) demonstrated inter-analyst agreement and accuracy in identifying cut marks, percussion marks, and carnivore tooth marks, approaching 100% for experts. Major human-made modifications to bone surfaces are outlined in the following sections and are illustrated and discussed by White (1992).

20.4.1 Cut Marks, Chop Marks, and Scrape Marks

When the sharp, often irregular edge of a stone tool contacts the surface of a bone during defleshing or disarticulation activities, a **cut mark** (Figure 20.7) is formed. These marks are usually much narrower, finer, and more V-shaped than carnivore tooth marks. Unlike the single rough furrow of a carnivore mark or the flat-bottomed trough of a rodent incisor mark, cut marks usually display striae within the mark and often show “shoulder marks” or “barbs” where different parts of the tool edge contact the bone and thereby cut their own parallel or subparallel marks. However, the ridges and crenulations on crocodile teeth may mimic this microdamage (Njau and Blumenschine, 2006, contra McPherron et al., 2010). Cut marks are usually the result of slicing activities in which the blade of the tool is used perpendicular to the grain of the tissue being sliced. **Chop marks** (Figure 20.8) are similar to cut marks, but result from forceful and abrupt contact between tool edge and bone rather than from slicing activities. Chop marks are less frequent in archaeological bone assemblages modified by stone tools with fragile edges and are more frequent in forensic cases where metal implements allow the chopping of tissues (Alunni-Perret et al., 2005). **Scrape marks**, made when the edge of the tool is scraped across the surface of the bone, also show lower frequencies in archaeological assemblages for the same reason. These are usually shallower than either cut marks or chop marks, but they cover wider areas with many parallel or subparallel striations.

20.4.2 Percussion Marks

Cut marks and chop marks are encountered in both forensic and archaeological contexts. In the forensic context, such marks can indicate antemortem trauma or postmortem attempts to disarticulate body segments. Once disarticulated and (less frequently) defleshed, the elements of the skeleton can be reduced further by direct percussion with a heavy object. This is rarely seen in forensic contexts, but it is virtually universal in zooarchaeological contexts. Fat is highly prized by many people, and bones contain fatty marrow in both their medullary cavities and their trabecular regions. To obtain fat from the first location, the shafts are cracked and pulled apart. Fat in the spongy bone can be extracted by eating the crushed trabecular portions or by boiling them to

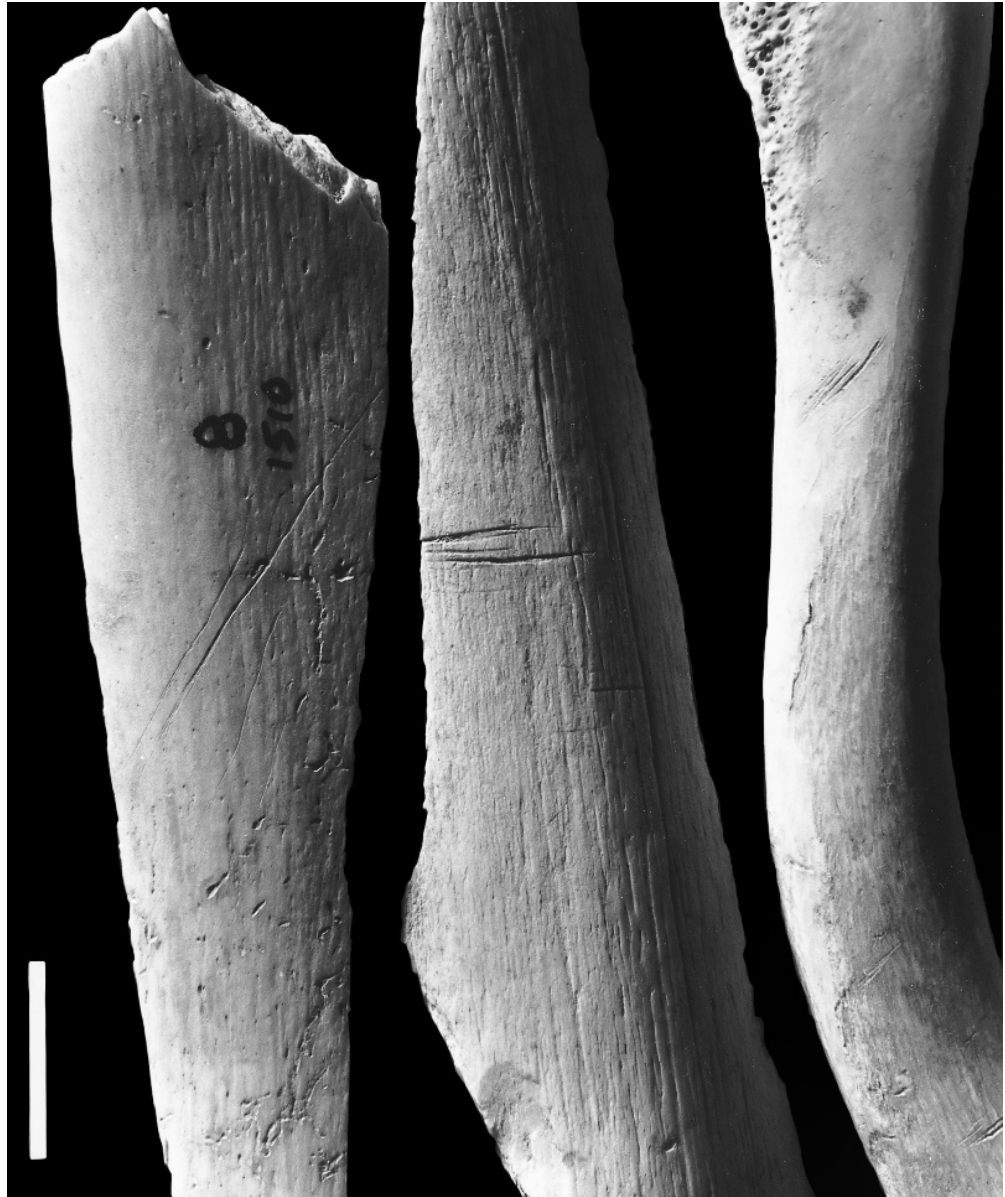

Figure 20.7 Cut marks made by stone tools on two femoral shaft fragments and a clavicle. Cut marks are usually patterned with respect to the soft tissue that was being cut from the body — here, defleshing cut marks to remove leg musculature, and marks made in the process of decapitation. Bar: 1 cm. From White (1992).




Figure 20.8 Chop marks made by stone tools on the posterior surface of a proximal tibial fragment. Bar: 1 cm. From White (1992).

render the fat in cooking vessels. All of these cultural activities have the potential to leave traces on the bones, and all have been investigated actualistically (White, 1992; Pickering and Eglund, 2006).

When fracture of the bone is effected with a stone hammerstone, irregular, roughened **percussion pits** (Figure 20.9) that correspond to the tip of the percussor may be left on the bone (particularly if all soft tissue has been removed). If this activity is undertaken on an anvil or if the percussor moves slightly as it impacts the bone, **percussion** (or **anvil**) **striae** (Figure 20.10) may result. This activity often produces **inner conchoidal scars** (Figure 20.11) on the medullary cavity surface of the bone shaft and **adhering flakes** on the shaft wall. When the target marrow is in the trabecular portions of the bone, the percussion to this area sometimes creates crushing (Figure 20.12), and when fresh bone fragments are pulled apart forcefully, the result is sometimes peeling, particularly on immature bones and ribs (Figure 20.13). When the fragmented bones are boiled in ceramic vessels in an attempt to render grease, some of the shaft fragments may acquire a peculiar form of abrasion on their tips called **pot polish** (White, 1992).




Figure 20.9 **Percussion pits**. Made by stone hammerstones. Bar: 1 cm. From White (1992).

Figure 20.10 Percussion pits associated with percussion striae on long bone shaft fragments. The co-occurrence of hammerstone and anvil striae with these pits is good evidence of human involvement in the processing of these bones. Bar: 1 cm. From White (1992).





Figure 20.11 Inner conchoidal scars. These were formed when these femoral specimens were fractured for their marrow. Bar: 1 cm. From White (1992).

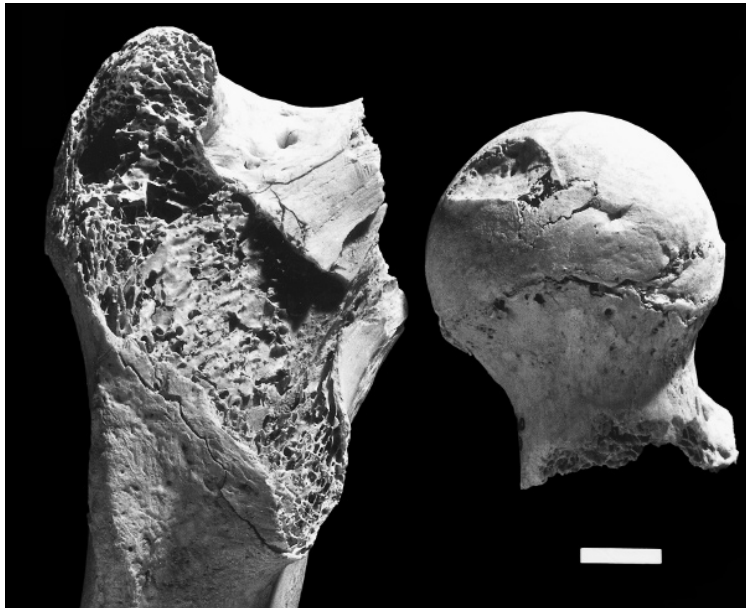


Figure 20.12 **Crushing damage.** When spongy bone is crushed by force, cortex on the adjacent areas is pushed into the crushed area, as in these femoral specimens. Note also the disarticulation cut marks on the femoral neck. Bar: 1 cm. From White (1992).

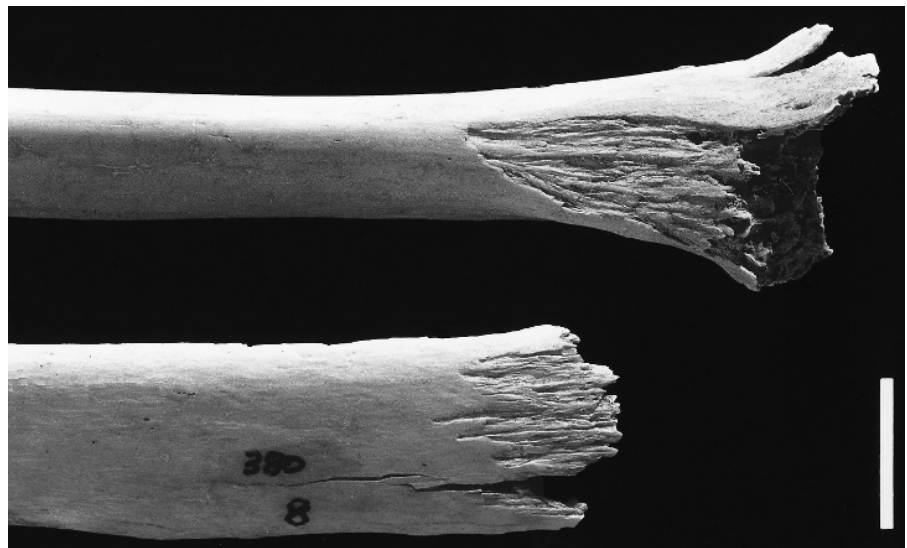


Figure 20.13 **Peeling damage.** Peeling on a juvenile's proximal ulna (top) and an adult's rib (bottom). Bar: 1 cm. From White (1992).

20.4.3 Projectiles

The previous examples of bone modification have been selected from archaeological contexts, but because fresh bone interacts with foreign objects in the same way, the behavioral deductions based on such modifications also largely apply in the modern forensic realm. In this realm, matching bone modifications found on victims of knives and other tools to the tools themselves is sometimes possible and important. High-speed projectiles such as arrows have been modifying human skeletal remains for thousands of years (Figure 20.14). In the modern forensic context, projectiles are most often metal, in the form of bullets of various caliber, or shrapnel (Figure 20.15). The analysis of entry versus exit damage to osteological remains is often critical in forensic investigations. In addition to this bone modification evidence, the radiographic discovery of foreign metal or other objects in skeletal remains often constitutes an additional critical dimension of forensic analysis, and X-radiography of skeletal remains in forensic cases is routine.

Figure 20.14 Projectile point embedded in the ventral surface of a human sternum. No bony reaction is seen, indicating that the event was perimortem, cause of death unknown. Prehistoric California. Natural size.

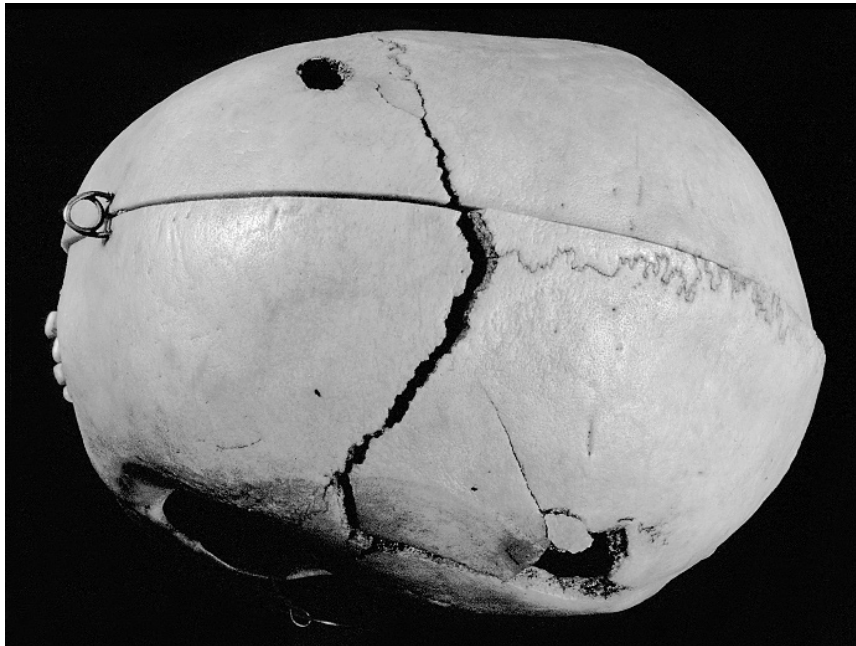


Figure 20.15 Bullet entry and exit wounds. From a modern human homicide victim. Cause of death known from autopsy records. Modern Cleveland. Approximately three-fifths natural size.

Suggested Further Readings

Binford, L. R. (1981) *Bones: Ancient men and modern myths*. New York, NY: Academic Press. 320 pp.
An important book about faunal remains in archaeological contexts.

Bonnichsen, R. and Sorg, M. H. (Eds.) (1989) *Bone modification*. Orono, ME: Center for the Study of the First Americans. 535 pp.

This publication of the results of the First International Conference of Bone Modification is a definitive sourcebook on the subject, with papers on topics related to bone modification in a wide range of settings.

Brain, C. K. (1981) *The hunters or the hunted? An introduction to African cave taphonomy*. Chicago, IL: University of Chicago Press. 365 pp.

A classic taphonomic study of bone assemblages from *Australopithecus*-bearing deposits in South Africa.

- Connor, M. A. (2007) *Forensic methods: Excavation for the archaeologist and investigator*. Walnut Creek, CA: Altamira Press. 272 pp.
A good introduction to many of the techniques used in forensic anthropology. Includes legal issues and crime scene reconstruction.
- Gifford, D. P. (1981) Taphonomy and paleoecology: A critical review of archaeology's sister disciplines. *Advances in archaeological method and theory* 4:365–438.
A comprehensive review of the history and applications of taphonomy.
- Haglund, W. D., and Sorg, M. H. (Eds.) (1997) *Forensic taphonomy: The postmortem fate of human remains*. Boca Raton, FL: CRC Press. 664 pp.
An edited volume that delivers the best available overview of the field.
- Haglund, W. D., and Sorg, M. H. (Eds.) (2001) *Advances in forensic taphonomy: Method, theory, and archaeological perspectives*. Boca Raton, FL: CRC Press. 544 pp.
An international and interdisciplinary perspective on the use of taphonomic techniques in archaeological and forensic contexts.
- Henderson, J. (1987) Factors determining the state of preservation of human remains. In: A. Boddington, A. N. Garland, and R. C. Janaway (Eds.) *Death, decay and reconstruction*. Manchester, UK: Manchester University Press, pp. 43–54.
A brief exposition of the complexities involved in differential preservation of human remains.
- Hunter, J., and Cox, M. (2005) *Forensic archaeology: Advances in theory and practice*. New York, NY: Routledge. 256 pp.
A good overview of the practice of forensic archaeology in the U.K.
- Lyman, R. L. (1994) *Vertebrate taphonomy*. Cambridge, UK: Cambridge University Press. 524 pp.
The essential sourcebook in taphonomy and zooarchaeology. Comprehensive, critical, and authoritative.
- Lyman, R. L. (2008) *Quantitative paleozoology*. New York, NY: Cambridge University Press. 348 pp.
Introduces numeric techniques for determining taxonomic abundance, taxonomic diversity, completeness, element frequencies, fragmentation, and taphonomic statistics in analyses of large faunal assemblages.
- Micozzi, M. S. (1991) *Postmortem change in human and animal remains: A systematic approach*. Springfield, IL: C. C. Thomas. 124 pp.
Concise volume on taphonomic processes.
- O'Connor, T. (2005) *Biosphere to lithosphere: New studies in vertebrate taphonomy*. Oakville, CT: Ox-bow Books. 176 pp.
Case studies are used to illustrate the diverse methodologies used in taphonomic analyses of human and faunal remains.
- Schmidt, C. W., and Symes, S. A. (Eds.) (2008) *The analysis of burned human remains*. Burlington, VT: Academic Press. 296 pp.
An overview of the methods used to interpret the morphological and chemical consequences of burning of human bone.
- White, T. D. (1992) *Prehistoric cannibalism at Mancos SMTUMR-2346*. Princeton, NJ: Princeton University Press. 462 pp.
Chapter 6, "Method and theory: Physical anthropology meets zooarchaeology," is a guide to hominid modification of bone, with many illustrations.

Chapter 21

THE BIOLOGY OF SKELETAL POPULATIONS: DISCRETE TRAITS, DISTANCE, DIET, DISEASE, AND DEMOGRAPHY

SORTING HUMAN FROM NONHUMAN skeletal remains and identifying the remains by element, side, age, and sex are generally the most important contributions the osteologist can make to archaeological research. Such identifications, far from being trivial, are often critical in answering archaeological questions. Additional information, however, can often be obtained from skeletal populations. This information can be crucial in reaching a fuller understanding of the past. The reconstruction of population biology from skeletal remains is an activity that involves potential pitfalls as well as potential benefits for the osteologist.

The aims of **paleoepidemiology** (the study of disease in ancient communities) and **paleodemography** (the study of vital statistics in ancient communities) are to gain knowledge about past populations based on the characteristics of subsets of those populations, including those for whom skeletal remains were recovered. As Waldron (1994, 2007) notes, four extrinsic factors act on dead populations, all reducing the size of the subset available for study. These four factors are extrinsic in the sense that they are independent of the biological features of the cemetery population under study. First, only a portion of those who die are buried at the sites being studied. Second, only a portion of those buried evade destruction. Third, only a portion of the undestroyed are discovered. Fourth, only a portion of the discovered are recovered for the osteologist to analyze. With each of these fractionations, the skeletal subset is biased relative to the sample of people in the original population who actually died. Careful evaluation of such potential bias is critical to accurately reconstructing populational attributes of ancient humans.

In the preceding chapters, emphasis was placed on the identification of skeletal parts at the level of the individual. The identifications of individuals and their sex, age, stature, pathology, and idiosyncratic skeletal characteristics can be critically important in forensic, archaeological, or paleontological contexts. In the archaeological context, however, skeletal remains allow us to take additional steps in anthropological analysis. Such analysis aims to elucidate biological parameters of past human populations, including relatedness, diet, disease, and demography. These are areas of human osteology in which research continues at a rapid pace. The reader can keep current in techniques, protocols, and findings through reference to primary research published in journals such as *The American Journal of Physical Anthropology*, *The Journal of Forensic Sciences*, *Forensic Science International*, and *The International Journal of Osteoarchaeology*.

21.1 Nonmetric Variation

One of the first and most important observations that every osteology student makes is that each human skull is different from every other human skull and can be recognized and differentiated on the basis of size, shape, and various bumps, grooves, foramina, or surface textures. Much of this variation may be partitioned according to the factors responsible for it — age, sex, and pathology. However, much of the variation is idiosyncratic and some of it is attributable to ancestry.

Minor variants of the human skeleton were noted by the ancient Greek scholar Hippocrates, who described Wormian bones in human cranial sutures over 2000 years ago. Nonmetric traits (also called **discontinuous morphological traits**, **epigenetic variants**, or **discrete traits**) are expressions of the variation observed in bones and teeth in the form of differently shaped and sized cusps, roots, tubercles, processes, crests, foramina, articular facets, and other features. El-Najjar and McWilliams (1978), Saunders (1989), and Saunders and Rainey (2008) provide reviews of work on these kinds of features in human osteology. The genetic basis for these traits, particularly nondental ones, remains ambiguous, in large part due to the lack of multi-generational skeletal populations with known pedigrees (Carson, 2006b). Another common complaint concerning the use of nonmetric traits is that their definitions and standards for scoring are inadequate or lacking (Rosing, 1984; Donlon, 2000; Hefner, 2009). Tyrrell (2000) reviews many of the assumptions inherent in studies of nonmetric traits.

Although the labels applied to nonmetric variation imply that it is discrete, this is not necessarily the case. As Mizoguchi (1985) points out, it is rare that nonmetric “traits” are really discontinuous and discrete, even though they are usually scored by osteologists in a nonmetric fashion (as dichotomous presence/absence scores, or as multilevel trait forms). The expression of many of the traits can, indeed, be quantified. Tyrrell (2000) discusses how the influence of a

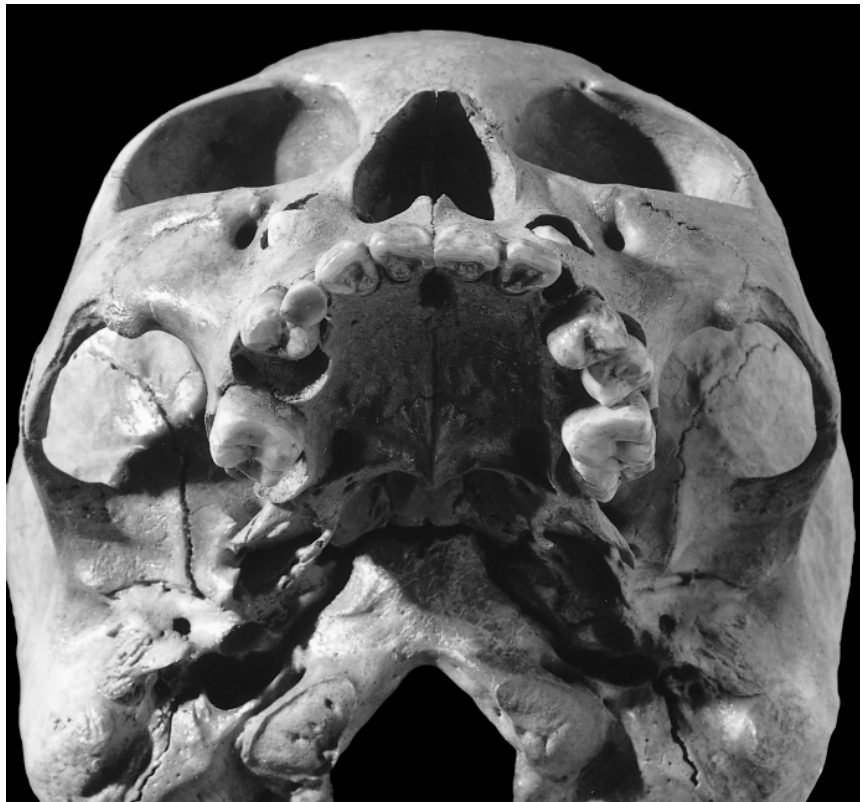

Figure 21.1 Dental nonmetric variations. Note the shoveled incisors on this individual, as well as the misdirected, unerupted (heterotopic) upper canines, which have here resulted in retention of the deciduous canines. The anomaly is bilateral, with the unerupted canine crowns visible through holes in the anterior surface of the maxillae. Prehistoric, California. Natural size.

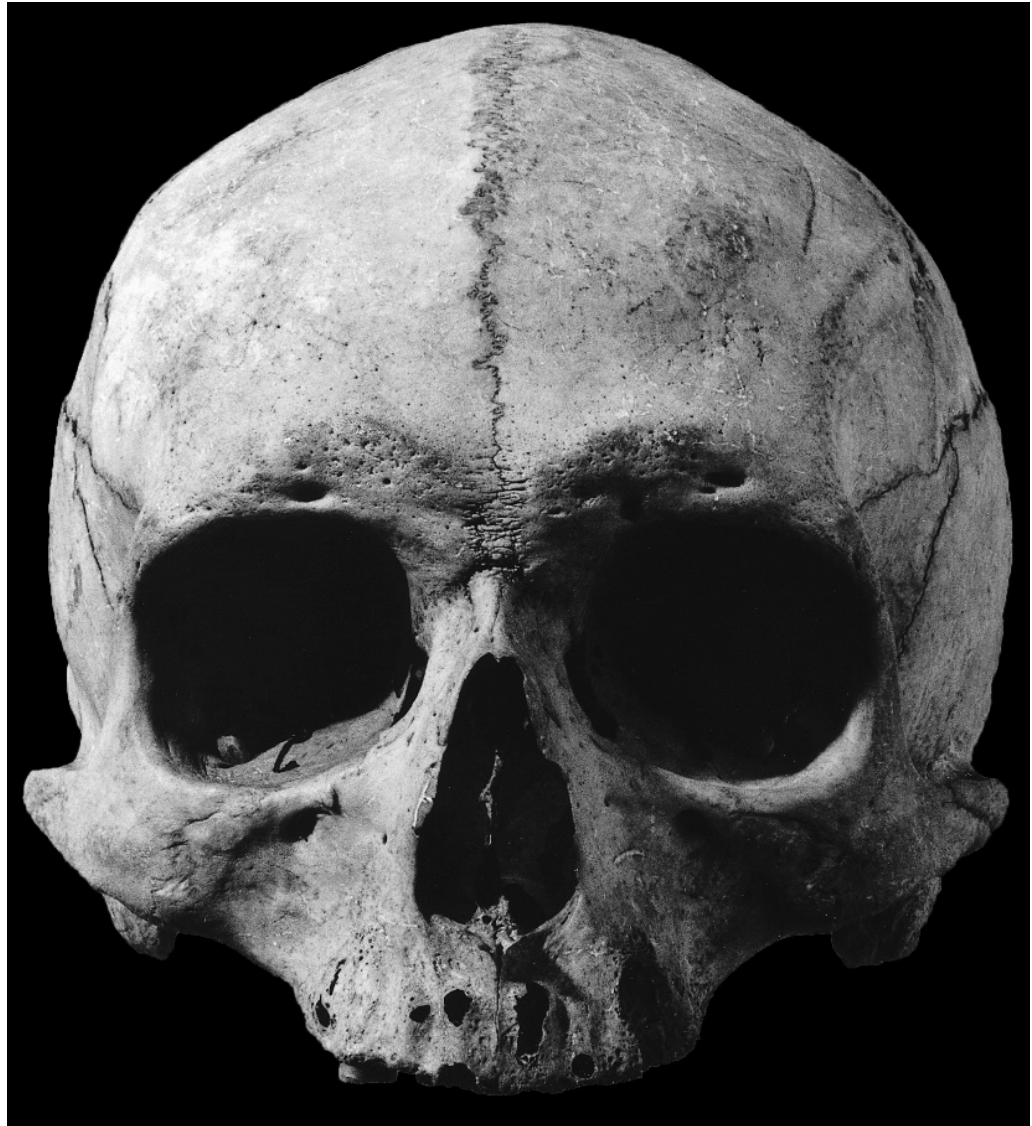


Figure 21.2 Cranial nonmetric variation. A metopic suture has persisted into adulthood in this male individual. Prehistoric, North America. Natural size.

developmental threshold on underlying continuous variation can result in dimorphic or polymorphic phenotypic variants that are incorrectly treated as discontinuous variation.

Despite their shortcomings, dental and skeletal nonmetric traits have been shown to be useful in gauging the affinity of extinct human populations. The kinds of nonmetric variation sometimes described in human osteology and used in assessing population affinity are introduced here (for a more complete review of human skeletal nonmetric traits, see El-Najjar and McWilliams, 1978, and Saunders, 1989). Saunders (1989) divides nonmetric traits into eight categories: 1) hyperostotic; 2) hypostotic; 3) foramina/canals/grooves; 4) supernumerary vault sutures; 5) craniobasal structures; 6) spinal structures; 7) prominent bony processes; and 8) facet variations. The Standards volume (Buikstra and Ubelaker, 1994) recommends gathering data for a limited number of “primary” nonmetric traits, and an optional set of “supplementary” traits, both presented in Table 21.5. Some nonmetric skeletal traits, such as the oval window in the middle ear, have proven valuable to forensic osteologists in establishing “racial” affinities of unknown crania (Napoli and Birkby, 1990).

Table 21.1 Skeletal nonmetric traits*	
<p>PRIMARY TRAITS, CRANIAL</p> <p>Metopic suture</p> <p>Supraorbital notch</p> <p>Supraorbital foramen</p> <p>Infraorbital suture</p> <p>Infraorbital foramen</p> <p>Zygomaticofacial foramina</p> <p>Parietal foramen</p> <p>Sutural bones</p> <p> epipteric bone</p> <p> coronal ossicle</p> <p> bregmatic bone</p> <p> sagittal ossicle</p> <p> apical bone</p> <p> lambdoid ossicle</p> <p> asterionic bone</p> <p> occipitomastoid ossicle</p> <p> parietal notch bone</p> <p>Inca bone</p> <p>Condylar canal</p> <p>Divided hypoglossal canal</p> <p>Flexure of superior sagittal sulcus</p> <p>Foramen ovale incomplete</p> <p>Foramen spinosum incomplete</p> <p>Pterygospinous bridge</p> <p>Pterygo-alar bridge</p> <p>Tympanic dehiscence</p> <p>Auditory exostosis</p> <p>Mastoid foramen</p> <p>Mental foramen</p> <p>Mandibular torus</p> <p>Mylohyoid bridge</p> <p>PRIMARY TRAITS, POSTCRANIAL</p> <p>Atlas bridging</p> <p>Accessory transverse foramina</p> <p>Septal aperture</p>	<p>SUPPLEMENTAL TRAITS, CRANIAL</p> <p>Frontal grooves</p> <p>Ethmoidal foramina</p> <p>Supratrochlear notch or foramen</p> <p>Trochlear spine</p> <p>Double occipital condylar facet</p> <p>Paracondylar process</p> <p>Jugular foramen bridging</p> <p>Pharyngeal tubercle</p> <p>Clinoid bridges or spurs</p> <p>Accessory lesser palatine foramina</p> <p>Palatine torus</p> <p>Maxillary torus</p> <p>Rocker mandible</p> <p>Suprameatal pit or spine</p> <p>Divided parietal bone</p> <p>Os japonicum</p> <p>Marginal tubercle</p> <p>SUPPLEMENTAL TRAITS, POSTCRANIAL</p> <p>Retroarticular bridge</p> <p>Accessory transverse foramen (C3–6)</p> <p>Vertebral number shift</p> <p>Accessory sacroiliac articulation</p> <p>Suprascapular foramen or notch</p> <p>Accessory acromial articular facet</p> <p>Unfused acromial epiphysis</p> <p>Glenoid fossa extension</p> <p>Circumflex sulcus</p> <p>Sternal foramen</p> <p>Supratrochlear spur</p> <p>Trochlear notch form</p> <p>Allen's fossa</p> <p>Poirier's facet or extension</p> <p>Third trochanter</p> <p>Vastus notch</p> <p>Squatting facets, distal tibia</p> <p>Squatting facets, talus</p> <p>Talar articular surface (calcaneus)</p>
<p>* Buikstra and Ubelaker (1994) divide traits into “primary” (for which they provide scoring standards) and “supplemental.” Their Standards volume provides illustrations and a standard recording form recommended for the compilation of data on the “primary” skeletal discrete traits, as well as references to all of these characters.</p>	

21.1.1 Dental Nonmetric Variation

Because teeth are often the most abundant elements in archaeological skeletal series and because tooth size and morphology are often more directly tied to underlying genetics than are other osteological features, teeth have been examined in detail and used widely in osteological analysis. Dental anthropologists use nonmetric variation of tooth crowns to assess biological affinity. Supernumerary teeth, crown fissure patterns, cusp numbers, accessory crown features, and root

number, size, and shape combine with a variety of other traits under the heading of nonmetric dental variation. Dahlberg's casts of dental nonmetric traits, available in many human osteology laboratories, provided a standard for work in this area. The Arizona State University Dental Anthropology System is the current, most widely employed set of standards in dental anthropology (Turner et al., 1991; Scott and Turner, 1997). Figure 21.1 illustrates two nonmetric variants possessed by the same individual. Occasionally there is insufficient space in the jaw for tooth eruption, and **crowding** or **impaction** of teeth are the consequences. These, in turn, can result in pathology of associated soft and hard tissues.

21.1.2 Cranial Nonmetric Variation

A wide variety of nonmetric variants in and between the bones of the skull have been used to differentiate skulls and groups of skulls. A few examples suffice to show the nature of the characters in question: presence or absence of a metopic suture (see Figure 21.2), parietal foramina, extra bones at pterion, wormian bones, multiple mental foramina, and mylohyoid bridges have all been used in nonmetric analyses. El-Najjar and McWilliams (1978) describe 44 such nonmetric traits, Hauser and DeStefano (1989) characterize 84, and Buikstra and Ubelaker (1994) recommend making observations of 21 "primary" cranial nonmetric traits, and list a further 17 "supplementary" cranial nonmetric traits. The traits that Buikstra and Ubelaker consider to be of either primary importance or supplementary are listed in Table 21.1, and details on the scoring of the primary traits are given in Section 4.23.

The importance of cranial nonmetric traits relies on the assumption that these traits are to some extent heritable and can thus be used to investigate ancestry and relatedness. Because of the rarity of skeletal collections of related individuals with known pedigrees, the heritability of nonmetric traits has not extensively tested. In the few studies that have been done (Berry, 1975; Sjøvold, 1984; Carson, 2006b), results have been inconclusive. The effect of cranial deformation on the expression of cranial nonmetric traits has also been investigated as means of determining the degree of environmental plasticity of these traits (Ossenberg, 1970; Pucciarelli, 1974; Konigsberg et al., 1993; O'Loughlin, 2004; Del Papa and Perez, 2007; Van Arsdale and Clark, in press). Del Papa and Perez (2007) found that traits that develop postnatally (*eg.*, sutural bones) are particularly phenotypically variable, and recommend against their use in studies of biological distance.

Developmental anomalies of the skull, such as scaphocephaly (long narrow skulls caused by premature closure of the sagittal suture), have also been considered by some to represent nonmetric variants. Others simply consider them to be developmental anomalies. A skeletal anomaly is usually considered to be pathological if it is selectively disadvantageous to the individual.

21.1.3 Postcranial Nonmetric Variation

Finnegan (1974) found that estimates of biological distance derived from cranial nonmetric traits were highly correlated with distance estimates derived from postcranial nonmetric traits. He suggested that postcranial nonmetric traits might be better suited to analyses of biological distance in archaeological samples because all of the traits used have the possibility of bilateral expression and because the traits are situated on elements that are often preserved in an archaeological context. Finnegan (1978) made observations of the presence of 30 postcranial nonmetric traits on a skeletal sample of known age, sex and ancestry (Terry collection, see Table 18.1). He found no side dimorphism, and found sexual dimorphism in some traits, but at levels lower than that found with cranial nonmetric traits.

Saunders (1978) examined a set of 50 postcranial nonmetric traits to determine which are best suited to analyses of biological distance. She found small inter-trait correlations within the hypostotic and hyperostotic trait groups, and reported that hyperostotic traits were more commonly present on the right side and in males.

Donlon (2000) examined a set of 40 postcranial nonmetric traits, 32 bilateral and 8 midline traits. Nineteen traits remained after excluding traits related to biomechanical adaptations, traits related to pathological conditions, insufficiently variable traits, and traits with high inter-trait associations. In an analysis of these 19 traits, Donlon found close conformity of biological distances with those obtained from genetic markers, but only for female and pooled-sex samples; results for males did not agree with the genetic distances.

Postcranial nonmetric traits still hold much promise, but more work is required to determine the extent to which these traits have a genetic basis. As a reflection of both the potential of and the problems with postcranial nonmetric traits, Buikstra and Ubelaker recommend the recording of data for only three primary postcranial nonmetric traits, listing a further 19 traits as supplementary.

21.2 Estimating Biological Distance

The assessment of affinity (biological relatedness, usually called biological distance or “biodistance”) based on skeletal form has a long history in physical anthropology (Armstrong and Van Gerven, 2003). Larsen (1997) and Mays (2010) provide good reviews of such studies. Osteologists who study the skeletal remains of anatomically modern humans often work on microevolutionary problems. To estimate the degree of biological relatedness between populations, the osteologist works under an important assumption: populations that display the most morphological similarity are the most closely related. The degree to which this assumption is met in practice depends on two major factors: adequacy of sampling, and choice of characters (osteological traits) for comparison (Ubelaker, 1999).

Osteologists observe only samples of biological populations. For osteologists working with archaeological samples, the populations themselves are no longer available for study. Therefore, the strength of osteologically based conclusions about affinity depends on the degree to which the samples accurately reflect the real populations that once existed. The conclusions about relationship can be weakened if the sample is too small or if its composition has been altered in some systematic way. Ubelaker (1999) recommends unbiased adult samples of 100 individuals for each group being compared in biodistance studies. Orton (2000: Chapter 3) gives a good overview of the many assumptions inherent in sampling.

Osteological assessment of the biological distances within and between past populations has traditionally been made on the basis of anatomical traits. These traits should ideally be directly and exclusively controlled by genes. The more susceptible to environmental (including cultural and biomechanical) influence a skeletal trait, the less valuable it is in establishing affinity. For example, flattening of the occipital by the cultural practice of cradleboarding can be observed in distantly related people, but to conclude that two populations manifesting cradleboard-induced occipital flattening were biologically closely related would be misleading. Unfortunately, no single skeletal trait is completely independent of environmental influence.

For several reasons, dentition has been used most effectively to assess relationships between modern and ancient populations. Teeth exhibit a variety of anatomical details that have been demonstrated to be stable through time, to have a high genetic component to their formation, and to differentiate living human populations. Teeth are usually better preserved than bone. In addition, the post-formation effects of environment, gender, and age have less influence on tooth morphology than on most bony anatomy. For these reasons, teeth have figured prominently in reconstructing the biological history of various human populations. Standardization of traits and the methods for scoring them (*e.g.*, Carabelli’s effects, fissure patterns, number of cusps, and incisor shoveling) has considerably facilitated and enhanced the accuracy of dental nonmetric analysis (Turner et al., 1991; Scott and Turner, 1997).

Osteologists have traditionally used both metric and nonmetric traits in their assessments of biological distance between skeletal populations (Pietrusewsky, 2008). Multivariate statistics

Table 21.2 Variation in crown trait occurrence among European American and selected southwestern Native American groups^a

		Hopi	Navajo	Zuni	Apache	Mojave	Euro. Amer.
I ¹	Shoveling	44.8%	53.7%	47.4%	61.3%	64.6%	0.0%
I ¹	Winging	31.4%	23.9%	20.0%	17.2%	32.7%	4.1%
C ¹	Tubercle	73.7%	65.6%	90.9%	73.7%	68.4%	72.0%
M ¹	Hypocone	84.3%	73.5%	70.5%	83.7%	89.6%	90.8%
M ¹	Carabelli's effects	80.3%	61.3%	74.5%	58.3%	72.3%	79.5%
M ¹	Cusp 5	18.9%	21.2%	2.9%	15.4%	6.8%	10.4%
C ₁	Distal accessory ridge	62.7%	44.6%	79.0%	50.0%	65.0%	21.9%
P ₄	Lingual cusp number	15.4%	23.5%	30.4%	17.4%	30.8%	50.9%
M ₁	Deflecting wrinkle	37.8%	39.7%	26.0%	66.7%	48.6%	1.8%
M ₂	Hypoconulid	76.3%	71.4%	57.1%	63.2%	53.3%	13.1%
M ₁	Protostylid	34.4%	35.7%	57.5%	29.2%	25.0%	4.8%
M ₁	Cusp 6	49.8%	44.5%	45.2%	56.2%	9.8%	6.1%
M ₁	Cusp 7	24.6%	18.4%	22.2%	8.2%	26.8%	24.5%

^a Data from Scott and Dahlberg, 1982.

such as discriminant functions, principal components analysis, the mean measure of divergence (MMD), and Mahalanobis' distance (d^2) have been employed with metric data, nonmetric data, or a combination of the two, to gauge the biological distance between populations or other groups of people. Such analyses can give insight into questions such as the relative origins (local versus nonlocal) of the victims of Moche ritual sacrifice (Sutter and Verano, 2007), the origins of the ancient Egyptians (Zakrzewski, 2007; Schillaci et al., 2009), or the details of the peopling of the New World (González-José et al., 2005).

The suitability of using nonmetric traits and select metric variables as proxies for genetic markers, and the appropriateness of using distance statistics based on these data as proxies for genetic divergence, rely on a number of assumptions. Several of these assumptions have been examined and tested previously, but the molecular revolution in osteology has now given researchers the means, at least in principle, to directly evaluate osteological biodistance results against genetic distance data. A number of factors (including, but not limited to: cost, bone quality/preservation, contamination issues, and the destructive nature of osteological DNA testing), still militate against the widespread adoption of genetic analyses in osteological analyses (Mulligan, 2005; Kolman and Tuross, 2000; see Chapter 22), but a few studies have included both genetic and osteological biodistance studies.

In one such example, Ricaut et al. (2010) present data on 63 cranial, dental, and postcranial nonmetric traits from 37 adults buried in the Egyin Gol necropolis in Mongolia, for whom genetic analyses had already been undertaken. Using the Mantel test (a correlation statistic), they compare the nonmetric distance matrix to the genetic distance matrix. They find support for the hypothesis that cranial nonmetric traits can serve as an alternative to genetic markers when "detecting outlier group and/or large familial groupings, involving a large number of subjects," but warn that "nonmetric traits do not possess the resolution necessary to detect close genetic proximities between pairs of individuals."

Other biochemical and geochemical analyses are now also being brought to bear on problems of population origin and movement. Some examples include work on the origin and movements of the Alpine Iceman (Müller et al., 2003), on the tracing of slave-trading routes (Schroeder et al., 2009), on commingled remains from Vietnam (Beard and Johnson, 2000), and on the geographic origin of Peruvian trophy heads (Finucane, 2008).

21.3 Diet

One of the primary goals of archaeological research is the reconstruction of subsistence patterns in past human populations. A multidisciplinary approach is usually taken in this endeavor, with specialists analyzing floral, faunal, and fecal material recovered in habitation sites, and still other archaeologists examining the remains of technology used to exploit different food resources. Such an approach uses information from many disciplines to elucidate the past. The osteologist can make contributions to understanding the diet of prehistoric people by examining skeletal pathologies, analyzing dental wear, and by analyzing the relative concentrations of trace and major elements and isotopes extracted from the skeletal remains themselves.

The interaction between nutrition and skeletal pathology is a complex, difficult subject area and the focus of a great deal of current research. For comprehensive reviews of the topic, see Martin et al. (1985), Larsen (1997) and Ambrose and Katzenberg (2000). Indicators such as Harris lines, dental hypoplasia, and craniodental asymmetries may be used on a populational basis to determine nutritional adequacy in prehistory. Unfortunately, however, stress markers in bone are nonspecific, and only patterns and trends of nutritional stress at the populational level can be ascertained. On the opposite end of dietary reconstruction spectrum, the focus can be individual and the results very specific, for example, when colon contents can reveal a meal (Shafer et al., 1989).

21.3.1 Dental Macrowear and Microwear

Dental macrowear (the overall degree of wear on a tooth) has long been used in attempts to characterize prehistoric diet. Teeth interact directly with foodstuffs, and the physical and chemical composition of food has a direct influence on dental macrowear and decay. Prehistoric people who incorporated large amounts of grit into their diet through food-preparation techniques, such as grinding food between stones, exhibit pronounced dental macrowear. The limitations of using dental macrowear to assess diet are easily understood by considering two imaginary prehistoric populations eating exactly the same diet. If one population used sandstone grinding stones to prepare the bulk of its diet, while the other group used wooden mortars, the rate and nature of dental macrowear would be very different, even though the nongrit content of the diet was identical. Smith (1984) and Schmucker (1985) summarized studies aimed at elucidating prehistoric diet through the analysis of tooth wear, and they both found that hunters and gatherers can be distinguished from farmers on the basis of macroscopic tooth wear.

Dental microwear refers to the microscopic traces of wear (pits and striations) seen in the enamel and dentin on the occlusal surfaces of teeth. The exact relationship of dental microwear to dental macrowear is still unclear (Schmidt, 2010). Whereas early approaches to dental microwear were qualitative, the advent of scanning electron microscopy (SEM) made it possible to carefully study and measure microscopic wear on high-resolution, two-dimensional images of teeth (Ungar et al., 2008; Teaford, 1991, 1994, 2000; Walker, 1981). Because of the time and cost involved in SEM studies, researchers have recently re-evaluated the use of low-magnification light microscopy for microwear analysis (Godfrey et al., 2004, 2005; Rivals and Semprebon, 2006). Both SEM and light microscopy rely on counts and measurements of features on two-dimensional images, and have inter-observer error rates of about 9% (Grine et al., 2002). To address the problems of these approaches, researchers are exploring three-dimensional approaches to quantifying dental microwear. Texture analysis uses white-light confocal microscopy to automatically produce a high-resolution three-dimension point cloud for a tooth surface (Ungar et al., 2003, 2008; Scott et al., 2005, 2006). Scale-sensitive fractal analysis (SSFA) is then used to automatically characterize the topography of the point cloud. This and other three-dimensional approaches will continue to be explored as the field of dental microwear matures. Much recent work has focused on the nutritional and other changes associated with the switch to agriculture (Mahoney, 2006; Watson, 2008; Rose, 2008; Deter, 2009). Reinhard and Danielson (2005) ex-

amine coprolites for phytoliths from desert succulents, and caution that the microwear signature of the switch to agriculture is likely to be confounded by continued episodic reliance on traditional hunter-gather staple foods by the earliest horticulturalists.

As with paleopathology, study of dental wear must be done on a populational basis to yield reliable dietary reconstructions. This is particularly true with microwear analysis because the microscopic signature of the individual's last meal or set of meals may not be indicative of what the average diet was over the life of the individual. More research in this area is required, especially with live animals and dental patients (Teaford, 2000). It is clear, however, that dental microwear study is an important complement to macroscopic wear, bone chemistry, and pathological assessment in dietary analysis.

21.3.2 Caries and Calculus

Dental caries also have a long history of inclusion in studies of ancient diets. Unlike dental wear, however, dental caries are a pathological condition whose incidence is under the influence of many factors, including diet. Powell (1985) reviews the use of dental wear and caries in reconstructing prehistoric diet. Lanfranco and Eggers (2010) warn against the using a simple comparison of caries frequencies for inferring dietary differences, and recommend information on caries location, lesion depth, and level of dental macrowear in analyses.

Dental caries is a disease characterized by demineralization of dental hard tissues by organic acids produced when bacteria ferment dietary carbohydrates (especially sugars). Because carious lesions are readily apparent on teeth, there is a very large literature associated with them, even for prehistoric populations. Osteologists have been studying temporal trends in caries since the 1800s. Changes in processing technology and food had important implications for the oral health of past human populations. The incidence of caries has been shown to be generally higher in agricultural than in hunting and gathering economies (*eg.*, Temple and Larsen, 2007). Cariogenic foods obviously lead to a higher prevalence of caries in a population. Within a population, sex and status differences in the amount of cariogenic food eaten may play important roles in determining the frequencies of caries (Walker and Hewlett, 1990). Larsen (1997) reviews the use of caries frequencies in studies of modern and archaeological skeletal samples.

Several studies (*eg.*, Hardy et al., 2009; Boyadjian et al., 2007; Henry and Piperno, 2008) have begun to explore the potential of dietary microfossils (starch granules and phytoliths) preserved within dental calculus. Whereas food residues like starch granules can be collected from archaeological tools used to process some foods, these residues are often diagenetically altered. Dental calculus, however, traps phytoliths and starch granules within a concreted matrix, protecting the microfossils from biochemical alteration and allowing for genus- or even species-level identification of the plants from which they derive (Hardy et al., 2009; Boyadjian et al., 2007).

21.3.3 Chemical Analyses

Developments in the chemical analysis of osteological remains have opened new windows on the past. Analysis of trace elements and stable light isotopes in human osteology has played an increasingly important role in dietary reconstruction over the last 30+ years (for reviews, see Price, 1989; Sandford, 1993; Schoeninger, 1995; Larsen, 1997; Sandford and Weaver, 2000; Bentley, 2006; Burton, 2008; Katzenberg, 2008; and Lee-Thorp, 2008).

Traditionally, the issues of diet and affinity have been approached in human osteology via morphological assessment. More recently, however, the application of chemical analyses of osteological remains from archaeological contexts has been added to the osteologist's toolkit. By taking a tiny sample of bone tissue, a researcher can convert the sample into a gas and measure its isotopic compositions with a mass spectrometer. These isotopic ratios can be compared between skeletal individuals, allowing evaluation of subsistence changes through time by direct reference

to the chemical composition of skeletal remains. As Larsen (1997) notes, documentation of diet in the past provides the context for studies of growth, stress, disease, and subsistence activities. Conventional approaches to diet utilized archaeological materials, particularly plant and animal remains. The archaeological record has long been known to be biased in its preservation of food remains, however, and plant remains often approach invisibility due to difficulties in preservation. Having an independent and objective means to generate consumption profiles of different foods eaten in the past is therefore very valuable.

Organisms comprise common elements such as hydrogen (H), carbon (C), oxygen (O), nitrogen (N), calcium (Ca), and less common (trace) elements such as strontium (Sr). Elements can occur as different isotopes, which differ from each other in the number of neutrons they possess. For instance, carbon occurs naturally in three isotopic forms: ^{12}C , ^{13}C , and ^{14}C . Isotopes with too many or too few neutrons (relative to protons) are unstable and prone to decay into lighter, more stable isotopes. ^{14}C is an unstable isotope of carbon whose decay forms the basis of radiocarbon dating. Lighter isotopes (*eg.*, ^{12}C relative to ^{13}C) break and form chemical bonds more rapidly than heavier isotopes. These facts of chemistry mean that ratios of the stable isotopes can be examined in efforts to deduce aspects of ancient ecology and human behavior, including diet. Carbon and nitrogen are the elements that have received the most attention in studies of human osteological isotopic chemistry, but work is also being done on isotopes of hydrogen (Reynard and Hedges, 2008) and oxygen (White et al., 2004), and it is possible that sulfur may also one day be able to yield paleodietary information (Lee-Thorp, 2008).

Both stable light isotopic forms of carbon (^{12}C and ^{13}C) are found in mammalian bones. The ratio of the heavier isotope (^{13}C) to the lighter isotope (^{12}C) is compared to an international standard ratio. The difference between the ratio found in the sample and the standard ratio is expressed as the isotopic “delta value,” or $\delta^{13}\text{C}$. The value of $\delta^{13}\text{C}$ in mammalian bones reflects diet (*eg.*, plant tissues consumed during life). Plants use two photosynthetic pathways. The so-called C_3 plants discriminate against the heavier isotope of carbon, and thus their tissues are enriched in ^{12}C . Organisms eating more of these plants will therefore have negative $\delta^{13}\text{C}$ values based on their bones. Maize and other C_4 plants do not discriminate as much and have more of the heavier isotope, increasing the ratio of carbon isotopes in the bone collagen of consuming organisms and resulting in positive $\delta^{13}\text{C}$ values. Similarly, the heavier ^{15}N isotope of nitrogen concentrates as it travels up through the food chain. Marine plants have higher concentrations of this isotope than land plants, and animals higher up in the marine food chain have, as a consequence, higher $\delta^{15}\text{N}$ values in their bones. People feeding on marine mammals are thus expected to have higher $\delta^{15}\text{N}$ values than those subsisting on terrestrial food sources. Thus, the isotopic compositions of the bone tissue are useful indicators of diet.

The initial chemical studies of bone (in the 1970s) were received with great enthusiasm because the techniques appeared to provide direct quantitative means for reconstructing diet (Sandford, 1993). By the 1980s, trace element and stable isotope research was heralded as a breakthrough, and more researchers began to conduct these studies. As Sandford (1993) notes, however, the early optimism was soon curbed by studies that demonstrated that elemental concentrations are influenced by many complex and often-interrelated processes. By the late 1980s authors were already referring to the “abuse of bone analyses for archaeological dietary studies” (Hancock et al., 1989) and proclaiming that there were “no more easy answers” (Sillen et al., 1989).

During life, elemental deposition in the skeleton is governed by more than just the abundance of elements in the diet. After burial, bones can be subjected to diagenesis. Concerns over how these variables influence the chemical composition of bone have generated a great deal of additional research. The initial reaction was generally negative, as exemplified by Radosevich’s comment (in “The Six Deadly Sins of Trace Element Analysis: A Case of Wishful Thinking in Science,” 1993: 318) that: “It is possible that a viable field of trace element analysis of bone in this field can still be constructed, but examinations of basic geochemistry and taphonomy of soil-buried bone must be carried out first, not as an afterthought.” Ambrose (1993) agreed in principle, noting that studies of stable isotopes have been developed mostly in geochemistry and plant physiology rather than in anthropology. Nearly two decades of subsequent research has clarified many of

these uncertainties, restoring confidence in isotopic research in anthropology. For example, research has now revealed that the signature of dietary protein is primarily deposited in collagen, whereas the signature of nonprotein dietary components is primarily stored in apatite carbonites (Katzenberg, 2008). Research into improved sampling locations (Jørkov et al., 2009) and extraction methodologies (Jørkov et al., 2007) has also been undertaken. Research is also being conducted to compare the $\delta^{13}\text{C}$ and $\delta^{15}\text{N}$ values from specific bone collagen amino acids within the same individual as a means of increasing the specificity of identifications of dietary components (Corr et al., 2005; Kellner and Schoeninger, 2007; Naito et al., 2010).

Using analyses of isotopic chemistry, substantial insights into prehistoric diet and land use have been achieved in several areas: the circumstances and timing of the introduction of C_4 plants such as maize (Carpenter et al., 2002; Coltrain et al., 2007); the demonstration that diets of high-status individuals were different from lower-status individuals in some societies (Ubelaker et al., 1995; Linderholm et al., 2008); the exploitation of marine versus terrestrial food sources (Richards et al., 2005); and even the timing of weaning from breast milk (Fuller et al., 2006). Dawson and Siegwolf (2007) and Schwarcz et al. (2010) provide recent overviews of these applications. As with the use of biomolecules in human osteology, stable isotope and trace element analyses require thorough grounding in chemistry, biochemistry, physiology, physics, and other laboratory sciences.

21.4 Disease and Demography

The study of populations, **demography**, is concerned with the vital statistics of populations — life expectancy, mortality rates, birth rates, and population growth, size, and density. Demographers interested in modern people use data collected by census takers who census the living. **Paleodemography** is the study of the demography of prehistoric populations. The vital statistics of these populations can be reconstituted by use of their skeletons. The osteologist can reconstruct these populations by censusing the dead. A major assumption used here by the osteologist is that the rates of growth and aging established for modern humans can be applied appropriately to individuals who lived in the distant past. The more ancient the populations under study, the less valid this assumption is likely to be.

The reliability of demographic reconstructions built on skeletal material depends on the accuracy of individual age and sex estimations of the skeletons. Wittwer-Backofen et al. (2008) demonstrate the difficulties inherent in estimating ages in archaeological material. In addition, their reliability depends on how accurately the sample of skeletons represents what was once the living population. Van Gerven and Armelagos (1983), Greene et al. (1986), Boddington (1987), Bocquet-Appel and Masset (1982), Wood et al. (1992), Jackes (1992, 2000), Konigsberg and Frankenberg (1994, 2002), Chamberlain (2000), Milner et al. (2000), Hoppa and Vaupel (2002), Wright and Yoder (2003), and Bocquet-Appel (2008) provide good reviews of the assumptions and limitations of archaeological data in demographic reconstructions. Figure 21.3 is an illustration of a large cemetery excavated during the 1960s in the midwestern United States. Here, 1327 articulated skeletons were recovered, ranging in age from *in utero* individuals to elderly adults. The excavators estimate that this represents a 300-year occupation (Lovejoy et al., 1985a).

To better understand the constraints and limitations of demographic reconstructions based on skeletal remains, imagine an ancient population in which all of the dead were buried in a single cemetery over the span of 100 years. In this imaginary case, no people died away from home or were cremated or were eaten by carnivores. None of the skeletons were disturbed after burial by biological or physical agents. Furthermore, imagine that the entire cemetery was preserved intact through the centuries. Finally, imagine that all of it was excavated and that all of the individuals, including very young infants, were recovered. Provided that recovery was complete, record keeping was good, none of the skeletal material was lost subsequent to excavation, and the osteologist could accurately age and sex all of the individuals, these data might be used directly to reconstruct demographic attributes of the population.

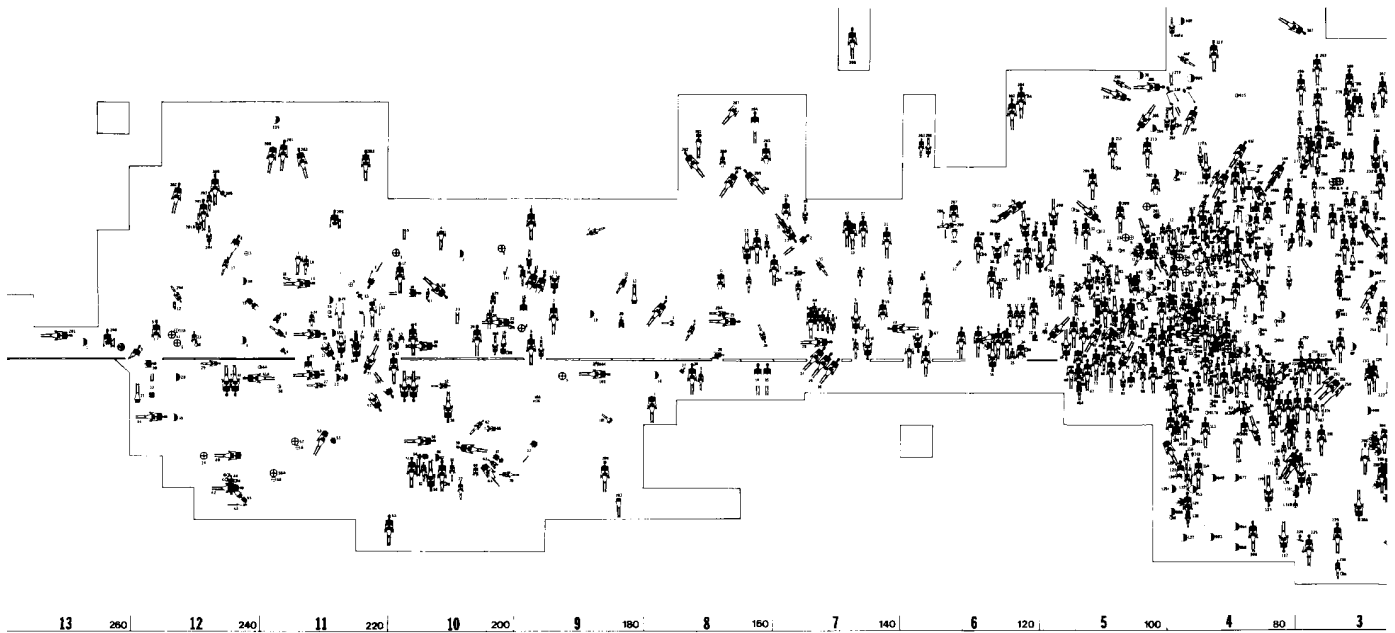


Figure 21.3 Plan of the prehistoric Libben site, Ottawa County, Ohio. Studies of skeletal populations such as this one can lead to insights into demographic aspects of early human populations. The area in bold outline is a blowup of part of the plot. From Lovejoy et al. (1985a).

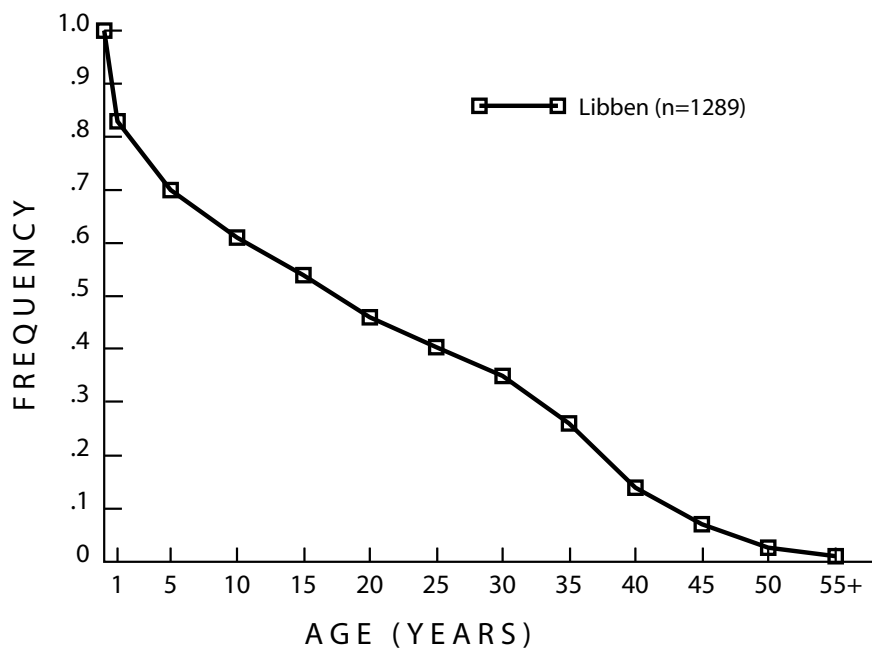
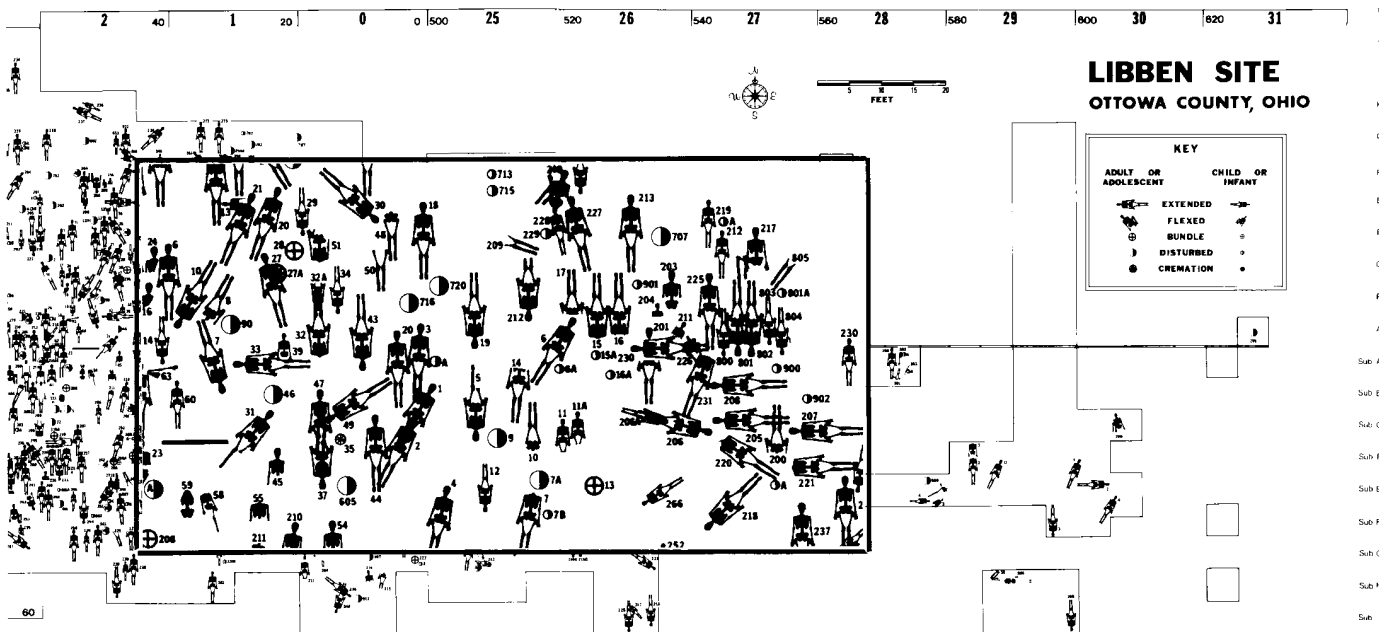


Figure 21.4 Survivorship curve based on the prehistoric Libben skeletal population. Data from Lovejoy et al. (1977).



In traditional paleodemography, the calculations involved in demographic reconstructions from skeletal remains are quite simple (eg, Ubelaker, 1989). For example, consider survival through time, beginning with live births. At birth, survival would be 100%. By age 5, with high infant mortality, perhaps only 60% of the original population would have survived. This would mean that 40% of the cemetery population would have been made up of children in the 0- to 5-year-old age range. By plotting the age estimates for these and the other burials in 5-year intervals through time, one could reconstruct a survivorship curve for the population (see Figure 21.4), examine survivorship by sex, or make deductions about life expectancy in the population. Meindl et al. (2008), however, point out that paleodemographic reconstruction is not this simple; rates of intrinsic population growth, female total fertility rate, and the incidence of infanticide, all of which are interrelated, must also be taken into account.

Bocquet-Appel and Masset (1982) were among the first to take a critical look at the practice of traditional paleodemography. They noted that the age-at-death profiles of prehistoric populations are artifacts of the age distributions of the modern skeletal collections upon which skeletal aging methods are based. They also noted that the low correlation between skeletal age and chronological age in humans leads to an inherent inaccuracy in all skeletal age estimates. Over the next two decades, concerns about the inherent assumptions of traditional paleodemography and the validity of traditional paleodemographic methodologies continued to grow.

In 1999, an international workshop to address many of these concerns was held in Rostock, Germany (Hoppa and Vaupel, 2002). The result was the “Rostock protocol,” a set of methodological improvements to paleodemography that can correct for age biases using maximum likelihood analysis and Bayesian inversion to produce unbiased age estimates.

It is important to be able to derive demographic information about past human groups. One must note, however, that accurate and reliable demographic reconstruction can only be achieved when all of the required parameters are known or can be reasonably estimated. Most archaeologically derived skeletal samples do not meet the conditions of the imaginary example given above, and survivorship curves that they generate are prone to systematic error as a result. For example,

many human groups differentially dispose of the dead. If there is bias in their burial practices, the demographic profile of that population cannot be determined accurately. Many cemeteries show differential preservation that favors young adult individuals over children or elderly adults because bones of the former are stronger and less prone to destruction by taphonomic agents [evidence for bias due to preservation can be found by careful analysis of the sample (Walker et al., 1988)]. Many cemeteries are excavated nonrandomly or are sampled incompletely. Only intact specimens are saved subsequent to collection in many archaeological excavations. Many skeletal samples are curated poorly, with the loss of much material. In short, most archaeologically derived skeletal populations are inadequate to provide accurate paleodemographic reconstructions. If an understanding of paleodemographic aspects of ancient populations is the goal of a research project, it is imperative that the osteologist work closely with the archaeologist to ensure that sampling strategy does not bias the ultimate results.

Waldron (1991: 24) expresses the linkages and pitfalls of studying demography and disease in skeletal populations as follows:

The underlying assumption that is inherent in any attempt to use a death assemblage to predict something about the living is that the dead population is representative — or at least typical — of the live population. Given all the non-random events that surround death and burial, not to mention preservation and recovery, this is at best an approximation, and at worst the two (the live and the dead) bear no epidemiological relation to each other whatsoever. However, it is clearly important to know where on this spectrum a particular group, or set of groups, lies, especially if the data derived from their study are to be used to construct life tables, to make inferences about changing patterns in disease or dietary habits, or to draw any of the other demographic conclusions that are so commonly bandied about.

The relationship between adoption/intensification of agriculture and population size and health has been an object of anthropological inquiry for several decades. Paleodemographic and paleopathological data have been brought to bear on this subject for many years, and in the early 1990s, the idea that agriculture brought with it a decreased quality of life and increased mortality rates was widely accepted. Then, in a sobering and influential contribution, Wood and colleagues (1992) reminded anthropologists that the study of prehistoric populations and their health is a complex undertaking, never straightforward or simple. These authors question a basic assumption made by many osteologists concerning lesions found on skeletal remains. They argue that rather than reflecting declining community health, such lesions indicate that the affected individuals survived some disease, that such survival might actually indicate an *improvement* in health, and that individuals who lived long enough to manifest pathological lesions on their skeletons were advantaged relative to people who succumbed to disease before their skeletons were affected. Furthermore, these authors note that large numbers of immature skeletons may indicate more about fertility than mortality. These observations are in sharp contrast to the received wisdom in paleopathology and paleodemography. How, then, are osteologists to interpret paleopathology on a populational basis? Wood et al. (1992) considered the skeletal evidence pertaining to the transition from hunting and gathering to settled agriculture to be equally consistent with either an improvement or a deterioration of health (see also Cohen, 1994), concluding that considerably more critical research is required. Nearly a decade ago the “Global History of Health Project,” an ambitious meta-project to facilitate the collection of standardized indicators of health, was launched. Based on the data produced in the first years of this project, Larsen (2006) concluded that “the change in diet and acquisition of food resulted in a decline in quality of life for most human populations in the last 10,000 years” (see also Gibbons, 2009).

Applying human skeletal data from historic and prehistoric contexts to important questions about culture and biology is an important avenue of anthropological investigation. Decades of such application have brought an increased understanding of the complexities involved in such studies. It is clear that anthropologists will continue to use skeletal populations in efforts to better understand the past and will do so with increasingly sophisticated techniques and heightened cautions built upon a better appreciation of the fragmentary and biased nature of the records that they study.

Suggested Further Readings

Bailey, S. E., and Hublin, J.-J. (Eds.) (2007) *Dental perspectives on human evolution: State-of-the-art research in dental paleoanthropology*. New York, NY: Springer. 409 pp.

Detailed volume on dental morphology, variation, pathology, and wear in modern and ancient populations. Techniques such as neural network analysis, micro-CT, and strontium-calcium ratio analysis are explored.

Bocquet-Appel, J.-P. (Ed.) (2008) *Recent advances in palaeodemography: Data, techniques, patterns*. Dordrecht, Netherlands: Springer. 294 pp.

Current methods and tools used in paleodemography are explored through papers that were presented at the 25th World Population Conference.

Chamberlain, A. T. (2006) *Demography in archaeology*. Cambridge, UK: Cambridge University Press. 256 pp.

Review of current methods used in the study of demography. Includes techniques used in exploring historic, ethnographic, and archeological lines of evidence.

Hoppa, R. D., and Vaupel, J. W. (2002) *Paleodemography: Age distributions from skeletal samples*. New York, NY: Cambridge University Press. 276 pp.

An important edited volume that introduces the Rostock protocol for obtaining unbiased age estimates, as well as other modern paleodemographic techniques.

Howells, W. W. (1989) Skull shapes and the map: Craniometric analyses in the dispersion of modern *Homo*. *Papers of the Peabody Museum of Archaeology and Ethnology* 79:1–189.

This monograph by the dean of craniometric analyses assesses the evolutionary divergence in cranial shape among different geographic areas.

Katzenberg, M. A., and Saunders, S. R. (2008) *Biological anthropology of the human skeleton* (2nd ed.). New York, NY: Wiley-Liss. 680 pp.

Part 4 (Chemical and Genetic Analyses of Hard Tissues) and Part 5 (Quantitative Methods and Population Studies) of this edited volume are of special interest.

Larsen C. S. (1997) *Bioarchaeology: Interpreting behavior from the human skeleton*. Cambridge, UK: Cambridge University Press. 461 pp.

A comprehensive summary of all aspects of bioarchaeology: the standard volume in the field.

Lewis, M. (2009) *The bioarchaeology of children: Perspectives from biological and forensic anthropology*. Cambridge, UK: Cambridge University Press. 268 pp.

An introduction to the osteology, paleopathology, and paleodemography of children.

Mays, S. (2010) *The archaeology of human bones* (2nd ed.). London, UK: Routledge. 432 pp.

Focuses on the analysis of bones from archaeological contexts. Includes a chapter dedicated to DNA analyses, as well as a chapter on isotope studies.

Mellars, P., Boyle, K., Bar-Yosef, O., and Stringer, C. (Eds.) (2007) *Rethinking the human revolution: New behavioural and biological perspectives on the origin and dispersal of modern humans*. Oakville, CT: McDonald Institute for Archaeological Research. 436 pp.

A compendium of current research including advances in demographic theory, presented at the 2005 conference “Rethinking the Human Revolution.”

Scott, G. R., and Turner, C. G. (1997) *The anthropology of modern human teeth: Dental morphology and its variation in recent human populations*. New York, NY: Cambridge University Press. 382 pp.

A comprehensive look at how teeth can be used to assess population biology.

Teaford, M. F. (1991) Dental microwear: What can it tell us about diet and dental function? In: M. A. Kelley, and C. S. Larsen (Eds.) *Advances in dental anthropology*. pp. 341–356. New York, NY: Wiley-Liss.

This paper summarizes work on the microwear of mammalian teeth, providing a good summary of the accomplishments and goals of using dental microwear to establish diet in extant and skeletal populations.

Ubelaker, D. H. (2008) *Human skeletal remains: Excavation, analysis, interpretation* (illust. ed.) New Brunswick, NJ: Aldine Transaction. 146 pp.

Chapter 5 provides a concise review on prehistoric population dynamics.

Ungar, P. S. (Ed.) (2007) *Evolution of the human diet: The known, the unknown, and the unknowable*. New York, NY: Oxford University Press. 413 pp.

A recent survey of the current state of research into prehistoric diets.

Verano, J. W., and Ubelaker, D. H. (Eds.) (1992) *Disease and demography in the Americas*. Washington, DC: Smithsonian Institution Press. 294 pp.

An edited volume to commemorate the Columbus Quincentenary by examining the effects of Europeans contacting New World populations. The contributions of skeletal studies to this field are summarized by leading experts for all regions of North and South America.

Waldron, T. (1994) *Counting the dead: The epidemiology of skeletal populations*. West Sussex, UK: John Wiley and Sons. 124 pp.

An excellent introduction and critical evaluation, useful in paleodemography and paleopathology.

Waldron, T. (2007) *Paleoepidemiology: The measure of disease in the human past*. Walnut Creek, CA: Left Coast Press. 150 pp.

A clear and approachable introduction to the concepts of epidemiological analysis in an archaeological context.

Chapter 22

MOLECULAR OSTEOLOGY

TRADITIONAL METHODS FOR analyzing skeletal remains are based on examining the sizes and shapes of bones. Accelerating advances in other fields have given rise to a new set of methods that allow the osteologist to analyze the molecular constituents of bone. Under certain conditions, skeletal remains retain sufficient quantities of DNA, amino acids, proteins, and/or various isotopes to permit their recovery and analysis. The techniques used are often complex and require specially equipped laboratory facilities. Contamination and diagenesis can confound the results (Nicholson et al., 2002). However, the accuracy and precision of the results obtained may be superior to those of traditional methods, depending on the question. Molecular methods are thus becoming the methods of choice for various types of osteological analysis. Even so, these techniques are best applied as part of an overall osteological analysis rather than in isolation.

DNA analysis, in particular, allows the bioarchaeologist or forensic osteologist to address questions that are beyond the range of morphological methods. Such methods are also finding application in paleontology, as seen in the recovery of both mitochondrial and nuclear DNA from Neanderthals (see Section 22.2.4).

As molecular biologists develop ways to extract more information from modern DNA, the types of questions that can be addressed with ancient DNA are expanding as well. For reviews, see Kaestle and Horsburgh (2002) and Pääbo et al. (2004). Currently, there are four major questions about a deceased individual that DNA analysis of skeletal remains can potentially address: sex, pathology, ancestry, and individual identity. Isotopic techniques can shed light on diet and potentially residence patterns.

22.1 Sampling

The use of new high-tech molecular methods does not mean that the fundamentals of proper recovery, preparation, and documentation of skeletal remains can be ignored. Indeed, mistakes made during the sampling of material for molecular analysis can seriously compromise results. In addition to the standard set of recommendations for recovery and documentation of skeletal remains (Chapter 15), investigators wishing to obtain good samples for molecular analysis should consider the following:

- **Potential contamination.** If molecular analysis is to be employed on newly recovered skeletal material, recovery procedures should be modified to minimize contamination of

the remains by modern compounds and modern humans. The specific procedures will depend on the nature of the site, the available time and resources, and the type of analysis planned. For DNA analysis, these would ideally include using disposable latex gloves and hair nets, and sterilizing excavation tools. If this is not practical for the entire sample, a reasonable compromise may be to employ such procedures on the specific elements destined for DNA analysis. Remember that all specimens should be protected against contamination and degradation. The Armed Forces DNA Identification Laboratory (AFDIL) has particular guidelines that cover these topics and many others.

- **Taphonomic alteration.** The exposure of skeletal remains substantially alters their environment. This may, in turn, lead to further decay of their molecular constituents. Currently, little is known about the effects of preservatives and changes in temperature, humidity, moisture, and air circulation on the preservation of various biomolecules. Until more information is available, the wisest course is to minimize the magnitude of such changes as much as is practical. Consulting with the specialist who will be conducting the molecular analysis is advisable.
- **Provenience of sample.** The evaluation of the accuracy of molecular analyses depends in part upon proper documentation of the provenience of the samples. If molecular analysis is to be employed on newly recovered skeletal material, particular attention should be paid to properly documenting both the context of the remains and the excavation methods employed. Depending on the type of analysis planned, it may be advisable to obtain soil samples from the area surrounding the elements to be analyzed. Here again, consultation with the appropriate specialist is crucial.
- **Selection of sample.** Whether the molecular methods are to be applied to newly recovered skeletal remains or to museum collections, the choice of which specimens to sample must be made carefully. Because molecular techniques are typically destructive, specimens for sampling should be chosen to minimize the morphological information lost while maximizing the potential information gained in the molecular analysis (DeGusta and White, 1996). In order to adequately weigh these often-competing goals, it is imperative that the skeletal remains first be examined for signs of pathology, bone modification, and other morphological variations. Only then can an accurate assessment be made of the “morphological value” of the skeletal specimens and of the various portions of individual specimens. It is often useful for molecular analysis to be first attempted on nonhuman remains or on human specimens of dubious provenience to establish the feasibility of the method prior to the destructive sampling of more valuable specimens.
- **Pre-sampling documentation.** Removal of skeletal tissue for molecular analysis destroys information about the morphology of the bone, but this loss can be reduced greatly by proper documentation prior to sampling. The exact methods employed to record the morphology will depend on the anticipated degree of destruction and the importance of the specimen. Minimally, high-quality photographs (with a scale bar) should be taken prior to sampling. Molding and casting of specimens provide a three-dimensional record of the morphology, as does 3-D laser scanning. This, in combination with photographs and potentially also radiographs, minimizes the loss of information. Documentation only preserves morphological information if it remains permanently accessible, so casts and photographs of the relevant specimens (along with copies of the results of the molecular analysis) should be deposited properly and promptly in the appropriate archives.

22.2 DNA

Deoxyribonucleic acid (DNA) is the molecule of heredity. The genetic code in DNA is based on four chemical building blocks called nucleotides: adenine, cytosine, thymine, and guanine. These nucleotides can be thought of as forming a four-letter alphabet that spells out the assembly instructions for all the proteins that make up an organism. Almost every cell in a person's body has a complete copy of their DNA, and all these copies are essentially identical.

There is a tremendous amount of research aimed at extracting various types of information from DNA, in part because many diseases are thought to have a genetic component. In a biomedical context, specific diseases such as Huntington's disease and sickle cell anemia can be diagnosed based on DNA alone. The sex and general ancestry of an unknown individual can be determined from DNA. Comparisons of DNA samples can be used to establish identity and paternity. Brown (2000) provides an overview of the application of "ancient DNA" studies to human osteology.

The ability to determine sex, ancestry, disease status, and identity from DNA has obvious applications in osteology, forensics, archaeology, and even paleontology. These applications, though, all depend on the ability to obtain DNA from organic remains of varying antiquity. After an organism dies, the highly organized molecules of DNA degrade rapidly. The key conceptual breakthrough that led to the field of ancient DNA was the recognition that despite this decay, fragments of DNA are sometimes present in remains of great antiquity. With only a few modifications, existing techniques for isolating modern DNA can also be used to retrieve this DNA (Kolman and Tuross, 2000). These techniques originally required a large amount of preserved DNA, a criterion met only in cases of exceptional preservation (*eg.*, mummies or ice-embedded animals).

22.2.1 PCR and methodology

Development of the **polymerase chain reaction (PCR)** made it possible to retrieve exponentially smaller amounts of DNA (Bartlett and Stirling, 2003). In order to analyze DNA, it is necessary to have a sufficient quantity of it. Using conventional techniques, even a dozen molecules of DNA are effectively invisible—they are too small to detect. The PCR acts as a "molecular photocopy machine" by making literally millions of copies of a section of DNA. This is referred to as amplification, and PCR can amplify a section of DNA starting from only a few original molecules. The large amount of DNA yielded by the method can then be analyzed quite easily using a variety of standard techniques. Using PCR, researchers were able to retrieve DNA from ancient skeletal remains (Hagelberg et al., 1989). This advance made ancient DNA methodology applicable to a broad range of questions in osteology.

The general methodology for obtaining and analyzing DNA from a bone or tooth involves three general stages. First, the DNA must be extracted and isolated. This involves reducing about a gram of bone or tooth to powder. The powder is then treated chemically to remove proteins and other compounds and to concentrate the DNA. Second, a predetermined section of the DNA is amplified using PCR. Finally, the resulting DNA sample is analyzed, typically by determining its nucleotide sequence. Knapp and Hofreiter (2010) examine the applicability of the "next generation sequencing" techniques to ancient DNA. Navascués et al. (2010) examine the problems inherent in comparing ancient DNA to modern DNA using analytic software designed according to panmictic assumptions (*i.e.*, contemporaneous populations of equally potentially interbreeding individuals).

22.2.2 Contamination

Despite the exciting potential of ancient DNA, the applications are still limited by methodological difficulties (Cooper and Poinar, 2000; Gilbert et al., 2005). The major problem is contamination by exogenous DNA (DNA not from the targeted individual). Living organisms are con-

stantly shedding DNA-bearing tissues in the form of skin cells, hair, saliva, and other secretions. Archaeological skeletal remains risk being contaminated by the DNA from organisms in the soil, microorganisms growing within the bones, excavators, curators, or even the DNA analysts themselves. The problem of contamination is worsened by the nature of PCR. The polymerase chain reaction preferentially amplifies well-preserved DNA molecules, which are more likely to be modern contaminants than truly ancient DNA. Because PCR produces large amounts of highly concentrated DNA, laboratories often encounter problems with the products of previous PCR reactions contaminating current work. Contamination is of extreme concern when attempting to retrieve DNA from ancient human remains, as humans are also the main source of exogenous DNA, making contamination more difficult to detect. Several published DNA sequences from very ancient remains are now widely held to be inauthentic (Lindahl, 1997). Because the materials used for the extraction of DNA are often unique, and the analysis is time consuming, independent replication of results is not always carried out. A number of techniques have been developed to reduce the chances of contamination occurring, and to increase the likelihood of the contamination being recognized. The independent verification of ancient DNA results is also becoming more common. So, whereas contamination will likely continue to be of concern, the body of reliable ancient DNA work will also continue to expand.

22.2.3 Taphonomy of DNA

Beyond a certain time period, perhaps 100,000 years (Poinar et al., 1996), no DNA is likely to be preserved in skeletal remains. Within that time range, the factors leading to preservation are not well understood. For example, some skeletal remains may yield DNA, whereas other remains, of similar antiquity or even younger, may not. The specifics of death, burial, and **diagenesis** (a change in the chemical, physical, or biological composition of bone subsequent to death; see Chapter 20) that result in the preservation of DNA in some cases, but not in others, are unknown. The preservation of DNA does seem to be primarily influenced by environmental conditions rather than by time, at least for remains younger than about 10,000 years (Parsons and Weedn, 1997). Bones and teeth that are macroscopically and microscopically well-preserved seem somewhat more likely to yield DNA. Empirical evidence also suggests that remains from colder regions may preserve DNA better than remains from warmer areas (Poinar et al., 1996). Eklund and Thomas (2010) examine the extent to which chemicals commonly used in conservation treatments of human and animal remains can damage DNA. Alaeddini et al. (2010) examine the effects/role of decomposition in DNA degradation and the potential impact it may have on forensic DNA profiling and identification.

Mitochondrial DNA (mtDNA)—the small portion of the genome that is inherited only from the mother—is easier to retrieve than nuclear DNA (Parsons and Weedn, 1997). This is likely due to the greater number of copies of mtDNA and perhaps its smaller, circular structure. Ho and Gilbert (2010) provide a review of the first decade of research into ancient mitochondrial genomics.

22.2.4 Applications

As molecular biologists develop ways to extract more information from modern DNA, the types of questions that can be addressed with ancient DNA will expand as well. Currently, there are five major questions about a deceased individual that DNA analysis of skeletal remains can potentially address:

- **What sex was this individual?** Methods of sexing skeletal remains based on morphology depend on the preservation of sexually dimorphic elements and have a significant error rate even for adult remains (Chapter 18). If DNA can be obtained, the sex of any

individual (regardless of age) can be determined with extremely high accuracy from even very fragmentary skeletal remains (Stone et al., 1996).

- **What diseases did this individual have?** A number of diseases are genetic in nature and could potentially be screened for in past populations using DNA analysis. Disease processes characterized by long-term infection by substantial densities of viral or bacterial pathogens might also be detected through recovery of the pathogen's DNA. As yet, very few studies of paleopathology have utilized DNA methods. The most notable application to date was the amplification of the *Mycobacterium tuberculosis* DNA from a Peruvian mummy to verify a pre-Columbian occurrence of tuberculosis in the New World (Salo et al., 1994).
- **With which ancestral population(s) did this individual have affinity?** A number of morphological techniques have been developed to assess the geographic affinity of skeletal remains, but they are of limited accuracy and require relatively complete remains (Chapter 21). Reliable methods to assess the populational affinities of skeletal remains are sorely needed in archaeology (to assess the relationships between past populations) and forensics (to provide information on an isolated skeleton that may lead to identification). DNA typing of skeletal remains has the potential to provide the best available information regarding the populational affinity of the individual. Mitochondrial DNA (mtDNA) is a small portion of the human genome that is inherited only from the mother. Several regions of mtDNA are highly variable within modern humans, and the sequencing of these regions can permit the estimation of the ancestral maternal population (Connor and Stoneking, 1994). Archaeologically, these techniques have been used to assess the relationships of prehistoric New World populations with various modern Native American groups (Stone and Stoneking, 1993; Hauswirth et al., 1994; Kaestle, 1995). Wallace and Torroni (2009) examine the interrelationships and ancestry of the three major linguistic groups of Native Americans. Forensically, analysis of mtDNA has been used to help identify the remains of U.S. military personnel in Vietnam (Holland et al., 1993).
- **Who was this individual?** A relatively common problem in forensic osteology is to establish the identity of a skeletonized individual. In some cases, a possible identity will be established based on other clues (eg, a recently missing person of similar age and sex), but confirmation is needed. DNA analysis is the best method for testing hypotheses about the identity of skeletal remains. The general approach is to compare the DNA from the skeleton with the DNA of the presumed relatives. For a number of variable regions of the DNA, the odds of a match between unrelated individuals are extremely low. Exactly how low is a matter of debate for cases involving blood samples from living individuals (Devlin et al., 1994), but in osteological contexts this is rarely if ever a concern. Steadman (2003) provides a review of mitochondrial DNA analysis and histomorphology. As she notes for the forensic context, DNA can build a genetic profile and result in individuation, but it cannot construct a biological profile of the individual. DNA typing has been used to identify skeletonized individuals in contexts involving mass deaths (the Branch Davidian incident in Waco, Texas; Houck et al., 1996), mass graves (Guatemala and former Yugoslavia; Boles et al., 1995; Primorac et al., 1996), remains of military personnel (Vietnam; Holland et al., 1993), war criminals (Josef Mengele; Jeffreys et al., 1992), historic figures (the Romanov family; Ivanov et al., 1996), and numerous forensic cases involving murder victims (eg, Hagelberg et al., 1991; Sweet and Sweet, 1995).
- **To which individuals was this individual related?** Even though the determination of familial relationships is most applicable in forensic or historical contexts, archaeological analysis of mortuary rituals and burial practices can often be advanced if the general relationships of the interred individuals can be established (Stone and Stoneking, 1993). Establishing the familial relationships between individuals in the same prehistoric population requires more detailed analysis than is usually attempted.
- **To what species did this individual belong?** Identification at the species level, some-

times a problem with extremely fragmentary remains, is also made possible through DNA analysis. However, the determination of whether fragmentary skeletal remains are human or nonhuman can usually be done quickly, cheaply, and accurately by visual inspection of the morphology, rendering DNA analysis unnecessary for this question in most osteological contexts. In paleontological settings, though, morphological methods for determining the species affiliation of hominid fossils often produce ambiguous results. In the case of Neanderthals, for example, paleoanthropologists working on skeletal remains have disagreed about whether there was gene flow between Neanderthals and contemporaneous early modern humans. A comparison of Neanderthal DNA with the DNA of early modern humans is providing a crucial test of hypotheses about their relations. Both mtDNA and nuclear DNA have been retrieved from a number of Neanderthal and early modern human remains, and substantial progress has been made toward assembling the complete Neanderthal genome. In May, 2010, Green et al. published their work sequencing 4 billion nucleotides from three Neanderthal individuals to map about 60% of the entire Neanderthal nuclear genome. The results from both nuclear DNA and mtDNA generally support the separation of these two lineages, but the specifics remain a matter of debate due to differing criteria for recognizing gene flow. For instance, Green and colleagues found support for low levels of gene flow (about 1–4%) from Neanderthals to modern humans at some point after the divergence of African and non-African lineages, but before the divergence of European and Asian lineages. Even though the processes of fossilization and DNA degradation preclude the application of DNA techniques to most of the fossil record, questions about species and evolutionary relationships within the last few hundred thousand years are now beginning to be addressed using this method.

22.3 Amino Acids

Amino acids are the chemical building blocks of proteins in all living organisms. Each type of amino acid comes in two mirror image forms: the D form and the L form. All amino acids incorporated into a protein are in the L form, but over time they gradually convert into the D form, a process known as racemization. Attempts to use the ratio of D to L forms as an absolute dating method have generally failed, as this ratio is significantly affected by diagenesis, but the technique has found two applications in modern osteology.

First, it has been suggested that the D:L ratio of aspartic acid in teeth is indicative of age-at-death (Ohtani and Yamamoto, 1991, 1992; Ohtani, 1995; Carolan et al., 1997). However, the error of the estimate is figured at about ± 15 years, and since the ratio is affected by diagenesis, the method is only applicable in modern contexts. Due to these limitations, the application of amino acid racemization for establishing age-at-death is of little use.

Second, Poinar et al. (1996) have proposed that the degree of racemization of aspartic acid in skeletal remains is correlated with the preservation of DNA. Beyond a certain degree of racemization, DNA was unlikely to be amplified. This technique takes advantage of the sensitivity of the racemization process to environmental factors, since it is just those factors which speed the decay of DNA. The main use of amino acid racemization in ancient DNA work is to assess the prospects of retrieving DNA and to help confirm the authenticity of the DNA obtained, although newer techniques are rapidly emerging (Green et al., 2009).

22.4 Isotopes

The documentation of diet in the past provides the context for studies of growth, stress, disease, and subsistence activities (Larsen, 1997). Questions regarding diet have traditionally been approached via morphological assessment of dental and skeletal remains, as described in Chapter 21. Increasingly, however, isotope studies are becoming the method of choice for investigating past diets, with the potential to also shed light on group affinities. In general, these methods exploit the variation in isotopic ratios preserved in bone and teeth to infer the composition of past diets and geological surroundings. See Section 21.3.3 for a discussion of isotopic analyses in osteology.

Suggested Further Readings

Cooper, A., and Poinar, H. N. (2000) Ancient DNA: Do it right or not at ALL. *Science* 289: 1139.

A sobering call to dismiss premature optimism about ancient DNA and to objectively gauge all ancient DNA results using 9 suggested “criteria of authenticity.”

Gilbert, M. T. P., Bandelt, H.-J., Hofreiter, M., and Barnes, I. (2005) Assessing ancient DNA studies. *Trends in Ecology & Evolution* 20:541–544

An argument against adopting the 9 criteria of authenticity for ancient DNA, advocating instead “a critical consideration of all available information.”

Graur, D., and Li, W.-H. (2000) *Fundamentals of molecular evolution* (2nd ed.). Sunderland, MA: Sinauer. 481 pp.

A textbook that presents both the essential information on DNA as well as the use of DNA in studies of evolution.

Green, R. E., and 55 others (2010) A draft sequence of the Neandertal genome. *Science* 328: 710–722.

The announcement of the mapping of the Neanderthal nuclear genome, with a good discussion of gene flow between modern humans, Neanderthals, and earlier hominids.

Herrmann, B., and Hummel, S. (Eds.) (1994) *Ancient DNA*. New York, NY: Springer-Verlag. 263 pp.

This edited volume provides an overview of the field, with an emphasis on techniques rather than applications.

Ho, S. Y. W., and Gilbert, M. T. P. (2010) Ancient mitogenomics. *Mitochondrion* 10:1–11.

A review of the first decade of ancient mitochondrial genomic research.

Kelman, L. M., and Kelman, Z. (1999) The use of ancient DNA in paleontological studies. *Journal of Vertebrate Paleontology* 19:8–20.

An excellent introduction to the subject with good cautions regarding contamination.

Knapp, M., and Hofreiter, M. (2010) Next generation sequencing of ancient DNA: Requirements, strategies and perspectives. *Genes* 1:227–243.

An examination of some of the most recent techniques in DNA sequencing and the degree to which each may be suitable to sequencing ancient DNA.

Krings, M., Stone, A., Schmitz, R. W., Krainitzki, H., Stoneking, M., and Pääbo, S. (1997) Neandertal DNA sequences and the origin of modern humans. *Cell* 90:19–30.

The first successful application of DNA methods to the human fossil record.

Navascués, M., Depaulis, F., and Emerson, B. C. (2010) Combining contemporary and ancient DNA in population genetic and phylogeographical studies. *Molecular Ecology Resources* 10:760–772.

An enlightening discussion of the problems inherent in comparing DNA from different time periods using algorithms designed for comparing contemporaneous individuals from a panmictic population.

Pääbo, S., Poinar, H., Serre, D., Jaenicke-Després, V., Hebler, J., Rohland, N., Kuch, M., Krause, J., Vigilant, L., and Hofreiter, M. (2004) Genetic analyses from ancient DNA. *Annual Review of Genetics* 38: 645–679.

A critical analysis of the state of ancient DNA research, with a consideration of what is currently possible and what can be reasonably expected from future research.

Parsons, T. J., and Weedn, V. W. (1997) Preservation and recovery of DNA in postmortem specimens and trace samples. In: W. D. Haglund and M. H. Sorg (Eds.) *Forensic taphonomy: The postmortem fate of human remains*. Pp. 109–138. Boca Raton, FL: CRC Press.

A review of the preservation of DNA in postmortem samples, including both forensic and ancient skeletal remains, and how it can be retrieved and analyzed.

Stone, A. C., and Stoneking, M. (1993) Ancient DNA from a pre-Columbian Amerindian population. *American Journal of Physical Anthropology* 92:463–471.

One of the few actual analyses of a prehistoric skeletal sample using DNA methods.

Stoneking, M. (1995) Ancient DNA: How do you know when you have it and what can you do with it? *American Journal of Human Genetics* 57:1259–1262.

Addresses the standards needed in ancient DNA work and identifies productive areas of future research.

Wallace, D. C., and Torroni, A. (2009) American Indian prehistory as written in the mitochondrial DNA: A review. *Human Biology* 81:509–521.

An examination of the mitochondrial evidence for addressing the question of the number of migration events for aboriginal American Indians.

Chapter 23

FORENSIC CASE STUDY

HOMICIDE: “WE HAVE THE WITNESSES BUT NO BODY”

THE PREVIOUS 22 CHAPTERS HAVE OUTLINED the basics of human osteology. Our focus has been on the use of skeletal remains in forensic, archaeological, and paleontological contexts. The remainder of the book is devoted to presenting case studies selected to show the great excitement and breadth of studies that share the foundation of human osteology.

Human osteologists routinely assist law-enforcement agencies, coroners, and medical examiners by identifying skeletal remains. The remains themselves are recovered from a variety of contexts, including aircraft crash sites, makeshift graves, and open fields. When skeletal material is found, the primary forensic concerns usually initially involve the age, sex, stature, and ancestry of the individuals in question and often require positive identifications. This case study provides an example of a difficult but successful investigation in forensic osteology — an investigation that led to the arrest, confession, and conviction of a murderer.

Many investigations in forensic human osteology involve fairly straightforward matches between the unknown remains and missing individuals. Where the evidence is complete, positive identification is usually easily obtained, even by investigators not trained in osteology. In the case of more fragmentary remains, however, this work of identification becomes more difficult, and osteologists may be in the unique position of performing the identification. Owsley et al. (1993) discuss their forensic work in the notorious Jeffrey Dahmer case, in which fragmentation of the victim's remains was intentional. As Rouge and colleagues note (1993), radiographic identification of human remains may often be accomplished by focusing on deformities and anomalies of the postcranial skeleton. Owsley (1993) provides an example of the kind of situation that a forensic osteologist may face in conducting investigations in the developing world by discussing the identification of the remains of two U.S. journalists seven years after their disappearance in Guatemala. Like these, the case study presented below is not typical of forensic osteological investigations because of the extreme circumstances surrounding disposal and identification of the body. However, it illustrates the importance of basic detective work, teamwork, and basic osteological identification — the fundamentals of osteology in any forensic context.

The case presented here, number 191613, is documented by materials on file at the Cuyahoga County Coroner's Office, Cleveland, Ohio. Official reports, print media reports, and photographs in the case file were used to write this chapter. The dates and names of the victim, witness, assailant, and scenes used in this chapter have been changed to protect these individuals.

23.1 A Disappearance in Cleveland

Katie Jones telephoned police to report the disappearance of her older brother Harry in July of 1980. She told police of an argument between her brother and Mr. Charles Cook, aka Chuckie, the owner of Chuckie's Corner, a nightclub in Cleveland, Ohio. Jones and Cook had been feuding for two years, and on this particular Saturday night the argument was over an alleged assault of a woman. Cook insisted that Jones leave his establishment. When Jones left, Cook followed him up Ashland Avenue.

Witnesses last saw Harry Jones being pursued east and north, the pursuer firing several shots at Jones. Because of the argument in the nightclub, Charles Cook became a suspect in the disappearance of Harry Jones. When questioned, suspect Cook admitted to owning a gun but insisted that his gun had been stolen on the night of the disappearance. He denied killing Jones.

23.2 Investigation

Because of the possibility that Jones had been shot, Cleveland homicide detectives were assigned to the case. They quickly learned that Cook had boasted to another witness that he had, indeed, killed Jones, but that no body would be found: "I burned him up and police won't find any evidence." Homicide detective Jon T. Qualey noted: "This is a new one for me. Usually we have a victim and no witnesses. This time we have the witnesses but no body."

On further investigation, the detectives learned that Cook was an assistant supervisor at the Animal Resource Center at the Case Western Reserve University School of Medicine, where his duties included the disposal of research animal carcasses in an incinerator. Following this realization, in the words of detective Qualey, "We put one and one together and we came up with two." Detectives contacted the Cuyahoga County Coroner's office. Members of its staff joined the Cleveland police in a preliminary examination of the contents of the incinerator where animal remains were disposed. Sifting through the incinerator debris, authorities identified what appeared to be human bone fragments. A melted piece of lead about the mass and size of a .38-caliber bullet was found in the debris.

23.3 Inventory

Cleveland Homicide Unit detectives organized a full investigation of the incinerator's remains. The investigation team included the deputy Cuyahoga County Coroner, Dr. Elizabeth Balraj, and Barbara Campbell of the Trace Evidence Department of the Coroner's office. The Cuyahoga County Coroner's office retains a number of consultants who contribute to its investigations as necessary. In this case, consulting anthropologist Dr. C. Owen Lovejoy of Kent State University, consulting dentists Drs. Elizabeth Robinson and James Simmelink, and consulting radiologist Dr. Benjamin Kaufman joined the incinerator investigation team.

The contents of the incinerator were emptied into 25 labeled metal bins. The incinerator was divided into an upper and a lower section, and the contents of these sections were kept separate. The contents removed from the top section of the incinerator had a total capacity of 40 gallons and weighed 60 kg. The bottom section had a 55-gallon capacity of contents weighing 75 kg. The contents comprised fragments of cremated skeletal remains, ash, masses of synthetic material, and metal and wire mesh (Figure 23.1).

Contents of each of the 25 metal bins were sifted through a fine wire screen. Sorting the human from nonhuman remains was the task of the consultant in anthropology, Dr. Lovejoy. All skeletal remains that were diagnostically human were set aside for further analysis. All skeletal remains that were diagnostically nonhuman were separated, photographed, and stored. Amal-



Figure 23.1 Bags of bone fragments. Recovered from the incinerator at the Animal Resource Center at Case Western Reserve University.

gam, ash, and all metal pieces were separated from the debris.

The human remains were extremely fragmentary, all of the specimens being brittle, grayish-white, and showing excessive shrinkage and exfoliation consistent with their exposure to high temperature. The incinerator was normally heated to between 1400 and 2000° F, hotter than normal incinerators but not as hot as a crematorium, which runs at 2300°. The skeleton had suffered greatly due to the incineration, but fragments of many body parts remained and were available for further analysis. Figure 23.2 illustrates the condition of the human skeletal parts recovered from the incinerator.

23.4 Identification

Once the 163 diagnostically human bone fragments were separated from the animal bone in the incinerator, the first question for the investigators was how many human individuals were represented by the remains. The second question was about the identity of the individual(s) whose bones were present.

Portions of elements from the entire skeleton were recovered. Mandible ramus, clavicle, scapula, ulna, os coxae, and femur were represented by portions on both right and left sides. Careful comparison of those pieces that were present bilaterally showed antimeric correspondence. Furthermore, no cases of mismatched right and left sides were found among the human remains. Finally, despite the large number of human fragments, no skeletal element was duplicated in the collection. All of these observations made it highly probable that a single human individual was cremated in the incinerator, and that the fragmentary skeletal remains of this individual were subsequently mixed in the incinerator debris with animal remains.

The investigative team then turned to the question of identity. Individuation in this case proceeded along two complementary lines. The first set of questions centered on the standard issues of age, sex, and ancestry of the individual in question. The second major question was whether the remains were those of the missing Harry Jones.

Determination of age, sex, and ancestry was difficult due to the extremely fragmentary nature of the remains. Fortunately, the recovery of a few important areas allowed Dr. Lovejoy to go beyond the determination of “adult.” Several sexually dimorphic portions of the skeleton were available for analysis. These included the femoral head, the right supraorbital region including

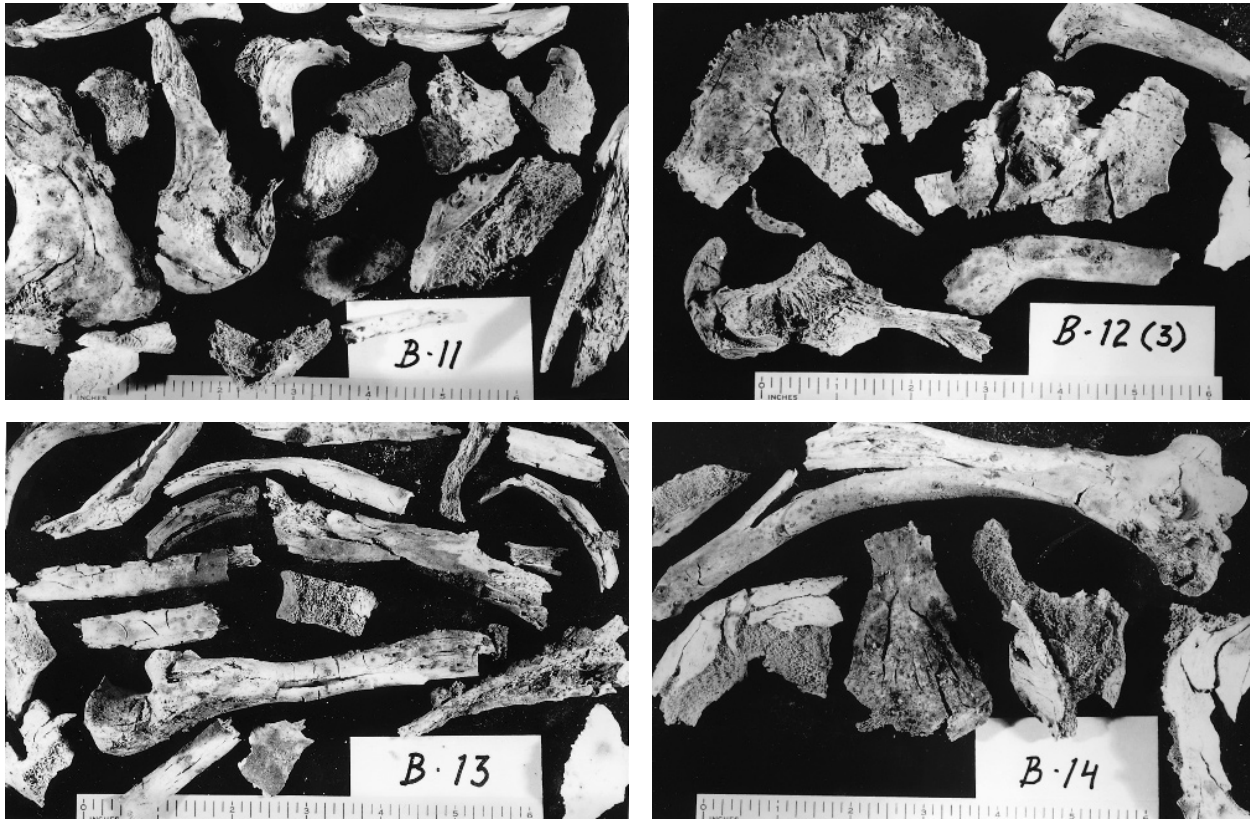


Figure 23.2 Some of the human bone fragments from bins B-11, B-12, B-13, and B-14. Scales are in inches.

the sinus system, the external occipital protuberance of the occipital, and the mastoid of the temporal bone. All of these features indicated to Dr. Lovejoy that the remains were those of a male individual.

A portion of the pubic symphyseal face was preserved. Here, the rampart was obviously complete with no remodeling scars. The surface was granular, with early rim formation. From these traits, Lovejoy concluded that the specimen was in the fourth decade of life. Because two complete auricular surfaces of the bony pelvis were recovered, Dr. Lovejoy was able to make an additional age assessment from this part of the skeleton. The surfaces had uniformly coarse granularity, with no significant macroporosity or microporosity. There were no islands of density and apical activity was moderate. Based on this, an age estimate of 36 (± 5) years was estimated.

Having established that the individual was a male in his late thirties at the time of death, the next step was to see whether the remains belonged to Harry Jones. Harry Jones was 37 years of age when he disappeared, so Lovejoy's age estimates were suggestive but not conclusive.

In many forensic cases, physical anthropologists can work from intact skeletons, or intact parts of skeletons. In such cases, the dentition or the intact cranium can often establish a definite tie with photographs or dental records taken before death. In the analysis of the incinerated remains, however, investigators were faced with the task of somehow matching the small fragments of skeleton they had with knowledge about Harry Jones. No teeth were recovered for the analysis. The challenging task of individuation was accomplished because of some skillful detective work and radiographic analysis.

Because investigators strongly suspected that the remains from the incinerator were those of Harry Jones, they searched for radiographs that had been taken of Jones during his life. Radiographs of Harry Jones had been taken in the 1970s and were available from St. Luke's Hospital,

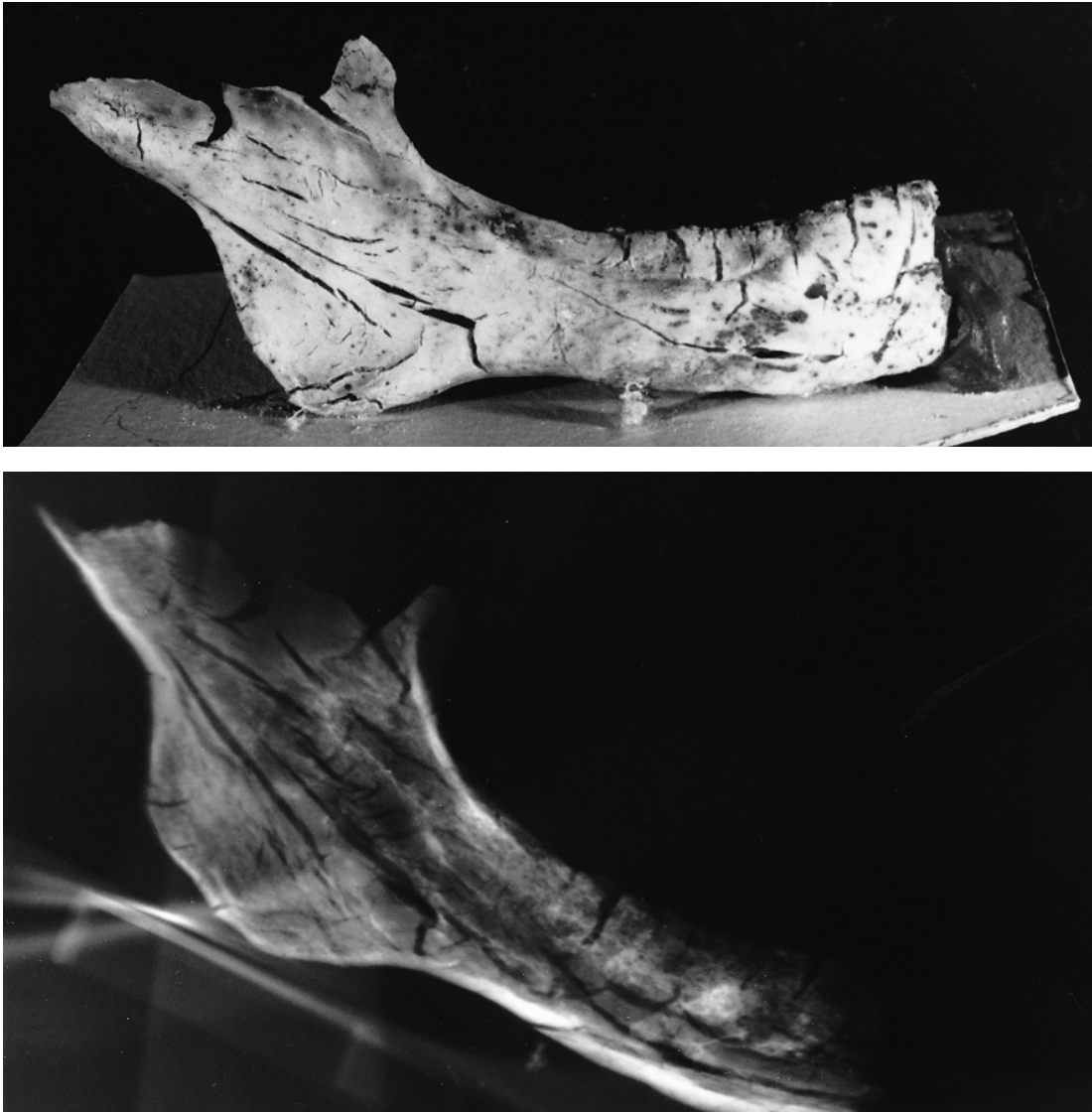

Figure 23.3 Right mandible from bin B-12. *Top*: photograph of the bone; *bottom*: radiograph of the bone. Natural size.

University Hospital, and Cleveland Metropolitan General Hospital.

Drs. Simmelink and Robinson, forensic odontologists, focused on one of the human bone fragments recovered from the ashes of bin B-12. This fragment was most of a right human mandible, including corpus and ramus (Figure 23.3). The 1977 films of Jones showed that he retained some upper and lower teeth at that time, but the 1981 films showed an edentulous Harry Jones. Radiographs of the mandibular specimen recovered from the incinerator were compared to the 1977 and 1981 films of Harry Jones. In addition to the lack of teeth or radiolucent sockets, the investigators discovered a 5-mm diameter “calcified density” in the body of the mandible that matched the antemortem films. Furthermore, several other areas of trabecular bone along the mandibular canal and inferior border of the mandible also matched. Finally, the outline of the mandible from the incinerator matched perfectly with that of Harry Jones’s radiographs (Figure 23.3 and 23.4). In summary, there were no radiographic inconsistencies between the 1981 films of Harry Jones and the 1984 films of the unknown mandible fragment from the incinerator bin.

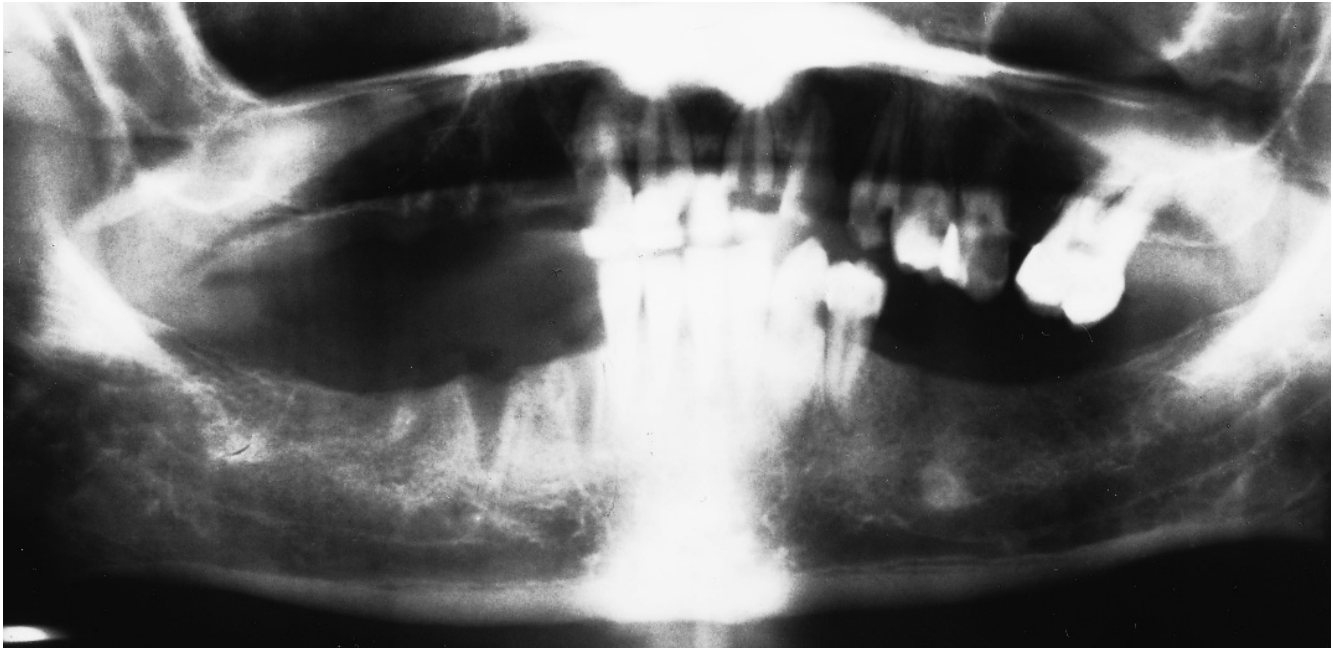


Figure 23.4 Radiographic comparison. A comparison of the radiograph of the mandible found in the incinerator (Figure 23.3) with the radiograph taken of Harry Jones before his death (shown here) revealed a correspondence in the lack of teeth, or radiolucent sockets, in the approximately 5-mm diameter “calcified density” in the body of the mandible, in trabecular bone patterns along the mandibular canal and inferior border of the mandible, and in the outline of the mandible. Aside from the loss of teeth, there are no radiographic inconsistencies between the 1981 films of Harry Jones and the 1984 films of the unknown mandible fragment from the incinerator bin. This provided a positive identification of the deceased.

In the opinion of the consulting forensic odontologists, “this detailed comparison of the right jaw bone indicates positively that (the unknown) right mandibular bone piece is from the skeleton of Harry Jones.”

Dr. Kaufman, the consulting radiologist on the case, concurred with the analysis of the odontologist. He also noted the identity of the condensation (“sclerosis”) of bone in the mandible body, of the bony trabeculations, and of the position and shape of the mental foramen. Furthermore, Dr. Kaufman noted no inconsistency in the appearance of the temporal bone and the vertebrae between the incinerator specimens and Harry Jones’s radiographs. Finally, antemortem radiographic views of Harry Jones’s hands taken in 1979 matched radiographs of the hand bones recovered from the incinerator. Thus, Dr. Kaufman confirmed the finding of the dentists, concluding that the skeletal fragments from the incinerator were from the skeleton of the recently deceased Harry Jones.

23.5 Conclusion

Deputy Coroner Balraj filed her report on the incinerator investigation, concluding that the human skeletal remains found among the cremated animal remains within the incinerator of the Animal Resource Department of the Case Western Reserve University School of Medicine were those of Mr. Harry Jones. A check of the closed-circuit television system that monitors and tapes activity around the clock in the medical school building produced pictures of the suspect, Charles Cook, backing a university truck up to the loading dock and entering the building at 3:10 a.m.

on Sunday morning, about six hours after the quarrel with Harry Jones. The receiving dock was located about 20 feet from the incinerator. Records at the university showed that the suspect, who was scheduled to report to work at 6:00 that morning, had clocked in at 3:15, just after he appeared on the television monitor. He did not, however, sign in at the security guard's desk, as required of anyone entering the building before 6:00 a.m.

Secure in the belief that the body would never be found, Charles Cook at first denied the murder of Harry Jones. When the evidence against him mounted, however, he reversed his position and pleaded guilty to the murder of Harry Jones. He was sentenced to 15 years to life in prison.

This case study was chosen because it effectively illustrates the unique contributions that the osteologist can make in the forensic arena. A knowledge of the basic principles of element identification and siding, and of individuation in human osteology, was the key in the analysis. In some ways, the forensic osteology of the Harry Jones homicide was unusual. The trail to the suspect was a short one, and witnesses were able to assist the detectives in locating the suspect as well as the deceased. The skeletal remains were very fragmentary, but an excellent radiographic history of the victim was available for comparative work. More often, the unknown skeletal remains are more complete, the suspect is not identified, and the possible victims are many. In any forensic situation, however, the keys to success are competent identification of the remains, careful, critical observation of the available clues, and close collaboration with other authorities on the investigation team.

This page intentionally left blank

Chapter 24

FORENSIC CASE STUDY

CHILD ABUSE, THE SKELETAL PERSPECTIVE

IN FORENSIC HUMAN OSTEOLOGY a key concern is often the identification of individuals based on the analysis of skeletal remains. The case study documented in Chapter 23 presented one example of how even the most fragmentary skeletal remains can be recovered, analyzed, and identified in a criminal investigation. Forensic work with skeletal remains often involves the documentation of events as well as identities. Within the last decade, for example, forensic osteologists have worked with authorities in Haiti, El Salvador, and Bosnia in efforts to reveal secrets of the very recent past. The current chapter presents a case study that illustrates the contribution that a careful analysis of skeletal remains can make in the realm of forensic science.

Child abuse is widespread in modern society. The magnitude of nonaccidental pediatric injuries is staggering. According to the Fourth National Incidence Study of Child Abuse and Neglect (NIS-4, <https://www.nis4.org>), there were more than 1.25 million cases of child abuse in the United States during the latest study year (2005–2006). Approximately 18% of these cases involved serious injuries resulting in more than 2400 nonaccidental deaths in infants and children. Before the 1990s, very little attention had been paid to the problems of identifying child abuse in the skeletal remains of children. Phil Walker and colleagues have changed this, with an important paper documenting their work on five case studies. One of these is detailed in the account below, an account that draws exclusively from Walker et al. (1997).

24.1 Child Abuse and the Skeleton

Forensic cases involving the skeletal remains of chronically abused children are common. When such a child is killed, the abusers may attempt to dispose of the body surreptitiously and claim that a kidnapping occurred. Under such circumstances, time may pass before the body is discovered, and a fragmentary, partial skeleton may be the only evidence remaining.

Such cases are very difficult for the forensic pathologist or radiologist who often lacks experience in dealing with defleshed skeletal remains. The patterns of scars, bruises, and soft tissue trauma seen by the medical examiner or forensic pathologist are no longer available as evidence under these conditions. Even the picture of the battered child syndrome seen radiographically is very different from the one studied by the forensic osteologist who is directly examining the bones themselves. In the case presented below, it was the expertise of the forensic osteologists

that led to the documentation of evidence not apparent to pathologists or radiologists — evidence crucial to the demonstration that child abuse had occurred.

24.2 A Missing Child Found

Police investigating a report of a boy who had been missing for five years discovered the partially skeletonized remains of a three-year-old child in the trunk of the family car. His parents first told law enforcement officials that the boy had died after slipping and hitting his head while taking a bath. Although at first they said that they had buried him, the discovery of his skeleton made it clear that instead they had carried the dead child in the trunk of their car for five years.

When the remains of the child were autopsied, the cause of death was not determined. The parents were charged with illegal disposal of the body. The remains were then sent to forensic osteologist Phil Walker of the University of California at Santa Barbara. An expert in both the forensic and bioarchaeological areas, Walker was well qualified to take a second look at the child's bones.

24.3 Analysis

Dental development was used to provide a precise age at death for the child using the techniques discussed in Chapter 18. Combined with long bone measurements, these data indicated an age of 3 to 4 years at death. More detailed histological work on the teeth, focusing on Retzius line and cross striation counts in histological sections of the child's teeth were consistent with an age of 3 years, 7 months at death. Furthermore, they indicated that the child had suffered disruption of dental development, the last occurring about two months before his death.

Although the remains of the child were left in the car trunk for five years, considerable soft tissue covered the bones. When the desiccated tissue was carefully cleaned away, a linear fracture was seen to cross the left occipital bone, extending from the foramen magnum to the lambdoid suture. A 3.5 cm² area of subperiosteal new bone formation was observed below the lambdoid suture, confined to the occipital, and extending to the fracture line (Figure 24.1).

Gross and histological analyses showed that the area of bone formation recorded at least two stages of healing. Most of the affected area lacked large porosities and was comparatively dense, reintegrating with the external vault table. To Walker's practiced eye, this indicated a month or more between the injury that produced the fracture and the death of the child. However, along the borders of the fracture, the well-healed bone was overlain by a second more recent episode of bone formation. Some of the fracture edge was starting to heal, and this newer, more porous bone would have taken more than a week to form.

Disruption of the healing process is commonly seen in child abuse cases. Multiple traumatic episodes lead to these osteological patterns. Parents involved in the chronic, repeated beating of their children usually avoid seeking medical treatment for the child for fear of detection of their abusive behavior. Untreated, the bone begins to heal, but the fracture can be reopened with further trauma.

Turning to the teeth, Walker noticed that an upper and a lower incisor had antemortem fractures. He could tell that they occurred before death because their occlusal surfaces were both worn. Such fractures, of course, could occur without any abusive parental behavior, but such injuries are found at high frequency among abused children, reinforcing the idea that this child had suffered repeated injury.

The rest of the skeleton held more evidence. The clavicle showed a healed fracture (Figure 24.2). The left radius and ulna showed areas of subperiosteal new bone formation. These lesions are thin layers of new bone that form beneath the periosteum in response to trauma and subpe-




Figure 24.1 Postero-inferior view of the cranium. The lambdoid suture traverses the vault from left to right. The vertical fissure is a partially healed fracture of the occipital. Close examination of this fracture revealed at least two stages of healing, showing that the child incurred the injury at least a month before his death. Photo courtesy of Phil Walker.

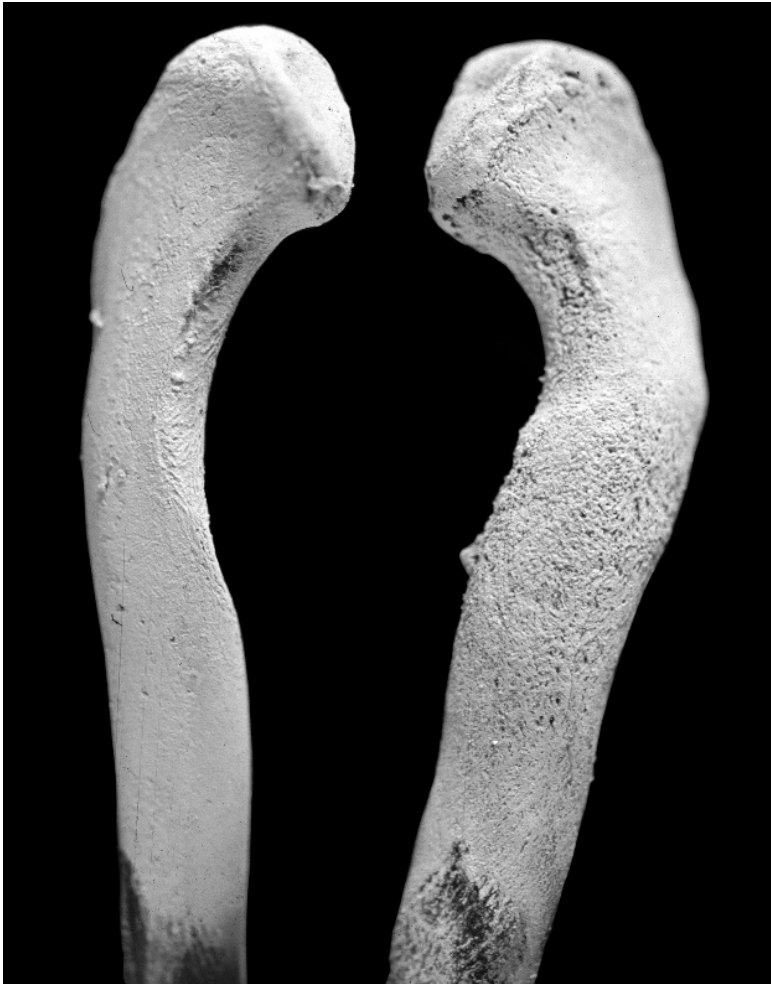

Figure 24.2 Healed fracture of the clavicle shaft (*right*) compared to the normal opposite side. Photo courtesy of Phil Walker.

riosteal bleeding (Figure 24.3). They are often asymmetrically distributed and can result from beating or stripping of the periosteum from the bone when the limbs are forcefully traumatized. In this case, the forearm had been traumatized in this manner with an area of subperiosteal new bone on the distal half of the ulna that nearly encircled the shaft (Figure 24.4).

No other long bones showed evidence of subperiosteal formation. Walker's work on other child abuse cases has shown that asymmetrical distribution of such subperiosteal lesions in vulnerable areas where bones are subcutaneous is common. Here, the borders of the lesions on the radius and ulna were beginning to integrate into the adjacent cortical bone. This healing indicated that the trauma that had caused them occurred a month prior to the death of the child. None of these subperiosteal lesions was visible on the high-resolution radiographs. Indeed, they are usually less than a half of a millimeter thick, but readily apparent to the osteologist. Here, the bare-bones osteologist had the advantage of seeing what was invisible to the radiologist and forensic pathologist.

Radiographs of the child's long bones showed that there were many Harris lines (see Chapter 19). These were bilaterally symmetrical in the distal radius, with 15 lines in the distal 18 mm of the bone. Some Harris lines are normally present in children of this age, but fewer than 5% of children between the ages of 2.5 and 4 years have as many Harris lines as this child.

Figure 24.3 From a similar case, an area of subperiosteal bone formation on the fibula. This shows porosities and sharp margins indicative of recent healing. Some of the bone at the end of the lesion has been lost through postmortem flaking damage. Photo from Walker et al. (1997), courtesy of Phil Walker.

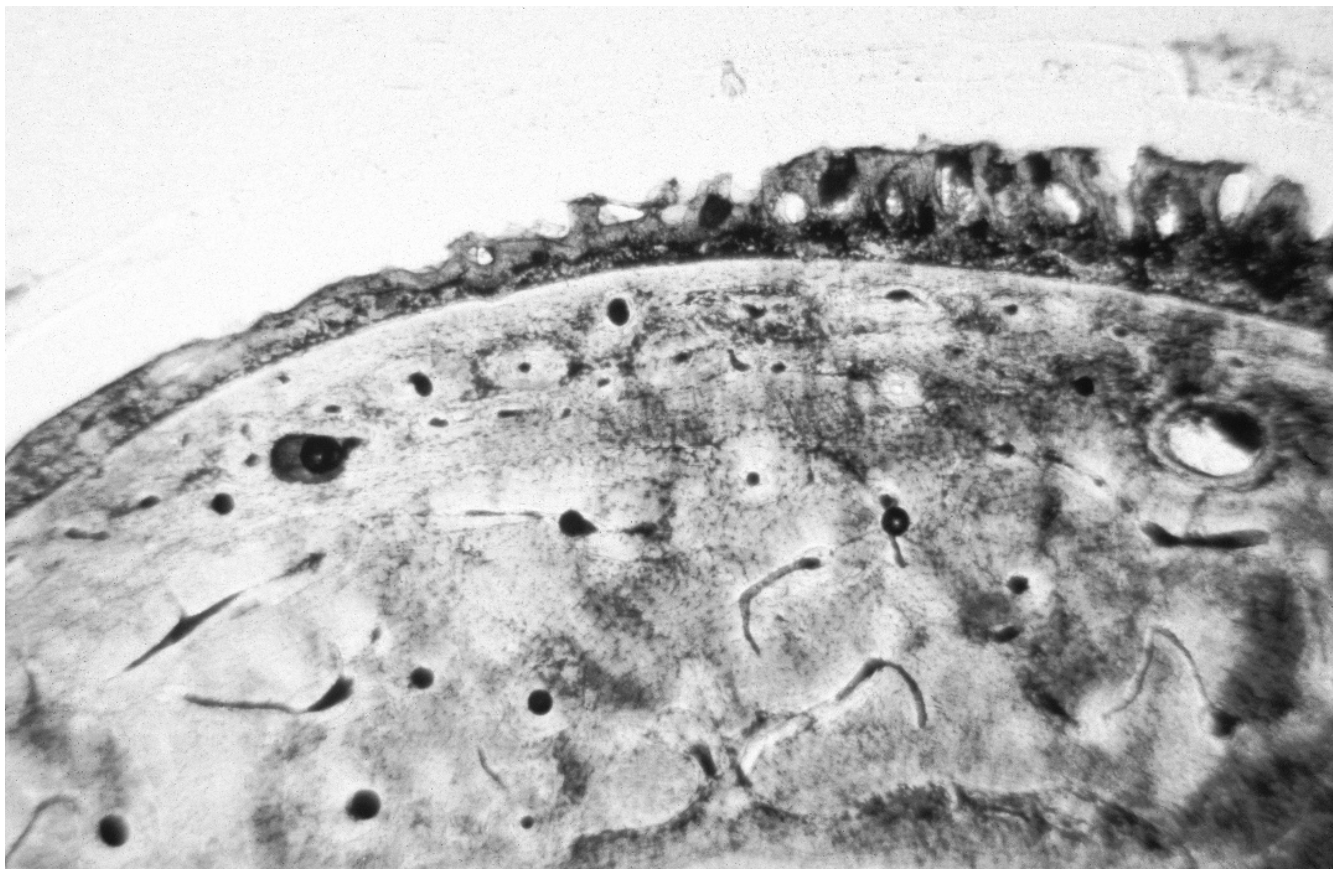
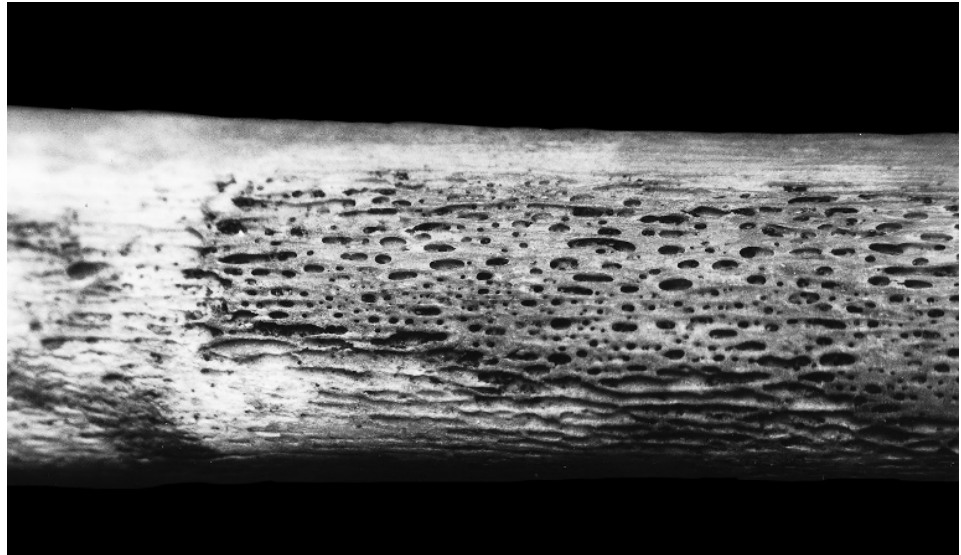


Figure 24.4 Cross section of the traumatized radius, showing the histological appearance of subperiosteal new bone formation in response to trauma. Normal, dense subperiosteal bone is seen at the margin of the lesion, with thickened, vascularized bone near the lesion's center. Photo from Walker et al. (1997), courtesy of Phil Walker.

24.4 The Result

Added up, the skeleton and teeth of the child whose remains had been recovered from the trunk of his parents' car showed that the months before the child's death had been punctuated with trauma. It was a pattern consistent with child abuse. Multiple injuries in different stages of healing are consistent with abuse. An accidental explanation for such injuries becomes increasingly unlikely as the number of traumatic episodes increases. The frequency of fractures produced by severe physical abuse decreases with advancing age, probably because smaller children are more easily held by their arms and legs and beaten, whereas such abuse is more difficult to inflict on older children because of their size and ability to resist. In this case, armed with the osteological evidence of severe physical abuse over a prolonged period, prosecutors charged the parents with second-degree murder, to which they eventually pled guilty.

Chapter 25

ARCHAEOLOGICAL CASE STUDY

THE BIOARCHAEOLOGY OF THE STILLWATER MARSH, NEVADA

THE PREVIOUS TWO CASE STUDIES dealt with osteological remains in the very recent past. Such forensic osteology cases represent an application of knowledge about the human skeleton to specific questions regarding individual identification and reconstructions of very recent human behavior. The next four case studies show how knowledge of human osteology can be applied in attempts to understand the more distant past. The first two case studies involve the relatively recent archaeological past, whereas the final two involve human paleontology.

The term “**bioarchaeology**” refers to the study of the human biological component of the archaeological record. Bioarchaeology is therefore a newer name for an old subfield of human osteology. Just like other subfields such as forensic osteology or hominid paleontology, bioarchaeology is multidisciplinary and uses the latest techniques to reveal as much as possible from skeletal remains. For example, the work of Phil Walker and colleagues (for example, Lambert and Walker, 1991) on native populations inhabiting the area adjacent to the Santa Barbara Channel in California has employed data from deep sea cores and tree rings, artifact assemblage change, archaeological evidence of trade, spatial patterning and density of habitation sites through time, and even early mission records. These data have been integrated with osteological evidence of paleopathology, demography, and isotopic composition in an effort to understand the evolution of social complexity. The present case study is another bioarchaeological analysis, the case of the Stillwater Marsh in Nevada. The account below is drawn directly from Larsen and Kelly (1995) and Larsen et al. (1996).

25.1 Background

The lives of hunting and gathering people were thought of by early anthropologists as short and difficult, but ethnographic studies changed that view by the 1960s. Even though all hominid subsistence was based on foraging economies until the relatively recent advent of agriculture, by the time anthropologists could scientifically study hunting and gathering societies, these foragers had already been forced into mostly marginal habitats by surrounding agriculturalists. Their lifeways had been substantially disturbed through contact. Because of this, the archaeological record has proven invaluable in illuminating forager lifeways. Because skeletal and dental indicators provide a cumulative biological history of an individual’s lifetime and can record stress,

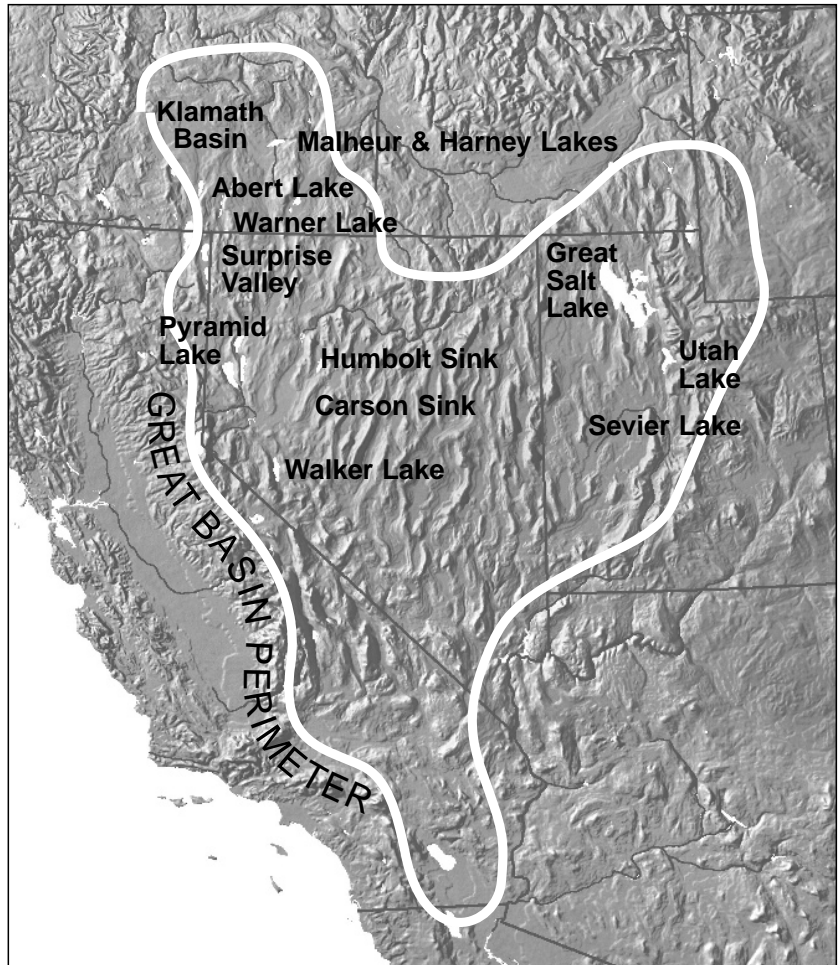


Figure 25.1 The Great Basin. Stillwater Marsh is on the eastern edge of the Carson sink. From Larsen and Kelly (1995).

nutrition, disease history, and physical activities, osteological remains are paramount in the study of human adaptation in the past. The conditions in the Great Basin of western North America (Figure 25.1) have preserved a remarkable archaeological record of occupation, a record that is now being enhanced more than ever before through the detailed, multidisciplinary analysis of human skeletal remains.

25.2 Geography of the Carson Sink

The Carson Desert is an extensive area of sand dunes, alkali flats, and slightly alkaline marshes covering an area of about 2800 km² at a distance of about 100 km east of the present city of Reno, Nevada. This area, one of the lowest in the Great Basin, is the landlocked drainage terminus for the Carson River, which feeds the Stillwater Marsh, an ecologically rich area inhabited for many years by pre-Columbian aboriginal populations who subsisted on the area's bounty (Figure 25.2). For the most part, these people buried their dead throughout the marsh rather than at cemeteries, a mortuary pattern likely to be characteristic of many prehistoric foraging groups.




Figure 25.2 Overview of the Stillwater Marsh area. The circle represents a probable house feature exposed by flooding. From Larsen and Kelly (1995).

25.3 Exposure and Recovery

Between 1982 and 1986, record winter precipitation resulted in massive flooding of several Great Basin wetlands, including the Stillwater Marsh. As the floodwaters withdrew in 1985 and 1986, many archaeological sites were exposed. Hundreds of burials were uncovered, as were trash and cache pits, artifacts, and pithouse sites. The alarming nature of the exposed human remains led a local resident and amateur archaeologist to alert state and federal authorities to the exposure of these valuable resources. The Nevada State Museum salvaged the disturbed remains, including 416 burials or individuals. Wind and wave erosion continued to disturb burials in the region, and in 1987 archaeological crews under the direction of Clark Larsen and Robert Kelly surveyed the most heavily impacted marsh shoreline. Additional remains were recovered by this effort. The combined skeletal sample is the largest of any reported to date from the Great Basin. In turn, many of the analytical techniques employed in the assessment of these remains represent the first of their type to be conducted on prehistoric Great Basin skeletal remains.

Six of the burials in the Stillwater series were radioisotopically dated, using radiocarbon. The dates range from ca. 2300 to 300 B.P. The predominant period represented by projectile points found in the sometimes associated archaeological sites was the Undertown phase (1250–650 B.P.). The skeletal series was treated, for the purpose of the analysis, as a single population. However, it is obvious that it is merely a tiny sample of the total human population inhabiting the Stillwater area over thousands of years. It is important to note that the human remains from Stillwater Marsh were not from cemeteries but rather from isolated graves scattered throughout the marsh region, indicating a probable lack of formal disposal areas (Figures 25.3 and 25.4). The remains represent a series of small samples drawn at unknown intervals from a larger population over a span of centuries, if not millennia, rendering paleodemographic analysis problematic.

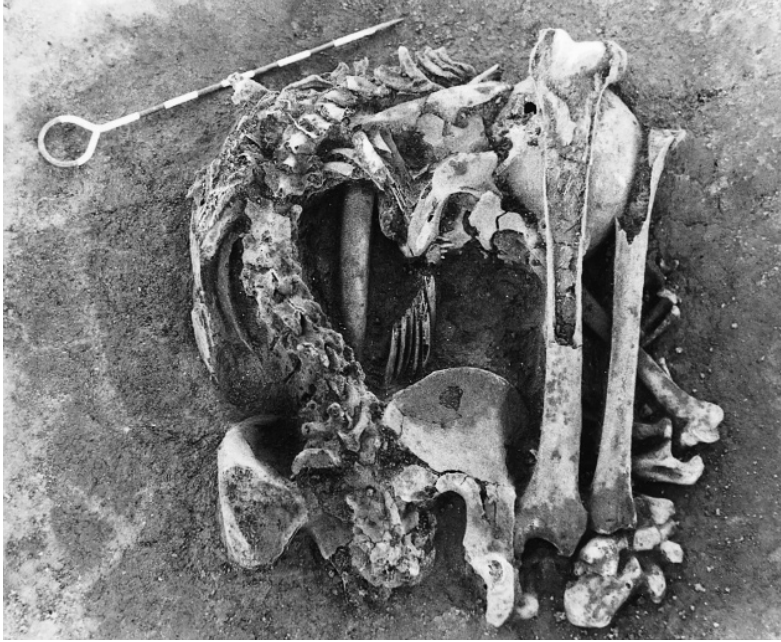


Figure 25.3 Flexed burial from Stillwater Marsh. From Larsen and Kelly (1995).

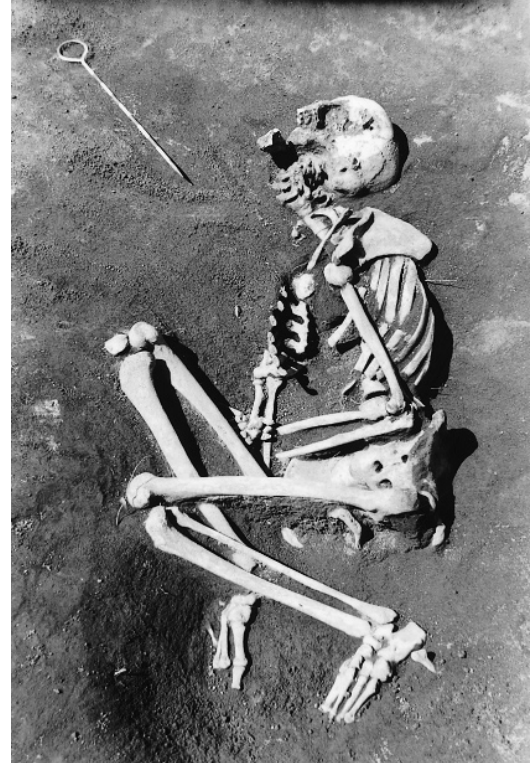


Figure 25.4 Burial from Stillwater Marsh. From Larsen and Kelly (1995).

25.4 Analysis

The biocultural analysis, therefore, necessitated a different approach from the ones usually employed on cemetery assemblages of skeletons. What were the problems encountered by the analytical team? First, there was an increased probability that the remains were not representative of the population from which they were drawn. Second, relative chronological placement was very difficult, particularly because most burials did not contain directly associated diagnostic artifacts.

The individual remains were all analyzed. Age, sex, and stature were all determined according to standard procedures (Chapter 18). Computed tomographic scanning of selected humeri and femora was undertaken at the Veterans Administration Hospital in Reno. Bone fragments were sampled for stable isotope and genetic analyses. Discrete trait analysis showed homogeneity among the remains, as did skeletal measurements (Brooks et al., 1988), so they were treated as a single sample for the purposes of the analysis. The five goals of the project were as follows:

1. to provide a description of the remains;
2. to assess the quality of life;
3. to improve documentation and understanding of population history;
4. to characterize diet; and
5. to identify physical activity patterns.

25.5 Affinity

There are long-standing debates about population movements in the Great Basin. Linguistic data suggest that Numic-speaking people arrived between 1000 and 700 B.P. Study of serum albumin derived from the skeletal remains revealed similarity with modern Numic speakers, but because the skeletal remains with the shared allele were undated, these results did not bear on the issue of entry of these people into the area. The analysis of mitochondrial DNA showed a very low frequency of the 9-basepair deletion, a deletion observed in some prehistoric and extant Native American populations. This suggested that the Stillwater population was probably not ancestral to any group with a high frequency of this deletion (e.g., California Penutian, Zuni, Yuman, Washo, or Southern-Uto-Aztecan language groups). The molecular analyses left several possibilities open regarding the identification of ancestral-descendant relationships in the Great Basin and beyond, but this study constitutes an important step in the ongoing work in this direction.

25.6 Osteoarthritis

Over three quarters of the individuals in the skeletal series were affected by osteoarthritis, and all individuals over 30 years of age showed this pathology. The highest frequency was in the lumbar vertebrae, but cervical vertebrae and elbows had frequencies of more than 50%. Controlling for age, there were several differences between males and females. The Stillwater series exhibited a pattern of sexual dimorphism in osteoarthritis prevalence, with the males more affected than females, with the exception of the lumbar vertebrae (Figure 25.5). This suggests that women frequently carried heavy loads (perhaps children, firewood, water, and/or food). Males had significantly higher frequencies of osteoarthritis in the hip and ankle.

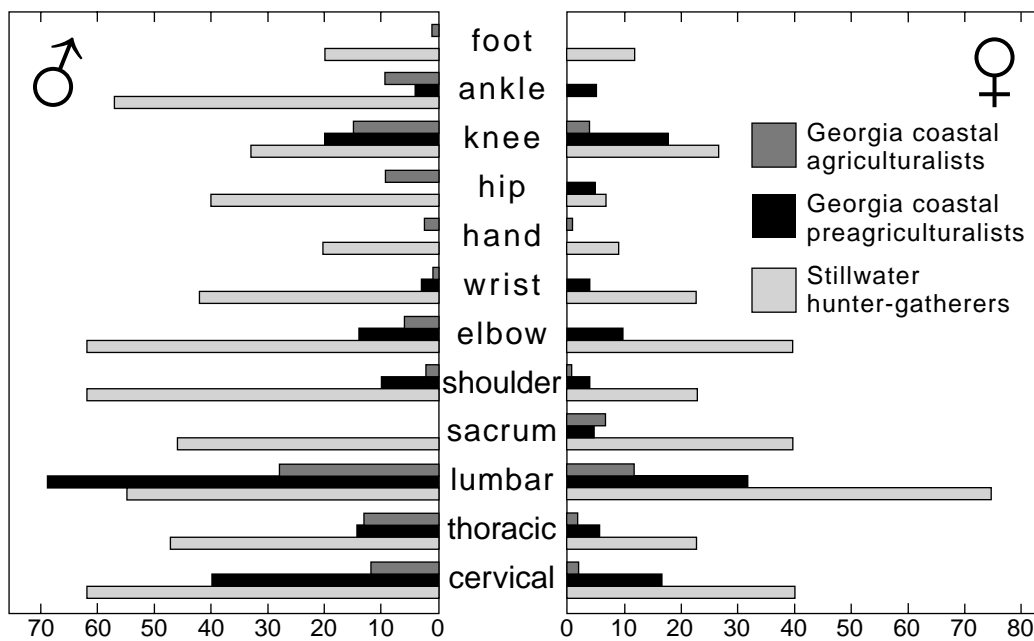


Figure 25.5 Prevalence of osteoarthritis among different Native American groups. Stillwater rates are shown as the lighter bars. From Larsen and Kelly (1995).

The rates of osteoarthritis prevalence are very high relative to other skeletal series. This was interpreted to mean that these foragers engaged in physically demanding activities, particularly high levels of mechanical loading of the spine. Several individuals had vertebral compression fractures (Figure 25.6). The investigators conclude that frequent foot transport of heavy loads might be implicated in these pathologies. They make reference to ethnographic accounts suggesting that the recent inhabitants of this region routinely engaged in physically demanding activities.

25.7 Limb Shaft Cross-Sectional Anatomy

The Stillwater series showed a consistent pattern of elevated bone strength relative to comparative samples, which the investigators interpreted to reflect high bending and torsional loading modes. The humeral values were low relative to the femoral values. The low bone mass (small total amount of cortical bone) in both elements relative to other skeletal series, when controlled for age, was interpreted to reflect episodic under-nutrition. Comparison of males and females showed high dimorphism, suggesting that females were less mobile and more “tethered” to the marsh setting.

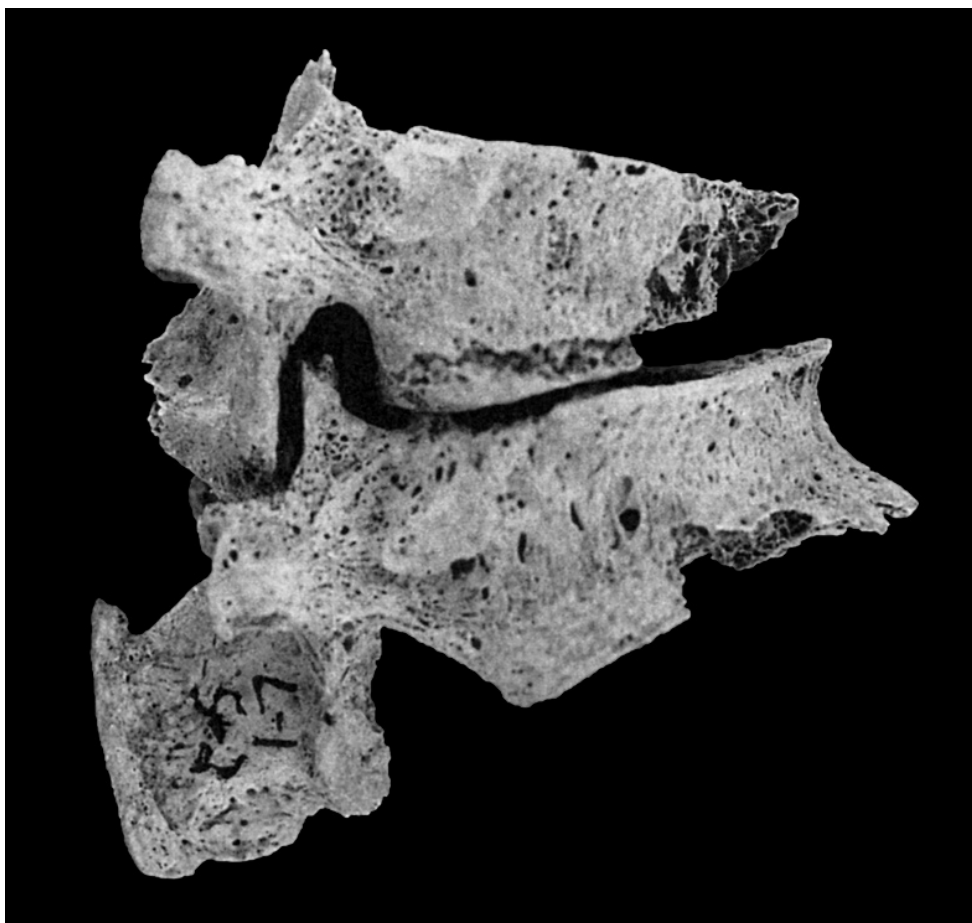


Figure 25.6 Compression fractures of lumbar vertebral bodies. From Larsen and Kelly (1995).

25.8 Physiological Stress

Dental hypoplasias are nonspecific growth arrest markers in teeth that give evidence of the periodicity and intensity of stress (Chapter 19). Two thirds of the individuals studied showed at least one hypoplasia, concentrated at 3–4 years of age. Overall, the Stillwater series showed relatively low levels of hypoplasia prevalence compared to other populations. Only 16% of the individuals showed periosteal inflammation, mostly of the tibia. This was also low relative to most other North American forager series. Although stress was not severe, it was present at appreciable levels. The investigators propose that the narrow hypoplasias and the bone mass data suggest that the Stillwater populations suffered from episodic nutritional stress.

25.9 Dietary Reconstruction

Stable carbon and nitrogen isotopic analysis of human bone samples showed that a variety of foods were consumed. The juvenile samples analyzed fell completely within the adult range, suggesting no age-related differences in diet. There were no differences between adult males and females and no differences between burials from different sites. The wide dispersion of isotopic values in the series indicated that some individuals consumed almost entirely C_3 plants, whereas others ate significant amounts of food with the C_4 isotopic signature. The relatively positive $\delta^{15}N$ values were interpreted to indicate that the diet did not include pinyon pine nuts as a major dietary component, but rather the cattail and desert-blite.

The frequency of dental caries in the series was very low. The high rate of occlusal surface wear, largely attributable to the introduction of grit into the diet via seed grinding on stone metates and via a sandy environment, may have contributed to this low frequency, but most available foods were noncariogenic in the first place. There was a low frequency of cribra orbitalia and porotic hyperostosis.

25.10 The Future

The investigation concluded that the populations inhabiting the Stillwater Marsh comprised individuals who were physically robust, ate varied diets, were in relatively good health, and were not sedentary, with heavy workloads and considerable mobility. These conclusions were reached on the basis of a small sample of the population who lived and died at one place in the Great Basin over a long time period. Even though several of the conclusions could be challenged on the basis of the small and dispersed samples (a restriction that the investigators could not avoid), their bioarchaeological study shows the way for more comprehensive and definitive studies that will surely follow.

All of the Stillwater Marsh burial recoveries and excavations and all of the subsequent skeletal analyses (including the destructive ones on already broken specimens) were conducted with permission from the Fallon Paiute-Shoshone Tribe under a Memorandum of Understanding between the U.S. Fish and Wildlife Service and the Tribe. All remains discussed here and in the monograph have been reinterred in a subterranean crypt on U.S. Fish and Wildlife Service land. With appropriate permissions from the Tribe and the U.S. Fish and Wildlife Service, these remains could be made accessible to other researchers in years to come, as new research questions arise and new, more sophisticated and precise techniques are developed by skeletal biologists.

This page intentionally left blank

Chapter 26

ARCHAEOLOGICAL CASE STUDY

ANASAZI REMAINS FROM COTTONWOOD CANYON

IN THE FOLLOWING THREE CASE STUDIES, the fundamentals of osteology outlined in Chapters 1–22 of this book are applied to fossils. Plio-Pleistocene hominid bones and teeth are rare, usually fragmentary, and almost always fossilized. A case study from an entirely different context is presented here. The skeletal remains are from anatomically modern humans found during an archaeological excavation.

In the post-Pleistocene archaeological record, many human skeletons recovered in and around habitation sites consist of single burials. When intact, these burials are relatively easy to analyze. Any one of hundreds of case studies involving such remains could have been chosen for this chapter, but most would have added little information to that provided in previous chapters. In contrast to the assessment of primary burials, bundle burials and ossuaries are progressively more difficult for the osteologist to deal with because the skeletal remains in them are usually more mixed and fragmentary. Even bigger challenges for the osteologist involve analysis of mixed cremations and other cases in which the skeletal remains have been deliberately damaged. In this chapter we present one such challenging case.

Characteristics of skeletal remains from some archaeological sites in the American Southwest have led investigators to conclude that sporadic cannibalism was practiced by the Anasazi, a prehistoric Native American group responsible for, among other things, constructing impressive cliff dwellings such as those at Mesa Verde in Colorado. In this chapter we describe the discovery, recovery, and analysis of one such assemblage from the state of Utah. This case study demonstrates the importance of being able to identify fragmentary osteological remains. Furthermore, it provides an illustration of how the study of osteological remains in an archaeological context can make significant contributions to the understanding of past events and behaviors.

26.1 Cannibalism and Archaeology

Cannibalism is a subject that holds considerable interest for the anthropologist. Workers in all three subdisciplines of anthropology—ethnology, archaeology, and physical anthropology—have become involved with the study of cannibalism over the past century. Textbooks in anthropology typically report on cannibalism in both the recent and the deep past. Students learn about cannibalism at Zhoukoudian, among the Aztec, and in highland New Guinea.

In 1979 William Arens wrote *The Man-Eating Myth*, in which he investigated some of the most popular and best-documented cases of cannibalism in the ethnohistorical record. Arens concluded that, aside from survival conditions, there was inadequate documentation of cannibalism as a custom in any form in any society. This conclusion sparked considerable controversy, but most critics agreed that, if cannibalism were as widespread as anthropologists had traditionally maintained, better documentation would be required to demonstrate it. Ethnologists have, however, run out of time to provide the documentation. Even in the remote corners of the world where cannibalism was widely reported in the 1800s, the practice no longer exists. The documentation, if it is to be forthcoming, will therefore have to come largely from the archaeological record.

Because the early historical and ethnographic accounts of cannibalism are riddled with doubts and because ethnographic observation is no longer possible, archaeology is the only remaining tool for investigating the existence and extent of cannibalism. But how is cannibalism recognized in the archaeological record? A long history of work on faunal remains from archaeological contexts provides the answer. The faunal analyst studies the context of the nonhuman bone assemblages from archaeological sites and the composition and modifications to these assemblages (cut marks, hammerstone percussion marks for marrow removal, and other trauma). The butchery and consumption of animals can be understood from these observations of faunal remains. When human remains from an archaeological site are consistent with a nutritionally motivated breakdown—when patterns of burning, cut marks, percussion marks, crushing, and other fracture on human remains match what is seen on faunal remains—the assemblage is usually interpreted as evidence of cannibalism.

Over the past 20 years there has been an accumulation of evidence in the American Southwest that indicates the occurrence of cannibalism among the Anasazi. Anasazi burials are typically primary burials and are often accompanied by grave goods. However, during excavation of several sites in the Four Corners area of Colorado, Arizona, New Mexico, and Utah, human skeletal remains have been encountered that were obviously not in primary contexts. These remains are extremely fragmentary, with obvious cut marks, intentional fracture, and signs of burning. Turner (1983b) and White (1992) summarized the evidence and concluded that cannibalism was practiced at these localities. Turner and Turner (1999) have extended these studies. The practice was very uncommon, however, as the number of recorded instances of cannibalism is very small when compared to the thousands of Anasazi sites that have yielded evidence of intentional, primary, considerate burial.

26.2 Cottonwood Canyon Site 42SA12209

Site 42SA12209 is an Anasazi Pueblo I habitation site located in Utah's Cottonwood Canyon, near the town of Blanding (Fetterman et al., 1988). The site was damaged by a uranium mining road in the 1950s or 1960s and not recorded until a 1971 archaeological survey covered the area. Because the site was seasonally impacted by road maintenance, the Forest Service arranged for testing in 1986 and salvage excavation by Woods Canyon Archaeological Consultants, Inc., in July of 1987.

The site is located about 2000 m above sea level in the semiarid Upper Sonoran life zone. The site was part of a large Cottonwood Canyon Pueblo I community. More than one hundred sites have already been located in the area. Based on dendrochronological analysis and ceramic seriation, occupation dates to the latter half of the ninth century (880–910 A.D.). The material culture, pollen, and macrobotanical remains from the site all indicate that the prehistoric inhabitants were agriculturalists who relied heavily on the cultivation of corn for their subsistence.

26.3 Discovery

The salvage fieldwork was aimed at excavating the portion of the site in danger of disturbance by road maintenance. This part of the site consisted of a plaza and seven surface rooms. Associated with the fill of one of the structures (Structure 3) was a feature consisting of hundreds of human bone fragments. The main concentration of bones was in an area 70×60 cm, vertically concentrated in a section of room fill 20 cm deep (Figures 26.1 and 26.2). The fill in this area was charcoal-stained and ashy, with much refuse. Among the hundreds of bone fragments, only one articulated hand was found (Figure 26.3). The “interment” was therefore not primary, and it obviously consisted of more than one individual. The remains were interred sometime after the abandonment of Structure 3 because the pit was dug into the roof-fall of the structure. To ascertain as much as possible about the biology of the individuals whose skeletal remains had been discovered in Structure 3, Jerry Fetterman of Woods Canyon Archaeological Consultants engaged human osteologists at the University of California at Berkeley.

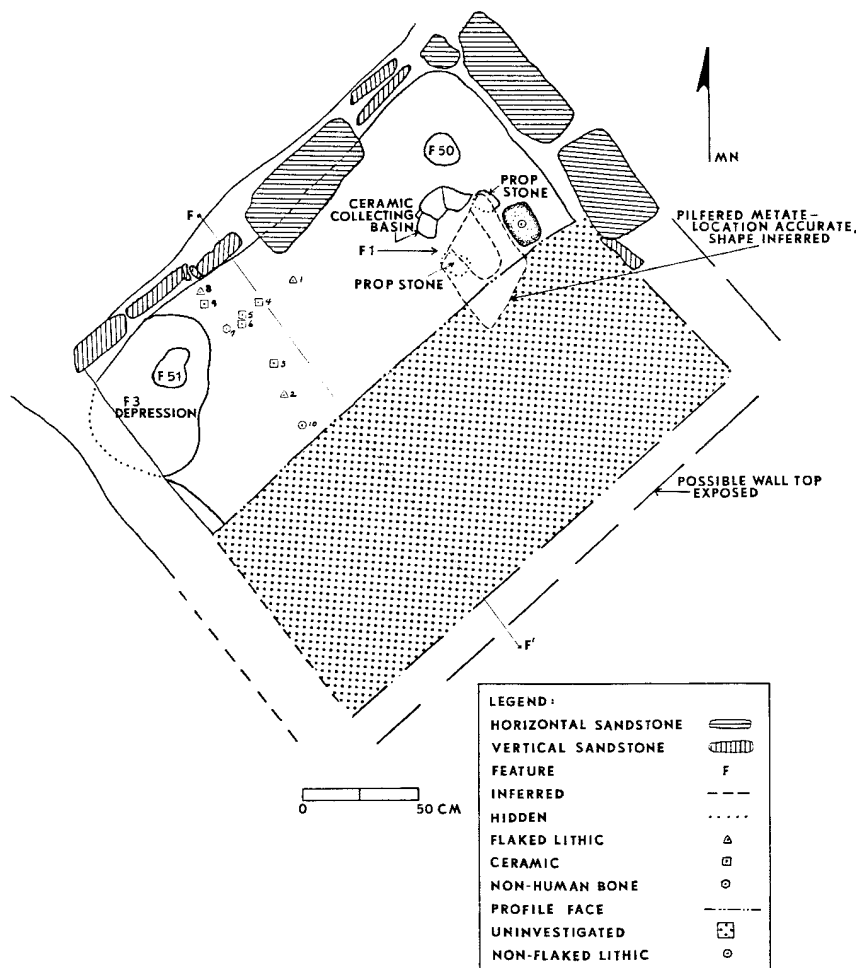


Figure 26.1 Plan map of Structure 3 showing the Feature 3 (F3) depression from which the human bones were recovered. This shallow pit extended below the surface in the west corner of the room and was filled with charcoal-stained and ashy material, with a good deal of refuse (from Fetterman et al., 1988).

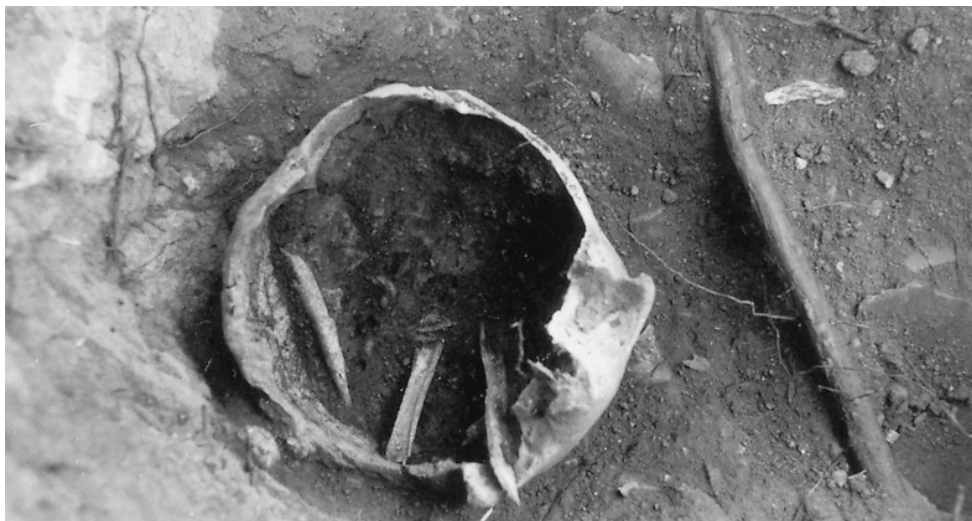

Figure 26.2 Inverted human cranium lacking the base, with fragments of human limb bone shaft inside, *in situ* in Feature 3. Note the nearby plant roots.

26.4 Analysis

26.4.1 Patterns of Damage

Approximately 700 specimens, mostly fragments of bone, arrived in the Berkeley laboratories in autumn 1987. Unlike the remains from several other localities in the Southwest which yielded this kind of material, the Cottonwood assemblage was not particularly well preserved. Root activity had etched the bone surfaces and weakened the fragments, making the collection difficult to handle and analyze. It was immediately apparent, however, that the patterns of damage on the assemblage were similar to those already reported by Nickens (1975) and Turner (1983b) at other sites (*i.e.*, possible cannibalism).

26.4.2 Sorting and Refitting

Procedures involving the identification of specimens in an assemblage like the one from 42SA12209 differ considerably from standard bioarchaeological practice. In normal osteological work, all broken elements are glued together, and all elements are then identified by direct comparison with complete skeletal material. The methodology developed to deal with assemblages like the one from Cottonwood Wash proceeds through several different analytical steps to ensure that the results can be compared directly to results reported by faunal analysts who rarely practice **refitting** (or **conjoining**: the fitting together of broken pieces). Data on the Cottonwood remains were therefore collected for use by both faunal analysts and physical anthropologists (White, 1992).

The Cottonwood Wash specimens received in Berkeley were unwrapped and sorted into cranial and postcranial elements (Figure 26.4). Because of the delicate nature of the bones, care was taken in handling the material. All specimens were identified and sorted by element category, side, and age. Primary identifications were made very conservatively because guessing about element identity at this stage can have negative effects on refitting broken pieces in later phases of the analysis. For example, if a femur fragment is first misidentified as a tibia fragment, it will not be checked against femur fragments later in the analysis, and potential joins will thus be missed.

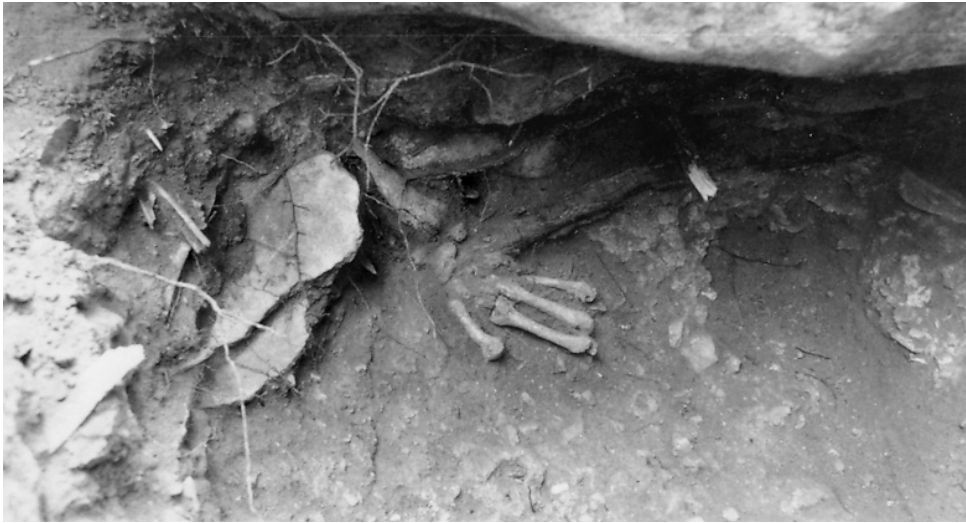

Figure 26.3 Articulated human hand and wrist *in situ* in Feature 3. Note the nearby roots and the limb bone shaft splinters projecting from the excavation wall.

Because of this potential problem, a series of four indeterminate postcranial element categories were used during the element sort.

All recognizably nonhuman elements were separated at this stage of the analysis. None of these were from the feature in Structure 3. The 691 remaining elements were all either recognizably human or indeterminate, with no way to eliminate the possibility that they were human. The number of identifiable human pieces and the lack of identifiable nonhuman pieces in the collection suggested that most of the unidentifiable fragments were human.

Once all of the specimens were sorted into element categories, data on specimen number, siding, fragmentation, element identity, age, identity in standard faunal analysis, and trauma were entered into a computerized database file. Specimens were examined for signs of perimortem trauma by eye and hand lens under strong directional lighting. Cut marks, burning, hammerstone impact scars, adhering flakes (flakes that adhere to the specimen on the edges of impact points), anvil damage, and crushing were all scored as present or absent.

All specimens were systematically checked against each other within each element category to see whether or not they joined. A systematic refitting exercise is time-consuming, but it is necessary for maximum restoration of the bones. Each cranial piece, for example, was checked against every other cranial piece in the collection for which a join was possible. For each pair of bones, all broken edges of the first piece were systematically checked against all broken edges of the second piece.

Of course, a join between two intact right temporals is impossible and need not be checked. Similarly, there is no reason to check a broken temporal edge against a frontal, because these bones do not articulate. Thus many pieces can be ruled out as impossible joins before any checking of broken edges is done. For pieces of vault or limb bone shaft, however, whenever the cortical thickness makes a join a possibility, that possibility must be completely explored. This means checking every appropriate broken edge of a given fragment against every other appropriate broken edge in the collection. This systematic refitting involves physically passing one broken edge against another, looking for a join. When the bone locks into place, the analyst should check for

matches in the cortical thickness as well as in anatomical structures that cross the break. Color and edge length are not factors to consider in such analysis, because post-depositional factors can differentially stain bones in the ground. Furthermore, several fragments can join along the broken edge of a single specimen. Figure 26.5 shows systematic refitting in progress.

The systematic refitting exercise produced many joins across the anciently fractured surfaces of the bone collection from Cottonwood. Nearly 140 pieces were found to join within 33 sets. Some sets were made up of nearly 30 pieces. Joins found during the exercise were temporarily taped together for analysis and photography. Gluing together specimens in an assemblage in which breakage was ancient is not recommended, because it gives future investigators an inaccurate portrait of the assemblage and makes comparison with nonhuman faunal remains more difficult. A few of the fractures were obviously of recent origin because of color and surface texture. These were glued together and notes in the catalog were made to this effect.



Figure 26.4 Analysis of the Cottonwood osteological sample. The specimens were identified and sorted by element, and each fragment was examined for possible refitting.

Figure 26.5 Refitting of the Cottonwood sample in progress. Within element categories, each specimen is checked against all other specimens for possible joins in an effort to restore skeletal elements.



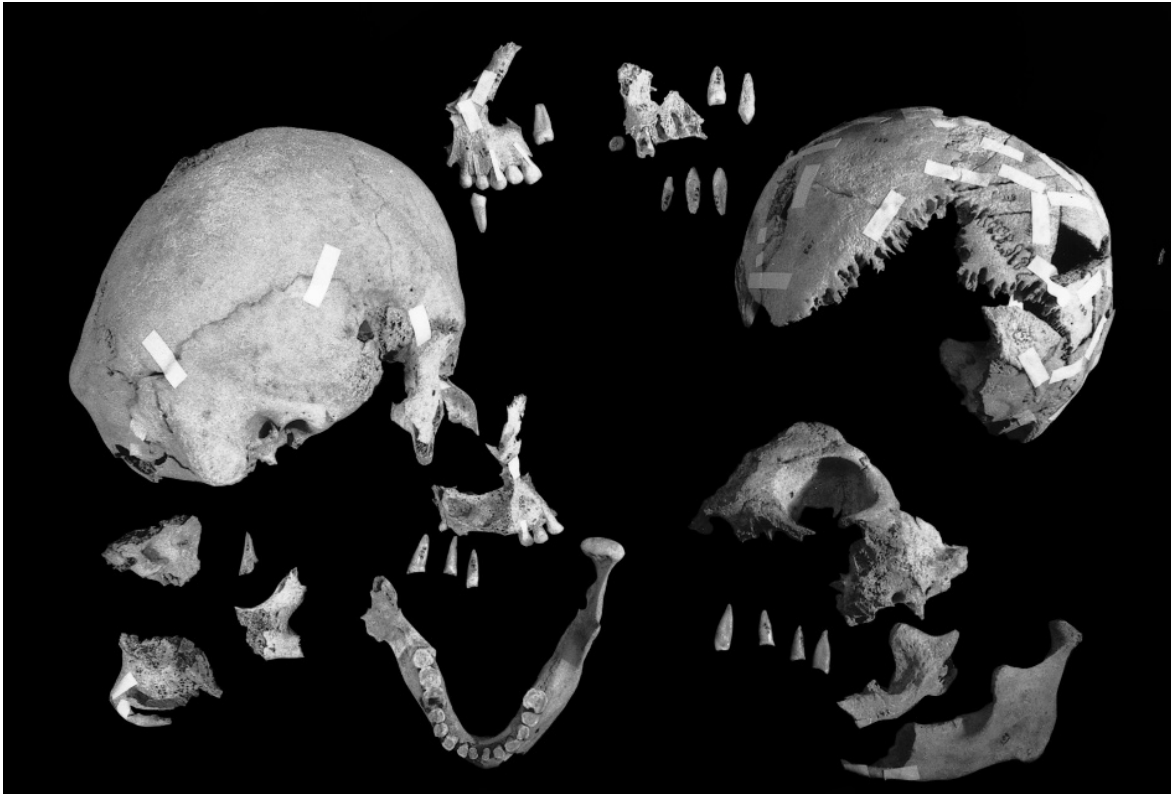


Figure 26.6 The minimum number of four individuals in the Cottonwood sample was estimated on the basis of cranial parts. Specimens are shown here after refitting. White tape holds temporary joins. One-fourth natural size.

26.4.3 Minimum Number, Age, and Sex of the Individuals

The archaeologists wanted to know exactly how many human individuals were represented by the collection of nearly 700 osteological specimens. It was possible, but extremely improbable, that each unrefitted, nonantimeric (not mirror images from opposite sides) fragment was from a different individual. A more appropriate method for estimating how many individuals were involved in the collection was the determination of the minimum number of individuals (MNI, see Chapter 15) that must have been represented to account for the remains recovered. A true minimum number count for a bone assemblage takes into account element, side, age, sex, occlusion, articulation, and antimeric partners.

The original on-site feature report for 42SA12209 noted the presence of at least two individuals and called for further analysis. For this site, as for many ravaged paleontological and archaeological assemblages, the MNI was determined on the basis of the cranial and dental evidence. The MNI of four individuals was calculated independently from both the dental and the cranial evidence (Figure 26.6). There were two immature frontal bones that probably belonged to the two individuals identified on the basis of teeth. There was an intact frontal belonging to a major vault portion of an adult specimen that included mostly intact parietals. A second adult individual was indicated by a large conjoined set from a partial vault with parietal areas duplicating those of the first adult.

These MNI results were achieved after refitting. Identical results were obtained by looking at the dental evidence prior to refitting. Using all of the available evidence, the four individuals based on craniodental evidence were defined as follows:

- **Individual 1.** A fragmentary maxilla with associated teeth. An age of 12 years is indicated by barely open canine and premolar root apices.
- **Individual 2.** Another maxilla fragment with associated teeth. This individual is slightly advanced in root fusion over individual 1, with a probable age of 12.5 years.
- **Individual 3.** Conjoining cranial specimens indicate a robust individual. Probably associated, on the basis of robusticity and size, is another craniofacial conjoining set, a mandibular conjoining set, and isolated teeth. This individual is an old adult.
- **Individual 4.** This individual is represented by most of a cranial vault and probably associated mandible. This individual is also an old adult.

In summary, the assemblage contained a minimum of two immature individuals at about age 12 years, and two old adults. Nothing in the postcranial sample was at odds with this assessment.

Sexing was not possible for the immature individuals. One of the adults was obviously male because of size and robusticity. The smaller adult vault was probably of a female individual. Strong artificially produced flattening of the posterior parietal and occipital areas, a cradle-boarding effect, was evident on both adult crania. The adult male had thickened cranial vault bones, suggesting a response to anemia. The presumed mandible of this individual showed extensive antemortem loss of the posterior teeth and subsequent alveolar resorption.

The presumed adult female individual showed heavy mandibular tooth wear and a large carious lesion on one first molar with an associated abscess in the mandibular alveolar region. A small adult metatarsal head showed minor arthritic lipping.

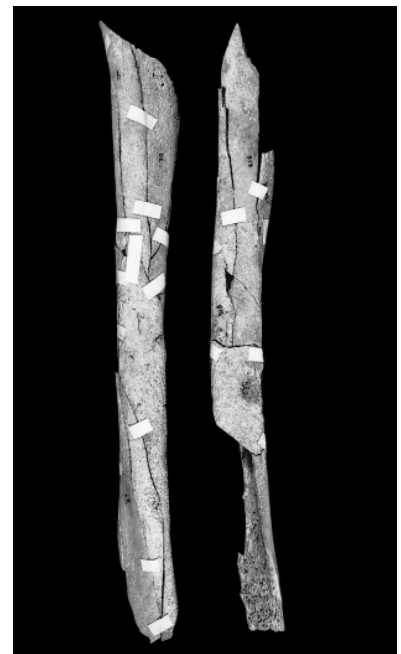

Figure 26.7 Adult femora from the Cottonwood sample. *Left:* individual fragments of shaft prior to refitting; *right:* two femoral shafts restored in the refitting exercise. Note that the bone ends are still missing. Masking tape marks and binds the temporary joints. One-fourth natural size.

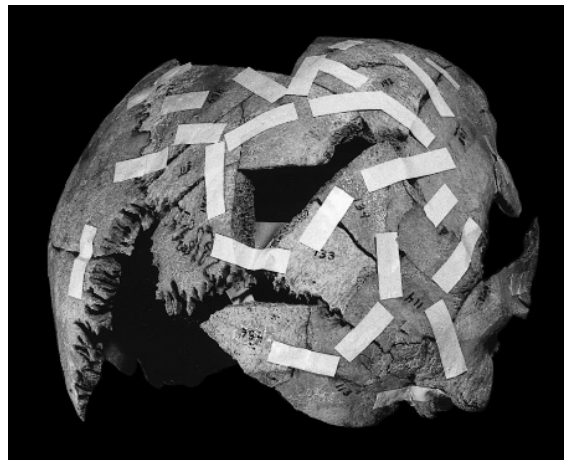


Figure 26.8 Adult cranium from the Cottonwood sample. *Top*: individual fragments of cranium prior to refitting; *right*: and the partial cranium restored in the refitting exercise. Masking tape marks and binds the temporary joins. View is three-quarters, from the right rear. One-half natural size.

26.5 What Happened? The Osteological Contribution

The large number of joins within the assemblage, particularly in the cranial vaults and the post-cranial conjoining sets, suggests that the bones were interred in Structure 3 soon after they were fractured (Figures 26.7 and 26.8). There is no doubt that the fractures crossed by the conjoins represent perimortem damage.

Beyond element preservation and representation, evidence for trauma was preserved in the form of surface modification of the bones in the assemblage. The preservation of the Cottonwood Wash assemblage, with much of the surface detail lost to root etching and erosion, made accurate observation of surface trauma to the bones extremely difficult. This poor preservation rendered quantification of cut marks, hammerstone and anvil damage, burning, and other modification meaningless and misleading; most of the evidence of perimortem surface modification had been erased by postmortem depositional modification.

The fracture on the cranial vaults of all four individuals was ancient, as indicated by the percussion scars, adhering flakes, crushing, anvil damage, and internal and external vault release (Figures 26.9 and 26.10). This pattern of fracture has been seen in other assemblages in the Southwest, particularly the one from Mancos Canyon (Nickens, 1975; White, 1992).

Fracture of the postcranial elements followed the pattern seen at Mancos and elsewhere, with shaft splinters dominating the assemblage. Fracture appears to have occurred while the bone was fresh. Indeterminate cranial fragments were the next most frequently encountered items. Estimates showed that fewer than 60 specimens in the assemblage, less than 10% of the sample, would have been considered identifiable by a faunal analyst.

The portions of each skeletal element represented in the refitted assemblage were also revealing. There was an absence of parts composed of spongy bone; for example, proximal humeri and vertebral bodies were absent. This pattern of element representation and element preservation has also been described for other assemblages in the Southwest. The intentional crushing of spongy bone portions may be involved with extraction of nutritive value from bone as described in ethnographic situations; it is suggestive of cannibalism.

Crushing of the bone was most evident on cranial pieces, and stone-on-bone impact seems to have been responsible. A few specimens showed clear scars of hammerstone impacts that did not result in fracture at the impact point. Several specimens showed flakes of bone still attached to the region immediately adjacent to the hammerstone impact point. These flakes were particularly evident on the long-bone shaft fragments and on the cranial vault pieces. There was some evidence of anvil scratching. The cut mark evidence from the collection was particularly poor, these superficial marks being susceptible to erasure by root action and bone exfoliation. There were, however, examples of cut marks preserved (Figure 26.11).

Unlike the better preserved Mancos Canyon collection, the Cottonwood Wash material was difficult to assess with respect to burning because of the preservation problems described above. It was evident that many of the fragments were burned, some of them extremely calcined. Little can be said about the burning of cranial elements prior to fracture of the vault or burning of the postcranial elements. After fracture, however, some of the fragments were intensely burned. This post-fracture burning included both vault and postcranial pieces in which conjoining showed fresh unburned bone on one side of a fracture edge and heavily burned bone on the opposite side, implying that some bone fragments were discarded in a fire after fracture.

The data from conjoining combine with the evidence of trauma detailed above to show that fragmentation of the assemblage resulted from percussion blows directed at cranial vaults and limb bones. Refitting results also show that many parts were missing from the assemblage.

Several important conclusions were drawn from the analysis of the assemblage from Cottonwood Wash. The assemblage from the feature in Structure 3 included no recognizable nonhuman elements. It included artificially fragmented bones and teeth representing the cranial and postcranial remains of at least four individuals. Two of these individuals were old adults, one a male and one probably a female. Two were young individuals of approximately 12 years of age.

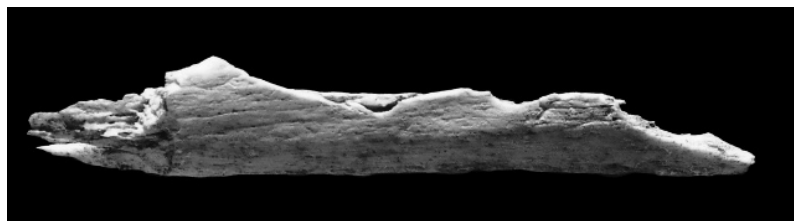


Figure 26.9 Limb bone shaft fragment from the Cottonwood sample shows evidence of hammerstone percussion. Magnification 1.5 \times .

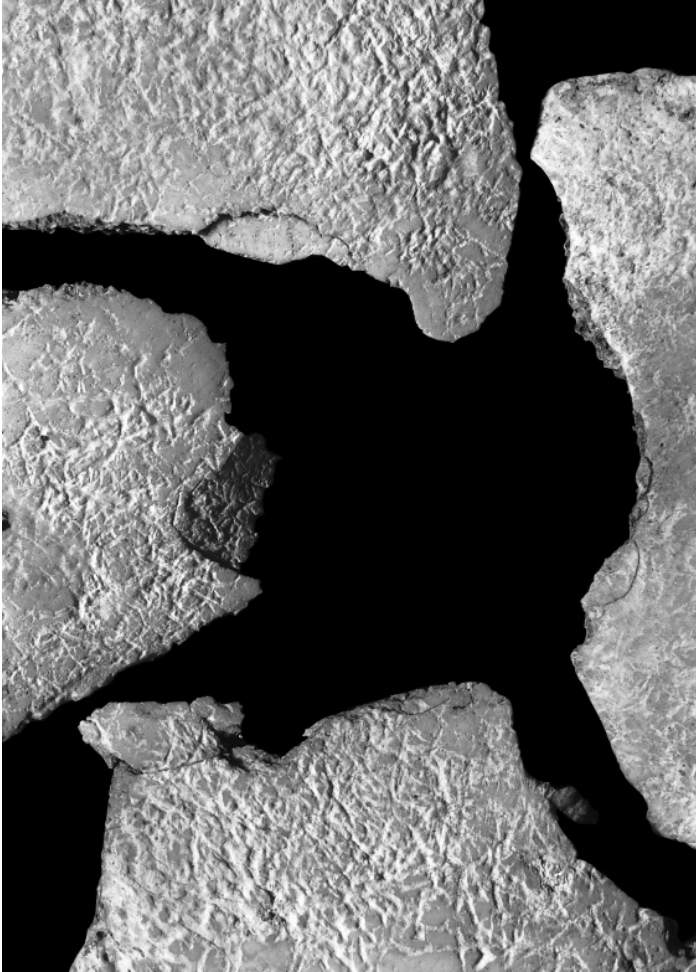

Figure 26.10 Cranial fragments from the Cottonwood sample that show evidence of hammerstone percussion. Note also the extensive root etching of the outer bone surface. Magnification 2 \times .




Figure 26.11 Cut marks made by a stone tool on a long bone shaft fragment. Magnification 4 \times .

The fragmentation in the assemblage and the data from conjoining studies indicate that there was extensive perimortem human involvement with the bone material. This involvement included skinning, flesh removal, or disarticulation activities indicated by cut marks. Burning was difficult to assess, but some bone fragments were heated to very high temperature after fracture. Fracture of the vault and limb bone shafts was accomplished by percussion with a hammerstone, resulting in anvil scars, adhering flakes, and crushing. The lack of spongy bone parts of elements suggests that these portions of the bone were also crushed by hammerstone impact.

The composition and characteristics of the fragmented human bone assemblage from Cottonwood Wash site 42SA12209 are similar to what is seen in a variety of sites across the Southwest. These assemblages have been interpreted as evidence of cannibalism (White, 1992). It will be necessary to address patterns within and variation between these assemblages of human bone from the prehistoric Southwest before we are in a position to understand their full behavioral significance. This endeavor will necessarily involve the combined skills of the archaeologist and the human osteologist if progress in understanding cannibalism is to be made.

Chapter 27

PALEONTOLOGICAL CASE STUDY

THE PIT OF THE BONES

RESearch on human origins is often called **paleoanthropology**. Once conducted by a few people searching for hominid fossil bones, investigations into human origins and evolution now involve large, multidisciplinary, often international teams of field and laboratory specialists who seek to reveal the past in a detail thought impossible only two decades ago. In today's paleoanthropological projects, paleontologists specializing in various plant and animal groups ranging from pollen to elephants are integrated with physical anthropologists, archaeologists, geologists, geochronologists, and remote sensing specialists. The present case study involves the most significant hominid discovery ever made in Europe, a discovery which is re-writing the textbooks of human evolution.

In 1856 a partial skeleton was recovered from a cave in the Neander valley near Dusseldorf in Germany. Recognized by their peculiar skeletal and cranial features, many more Neanderthals have since been found in Europe and the Middle East. *Homo neanderthalensis* is now a widely accepted side branch in the human evolutionary tree. But from where did this form come? When, where, and how did it evolve its anatomical peculiarities? For years, paleoanthropologists posed these and many other questions. Answers came slowly, fragment by fragment, as bits of crania, mandible, and postcrania were revealed at sites such as La Chapelle, Le Moustier, Heidelberg, and Swanscombe. Discoveries at a series of sites in northern Spain, collectively known as Atapuerca, have recently shaken European paleoanthropology. This research is ongoing, but the spectacular finds made by teams of paleoanthropologists working to reveal the Pleistocene Europeans are revolutionizing our views of these ancestors and relatives. This case study is about the most impressive set of Atapuerca discoveries, that of the skeletal remains of over 30 individuals found deep in a cave system, in a small cavity known as the Sima de los Huesos, the Pit of the Bones (Arsuaga et al., 1997). This work involves building knowledge of the past through applying the principles of skeletal identification and analysis stressed in previous chapters. Like most osteological work, it involves many steps, illustrated in Figure 27.1.

FOSSIL HOMINIDS: STEPS TO PUBLICATION



PUBLISH

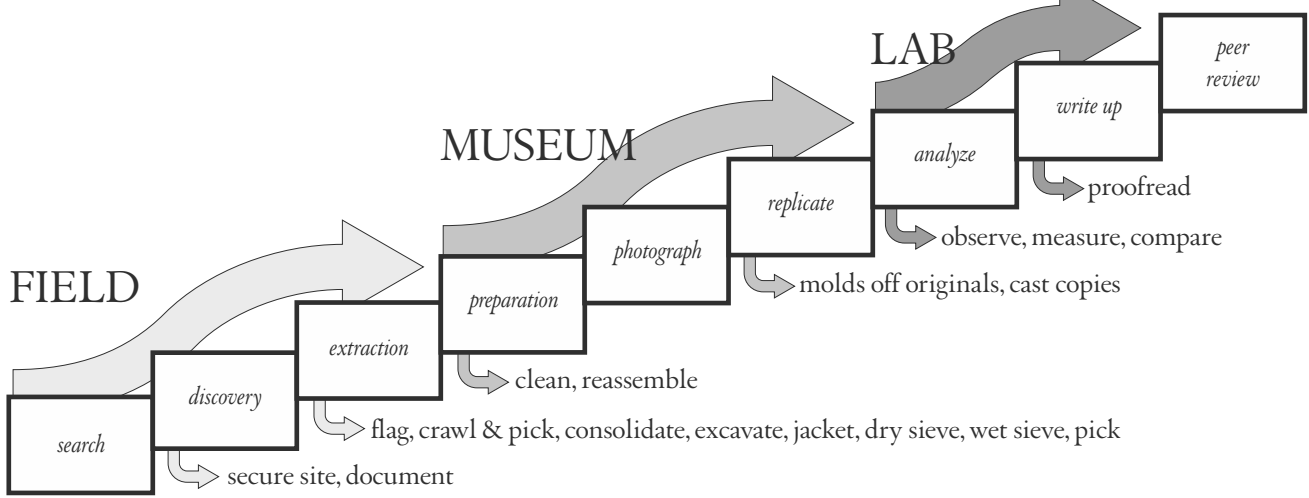


Figure 27.1 The process to publication. Bioarchaeological and paleoanthropological research proceeds through a series of steps that intervene between project conception and publication. Depending on the nature of the fieldwork and laboratory analysis, such work can take large teams of specialists decades to complete.

27.1 Atapuerca

The Sierra de Atapuerca is 12 km northeast of the historic city of Burgos, in the northern part of Spain. The hills here feature a variety of karst systems, including extensive cave systems, sinkholes, and collapsed caves in upper Cretaceous marine rocks. The cutting of a deep and narrow trench for a former railway exposed some of these caves and their fillings. Excavations in the Gran Dolina, one of the cave fillings exposed in the wall of the railway cut at Atapuerca, recently yielded the earliest dated hominid remains from Europe, ca. 800,000-year-old remains that show evidence of cannibalism. The younger Sima de los Huesos is found close by, across the railroad trench, opposite the Gran Dolina.

To get to the Sima today, one enters the Cueva Major-Cueva del Silo system about 500 m away. To reach the Pit of the Bones one must descend into the cave system and traverse a labyrinth of angular, tortuous, mazelike passages. Sometimes stooping, sometimes walking crablike, and often crawling and sliding through tiny openings, one passes 500 m through the dark, silent, and always muddy passages and galleries of this cold subterranean complex. Getting to the Sima and back out is physically exhausting. Near the end of the approach, the cave system opens up into the colossal Cyclops Gallery (Figure 27.2), with a narrow passageway leading into the Sala de las Osas (the bear-nest chamber), where bear hibernation nests and claw marks are found in the clay adhering to the chamber's walls. Excavations there revealed bears who died during hibernation. In the opinion of the researchers, there was probably a small entrance to the cave system near the Cyclops Gallery that allowed bears to get into this part of the cave system to hibernate. Humans apparently only came here once, or a few times, because no archaeological remains are present,

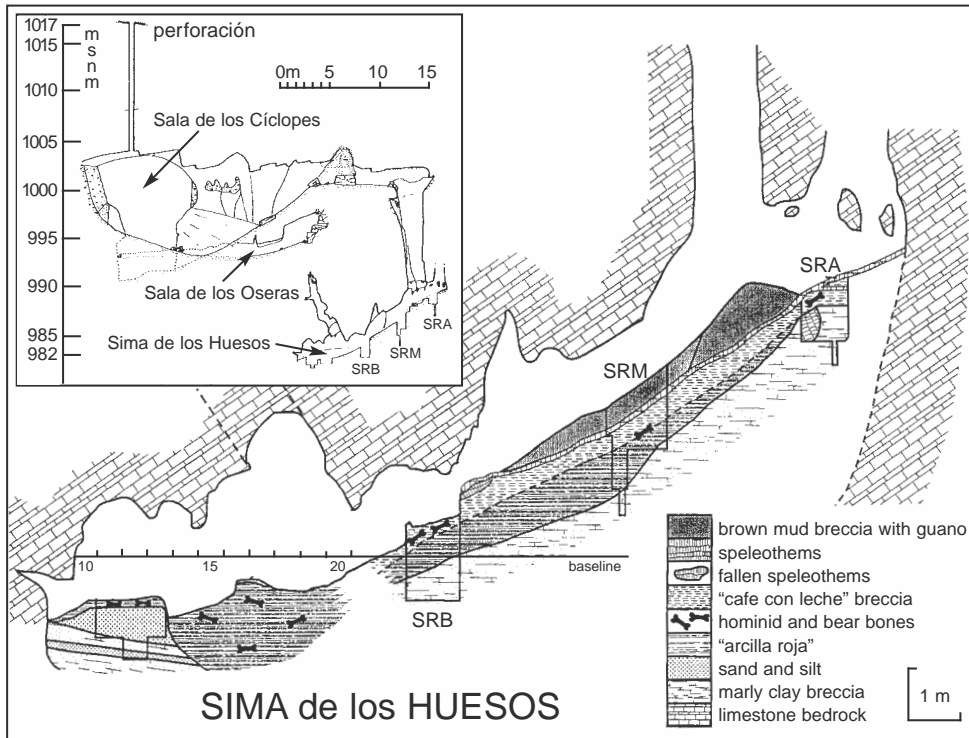


Figure 27.2 Geological sections. Profiles of the Cyclops Gallery and the Sima de los Huesos. From Arsuaga et al. (1997).

and this entrance to the cave system was blocked by a cave collapse in the Middle Pleistocene and sealed.

Today, after traversing the Cyclops Gallery, one passes down a steeply sloping, 2-m-wide passageway leading to a vertical shaft which connects to the Sima below. The only entrance to the Sima is through this vertical shaft. With climbing safety ropes attached, one descends slowly down a narrow ladder into the cavity below (Figure 27.3), reaching an inclined surface known as La Rampa, the ramp. The Sima de los Huesos is the small cavern at the foot of the ramp.

27.2 Discovery

The first hominid fossils from the Sima were found in 1976 during a sampling of its bones by a graduate student of Professor E. Aguirre of Madrid. The sediments of the Sima had been badly disturbed by amateur collectors attracted by the abundant bear bones. A small sample of the disturbed sediment was collected during a brief 1983 visit by Aguirre's team. It yielded three additional hominid teeth among the bear bones. In 1984 the systematic removal of the Sima's disturbed sediment began and the first fossils were found *in situ*. In those days the Sima was choked with disturbed sediment, bones, and fallen limestone blocks.



Figure 27.3 Descending into the pit. Team leader Arsuaga climbs down the 13 meter chimney into the Sima de los Huesos. Photo by and courtesy of Javier Trueba.

27.3 Recovery

In order to reach the *in situ* remains, the overlying mass of debris and disturbed sediments had to be cleared. Large blocks were broken by hammer and chisel. Everything was removed and pulled up through the shaft. Only a few workers could work in the Sima at one time, and oxygen was rapidly exhausted because there was no ventilation. All the disturbed sediment, several tons worth, was removed in the backpacks of workers who climbed out of the pit and snaked their way back to the surface with their precious cargo (Figure 27.4). The sediment was taken to a nearby river where it was wet-sieved to recover the fragmented remains of hundreds of bears and the few hominid remains.



Figure 27.4 The Sima de los Huesos team at the entrance of the Cueva Major. During the field season these workers crawl through 500 m of narrow passageways and cave galleries each day as they descend into the cold, dark, Pit of the Bones. The team leader, Juan Luis Arsuaga, is centered in the back row. Photo by and courtesy of Javier Trueba, from Arsuaga et al. (1997).

Most of the bones were broken, some of them into many dozens of pieces. The resulting mixture of mostly bear and hominid remains was sorted piece by piece, first by taxon and then element. The slow and tedious job of restoration proceeded simultaneously. It took over five years to remove the uppermost disturbed sediments from the cave, but the hominid count climbed. In 1987 a suspended scaffolding was installed in the Sima to allow the paleontologists to work without stepping on the newly exposed, *in situ* sediment (Figure 27.5). A shaft was drilled through the roof of the Cyclops Gallery to allow a more direct removal of sediment.

As the *in situ* deposit was excavated, it was found to contain a bone-bearing breccia with clay matrix, mainly composed of *Ursus deningeri*. This Middle Pleistocene bear was the ancestor of the larger, later Pleistocene cave bear. By the end of the 1995 season, a minimum number of 166 bear individuals was calculated from the thousands of bear bones recovered from the excavations. A total of 1685 hominid pieces had been found to represent a minimum number of 32 hominid individuals. Every part of the hominid skeleton was represented, often by many individuals. A



Figure 27.5 The Sima de los Huesos team at work, deep in the pit. They are working on a suspended scaffold which protects the unexcavated, fragile fossils beneath them. Photo by and courtesy of Javier Trueba.

few other carnivores and micromammals were found, but no ungulates and no archaeological remains. None of the hominid bones were found in articulation, but there are some significant associations. For instance, Cranium 5 and its mandible were found together, as were two hip bones and sacrum of the complete pelvis and many bones of the same hand. Almost all of the bones in the deposit were broken, and restorations and individual associations were difficult to perform.

Excavation of the *in situ* remains had to proceed very slowly because of the logistical conditions and the fragility of the specimens. The bones were extremely soft and fragile, and wooden implements were used to slowly remove the wet clay in which they were embedded. Careful application of preservative was required for each piece. In some parts of the deposit, there was more bone than matrix (Figure 27.6). Only a small part of the Sima deposit has so far been excavated, and it is certain that many more hominid fossils will be recovered. Dating efforts are continuing, but it is clear from biochronologic and radioisotopic considerations that the site is probably greater than 300,000 years old. Already, however, this assemblage is staggering in its size and importance—Atapuerca's Sima de los Huesos is already the largest known repository of fossil hominids from the Middle Pleistocene and a tremendous source of knowledge about the skeletal biology of a hominid population from the deep past.



Figure 27.6 A portion of the hominid fossil breccia during the 1992 excavation. All of the pieces are hominid, except for a bear's rib fragment at the top center. Multiple crania, a mandible, and postcranial elements are visible. The bones are very soft and delicate at this stage of extraction, and can only be extracted, handled, and studied after preservative is applied. Anatomical detail is excellent. Photo by and courtesy of Javier Trueba, from Arsuaga et al. (1997).

27.4 Paleodemography

After the tens of thousands of bear bones had been segregated from the ca. 1600 hominid pieces, and after a massive refitting exercise joined as many of the bones from the ever-growing sample as was possible (Figure 27.7), it was necessary to estimate the minimum number of hominid individuals that had been recovered so far. This was done by Bermúdez de Castro and colleagues, working on the mandibular, maxillary and dental remains. A minimum of 32 individuals were represented, and of these, a balanced sex ratio was calculated (Figure 27.8). Age at death was estimated by applying the Miles method described in Section 18.4.2. The resulting survivorship curve showed low representation of infants and children, and a high representation of adolescents and prime-age adults.

27.5 Paleopathology

Analysis of the hominid sample showed that it was characterized by a high incidence of temporomandibular joint disease. Signs of this pathology were found in 70% of individuals, well above values seen in historic populations. One skull showed an extensive maxillary osteitis associated with a dental apical abscess, and another apical abscess in its mandible. There were no fractures or clear traumatic lesions among 1200 postcranial elements, but one immature individual showed a severe traumatic lesion on its left browridge. Enamel hypoplasias were present, and most commonly emplaced between birth and seven years. There were significantly fewer hypoplasias than are found in either Neanderthals or most modern human populations.

Figure 27.7 Work in progress. Arsuaga stands behind the tabletop of hominid bones recovered from the Sima. Analysis of this large sample could only begin after a meticulous excavation, careful cleaning and preservation, and a full sorting, identification, and refitting. This is only a fraction of the hominid sample that will eventually come from the Pit of the Bones, but it is already the largest and most significant fossil hominid assemblage ever found. Each summer's excavation increases the size of the sample. Photo by and courtesy of Javier Trueba.

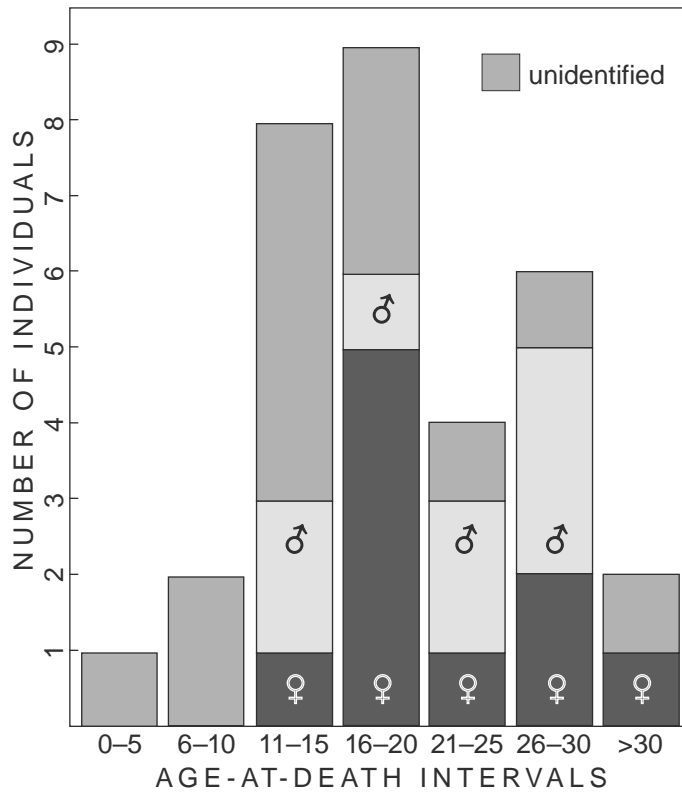


Figure 27.8 Age profile. Age-at-death distribution of the 32 individuals identified in the Atapuerca Sima de los Huesos fossil hominid assemblage. Sexes are differentiated here where determination was possible. From Arsuaga et al. (1997).

27.6 Functional and Phylogenetic Assessment

The skeletal remains from the Sima, because of their excellent preservation and completeness, and because of the large number of individuals, allow for considerations not often available to paleoanthropologists. For example, it is evident that the sexual dimorphism in these hominids was no greater than that seen among modern human populations. It is evident that not all of the peculiar morphological characters defining later Neanderthals had yet evolved in the Sima people. However, a set of traits uniting these Middle and Late Pleistocene forms was detected. For example, the Sima hominids, and the Neanderthals that followed them, share a more laterally oriented scapular glenoid cavity than any other hominid, a transversely oval humeral head, and a host of characters of the occipital, frontal, and facial skeleton. These novel traits, characters shared exclusively between the two hominid forms, suggest to the Atapuerca team that they have discovered the exclusive ancestors of Neanderthals. This interpretation would mean that European populations had a distinct evolutionary role for hundreds of thousands of years. Such findings lead the Atapuerca team to predict that the ancestry of anatomically modern humans will not be found in European fossils but perhaps in Asian or African contemporaries of the Sima people.

27.7 Continuing Mysteries

The fossil hominids from the Pit of the Bones, and the still larger sample that lies entombed within the Pit, will keep paleoanthropologists busy for decades, if not centuries. All these remains will come under the scrutiny of new workers and new techniques. How did this unique collection of fossils come to be deposited in this deep chamber in the first place? This is the central mystery of the Sima de los Huesos. Some facts surrounding the assemblage illustrate the magnitude of solving this puzzle. The demographic profile suggests part of the age pyramid of a living population. Deposition was far from a cave entrance. There are a few rodents, no herbivores, no food refuse, no stone tools, and no human modifications on the bones of either the bears or the hominids (there are some carnivore tooth marks on both). Bears, by far, are the most abundantly represented mammals in the deposit. There is no clear size sorting or alignment of the bones. All elements of the body are represented. The main biases are against sternae, vertebrae, and ribs. No bones are articulated.

Arsuaga and colleagues believe that the Sima was a natural trap for bears in the Middle Pleistocene, and that animals falling into the pit could not climb up the chimney from the pit. They suggest that mortuary practices were responsible for the accumulation of men, women, and children in the Sima. As bears fell into the pit, and desperately struggled in vain to dig their way out, they disarticulated, trampled, unintentionally fractured during digging, and occasionally gnawed other bones already in the Sima. They, in turn, died — only to later become disarticulated, fractured skeletal remains themselves. These remains stayed trapped in the wet, cold mud of the Sima until their scientific rescue began late in the 20th century. It is important to remember that only a small volume of sediments has so far been excavated. It is too early for meaningful studies of spatial distribution to be made, and it is virtually certain that additional element associations will be found. As excavations by this remarkable team of Spanish investigators continue into the next century, more clues to the central mystery of the Sima de los Huesos will continue to bring us closer to a solution and to a better understanding of the deep past.

Chapter 28

PALEONTOLOGICAL CASE STUDY

“ARDI,” THE *Ardipithecus ramidus* SKELETON FROM ETHIOPIA

THIS FINAL CASE study illustrates the application of human osteology in a deeper paleontological context. Like the previous case studies, this one shows that research in human osteology is a team effort built on the basic skills and techniques of identification, recovery, and analysis.

28.1 Background

Fossil remains of truly early **hominids** are frustratingly rare and incomplete (the zoological family Hominidae — “hominids” — includes *Homo sapiens* as well as all species more closely related to humans than to living chimpanzees and bonobos). Even the relatively intact, uniquely preserved partial skeleton of “Lucy” from 3.2 million years ago represents only a single individual, indeed, so far the smallest *Australopithecus* ever found. There are very few places in Africa, let alone the rest of the world, where a dead organism has a good chance of becoming fossilized. There are even fewer places where these fossilized remains are accessible to the scientists who seek them (White, 2004).

Three of the world’s great rift valleys intersect in the Afar Rift of northeastern Ethiopia (Figure 28.1). This large, depressed region is a hot, dry desert inhabited by nomadic pastoralists called the Afar people. Flowing through their desert homeland is the Awash River, draining the Ethiopian highlands (Figure 28.2).

Paleoanthropological research came relatively late to the Afar rift, well after the discoveries of the Leakeys at Olduvai Gorge (in Tanzania) and Lake Turkana (in Kenya). Work in Ethiopia’s lower Omo valley (led by Clark Howell and colleagues) was underway when the young French geologist Maurice Taieb became the first to realize the Afar’s paleoanthropological potential. Taieb performed geological mapping in this region during the late 1960s, collecting the first fossils along the middle portion the Awash River.

Since Taieb’s first explorations, the Afar has become the most important place on earth for the study of human origins and evolution. Discovery of the relatively complete and well-preserved fossil specimen nicknamed “Lucy” by anthropologist Donald Johanson in 1974 first focused global attention here. This and other discoveries at Hadar — the “Lucy” site — led to the recognition of a species of human ancestor known as *Australopithecus afarensis*.

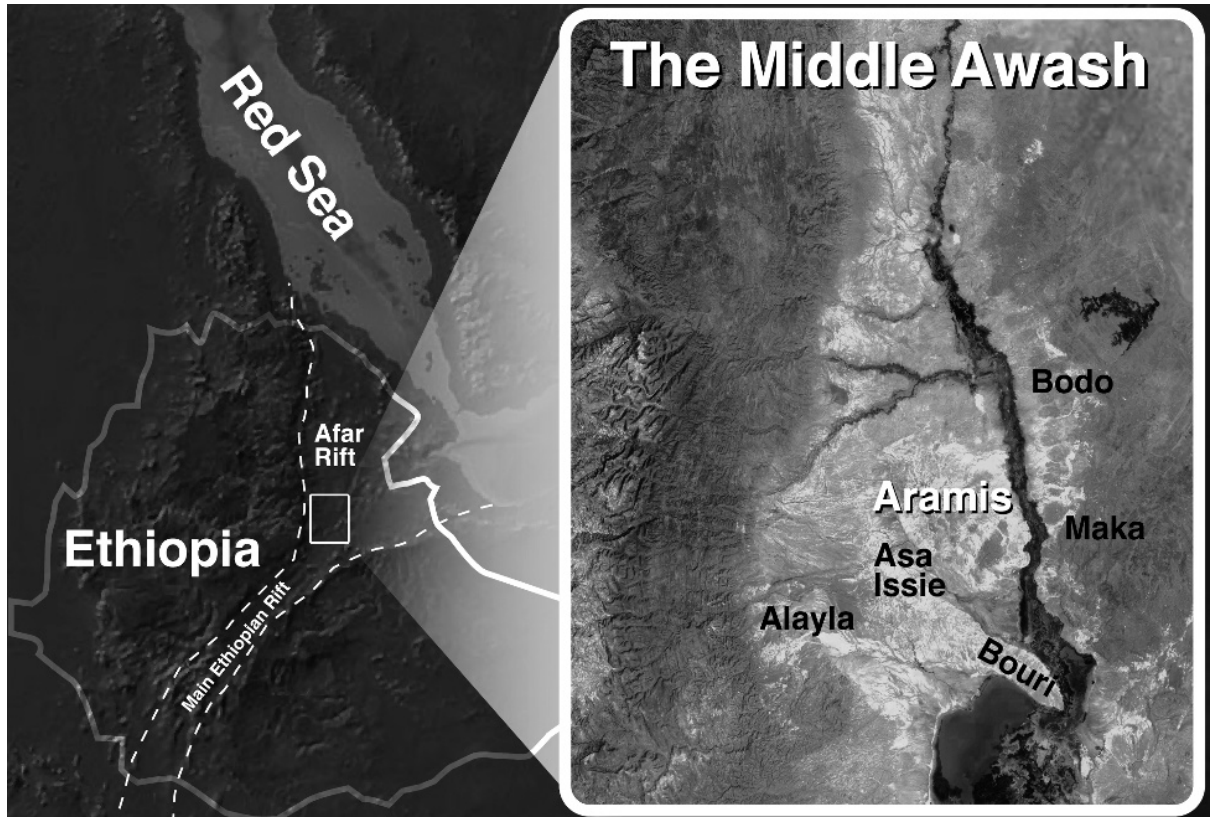


Figure 28.1 **Hominid discoveries.** Map showing the location of Aramis within the Middle Awash study area of Ethiopia. Modified from Gilbert and Asfaw (2008).

When this species was named in the late 1970s its remains came from two sites, Hadar in the Afar, and Laetoli in Tanzania, where Mary Leakey’s team had excavated fossilized bones and teeth as well as footprints preserved in hardened volcanic ash. Since then, even more fossils of this species have been found, and deposits in Ethiopia and Kenya have revealed an even earlier chronospecies, *Australopithecus anamensis* (White et al., 2006). The origins of *Australopithecus* have been a key research problem for the 75 years since Dart’s initial discovery of this genus in South Africa.



Figure 28.2 **Team leaders.** Middle Awash research team leaders with Maurice Taieb (second from right) on the west bank of the Awash River in 2010. Taieb’s pioneering geological work in the 1960s led to the establishment of Ethiopia’s Afar depression as one of the most important paleoanthropological repositories on Earth.

Our team, initially led by the late Professor J. Desmond Clark, has been working under Ethiopian government permit since 1981 in a study area designated as the **Middle Awash**, located about 75 km south of the “Lucy” locality (Figure 28.3). Here, beginning in the 1970s, fossil hominid remains from multiple time horizons have been recovered (Shreeve, 2010; White, 2009b, 2010). Among the earliest Middle Awash hominid fossils is a partial skeleton of a young adult female nicknamed “**Ardi**.” Its first pieces were discovered in 1994.



Figure 28.3 Entering the field. Some paleoanthropological study areas are located in very remote areas. The Middle Awash project team is shown here building a track for the vehicles carrying all of their research and camping equipment into the Afar desert in 2010.

28.2 Finding Fossils

Most of the important fossil remains from open-air sites such as Hadar, Olduvai, Laetoli, Aramis, and Koobi Fora are found as fragments of surface specimens by survey teams walking and crawling eroding outcrops of ancient sediments in search of fossils recently exposed by erosion. There can be literally thousands of fossils at such sites. The identifiable ones are collected and returned to the laboratory for study after their spatial coordinates have been determined to within meter precision by Differential Global Positioning Systems (DGPS; Figure 28.4), and their stratigraphic horizon information recorded by geologists.

Finding the fossils that comprise the very extensive and diverse faunal and floral assemblages for the many localities of the Middle Awash represents a challenge that has led our large international team to devote many years to field research. Each rain brings more erosion to the sediments, exposing more of the buried fossils to the paleontologist. In large collection fields such



Figure 28.4 Recording positions. Two vital pieces of information about fossils are their spatial and stratigraphic positions. Here, a differential GPS is being used to determine precise latitude and longitude for the suid (pig) bones marked by the pin flag. The resistant mesa top in the distance is formed by a 5.2 million-year-old basalt. The Aramis localities are much higher in the stratigraphic succession of the Middle Awash, and therefore younger than the suid fossils being collected here from the eroding clays.

as at Aramis, fossils reaching the surface are best recovered as soon as possible because they can be very fragile (Figure 28.5). Organic components within these remains have long since disappeared. The fossilized bones usually fragment below the surface, even before the paleoanthropologist can see them. Once exposed, they scatter more and more widely in successive rainstorms as they weather out of the ancient sediment and tumble downslope, displaced by everything from whirlwinds to foraging goats.

Middle Awash project paleontologists collect fossils ranging in size from pollen grains to seeds, fossil wood, snails, small mammals such as mice, and large ones as big as elephants. Hominid fossils are rare. The Middle Awash has so far yielded more than 20,000 individually catalogued vertebrate fossils. Of these, only about 300 are hominids. It must be emphasized that it is extremely rare for fossil hominid crania or other body parts to be found intact at such open air paleontological sites. Indeed, the term “site” is not an apt description of these occurrences, which are better referred to as “**fossil fields,**” in which skeletons are rarer than skulls, skulls are rarer than jaws, and isolated teeth are the most common intact elements found. Taphonomic agents ranging from ancient hyenas to modern erosion act together to render the fossil record fragmentary.

Compounding the problems associated with erosion, hominids were never common components of total biomass. They had lifetimes much longer than the average mammal’s. As a consequence, in any given time interval, relatively few hominid carcasses were available for burial and fossilization. Because of their intelligence and lifestyles, hominids rarely died in swamps or lakes where conditions favored fossilization. Hominids are therefore rare members of fossil assemblages.



Figure 28.5 Shattered on arrival. The ancient Aramis silts have a high bentonitic content, so they crack when subjected to repeated wet-dry cycles. By the time the eroding surface reaches fossils, they are sometimes so fragile and fragmented that reconstruction is nearly impossible. Such fossils require immediate application of consolidant and careful extraction.

Given the geological facts and geomorphological settings of such fossil fields, hominids are rarely found *in situ*. Excavations are usually limited to recovering already disturbed and scattered remains of fossils found by paleontologists surveying the surfaces of eroding sedimentary units. The human osteologist working under such conditions must therefore be able to identify small, scattered, and often highly fragmentary skeletal and dental elements. Indeed, were it not for the osteological skills of the surveyors, many fossils such as the famous *Homo erectus* Turkana Boy (specimen KNM WT-15000) from northern Kenya would remain unidentified and unrecovered. If the survey osteologist dismisses a small hominid fragment as an unidentifiable scrap of bone in the field, it may be many years before anyone returns to the area. Field identification is truly the key to success.

The concept of a **search image** is important in this kind of surface survey. It is obvious that a paleontologist wishing to recover the jaw of a shrew-sized animal remains spends a great deal of time on his or her knees, closely scrutinizing the surface of the ground for tiny bones and teeth. The paleontologist searching for fossil elephant remains, in contrast, can walk quickly across the outcrops, scanning much larger areas of the surface for much larger remains. The paleontologist searching specifically for hominid remains should carry an intermediate search image, whether the application is forensic, archaeological, or paleontological. Isolated hominid teeth are usually discernible only from a bending or kneeling stance on the outcrop, whereas a distal femur can be spotted from standing position.

28.3 The Geography, Geology, and Geochronology of Aramis

Today the Awash River supports a wide, green ribbon of vegetation that winds through the otherwise parched desert landscape of the Afar. Each of the small tributary drainages that flow into the modern Awash River bears an Afar name. The Middle Awash project uses these names to identify paleontological and archeological collection areas within which localities are then designated (Gilbert and Asfaw, 2008). Except when the stream infrequently floods due to local rains, the **Aramis** tributary is a dry wadi (dry streambed) within a small catchment whose walls carve into the upper part of a 300-meter-deep sedimentary succession. The overall stack of geological layers in the immediate area ranges in age from 5.5 to 3.4 million years (Renne et al, 1999).

The ancient strata exposed by recent and ongoing erosion in the Aramis area were originally deposited horizontally, in a layer-cake fashion. Today the beds are tilted about five degrees toward the east due to continuing tectonic activity, and faults slicing through the beds are abundant. Each sediment layer in the depository contains clues to the past. Layers of black basalt show that molten lava flowed out to cover a floodplain. In the area's stratigraphic succession, coarse-grained sandy beds are evidence of ancient rivers and lake margins. Lignite beds indicate swamps. Ancient shallow lakes revealed by thinly laminated sediments contain abundant fossilized fish and crocodiles.

The desolate badlands of the Aramis area today bear no resemblance to the many habitats available to the Pliocene creatures who roamed this place millions of years ago. Indeed, in their efforts to probe the past, paleoanthropologists have come to understand that it is sometimes best to ignore the modern lakes, rivers, streams, and mountains that they see today. This is because most of these modern features making up today's geography had not even formed at the time of deposition of the fossiliferous sediments.

Not only were the ancient landscapes very different from those that we see today, but the deposition on these landscapes took place at higher elevations, long before the Afar floor had been dropped to its present low elevation by massive tectonic movements associated with rift formation. Our paleoanthropological challenge at Aramis was to locate and recover fossils and contextual data that would allow a detailed understanding of what this part of the world was like thousands of generations before "Lucy" was even born.

Determining the age of the Aramis sediments was a challenge when we first visited in 1981. The animal fossils found eroding from them were somewhat similar but generally less evolved

than those found at Hadar, to the north (Hadar had already been dated to between 3 and 4 million years ago). Fortunately, intensified work in 1992 allowed Middle Awash project scientists to locate multiple volcanic horizons at Aramis. These could be directly dated by the Argon-Argon radioisotopic technique, and the calculated ages cross-checked via paleomagnetism and biochronology.

Two of the volcanic horizons centered in the long sedimentary succession at Aramis were traced across the eroding landscape, dated, and named. “Gàala” means “camel” in the Afar language (abbreviated GATC for “Gàala tuff complex”); “Daam Aatu” means “baboon” (abbreviated DABT for “Daam Aatu basaltic tuff”). These provided virtually indistinguishable dates of 4.4 million years (Figure 28.6). The dated volcanic strata were separated by a few meters of sediments deposited on a broad, flat floodplain. Very large assemblages of invertebrate and vertebrate fossils were embedded in the silty sediments sandwiched between these tuffs, all of them well-calibrated to a period over a million years older than “Lucy.”




Figure 28.6 Bracketing the fossils. The narrow stratigraphic window sandwiched between two volcanic ash horizons at Aramis (each dated by the Argon/Argon radioisotopic method to 4.4 million years old) contained the “Ardi” skeleton and the thousands of other fossils associated with it.

28.4 Discovering “Ardi”

As they began collection of surface fossils at Aramis in 1992, Middle Awash team members were familiar with the challenge of finding and recognizing the few, usually broken hominid bones and teeth scattered on sedimentary outcrops. The Aramis outcrops were then unusually rich in vertebrate and invertebrate fossils, with abundant bones and teeth representing dozens of ancient species. Most of these fossils, however, were highly fragmentary due to the active hyaena population in the area when this was a wooded floodplain during the geologically brief interval between the two volcanic eruptions 4.4 million years ago.

We were initially impressed by abundant fossil wood at Aramis. Also abundant were leaf-eating monkeys called colobines, and spiral-horned antelope called tragelaphines. The first hominid specimen found was an upper third molar found and identified by Gen Suwa, a Japanese paleontologist. During the first two field seasons our team recovered more parts, belonging to several

additional individuals of this new hominid species. We recovered more isolated teeth, associated dentitions, a child's jaw, a basicranium, and a few limb bones. We published our initial research results in the journal *Nature* in late September, 1994. A little more than a month later, we were back on the Aramis outcrops to continue controlled, cautious collecting. Not only are the eroding slopes at Aramis soft and the fossils fragile, the sediments between the volcanic ashes are often steep, littered with carbonate rubble that makes good hiding places for scorpions and vipers.

Due to the fact that so much of the fauna had been anciently broken into very small pieces, and our realization that there were thousands of such pieces on these outcrops, the project had developed the technique of "crawling," (Figure 28.7) to collect all available fossil material at Aramis. Crawls are generally upslope in direction, conducted by teams of between 5 and 15 collectors who



Figure 28.7 Helicopter (top) and ground-based (below) views of fossil collection. Crawling the surface of the Aramis sediments below the DABT tuff horizon dated to 4.4 million years. The team crawls shoulder-to-shoulder, picking up every fossil fragment within a designated segment of outcrop. The most highly skilled osteologist, the crew chief, is responsible for evaluating the collections as they are compiled. If a particularly valuable fossil is found, crawling ceases, and sieving ensues to recover scattered and, sometimes, *in situ* fragments.



crawl the surface on hands and knees, shoulder to shoulder, collecting all fossilized biological materials between a prescribed pair of taut nylon cords. The Aramis exposures were repeatedly collected with this technique between 1993 and 2005.

The overall Aramis GATC-DABT fauna was so thoroughly fragmented by **taphonomic** causes (see Chapter 20) that we had little expectation of finding more than a few bones belonging to any one mammalian individual — let alone a hominid. It was therefore not surprising that the “Ardi” partial skeleton discovery began with just such a small piece, found late in the afternoon of November 11th, 1994, by then-graduate student Yohannes Haile-Selassie (who had used earlier editions of *Human Osteology* to help learn and then teach bone identification and field techniques). Just 54 meters north of the boulder left by our team ten months earlier (to mark a juvenile’s scattered teeth), he found the base and then the distal end of a second metacarpal belonging to an adult hominid (Figure 28.8).

After he and the other “crawlers” gently retreated in their own footprints (to avoid crushing any other potential fragments), a “no-go” perimeter was established around the fossil so that others would not tread on any additional pieces that we suspected might be lying nearby because of the recent breaks on the metacarpal shaft. It is very important to control the passage of people across a new discovery site because even well meaning efforts have the potential to push fragile fossils into the soft surface, or even crush them underfoot (see Chapter 15).

In a situation such as this, it is very important to establish the distribution of all pieces of the hominid fossil. We do this with pin flags set at the undisturbed location of each piece. This procedure is important because it provides critical clues about the position in which the fossil was originally buried, and thereby provides a guide to the recovery operation that must inevitably follow.



Figure 28.8 First fragments. Second metacarpal fragments were the first element portions found at the ARA-VP-6/500 discovery site in November of 1994.

The most opportune time to find a fossil is just after the first part of it has been exposed by erosion. Unfortunately, the paleontologist usually arrives later than this. As discussed above, many fossils have already entirely weathered out of their original deposit by the time they are discovered. However, by carefully assessing the geomorphology and lithostratigraphy of the site, the surface scatter, and matrix on the specimen, it is often possible to identify the original stratum that contained the fossil, and the spot from which it most likely came.

Pinpointing the *in situ* resting place of a fossil can be much like placer mining for a gold vein. The original spot from which fossils have eroded can be converged upon by looking at the concentration and patterning of fossil fragments—and by taking local topography into account. Many fossils found during paleontological surface prospection have lain on the erosional surface for years. In the case of the “Ardi” discovery, we had a real exception to that rule; we had been lucky to find this fossil while parts of the skeleton were still embedded below the surface, protected from erosion. But we didn’t know that in the beginning; we were just collecting loose fossils on the surface.

Indeed, our initial encounter had suggested that this was simply an isolated, broken metacarpal. No other fragments were visible on the surface, and darkness was falling. Since no rain was imminent, it was judged safe to return to camp after marking the discovery spot and delineating the catchment area in which additional recovery efforts were needed. The individual initially represented by the metacarpal fragments was given the specimen number designation “ARA-VP-6/500,” specifying it as the five-hundredth specimen from ARAmis Vertebrate Paleontological Locality number 6.

28.5 Recovering “Ardi”

During the next week we repeatedly returned to Aramis Locality 6 to carefully sweep the loose sediment around the initial metacarpal discovery point. These loose sediments were sieved through 1.5mm screen (Figure 28.9). Sieving produced additional hominid phalanges, and as we plotted the position of these pieces, we began to identify the likely source of the bones, a small hill just upslope from the spot where the first metacarpal fragments had been found. As we brushed



Figure 28.9 Screening for shattered fragments. Loose sediments surrounding the original surface find are systematically sieved. Establishing the distribution of surface fossils is a key to identifying the original position of the bones, and a necessary step in determining whether additional fossils may be *in situ*.

and scraped the loose sediment from the outcrop, we exposed a hominid phalanx *in situ*, followed by a femur shaft and nearly complete tibia (Figure 28.10). Subsequent excavation at a rate of ~20 vertical mm/day across ~3 square meters during 1994 and 1995 revealed >100 additional *in situ* hominid fragments, including probable hand and foot sesamoids. All were fragile and many were crushed; even some molars had been exploded by calcite crystal growth (Figure 28.11).

There were many questions that arose as we slowly and carefully uncovered the fossils. How many individuals were represented? How much of the skeleton(s) might eventually be found? What kind of a hominid was this? The task at hand, however, was to focus on the controlled exposure and extraction of whatever fossils were still embedded in the silty clay. A skeleton of this antiquity had never been found, so it was obviously scientifically important, as well as representing Ethiopian and world heritage. It was a very heavy responsibility to ensure that everything was recovered without any damage to the uniquely ancient fossils. The activities required for successful extraction of all the pieces lasted over three successive field seasons (Figures 28.12 and 28.13).

The bony remains were off-white in color and very poorly fossilized. Smaller elements (hand and foot bones and teeth) were mostly undistorted, but all the larger limb bones were variably crushed. In the excavation, the fossils were so soft that they would crumble when touched. Each was rescued after exposure by dental pick, bamboo, and/or porcupine quill probe. Exposure was followed by *in situ* consolidation.

As the excavation proceeded, we were forced to dampen the encasing sediment in order to prevent desiccation cracking that would further disintegrate the fossils during exposure and removal. Each of the skeletal elements and/or fragments required multiple coats of consolidant, followed by extraction of the sediment block containing the bone inside, protected and stabilized with encasing plaster and/or aluminum foil jackets (Figure 28.14). Additional consolidant was applied before the fossils were transported to the laboratory at the National Museum of Ethiopia in Addis Ababa.



Figure 28.11 Fracture and distortion. Even the teeth were affected by post-depositional processes. In the case of this molar crown, calcite crystals grew between cracks in the crown to displace the mesial margin from the rest of the tooth. This matrix had to be removed, the enamel fragments isolated, cleaned, and then glued together properly after all internal anatomy had been measured and recorded.

Figure 28.10 The tibia. The “Ardi” tibia was encountered *in situ* by sweeping, and required immediate application of consolidant (hardener) to solidify it prior to extraction.



Figure 28.12 **The excavation.** The “Ardi” discovery site before, during, and after excavation. Field operations of three years established the perimeter of the scattered pieces that the team was able to recover via excavation.



Figure 28.13 **Jacketing a limb bone.** Only the upper surfaces of larger bones were exposed before the specimen was pedestaled, and a plaster jacket was formed with medical bandages in order to protect and stabilize the fossil prior to removal to the laboratory.



Figure 28.14 **Slow, careful excavation proceeds.** Excavation of the site at the end of the 1994 field season. The sediment had to be kept damp in order to prevent dessication cracking, and slow, painstaking excavation was required to avoid damage to the bones entombed in the ancient silts.

Pieces were assigned number suffixes based on recovery order. Back-dirt was weathered in place and re-sieved each season. The 1995 field season yielded facial fragments and a few other elements in northern and eastern extensions of the initial excavation. Further excavation in 1996 exposed no additional remains but established a wide perimeter around the polygonal distribution of hominid skeletal elements.

Each fragment's position, axial orientation, and dip were logged relative to a datum (strata here dip east at -4° to 5°) (Figure 28.15). The polygon representing the outer perimeter and vertical extent of the hominid fragment constellation (based on each bone's center point) was ultimately demarcated by a carapace of limestone blocks cemented after excavation with concrete, then further protected by a superimposed pile of boulders to permanently mark the discovery site and spatial distribution, per local Afar mortuary custom.



Figure 28.15 Plotting the distribution. The bones were tightly clustered spatially and stratigraphically. Here, the base of each yellow pin flag represents the center point of each fossil already extracted from the excavation. The beds here have been tilted to the east (away from the photographer) by faulting.

The distribution of bones and local microstratigraphy indicated that they had come to rest in a shallow swale on the ancient floodplain. There was no evidence of weathering or mammalian chewing identified on ARA-VP-6/500. Bony elements were completely disarticulated and lacked anatomical association. Many larger elements showed pre-fossilization fragmentation, orientation, and scatter suggestive of trampling (Figure 28.16).

The skull was particularly affected, its facial elements and teeth found widely scattered across the excavated area. Bioturbation tilted some phalanges and metacarpals at high dip angles (Figure 28.17). A few postcrania of a large *Aquila* (eagle) and other birds were recovered during excavation, as were a few micromammals. No large mammal remains besides isolated cercopithecoid teeth and shaft splinters from a medium-to-large mammal limb bone were associated. Evidently, the carcass had decomposed close to where it ended up on the ancient floodplain.

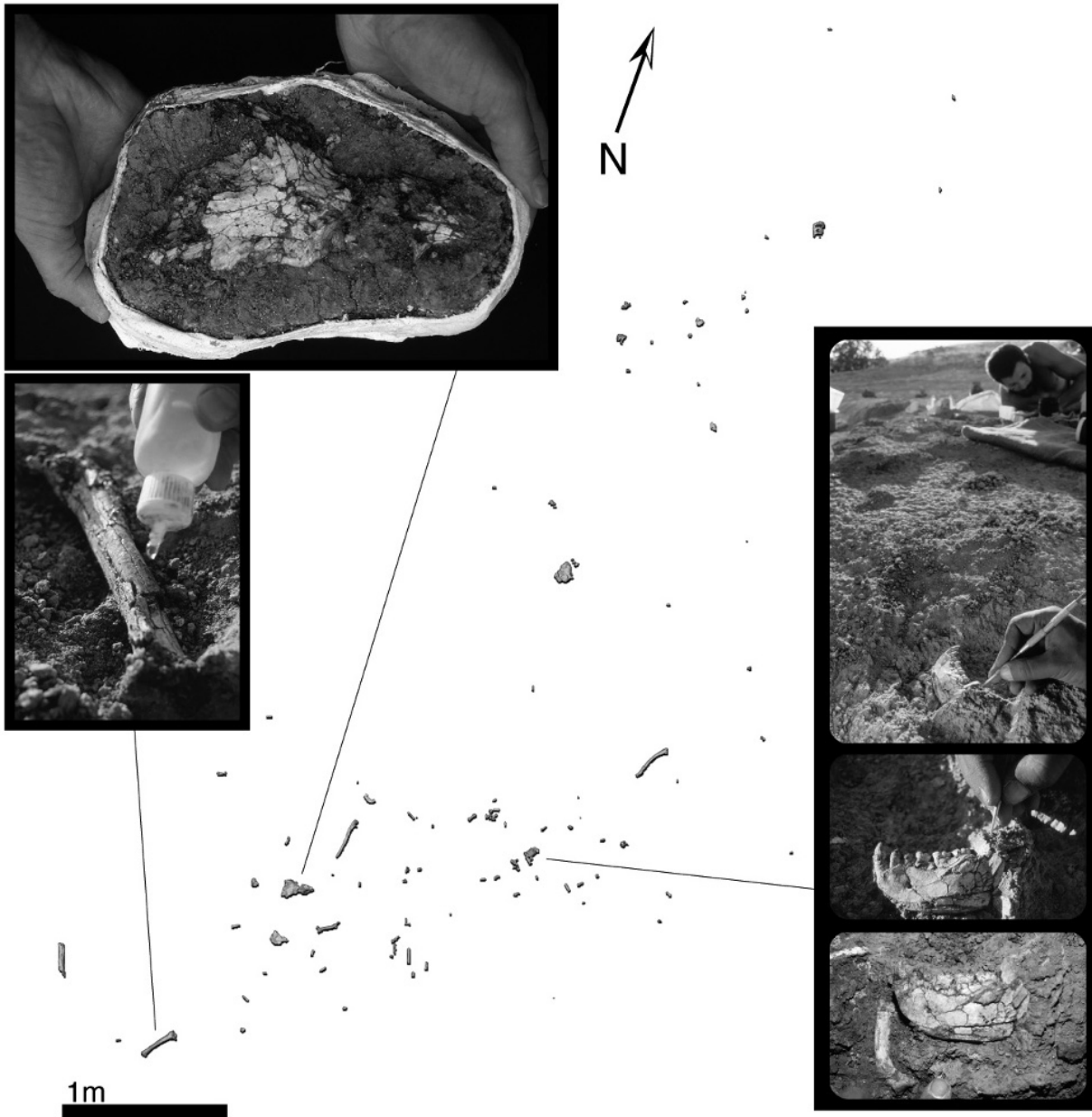


Figure 28.16 **Distribution of elements.** The plan view of the *in situ* skeletal element distribution at the ARA-VP-6/500 hominid excavation.



Figure 28.17 **An *in situ* hand phalanx.** Individual fossils had already begun to disintegrate below the surface because of the expanding and contracting silty clays they had been buried in. Careful excavation was required to expose the major dimensions of each specimen, and each was lifted individually after liberal application of consolidant.

28.6 Restoring “Ardi”

Removing the skeletal remains to the laboratory was the only way to ensure the time and equipment necessary for their safe extraction from the crumbling matrix that still held them (Figures 28.18 and 28.19). Exposure and consolidation of the soft, crushed fossils were both accomplished under a binocular microscope.

Acetone was applied with brushes and hypodermic needles to re-soften and remove small patches of consolidant-hardened encasing matrix. Microsurgery under a binocular microscope at the interface between softened matrix and bone proceeded millimeter-by-submillimeter. Each cleaned surface was re-hardened with consolidant after exposure. This process took several years. The freed specimens remain fragile and soft, but radiographic accessibility is excellent. Most restoration and correction for distortion were accomplished with plaster replicas or micro-CT digital data in order to safeguard and preserve the fragile and precious original fossils in their discovery state.



Figure 28.18 Plaster jacket. The lateral surface of the left os coxae of the skeleton is seen here in the plaster jacket. In the laboratory the matrix was removed millimeter-by-millimeter.

Figure 28.19 First season's yield. At the end of the first field season, many individual elements of the skeleton had been recovered, and are shown here within their plaster jackets, ready for transport to the National Museum of Ethiopia for further preparation.



28.7 Documenting “Ardi”

The National Museum of Ethiopia employs many techniques to make permanent records of its fossil heritage. Prior to molding, each specimen is photographed and videotaped from many angles. Because of the fragility of the “Ardi” specimen, its parts were subjected to micro-computed tomography (micro CT). This scanning provided internal images with which the analytical team could access and study such things as cortical thickness of the various bones (Figure 28.20). Furthermore, the non-invasive, internal views of the bones allowed their distortion to be accurately assessed and compensated for. Finally, by segmenting the various broken fragments, digital restorations were possible to achieve for crushed and distorted elements such as the mandible and cranium.

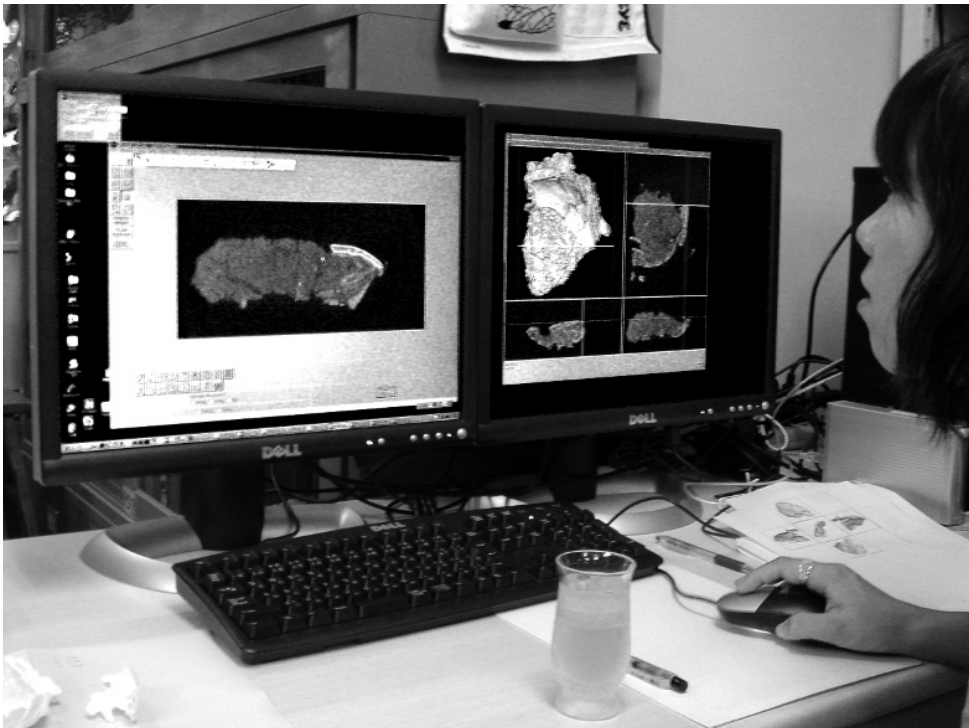


Figure 28.20 Digital segmentation of the crushed cranium. Once the bones had been freed from matrix, they were subjected to micro-CT scanning, which allowed accurate restoration of the original piece, in this case, the crushed cranium.

Silicon rubber molds were prepared after the specimens were cleaned and stabilized (Figure 28.21; see Chapter 16 for details of these procedures). The first “perfect” casts (dental plaster for dimensional stability) produced from these molds were designated as record casts and locked in a protected location in the unlikely event that the original fossils are ever lost or destroyed.

28.8 Studying “Ardi”

One of the first questions asked by the Aramis field recovery team about the set of fossils recovered at the “metacarpal” site was whether we were excavating remains of a single individual. The answer would not be available until well after excavation was over, the fossils cleaned and restored, and a full Minimum Number of Individuals assessment completed (Chapter 16).




Figure 28.21 Molding the mandible. The lower jaw of “Ardi” being prepared for molding with silicon rubber. The two-part mold will make multiple, highly accurate physical copies of the specimen for study and display around the world. Not even the highest resolution micro-CT scanner can render stereolithographic casts with the detail captured by the silicon rubber.



Figure 28.22 Specialists at work. Dozens of scientists from many disciplines were involved with the work on the Aramis fossils. Here, thousands of shaft fragments, mostly from large ungulates found in the same stratigraphic interval as the “Ardi” skeleton, are being identified, and their surfaces analyzed during a taphonomic analysis.

No surface or *in situ* fragments of the ARA-VP-6/500 specimen represented duplicated anatomical elements. Only 10% of the 136 total pieces were surface recoveries at the excavation site; all other pieces were excavated *in situ*. Preservation was identical across the entire recovered set of remains. There was no evidence of different maturational ages among the 136 pieces, and many of them conjoined.

Given the close stratigraphic and spatial association, and given no evidence of any other individual from the carefully excavated spatio-stratigraphic envelope, it was evident that the parts of the ARA-VP-6/500 specimen represented a partial disarticulated skeleton of a single individual. Estimation of the “percentage” representation of a skeleton is not very meaningful in a case like this, but the most important parts of any early hominid skeleton are the skull, teeth, arms, hands, pelvis, legs, and feet. All these were recovered for this individual, judged to be adult due to the fully erupted and wearing third molars, and the complete epiphyseal fusion of all elements.

The cause of death was indeterminate. The specimen was judged to be female on the basis of an extensive analysis of the dentition (the cranial and pelvic anatomy of such an early hominid cannot be assessed by techniques used to sex modern humans). The only pathology revealed by close examination was a partially healed osteolytic lesion of the left proximal ray 5 pedal phalanx (ARA-VP-6/500-044) indicating local infection.

28.9 Publishing “Ardi”

As with any modern multidisciplinary research into human origins, the Middle Awash project includes personnel from many different countries working together on myriad aspects of the study area’s prehistory (Figure 28.22). The Aramis hominid discoveries (a MNI of 36 *Ardipithecus* individuals were represented in the collections) were accompanied by massive data sets that took a very large team 17 years of laboratory and field work to compile and assess.

Because of the abundance of information, each group of plants and animals had to be recovered through fieldwork, and then analyzed in Ethiopia and many other laboratories throughout the world. Because of “Ardi’s” completeness and particularly poor fossilization, great care had to be taken in preparing the fossils for handling, and then molding, photographing, reconstructing, and conducting comparisons with other fossil and modern ape and hominid species.

Many specialized techniques and instruments were used in these studies, ranging from mass spectrometers (to measure the age of the rocks, and composition of isotopes of the tooth enamel and soil carbonates), to micro-CT scanners (to restore and study the inner and outer anatomy of the bones and teeth), to scanning electron microscopes (to study structure and surface details of bone and teeth). Obtaining and processing just the *Ardipithecus* CT scans took thousands of hours. Many more were spent gathering and analyzing comparative modern ape and human materials.

A total of 47 different scientists representing 10 countries and many different research areas of paleontology and geology worked together to author the 11 scientific papers ultimately published in the journal *Science* in October of 2009. These papers covered a variety of different subjects ranging from geology (WoldeGabriel et al., 2009) to “Ardi’s” preferred habitat (a woodland; White et al., 2009; Louchart et al., 2009) to her postcranial (Lovejoy et al., 2009a–d), cranial (Suwa et al., 2009) and dental anatomy (Suwa et al., 2009). As one of the earliest hominid skeletons ever found (Figure 28.23), she will be curated as a national treasure in Ethiopia, where she will be studied by generations of scholars to follow us.

It is hoped that by applying the fundamentals of osteology outlined in this textbook, many more such discoveries and interpretations of human and prehuman skeletal remains will follow, helping to illuminate many aspects of the recent and distant pasts.

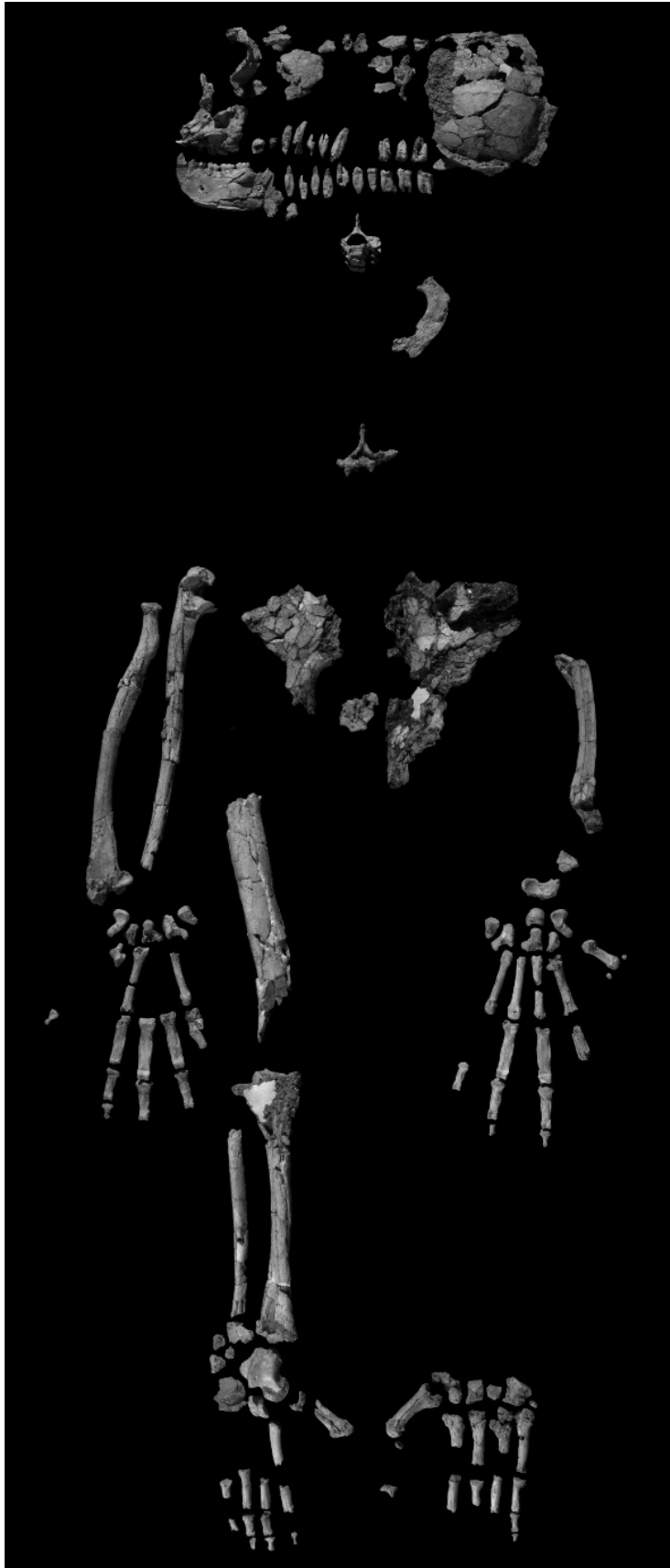

Figure 28.23 The “Ardi” partial skeleton.

Appendix 1

IMAGING METHODOLOGY

THIS BOOK FOCUSES PRIMARILY ON the topographical features of human bone. To adequately convey this information through images, we endeavored to minimize the confusing and unnecessary aspects of natural bone material, such as stains and the translucence of some bones and teeth, and to concentrate on the important morphological features. Preparation of the bone, imaging equipment, lighting and staging, media, and post-processing were each significant variables in meeting these goals.

A1.1 Photography

A1.1.1 Preparation of the Bone

Osteological material was coated in such a way that stains and glare were reduced without loss of surface details. After the bone material was degreased, a finely ground, opaque titanium pigment suspended in a solution of ethylene glycol and water was applied through the nozzle of a 0.2 mm double-action airbrush. Air pressure was adjusted between 24 and 40 PSI during application, depending on a variety of circumstances including the nature of the bone surface and humidity. One coat was generally sufficient to obscure stains and create an opaque nonreflective surface.

Other methods of coating, including ammonium carbonate smoking and direct brushing with a variety of paints, proved unacceptable. The titanium coating used was easily removed with water and/or alcohol.

A1.1.2 Equipment

Cameras used to record the images included a Sinar F2 4 × 5 view camera, a Hasselblad 500CM (medium format), and a Nikon F3T (35 mm format). The use of three formats allowed similar proportional enlargements of the negatives regardless of subject size, because subject-to-image ratios could be kept somewhat the same. This resulted in a fairly consistent grain character for each figure. The primary 4 × 5 lens was a Schneider Symmar HM 240 mm f/5.6 with a Copal #3 shutter. A 120 mm f/2.8 Zeiss S-Planar with a B55 extension tube provided the images in the medium format, and a 55 mm f/2.8 Micro-Nikkor with a PK-13 extension tube worked on the tooth shots in the 35-mm format.

A few images new to this edition (phalangeal bases for example) were shot digitally from the original source material with a Nikon D2xs and 35–70mm f/2.8 Nikkor lens.

A1.1.3 Lighting and Staging

Lighting was exclusively artificial (daylight-balanced). Two Speedotron® electronic strobe packs at full power were used to drive one quad head (4800 watts) main light and one single head (2400 watts) background. Each strobe was raw (without reflector or diffusion).

Staging began with a 4 × 8 foot neutral gray sheet of formica on the floor. An 18 × 24 inch sheet of nonglare glass was suspended about 16 inches over the background on two C-stands. Several sheets of white foam core board formed a tunnel through which the background strobe flashed. An additional board acted as a bounce reflector at the end of the tunnel. The only outlet for background light was through the glass stage from below. To maximize surface detail, the main light flashed at a very low angle to the subject. This light bounced off of a white card on the opposite side of the subject to fill in shadows and reduce contrast.

Each bone was placed on the glass and oriented on a variety of pliable and tacky substances hidden from view. In most cases, the angle and power of the flash created a slight reflection of the subject on the glass. To absorb excess light and minimize this effect, a black mask was cut for most subjects and placed out of view on the underside of the bone.

The direction of light and subject orientation follow traditional scientific illustration convention. In general, the light falls on the subject from the upper left relative to the viewer. Within this reference a hierarchy is followed for the preferred orientation: dorsal top, ventral bottom; proximal up, distal down; anterior left, posterior right; superior up, inferior down; and any special view required to convey specific information. Lateral views are left lateral where bilateral symmetry exists. All skull part figures are oriented in approximate Frankfurt Horizontal with the aforementioned conventions in mind. Any deviation from these conventions is mentioned in the figure legends. All bones were photographed complete with one exception. The femur was too long to fit on the stage and was shot in two parts.

A1.1.4 Film and Development

Ilford FP4 black-and-white film (rated ISO 125) was chosen for its moderate contrast, wide latitude, availability in all formats, and fine-grain characteristics. Preliminary tests indicated that an ASA of 80 worked best for the high-key subjects of the project. Polaroid instant films type 55 and 554 were employed to check contrast, lighting, depth of field, and orientation before most final exposures.

Because extension tubes and long bellows extensions were used in most shots, depth of field (focus) became a concern. Thus a near-minimum lens aperture was used whenever possible to balance sharpness with depth of field. A slower film speed would have required a very close and difficult-to-control flash-to-subject distance. Also, the additional fine grain available from the slower films, though desirable, was superfluous because of the limitations of photolithography and the printing process.

All film was developed normally. The images were enlarged to produce prints at natural size of the subject bone. We made separate prints of each end of the longest bones that required splitting the images to fit on a page at natural size. Most images were printed on Ilford Polycontrast resin-coated paper with #4 and #4.5 filters. Some photographs were printed on Ilfobrom fiber-base paper, contrast grade 3. Certain areas of each image were burned with no filter to bring out highlight detail; other areas were dodged to open shadows. The prints were slightly overexposed to avoid loss of texture in the highlights and to carry all the detail evident in the negative. This artistic compromise maximized the educational content.

Main light-to-subject distance remained largely constant. The camera-to-stage distance varied in some cases to maintain a consistent film plane-to-subject focus distance as the size of the subject changed. Certain deep subjects (*e.g.*, proximal views of limb bones) dictated adjustments that resulted in great camera-to-stage distances. These greater camera-to-stage distances led to unavoidable variations in lighting ratios between the main and background lights. Since the background

is superfluous to the intent, we printed the figures to maximize the information on the bone and allowed the neutral dark gray background to vary as much as one-and-a-half gray scale zones.

A1.1.5 Scanning and Photolithography

For the original edition of this book, halftone screens were created from the photographic prints. In the second edition, digital encapsulated postscript files were used in “direct to plate” printing, as is the case for the present edition. A few figures new to this edition featuring non-split long bone images were re-scanned using a Microtek ArtixScan 1800f directly from the original negatives to avoid the inconsistencies of matching the ends of split prints used in the core of the book. These images were processed in Adobe® Photoshop® CS3.

A1.1.6 Post-processing of Digital Images

For the current edition of this book, the tonally variant backgrounds of the original photographic prints were digitally isolated and set to digital black.

For each image, the background was digitally isolated using Adobe® Photoshop® CS3. A coarse level of background selection was initially accomplished using Photoshop’s Quick Selection Tool with a 10-pixel brush on the image at 100% magnification. Then, while viewing the image at 300% magnification, and with a 5-pixel brush, the selection area was manually edited to include all background areas in the photograph and to ensure that no portions of bone or photographic scale were included in the selection area. Finally, the magnification was increased to 600% and final touch-up was done with a 3-pixel brush and the Elliptical Marquee Tool.

Using the Refine Selection Edge Tool with the radius set to 0 pixels, contrast set to 10%, smooth set to 0, and feather set to 0.5 pixels, the selection was set to contract (away from the bone and other subject matter) by 15%. Before applying the selection refinement, the selection was viewed as a Quick Mask, toggling back and forth between the mask and the image to visually verify the boundaries of the refined selected area. While setting the selected area to contract by 0% would have a more visually pleasing result, contracting by 15% was selected as a safety factor to ensure that not even the slightest portions of the edges of bones would be accidentally selected.

As a final step, a new layer was created and superimposed on the image layer. With the foreground color set to digital black, and with a brush size set to 2500 pixels, the refined selected areas of background were painted digital black in the superimposed layer. After a final visual inspection of the result, the dual-layer image was archived. A flattened (single-layer) copy of each image was produced for inclusion in this volume.

For a few non-critical images of bones, we resorted to creating clipping paths around the subject(s) to drop out backgrounds in the original image. These files were then placed in image frames with a consistent background. This technique was also used to reduce gaps between subjects in one photograph and align them in the final image to fit better on the printed page.

A1.2 Micro-computed Tomography

The bone cross-sections illustrated in Chapters 8, 9, 10, 12, 13, and 14 were obtained through high-resolution peripheral quantitative computed tomographic (HR-pQCT) scanning. The bones were scanned on December 10–11, 2009, by Andrew Burghardt of the Musculoskeletal Quantitative Imaging Research (MQIR) Group of the Department of Radiology and Biomedical Imaging at UC San Francisco, using a Scanco Medical XtremeCT HR-pQCT scanner. The scanner has an isotropic resolution of $41\ \mu\text{m}$ (*i.e.*, voxel size of $41\ \mu\text{m}^3$). The exact locations of the sections were indicated by single, short, light pencil marks executed with soft lead (the resolution of

the machine rendered the use of even the thinnest Teflon ribbon or PTFE tape problematic).

The bones were placed on a carbon-fiber plate and oriented according to anatomical and biomechanical conventions using radiotranslucent foam. Once properly positioned, the bones were firmly fastened to the carbon-fiber plate using 3M Micropore™ adhesive tape. The portions of the adhesive side of the tape that were closest to the bone were covered by short, reversed segments of the same tape, such that no adhesive touched the bone. The carbon-fiber plate was positioned inside a carbon-fiber specimen tube which was then placed into the gantry of the scanner. The plate was then leveled using a bubble level. The position of the tomographic acquisition was aligned with the desired section location using a laser alignment beam. The scanner then scanned a 9 mm section of the bone, centered on the desired section.

Raw data were gathered by an array of three 1024×256 charge-coupled devices (CCDs), and were subsequently reconstructed using a modified Feldkamp algorithm across a 3072×3072 matrix with 16-bit color depth.

Appendix 2

A DECISION TREE (“KEY”) APPROACH TO TOOTH IDENTIFICATION

LEARNING TO IDENTIFY ISOLATED TEETH is difficult. The task of differentiating the 52 possible anatomically normal (*i.e.*, nonpathological, nonidiosyncratically variant) combinations of tooth type (I, C, P, M), dentition (permanent *vs.* deciduous), arcade (upper *vs.* lower), position (*e.g.*, P₃ *vs.* P₄), and side can seem daunting at first. With time and practice, these identifications will become much easier. A trained osteologist can make such an identification nearly instantaneously by comparing the unknown tooth to 26 familiar mental patterns (26 unsided patterns, or half of the total of 52 sided teeth) and then siding the unknown tooth.

In order to learn these visual patterns, the beginning osteologist must learn to make a series of observations and judgments about the morphology of the tooth to be identified. This hierarchy of judgments can be visualized as a decision tree (or identification key). The complete, illustrated decision tree (see Figure A2.1 for an overview) is too large to present as a single diagram in this book, so it has been broken down into thirteen segments (Figures A2.2–A2.14) in order to include the most useful criteria. You may find it helpful to copy these charts and then combine and recombine them as needed while you learn to identify isolated teeth. As you internalize the information presented in the charts, you will find that you need to refer to fewer and fewer charts in your identifications.

A2.1 Using the Decision Tree

Each of the decision trees is meant to be read starting at the leftmost node. From that node, there will be either two or three identification paths, each represented by an arrow. To determine which identification path to take, read the identification criteria that are printed over each arrow and select the path (arrow) whose identification criteria most closely match the characteristics of the tooth you are trying to identify. Using these decision trees, every one of the 52 possible normal human teeth can be identified by making no more than six choices between two (or sometimes three) possible answers (see Figure A2.1).

On each of the partial decision trees (Figures A2.2–A2.14), the possible choices are presented as paths (arrows) from a known starting point (at the far left) to one of a series of possible identifications (at the far right). A set of observations lies between these endpoints, arranged into two columns. The column on the right contains observations and comparative statements that you can use to judge which identification is more likely to be the correct one. The column on the

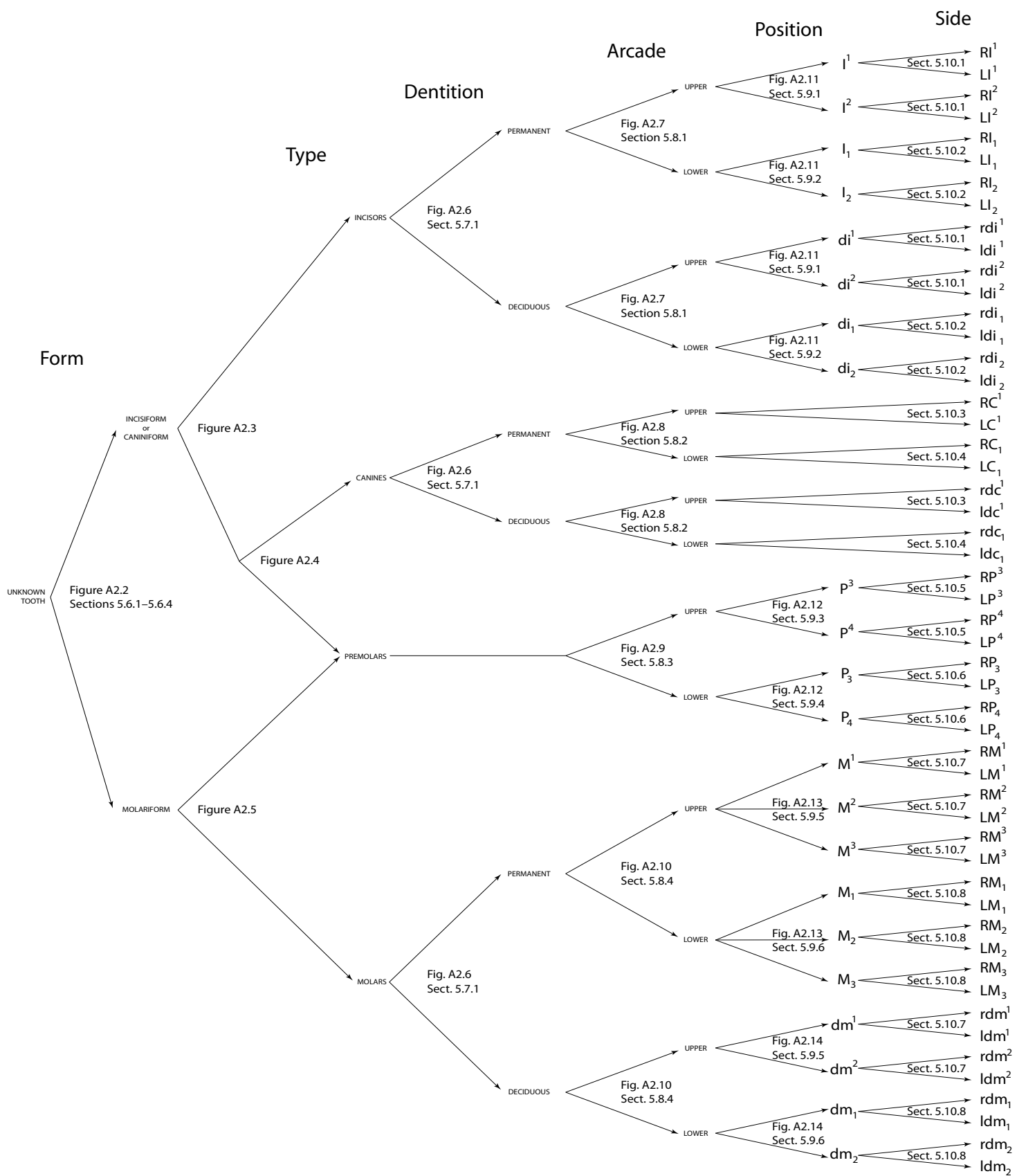


Figure A2.1 An overview of the complete decision tree that can be used to assist in the determination of dentition, tooth type, arcade, position, and side of an unidentified human tooth.

left contains observations that can serve as “shortcuts” to identifications. You will not always be able to use these shortcuts, but when you can, they will save you time in your identifications. When you arrive at an identification using a shortcut, however, always confirm that identification against all of the available evidence.

While many shortcuts to identification are available, always remember that there is no single, magic criterion that will always successfully distinguish one tooth from all others. Shortcuts will give you a good idea of the direction you should follow in your identification, but you should always use multiple criteria for each identification, checking each one independently and making your decision based on the majority of the evidence whenever there is conflict. The criteria to check include the number, location, and size of cusps, fissures, foveae, and other crown morphology; the number, location, and orientation of roots; the presence, placement, and shape of interproximal contact facets; and the location and orientation of occlusal contact facets. At each endpoint on the decision tree, you will find a reference to the relevant section of Chapter 5 for that tooth. Be sure to check your identifications against the descriptions given in these sections.

The decision trees presented here are intended for use on only anatomically normal human teeth; the presence of pathologies, malformations, or nonmetric traits may affect the accuracy of the identifications reached.

What is the general form of the tooth?

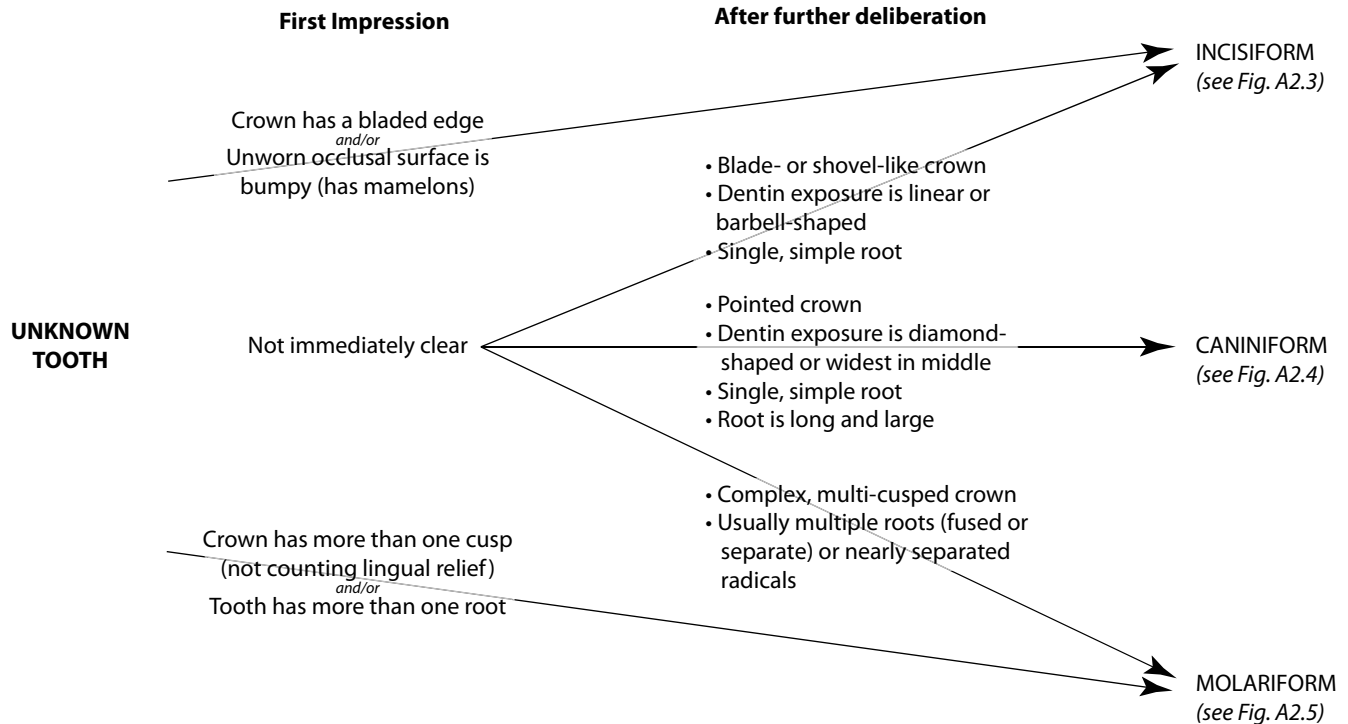


Figure A2.2 Partial decision tree for the determination of the general form of an unknown tooth.

Incisor or canine/premolar?

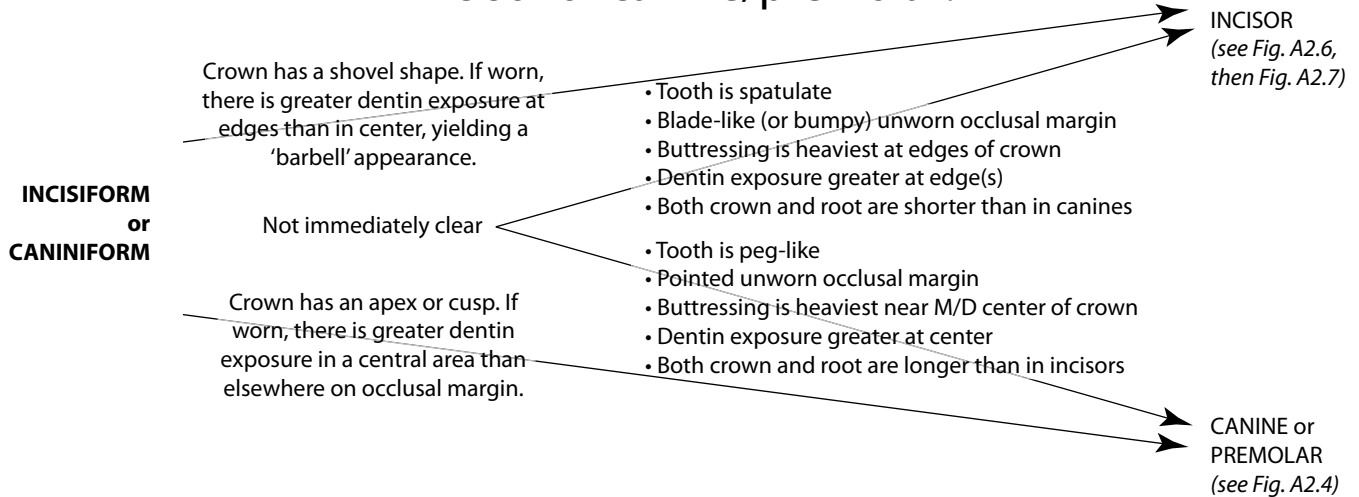


Figure A2.3 Partial decision tree for the determination of whether a nonmolariform tooth is an incisor or something else (*i.e.*, a canine or premolar).

Canine or premolar?

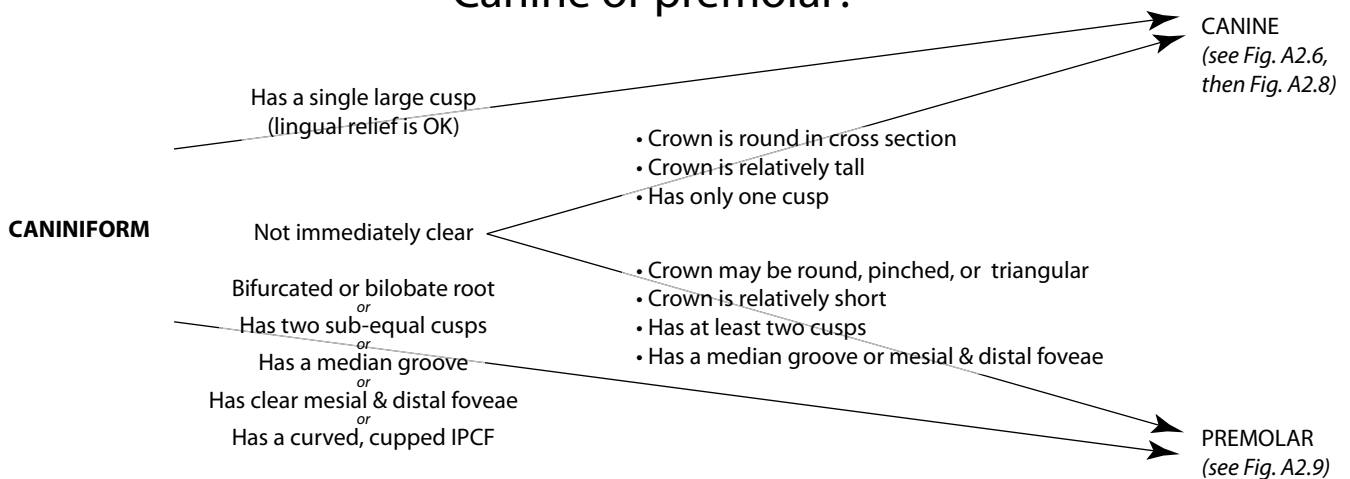


Figure A2.4 Partial decision tree for the determination of whether a nonmolariform tooth is a canine or a premolar.

Molar or premolar?

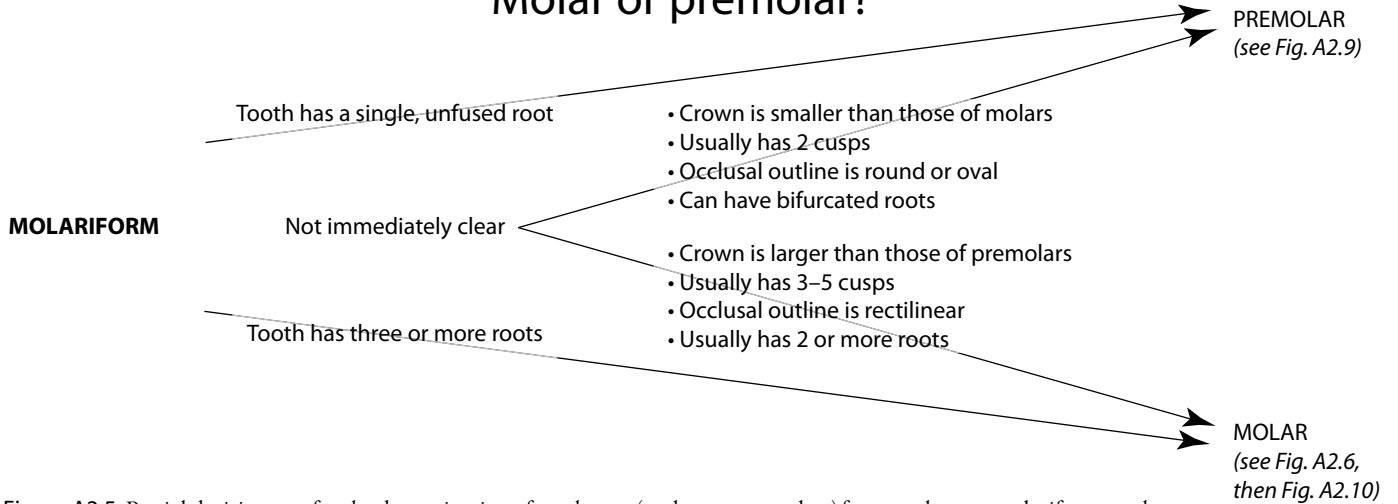


Figure A2.5 Partial decision tree for the determination of tooth type (molars vs. premolars) for an unknown molariform tooth.

Permanent or deciduous?

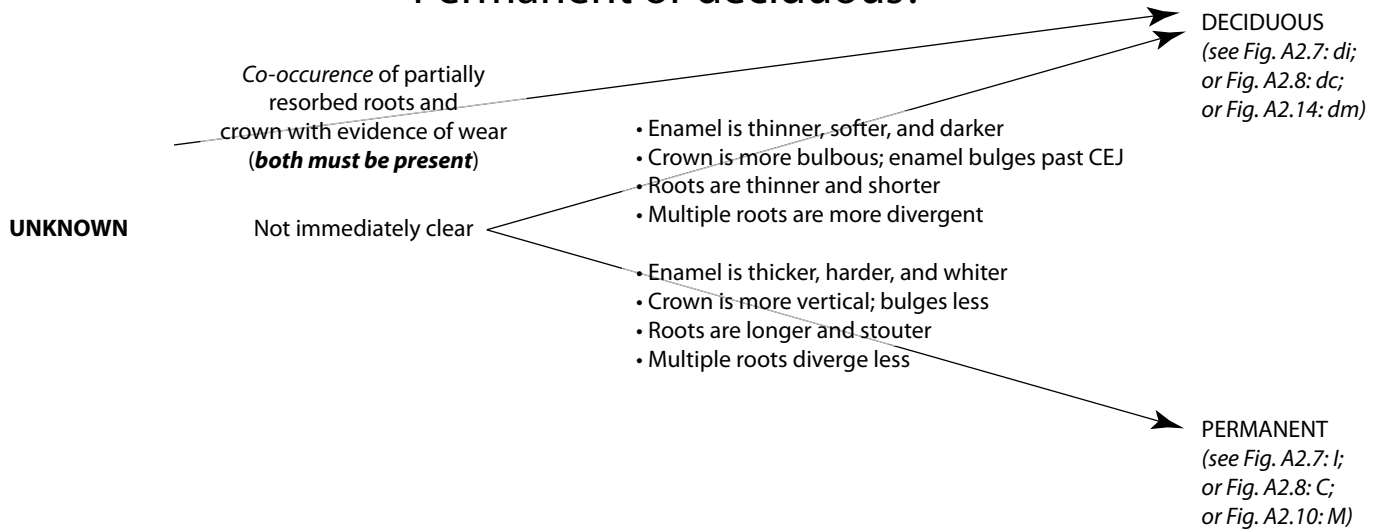


Figure A2.6 Partial decision tree for the determination of the dentition (permanent vs. deciduous) for an unknown tooth.

Upper or lower incisor?

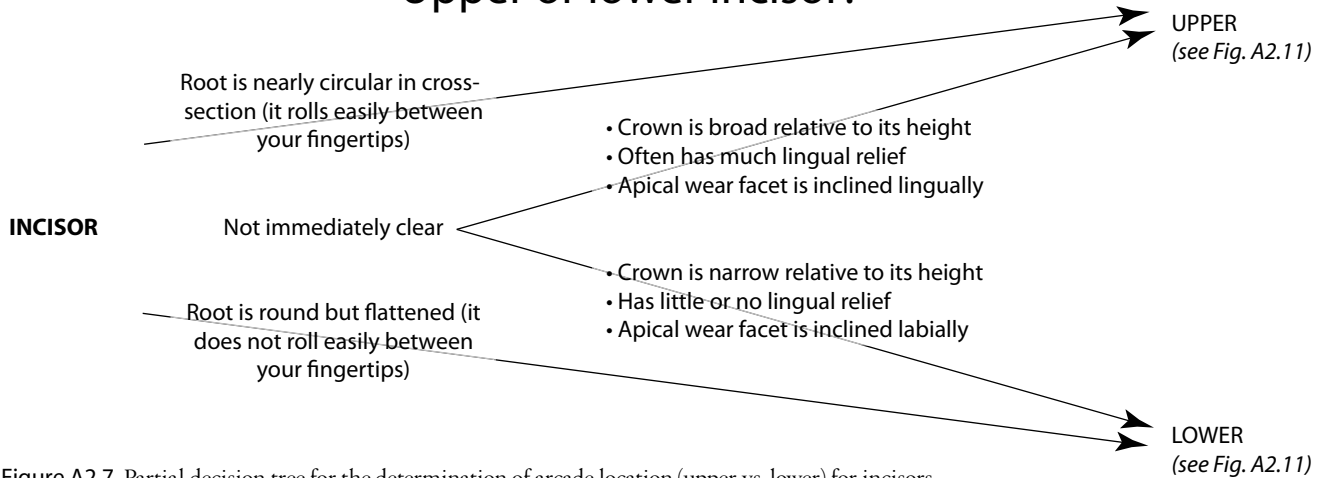


Figure A2.7 Partial decision tree for the determination of arcade location (upper vs. lower) for incisors.

Upper or lower canine?

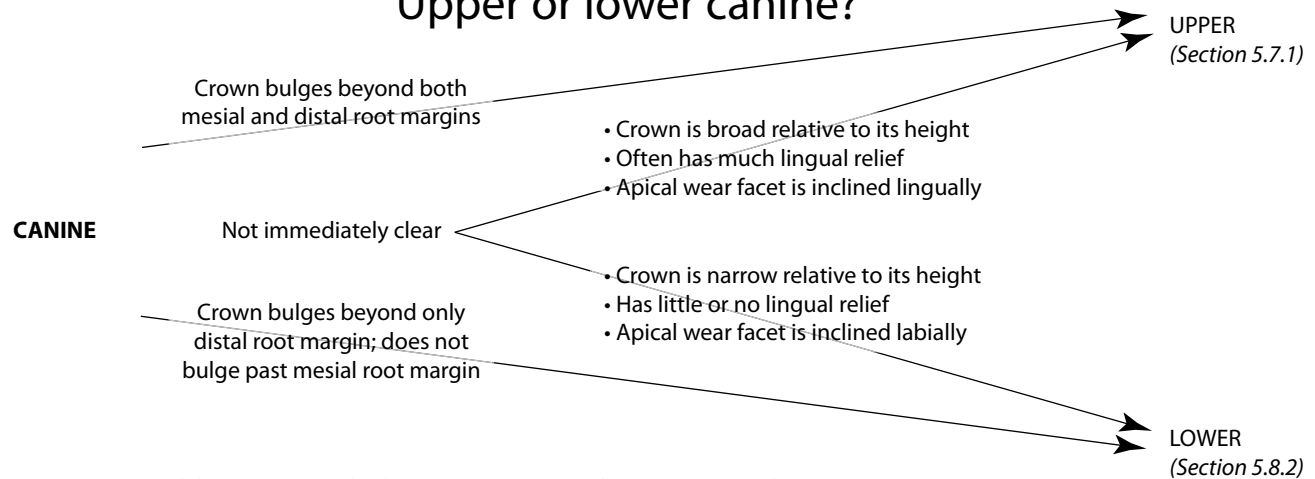


Figure A2.8 Partial decision tree for the determination of arcade location (upper vs. lower) for canines.

Upper or lower premolar?

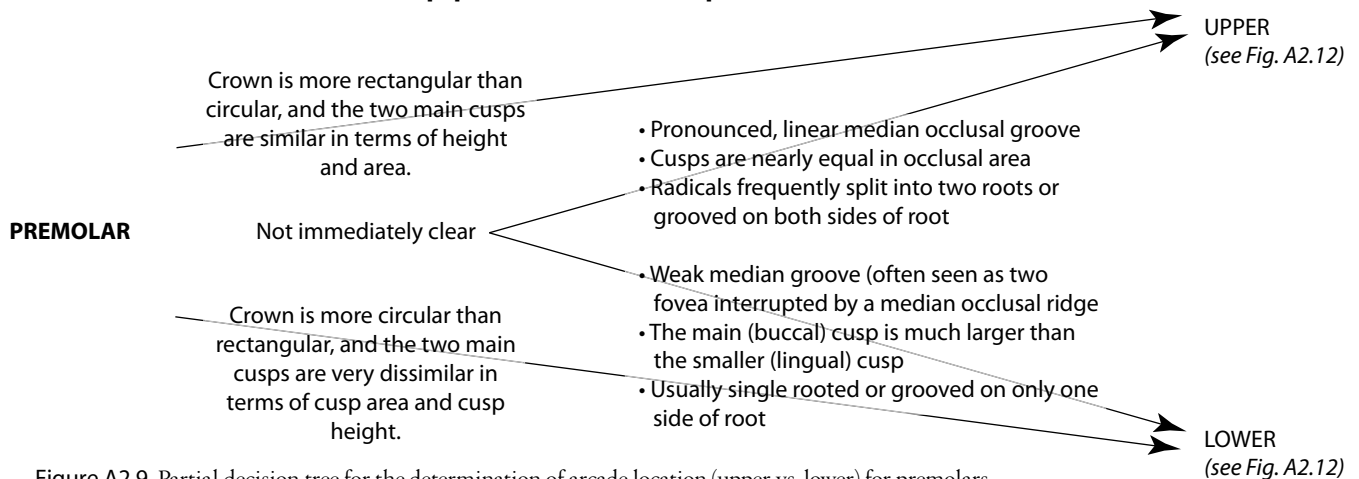


Figure A2.9 Partial decision tree for the determination of arcade location (upper vs. lower) for premolars.

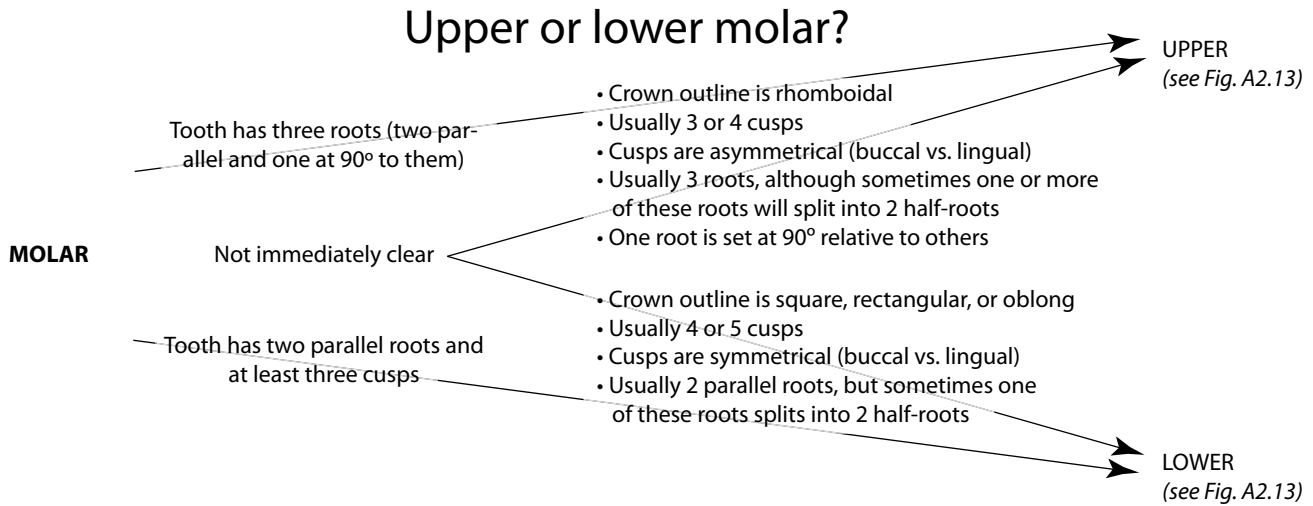


Figure A2.10 Partial decision tree for the determination of arcade location (upper vs. lower) for molars.

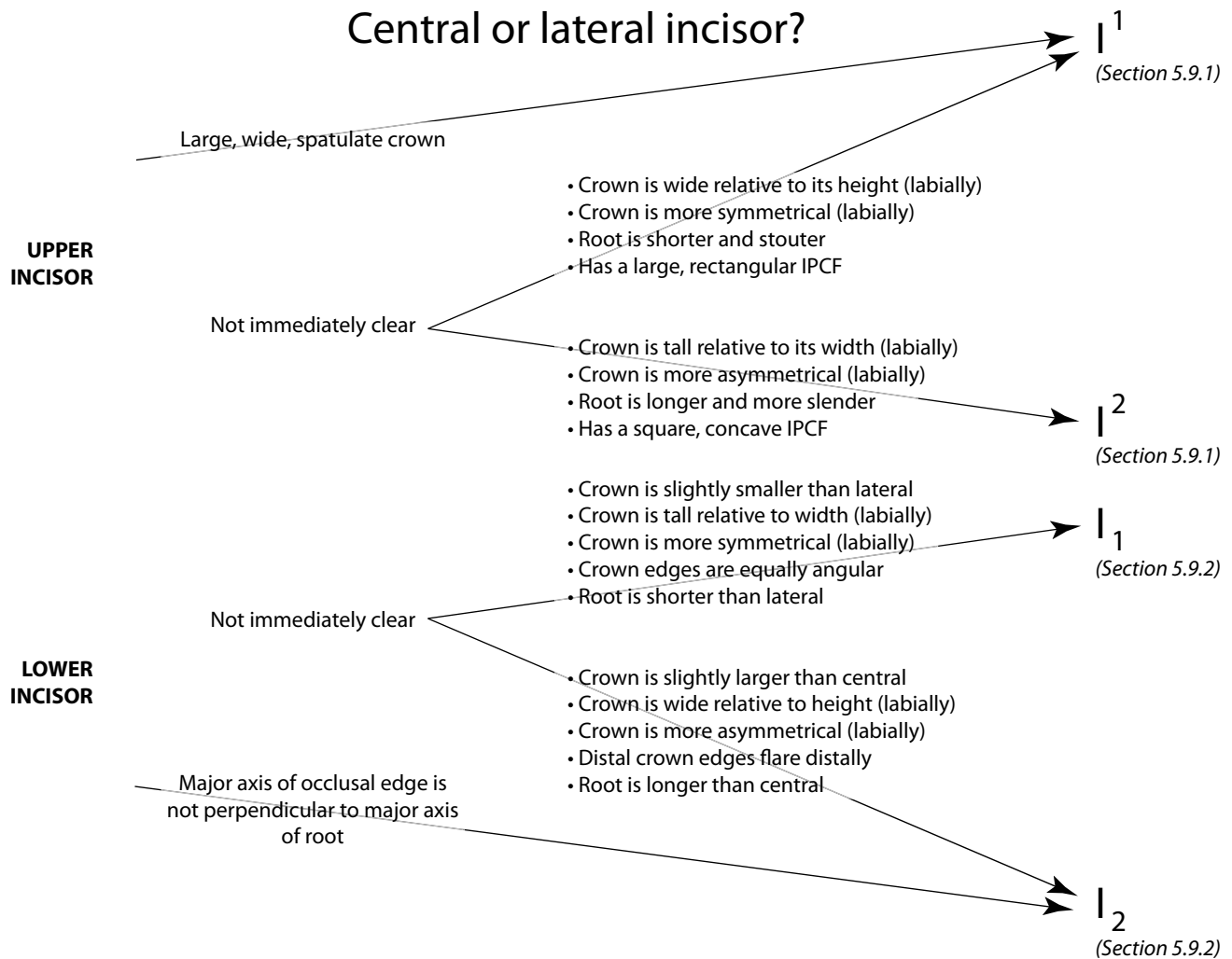


Figure A2.11 *Top:* decision tree for the determination of incisor position in the upper arch (I¹ vs. I²). *Bottom:* decision tree for the determination of incisor position in the lower arch (I₁ vs. I₂).

Third or fourth premolar?

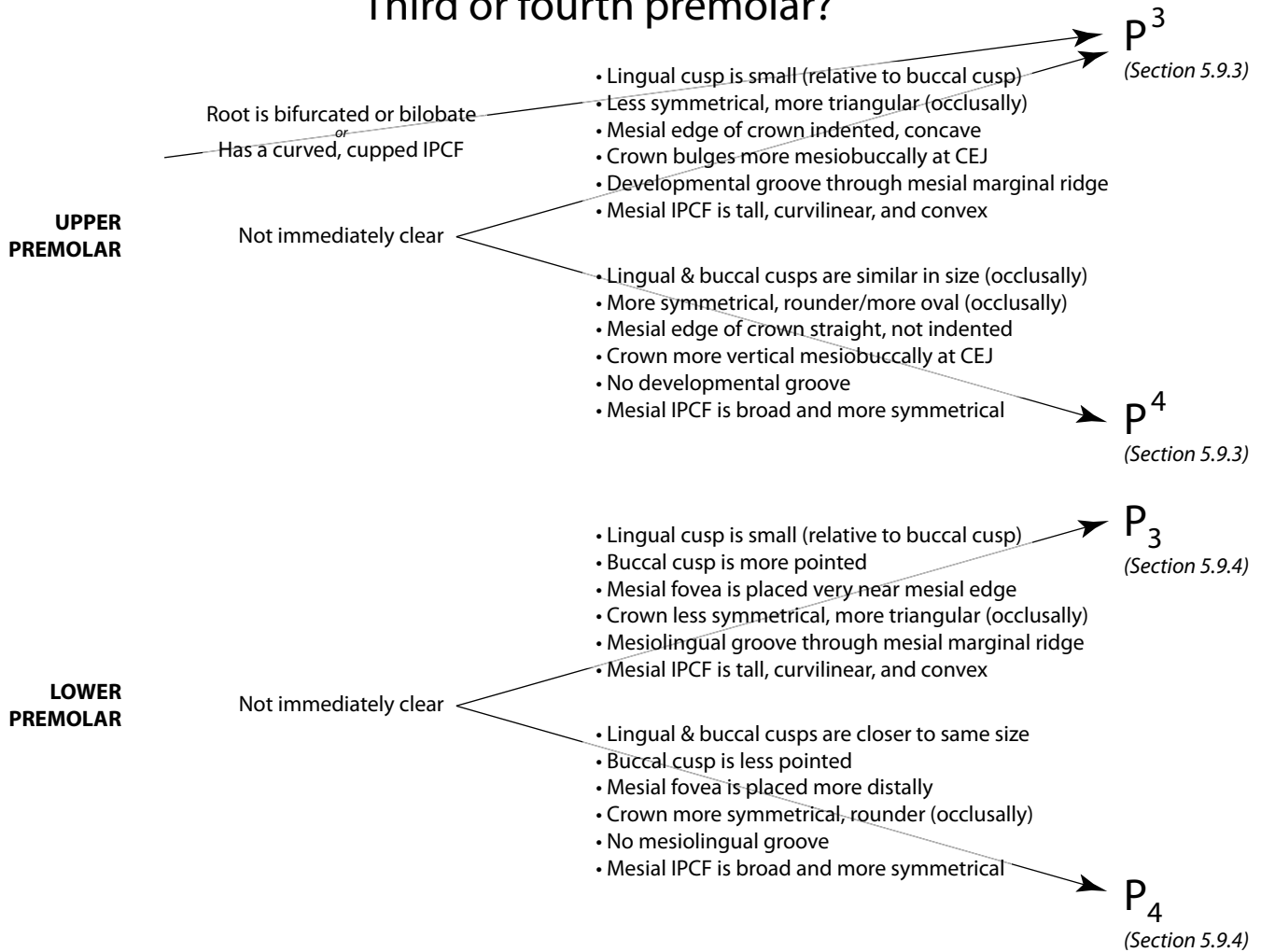


Figure A2.12 *Top*: decision tree for the determination of premolar position in the upper arch (P³ vs. P⁴). *Bottom*: decision tree for the determination of premolar position in the lower arch (P₃ vs. P₄).

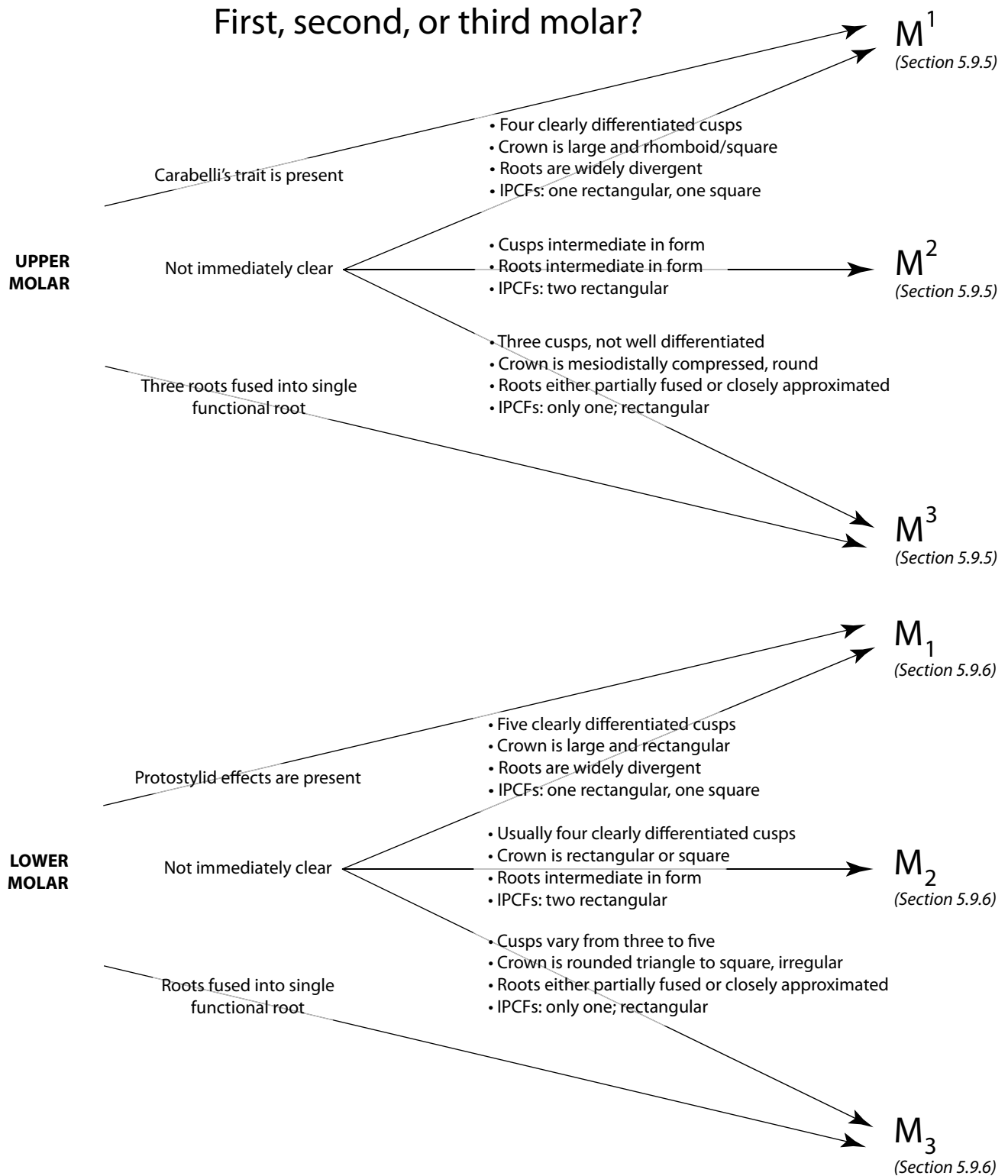


Figure A2.13 *Top*: decision tree for the determination of molar position in the upper arch (M¹ vs. M² vs. M³). *Bottom*: decision tree for the determination of molar position in the lower arch (M₁ vs. M₂ vs. M₃).

First or second deciduous molar?

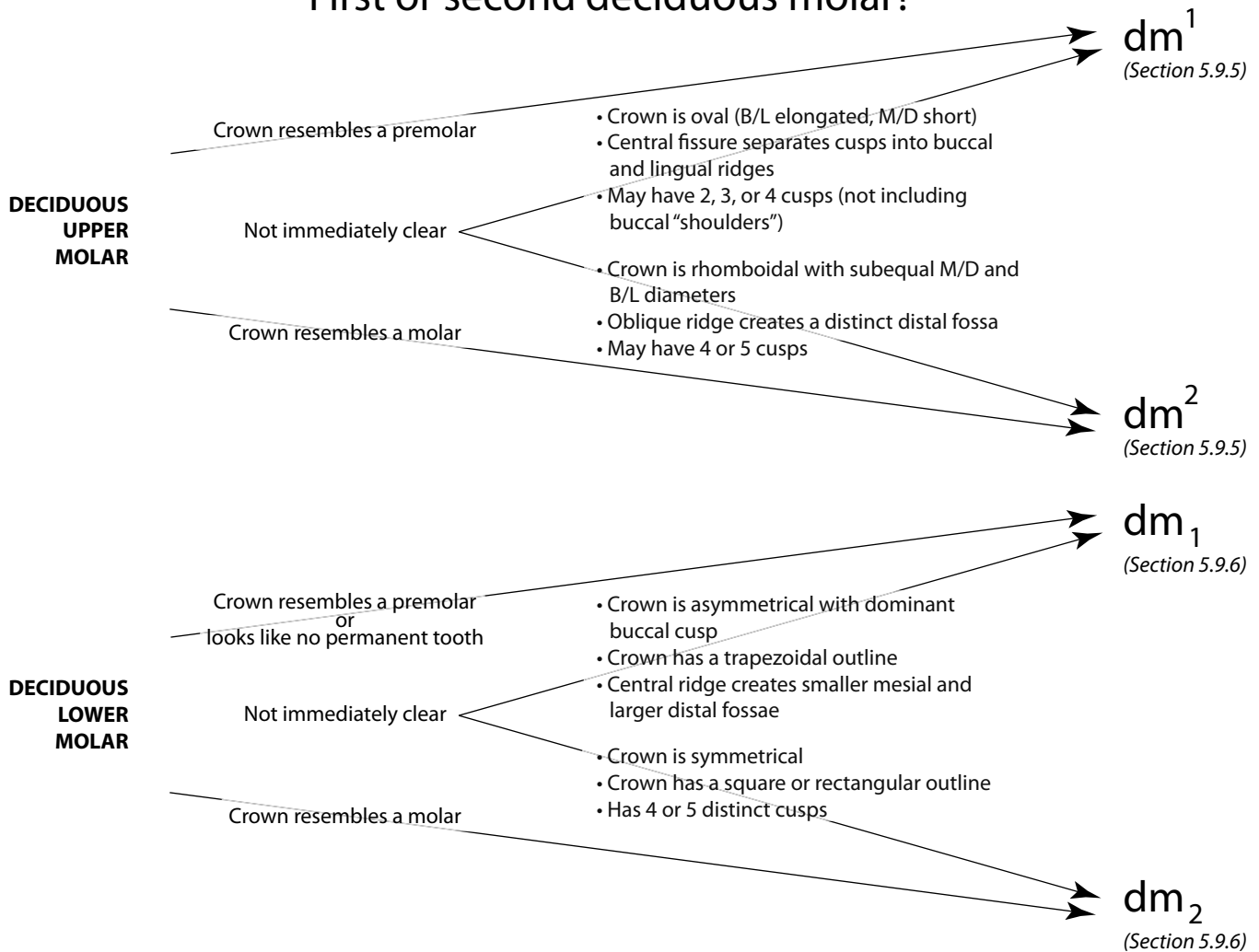


Figure A2.14 *Top*: decision tree for the determination of deciduous molar position in the upper arch (dm¹ vs. dm²). *Bottom*: decision tree for the determination of deciduous molar position in the lower arch (dm₁ vs. dm₂).

Appendix 3

ONLINE RESOURCES FOR HUMAN OSTEOLOGY

USE WORDS AND PHRASES such as *human osteology, forensic archeology, forensic science, human skeleton, paleopathology, skeletal biology, human bone, paleoanthropology, radiology*, etc. in your internet search engine to explore the myriad online resources available to the student and professional.

The following is a set of handy online resources involving human osteology and some of the many disciplines with which it is associated.

A3.1 General

<http://anthropology.tamu.edu/news/>

Keep updated on breaking stories in anthropology

A3.2 Soft Tissue

<http://www.ptcentral.com/article.php?id=2>

Tables of muscular attachments, actions, innervation, and blood supply

http://www.medicallook.com/human_anatomy/

An encyclopedic overview of human anatomy

http://www.nlm.nih.gov/research/visible/visible_human.html

The visible human project

A3.3 Forensics

<http://www.aafs.org/resources>

American Academy of Forensic Sciences resource page

<http://www.all-about-forensic-science.com/forensic-anthropology-schools.html>

A list of schools that offer forensic programs

<http://www.mnsu.edu/emuseum/biology/forensics/osteology.html>

General website about forensic osteology

<http://www.swganth.org/>

Scientific Working Group for Forensic Anthropology

<http://web.utk.edu/~fac/databank.shtml>

Forensic Anthropology Data Bank, with information on FORDISC

<http://www.jpac.pacom.mil/index.php?page=cil&ind=3>

JPAC Central Identification Laboratory

<http://web.anthro.ufl.edu/capoundlab.shtml>

C.A. Pound Human Identification Laboratory

A3.4 Casting and Molding

<http://www.duke.edu/~mtb3/castingmanual/titlepage.html>

Information about casting and molding

A3.5 Digital Photography

http://www.codesta.com/knowledge/technical/digital_photography

Basics of digital photography

<http://www.councilscienceeditors.org/i4a/pages/index.cfm?pageid=3331>

Section 3.4 is titled "Digital Images and Misconduct"

A3.6 Radiology

<http://www.med-ed.virginia.edu/courses/rad/>

Introduction to radiology

<http://www.rad.washington.edu/academics/academic-sections/msk/teaching-materials/teaching-files>

Teaching files for musculoskeletal radiology

<http://www.radiologyinfo.org/en/careers/index.cfm?pg=diagcareer>

A list of radiology professions with links to other information about the discipline

<http://www.learningradiology.com/>

A good practice website that shows one case per day and how it was solved with radiology

<http://www.radiologyeducation.com/>

A teaching website for radiology

<http://plum.museum.upenn.edu/~orsa/welcome.html>

The Open Research Scan Archive (formerly: Penn Cranial CT Database) contains high resolution (sub-millimeter) scans of human and non-human crania from the Penn University Museum and other institutions

A3.7 Paleopathology

<http://www.isds.ch/>

The International Skeletal Dysplasia Society

<http://www.ncbi.nlm.nih.gov/omim>

The Online Mendelian Inheritance in Man database

<http://www.merck.com/mmhe/index.html>

Merck Manual online

<http://www.bonetumor.org>

Comprehensive information on bone tumors

<http://www.frost.org>

A forensic osteology visual metabase with hundreds of illustrated cases from dozens of institutions

<http://www.paleopathology.org/links.html>

A collection of useful links from the Paleopathology Association

[http://www.uic.edu/classes/osci/osci590/6_1Paleopathology Disease in the Past.htm](http://www.uic.edu/classes/osci/osci590/6_1Paleopathology%20Disease%20in%20the%20Past.htm)

Information about common paleopathological diseases

<http://www.rcseng.ac.uk/museums/wellcome>

Wellcome Museum of Anatomy and Pathology

A3.8 Taphonomy

<http://webspaces.webring.com/people/ma/abeisaw/Taphonomy.html>

Annotated bibliographies and useful links for taphonomy and zooarchaeology

<http://carolsmith.us/downloads/674taphonomy.pdf>

Downloadable resource guide for taphonomy

A3.9 Professional Associations

<http://www.physanth.org/>

American Association of Physical Anthropologists

<http://www.aaanet.org/>

American Anthropological Association

<http://www.babao.org.uk/>

British Association for Biological Anthropology and Osteology

<http://anthropology.osu.edu/DAA/index.htm>

Dental Anthropology Association

<http://www.aafs.org/>

American Academy of Forensic Sciences

<http://www.theabfa.org/>

American Board of Forensic Anthropology

<http://www.anatomy.org/>

American Association of Anatomists

<http://www.archaeological.org/webinfo.php?page=10016>

The Archaeological Institute of America (with worldwide database of fieldwork opportunities)

A3.10 NAGPRA (Native American Graves Protection and Repatriation Act)

<http://www.nps.gov/nagpra/>

National Park Service website for national NAGPRA

<http://www.cast.uark.edu/other/nps/nagpra/>

National NAGPRA online database

A3.11 Comparative Anatomy

<http://www.eskeletons.org/>

Comparative skeletal anatomy

A3.12 Skeletal Collections

<http://publicus.culture.hu-berlin.de/collections/list.php?id=i&s=osteology>

Skeletal collections in universities worldwide

<http://skeletal.highfantastical.com/>

A database of human skeletal collections and derivative research

<http://www2.potsdam.edu/usherbm/reference/>

A large list of documented skeletal collections, including links for more information

<http://www.museumoflondon.org.uk/English/Collections/OnlineResources/CHB/Database/>

Database of the skeletal remains curated by the Museum of London

<http://www.cmnh.org/site/ResearchandCollections/PhysicalAnthropology/Collections/Hamann-ToddCollection.aspx>

Information about the Hamann-Todd osteological collection, with downloadable collections data

A3.13 Osteometric Instruments

<http://www.paleo-tech.com>

Instruments for physical anthropologists

GLOSSARY

Abduction The movement of a body part, usually a limb, away from the sagittal plane. When the arm is raised to the side from standard anatomical position, *abduction* of the arm occurs. For the special case of fingers and toes, *abduction* is movement of the digit away from the midline of the hand or foot (spreading the digits).

Ablation The removal of part of the body; usually used when referring to the removal of teeth.

Abscess A localized collection of pus in a cavity formed by tissue disintegration; often found within alveolar bone near the tooth root apices.

Achondroplasia A hereditary form of dwarfism with limb shortening, nearly normal trunk and vault development, and a small face; caused by a congenital disturbance of cartilage formation at the epiphyses.

Acromegaly A condition caused by an overly productive pituitary, but after the epiphyses are fused; the most dramatic osteological manifestation of *acromegaly* is growth at the mandibular condyle and a resulting elongation and distortion of the lower jaw.

Adduction The movement of a body part, usually a limb, toward the sagittal plane. Bringing the arm down to slap the side of the thigh is *adduction*. For the special case of fingers and toes, *adduction* is movement of the digit toward the midline of the hand or foot (closing the digits). The opposite of abduction.

Adolescent An individual between 12 and 20 years old.

Adult Often used for any individual whose long bone epiphyses have all fused. Usually taken to denote an age of greater than 18 years. See also young adult, middle adult, and old adult.

Agensis The lack of tooth formation at a given position.

Ala (plural: *alae*) In the shape of a wing.

Alveolar resorption The atrophy, through remodeling, of alveolar bone.

Alveolus (plural: *alveoli*) A tooth socket. The mandibular canine *alveolus* is deeper than the mandibular incisor *alveolus*.

Ameloblasts Cells that form enamel through a process known as amelogenesis.

Amerindian See Native American.

Ankylosing spondylitis A condition in which the ligaments of the spine ossify, immobilizing the adjacent vertebrae.

Ankylosis An abnormal, complete immobility or fixation of a joint, resulting from pathological changes in the joint.

Anlage (pronounced *Ann-LOG-uh*) The aggregation of cells indicating the first trace of an organ during embryogenesis.

Annulus fibrosus The tough, fibrous ring around the periphery of an intervertebral disk.

Antebrachial Of, belonging to, or related to the forearm.

Antecubital Of, belonging to, or related to the front of the elbow.

Antemortem Related to a period (an unspecified length of time) before the time of death.

Anterior A directional term meaning “towards the front of the body” (in standard anatomical position).

Antimere The opposite side, usually used for bilaterally paired elements.

Apical A directional term for teeth meaning “towards the tip of the tooth root.”

Approximal See interproximal.

Apophysis An outgrowth or small bony projection.

Appendicular skeleton Bones of the limbs, including the shoulder and pelvic girdles (but not the sacrum).

Arcade See dental arcade.

Arthritis Inflammation of a joint.

Arthropathy Any disease affecting the joints.

Articulated 1) Bones positioned in close approximation in order to mimic their relative placements within a living individual; 2) An interment in which the individual decomposed in the same place and position he or she was buried in, as attested to by relative position and orientation of the bones. Contrasts with disarticulated.

Articulation A place where two anatomically adjacent bones contact.

Atrophy Wasting away and reduction in size, particularly after the tissue or organ has matured.

Attrition Wear, usually used in reference to the teeth.

Auditory exostosis A bony growth within the external acoustic meatus.

Avulsion The forcible tearing away of part of a structure.

Axial skeleton Bones of the trunk, including the vertebrae, sacrum, ribs, and sternum.

Axillary Of, belonging to, or related to the armpit.

Ball-and-socket joint A spheroidal joint (such as the hemispherical femoral head fitting into the acetabulum), that allows for movement in many directions.

Basicranium Bones of the cranial base.

Bifid Split into two parts by a cleft or notch. See also bifurcated.

Bifurcated Split into two branches or forks. See also bifid.

Bilobate Composed of two distinct (but connected) lobes or blunt projections.

Boss A smooth, round, broad eminence. Female skulls tend to show more *bossing* of the frontal bone than those of males.

Brachial Of, belonging to, or related to the arm; specifically the upper arm.

Buccal Pertaining to the cheek. As a directional term for teeth, it refers to the side or surface of the tooth facing the cheek. Its use is restricted to premolars and molars. See also labial.

Buccolingual An axis passing from the lingual (tongue) side to the buccal (cheek) side of a molar or premolar; the axis in which the breadth or width of cheek teeth is measured. See also labiolingual and mesiodistal.

Burial Covering by earth (either intentionally in a grave, or accidentally) or placement in a tomb. Intentional burial is synonymous with inhumation and interment.

Calculus Tartar, a deposit of calcified dental plaque on teeth.

Callus Hard tissue formed in the osteogenic layer of the periosteum as a fracture repair tissue; normally replaced.

Calotte A calvaria without the base.

Calvaria The cranium excluding the face.

Canal A tunnel-like passage, usually extending from a foramen. The carotid *canal* is found at the base of the skull.

Canaliculus (plural: *canaliculi*) A very small passage or duct. Within compact bone, cells called osteocytes are locally interconnected via a network of *canaliculi*.

Cancellous bone Spongy, porous lightweight bone found under protuberances where tendons attach, in the vertebral bodies, in the ends of long bones, in short bones, and sandwiched within flat bones; also called trabecular bone.

Carabelli's effects An accessory cusplet or other feature that sometimes develops on the upper first permanent molar or upper second deciduous molar's lingual protocone surface. Also called Carabelli's cusp or Carabelli's trait.

Carcinoma An invasive malignant tumor arising from epithelial tissue. Contrasts with sarcoma.

Caries A disease characterized by the progressive decalcification of enamel or dentine; the hole or cavity left by such decay.

Carpal Of, belonging to, or related to the wrist.

Cartilage A form of connective tissue consisting of cells embedded in a matrix.

Cartilaginous joint A joint, such as that between the first rib and the sternum, in which the articulating bones are united by means of cartilage and very little movement is allowed. Synonymous with synchondrosis.

CAT scan See computed tomography.

Caudal Towards the tail (or coccyx). The lumbar vertebrae are caudal to the thoracic vertebrae.

Cephalic Of, belonging to, or related to the head. Also a directional term meaning "towards the head." See also cranial.

CEJ See cementoenamel line or junction.

Cementum A bone-like tissue that covers the external surface of tooth roots, surrounding the dentin of the root and neck of a tooth.

Cervical, cervix Pertaining to the neck or to a neck-like (*i.e.*, constricted) anatomical feature. As a directional term for teeth meaning "close(r) to the cervicoenamel junction."

Cementoenamel line or junction (CEJ) The line encircling the crown of the tooth, delimiting the most rootward extent of the enamel. Also called cervicoenamel line.

Child An individual between 3 and 12 years old.

Circumduction A movement which is a combination of abduction and adduction, as well as flexion and extension, resulting in an appendage being moved in a cone-shaped path. When the driver of a slow vehicle signals someone behind him to pass, this "waving on" is often done by *circumducting* the arm.

Cnemial Of, belonging to, or related to the shin or tibia.

Collagen A fibrous structural protein constituting about 90% of bone's organic content.

Commingled Bone assemblages containing remains of multiple individuals, often incomplete and fragmentary.

Comminuted fracture A fracture in which the bone splinters.

Compact bone The solid, dense bone that is found in the walls of bone shafts and on external bone surfaces, also called cortical bone.

Complete fracture A fracture in which broken ends of a bone become separated.

Compound fracture A fracture in which the broken bone perforates the skin.

Computerized tomography (CT scanning) A radiological technique that involves the computer processing of a set of images taken at different angular orientations, generating three-dimensional views and cross-sectional slices of an object. Sometimes referred to as CAT scanning, or computerized axial tomography.

Condyle A rounded articular process. The occipital *condyles* lie on the base of the cranium and articulate with the uppermost vertebra, the atlas.

Conoid Having a cone-like shape.

Convex Having a profile or a surface that curves outward.

Coronal plane A plane that divides the body into front and rear portions. Synonymous with frontal plane.

Coronal suture The suture that lies between the frontal and parietal bones.

Cortical bone See compact bone.

Costal Of, belonging to, or related to the ribs.

Coxal Of, belonging to, or related to the pelvis, hip, or hip-joint.

Cranial Refers to bones of the skull, including the mandible. Contrasts with postcranial. As a directional term, it means “towards the head.” When referring to a human in standard anatomical position, the term is synonymous with superior in humans. See also cephalic.

Cranial sutures Fibrous joints of the skull. Articulations of the skull bones along joints with interlocking, sawtooth, or zipper-like articulations.

Craniosynostosis Same as craniostosis; premature fusion of cranial sutures resulting in abnormal skull shape.

Cranium The skeleton of the head; all of the bones of the skull except for the mandible.

Cremation A mortuary practice involving the intentional burning of the body.

Crenulated Having a finely wrinkled, notched, or undulating appearance.

Crest A prominent, usually sharp and thin ridge of bone; often formed between adjacent muscle masses. The sagittal *crest* is a structure that forms as a result of the development of large *temporalis muscles* in the gorilla. Also, an elevated feature connecting cusps on teeth.

Cribra orbitalia Lesions on the roof of the orbit, usually in the form of bilateral pitting of the orbital part of the frontal.

Cross striae Circadian growth increments in the Striae of Retzius.

Cruciate Crossed, or cross-shaped. See also cruciform.

Cruciform In the shape of a cross. See also cruciate.

Crural Of, belonging to, or related to the leg, specifically the lower leg or calf.

Cubital Of, belonging to, or related to the elbow.

Cuneiform In the shape of a wedge.

Cusp An occlusal projection on a the crown of a tooth. See also mamelon.

Cutaneous Of, belonging to, or related to the skin.

CT scan See computerized tomography.

Deciduous teeth The first set of teeth to form, erupt, and function, doing so in the first years of life. Often informally called “baby teeth.”

Dehiscence A developmental abnormality that results in a perforation of the tympanic plate of the temporal bone; sometimes called foramen of Huschke.

Deep A directional term meaning “farther from the surface;” the opposite of superficial. The dentine core of a tooth is deep to the enamel.

DEJ See dentinoenamel junction.

Deltoid In the shape of the Greek letter Δ (*delta*); *i.e.*, having a triangular shape or outline.

Demography The study of population composition and vital statistics.

Dental arcade One of the two arches of teeth: upper (maxillary) or lower (mandibular).

Dental formula A means for specifying how many of each of the four types of teeth is typical for a population or species. A series of eight numbers giving the number of incisors, canines, premolars, and molars for both upper and lower arcades. The human dental formula is $\frac{2:1:2:3}{2:1:2:3}$, whereas that of primitive mammals is $\frac{3:1:4:3}{3:1:4:3}$. If the formula is identical for both upper and lower teeth, the formula may be abbreviated to just that for the upper dentition.

Dental hypoplasia A condition characterized by transverse lines, pits, and grooves on the surface of tooth crowns; such disturbances are defects in dental development.

Dental plaque The matrix and its resident community of bacteria that forms on a tooth.

Dentin A special type of calcified, but slightly resilient, connective tissue; primary dentin develops during growth, whereas secondary dentin forms after root formation is complete.

Dentinoenamel junction (DEJ) The boundary between the enamel cap and the underlying dentin. Sometimes referred to as enameldental junction or EDJ.

Dentition A set of teeth. Humans have two successive dentitions: a deciduous dentition and a permanent dentition.

Deoxyribonucleic acid (DNA) The molecule of heredity that contains the genetic code.

Dermal Of, belonging to, or related to the skin.

Diachronic Changes or events considered through time.

Dermal bone See intramembranous ossification.

Diagenesis Chemical, physical, and biological changes undergone by a bone through time.

Diaphysis The shaft of a long bone.

Diffuse idiopathic skeletal hyperostosis (DISH) A pathological condition characterized by the ossification of spinal ligaments (resulting in a fluid, 'melted candle wax' appearance of the vertebral column in which several successive vertebrae are involved), as well as the ossification of additional idiosyncratic tendinous and ligamentous attachments. Also called Forestier's disease.

Digital In anatomy, of, belonging to, or related to the finger(s) or toe(s).

Diphyodont Having two (sequential) sets of teeth (or dentitions) during a lifetime.

Disarticulated 1) Bones which have been removed from their joints; 2) An interment in which the bones have been purposefully taken from their original, anatomical position after decomposition, and then rearranged. Contrasts with articulated.

Discontinuous morphological traits Also called epigenetic variants, discrete traits, or nonmetric variation; variation observed in bones and teeth, and in the form of differently shaped and sized cusps, roots, tubercles, processes, crests, foramina, articular facets and similar features.

Discrete variables Variables composed of a finite number of values, such as nonmetric traits that are usually scored as present or absent.

DISH See diffuse idiopathic skeletal hyperostosis.

Distal A directional term meaning "farther away." As a directional term for teeth, it refers to the side or surface of the tooth farthest from the midline of the dental arcade. As a directional term for other bones, it refers to the portion of the bone farther from the vertebral column. Thus, the styloid process is on the distal radius, and the distal end of the seventh rib articulates with the sternum via costal cartilage. Distal can also be used as a term of relative position, regardless of the absolute position of the points or features in question; *eg.* the lesser trochanter is distal to the femoral head.

DNA See deoxyribonucleic acid.

Dorsal Of, belonging to, or related to the back. Also a directional term meaning "towards the back." When referring to a human in standard anatomical position, the term is synonymous with posterior.

Dorsiflexion Flexion of the entire foot away from the ground. When a mime walks on her heels, her feet are *dorsiflexed*.

Dysplasia An abnormal development of bone tissue.

EAM See external acoustic meatus.

Eburnation Worn, polished, ivory-like appearance of bone resulting from exposure and wear of adjacent subchondral bone at a joint.

Ectocranial Outer surface of the cranial vault. The temporal line is on the *ectocranial* surface of the parietal.

Edentulous Lacking teeth.

EDJ See dentinoenamel junction.

Eminence A bony projection; usually not as prominent as a process. The articular *eminence* of the temporal bone is the rounded area with which the mandibular condyle articulates during chewing.

Enamel A layer of extremely hard, brittle material that covers the crown of a tooth.

Endochondral ossification One of the two processes by which bone is formed in mammals. In contrast to intramembranous ossification, bone formed endochondrally is first formed in cartilage. These cartilage precursors (called cartilage models) are then gradually replaced by bone tissue.

Endocranial The inner surface of the cranial vault. The brain fills the *endocranial* cavity.

Endosteum An ill-defined and largely cellular membrane that lines the inner surface of bones.

Epicondyle A nonarticular projection adjacent to a condyle. The lateral *epicondyle* of the humerus is located just proximal to the elbow, adjacent to the lateral condylar surface.

Epiphysis The cap at the end of a long bone that develops from a secondary ossification center.

Eversion Turning the sole of the foot outward so that it faces away from the midline of the body. Also known as pronation of the foot.

Evulse To forcibly extract.

Exostosis A bony growth from a bone surface, often involving the ossification of muscular or ligamentous attachments.

Extended 1) The relative positioning of bones around a joint that results from extension; 2) A burial position in which the body is laid out straight, as if standing, often with the arms positioned along the sides of the body. In both cases, the opposite of flexed.

Extension A straightening movement that increases the angle between body parts. The classic karate chop is made by a rigid hand in which the fingers are extended. By convention, *extension* at the shoulder or hip joint is a dorsal (backward) swing of the limb. The opposite of flexion.

External A directional term meaning “outer;” the opposite of internal. The rib cage is *external* to the lungs and heart.

External acoustic meatus (EAM) The outer ear hole.

Extrinsic External to that which it acts upon. *Flexor pollicis longus*, a muscle that flexes the thumb, is considered an *extrinsic* hand muscle because the belly of the muscle is found deep in the forearm, not in the hand itself.

Facet A small articular surface, or a tooth contact. Bodies of the thoracic vertebrae have *facets* for articulation with the heads of ribs. Occlusal *facets* form on the chewing surfaces of the teeth shortly after crown eruption.

Femoral Of, belonging to, or related to the leg, specifically the thigh, or upper leg.

Fetus A not-yet-born, developing human.

Flexed 1) The relative positioning of bones around a joint that results from flexion; 2) A burial position in which the knees and hands are pressed against the chest, and the back and neck are bent forward. In both cases, the opposite of extended.

Flexion A bending movement that decreases the angle between body parts. When a hand is clenched into a fist there is strong *flexion* of the phalanges on the metacarpal heads. By convention, flexion at the shoulder or hip joint refers to a ventral (forward) movement of the limb.

Fontanelles Soft spots of cartilaginous membrane in the skull of a newborn that eventually harden and turn into bone.

Foramen (plural: *foramina*) An opening through a bone, usually a passage for blood vessels and nerves. The mental *foramen* is an opening on the lateral surface of the mandible.

Foramen magnum The large oval hole in the base of the skull through which the spinal cord passes.

Forensic osteology Osteological work aimed at the identification of relatively recently deceased individuals, usually done in a legal context.

Fossa (plural: *fossae*) A depressed area; usually broad and shallow. The olecranon *fossa* is located on the posterior surface of the distal humerus, where it receives the proximal ulna during full extension of the arm.

Fovea (plural: *foveae*) A pit-like, depressed area; usually smaller than a fossa. The anterior *fovea* of an unworn molar is seen in occlusal view.

Frankfurt Horizontal A plane defined by three osteometric points: the right and left porion points and the left orbitale. It is used to systematically orient the skull.

Frontal plane See coronal plane.

Gigantism A condition arising from an excessive production of somatotrophic hormone, causing an overstimulation of growth cartilages and resulting in gigantic proportions of the skeleton.

Glossal Of, belonging to, or related to the tongue.

Gomphosis The joint between the roots of the teeth and the alveolar bone of the jaws.

Greenstick fracture See incomplete fracture.

Groove A long pit or furrow. The intertubercular *groove* passes between the two tubercles on the humerus.

Hallucial Of, belonging to, or related to the big toe.

Hallux The first or big toe.

Hamulus A hook-shaped projection. The *hamulus* of the wrist's hamate bone gives the bone its name.

Harris lines Lines of increased bone density that represent the position of the growth plate at the time of insult to the organism. Formed on long bones due to growth arrest.

Haversian canals Also known as secondary osteons; freely anastomosing canals in compact bone that contain blood and lymph vessels, nerves, and marrow.

Head A large, spherical, usually articular end of a bone. The *head* of the humerus is the superior (proximal) end of the bone.

Helical In the shape of a helix.

Hematopoietic Related to the production and development of red blood cells.

Heterodont Having different, specialized types of teeth (*i.e.*, incisors, canines, premolars, and molars). The opposite of homodont.

Hinge joint A joint, such as the knee or elbow, allowing movement that is largely restricted to a single plane.

Hominid A member of the taxonomic family Hominidae, which includes humans as well as several extinct species that are evolutionarily closer to humans than to any of the other living great apes.

Horizontal plane See transverse plane.

Hyaline cartilage Smooth cartilage that covers the articular surfaces of bones.

Hydroxyapatite A dense, inorganic, mineral matrix; the second component of bone.

Hypercementosis A condition in which an excess of cementum forms on the root of a tooth.

Hyperostosis An abnormal growth of bone tissue.

Hyperplasia An excessive growth of bone or other tissue.

Hypertrophy Increase in the volume of a tissue or organ.

Hypoplasia An insufficient growth of bone or tissue; for teeth, dental enamel hypoplasia is a disturbance of enamel formation that often manifests itself in transverse lines, pits, or other irregularities on the enamel surface.

Idiopathic Describes a condition or disease that can result from different causes in different people. For an example, see diffuse idiopathic skeletal hyperostosis (DISH).

Idiosyncratic Used to describe a feature or trait that is peculiar to, or characteristic of, an individual.

Immature A still-growing individual (has one or more unfused secondary growth centers). Synonymous with juvenile.

Infancy The period between birth and three years after birth.

in situ In the exact place in which an object was placed or deposited.

in utero Still developing in the womb.

Inca bone A specific, named type of extrasutural bone found in some individuals. The triangular *inca bone* is formed when the occipital squama is separated from the rest of the occipital bone by a transverse suture at the level of the superior nuchal line.

Incisal A directional term for anterior teeth meaning “towards the biting surface of the crown.” Generally the opposite of apical. Used only with incisors and canines; occlusal is used for the posterior teeth.

Incomplete fracture A fracture in which breakage and bending of a bone are combined. Also called a greenstick fracture.

Individuation To distinguish from other individuals. The process of parsing the commingled bones of a multiple interment into constituent individuals is an example of *individuation*. Not to be confused with personal identification, in which remains are determined to be those of a specific, named person.

Inferior A directional term meaning “towards the bottom of the body” (in standard anatomical position).

Inhumation See burial.

Insertion The attachment point of a muscle that is on the more freely moving bone of the joint.

Interdigitated Intricately joined together (articulated), as when fingers are woven together.

Interment See burial.

Internal A directional term meaning “inner” the opposite of external. The *internal* surface of the parietal is marked by a set of grooves made by blood vessels that lie external to the brain.

Interobserver error Error stemming from variation in the accuracy of data recorded by different observers analyzing the same things.

Interproximal Between adjacent surfaces, especially of teeth. Synonymous with approximal.

Intramembranous ossification One of the two processes by which bone is formed in mammals. In contrast to endochondral ossification, intramembranous ossification does not involve a cartilaginous precursor of the bone. Instead, bones ossify by apposition on tissue within an embryonic connective tissue membrane. Bone formed intramembranously is sometimes referred to as dermal bone.

Intraobserver error Error related to the precision of data recorded by the same observer analyzing the same things at different times.

Intrasutural bones See Wormian bones, inca bone, and sutural bones.

Intrinsic Internal to that which it acts upon. *Flexor pollicis brevis*, another muscle that flexes the thumb, is considered an *intrinsic* hand muscle because the muscle is located entirely in the hand.

Inversion Turning the sole of the foot inward so that it faces toward the midline of the body. Also known as supination of the foot.

Joint Any connection between different skeletal elements.

Juvenile A still-growing individual (has one or more unfused secondary growth centers). Synonymous with immature.

Kyphosis The collapse of one or several vertebral bodies causing a sharp angle in the spine.

Labial Pertaining to lips. As a directional term for teeth, it refers to the side or surface of the tooth facing the lips. Its use is restricted to incisors and canines. See also buccal.

Labiolingual An axis passing from the labial (lip) side to the lingual (tongue) side of an incisor or canine; the axis in which the breadth or width of anterior teeth is measured. See also buccolingual and mesiodistal.

Lambdoid In the shape of the Greek letter λ (*lambda*), much like an inverted ‘Y’.

Lambdoid suture The suture that passes between the two parietals and the occipital bone.

Lamellar bone Bone whose microscopic structure is characterized by collagen fibers arranged in layers or sheets around Haversian canals.

Laminar Wall-like; usually applied to thin, vertical structures.

Lateral A directional term meaning “towards the side(s).” As a directional term, it refers to the portion of a bone farther from the midline of the body (the sagittal plane). Thus, the radius is lateral to the ulna in standard anatomical position.

Left Refers to the left-hand side of the individual being examined, not to the left-hand side of the observer.

Lentiform In the shape of a lentil; lens-shaped.

Lesion An injury or wound; an area of pathologically altered tissue.

Line A raised linear surface, not as thick as a torus or as sharp as a crest. The inferior temporal *lines* mark the superior extent of the *temporalis muscles*.

Lingual Pertaining to the tongue. As a directional term for teeth, it refers to the side or surface of the tooth facing the tongue.

Lipping Bone projecting beyond the margin of the affected articular surface, usually in osteoarthritis.

Lobate Having a lobe or lobes.

Lumbar Of, belonging to, or related to the loin, or lower back.

Lunate Shaped like a crescent, especially like a crescent moon.

Malleolus (plural: *malleoli*) A rounded protuberance adjacent to the ankle joint. It is easy to palpate (examine by touch) both lateral and medial *malleoli*.

Malocclusion The condition in which upper and lower teeth do not occlude, or meet, properly.

Mamelon Cusplets on the incisal edges of unworn incisors.

Manual Of, belonging to, or related to the hand.

Mastication The action of chewing (masticating).

Matrix 1) The [usually adhering] material (earth/soil/dirt, breccia, sand, etc.) in which remains or artifacts were originally encased; 2) The organic collagen-rich medium in which bones develop during ontogeny; 3) The dental plaque deposits formed by oral bacteria. See also substrate.

Meatus (plural: *meati* or *meatuses*) A short, wide canal. The external acoustic *meatus* is the canal that connects the middle and outer ear.

Medial A directional term meaning “towards the middle.” As a directional term, it refers to the portion of a bone closer to the right-left center of the body (the sagittal plane). Thus, the tibia is *medial* to the fibula. Not to be confused with mesial.

Median plane See sagittal plane.

Medullary cavity The canal inside the shaft of a long bone.

Mental Of, belonging to, or related to the chin.

Mesial A directional term for teeth meaning “towards the midline.” It refers to the side or surface of the tooth closest to the midline of the dental arcade. Not to be confused with medial.

Mesiodistal An axis passing from the mesial (closer to the midline of the arcade) side to the distal (farther from the midline) side of a tooth; the axis in which the length of a tooth is measured. See also buccolingual and labiolingual.

Metaphyses (singular: *metaphysis*) The expanded, flared ends of the shaft of a long bone.

Metopic suture The suture that passes between unfused frontal halves and only rarely persists into adulthood. Sometimes called the frontal suture.

Middle adult An individual between 35 and 50 years old. See also adult.

Midline See sagittal plane.

Midsagittal plane See sagittal plane.

Minimum number of individuals (MNI) The minimum number of individuals required to account for all of the elements in the assemblage.

Mitochondrial DNA (mtDNA) A small, nonnuclear genome that is inherited only maternally, often used in ancient DNA analysis because it is easier to retrieve than nuclear DNA.

MNI See minimum number of individuals.

Morphogen A molecule that influences morphogenesis.

Morphogenesis The development of form during ontogenesis.

Morphology The form and structure of an object.

Multiple interment A burial in which more than one individual is present.

mtDNA See mitochondrial DNA.

NAGPRA The Native American Graves Protection and Repatriation Act. A U.S. Federal law passed in 1990 that mandates the process that museums, Federal agencies, Native American tribes, and Native Hawaiian organizations must follow when negotiating the custody and/or repatriation of human remains, funerary objects, sacred objects, and objects of cultural patrimony.

Nasal Of, belonging to, or related to the nose.

Native American Colloquially, a person who can trace their ancestry to an aboriginal cultural group present in the Americas before the arrival of Columbus in 1492. Under NAGPRA, the term “‘Native American’ means of, or relating to, a tribe, people, or culture that is indigenous to the United States.”

Navicular In the shape of a boat.

Neck A constricted anatomical feature. On long bones, the neck is between the head and the shaft. On teeth, the neck (or *cervix*) is the junction between enamel and cementum. See also nuchal.

Necrosis Physiological death of a cell or a group of cells.

Neonatal Newly born; specifically, from birth to four weeks after birth.

Neural Of, belonging to, or related to the brain or nervous system.

Nonmetric trait Dichotomous, discontinuous, discrete, or epigenetic traits; nonpathological variations of tissues difficult to quantify by measurement.

Nuchal Of, belonging to, or related to the nape, or back of the neck.

Obtured Obstructed; closed or blocked off.

Occlusal A directional term for teeth meaning “towards the chewing surface of the crown.” Generally the opposite of apical. For anterior teeth, incisal is sometimes used instead of *occlusal*.

Odontoblasts Cells that form dentin through a process known as odontogenesis.

Odontogenesis Tooth formation and development.

Odontometric Relating to the measurement of teeth.

Old adult An individual over 50 years old. See also adult.

Ontogeny The development or course of development of an individual; growth.

Opposition Motion in which body parts are brought together. *Opposition* of the thumb and finger tips allows us to grasp small objects.

Orbital Of, belonging to, or related to the eye socket.

Origin The attachment point of a muscle which is on the more fixed bone of the joint.

Orthograde Having a habitually upright torso and, thus, an erect posture. Contrasts with pronograde.

Ossuary A communal grave made up of secondarily interred remains of individuals initially stored somewhere else.

Osteitis A general term used to refer to any inflammation of bone tissue caused by infection or injury.

Osteoarthritis Also called degenerative joint disease; the most common form of arthritis, characterized by a destruction of the articular cartilage in a joint, and accompanied by bony lipping and spur formation adjacent to the joint.

Osteoblasts The bone-forming cells responsible for synthesizing and depositing bone material.

Osteochondroma The most common tumor of bone; benign tumors, usually asymptomatic, that always arise at epiphyseal lines and protrude at right angles to the long axis of a bone.

Osteoclasts Cells responsible for the resorption of bone tissue.

Osteocyte Living bone cell developed from an osteoblast.

Osteogenesis Bone formation and development.

Osteoma (plural: *osteomata* or *osteomas*) Often called “button” *osteomata*; a mound of compact bone, usually on the ectocranial surface.

Osteomalacia A disease that causes a softening of the bones, usually linked to general malnutrition—particularly deficiencies in protein, fat, calcium, and phosphorous.

Osteometric Relating to the measurement of bones.

Osteomyelitis An inflammation of a bone caused by bacteria that usually enter the bone initially via a wound.

Osteon A Haversian system, the structural unit of compact bone composed of a central vascular (Haversian) canal and the concentric lamellae surrounding it; a primary osteon is composed of a vascular canal without a cement line, whereas the cement line and lamellar bone organized around the central canal characterize a secondary osteon.

Osteophyte A small, abnormal bony outgrowth often found at the margins of articular surfaces as a feature of osteoarthritis.

Osteoporosis Increased porosity of bone due to a reduction in bone mineral density.

Osteosarcoma A malignant tumor of the bone cells.

Ovoid In the shape of an oval.

Paleodemography The study of the demography of prehistoric populations.

Paleopathology The study of diseases in ancient populations as revealed by skeletal remains and preserved soft tissues.

Palmar A directional term for the hand meaning “towards the palm” (of the hand). When referring to a human in standard anatomical position, the term is synonymous with anterior in humans.

Parabolic In the shape of a parabola; a symmetrical curving line whose branches get gradually and increasingly close to parallel without ever becoming parallel.

Parasagittal section Any planar slice that parallels the sagittal plane.

Pathological fracture A fracture that occurs as a result of bones already having been weakened by other pathological or metabolic conditions, such as osteoporosis.

Patellar Of, belonging to, or related to the front of the knee.

Pedal Of, belonging to, or related to the foot.

Perikymata Transverse horizontal ridges and grooves on the surface of tooth enamel which represent the intersection of the striae of Retzius and the outer enamel surface.

Perimortem At, around, or just before the time of death.

Perinatal Around the time of birth; specifically, from 28 weeks *in utero* until one week after birth.

Periodontitis The inflammation of tissues around a tooth; can involve both soft tissues and the bone itself.

Periosteum Thin tissue covering the outer surface of bones (except in areas of articulation).

Periostitis A condition of inflammation of the periosteum caused by trauma or infection; can be acute or chronic.

Periostosis Abnormal bone formation on the periosteal surface of a bone.

Personal identification To positively determine that remains are those of a specific, named person. Not to be confused with individuation, in which skeletal individuals are distinguished from other skeletal individuals.

Piriform aperture The opening below and between the orbits; the nose hole. Also called the anterior nasal aperture.

Pisiform In the shape of a pea.

Planar joint A joint that allows two bones to slide across one another.

Plantar A directional term for the foot meaning “towards the sole” (of the foot). When referring to a human in standard anatomical position, the term is synonymous with inferior in humans.

Plantarflexion The flexing of the entire foot inferiorly, toward the ground at the ankle. Action in both dorsiflexion and plantarflexion occurs at the ankle. When a ballerina walks on her toes, her feet are strongly *plantarflexed*. The opposite of dorsiflexion.

Pollex The thumb or first digit of the hand.

Pollical Of, belonging to, or related to the thumb.

Polymerase chain reaction (PCR) A technique that acts as a “molecular photocopy machine” to produce many copies of a section of DNA, beginning with just a few molecules of DNA; this allows DNA to be retrieved from some skeletal remains.

Popliteal Of, belonging to, or related to the back of the knee.

Porosity A condition in which many small openings pass through a surface.

Porotic (or spongy) hyperostosis A condition exhibiting lesions, usually of the cranial vault, representing a thinning and often complete destruction of the outer table of the cranial vault.

Postcranial Refers to all bones in the skeleton except those of the cranium and mandible. Contrasts with cranial.

Posterior A directional term meaning “towards the back of the body” (in standard anatomical position).

Postmortem modifications Alterations to the bone that occur after the death of an individual.

Prenatal Before birth; from conception through the onset of labor.

Primary bony callus Woven bone formed when a callus is subsequently mineralized.

Primary interment A burial in which all the bones are in an anatomically “natural” arrangement; an articulated skeleton buried in the flesh.

Primary ossification center The first site where bone begins to form during growth; usually in the shaft of a long bone, or the body of other bones.

Process A bony prominence. The mastoid *process* forms the prominence behind the ear.

Pronation A rotary motion of the forearm that turns the palm from anteriorly facing (thumb lateral) to posteriorly facing (thumb medial). Typewriters are used with the hand in *pronation*.

Pronograde Having a habitually horizontal torso; also, the posture resulting from this anatomical configuration. Contrasts with orthograde.

Provenience The stratigraphic and spatial position, usually of an object.

Proximal A directional term meaning “closer,” and referring to that portion of a bone closer to the vertebral column. Thus, the tibial tuberosity is on the proximal tibia, and the head of a rib lies at the proximal end of the rib. Proximal can also be used as a term of relative position, regardless of the absolute position of the points or features in question; *eg.*, the popliteal surface is proximal to the femoral condyles.

Pseudarthrosis A new or false joint arising between parts of a fractured bone that do not heal.

Quadrangle Rectilinear; in the general shape of a rectangle or square; *i.e.*, having four sides joining at 90° angles.

Radiograph An image produced on photographic film exposed to X-rays that have passed through an object.

Ramus (plural: *rami*) A branch. The pubic bone splits into two *rami* around the obturator foramen.

Reactive bone Bone in the process of being formed or lost, often in response to a pathological stimulus.

Rectus In a straight line; straight, linear.

Remodeling A cyclical process of bone resorption and deposition at one site.

Resorption The process of bone destruction by osteoclasts.

Rheumatoid arthritis Inflammation and degeneration of the joints, particularly those of the hands and feet; usually chronic and accompanied by deformities.

Rhomboid Shaped like a rhombus (any parallelogram besides a square or rectangle).

Rickets A form of osteomalacia resulting from vitamin D deficiency.

Ridge A linear bony elevation, often roughened. The lateral supracondylar *ridge* of the humerus borders the bone above the lateral epicondyle.

Right Refers to the right-hand side of the individual being examined, not to the right-hand side of the observer.

Rugose Roughened with wrinkles.

Saddle-shaped (or sellar) joint A joint that is saddle-shaped, such as the joint at the base of the thumb.

Sagittal plane A plane that divides the body into symmetrical right and left halves. Synonymous with midsagittal plane, median, and midline.

Sagittal suture The midline suture that passes between the parietal bones.

Sarcoma Originally, a malignant tumor originating in connective tissue. Some tumors known as sarcomas are now known to arise from epithelial tissue. Contrasts with carcinoma.

Scanning electron microscope (SEM) A device that produces an image of the surface of a metal-coated specimen by the reflection of electrons.

Secondary center of ossification Center of bone formation that appears following the formation of the primary center, such as the epiphysis of a long bone.

Secondary interment A burial in which the bones of a skeleton are disarticulated.

Sellar Having a saddle shape.

Serial homology Correspondence of parts in sequential bones, as in the vertebrae.

Sesamoid Shaped like a sesame seed.

Sesamoid bones Small bones that lie within tendons near a joint.

Sigmoid In the shape of the Greek letter 'S' (Σ , *sigma*). Recursively curving, like a snake.

Sexual dimorphism Differences between males and females.

Shaft The long, straight section between the ends of a long bone. The femoral *shaft* is roughly circular in cross section. See also diaphysis.

Shovel-shaped incisors Incisors with strongly developed mesial and distal lingual marginal ridges, imparting a shovel-like appearance to the tooth.

Sinus (plural: *sinuses*) Air sinuses are void chambers in the cranial bones that enlarge with the growth of the face. There are four basic sets of air sinuses: one each in the maxillae, frontal, ethmoid, and sphenoid bones. Venous sinuses are large chambers that are located around the brain and lie within the dura mater. Venous sinuses collect oxygen-depleted blood from the brain and route it to the jugular vein.

Skull The bones of the head, including both cranium and mandible.

Sphenooccipital synchondrosis Actually a synchondrosis; lies between the sphenoid and the occipital. Also called the basilar suture.

Spine Generally a longer, thinner, sharper process than an eminence. Synonymous with *spinous process*. Vertebral *spinous processes* are used in the identification of various vertebrae.

Splanchnocranium The facial skeleton.

Squamous Scale-like; in the form of a reptile's scale.

Squamous suture An unusual, scale-like, beveled suture between the temporal and parietal bones.

Standard anatomical position For humans, defined as standing with feet together and pointing forward, looking forward, and palms facing forward. Positioned thusly, none of the long bones cross each other.

Stenotic Abnormally narrowed or constricted (used for passages and internal spaces).

Striae (singular: *stria*) Also called *striations*. A general term that refers to parallel and/or closely spaced fine, shallow, and/or narrow lines, bands, or grooves. Examples include the *striae* of Retzius (in the enamel of teeth) and parietal *striae* (on the parietal bone above the squamous suture).

Striae of Retzius Growth surfaces of enamel. A three-dimension analog of the growth rings of a tree. See also perikymata and cross striae (circadian growth increments).

Subadult Sometimes used synonymously with immature, but usually used to imply a closer-to-mature individual.

Subchondral bone The compact bone covered by cartilage at the joints.

Subcutaneous Just below the skin. The anteromedial surface of the tibia is *subcutaneous*.

Substrate A general term for a substance or layer that underlies something; the ground is the substrate upon which we walk; or, in the early stages of endochondral ossification, osteoblasts are attached to a cartilaginous substrate. See also matrix.

Sulcus (plural: *sulci*) A long, wide groove. A strong supratatorial *sulcus* is present on African ape crania but is weak or absent on *Australopithecus* crania.

Superficial Closer to the surface. The ribs are *superficial* compared to the heart.

Superior A directional term meaning “towards the top of the body” (in standard anatomical position).

Supernumerary teeth Teeth that exceed the expected number of teeth in any given category.

Supination A rotary motion of the forearm that returns the palm to a position in which the thumb is lateral. When chimpanzees beg for food the hand is often held in *supination*. The opposite of pronation.

Sutural bones Occurring within the cranial sutures; defined by abnormal or additional cranial sutures. Intrasutural bones are also called Wormian bones, intrasutural bones, or extrasutural bones.

Sutures See cranial sutures.

Symphysis A type of semi-rigid joint in which the ends of the bones are covered with a thin layer of hyaline cartilage, but the connection between the cartilage-covered bones is actually made by fibrocartilage.

Synchondrosis A type of semi-rigid joint in which the bones are joined by hyaline cartilage. Examples include epiphyseal plates and the sphenoccipital synchondrosis.

Syndesmosis Tight, inflexible fibrous joint between bones united by bands of dense fibrous tissue in the form of membranes or ligaments.

Synostosis The result when any two bony elements fuse together.

Synovial joints Freely moving joints such as the hip, elbow, knee, and thumb that are coated with a thin layer of hyaline cartilage, and lubricated by synovial fluid within a fibrous joint capsule.

Talon(id) The distal (posterior) portion of a primate molar added to the modified original triangle of cusps; use suffix -id for lower molars.

Taphonomy The study of processes that affect skeletal remains between death and curation.

Tarsal Of, belonging to, or related to the ankle.

Taurodontism The condition in which the pulp chamber is enlarged relative to the normal condition.

Temporal Of, belonging to, or related to the temples.

Thoracic Of, belonging to, or related to the chest.

TMJ Temporomandibular joint; the jaw joint between the mandible and cranium.

Torus (plural: *tori*) A bony thickening. The supraorbital torus on some *Homo erectus* frontal bones is very thick.

Transverse plane Any horizontal plane that divides the body into top and bottom portions. Synonymous with horizontal plane.

Trephination A practice in which an artificial hole is made in the cranial vault of a living person. Also called trepanation.

Trigon (id) The mesial (anterior) portion of a primate molar comprising the modified original triangle of cusps; use suffix -id for lower molars.

Trochanter One of two large, prominent, blunt, rugose processes found only on the femur. The larger of these is called the greater *trochanter*, the smaller is the lesser *trochanter*.

Trochlear Spindle- or spool-shaped. In the shape of a pulley: grooved in the center and raised on the edges.

Tubercle A small, usually rugose eminence; often a site of tendon or ligament attachment. The conoid *tubercle* is found along the inferior edge of the clavicle.

Tuberosity A large, usually rugose (roughened) eminence of variable shape; often a site of tendon or ligament attachment. The deltoid *tuberosity* marks the shaft of the humerus.

Typology The practice of choosing one individual to characterize a group, population, or species.

Vascular Of, belonging to, or related to vessels, specifically blood vessels.

Vault The arched roof of a cavity.

Ventral A directional term meaning “towards the belly.” When referring to a human in standard anatomical position, the term is synonymous with anterior.

Volar A general term, referring to the ‘hollow’ of either the hand or foot: in the hand, *volar* is synonymous with palmar, and in the foot, it is synonymous with plantar.

Volarflexion See plantarflexion.

Wormian bone Any of the small, irregular bones along the cranial sutures; an extrasutural bone.

Young adult An individual between 20 and 35 years old. See also adult.

This page intentionally left blank

BIBLIOGRAPHY

- Abrahams, P. H., Boon, J. M., Spratt, J. D., Hutchings, R. T., and McMinn, R. M. H. (2007) *McMinn's clinical atlas of human anatomy* (6th ed.). St. Louis, MO: Mosby/Elsevier. 386 pp. + DVD.
- Abrahams, P. H., Marks, S. C., and Hutchings, R. T. (2003) *McMinn's color atlas of human anatomy* (5th ed.). Philadelphia, PA: Mosby. 392 pp.
- Acsádi, G. Y., and Nemeskéri, J. (1970) *History of human life span and mortality*. Budapest, Hungary: Akadémiai Kiadó. 346 pp.
- A.D.A.M. (2010) Osteosarcoma (updated 2010 Aug 19; cited 2010 Aug 30). In: *A.D.A.M. Medical Encyclopedia*. Atlanta, GA: A.D.A.M., Inc. Available from: <http://www.nlm.nih.gov/medlineplus/ency/article/001650.htm>.
- Adams, B. J., and Byrd, J. E. (2006) Resolution of small-scale commingling: a case report from the Vietnam War. *Forensic Science International* 156:63–69.
- Adams, B. J., and Byrd, J. E. (Eds.) (2008) *Recovery, analysis, and identification of commingled human remains*. Totowa, NJ: Humana Press. 374 pp.
- Adams, B. J., and Konigsberg, L. W. (2004) Estimation of the most likely number of individuals from commingled human skeletal remains. *American Journal of Physical Anthropology* 125:138–151.
- Adams, B. J., and Konigsberg, L. W. (2004) How many people? Determining the number of individuals represented by commingled human remains. In: B. Adams and J. Byrd (Eds.) *Recovery, analysis, and identification of commingled human remains*. Pp. 241–255. Totowa, NJ: Humana Press.
- Adler, C. J., and Donlon, D. (2010) Sexual dimorphism in deciduous crown traits of a European derived Australian sample. *Forensic Science International* 199:29–37.
- Agarwal, S. C., and Stout, S. D. (2003) *Bone loss and osteoporosis: An anthropological perspective*. New York, NY: Kluwer Academic/ Plenum. 244 pp.
- Agematsu, H., Someda, H., Hashimoto, M., Matsunaga, S., Abe, S., Kim, H. J., Koyama, T., Naito, H., Ishida, R., and Ide, Y. (2010) Three-dimensional observation of decrease in pulp cavity volume using micro-CT: age-related change. *The Bulletin of Tokyo Dental College* 51:1–6.
- Agur, A. M. R., and Dalley, A. F. (2008) *Grant's atlas of anatomy* (12th ed.). Philadelphia, PA: Lippincott Williams & Wilkins. 834 pp.
- Aiello, L. C., and Molleson, T. (1993) Are microscopic ageing techniques more accurate than macroscopic ageing techniques? *Journal of Archaeological Science* 20:689–704.
- Aiello, L., and Dean, C. (1990) *An introduction to human evolutionary anatomy*. San Diego, CA: Elsevier. 608 pp.
- Akkus, O., Polyakova-Akkus, A., Adar, F., and Schaffler, M. B. (2003) Aging of microstructural compartments in human compact bone. *Journal of Bone and Mineral Research* 18:1012–1019.
- Aktas, E. O., Koçak, A., Aktas, S., and Yemisçigil, A. (2004) Intercostal variation for age estimation: Are the standards for the right 4th rib applicable for other ribs? *Collegium Antropologicum* 28 Suppl 2:267–272.
- Alaeddini, R., Walsh, S. J., and Abbas, A. (2010) Forensic implications of genetic analyses from degraded DNA: A review. *Forensic Science International: Genetics* 4:148–157.
- Albert, A. M., and Maples, W. R. (1995) Stages of epiphyseal union for thoracic and lumbar vertebral centra as a method of age determination for teenage and young adult skeletons. *Journal of Forensic Sciences* 40:623–633.
- Alexander, R. M. (2004) *Human bones: A scientific and pictorial investigation*. New York, NY: Pi Press. 208 pp.
- Alfonso, M. P., and Powell, J. (2007) Ethics of flesh and bone, or ethics in the practice of paleopathology, osteology, and bioarchaeology. In: V. N. Cassman, N. Odegaard, and J. Powell (Eds.) *Human remains: Guide for museums and academic institutions*. Pp. 5–19. New York, NY: AltaMira Press.

- Ali, R. S., and MacLaughlin, S. M. (1991) Sex identification from the auricular surface of the adult human ilium. *International Journal of Osteoarchaeology* 1:57–61.
- Alt, K. W., Rösing, F. W., and Teschler-Nicola, M. (Eds.) (2003) *Dental anthropology: Fundamentals, limits and prospects*. New York, NY: Springer. 564 pp.
- Alunni-Perret, V., Muller-Bolla, M., Laugier, J. P., Lupi-Pegurier, L., Bertrand, M. F., Staccini, P., Bolla, M., and Quatrehomme, G. R. (2005) Scanning electron microscopy analysis of experimental bone hacking trauma. *Journal of Forensic Sciences* 50:796–801.
- Alvesalo, L. (1997) Sex chromosomes and human growth: A dental approach. *Human Genetics* 101:1–5.
- Alvesalo, L. (2009) Human sex chromosomes in oral and craniofacial growth. *Archives of Oral Biology* 54 (Suppl. 1):S18–S24.
- Ambrose, S. H. (1993) Isotopic analysis of paleodiets: Methodological and interpretive considerations. In: M. K. Sandford (Ed.) *Investigations of ancient human tissue: Chemical analyses in anthropology*. Pp. 59–130. Langhorne, PA: Gordon and Breach Science Publishers, SA.
- Ambrose, S. H., and Katzenberg, M. A. (Eds.) (2000) *Biogeochemical approaches to paleodietary analysis*. New York, NY: Kluwer Academic/Plenum Publishers. 286 pp.
- American Association of Physical Anthropologists (1996) Statement on biological aspects of race. *American Journal of Physical Anthropology* 101:569–570.
- Amory S., Keyser, C., Crubézy, E., and Ludes, B. (2007) STR typing of ancient DNA extracted from hair shafts of Siberian mummies. *Forensic Science International* 166:218–229.
- Anderson, D. L., Thompson, G. W., and Popovich, F. (1976) Age of attainment of mineralization stages of the permanent dentition. *Journal of Forensic Sciences* 21:191–200.
- Andrushko, V. A., Latham, K. A. S., Grady, D. L., Pastron, A. G., and Walker, P. L. (2005) Bioarchaeological evidence for trophy-taking in prehistoric central California. *American Journal of Physical Anthropology* 127:375–384.
- Andrushko, V. A., Schwitalla, A. W., and Walker, P. L. (2010) Trophy-taking and dismemberment as warfare strategies in prehistoric central California. *American Journal of Physical Anthropology* 141:83–96.
- Andrushko, V. A., and Verano, J. W. (2008) Prehistoric trepanation in the Cuzco region of Peru: A view into an ancient Andean practice. *American Journal of Physical Anthropology* 137:4–13.
- Antón, S. C. (1989) Intentional cranial vault deformation and induced changes of the cranial base and face. *American Journal of Physical Anthropology* 79:253–267.
- Arany, S., and Ohtani, S. (2010) Age estimation by racemization method in teeth: Application of aspartic acid, glutamate, and alanine. *Journal of Forensic Sciences* 55:701–705.
- Arens, W. (1979) *The man-eating myth: Anthropology and anthropophagy*. New York, NY: Oxford University Press. 224 pp.
- Arensburg, B. (1991) The vertebral column, thoracic cage and hyoid bone. In: O. Bar-Yosef and B. Vandermeersch (Eds.) *Le squelette moustérien de Kebara 2*. Pp. 113–147. Paris: Éditions du CNRS.
- Ari, I., and Kafa, I. M. (2009) Bone length estimation and population-specific features of calcaneus and talus bones of the late Byzantine Era. *Collegium Antropologicum* 33:613–618.
- Arismendi, J. L., Baker, L. E., and Matteson, K. J. (2004) Effects of processing techniques on the forensic DNA analysis of human skeletal remains. *Journal of Forensic Sciences* 49:1–5.
- Armstrong, G. J., Carlson, D. S., and Van Gerven, D. P. (1982) The theoretical foundations and development of skeletal biology. In: F. Spencer (Ed.) *A history of American physical anthropology 1930–1980*. Pp. 305–328. New York, NY: Academic Press.
- Armstrong, G. J., and Van Gerven, D. P. (2003) A century of skeletal biology and paleopathology: Contrasts, contradictions, and conflicts. *American Anthropologist* 105:53–64.
- Arnott, R., Finger, S., and Smith, C. U. M., (Eds.) (2003) *Trepanation: History, discovery, theory*. Lisse, Netherlands: Swets and Zeitlinger. 350 pp.
- Arriaza, B., and Pfister, L.-A. (2007) Working with the dead: Health concerns. In: V. Cassman, N. Odegaard, and J. Powell (Eds.) *Human remains: Guide for museums and academic institutions*. Pp. 205–221. Lanham, MD: AltaMira Press.
- Aufderheide, A. C. (2003) *The scientific study of mummies*. New York, NY: Cambridge University Press. 626 pp.
- Aufderheide, A. C., and Rodríguez-Martín, C. (1998) *The Cambridge encyclopedia of human paleopathology*. Cambridge, UK: Cambridge University Press. 496 pp.
- Austin-Smith, D., and Maples, W. R. (1994) The reliability of skull/photograph superimposition in individual identification. *Journal of Forensic Sciences* 39:446–455.
- Avery, J. K. (Ed.) (2001) *Oral development and histology* (3rd ed.). New York, NY: Thieme. 480 pp.
- Baccino E., Ubelaker, D. H., Hayek, L. A. C., and Zerilli, A. (1999) Evaluation of seven methods of estimating age at death from mature human skeletal remains. *Journal of Forensic Sciences* 44:931–936.
- Bahn, P. (2003) *Written in bones: How human remains unlock the secrets of the dead*. Buffalo, NY: Firefly Books. 192 pp.

- Bailey, S. E., and Hublin, J.-J. (Eds.) (2007) *Dental perspectives on human evolution: State-of-the-art research in dental paleoanthropology*. New York, NY: Springer. 409 pp.
- Baker, B. J., and Armelagos, G. J. (1988) The origin and antiquity of syphilis. *Current Anthropology* 29:703–737.
- Baker, B. J., Dupras, T. L., and Tocheri, M. W. (2005) *The osteology of infants and children*. College Station, TX: Texas A&M University Press. 192 pp.
- Baker, S. J., Gill, G. W., and Kieffer, D. A. (1990) Race and sex determination from the intercondylar notch of the distal femur. In: G. W. Gill and S. Rhine (Eds.) *Skeletal attribution of race: Methods for forensic anthropology* (Anthropological Papers Number 4). Pp. 91–95. Albuquerque, NM: Maxwell Museum of Anthropology.
- Balci, Y., Yavuz, M. F., and Çağdır, S. (2005) Predictive accuracy of sexing the mandible by ramus flexure. *Homo* 55:229–237.
- Banning, E. B. (2002) *Archaeological survey*. New York, NY: Kluwer Academic/Plenum. 273 pp.
- Barnes, E. (1994) *Developmental defects of the axial skeleton in paleopathology*. Niwot, CO: University Press of Colorado. 392 pp.
- Bartlett, J. M. S., and Stirling, D. (2003) A short history of the polymerase chain reaction. In: J. M. S. Bartlett and D. Stirling (Eds.) *Methods in molecular biology, vol 226: PCR protocols* (2nd ed.). Pp. 3–6. Totowa, NJ: Human Press, Inc.
- Bass, W. M. (1995) *Human osteology: A laboratory and field manual* (4th ed.). Columbia, MO: Missouri Archaeological Society. 361 pp.
- Bass, W. M. (2005) *Human osteology: A laboratory and field manual* (5th ed.). Columbia, MO: Missouri Archaeological Society. 365 pp.
- Beard, B. L., and Johnson, C. M. (2000) Strontium isotope composition of skeletal material can determine the birth place and geographic mobility of humans and animals. *Journal of Forensic Sciences* 45:1049–1061.
- Behrensmeyer, A. K. (1978) Taphonomic and ecologic information from bone weathering. *Paleobiology* 4:150–162.
- Behrensmeyer, A. K., and Hill, A. P. (1980) *Fossils in the making: Vertebrate taphonomy and paleoecology*. Chicago, IL: University of Chicago Press. 345 pp.
- Belcastro, M. G., Rastelli, E., and Mariotti, V. (2008) Variation of the degree of sacral vertebral body fusion in adulthood in two European modern skeletal collections. *American Journal of Physical Anthropology* 135:149–160.
- Bell, M. A., Futuyma, D. J., Eanes, W. F., and Levinton, J. S. (Eds.) (2010) *Evolution since Darwin: The first 150 years*. Sunderland, MA: Sinauer Associates. 688 pp.
- Bennett, K. A. (1993) *A field identification guide for human skeletal identification* (2nd ed.). Springfield, IL: C. C. Thomas.
- Bentley, R. A. (2006) Strontium isotopes from the Earth to the archaeological skeleton: A review. *Journal of Archaeological Method and Theory* 13:135–187.
- Benzel, E. C., and Stillerman, C. B. (Eds.) (1999) *The thoracic spine*. St. Louis, MO: Quality Medical Publishing. 654 pp.
- Bermúdez de Castro, J. M., Durand, A. I., and Ipiña, S. L. (1993) Sexual dimorphism in the human dental sample from the SH site (Sierra de Atapuerca, Spain): A statistical approach. *Journal of Human Evolution* 24:43–56.
- Berry, A. C. (1975) Factors affecting the incidence of nonmetrical skeletal variants. *Journal of Anatomy* 120:519–535.
- Berryman, H. E., Bass, W. M., Symes, S. A., and Smith, O. C. (1991) Recognition of cemetery remains in the forensic setting. *Journal of Forensic Sciences* 36:230–237.
- Berryman, H. E., and Symes, S. A. (1998) Recognizing gunshot and blunt cranial trauma through fracture interpretation. In: K. J. Reichs (Ed.) *Forensic osteology: Advances in the identification of human remains* (2nd ed.). Pp. 333–352. Springfield, IL: C. C. Thomas.
- Beyer-Olsen, E. M. S., and Alexandersen, V. (1995) Sex assessment of medieval Norwegian skeletons based on permanent tooth crown size. *International Journal of Osteoarchaeology* 5:274–281.
- Bidmos, M. A. (2008) Metatarsals in the estimation of stature in South Africans. *Journal of Forensic and Legal Medicine* 15:505–509.
- Bilezikian, J. P., Raisz, L. G., and Martin, T. J. (2008) *Principles of bone biology* (3rd ed.). San Diego, CA: Elsevier. 1900 pp. in 2 vols.
- Binford, L. R. (1981) *Bones: Ancient men and modern myths*. New York, NY: Academic Press. 320 pp.
- Black, S., and Scheuer, L. (1997) The ontogenetic development of the cervical rib. *International Journal of Osteoarchaeology* 7:2–10.
- Blau, S., and Ubelaker, D. H. (Eds.) (2009) *Handbook of forensic archaeology and anthropology*. Walnut Creek, CA: Left Coast Press. 800 pp.
- Blumenschine, R. J., Marean, C. W., and Capaldo, S. D. (1996) Blind tests of inter-analyst correspondence and accuracy in the identification of cut marks, percussion marks, and carnivore tooth marks on bone

- surfaces. *Journal of Archaeological Science* 23:493–507.
- Boddington, A. (1987) From bones to population: The problem of numbers. In: A. Boddington, A. N. Garland, and R. C. Janaway (Eds.) *Death, decay and reconstruction*. Pp. 180–197. Manchester: Manchester University Press.
- Bocaage, E., Humphrey, L. T., and Hillson, S. (2010) Technical note: A new three-dimensional technique for high resolution quantitative recording of perikymata. *American Journal of Physical Anthropology* 141:498–503.
- Bocquet-Appel, J.-P. (Ed.) (2008) *Recent advances in palaeodemography: Data, techniques, patterns*. Dordrecht, Netherlands: Springer. 294 pp.
- Bocquet-Appel, J.-P., and Masset, C. (1982) Farewell to paleodemography. *Journal of Human Evolution* 11:321–333.
- Boles, T. C., Snow, C. C., and Stover, E. (1995) Forensic DNA testing on skeletal remains from mass graves: A pilot project in Guatemala. *Journal of Forensic Sciences* 40:349–355.
- Bonnichsen, R., and Sorg, M. H. (Eds.) (1989) *Bone modification*. Orono, ME: Center for the Study of the First Americans. 534 pp.
- Bonnichsen, R., and Sorg, M. H. (Eds.) (2004) *Bone modification* (2nd ed.). Orono, ME: Center for the Study of the First Americans. 532 pp.
- Bookstein, F. L. (1991) *Morphometric tools for landmark data: Geometry and biology*. Cambridge, UK: Cambridge University Press. 456 pp.
- Bouwman, A. S., and Brown, T. (2005) The limits of biomolecular palaeopathology: Ancient DNA cannot be used to study venereal syphilis. *Journal of Archaeological Science* 32:703–713.
- Boyadjian, C. H. C., Eggers, S., and Reinhard, K. (2007) Dental wash: A problematic method for extracting microfossils from teeth. *Journal of Archaeological Science* 34:1622–1628.
- Brace, C. L. (1995) Region does not mean “race:” Reality versus convention in forensic anthropology. *Journal of Forensic Sciences* 40:171–175.
- Brain, C. K. (1981) *The hunters or the hunted? An introduction to African cave taphonomy*. Chicago, IL: University of Chicago Press. 365 pp.
- Brandt, E., Wiechmann, I., and Grupe, G. (2002) How reliable are immunological tools for the detection of ancient proteins in fossil bones? *International Journal of Osteoarchaeology* 12:307–316.
- Bräuer, G. (1988) Osteometrie. In: R. Knußmann, R. (Ed.) *Anthropologie: Handbuch der vergleichenden Biologie des Menschen, begründet von Rudolf Martin*. Pp. 160–232. Stuttgart: Gustav Fischer.
- Braun, B., Cook, D. C., and Pfeiffer, S. (1998) DNA from *Mycobacterium tuberculosis* complex identified in North American pre-Columbian human skeletal remains. *Journal of Archaeological Science* 25:271–277.
- Bray, T. (1995) Repatriation: A clash of world views. *AnthroNotes: National Museum of Natural History Bulletin for Teachers* 17.
- Brickley, M., and Ferllini, R. (Eds.) (2007) *Forensic anthropology: Case studies from Europe*. Springfield, IL: C. C. Thomas. 268 pp.
- Brickley, M., and Ives, R. (2008) *The bioarchaeology of metabolic bone disease*. Boston, MA: Elsevier/Academic Press. 333 pp.
- Brickley, M. B., and McKiney, J. I. (Eds.) (2004) *Guidelines to the Standards for Recording Human Remains*. Reading, UK: British Association for Biological Anthropology and Osteology, University of Southampton, and the Institute of Field Archaeologists (IFA Paper No. 7). 62 pp.
- Bridges, P. S. (1992) Prehistoric arthritis in the Americas. *Annual Review of Anthropology* 21:67–91.
- Bridges, P. S. (1993) The effect of variation in methodology on the outcome of osteoarthritic studies. *International Journal of Osteoarchaeology* 3:289–295.
- Britz, H. M., Thomas, C. D., Clement, J. G., and Cooper, D. M. (2009) The relation of femoral osteon geometry to age, sex, height and weight. *Bone* 45:77–83.
- Bronner, F., and Farach-Carson, M. C. (2004) *Bone formation*. London, UK: Springer-Verlag. 160 pp.
- Brooks, S., and Suchey, J. M. (1990) Skeletal age determination based on the os pubis: A comparison of the Acsádi-Nemeskéri and Suchey-Brooks methods. *Human Evolution* 5:227–238.
- Brooks, S. T. (1955) Skeletal age at death: Reliability of cranial and pubic age indicators. *American Journal of Physical Anthropology* 13:567–597.
- Brothwell, D. R. (1981) *Digging up bones* (3rd ed.). Ithaca, NY: Cornell University Press. 208 pp.
- Brothwell, D. R. (1989) The relationship of tooth wear to aging. In: M. Y. İşcan, (Ed.) *Age markers in the human skeleton*. Pp. 303–316. Springfield, IL: C. C. Thomas.
- Brothwell, D. R., and Pollard, A. M. (Eds.) (2001) *Handbook of archaeological sciences*. Hoboken, NJ: John Wiley and Sons. 782 pp.
- Brown, K. (2000) Ancient DNA applications in human osteoarchaeology: Achievements, problems and potential. In: M. Cox and S. Mays (Eds.) *Human osteology in archaeology and forensic science*. Pp. 455–473. London, UK: Greenwich Medical Media, Ltd.

- Brown, P. (1981) Artificial cranial deformation: A component of the variation in Pleistocene Australian aboriginal crania. *Archaeology in Oceania* 16:156–167.
- Brown, T. A., and Brown, K. A. (1992) Ancient DNA and the archaeologist. *Antiquity* 66:10–23.
- Bruwelheide, K. S., Beck, J., and Pelot, S. (2001) Standardized protocol for radiographic and photographic documentation of human skeletons. In: E. Williams (Ed.) *Human remains: Conservation, retrieval and analysis*. (B.A.R. International Series 934). Pp. 153–165. Oxford, UK: British Archaeological Reports.
- Brůžek, J. (2002) A method for visual determination of sex, using the human hip bone. *American Journal of Physical Anthropology* 117:157–168.
- Buck, S. (2003) Searching for graves using geophysical technology: Field tests with ground penetrating radar, magnetometry, and electrical resistivity. *Journal of Forensic Sciences* 48:1–7.
- Buckberry, J. L., and Chamberlain, A. T. (2002) Age estimation from the auricular surface of the ilium: A revised method. *American Journal of Physical Anthropology* 119:231–239.
- Buckley, H. R., and Dias, G. J. (2002) The distribution of skeletal lesions in treponemal disease: Is the lymphatic system responsible? *International Journal of Osteoarchaeology* 12:178–188.
- Buikstra, J. E. (1981a) A specialist in ancient cemetery studies looks at the reburial issue. *Early Man* 3:26–27.
- Buikstra, J. E. (Ed.) (1981b) *Prehistoric tuberculosis in the Americas*. Evanston, IL: Northwestern University Archaeological Program. 182 pp.
- Buikstra, J. E. (1983) Reburial: How we all lose. *Society for California Archaeology Newsletter* 17:1.
- Buikstra, J. E. (2006) Repatriation and bioarchaeology: Challenges and opportunities. In: J. E. Buikstra and L. A. Beck (Eds.) *Bioarchaeology: The contextual analysis of human remains*. Pp. 389–415. New York, NY: Academic Press.
- Buikstra, J. E., and Cook, D. C. (1980) Paleopathology: An American account. *Annual Review of Anthropology* 9:433–470.
- Buikstra, J. E., and Ubelaker, D. H. (1994) *Standards for data collection from human skeletal remains*. (Report Number 44). Fayetteville, AR: Arkansas Archaeological Survey. 218 pp.
- Buikstra, J. E., and Mielke, J. H. (1985) Demography, diet and health. In: R. I. Gilbert and J. H. Mielke (Eds.) *The analysis of prehistoric diets*. Pp. 359–422. Orlando, FL: Academic Press.
- Burbano, H. A., Hodges, E., Green, R. E., Briggs, A. W., Krause, J., Meyer, M., Good, J. M., Maricic, T., Johnson, P. L. F., Xuan, Z., Rooks, M., Bhattacharjee, A., Brizuela, L., Albert, F. W., de la Rasilla, M., Forste, J., Rosas, A., Lachmann, M., Hannon, G. J., and Pääbo, S. (2010) Targeted investigation of the Neandertal genome by array-based sequence capture. *Science* 328:723–725.
- Burge, R., Dawson-Hughes, B., Solomon, D. H., Wong, J. B., King, A., and Tosteson, A. (2007) Incidence and economic burden of osteoporosis-related fractures in the United States, 2005–2025. *Journal of Bone and Mineral Research* 22:465–475.
- Burke, H., Smith, C., Lippert, D., Watkins, J., and Zimmerman, L. (Eds.) (2008) *Kennewick Man: Perspectives on the Ancient One*. Walnut Creek, CA: Left Coast Press. 300 pp.
- Burns, K. R. (1998) Forensic anthropology and human rights issues. In: K. J. Reichs (Ed.) *Forensic osteology: Advances in the identification of human remains* (2nd ed.). Pp. 63–85. Springfield, IL: C. C. Thomas.
- Burns, K. R. (2006) *Forensic anthropology training manual* (2nd ed.). Upper Saddle River, NJ: Prentice Hall. 384 pp.
- Burr, D. B. (1980) The relationships among physical, geometrical and mechanical properties of bone, with a note on the properties of nonhuman primate bone. *Yearbook of Physical Anthropology* 23:109–146.
- Burrows, A. M., Zanella, V. P., and Brown, T. M. (2003) Testing the validity of metacarpal use in sex assessment of human skeletal remains. *Journal of Forensic Sciences* 48:1–4.
- Burton, J. (2008) Bone chemistry and trace element analysis. In: M. A. Katzenberg and S. R. Saunders (Eds.) *Biological anthropology of the human skeleton* (2nd ed.). Pp. 443–460. New York, NY: Wiley-Liss.
- Bush, M. E., Lovejoy, C. O., Johanson, D. C., and Coppens, Y. (1982) Hominid carpal, metacarpal, and phalangeal bones recovered from the Hadar Formation: 1974–1977 collections. *American Journal of Physical Anthropology* 57:651–677.
- Byers, Steven N. (2008) *Introduction to forensic anthropology* (3rd ed.). Boston, MA: Pearson/Allyn and Bacon.
- Caffell, A. C., Roberts, C. A., Janaway, R. C., and Wilson, A. S. (2001) Pressures on osteological collections: The importance of damage limitation. In: E. Williams (Ed.) *Human remains: Conservation, retrieval and analysis*. Pp. 187–197. Oxford, UK: Archaeopress.
- Caldwell, P. C. (1986) New questions (and some answers) on the facial reproduction techniques. In: K. J. Reichs (Ed.) *Forensic osteology: Advances in the identification of human remains* (1st ed.). Pp. 229–255. Springfield, IL: C. C. Thomas.
- Capasso, L., Kennedy, K. A. R., and Wilczak, C. A. (1998) *Atlas of occupational markers on human remains*. (Journal of Paleopathology, Monographic Publication 3). Teramo, Italy: Edigrafital S.p.A. 184 pp.

- Cardoso, H. F. V. (2005) *Patterns of growth and development of the human skeleton and dentition in relation to environmental quality: A biocultural analysis of a 20th century sample of Portuguese subadult documented skeletons*. Ph.D. thesis. Hamilton, Ontario: McMaster University. 347 pp.
- Cardoso, H. F. V. (2006) Brief communication: The collection of identified human skeletons housed at the Bocage Museum (National Museum of Natural History), Lisbon, Portugal. *American Journal of Physical Anthropology* 129:173–176.
- Cardy, A. (1997) The environmental material: The human bones. In: P. Hill (Ed.) *Whithorn and St. Ninian: the excavation of a monastic town, 1984–91*. Pp. 519–562. Stroud, UK: Sutton Publishing.
- Carolan, V. A., Gardner, M. L. G., Lucy, D., and Pollard, A. M. (1997) Some considerations regarding the use of amino acid racemization in human dentine as an indicator of age at death. *Journal of Forensic Sciences* 42:10–16.
- Carpenter, J. P., Sanchez, G., and Villalpando, M. E. (2002) Of maize and migration: Mode and tempo in the diffusion of *Zea mays* in northwest Mexico and the American southwest. In: S. H. Schlanger (Ed.) *Traditions, transitions, and technologies: Themes in southwestern archaeology*. Pp. 245–258. Boulder, CO: University Press of Colorado.
- Carson, E. A. (2006a) Maximum likelihood estimation of human craniometric heritabilities. *American Journal of Physical Anthropology* 131:169–180.
- Carson, E. A. (2006b) Maximum-likelihood variance components analysis of heritabilities of cranial non-metric traits. *Human Biology* 78:383–402.
- Carter, D. R. (1980) SI: The international system of units. In: V. H. Frankel and M. Nordin (Eds.) *Basic biomechanics of the skeletal system*. Pp. 1–11. Philadelphia, PA: Lea and Febiger.
- Carter, D. R., and Beaupré, G. S. (2001) *Skeletal function and form: Mechanobiology of skeletal development, aging, and regeneration*. New York, NY: Cambridge University Press. 332 pp.
- Cartmill, M., Hylander, W. L., and Shafland, J. (1987) *Human structure*. Cambridge, MA: Harvard University Press. 448 pp.
- Carver, M. (2009) *Archaeological investigation*. New York, NY: Routledge. 480 pp.
- Cassman, V., Odegard, N., and Powell, J. (Eds.) (2007) *Human remains: Guide for museums and academic institutions*. Lanham, MD: AltaMira Press. 308 pp.
- Catón, J., and Tucker, A. S. (2009) Current knowledge of tooth development: Patterning and mineralization of the murine dentition. *Journal of Anatomy* 214:502–515.
- Chamberlain, A. T. (2000) Problems and prospects in palaeodemography. In: M. Cox and S. Mays (Eds.) *Human osteology in archaeology and forensic science*. Pp. 101–115. London, UK: Greenwich Medical Media, Ltd.
- Chamberlain, A. T. (2006) *Demography in archaeology*. Cambridge, UK: Cambridge University Press. 256 pp.
- Chegini-Farahani, S., Fuss, J., and Townsend, G. (2000) Intra- and inter-population variability in mamelon expression on incisor teeth. *Dental Anthropology* 14:1–6.
- Chhem, R. K., and Brothwell, D. R. (2008) *Paleoradiology: Imaging mummies and fossils*. New York, NY: Springer. 163 pp.
- Christensen, A. M. (2004) The impact of Daubert: Implications for testimony and research in forensic anthropology (and the use of frontal sinuses in personal identification). *Journal of Forensic Sciences* 49:1–4.
- Clarke, N. G., and Hirsch, R. S. (1991) Physiological, pulpal, and periodontal factors influencing alveolar bone. In: M. A. Kelley and C. S. Larsen (Eds.) *Advances in dental anthropology*. Pp. 241–266. New York, NY: Wiley-Liss.
- Clarke, R. J., and Howell, F. C. (1972) Affinities of the Swartkrans 847 hominid cranium. *American Journal of Physical Anthropology* 37:319–335.
- Clement, J. G., and Ranson, D. L. (Eds.) (1998) *Craniofacial identification in forensic medicine*. London, UK: Arnold. 306 pp.
- Clement, J. G., and Marks, M. K. (Eds.) (2005) *Computer-graphic facial reconstruction*. Burlington, MA: Elsevier Academic Press. 390 pp.
- Clemente, C. D. (2010) *Anatomy: A regional atlas of the human body* (6th ed.). Baltimore, MD: Lippincott Williams & Williams. 752 pp.
- CMNH (n.d.) Hamann-Todd Human Osteological Collection. *Cleveland Museum of Natural History website*. Accessed 2010 Oct 2. Available from: <http://www.cmnh.org/site/ResearchandCollections/PhysicalAnthropology/Collections/Hamann-ToddCollection.aspx>.
- Cobourne, M. T., and Mitsiadis, T. (2006) Neural crest cells and patterning of the mammalian dentition. *Journal of Experimental Zoology* 306B:251–260.
- Cobourne, M. T., and Sharpe, P. T. (2003) Tooth and jaw: Molecular mechanisms of patterning in the first branchial arch. *Archives of Oral Biology* 48:1–14.
- Cobourne, M. T., and Sharpe, P. T. (2010) Making up the numbers: The molecular control of mammalian dental formula. *Seminars in Cell & Developmental Biology* 21:314–324.
- Cohen, M. N. (1994) The osteological paradox reconsidered. *Current Anthropology* 35:629–637.

- Cohen, M. N., and Armelagos, G. J. (Eds.) (1985) *Paleopathology at the origins of agriculture*. Orlando, FL: Academic Press. 615 pp.
- Cohen, M. N., and Crane-Kramer, G. M. M. (2007) *Ancient health: skeletal indicators of agricultural and economic intensification*. Gainesville, FL: University Press of Florida. 432 pp.
- Coleman, B. L. (2008) Recovering the Korean War dead, 1950–1958: Graves registration, forensic anthropology, and wartime memorialization. *The Journal of Military History* 72:179–222.
- Collins, M. J., Nielsen-Marsh, C. M., Hiller, J., Smith, C. I., Roberts, J. P., Prigodich, R. V., Wess, T. J., Csapò, J., Millard, A. R., and Turner-Walker, G. (2002) The survival of organic material in bone: A review. *Archaeometry* 44:383–394.
- Coltrain, J. B., Janetski, J. C., and Carlyle, S. W. (2007) The stable- and radio-isotope chemistry of western basketmaker burials: Implications for early Puebloan diets and origins. *American Antiquity* 72:301–321.
- Committee on Science, Engineering, and Public Policy (U.S.), National Academy of Sciences (U.S.), National Academy of Engineering, and Institute of Medicine (U.S.). (2009) *On being a scientist: A guide to responsible conduct in research* (3rd ed.). Washington, DC: National Academy Press. 82 pp.
- Connor, A., and Stoneking, M. (1994) Assessing ethnicity from human mitochondrial DNA types determined by hybridization with sequence-specific oligonucleotides. *Journal of Forensic Sciences* 39:1360–1371.
- Connor, M. A., and Scott, D. A. (Eds.) (2001a) Archaeologists as forensic investigators: Defining the role. *Historical Archaeology* 35:1–104.
- Connor, M. A., and Scott, D. A. (2001b) Paradigms and perpetrators. *Historical Archaeology* 35:1–6.
- Connor, M. A. (2007) *Forensic methods: Excavation for the archaeologist and investigator*. Lanham, MD: AltaMira Press. 272 pp.
- Cool, S. M., Hendrikz, J. K., and Wood, W. B. (1995) Microscopic age changes in the human occipital bone. *Journal of Forensic Sciences* 40:789–796.
- Cooper, P. D., Stewart, J. H., and McCormick, W. F. (1988) Development and morphology of the sternal foramen. *American Journal of Forensic Medicine and Pathology* 9:342–347.
- Cordeiro, C., Muñoz-Barús, J. I., Wasterlain, S., Cunha, E., and Vieira, D. N. (2009) Predicting adult stature from metatarsal length in a Portuguese population. *Forensic Science International* 193:131.e1–131.e4.
- Corr, L. T., Sealy, J. C., Horton, M. C., and Evershed, R. P. (2005) A novel marine dietary indicator utilising compound-specific bone collagen amino acid $\delta^{13}\text{C}$ values of ancient humans. *Journal of Archaeological Science* 32:321–330.
- Corruccini, R. S. (1978) Morphometric analysis: Uses and abuses. *Yearbook of Physical Anthropology* 21:134–150.
- Corruccini, R. S. (1987) Shape in morphometrics: Comparative analyses. *American Journal of Physical Anthropology* 73:289–303.
- Cox, M. (1996) *Life and death in Spitalfields, 1700–1850*. York, UK: Council for British Archeology. 142 pp.
- Cox, M. (Ed.) (1998) *Grave concerns: Death and burial in England, 1700 to 1850*. York, UK: Council for British Archaeology (Report no. 113). 275 pp.
- Cox, M. (2000a) Ageing adults from the skeleton. In: M. Cox and S. Mays (Eds.) *Human osteology in archaeology and forensic science*. Pp. 61–81. London, UK: Greenwich Medical Media, Ltd.
- Cox, M. (2000b) Assessment of parturition. In: M. Cox and S. Mays (Eds.) *Human osteology in archaeology and forensic science*. Pp. 131–142. London, UK: Greenwich Medical Media, Ltd.
- Cox, M., and Mays, S. (2000) *Human osteology in archaeology and forensic science*. London, UK: Greenwich Medical Media, Ltd. 548 pp.
- Cox, M., and Scott, A. (1992) Evaluation of the obstetric significance of some pelvic characters in an 18th century British sample of known parity. *American Journal of Physical Anthropology* 89:43–440.
- Crist, T. A. J. (2001) Bad to the bone? Historical archaeologists in the practice of forensic science. *Historical Archaeology* 35:39–56.
- Currey, J. (1984) *The mechanical adaptations of bones*. Princeton, NJ: Princeton University Press. 304 pp.
- Currey, J. (2002) *Bones: Structure and mechanics*. Princeton, NJ: Princeton University Press. 456 pp.
- Danforth, M. E., Herndon, K. S., and Propst, K. B. (1993) A preliminary study of patterns of replication in scoring linear enamel hypoplasias. *International Journal of Osteoarchaeology* 3:297–302.
- Dauber, W., and Feneis, H. (2007) *Pocket atlas of human anatomy, founded by Heinz Feneis* (5th ed.). New York, NY: Thieme. 545 pp.
- Davenport, G. C. (2001) Remote sensing applications in forensic investigations. *Historical Archaeology* 35:87–100.
- Dawson, T. E., and Siegwolf, R. T. W. (Eds.) (2007) *Stable isotopes as indicators of ecological change, vol. 1 (Terrestrial ecology)*. San Diego, CA: Academic Press. 436 pp.
- Dayal, M. R., Kegley, A. D., Strkalj, G., Bidmos, M. A., and Kuykendall, K. L. (2009) The history and composition of the Raymond A. Dart Collection of Human Skeletons at the University of the Witwatersrand, Johannesburg, South Africa. *American Journal of Physical Anthropology* 140:324–335.

- De Biase, P., and Capanna, R. (2007) Bone morphogenetic proteins and growth factors: Emerging role in regenerative orthopaedic surgery. *Journal of Orthopaedics and Traumatology* 8:43–48.
- De Greef, S., and Willems, G. (2005) Three-dimensional cranio-facial reconstruction in forensic identification: Latest progress and new tendencies in the 21st century. *Journal of Forensic Sciences* 50:1–6.
- DeGusta, D., and White, T. D. (1996) On the use of skeletal collections for DNA analysis. *Ancient Biomolecules* 1:89–92.
- D'Elia, M., Gianfrate, G., Quarta, G., Giotta, L., Giancane, G., and Calcagnile, L. (2007) Evaluation of possible contamination sources in the C-14 analysis of bone samples by FTIR spectroscopy. *Radiocarbon* 49:201–210.
- Del Papa, M. C., and Perez, S. I. (2007) The influence of artificial cranial vault deformation on the expression of cranial nonmetric traits: Its importance in the study of evolutionary relationships. *American Journal of Physical Anthropology* 134:251–262.
- Denys, C. (2002) Taphonomy and experimentation. *Archaeometry* 44:469–484.
- Deter, C. A. (2009) Gradients of occlusal wear in hunter-gatherers and agriculturalists. *American Journal of Physical Anthropology* 138:247–254.
- De Vito, C., and Saunders, S. R. (1990) A discriminant function analysis of deciduous teeth to determine sex. *Journal of Forensic Sciences* 35:845–858.
- Devlin, B., Risch, N., and Roeder, K. (1994) Comments on the statistical aspects of the NRC's report on DNA typing. *Journal of Forensic Sciences* 39:28–40.
- DiGangi, E. A., Bethard, J. D., Kimmerle, E. H., and Konigsberg, L. W. (2009) A new method for estimating age-at-death from the first rib. *American Journal of Physical Anthropology* 138:164–176.
- DiMaio, D., and DiMaio, J. M. (2001) *Forensic pathology* (2nd ed.). Boca Raton, FL: CRC Press. 592 pp.
- Dirkmaat, D. C., and Adovasio, J. M. (1997) The role of archaeology in the recovery and interpretation of human remains from an outdoor forensic setting. In: W. D. Haglund and M. H. Sorg (Eds.) *Forensic taphonomy: The postmortem fate of human remains*. Pp. 39–64. Boca Raton, FL: CRC Press.
- Dobberstein, R. C., Huppertz, J., von Wurmb-Schwark, N., and Ritz-Timme, S. (2008) Degradation of biomolecules in artificially and naturally aged teeth: implications for age estimation based on aspartic acid racemization and DNA analysis. *Forensic Science International* 179:181–191.
- Dobney, K., and Brothwell, D. (1986) Dental calculus: Its relevance to ancient diet and oral ecology. In E. Cuwys and R. A. Foley (Eds.) *Teeth and Anthropology*. (B.A.R. International Series 291). Pp. 55–81. Oxford, UK: British Archaeological Reports.
- Donlon, D. A. (2000) The value of infracranial nonmetric variation in studies of modern *Homo sapiens*: An Australian focus. *American Journal of Physical Anthropology* 113:349–368.
- Donnelly, S. M., Hens, S. M., Rogers, N. L., and Schneider, K. L. (1998) Technical note: A blind test of mandibular ramus flexure as a morphologic indicator of sexual dimorphism in the human skeleton. *American Journal of Physical Anthropology* 107:363–366.
- Donoghue, H. D., Spigelman, M., Zias, J., Gernaey-Child, A. M., and Minnikin, D. E. (1998) *Mycobacterium tuberculosis* complex DNA in calcified pleura from remains 1400 years old. *Letters in Applied Microbiology* 27:265–269.
- Dorfman, H. D., and Czerniak, B. (1998) *Bone Tumors*. London, UK: Mosby. 1261 pp.
- Drancourt, M., Aboudharam, G., Signoli, M., Dutour, O., and Raoult, D. E. (1998) Detection of a 400-year old *Yersinia pestis* DNA in human dental pulp: An approach to the diagnosis of ancient septicemia. *Proceedings of the National Academy of Sciences, USA* 95:12637–12640.
- Dreier, F. G. (1994) Age at death estimates for the protohistoric Arikara using molar attrition rates: A new quantification method. *International Journal of Osteoarchaeology* 4:13–147.
- Drusini, A. G., Toso, O., and Ranzato, C. (1997) The coronal pulp cavity index: A biomarker for age determination in human adults. *American Journal of Physical Anthropology* 103:353–363.
- Dryden, I. L., and Mardia, K. V. (1998) *Statistical shape analysis*. Chichester, UK: John Wiley and Sons. 376 pp.
- Dudar, J. C. (1993) Identification of rib number and assessment of intercostal variation at the sternal end. *Journal of Forensic Sciences* 38:788–797.
- Dudar, J. C., Pfeiffer, S., and Saunders, S. R. (1993) Evaluation of morphological and histological adult skeletal age-at-death estimation using ribs. *Journal of Forensic Sciences* 38:677–685.
- Duday, H. (1978) Archéologie funéraire et anthropologie: Application des relevés et de l'étude ostéologique à quelques sépultures pré- et protohistorique du midi de la France. *Cahiers d'Anthropologie* 1:55–101.
- Duday, H., and Masset, C. (Eds.) (1987) *Anthropologie Physique et Archéologie*. Paris: C.N.R.S.
- Dupras, T. L., Schultz J. J., Wheeler, S. M., and Williams, L. J. (2005) *Forensic recovery of human remains: Archaeological approaches*. Boca Raton, FL: CRC Press. 232 pp.
- Eklund, J. A., and Thomas, M. G. (2010) Assessing the effects of conservation treatments on short sequences of DNA *in vitro*. *Journal of Archaeological Science* 37:2831–2841.

- Edgar, H. J. H. (2005) Prediction of race using characteristics of dental morphology. *Journal of Forensic Sciences* 50:1–5.
- Efremov, I. A. (1940) Taphonomy: A new branch of paleontology. *Pan-American Geologist* 74:81–93.
- Elcock, C., Smith, R. N., Simpson, J., Abdellatif, A., Bäckman, B., and Brook, A. H. (2006) Comparison of methods for measurement of hypoplastic lesions. *European Journal of Oral Science* 114 (Suppl. 1):365–369.
- Elerick, D. V., and Tyson, R. A. (Eds.) (1997) *Human paleopathology and related subjects: An international bibliography*. San Diego, CA: San Diego Museum of Man. 716 pp.
- Eliášová, I., Mazura, I., and Smejtek, L. (2010) DNA analysis of ancient skeletal remains. *Folia Biologica (Prague)* 56:47–50.
- El-Najjar, M. Y., and McWilliams, K. R. (1978) *Forensic anthropology: The structure, morphology, and variation of human bone*. Springfield, IL: C. C. Thomas. 190 pp.
- El-Zaatari, S. (2010) Occlusal microwear texture analysis and the diets of historical/prehistoric hunter-gatherers. *International Journal of Osteoarchaeology* 20:67–87.
- Epstein, F. H. (1989) The biology of osteoarthritis. *New England Journal of Medicine* 320:1322–1330.
- Erdal, Y. S. (2008) Occlusal grooves in anterior dentition among Kovuklukaya inhabitants (Sinop, northern Anatolia, 10th century AD). *International Journal of Osteoarchaeology* 18:152–166.
- Erickson, G. M., Catanese, J., and Keaveny, T. M. (2002) Evolution of the biomechanical properties of the femur. *The Anatomical Record* 268:115–124.
- Ericksen, M. F. (1991) Histologic estimation of age at death using the anterior cortex of the femur. *American Journal of Physical Anthropology* 84:171–179.
- Eshed, V., Gopher, A., and Hershkovitz, I. (2006) Tooth wear and dental pathology at the advent of agriculture: New evidence from the Levant. *American Journal of Physical Anthropology* 130:145–159.
- Eshed, V., Latimer, B., Greenwald, C. M., Jellema, L. M., Rothschild, B. M., Wish-Baratz, S., and Hershkovitz, I. (2002) Button osteoma: Its etiology and pathophysiology. *American Journal of Physical Anthropology* 118:217–230.
- Estalrich, A., Rosas, A., García-Vargas, S., García-Taberner, A., Santamaría, D., and de la Rasilla, M. (in press) Brief communication: Subvertical grooves on interproximal wear facets from the El Sidrón (Asturias, Spain) Neandertal dental sample. *American Journal of Physical Anthropology* Early view: www.interscience.wiley.com, DOI: 10.1002/ajpa.21359.
- Fairgrieve, S. I., and Oost, T. S. (2001) *Human skeletal anatomy: Laboratory manual and workbook*. Springfield, IL: C. C. Thomas. 188 pp.
- Fairgrieve, S. I. (2008) *Forensic cremation: Recovery and analysis*. Boca Raton, FL: CRC Press. 224 pp.
- Faith, J. T., Marean, C. W., and Behrensmeier, A. K. (2007) Carnivore competition, bone destruction, and bone density. *Journal of Archaeological Science* 34:2025–2034.
- Falsetti, A. B. (1995) Sex assessment from metacarpals of the human hand. *Journal of Forensic Sciences* 40:774–776.
- Falys, C. G., and Lewis, M. E. (in press) Proposing a way forward: A review of standardisation in the use of age categories and ageing techniques in osteological analysis (2004–2009). *International Journal of Osteoarchaeology* Early view: www.interscience.wiley.com, DOI: 10.1002/oa.1179.
- Falys, C. G., Schutkowski, H., and Weston, D. A. (2006) Auricular surface aging: Worse than expected? A test of the revised method on a documented historic skeletal assemblage. *American Journal of Physical Anthropology* 130:508–513.
- Fanton, L., Gustin, M.-P., Paultre, U., Schrag, B., and Malicier, D. (2010) Critical study of observation of the sternal end of the right 4th rib. *Journal of Forensic Sciences* 55:467–472.
- Fawcett, D. W., and Jensch, R. P. (2002) *Bloom & Fawcett: Concise histology* (2nd ed.). New York, NY: Arnold. 352 pp.
- Fazekas, G., and Kósa, F. (1978) *Forensic fetal osteology*. Budapest, Hungary: Akadémiai Kiadó. 413 pp.
- Feder, H. A., and Houck, M. M. (2008) *Feder's succeeding as an expert witness* (4th ed.). Boca Raton, FL: CDC Press. 216 pp.
- Federative Committee on Anatomical Terminology. (1998) *Terminologia Anatomica: International anatomical terminology*. New York, NY: Thieme. 292 pp. + CD-ROM.
- Feldesman, M. R., and Fountain, R. L. (1996) "Race" specificity and the femur/stature ratio. *American Journal of Physical Anthropology* 100:207–224.
- Feldtkeller, E., Khan, M. A., van der Heijde, D., van der Linden, S., and Braun, J. (2003) Age at disease onset and diagnosis delay in HLA-B27 negative vs. positive patients with ankylosing spondylitis. *Rheumatology International* 23:61–66.
- Feldmann, R. M., Chapman, R. E., and Hannibal, J. T. (Eds.) (1989) *Paleotechniques*. Knoxville, Tennessee: Paleontological Society Special Publication Number 4. 358 pp.
- Fenton, T. W., Birkby, W. H., and Cornelison, J. (2003) A fast and safe nonbleaching method for forensic skeletal preparation. *Journal of Forensic Sciences* 48:1–3.

- Fenton, T. W., Heard, A. N., and Sauer, N. J. (2008) Skull-photo superimposition and border deaths: Identification through exclusion and the failure to exclude. *Journal of Forensic Sciences* 53:34–40.
- Finnegan, M. (1974). Discrete non-metric variation of the post-cranial skeleton in man (abstract). *American Journal of Physical Anthropology* 40:135–136.
- Finnegan, M. (1978) Non-metric variation of the infracranial skeleton. *Journal of Anatomy* 125:23–37.
- Finnegan, M., and Kysar, D. A. (1998) The third exhumation of Jesse Woodson James: Implications for the analysis of historic figures. In: K. J. Reichs (Ed.) *Forensic osteology: Advances in the identification of human remains* (2nd ed.). Pp. 533–556. Springfield, IL: C. C. Thomas.
- Finucane, B. C. (2008) Trophy heads from Nawinpuquio, Perú: Physical and chemical analysis of Huarpa-era modified human remains. *American Journal of Physical Anthropology* 135:75–84.
- Fitzgerald, C. M., and Rose, J. C. (2000) Reading between the lines: Dental development and subadult age assessment using the microstructural growth markers of teeth. In: M. A. Katzenberg and S. R. Saunders (Eds.) *Biological anthropology of the human skeleton* (1st ed.). Pp. 163–186. New York, NY: Wiley-Liss.
- Flander, L. B. (1978) Univariate and multivariate methods for sexing the sacrum. *American Journal of Physical Anthropology* 49:103–110.
- Fletcher, H. A., Donoghue, H. D., Holton, J., Pap, I., and Spigelman, M. (2003) Widespread occurrence of *Mycobacterium tuberculosis* DNA from 18th–19th century Hungarians. *American Journal of Physical Anthropology* 120:144–152.
- Forbes, S. L. (2008) Decomposition chemistry in a burial environment. In: M. Tibbet and D. O. Carter (Eds.) *Soil analysis in forensic taphonomy: Chemical and biological effects of buried human remains*. Pp. 203–223. Boca Raton, FL: CRC Press.
- Formicola, V. (1993) Stature reconstruction from long bones in ancient population samples: An approach to the problem of its reliability. *American Journal of Physical Anthropology* 90:351–358.
- Fox, C. L. (1992) Information obtained from the microscopic examination of cultural striations in human dentition. *International Journal of Osteoarchaeology* 2:155–169.
- France, D. L. (1998) Observational and metric analysis of sex in the skeleton. In: K. J. Reichs (Ed.) *Forensic osteology: Advances in the identification of human remains* (2nd ed.). Pp. 163–186. Springfield, IL: C. C. Thomas.
- France, D. L. (2009) *Human and nonhuman bone identification: A color atlas*. Boca Raton, FL: CRC Press. 584 pp.
- France, D. L., Griffin, T. J., Swanburg, J. G., Lindemann, J. W., Davenport, G. C., Tramell, V., Armbrust, C. T., Kondratieff, B., Nelson, A., Castellano, K., and Hopkins, D. (1992) A multidisciplinary approach to the detection of clandestine graves. *Journal of Forensic Sciences* 37:1445–1458.
- Franciscus, R. G., and Churchill, S. E. (2002) The costal skeleton of Shanidar 3 and a reappraisal of Neanderthal thoracic morphology. *Journal of Human Evolution* 42:303–356.
- Franklin, D., O'Higgins, P., Oxnard, C. E., and Dadour, I. (2007) Sexual dimorphism and population variation in the adult mandible: Forensic applications of geometric morphometrics. *Forensic Science, Medicine, and Pathology* 3:15–22.
- Franklin, D., Oxnard, C. E., O'Higgins, P., and Dadour, I. (2007) Sexual dimorphism in the subadult mandible: Quantification using geometric morphometrics. *Journal of Forensic Sciences* 52:6–10.
- Frayser, D. W. (1985) Multivariate morphometrics. *Reviews in Anthropology* 12:289–298.
- Frayser, D. W. (1991) On the etiology of interproximal grooves. *American Journal of Physical Anthropology* 85:299–304.
- Frost, H. M. (1987) Secondary osteon populations: An algorithm for determining mean bone tissue age. *Yearbook of Physical Anthropology* 30:221–238.
- Fuller, B. T., Fuller, J. L., Harris, D. A., and Hedges, R. E. M. (2006) Detection of breastfeeding and weaning in modern human infants with carbon and nitrogen stable isotope ratios. *American Journal of Physical Anthropology* 129:279–293.
- Galána, A. B., Rodríguez, M., de Juana, S., and Domínguez-Rodrigo, M. (2009) A new experimental study on percussion marks and notches and their bearing on the interpretation of hammerstone-broken faunal assemblages. *Journal of Archaeological Science* 36:776–784.
- Galera, V., Ubelaker, D. H., and Hayek, L. C. (1998) Comparison of macroscopic cranial methods of age estimation applied to skeletons of the Terry Collection. *Journal of Forensic Sciences* 43:933–939.
- Galis, F. (1999) Why do almost all mammals have seven cervical vertebrae? Developmental constraints, Hox genes, and cancer. *Journal of Experimental Zoology* 285:19–26.
- Galloway, A., and Simmons, T. L. (1997) Education in forensic anthropology: Appraisal and outlook. *Journal of Forensic Sciences* 42:796–801.
- Galloway, A., and Snodgrass, J. J. (1998) Biological and chemical hazards of forensic skeletal analysis. *Journal of Forensic Sciences* 43:1144–1147.
- Gao, B., Hu, J., Stricker, S., Cheung, M., Ma, G., Law, K. F., Witte, F., Briscoe, J., Mundlos, S., He, L., Cheah, K. S., and Chan, D. (2009) A mutation in *Ihh* that causes digit abnormalities alters its signalling capacity and range. *Nature* 458:1196–1200.

- Garn, S. M. (1972) The course of bone gain and the phases of bone loss. *Orthopedic Clinics of North America* 3:503–520.
- Garn, S. M., Cole, P. E., and van Astine, W. L. (1979) Sex discriminatory effectiveness using combinations of root lengths and crown diameters. *American Journal of Physical Anthropology* 50:115–118.
- Garn, S. M., Sullivan, T. V., Decker, S. A., Larkin, F. A., and Hathorne, V. M. (1992) Continuing bone expansion and increasing bone loss over a two-decade period in men and woman from a total community sample. *American Journal of Human Biology* 4:57–67.
- Garn, S. M., van Astine, W. L., and Cole, P. E. (1978) Relationship between root lengths and crown diameters of corresponding teeth. *Journal of Dental Research* 57:636.
- Garrison, E. G. (2003) *Techniques in archaeological geology*. New York, NY: Springer-Verlag. 295 pp.
- Genovés, S. (1967) Proportionality of long bones and their relation to stature among Mesoamericans. *American Journal of Physical Anthropology* 26:67–78.
- Getlin, J. (1986) Hearts and bones. *Los Angeles Times Magazine*. October 12, 1986, pp. 11–27.
- Giannelli, P. C., and Imwinkelried, E. J. (2007) *Scientific evidence* (4th ed.), in 2 vols. Newark, NJ: LexisNexis.
- Giannelli, P. C., and McMunigal, K. C. (2007) Prosecutors, ethics, and expert witnesses. Case Legal Studies Research Paper No. 08-04. *Fordham Law Review* 76:1493–1537.
- Gibbons, A. (2009) Civilization's cost: The decline and fall of human health. *Science* 324:588.
- Gifford, D. P. (1981) Taphonomy and paleoecology: A critical review of archaeology's sister disciplines. *Advances in Archaeological Method and Theory* 4:365–438.
- Gilbert, B. M., and McKern, T. W. (1973) A method for aging the female os pubis. *American Journal of Physical Anthropology* 38:31–38.
- Gilbert, N. (2009) Science journals crack down on image manipulation. *Nature News*. Accessed 2010 Sept 5. Available from: <http://www.nature.com/news/2009/091009/full/news.2009.991.html>.
- Gilbert, W. H., and Richards, G. D. (2000) Digital imaging of bone and tooth modification. *Anatomical Record* 261:237–246.
- Gilbert, W. H., and Asfaw, B. (Eds.) (2008) *Homo erectus: Pleistocene evidence from the Middle Awash, Ethiopia*. Berkeley, CA: University of California Press. 458 pp.
- Giles, E. (1991) Corrections for age in estimating older adult's stature from long bones. *Journal of Forensic Sciences* 36:898–901.
- Giles, E. (1993) Modifying stature estimation from the femur and tibia. *Journal of Forensic Sciences* 38:758–760.
- Giles, E., and Elliot, O. (1962) Race identification from cranial measurements. *Journal of Forensic Sciences* 7:147–157.
- Giles, E., and Elliot, O. (1963) Sex determination by discriminant function analysis of crania. *American Journal of Physical Anthropology* 21:53–68.
- Gill, G. W. (1984) A forensic test case for a new method of geographical race determination. In: T. A. Rathburn and J. E. Buikstra (Eds.) *Human identification: Case studies in forensic anthropology*. Pp. 329–339. Springfield, IL: C. C. Thomas.
- Gill, G. W. (1995) Challenge on the frontier: Discerning American Indians from whites osteologically. *Journal of Forensic Sciences* 40:783–788.
- Gill, G. W. (1998) Craniofacial criteria in the skeletal attribution of race. In: K. J. Reichs (Ed.) *Forensic osteology: Advances in the identification of human remains* (2nd ed.). Pp. 293–318. Springfield, IL: C. C. Thomas.
- Gill, G. W. (2001) Racial variation in the proximal and distal femur: Heritability and forensic utility. *Journal of Forensic Sciences* 46:791–799.
- Gill, G. W., Fisher, J. W., and Zeimens, G. M. (1984) A pioneer burial near the historic Bordeaux trading post. *Plains Anthropologist* 29:229–238.
- Gill, G. W., and Rhine, S. (Eds.) (1990) *Skeletal attribution of race: Methods for forensic anthropology* (Anthropological Papers Number 4). Albuquerque, NM: Maxwell Museum of Anthropology. 127 pp.
- Gilroy, A. M., MacPherson, B. R., and Ross, L. M. (2008) *Atlas of anatomy*. New York, NY: Thieme. 656 pp.
- Godfrey, L. R., Semperebon, G. M., Jungers, W. L., Sutherland, M. R., Simons, E. L., and Solounias, N. (2004) Dental use wear in extinct lemurs: evidence of diet and niche differentiation. *Journal of Human Evolution* 47:145–169.
- Godfrey, L. R., Semperebon, G. M., Schwartz, G. T., Burney, D. A., Jungers, W. L., Flanagan, E. K., Cuozzo, F. P., and King, S. J. (2005) New insights into old lemurs: The trophic adaptations of the *Archaeolemuridae*. *International Journal of Primatology* 26:825–854.
- Goldberg, K. E. (1985) *The skeleton: Fantastic framework*. New York, NY: Torstar Books. 165 pp.
- Goldstein, L. (1995) Politics, law, pragmatics, and human burial excavations: An example from northern California. In: A. L. Grauer (Ed.) *Bodies of evidence: Reconstructing history through skeletal analysis*. Pp. 3–17. New York, NY: Wiley-Liss.

- Goldstein, L. (2000) The potential for future relationships between archaeologists and Native Americans. In: M. Lynott and A. Wylie (Eds.) *Ethics in American archaeology*. Pp. 118–125. Washington, DC: Society for American Archaeology.
- Goldstein, L., and Kintigh, K. (1990) Ethics and the reburial controversy. *American Antiquity* 55:585–591.
- Gómez-Olivencia, A., Eaves-Johnson, K. L., Franciscus, R. G., Carretero, J. M., and Arsuaga, J. L. (2009) Kebara 2: New insights regarding the most complete Neandertal thorax. *Journal of Human Evolution* 57:75–90.
- González-José, R., Neves, W., Lahr, M. M., González, S., Pucciarelli, H., Martínez, M. H., and Correal, G. (2005) Late Pleistocene/Holocene craniofacial morphology in Mesoamerican Paleoindians: Implications for the peopling of the New World. *American Journal of Physical Anthropology* 128:772–780.
- Goodman, A. H., and Armelagos, G. J. (1985) Factors affecting the distribution of enamel hypoplasias within the human permanent dentition. *American Journal of Physical Anthropology* 68:479–493.
- Goodman, A. H., and Rose, J. C. (1991) Dental enamel hypoplasias as indicators of nutritional status. In: M. A. Kelley and C. S. Larsen (Eds.) *Advances in dental anthropology*. Pp. 279–293. New York, NY: Wiley-Liss.
- Goodman, A. H., and Song, R. (1999) Sources of variation in estimated ages at formation of linear enamel hypoplasias. In: R. D. Hoppa and C. M. FitzGerald (Eds.) *Human growth in the past: Studies from bones and teeth*. Pp. 210–240. Cambridge, UK: Cambridge University Press.
- Goose, D. H. (1956) Variability of the form of maxillary permanent incisors. *Journal of Dental Research* 35:902–908.
- Götherström, A., Collins, M. J., Angerbjörn, A., and Lidén, K. (2002) Bone preservation and DNA amplification. *Archaeometry* 44:1395–1404.
- Gould, R. M. (2004) 1579 *Bonnichsen v. United States*, Opinion. 9th Circuit Court of Appeals, U.S. *Federal Reporter* 367: 367 F.3d 864. Accessed 2010 Oct 4. Available from: <http://ftp.resource.org/courts.gov/c/F3/367/367.F3d.864.02-35996.02-35994.html>
- Grauer, A. L. (Ed.) (1995) *Bodies of evidence: Reconstructing history through skeletal analysis*. New York, NY: Wiley-Liss. 256 pp.
- Graur, D., and Li, W.-H. (2000) *Fundamentals of molecular evolution* (2nd ed.). Sunderland, MA: Sinauer. 481 pp.
- Graw, M., Czarnetzki, A., and Haffner, H.-T. (1999) The form of the supraorbital margin as a criterion in identification of sex from the skull: Investigations based on modern human skulls. *American Journal of Physical Anthropology* 108:91–96.
- Green, R. E., Krause, J., Ptak, S. E., Briggs, A. W., Ronan, M. T., Simons, J. F., Du, L., Egholm, M., Rothberg, J. M., Paunovic, M., and Pääbo, S. (2006) Analysis of one million base pairs of Neanderthal DNA. *Nature* 444:330–336.
- Green, R. E., Briggs, A. W., Krause, J., Prüfer, K., Burbano, H. A., Siebauer, M., Lachmann, M., and Pääbo, S. (2009) The Neandertal genome and ancient DNA authenticity. *The EMBO Journal* 28:2494–2502.
- Green, R. E., Krause, J., Briggs, A. W., Maricic, T., Stenzel, U., Kircher, M., Patterson, N., Li, H., Zhai, W., Fritz, M. H.-Y., Hansen, N. F., Durand, E. Y., Malaspina, A.-S., Jensen, J. D., Marques-Bonet, T., Alkan, C., Prüfer, K., Meyer, M., Burbano, H. A., Good, J. M., Schultz, R., Aximu-Petri, A., Butthof, A., Höber, B., Höffner, B., Siegemund, M., Weihmann, A., Nusbaum, C., Lander, E. S., Russ, C., Novod, N., Affourtit, J., Egholm, M., Verna, C., Rudan, P., Brajkovic, D., Kucan, Z., Gusic, I., Doronichev, V. B., Golovanova, L. V., Lalueza-Fox, C., de la Rasilla, M., Fortea, J., Rosas, A., Schmitz, R. W., Johnson, P. L. F., Eichler, E. E., Falush, D., Birney, E., Mullikin, J. C., Slatkin, M., Nielsen, R., Kelso, J., Lachmann, M., Reich, D., and Pääbo, S. (2010) A draft sequence of the Neandertal genome. *Science* 328:710–722.
- Greenberg, J. H., Turner, C. G., and Zegura, S. L. (1986) The settlement of the Americas: A comparison of the linguistic, dental and genetic evidence. *Current Anthropology* 27:477–497.
- Greene, D. L., Van Gerven, D. P., and Armelagos, G. J. (1986) Life and death in ancient populations: Bones of contention in paleodemography. *Human Evolution* 1:193–207.
- Gregg, J. B., and Gregg, P. S. (1988) *Dry bones, Dakota Territory reflected: An illustrated descriptive analysis of the health and well being of previous people and cultures as is mirrored in their remnants*. Sioux Falls, SD: University of South Dakota Press. 236 pp.
- Griffen, R. C., Chamberlain, A. T., Hotz, G., Penkman, K. E. H., and Collins, M. J. (2009) Age estimation of archaeological remains using amino acid racemization in dental enamel: A comparison of morphological, biochemical, and known ages-at-death. *American Journal of Physical Anthropology* 140:244–252.
- Grine, F. E., Ungar, P. S., and Teaford, M. F. (2002) Error rates in dental microwear quantification using scanning electron microscopy. *Scanning* 24:144–153.
- Grivas, C. R., and Komar, D. A. (2008) *Kumho, Daubert*, and the nature of scientific inquiry: Implications for forensic anthropology. *Journal of Forensic Sciences* 53:771–776.
- Grupe, G. (2001) Archaeological microbiology. In: D. R. Brothwell and A. M. Pollard (Eds.) *Handbook of archaeological sciences*. Pp. 351–358. Hoboken, NJ: John Wiley and Sons.
- Gruspier, K. L., and Mullen, G. J. (1991) Maxillary suture obliteration: A test of the Mann method. *Journal of Forensic Sciences* 36:512–519.

- Guatelli-Steinberg, D. (2008) Dental crown size and sex hormone concentrations: Another look at the development of sexual dimorphism. *American Journal of Physical Anthropology* 137:324–333.
- Guatelli-Steinberg, D., Scullini, P. W., and Betsinger, T. K. (2008) Dental crown size and sex hormone concentrations: Another look at the development of sexual dimorphism. *American Journal of Physical Anthropology* 137:324–333.
- Gülekon, I. N., and Turgut, H. B. (2003) The external occipital protuberance: Can it be used as a criterion in the determination of sex? *Journal of Forensic Sciences* 48:1–4.
- Gustafson, G., and Koch, G. (1974) Age estimation up to 16 years of age based on dental development. *Odontologisk Revy* 25:297–306.
- Haack, S. (2003) Trials and tribulations: Science in the courts. *Daedalus* 132:54–63.
- Haas, C. J., Zink, A., Pálfi, G., Szeimies, U., and Nerlich, A. G. (2000) Detection of leprosy in ancient human skeletal remains by molecular identification of *Mycobacterium leprae*. *American Journal of Clinical Pathology* 114:428–436.
- Hagelberg, E., Sykes, B., and Hedges, R. (1989) Ancient bone DNA amplified. *Nature* 342:485.
- Hagelberg, E., Gray, I. C., and Jeffreys, A. J. (1991) Identification of the skeletal remains of a murder victim by DNA analysis. *Nature* 352:427–429.
- Haglund, W. D. (1992) Contributions of rodents to postmortem artifacts of bone and soft tissue. *Journal of Forensic Sciences* 37:1459–1465.
- Haglund, W. D. (1997) Dogs and coyotes: Postmortem involvement with human remains. In: W. D. Haglund and M. H. Sorg (Eds.) *Forensic taphonomy: The postmortem fate of human remains*. Pp. 367–381. Boca Raton, FL: CRC Press.
- Haglund, W. D. (1998) The scene and context: Contributions of the forensic anthropologist. In: K. J. Reichs (Ed.) *Forensic osteology: Advances in the identification of human remains* (2nd ed.). Pp. 41–62. Springfield, IL: C. C. Thomas.
- Haglund, W. D. (2001) Archaeology and forensic death investigations. *Historical Archaeology* 35:26–34.
- Haglund, W. D., Reay, D. T., and Swindler, D. R. (1988) Tooth mark artifacts and survival of bones in animal scavenged human skeletons. *Journal of Forensic Sciences* 33:985–997.
- Haglund, W. D., and Sorg, M. H. (Eds.) (1997) *Forensic taphonomy: The postmortem fate of human remains*. Boca Raton, FL: CRC Press. 636 pp.
- Hall, Brian K. (2005) *Bones and cartilage: Developmental and evolutionary skeletal biology*. San Diego, CA: Elsevier Academic Press. 792 pp.
- Hamilton, M. E. (1982) Sexual dimorphism in skeletal samples. In: R. L. Hall (Ed.) *Sexual dimorphism in Homo sapiens*. Pp. 107–163. New York, NY: Praeger.
- Hancock, R. G. V., Grynopas, M. D., and Pritzker, K. P. H. (1989) The abuse of bone analyses for archaeological dietary studies. *Archaeometry* 31:169–179.
- Handt, O., Höss, M., Krings, M., and Pääbo, S. (1994) Ancient DNA: Methodological challenges. *Experientia* 50:524–529.
- Hanihara, T., and Ishida, H. (2001) Os incaea: Variation in frequency in major human population groups. *Journal of Anatomy* 198:137–152.
- Hanihara, T. (2008) Morphological variation of major human populations based on nonmetric dental traits. *American Journal of Physical Anthropology* 136:169–182.
- Hansen, M. (1993) Believe it or not. *American Bar Association Journal*, June, pp. 64–67.
- Hardy, J. R. W., Chimumengwende-Gordon, M., and Bakar, I. (2005) Rupture of the quadriceps tendon: An association with a patellar spur. *Journal of Bone and Joint Surgery* 87-B:1361–1363.
- Hardy, K., Blakeney, T., Copeland, L., Kirkham, J., Wrangham, R., and Collins, M. (2009) Starch granules, dental calculus and new perspectives on ancient diet. *Journal of Archaeological Science* 36:248–255.
- Harris, E. F., and McKee, J. H. (1990) Tooth mineralization standards for blacks and whites from the middle southern United States. *Journal of Forensic Sciences* 35:859–872.
- Harth, S., Obert, M., Ramsthaler, F., Reuß, C., Traupe, H., and Verhof, M. A. (2010) Ossification degrees of cranial sutures determined with flat-panel computed tomography: Narrowing the age estimate with extrema. *Journal of Forensic Sciences* 55:690–694.
- Hartnett, K. M. (2010) Analysis of age-at-death estimation using data from a new, modern autopsy sample, Part II: Sternal end of the fourth rib. *Journal of Forensic Sciences* 55:1152–1156.
- Hass, C. J., Zink, A., Molnar, E., Szeimies, U., Reischl, U., Marcsik, A., Ardagna, Y., Dutour, O., Pálfi, G., and Nerlich, A. G. (2000) Molecular evidence for different stages of tuberculosis in ancient bone samples from Hungary. *American Journal of Physical Anthropology* 113:293–304.
- Hasselstrøm, H., Karlsson, K. M., Hansen, S. E., Grønfeldt, V., Froberg, K., and Andersen, L. B. (2006) Sex differences in bone size and bone mineral density exist before puberty. The Copenhagen School Child Intervention Study (CoSCIS). *Calcified Tissue International* 79:7–14.

- Hastings, D., and Sampson, D. (1997) Q: Should scientists be allowed to 'study' the skeletons of ancient American Indians? *Insight on the News* 13:24–27.
- Haun, S. J. (2000) Brief communication: A study of the predictive accuracy of mandibular ramus flexure as a single morphologic indicator of sex in an archaeological sample. *American Journal of Physical Anthropology* 111:429–432.
- Hauser, G., and DeStefano, G. F. (1989) *Epigenetic variants of the human skull*. Stuttgart, Germany: E. Schweizerbart'sche Verlagsbuchhandlung. 301 pp.
- Hauswirth, W. W., Dickel, C. D., Rowold, D. J., and Hauswirth, M. A. (1994) Inter- and intrapopulation studies of ancient humans. *Experientia* 50:585–591.
- Heathcote, G. M. (1981) The magnitude and consequences of measurement error in human craniometry. *Canadian Review of Physical Anthropology* 3:18–40.
- Hedges, R. E. M. (2002) Bone diagenesis: An overview of processes. *Archaeometry* 44:319–328.
- Hefner, J. T. (2009) Cranial nonmetric variation and estimating ancestry. *Journal of Forensic Sciences* 54:985–995.
- Henderson, J. (1987) Factors determining the state of preservation of human remains. In: A. Boddington, A. N. Garland, and R. C. Janaway (Eds.) *Death, decay, and reconstruction*. Pp. 43–54. Manchester, UK: Manchester University Press.
- Henke, W., and Tattersall, I. (Eds.) (2007) *Handbook of paleoanthropology (vol. I: Principles, methods and approaches; vol. II: Primate evolution and human origins; vol. III: Phylogeny of hominids)*. New York, NY: Springer. 2173 pp.
- Henry, A. G., and Piperno, D. R. (2008) Using plant microfossils from dental calculus to recover human diet: A case study from Tell al-Raqa' I, Syria. *Journal of Archaeological Science* 35:1943–1950.
- Herrmann, B., and Hummel, S. (Eds.) (1994) *Ancient DNA: Recovery and analysis of genetic material from paleontological, archaeological, museum, medical, and forensic specimens*. New York, NY: Springer-Verlag. 284 pp.
- Hertzog, K. P. (1967) Shortened fifth medial phalanges. *American Journal of Physical Anthropology* 27:113–117.
- Higuchi, R., Bowman, B., Freiberger, M., Ryder, O. A., and Wilson, A. C. (1984) DNA sequences from the quagga, an extinct member of the horse family. *Nature* 312:282–284.
- Hildebrand, M. (1968) *Anatomical preparations*. Berkeley, CA: University of California Press. 100 pp.
- Hill, C. A. (2000) Technical note: Evaluating mandibular ramus flexure as a morphological indicator of sex. *American Journal of Physical Anthropology* 111:573–577.
- Hillson, S. (2005) *Teeth* (2nd ed.). New York, NY: Cambridge University Press. 388 pp.
- Hillson, S. (1992) Impression and replica methods for studying hypoplasia and perikymata on human tooth crown surfaces from archaeological sites. *International Journal of Osteoarchaeology* 2:65–78.
- Hillson, S. (1996) *Dental anthropology*. Cambridge, UK: Cambridge University Press. 392 pp.
- Hillson, S. (2001) Recording dental caries in archaeological human remains. *International Journal of Osteoarchaeology* 11:249–289.
- Hillson, S. (2008) Dental pathology. In: M. A. Katzenberg and S. R. Saunders (Eds.) *Biological anthropology of the human skeleton* (2nd ed.). Pp. 249–286. New York, NY: Wiley-Liss.
- Hiss, J., Freund, M., and Kahana, T. (2007) The forensic expert witness: An issue of competency. *Forensic Science International* 168:89–94.
- Hlusko, L. J. (2003) The oldest hominid habit? Experimental evidence for toothpicking with grass stalks. *Current Anthropology* 44:738–741.
- Hlusko, L. J., and Mahaney, M. C. (2007) Of mice and monkeys: Quantitative genetic analyses of size variation along the dental arcade. In: S. E. Bailey and J.-J. Hublin (Eds.), *Dental perspectives on human evolution: State-of-the-art research in dental paleoanthropology*. Pp. 237–245. New York, NY: Springer.
- Hlusko, L. J., and Mahaney, M. C. (2009) Quantitative genetics, pleiotropy, and morphological integration in the dentition of *Papio hamadryas*. *Evolutionary Biology* 36:5–18.
- Ho, S. Y. W., and Gilbert, M. T. P. (2010) Ancient mitogenomics. *Mitochondrion* 10:1–11.
- Hoffman, R., and Hays, C. (1987) The eastern wood rat (*Neotoma floridana*) as a taphonomic factor in archaeological sites. *Journal of Archaeological Science* 14:325–337.
- Hogge, J. P., Messmer, J. M., and Doan, Q. N. (1994) Radiographic identification of unknown human remains and interpreter experience level. *Journal of Forensic Sciences* 39:373–377.
- Holland, M. M., Fisher, D. L., Mitchell, L. G., Rodriguez, W. C., Canik, J. J., Merrill, C. R., and Weedn, V. W. (1993) Mitochondrial DNA sequence analysis of human skeletal remains: Identification of remains from the Vietnam War. *Journal of Forensic Sciences* 38:542–553.
- Holliday, T. W., and Falsetti, A. B. (1999) A new method for discriminating African-American from European-American skeletons using postcranial osteometrics reflective of body shape. *Journal of Forensic Sciences* 44:926–930.
- Hollien, H. (1990) The expert witness: Ethics and responsibilities. *Journal of Forensic Sciences* 35:1414–1423.
- Hoppa, R. D. (2000) Population variation in osteological aging criteria: An example from the pubic symphysis. *American Journal of Physical Anthropology* 111:185–191.

- Hoppa, R. D., and Saunders, S. (1998) Two quantitative methods for rib seriation in human skeletal remains. *Journal of Forensic Sciences* 43:174–177.
- Hoppa, R. D., and FitzGerald, C. M. (Eds.) (1999) *Human growth in the past: Studies from bones and teeth*. Cambridge, UK: Cambridge University Press. 336 pp.
- Hoppa, R. D., and Vaupel, J. W. (Eds.) (2002) *Paleodemography: Age distributions from skeletal samples*. New York, NY: Cambridge University Press. 276 pp.
- Hoshow, L. M. (1998) Forensic archeology and the need for flexible excavation strategies: A case study. *Journal of Forensic Sciences* 43:53–56.
- Houck, M. M. (1998) Skeletal trauma and the individualization of knife marks in bones. In: K. J. Reichs (Ed.) *Forensic osteology: Advances in the identification of human remains* (2nd ed.). Pp. 410–424. Springfield, IL: C. C. Thomas.
- Houck, M. M., Ubelaker, D., Owsley, D., Craig, E., Grant, W., Fram, R., Woltanski, T., and Sandness, K. (1996) The role of forensic anthropology in the recovery and analysis of Branch Davidian compound victims: Assessing the accuracy of age estimations. *Journal of Forensic Sciences* 41:796–801.
- Howells, W. W. (1969a) Criteria for selection of osteometric dimensions. *American Journal of Physical Anthropology* 30:451–458.
- Howells, W. W. (1969b) The use of multivariate techniques in the study of skeletal populations. *American Journal of Physical Anthropology* 31:311–314.
- Howells, W. W. (1973) *Cranial variation in man: A study by multivariate analysis of patterns of differences among recent human populations*. Cambridge, MA: Peabody Museum. 259 pp.
- Howells, W. W. (1978) *Cranial variation in man: study by multivariate analysis of patterns of differences among recent human populations* (illustr. ed.). Cambridge, MA: Harvard University Press. 259 pp.
- Howells, W. W. (1983) Origins of Chinese people: Interpretations of the recent evidence. In: D. N. Keightly (Ed.) *The origins of Chinese civilization*. Pp. 297–319. Berkeley, CA: University of California Press.
- Howells, W. W. (1986) Physical anthropology of the prehistoric Japanese. In: R. J. Pearson (Ed.) *Windows on the Japanese past*. Pp. 85–99. Ann Arbor, MI: Center for Japanese Studies.
- Howells, W. W. (1989) Skull shapes and the map: Craniometric analyses in the dispersion of modern *Homo*. *Papers of the Peabody Museum of Archaeology and Ethnology* 79:1–189.
- Howells, W. W. (1995) Who's who in skulls: Ethnic identification of crania from measurements. *Papers of the Peabody Museum of Archaeology and Ethnology, Harvard University* 82:1–108.
- Hrdlička, A. (1939) *Practical anthropometry*. Philadelphia, PA: Wistar Institute of Anatomy and Biology.
- Hubbard, A., Guatelli-Steinberg, D., and Sciuili, P. W. (2009) Under restrictive conditions, can the widths of linear enamel hypoplasias be used as relative indicators of stress episode duration? *American Journal of Physical Anthropology* 138:177–189.
- Hubert, J. (1989) A proper place for the dead: A critical review of the “reburial” issue. In: R. Layton (Ed.) *Conflict in the archaeology of living traditions*. Pp. 131–166. London, UK: Unwin Hyman.
- Huchet, J.-B., Deverly, D., Gutierrez, B., and Chauca, C. (in press) Taphonomic evidence of a human skeleton gnawed by termites in a Moche-Civilisation grave at Huaca de la Luna, Peru. *International Journal of Osteoarchaeology* Early view: www.interscience.wiley.com, DOI: 10.1002/oa.1110.
- Hughes, C., Juarez, C., Zephro, L., Fowler, G., and Chacon, S. (in press) Past or present? Differentiating California prehistoric Native American remains from forensic cases: An empirical approach. *International Journal of Osteoarchaeology* Early view: www.interscience.wiley.com, DOI: 10.1002/oa.1192.
- Humes, D., Jähnich, H., Rehm, A., and Compson, J. P. (2004) The osteology of the trapezium. *Journal of Hand Surgery (British and European Volume)* 29B: 42–45.
- Hummert, J. R., and Van Gerven, D. P. (1985) Observations on the formation and persistence of radiopaque transverse lines. *American Journal of Physical Anthropology* 66:297–306.
- Humphrey, L. T., Dean, M. C., and Stringer, C. B. (1999) Morphological variation in great ape and modern human mandibles. *Journal of Anatomy* 195:491–513.
- von Hunnius, T. E., Roberts, C. A., Boylston, A., and Saunders, S. R. (2006) Histological identification of syphilis in pre-Columbian England. *American Journal of Physical Anthropology* 129:559–566.
- Hunt, D. R. (n.d.) The Robert J. Terry Anatomical Skeletal Collection. *Smithsonian (National Museum of Natural History), Department of Anthropology website*. Accessed 2010 Aug 30. Available from: <http://anthropology.si.edu/cm/terry.htm>.
- Hunt, D. R., and Albanese, J. (2005) History and demographic composition of the Robert J. Terry Anatomical Collection. *American Journal of Physical Anthropology* 127:406–417.
- Hunter, J., and Cox, M. (Eds.) (2005) *Forensic archaeology: Advances in theory and practice*. New York, NY: Routledge. 256 pp.
- Huss-Ashmore, R., Goodman, A. H., and Armelagos, G. J. (1982) Nutritional inference from paleopathology. *Advances in Archaeological Method and Theory* 5:395–474.

- Huxley, A. K. (2005) Gestational age discrepancies due to acquisition artifact in the Forensic Fetal Osteology Collection at the National Museum of Natural History, Smithsonian Institution, USA. *American Journal of Forensic Medicine & Pathology* 26:216–220.
- International Human Genome Sequencing Consortium (2004) Finishing the euchromatic sequence of the human genome. *Nature* 431:931–945.
- Introna, F., Jr., Di Vella, G., Campobasso, C. P., and Dragone, M. (1997) Sex determination by discriminant analysis of calcanei measurements. *Journal of Forensic Sciences* 42:725–728.
- Irish, J. D., and Nelson, G. C. (Eds.) (2008) *Technique and application in dental anthropology*. Cambridge, UK: Cambridge University Press. 470 pp.
- Irwin J. A., Leney, M. D., Loreille, O., Barritt, S. M., Christensen, A. F., Holland, T. D., Smith, B. C., and Parsons, T. J. (2007) Application of low copy number STR typing to the identification of aged, degraded skeletal remains. *Journal of Forensic Sciences* 52:1322–1327.
- İşcan, M. Y. (1988) Rise of forensic anthropology. *Yearbook of Physical Anthropology* 31:203–230.
- İşcan, M. Y. (Ed.) (1989) *Age markers in the human skeleton*. Springfield, IL: C. C. Thomas. 359 pp.
- İşcan, M. Y., and Cotton, T. S. (1985) The effect of age on the determination of race from the pelvis. *Journal of Human Evolution* 14:275–282.
- İşcan, M. Y., and Helmer, R. P. (1993) *Forensic analysis of the skull: Craniofacial analysis, reconstruction, and identification*. New York, NY: Wiley-Liss. 258 pp.
- İşcan, M. Y., and Kennedy, K. A. R. (Eds.) (1989) *Reconstruction of life from the skeleton*. New York, NY: Alan R. Liss. 332 pp.
- İşcan, M. Y., and Loth, S. R. (1986a) Determination of age from the sternal rib in white males: A test of the phase method. *Journal of Forensic Sciences* 31:122–132.
- İşcan, M. Y., and Loth, S. R. (1986b) Determination of age from the sternal rib in white females: A test of the phase method. *Journal of Forensic Sciences* 31:990–999.
- İşcan, M. Y., and Loth, S. R. (1986c) Estimation of age and determination of sex from the sternal rib. In: K. J. Reichs (Ed.) *Forensic osteology: Advances in the identification of human remains* (1st ed.). Pp. 68–89. Springfield, IL: C. C. Thomas.
- İşcan, M. Y., Loth, S. R., and Wright, R. K. (1984a) Age estimation from the rib by phase analysis: White males. *Journal of Forensic Sciences* 29:1094–1104.
- İşcan, M. Y., Loth, S. R., and Wright, R. K. (1984b) Metamorphosis at the sternal rib end: A new method to estimate age at death in white males. *American Journal of Physical Anthropology* 65:147–156.
- İşcan, M. Y., Loth, S. R., and Wright, R. K. (1985) Age estimation from the rib by phase analysis: White females. *Journal of Forensic Sciences* 30:853–863.
- İşcan, M. Y., Loth, S. R., and Wright, R. K. (1987) Racial variation in the sternal extremity of the rib and its effect on age determination. *Journal of Forensic Sciences* 32:452–466.
- Jackes, M. (1992) Paleodemography: Problems and techniques. In: S. R. Saunders and M. A. Katzenberg (Eds.) *Skeletal biology of past peoples: Research methods*. Pp. 189–224. New York, NY: Wiley-Liss.
- Jackes, M. (2000) Building the bases for paleodemographic analysis: Adult age determination. In: M. A. Katzenberg and S. R. Saunders (Eds.) *Biological anthropology of the human skeleton* (1st ed.). Pp. 417–466. New York, NY: Wiley-Liss.
- Janaway, R. C., Percival, S. L., and Wilson, A. S. (2009) Decomposition of human remains. In: S. L. Percival (Ed.) *Microbiology and aging: Clinical manifestations*. Pp. 313–334. New York, NY: Springer.
- Janjua, M. A., and Rogers, T. L. (2008) Bone weathering patterns of metatarsal v. femur and the postmortem interval in Southern Ontario. *Forensic Science International* 178:16–23.
- Jantz, R. L. (1992) Modification of the Trotter and Gleser female stature estimation formulae. *Journal of Forensic Sciences* 37:1230–1235.
- Jantz, R. L. (1993) Modifying stature estimation from the femur and tibia: Author's response. *Journal of Forensic Sciences* 38:760–763.
- Jantz, R. L., Hunt, D. R., and Meadows, L. (1995) The measure and mismeasure of the tibia: Implications for stature estimation. *Journal of Forensic Sciences* 40:758–761.
- Jarvik, E. (1980) *Basic structures and evolution of vertebrates, vol. 2*. New York, NY: Academic Press. 350 pp.
- Jeffreys, A. J., Allen, M. J., Hagelberg, E., and Sonnberg, A. (1992) Identification of the skeletal remains of Josef Mengele by DNA analysis. *Forensic Science International* 56:65–76.
- Jelderks, J. (2002) *Bonnichsen v. United States*, Opinion and order, Civil no. 96-1481-JE, 217 F. Supp. 2d 1116 (D. Or. 2002) (appeal after remand, 969 F. Supp. 628 (D. Or. 1997)).
- Johanson, D. C. (1979) A consideration of the “*Dryopithecus* pattern.” *Ossa* 6:125–138.
- Johnson, G. (2002) Tradition, authority and the Native American Graves Protection and Repatriation Act. *Religion* 32:355–381.
- Johnson, J. S. (2001) A long-term look at polymers used to preserve bone. In: E. Williams (Ed.) *Human remains: Conservation, retrieval and analysis*. Pp. 99–102. Oxford, UK: Archaeopress.

- Jones, D. G., and Harris, R. J. (1998) Archeological human remains. *Current Anthropology* 39:253–264.
- Joukowsky, M. (1980) *A complete manual of field archaeology: Tools and techniques of field work for archaeologists*. Englewood Cliffs, NJ: Prentice Hall. 630 pp.
- Joint POW/MIA Accounting Command/Central Identification Laboratory (JPAC-CIL) (2008) JPAC laboratory manual, part IV: SOP 4.0. Last revised 02 April 2008.
- Jungers, W. L., and Minns, R. J. (1979) Computed tomography and biomechanical analysis of fossil long bones. *American Journal of Physical Anthropology* 50:285–290.
- Jurmain, R., Bartelink, E. J., Leventhal, A., Bellifemine, V., Nechayev, I., Atwood, M., and DiGiuseppe, D. (2009) Paleoepidemiological patterns of interpersonal aggression in a prehistoric central California population from CA-ALA-329. *American Journal of Physical Anthropology* 139:462–473.
- Jørkov, M. L. S., Heinemeier, J., and Lynnerup, N. (2007) Evaluating bone collagen extraction methods for stable isotope analysis in dietary studies. *Journal of Archaeological Science* 34:1824–1829.
- Jørkov, M. L. S., Heinemeier, J., and Lynnerup, N. (2009) The petrous bone: A new sampling site for identifying early dietary patterns in stable isotopic studies. *American Journal of Physical Anthropology* 138:199–209.
- Kachlik, D., Baca, V., Bozdechova, I., Cech, P., and Musil, V. (2008) Anatomical terminology and nomenclature: Past, present and highlights. *Surgical and Radiologic Anatomy* 30:459–466.
- Kaestle, F. A. (1995) Chapter 5. Mitochondrial DNA evidence for the identity of descendants of the prehistoric Stillwater Marsh population. In: C. S. Larsen and R. L. Kelley (Eds.) *Bioarchaeology of the Stillwater Marsh: Prehistoric human adaptation in the western Great Basin*. *American Museum of Natural History Anthropological Papers* 77:73–80.
- Kaestle, F. A., and Horsburgh, K. A. (2002) Ancient DNA in anthropology: Methods, applications, and ethics. *Yearbook of Physical Anthropology* 119:92–130.
- Kaiser, T. M. (2000) Proposed fossil insect modification to fossil mammalian bone from Plio-Pleistocene hominid-bearing deposits of Laetoli (northern Tanzania). *Annals of the Entomological Society of America* 93:693–700.
- Kangas, A. T., Evans, A. R., Thesleff, I., and Jernvall, J. (2004) Nonindependence of mammalian dental characters. *Nature* 432:211–214.
- Karsenty, G., Kronenberg, H. M., and Settembre, C. (2009) Genetic control of bone formation. *Annual Review of Cell and Developmental Biology* 25:629–648.
- Katz, D., and Suchey, J. M. (1986) Age determination of the male os pubis. *American Journal of Physical Anthropology* 69:427–435.
- Katz, D., and Suchey, J. M. (1989) Race differences in pubic symphyseal aging patterns in the male. *American Journal of Physical Anthropology* 80:167–172.
- Katzenberg, M. A. (2008) Stable isotope analysis: A tool for studying past diet, demography, and life history. In: M. A. Katzenberg and S. R. Saunders (Eds.) *Biological anthropology of the human skeleton* (2nd ed.). Pp. 413–442. New York, NY: Wiley-Liss.
- Katzenberg, M. A., and Saunders, S. R. (Eds.) (2000) *Biological anthropology of the human skeleton* (1st ed.). New York, NY: Wiley-Liss. 504 pp.
- Katzenberg, M. A., and Saunders, S. R. (Eds.) (2008) *Biological anthropology of the human skeleton* (2nd ed.). New York, NY: Wiley-Liss. 680 pp.
- Kelley, M. A. (1979) Parturition and pelvic changes. *American Journal of Physical Anthropology* 51:541–546.
- Kelley, M. A., and Larsen, C. S. (Eds.) (1991) *Advances in dental anthropology*. New York, NY: Wiley-Liss.
- Kellner, C. M., and Schoeninger, M. J. (2007) A simple carbon isotope model for reconstructing prehistoric human diet. *American Journal of Physical Anthropology* 133:1112–1127.
- Kelman, L. M., and Kelman, Z. (1999) The use of ancient DNA in paleontological studies. *Journal of Vertebrate Paleontology* 19:8–20.
- Kemkes, A. (2007) The unknown female from Cologne: Science at a dead end? In: M. B. Brickley and R. Ferllini (Eds.), *Forensic anthropology: Case studies from Europe*. Pp. 120–136. Springfield, IL: C. C. Thomas.
- Kemkes-Grotenthaler A., Löbig F., and Stock F. (2002) Mandibular ramus flexure and gonial eversion as morphologic indicators of sex. *Homo* 53:97–111.
- Kennedy, K. A. R. (1989) Skeletal markers of occupational stress. In: M. Y. İşcan and K. A. R. Kennedy (Eds.) *Reconstruction of life from the skeleton*. Pp. 129–160. New York, NY: Alan R. Liss.
- Kennedy, K. A. R. (1995) But professor, why teach race identification if races don't exist? *Journal of Forensic Sciences* 40:797–800.
- Kent, S. (1987) The influence of sedentism and aggregation on porotic hyperostosis and anaemia: A case study. *Man* 21:605–636.
- Keough, N., L'Abbé, E. N., and Steyn, M. (2009) The evaluation of age-related histomorphometric variables in a cadaver sample of lower socioeconomic status: implications for estimating age at death. *Forensic Science International* 191:114.e1–6.

- Kieser, J. A. (1990) Human adult odontometrics: The study of variation in adult tooth size. New York, NY: Cambridge University Press. 208 pp.
- Killam, E. W. (2004) *The detection of human remains* (2nd ed.). Springfield, IL: C. C. Thomas. 268 pp.
- King, C. A., İşcan, M. Y., and Loth, S. R. (1998) Metric and comparative analysis of sexual dimorphism in the Thai femur. *Journal of Forensic Sciences* 43:954–958.
- Kipfer, B. A. (2007) *The archaeologist's fieldwork companion*. Malden, MA: Wiley-Blackwell. 488 pp.
- Kirk, N. J., Wood, R. E., and Goldstein, M. (2002) Skeletal identification using the frontal sinus region: A retrospective study of 39 cases. *Journal of Forensic Sciences* 47:318–323.
- Kitayama, T., Ogawa, Y., Fujii, K., Nakahara, H., Mizuno, N., Sekiguchi, K., Kasai, K., Yurino, N., Yokoi, T., Fukuma, Y., Yamamoto, K., Oki, T., Asamura, H., and Fukushima, H. (2010) Evaluation of a new experimental kit for the extraction of DNA from bones and teeth using a non-powder method. *Legal Medicine (Tokyo)* 12:84–89.
- Klepinger, L. L. (2006) *Fundamentals of forensic anthropology*. New York, NY: Wiley-Liss. 220 pp.
- Klepinger, L. L., and Giles, E. (1998) Clarification or confusion: Statistical interpretation in forensic anthropology. In: K. J. Reichs (Ed.) *Forensic osteology: Advances in the identification of human remains* (2nd ed.). Pp. 427–440. Springfield, IL: C. C. Thomas.
- Klepinger, L. L., Katz, D., Micozzi, M. S., and Carroll, L. (1992) Evaluation of cast methods for estimating age from the os pubis. *Journal of Forensic Sciences* 37:763–770.
- Klesert, A. L., and Powell, S. (1993) A perspective on ethics and the reburial controversy. *American Antiquity* 58:348–354.
- Klippel, W. E., and Synsteliën, J. A. (2007) Rodents as taphonomic agents: Bone gnawing by brown rats and gray squirrels. *Journal of Forensic Sciences* 52:765–773.
- Knapp, M., and Hofreiter, M. (2010) Next generation sequencing of ancient DNA: Requirements, strategies and perspectives. *Genes* 1:227–243.
- Knußmann, R. (Ed.) (1988) *Anthropologie: Handbuch der vergleichenden Biologie des Menschen, begründet von Rudolf Martin*. Stuttgart, Germany: Gustav Fischer.
- Kogan, J. D. (1978) On being a good expert witness in a criminal case. *Journal of Forensic Sciences* 23:190–200.
- Kogon, S. L., and MacLean, D. F. (1996) Long-term validation study of bitewing dental radiographs for forensic identification. *Journal of Forensic Sciences* 41:230–232.
- Kolman, C. J., and Tuross, N. (2000) Ancient DNA analysis of human populations. *American Journal of Physical Anthropology* 111:5–23.
- Kolman, C. J., Centurion-Lara, A., Lukehart, S. A., Owsley, D. A., and Tuross, N. (1999) Identification of *Treponema pallidum* subspecies *pallidum* in a 200-year-old skeletal specimen. *Journal of Infectious Diseases* 180:2060–2063.
- Komar, D. A. (1999) The use of cadaver dogs in locating scattered, scavenged human remains: Preliminary field test results. *Journal of Forensic Sciences* 44:405–408.
- Komar, D. A., and Buikstra, J. E. (2007) *Forensic anthropology: Contemporary theory and practice*. New York, NY: Oxford University Press. 362 pp.
- Komar, D. A., and Grivas, C. (2008) Manufactured populations: What do contemporary reference skeletal collections represent? A comparative study using the Maxwell Museum documented collection. *American Journal of Physical Anthropology* 137:224–233.
- Konigsberg, L. W., and Frankenberg, S. R. (1994) Paleodemography: “Not quite dead.” *Evolutionary Anthropology* 2:92–105.
- Konigsberg, L. W., and Frankenberg, S. R. (2002) Deconstructing death in paleodemography. *American Journal of Physical Anthropology* 117:297–809.
- Konigsberg, L. W., Kohn, L. A. P., and Cheverud, J. M. (1993) Cranial deformation and nonmetric trait variation. *American Journal of Physical Anthropology* 90:35–48.
- Koski, K. (1996) Mandibular ramus flexure: Indicator of sexual dimorphism? *American Journal of Physical Anthropology* 101:545–546.
- van der Kraan, P. M., Davidson, E. N. B., and van den Berg, W. B. (2010) Bone morphogenetic proteins and articular cartilage: To serve and protect or a wolf in sheep's clothing? *Osteoarthritis and Cartilage* 18:735–741.
- Krahl, V. E., and Evans, F. G. (1945) Humeral torsion in man. *American Journal of Physical Anthropology* 3:229–253.
- Kranioti, E. F., Rosas, A., García-Vargas, S., Estalrich, A., Bastir, M., and Peña-Melián, A. (2009) Remodeling patterns of occipital growth: a preliminary report. *Anatomical Record* 292:1764–1770.
- Kres, L. A., and Lovell, N. C. (1995) A comparison of consolidants for archaeological bone. *Journal of Field Archaeology* 22:508–515.
- Krings, M., Stone, A., Schmitz, R. W., Krainitzki, H., Stoneking, M., and Pääbo, S. (1997) Neandertal DNA sequences and the origin of modern humans. *Cell* 90:19–30.

- Krogman, W. M., and İşcan, M. Y. (1986) *The human skeleton in forensic medicine* (2nd ed.). Springfield, IL: C. C. Thomas. 551 pp.
- Krueger, J. W. (2002) Forensic examination of questioned scientific images. *Accountability in Research: Policies and Quality Assurance* 9:105–125.
- Krueger, J. W. (2008) Image manipulation in science: Detection and choices. Lecture delivered as part of the Allen Press Seminar, “Emerging trends in scholarly publication,” held April 17, 2008, at the National Press Club, Washington, DC. Accessed 2010 Sept 05. Available from: http://allenpress.com/system/files/pdfs/library/presentations/John_Krueger_ET08.pdf.
- Krueger, J. W. (2009) Incidences of ORI cases involving falsified images. *Office of Research Integrity Newsletter* 17:2–3.
- Krueger, K. L., and Ungar, P. S. (2010) Incisor microwear textures of five bioarcheological groups. *International Journal of Osteoarchaeology* 20:549–560.
- Kunos, C. A., Simpson, S. W., Russell, K. F., and Hershkovitz, I. (1999) First rib metamorphosis: Its possible utility for human age-at-death estimation. *American Journal of Physical Anthropology* 110:303–323.
- Kvaal, S. I., Sellevold, B. J., and Solheim, T. (1994) A comparison of different non-destructive methods of age estimation in skeletal material. *International Journal of Osteoarchaeology* 4:363–370.
- L'Abbé, E. N., Loots, M., and Meiring, J. H. (2005) The Pretoria Bone Collection: A modern South African skeletal sample. *Homo* 56:197–205.
- Lacy, G. H., and Swatek, F. E. (1974) Soil ecology of *Coccidioides immitis* at Amerindian middens in California. *Applied Microbiology* 27:379–388.
- Lambert, P. M., and Walker, P. L. (1991) Physical anthropological evidence for the evolution of social complexity in coastal southern California. *Antiquity* 65:963–973.
- Lamendin, H., Baccino, E., Humbert, J. F., Tavernier, J. C., Nossintchouk, R. M., and Zerilli, A. (1992) A simple technique for age estimation in adult corpses: The two criteria dental method. *Journal of Forensic Sciences* 37:1373–1379.
- Lampl, M. (2009) Human growth from the cell to the organism: Saltations and integrative physiology. *Annals of Human Biology* 36:478–495.
- Lampl, M., Veldhuis, J. D., and Johnson, M. L. (1992) Saltation and stasis: A model of human growth. *Science* 258:801–803.
- Lampl, M., and Johnston, F. E. (1996) Problems in the aging of skeletal juveniles: Perspectives from maturation assessments of living children. *American Journal of Physical Anthropology* 101:345–355.
- Lanfranco, L. P., and Eggers, S. (2010) The usefulness of caries frequency, depth, and location in determining cariogenicity and past subsistence: A test on early and later agriculturalists from the Peruvian coast. *American Journal of Physical Anthropology* 143:75–91.
- Lanier, R. R. (1944) Length of first, twelfth, and accessory ribs in American whites and negroes: Their relationship to certain vertebral variations. *American Journal of Physical Anthropology N.S.* 2:137–146.
- Larsen, C. S. (1983) Behavioral implications of temporal change in cariogenesis. *Journal of Archaeological Science* 10:1–8.
- Larsen, C. S. (1997) *Bioarchaeology: Interpreting behavior from the human skeleton*. Cambridge, UK: Cambridge University Press. 461 pp.
- Larsen, C. S. (Ed.) (2001) *Bioarchaeology of Spanish Florida: The impact of colonialism*. Gainesville, FL: University Press of Florida. 352 pp.
- Larsen, C. S. (2006) The Agricultural Revolution as environmental catastrophe: Implications for health and lifestyle in the Holocene. *Quaternary International* 150:12–20.
- Larsen, C. S., and Kelly, R. L. (Eds.) (1995) Bioarchaeology of the Stillwater Marsh: Prehistoric human adaptation in the western Great Basin. *American Museum of Natural History Anthropological Papers* 77:1–170.
- Larsen, C. S., Kelly, R. L., Ruff, C. B., Schoeninger, M. J., and Hutchinson, D. L. (1996) Biobehavioral adaptations in the western Great Basin. In: E. J. Reitz, L. A. Newson, and S. J. Scudder (Eds.) *Case studies in environmental archaeology*. Pp. 149–174. New York, NY: Plenum Press.
- Larsen, C. S., and Walker, P. L. (2005) The ethics of bioarchaeology. In: T. R. Turner (Ed.) *Biological anthropology and ethics: From repatriation to genetic identity*. Pp. 111–119. Albany, NY: State University of New York Press.
- Larson, S. G. (2007) The definition of humeral torsion: A comment on Rhodes (2006). *American Journal of Physical Anthropology* 138:819–821.
- Latimer, B., and Ward, C. V. (1993) The thoracic and lumbar vertebrae. In: A. Walker and R. Leakey (Eds.) *The Nariokotome Homo erectus skeleton*. Pp. 266–293. Cambridge, MA: Harvard University Press.
- Lawing, A. M., and Polly, P. D. (2010) Geometric morphometrics: recent applications to the study of evolution and development. *Journal of Zoology* 280:1–7.
- Layton, R. (Ed.) (1994) *Conflict in the archaeology of living traditions* (2nd ed.). New York, NY: Routledge. 276 pp.

- Lee, E. J., Luedtke, J. G., Allison, J. L., Arber, C. E., Merriwether, D. A., and Steadman, D. W. (2010) The effects of different maceration techniques on nuclear DNA amplification using human bone. *Journal of Forensic Sciences* 55:1032–1038.
- Lee-Thorp, J. A. (2008) On isotopes and old bones. *Archaeometry* 50:925–950.
- Leiggi, P., and May, P. J. (Eds.) (1994) *Vertebrate paleontological techniques, vol. 1*. Cambridge, UK: Cambridge University Press. 344 pp.
- Lenchik, L., and Sartoris, D. J. (1997) Current concepts in osteoporosis. *American Journal of Roentgenology* 168:905–911.
- Leroy, S. A. G., Jousse, H., and Cremaschi, M. (Eds.) (2006) Impact of rapid environmental changes on humans and ecosystems. *Quaternary International* 150:1–129.
- Lewis, M. (2000) Non-adult palaeopathology: Current status and future potential. In: M. Cox and S. Mays (Eds.) *Human osteology in archaeology and forensic science*. Pp. 39–57. London, UK: Greenwich Medical Media, Ltd.
- Lewis, M. (2009) *The bioarchaeology of children: Perspectives from biological and forensic anthropology*. Cambridge, UK: Cambridge University Press. 268 pp.
- Ley, C. A., Aiello, L. C., and Molleson, T. (1994) Cranial suture closure and its implications for age estimation. *International Journal of Osteoarchaeology* 4:193–207.
- Lindahl, T. (1997) Facts and artifacts of ancient DNA. *Cell* 90:1–3.
- Linderholm, A., Jonson, C. H., Svensk, O., and Lidén, K. (2008) Diet and status in Birka: Stable isotopes and grave goods compared. *Antiquity* 82:446–461.
- Listi, G. A., Manhein, M. H., and Leitner, M. (2007) Use of the global positioning system in the field recovery of scattered human remains. *Journal of Forensic Sciences* 52:11–15.
- Liversidge, H. M. (1994) Accuracy of age estimation from developing teeth of a population of known age (0–5.4 years) *International Journal of Osteoarchaeology* 4:37–45.
- Lomawaima, H., McKeown, C. T., Harjo, S. S., Isaac, B., and West, W. R. (2000) NAGPRA at 10: Examining a decade of the Native American Graves Protection and Repatriation Act. *Museum News* 79:42–49, 67–75.
- Loth, S. R. (1995) Age Assessment of the Spitalfields Cemetery Population by Rib Phase Analysis. *American Journal of Human Biology* 7:465–471.
- Loth, S. R., and Henneberg, M. (1996) Mandibular ramus flexure: A new morphologic indicator of sexual dimorphism in the human skeleton. *American Journal of Physical Anthropology* 99:473–485.
- Loth, S. R., and Henneberg, M. (1998) Mandibular ramus flexure is a good indicator of sexual dimorphism. *American Journal of Physical Anthropology* 105:91–92.
- Loth, S. R., and Henneberg, M. (2000) Gonial eversion: Facial architecture, not sex. *Homo* 51:81–89.
- Loth, S. R., and Henneberg, M. (2001) Sexually dimorphic mandibular morphology in the first few years of life. *American Journal of Physical Anthropology* 115:179–186.
- Loth, S. R., İscan, M. Y., and Scheuerman, E. H. (1994) Intercostal variation at the sternal end of the rib. *Forensic Science International* 65:135–143.
- Lovejoy, C. O. (1978) A biomechanical review of the locomotor diversity of early hominids. In: C. J. Jolly (Ed.) *Early hominids of Africa*. Pp. 403–429. London, UK: Duckworth.
- Lovejoy, C. O. (1985) Dental wear in the Libben population: Its functional pattern and role in the determination of adult skeletal age at death. *American Journal of Physical Anthropology* 68:47–56.
- Lovejoy, C. O. (1988) Evolution of human walking. *Scientific American* 256:118–125.
- Lovejoy, C. O., and Barton, T. J. (1980) A simple, rapid method of obtaining geometrical properties from sections of laminograms of long bones. *Journal of Biomechanics* 13:65–67.
- Lovejoy, C. O., and Burstein, A. H. (1977) Geometrical properties of bone sections determined by laminography and physical section. *Journal of Biomechanics* 10:527–528.
- Lovejoy, C. O., Burstein, A. H., and Heiple, K. G. (1976) The biomechanical analysis of bone strength: A method and its application to platycnemia. *American Journal of Physical Anthropology* 44:489–506.
- Lovejoy, C. O., and Heiple, K. G. (1981) The analysis of fractures in skeletal populations with an example from the Libben Site, Ottawa County, Ohio. *American Journal of Physical Anthropology* 55:529–541.
- Lovejoy, C. O., Latimer, B., Suwa, G., Asfaw, B., and White, T. D. (2009a) Combining prehension and propulsion: The foot of *Ardipithecus ramidus*. *Science* 326:72, 72e1–72e8.
- Lovejoy, C. O., McCollum, M. A., Reno, P. L., and Rosenman, B. A. (2003) Developmental biology and human evolution. *Annual Review of Anthropology* 32:85–109, C1–C4.
- Lovejoy, C. O., Meindl, R. S., Mensforth, R. P., and Barton, T. J. (1985a) Multifactorial determination of skeletal age at death: A method and blind tests of its accuracy. *American Journal of Physical Anthropology* 68:1–14.
- Lovejoy, C. O., Meindl, R. S., Pryzbeck, T. R., Barton, T. S., Heiple, K. G., and Kotting, D. (1977) The palaeodemography of the Libben Site, Ottawa County, Ohio. *Science* 198:291–293.

- Lovejoy, C. O., Meindl, R. S., Pryzbeck, T. R., and Mensforth, R. P. (1985b) Chronological metamorphosis of the auricular surface of the ilium: A new method for the determination of adult skeletal age at death. *American Journal of Physical Anthropology* 68:15–28.
- Lovejoy, C. O., Meindl, R. S., Tague, R. G., and Latimer, B. (1997) The comparative senescent biology of the hominoid pelvis and its implications for the use of age-at-death indicators in the human skeleton. In: R. Paine (Ed.) *Integrating archaeological demography: Multidisciplinary approaches to prehistoric population*. Pp. 43–63. Carbondale, IL: Center for Archaeological Investigations, Southern Illinois University.
- Lovejoy, C. O., Meindl, R. S., Tague, R. G., and Latimer, B. (1995) The senescent biology of the hominoid pelvis. *Rivista di Antropologia (Roma)* 73:31–49.
- Lovejoy, C. O., Simpson, S. W., White, T. D., Asfaw, B., and Suwa, G. (2009b) Careful climbing in the Miocene: The forelimbs of *Ardipithecus ramidus* and humans are primitive. *Science* 326:70, 70e1–70e8.
- Lovejoy, C. O., Suwa, G., Simpson, S. W., Matternes, J. H., and White, T. D. (2009c) The great divides: *Ardipithecus ramidus* reveals the postcrania of our last common ancestors with African apes. *Science* 326:73, 100–106.
- Lovejoy, C. O., Suwa, G., Spurrlock, L., Asfaw, B., and White, T. D. (2009d) The pelvis and femur of *Ardipithecus ramidus*: The emergence of upright walking. *Science* 326:71, 71e1–71e6.
- Lovell, N. C. (1989) Test of Phenice's technique for determining sex from the os pubis. *American Journal of Physical Anthropology* 79:117–120.
- Lovell, N. C. (2000) Paleopathological description and diagnosis. In: M. A. Katzenberg and S. R. Saunders (Eds.) *Biological anthropology of the human skeleton* (1st ed.). Pp. 217–248. New York, NY: Wiley-Liss.
- Lovell, N. C. (2008) Analysis and interpretation of skeletal trauma. In: M. A. Katzenberg and S. R. Saunders (Eds.) *Biological anthropology of the human skeleton* (2nd ed.). Pp. 341–386. New York, NY: Wiley-Liss.
- Louchart, A., Wesselman, H., Blumenschine, R. J., Hlusko, L. J., Njau, K., Black, M. T., Asnake, M., and White, T. D. (2009) Taphonomic, avian, and small-vertebrate indicators of *Ardipithecus ramidus* habitat. *Science*, 326:66, e61–e64.
- Lucy, D. (1996) *Human age estimation from skeletal and dental evidence: The theories and practice of adult human age estimation focusing on the application of non-parametric likelihood estimation techniques to continuous and discrete data types*. Ph.D. thesis. Bradford, UK: University of Bradford. 161 pp.
- Lukacs, J. R. (1989) Dental pathology: Methods for reconstructing dietary patterns. In: M. Y. İşcan and K. A. R. Kennedy (Eds.) *Reconstruction of life from the skeleton*. Pp. 261–286. New York, NY: Alan R. Liss.
- Lukacs, J. R. (2008) Fertility and agriculture accentuate sex differences in dental caries rates. *Current Anthropology* 49:901–914.
- Lyman, R. L. (1994) *Vertebrate taphonomy*. Cambridge, UK: Cambridge University Press. 524 pp.
- Lyman, R. L. (2008) *Quantitative paleozoology*. New York, NY: Cambridge University Press. 348 pp.
- Lyman, R. L., and Fox, G. L. (1989) A critical evaluation of bone weathering as an indication of bone assemblage formation. *Journal of Archaeological Science* 16:293–317.
- Lyman, R. L., and Fox, G. L. (1997) A critical evaluation of bone weathering as an indication of bone assemblage formation. In: W. D. Haglund and M. H. Sorg (Eds.) *Forensic taphonomy: The postmortem fate of human remains*. Pp. 223–247. Boca Raton, FL: CRC Press.
- Lyman, R. L., and VanPool, T. L. (2009) Metric data in archaeology: A study of intra-analyst and inter-analyst variation. *American Antiquity* 74:485–504.
- Lynnerup, N., Fröhlich, B., and Thomsen, J. L. (2006) Assessment of age at death by microscopy: Unbiased quantification of secondary osteons in femoral cross sections. *Forensic Science International* 159 Suppl 1:S100–203.
- Lynnerup, N., Hjalgrim, H., Nielsen, L. R., Gregersen, H., and Thuesen, I. (1997) Non-invasive archaeology of skeletal material by CT scanning and three-dimensional reconstruction. *International Journal of Osteoarchaeology* 7:91–94.
- Lynott, M. J. (1997) Ethical principles and archaeological practice: development of an ethics policy. *American Antiquity* 62:589–599.
- Ma, P. H., and Teaford, M. F. (2010) Diet reconstruction in antebellum Baltimore: Insights from dental microwear analysis. *American Journal of Physical Anthropology* 141:571–582.
- Maat, G. J. R. (1981) Human remains at the Dutch whaling stations on Spitsbergen. In: A. G. F. van Holk, H. K. s' Jacob, and A. A. Temming (Eds.) *Early European exploitation of the northern Atlantic, 800–1700*. Pp. 153–201. Groningen, The Netherlands: Arctic Centre, University of Groningen.
- Maat, G. J. R. (1984) Dating and rating of Harris's lines. *American Journal of Physical Anthropology* 63:291–299.
- Maat, G. J. R. (1987) Osteology of human remains from Amsterdamøya and Ytre Norskøya. *Norsk Polarinstittutt Rapportserie* 38:35–55.
- Maat, G. J. R. (2004) Scurvy in adults and youngsters, the Dutch experience: A review of the history and pathology of a disregarded disease. *International Journal of Osteoarchaeology* 14:77–81.

- Maat, G. J. R., Maes, A., Aarents, M. J., and Nagelkerke, N. J. D. (2006) Histological age prediction from the femur in a contemporary Dutch sample: The decrease of nonremodeled bone in the anterior cortex. *Journal of Forensic Sciences* 51:230–237.
- Macchiarelli, R., and Bondioli, L. (1994) Linear densitometry and digital image processing of proximal femur radiographs: Implications for archaeological and forensic anthropology. *American Journal of Physical Anthropology* 93:109–122.
- Macchiarelli, R., Bondioli, L., Censi, L., Hernaez, M. K., Salvadei, L., and Sperduti, A. (1994) Intra- and inter-observer concordance in scoring Harris lines: A test on bone sections and radiographs. *American Journal of Physical Anthropology* 95:77–83.
- MacLaughlin, S. M., and Bruce, M. F. (1990) The accuracy of sex identification in European skeletal remains using the Phenice characters. *Journal of Forensic Sciences* 35:1384–1392.
- Mafart, B., and Delingette, H. (Eds.) (2002) *Three-dimensional imaging in paleoanthropology and prehistoric archaeology*. (B.A.R. International Series 1049). Oxford, UK: British Archaeological Reports. 108 pp.
- Mafart, B., Guipert, G., de Lumley, M.-A., and Subsol, G. (2004) Three-dimensional computer imaging of hominid fossils: A new step in human evolution studies. *Canadian Association of Radiologists Journal* 55:264–270.
- Mahoney, P. (2006) Dental microwear from Natufian hunter-gatherers and early Neolithic farmers: Comparisons within and between samples. *American Journal of Physical Anthropology* 130:308–319.
- Mahoney, P. (in press) Human deciduous mandibular molar incremental enamel development. *American Journal of Physical Anthropology* Early view: www.interscience.wiley.com, DOI: 10.1002/ajpa.21386.
- Malakoff, D. (2000) Columbus, syphilis, and English monks. *Science* 289:723.
- Manhein, M. H., Listi, G. A., and Leitner, M. (2006) The application of geographic information systems and spatial analysis to assess dumped and subsequently scattered human remains. *Journal of Forensic Sciences* 51:469–474.
- Manisty, E., and Smith, J. (2010) The deaccessioning of objects from public institutions: Legal and related considerations. *Art Antiquity and Law* 15:1–74.
- Mann, A., and Monge, J. (1987) Reproducing our ancestors. *Expedition: The University of Pennsylvania University Museum Magazine of Archaeology* 29:2–9.
- Mann, R. W. (1993) Technical note: A method for siding and sequencing human ribs. *Journal of Forensic Sciences* 38:151–155.
- Mann, R. W., and Hunt, D. R. (2005) *Photographic regional atlas of bone disease: A guide to pathologic and normal variation in the human skeleton*. Springfield, IL: C. C. Thomas. 297 pp.
- Mann, R. W., Jantz, R. L., Bass, W. M., and Willey, P. S. (1991) Maxillary suture obliteration: A visual method for estimating skeletal age. *Journal of Forensic Sciences* 36:781–791.
- Manolis, S. K., Eliopoulos, C., Koiliias, C. G., and Fox, S. C. (2009) Sex determination using metacarpal biometric data from the Athens Collection. *Forensic Science International* 193:130.e1–130.e6.
- Maples, W. R. (1986) Trauma analysis by the forensic anthropologist. In: K. J. Reichs (Ed.) *Forensic osteology: Advances in the identification of human remains* (1st ed.). Pp. 218–228. Springfield, IL: C. C. Thomas.
- Maples, W. R., and Browning, M. (1994) *Dead men do tell tales*. New York, NY: Doubleday.
- Marcus, R., Feldman, D., Nelson, D. A., and Rosen, C. J. (2008) *Osteoporosis* (3rd ed.), in 2 vols. San Diego, CA: Elsevier Academic Press. 2016 pp.
- Marks, J. (1996) Science and race. *American Behavioral Scientist* 40:123–133.
- Martin, B. D., Thorpe, D., Barnes, R., DeLeon, M., and Hill, D. (2009) Frequency in usage of FCAT-approved anatomical terms by North American anatomists. *Anatomical Sciences Education* 2:94–106.
- Martin, B. D., Thorpe, D., Merenda, V., Finch, B., Anderson-Smith, W., and Consiglio-Lahti, Z. (2010) Contrast in usage of FCAT-approved anatomical terminology between members of two anatomy associations in North America. *Anatomical Sciences Education* 3:25–32.
- Martin, D. L., and Frayer, D. W. (Eds.) (1997) *Troubled times: Violence and warfare in the past*. New York, NY: Gordon and Breach. 376 pp.
- Martin, D. L., Goodman, A. H., and Armelagos, G. J. (1985) Skeletal pathologies as indicators of quality and quantity of diet. In: R. I. Gilbert and J. H. Meikle (Eds.) *The analysis of prehistoric diets*. Pp. 227–279. Orlando, FL: Academic Press.
- Martin, E. J. (1960) Incidence of bifidity and related rib abnormalities in Samoans. *American Journal of Physical Anthropology* 18:179–187.
- Martin, R. (1928) *Lehrbuch der Anthropologie in Systematischer Darstellung mit Besonderer Berücksichtigung der anthropologischen Methoden für Studierende, Ärzte und Forschungsreisende, vol. 2: Kraniologie, Osteologie*. Jena, Germany: Gustav Fischer. 580 pp.
- Martin, R., and Saller, K. (1957) *Lehrbuch der Anthropologie in Systematischer Darstellung mit besonderer Berücksichtigung der anthropologischen Methoden für Studierende, Ärzte und Forschungsreisende, vol. 1*. Stuttgart, Germany: Gustav Fischer. 661 pp.

- Matos, V. (2009) Broken ribs: Paleopathological analysis of costal fractures in the human identified skeletal collection from the Museu Bocage, Lisbon, Portugal (late 19th to middle 20th centuries). *American Journal of Physical Anthropology* 140:25–38.
- Matsches, E. W., Burbridge, B., Sher, B., Mohamed, A., and Juurlink, B. (2004) *Human osteology & skeletal radiology: An atlas and guide*. Boca Raton, FL: CRC Press. 448 pp.
- Matsumoto, K., Li, Y., Jakuba, C., Sugiyama, Y., Sayo, T., Okuno, M., Dealy, C. N., Toole, B. P., Takeda, J., Yamaguchi, Y., and Kosher, R. A. (2009) Conditional inactivation of Has2 reveals a crucial role for hyaluronan in skeletal growth, patterning, chondrocyte maturation and joint formation in the developing limb. *Development* 136:2825–2835.
- Mayhall, J. T. (2000) Dental morphology: Techniques and strategies. In: M. A. Katzenberg and S. R. Saunders (Eds.) *Biological anthropology of the human skeleton* (1st ed.). Pp. 103–134. New York, NY: Wiley-Liss.
- Mayhall, J. T., and Kageyamu, I. (1997) A new, three-dimensional method for determining tooth wear. *American Journal of Physical Anthropology* 103:463–469.
- Mays, S. (1998) *The archaeology of human bones* (1st ed.). London, UK: Routledge. 256 pp.
- Mays, S. (2002) The relationship between molar wear and age in an early 19th century AD archaeological human skeletal series of documented age at death. *Journal of Archaeological Science* 29:861–871.
- Mays, S. (2008) Septal aperture of the humerus in a mediaeval human skeletal population. *American Journal of Physical Anthropology* 136:432–440.
- Mays, S. (2010) *The archaeology of human bones* (2nd ed.). London, UK: Routledge. 432 pp.
- Mays, S., and Cox, M. (2000) Sex determination in skeletal remains. In: M. Cox and S. Mays (Eds.) *Human osteology in archaeology and forensic science*. Pp. 117–130. London, UK: Greenwich Medical Media, Ltd.
- Mays, S., Crane-Kramer, G., and Bayliss, A. (2003) Two probable cases of treponemal disease of medieval date from England. *American Journal of Physical Anthropology* 120:133–143.
- Mays, S., Taylor, G. M., Legge, A. J., Young, D. B., and Turner-Walker, G. (2001) Paleopathological and bimolecular study of tuberculosis in a medieval skeletal collection from England. *American Journal of Physical Anthropology* 114:298–311.
- McCown, T. D., and Keith, A. (1939) *The Stone Age of Mount Carmel, vol. 2: The fossil human remains from the Levallois-Mousterian*. Oxford, UK: Clarendon Press.
- McGuire, R. (1989) The sanctity of the grave: White concepts and American Indian burials. In: R. Layton (Ed.) *Conflict in the archaeology of living traditions*. Pp. 167–184. London, UK: Unwin Hyman.
- McKee, J. K., and Molnar, S. (1988) Measurements of tooth wear among Australian Aborigines. II. Intrapopulation variation in patterns of dental attrition. *American Journal of Physical Anthropology* 76:125–136.
- McKern, T. W., and Stewart, T. D. (1957) *Skeletal age changes in young American males: Analyzed from the standpoint of age identification*. Natick, MA: Quartermaster Research and Development Command Technical Report EP-45. 188 pp.
- McPherron, S. P., Alemseged, Z., Marean, C. W., Wynn, J. G., Reed, D., Geraads, D., Bobe, R., and Béarat, H. A. (2010) Evidence for stone-tool-assisted consumption of animal tissues before 3.39 million years ago at Dikika, Ethiopia. *Nature* 466:857–860.
- Mead, E. M., and Meeks, S. (1989) Photography of archaeological and paleontological bone specimens. In: R. Bonnichsen and M. H. Sorg (Eds.) *Bone modification*. Pp. 267–281. Orono, ME: Center for the Study of the First Americans.
- Meighan, C. W. (1992) Some scholar's views on reburial. *American Antiquity* 57:704–710.
- Meindl, R. S., and Lovejoy, C. O. (1985) Ectocranial suture closure: A revised method for the determination of skeletal age at death based on the lateral-anterior sutures. *American Journal of Physical Anthropology* 68:57–66.
- Meindl, R. S., Lovejoy, C. O., Mensforth, R. P., and Walker, R. A. (1985a) A revised method of age determination using the os pubis, with a review and tests of accuracy of other current methods of pubic symphyseal aging. *American Journal of Physical Anthropology* 68:29–45.
- Meindl, R. S., Lovejoy, C. O., Mensforth, R. P., and Don Carlo, L. (1985b) Accuracy and direction of error in the sexing of the skeleton: Implications for paleodemography. *American Journal of Physical Anthropology* 68:79–85.
- Meindl, R. S., Mensforth, R. P., and Lovejoy, C. O. (2008) The Libben Site, a hunting, fishing, and gathering village from the eastern Late Woodlands of North America: Analysis and implications for palaeodemography and human origins. In: J.-P. Bocquet-Appel (Ed.) *Recent advances in palaeodemography: Data, techniques, patterns*. Pp. 259–275. Dordrecht, Netherlands: Springer.
- Melbye, J., and Jimenez, S. B. (1997) Chain of custody from the field to the courtroom. In: W. D. Haglund and M. H. Sorg (Eds.) *Forensic taphonomy: The postmortem fate of human remains*. Pp. 65–75. Boca Raton, FL: CRC Press.
- Mellars, P., Boyle, K., Bar-Yosef, O., and Stringer, C. (Eds.) (2007) *Rethinking the human revolution: New behavioural and biological perspectives on the origin and dispersal of modern humans*. Oakville, CT: McDonald

- Institute for Archaeological Research. 436 pp.
- Mellars, P., and Stringer, C. (Eds.) (1989) *The human revolution: Behavioural and biological perspectives on the origins of modern humans*. Princeton, NJ: Princeton University Press. 232 pp.
- Mensforth, R. P., and Lovejoy, C. O. (1985) Anatomical, physiological, and epidemiological correlates of the aging process: A confirmation of multifactorial age determination in the Libben skeletal population. *American Journal of Physical Anthropology* 68:87–106.
- Mensforth, R. P., Lovejoy, C. O., Lallo, J. W., and Armelagos, G. J. (1978) The role of constitutional factors, diet, and infectious disease in the etiology of porotic hyperostosis and periosteal reactions in prehistoric infants and children. *Medical Anthropology* 2:1–59.
- Merbs, C. F. (1983) Patterns of activity-induced pathology in a Canadian Inuit population. *Archaeological Survey of Canada, Paper No. 119*. (National Museum of Man, Mercury series). Ottawa, Canada: National Museums of Canada. 200 pp.
- Micozzi, M. S. (1991) *Postmortem change in human and animal remains*. Springfield, IL: C. C. Thomas. 124 pp.
- Mihesuah, D. A. (1996) American Indians, anthropologists, pothunters, and repatriation: Ethical, religious, and political differences. *American Indian Quarterly* 20:229–237.
- Miles, A. E. W. (1963) Dentition in the estimation of age. *Journal of Dental Research* 42:255–263.
- Miles, A. E. W. (2001) The Miles method of assessing age from tooth wear revisited. *Journal of Archaeological Science* 28:973–982.
- Miller, E., Ragsdale, B. D., and Ortner, D. J. (1996) Accuracy in dry bone diagnosis: A comment on palaeopathological methods. *International Journal of Osteoarchaeology* 6:221–229.
- Milner, G. R., and Larsen, C. S. (1991) Teeth as artifacts of human behavior: Intentional modification and accidental modification. In: M. A. Kelley and C. S. Larsen (Eds.) *Advances in dental anthropology*. Pp. 357–378. New York, NY: Wiley-Liss.
- Milner, G. R., Wood, J. W., and Boldsen, J. L. (2000) Paleodemography. In: M. A. Katzenberg and S. R. Saunders (Eds.) *Biological anthropology of the human skeleton* (1st ed.). Pp. 467–497. New York, NY: Wiley-Liss.
- Mincer, H. H., Berryman, H. E., Murray, G. A., and Dickens, R. L. (1990) Technical note: Methods for physical stabilization of ashed teeth in incinerated remains. *Journal of Forensic Sciences* 35:971–974.
- Mincer, H. H., Harris, E. F., and Berryman, H. E. (1993) The A.B.F.O. study of third molar development and its use as an estimator of chronological age. *Journal of Forensic Sciences* 38:379–390.
- Misner, L. M., Halvorson, A. C., Dreier, J. L., Ubelaker, D. H., and Foran, D. R. (2009) The correlation between skeletal weathering and DNA quality and quantity. *Journal of Forensic Sciences* 54:822–828. Erratum in: *Journal of Forensic Sciences* 54:1502.
- Mizoguchi, Y. (1985) Shovelling: A statistical analysis of its morphology. *Bulletin, University of Tokyo Museum* 26:1–176.
- Moeller, T., and Reif, E. (2009) *Atlas of sectional anatomy: The musculoskeletal system*. New York, NY: Thieme. 300 pp.
- Molnar, S. (1971) Human tooth wear, tooth function, and cultural variability. *American Journal of Physical Anthropology* 34:175–190.
- Molnar, P. (2008) Dental wear and oral pathology: possible evidence and consequences of habitual use of teeth in a Swedish Neolithic sample. *American Journal of Physical Anthropology* 136:423–431.
- Monge, J., and Mann, A. (2007) Paleodemography of extinct hominin populations. In W. Henke and I. Tattersall (Eds.) *Handbook of Paleoanthropology, volume 1*. Pp. 673–700. New York, NY: Springer-Verlag.
- Montiel, R., Garcia, C., Canadas, M. P., Isidro, A., Guijo, J. M., and Malgosa, A. (2003) DNA sequences of *Mycobacterium leprae* recovered from ancient bones. *FEMS Microbiology Letters* 226:413–414.
- Moore, J. A. (1999) *Science as a way of knowing: The foundations of modern biology*. Cambridge, MA: Harvard University Press. 544 pp.
- Moore-Jansen, P. H., Ousley, S. D., and Jantz, R. L. (1994) *Data collection procedures for forensic skeletal material (3rd ed.)*. Report of Investigations No. 48. Knoxville, TN: University of Tennessee. 78 pp.
- Mori, J. L. (1970) Procedures for establishing a faunal collection to aid in archaeological analysis. *American Antiquity* 35:387–389.
- Morell, V. (1998) Kennewick Man's trials continue. *Science* 280:190–192.
- Morton, R. A. (Ed.) (1984) *Photography for the scientist* (2nd ed.). London, UK: Academic Press. 542 pp.
- Mulhern, D. M., and Jones, E. B. (2004) Test of revised method of age estimation from the auricular surface of the ilium. *American Journal of Physical Anthropology* 126:61–65.
- Müller, W., Fricke, H., Halliday, A. N., McCulloch, M. T., and Wartho, J. (2003) Origin and migration of the alpine iceman. *Science* 302:862–866.
- Müller, W. A. (1997) *Developmental biology*. New York, NY: Springer. 382 pp.
- Mulligan, C. J. (2005) Isolation and analysis of DNA from archaeological, clinical, and natural history specimens. *Methods in Enzymology* 395:87–103.

- Mullis, K. B., and Faloona, F. (1987) Specific synthesis of DNA in vitro via a polymerase-catalyzed chain reaction. *Methods in Enzymology* 155:335–350.
- Murray, K. A., and Murray, T. (1991) A test of the auricular surface aging technique. *Journal of Forensic Sciences* 36:1162–1169.
- Naito, Y. I., Honch, N. V., Chikaraishi, Y., Ohkouchi, N., and Yoneda, M. (2010) Quantitative evaluation of marine protein contribution in ancient diets based on nitrogen isotope ratios of individual amino acids in bone collagen: An investigation at the Kitakogane Jomon site. *American Journal of Physical Anthropology* 143:31–40.
- NAPA (1988) *Ethical guidelines for practitioners*. National Association for the Practice of Anthropology.
- Napoli, M. L., and Birkby, W. H. (1990) Racial differences in the visibility of the oval window in the middle ear. In: G. W. Gill and S. Rhine (Eds.) *Skeletal attribution of race: Methods for forensic anthropology* (Anthropological Papers Number 4). Pp. 27–32. Albuquerque, NM: Maxwell Museum of Anthropology.
- National Academy of Sciences (NAS), Committee on Ensuring the Utility and Integrity of Research Data in a Digital Age (2009) *Ensuring the integrity, accessibility, and stewardship of research data in the digital age*. Washington, DC: The National Academies Press. 180 pp.
- Navascués, M., Depaulis, F., and Emerson, B. C. (2010) Combining contemporary and ancient DNA in population genetic and phylogeographical studies. *Molecular Ecology Resources* 10:760–772.
- Nawrocki, S. P. (1995) Taphonomic processes in historic cemeteries. In: A. L. Grauer (Ed.) *Bodies of evidence: Reconstructing history through skeletal analysis*. Pp. 49–66. New York, NY: Wiley-Liss.
- Neave, R. (2000) Forensic and archaeological reconstruction of the human face upon the skull. In: M. Cox and S. Mays (Eds.) *Human osteology in archaeology and forensic science*. Pp. 325–333. London, UK: Greenwich Medical Media, Ltd.
- Nelson, S. J. (2009) *Wheeler's dental anatomy, physiology and occlusion* (9th ed.). St. Louis, MO: Saunders/Elsevier. 368 pp.
- Netter, F. H. (2006) *Atlas of human anatomy* (4th ed.). Philadelphia, PA: Saunders/Elsevier. 548 pp.
- Netter, F. H. (2010) *Atlas of human anatomy* (5th ed.). Philadelphia, PA: Saunders/Elsevier. 624 pp.
- Nicholson, G. J., Tomiuk, J., Czarnetzki, A., Bachmann, L., and Pusch, C. M. (2002) Detection of bone glue treatment as a major source of contamination in ancient DNA analyses. *American Journal of Physical Anthropology* 117:397–309.
- Nielsen-Marsh, C., Gernaey, A., Turner-Walker, G., Hedges, R., Pike, A., and Collins, M. (2000) The chemical degradation of bone. In: M. Cox and S. Mays (Eds.) *Human osteology in archaeology and forensic science*. Pp. 439–454. London, UK: Greenwich Medical Media, Ltd.
- Njau, J. K., and Blumenschine, R. J. (2006) A diagnosis of crocodile feeding traces on larger mammal bone, with fossil examples from the Plio-Pleistocene Olduvai Basin, Tanzania. *Journal of Human Evolution* 50:142–162.
- NMNH (n.d.) Physical Anthropology Collections. *Smithsonian (National Museum of Natural History), Department of Anthropology website*. Accessed 2010 Aug 30. Available from: http://anthropology.si.edu/cm/phys_intro.htm.
- Nordby, J. J. (1992) Can we believe what we see, if we see what we believe? Expert disagreement. *Journal of Forensic Sciences* 37:1115–1124.
- Novotný, V., İscan, M. Y., and Loth, S. R. (1993) Morphological and osteometric assessment of age, sex, and race from the skull. In: M. Y. İscan and R. P. Helmer (Eds.) *Forensic analysis of the skull*. Pp. 71–88. New York, NY: Wiley-Liss.
- Ochani, S. C., Ahmad, A. M., and Malik, F. R. (2004) Modern grave robbers. *Student BMJ* 12:466–467.
- Odegaard, N., and Cassman, V. (2007) Treatment and invasive actions. In: V. Cassman, N. Odegaard, and J. Powell (Eds.) *Human remains: Guide for museums and academic institutions*. Pp. 77–95. Lanham, MD: Alta-Mira Press.
- Odwak, H., and Schulting, R. J. (1996) A simple technique for aiding the interpretation and enhancement of radiographs. *International Journal of Osteoarchaeology* 6:502–505.
- Oettlé, A. C., Pretorius, E., and Steyna, M. (2009) Geometric morphometric analysis of the use of mandibular gonial eversion in sex determination. *Homo* 60:29–43.
- Ogden, J. A. (1990) Histogenesis of the musculoskeletal system. In: D. J. Simmons (Ed.) *Nutrition and bone development*. Pp 3–36. New York, NY: Oxford University Press.
- Ogura, M., Al-Kalaly, A., Sakashita, R., Kamegai, T., and Miyawaki, S. (2006) Relationship between anteroposterior cranial vault deformation and mandibular morphology in a pre-Columbian population. *American Journal of Orthodontics and Dentofacial Orthopedics* 130:535–539.
- O'Higgins, P., Milne, N., Johnson, D. R., Rynnion, C. K., and Oxnard, C. E. (1997) Adaptation in the vertebral column: A comparative study of patterns of metameric variation in mice and men. *Journal of Anatomy* 190:105–113.
- Ohtani, S. (1995) Studies on age estimation using racemization of aspartic acid in cementum. *Journal of Forensic Sciences* 40:805–807.

- Ohtani, S., and Yamamoto, K. (1991) Age estimation using the racemization of amino acid in human dentin. *Journal of Forensic Sciences* 36:792–800.
- Ohtani, S., and Yamamoto, K. (1992) Estimation of age from a tooth by means of racemization of an amino acid, especially aspartic acid: Comparison of enamel and dentin. *Journal of Forensic Sciences* 37:1061–1067.
- Ohtani, S., and Yamamoto, T. (2005) Strategy for the estimation of chronological age using the aspartic acid racemization method with special reference to coefficient of correlation between D/L ratios and ages. *Journal of Forensic Sciences* 50:1–8.
- Okazaki, K. (2005) Sex assessment of subadult skeletons based on tooth crown measurements: An examination on the interpopulational variation of sex differences and an application to excavated skeletons. *Anthropological Science (Japanese Series)* 113:139–159.
- O'Loughlin, V. D. (2004) Effects of different kinds of cranial deformation on the incidence of wormian bones. *American Journal of Physical Anthropology* 123:146–155.
- Olejniczak, A. J., and Grine, F. E. (2006) Assessment of the accuracy of dental enamel thickness measurements using microfocal X-ray computed tomography. *The Anatomical Record Part A* 288A:263–275.
- Olejniczak, A. J., Tafforeau, P., Smith, T. M., Temming, H., and Hublin, J.-J. (2007) Technical note: Compatibility of microtomographic imaging systems for dental measurements. *American Journal of Physical Anthropology* 134:130–134.
- OMB (Office of Management and Budget) (1997) Directive 15: Race data, U.S. Census Bureau website. Accessed 2010 Oct 17. Available from http://www.census.gov/population/www/socdemo/race/Directive_15.html
- OMIM™: Online Mendelian Inheritance in Man (n.d.) McKusick-Nathans Institute of Genetic Medicine, Johns Hopkins University (Baltimore, MD) and National Center for Biotechnology Information, National Library of Medicine (Bethesda, MD). Accessed 2010 Aug 30. Available from: <http://www.ncbi.nlm.nih.gov/omim/>
- O'Rahilly, R. (1989) Anatomical terminology, then and now. *Acta Anatomica* 134:291–300.
- Orton, C. (2000) *Sampling in archaeology (Cambridge Manuals in Archaeology)*. New York, NY: Cambridge University Press. 261 pp.
- Ortner, D. J., and Aufderheide, A. C. (1991) *Human paleopathology: Current syntheses and future options*. Washington, DC: Smithsonian Institution Press. 311 pp.
- Ortner, D. J., and Putschar, W. G. J. (1981) *Identification of pathological conditions in human skeletal remains. (Smithsonian Contributions to Anthropology 28)*. Washington, DC: Smithsonian Institution Press.
- Ortner, D. J. (2003) *Identification of pathological conditions in human skeletal remains* (2nd ed.). San Francisco, CA: Elsevier/Academic Press. 645 pp.
- Osborne, D. L., Simmons, T. L., and Nawrocki, S. P. (2004) Reconsidering the auricular surface as an indicator of age of death. *Journal of Forensic Sciences* 49:1–7.
- Ossenberg, N. S. (1970) The influence of artificial cranial deformation on discontinuous morphological traits. *American Journal of Physical Anthropology* 33:375–382.
- Owsley, S. (1995) Should we estimate biological or forensic stature? *Journal of Forensic Sciences* 40:768–773.
- Owsley, S. D., Billeck, W. T., and Hollinger, R. E. (2005) Federal repatriation legislation and the role of physical anthropology in repatriation. *Yearbook of Physical Anthropology* 41:2–32.
- Owsley, S., and McKeown, A. (2001) Three dimensional digitizing of human skulls as an archival procedure. In: E. Williams (Ed.) *Human remains: Conservation, retrieval and analysis*. (B.A.R. International Series 934). Pp. 173–184. Oxford, UK: British Archaeological Reports.
- Outram, A. K., Knüsel, C. J., Knight, S., and Harding, A. F. (2005) Understanding complex fragmented assemblages of human and animal remains: a fully integrated approach. *Journal of Archaeological Science* 32:1699–1710.
- Overbury, R. S., Cabo, L. L., Dirkmaat, D. C., and Symes, S. A. (2009) Asymmetry of the os pubis: Implications for the Suchey-Brooks method. *American Journal of Physical Anthropology* 139:261–268.
- Owers, S. K., and Pastor, R. F. (2006) Analysis of quantitative methods for rib seriation using the Spitalfields documented skeletal collection. *American Journal of Physical Anthropology* 127:210–218.
- Owsley, D. W. (1993) Identification of the fragmentary, burned remains of two U.S. journalists seven years after their disappearance in Guatemala. *Journal of Forensic Sciences* 38:1372–1382.
- Owsley, D. W. (2001) Why the forensic anthropologist needs the archaeologist. *Historical Archaeology* 35:35–38.
- Owsley, D. W., and Mann, R. W. (1992) Positive personal identity of skeletonized remains using abdominal and pelvic radiographs. *Journal of Forensic Sciences* 37:332–336.
- Owsley, D. W., Mann, R. W., Chapman, R. E., Moore, E., and Cox, W. (1993) Positive identification in a case of intentional extreme fragmentation. *Journal of Forensic Sciences* 38:985–996.
- Owsley, D. W., Ubelaker, D. H., Houck, M. M., Sandness, K. L., Grant, W. E., Craig, E. A., Woltanski, T. J., and Peerwani, N. (1995) The role of forensic anthropology in the recovery and analysis of Branch Duvian compound victims: Techniques of analysis. *Journal of Forensic Sciences* 40:341–348.

- Oxenham, M. (Ed.) (2008) *Forensic approaches to death, disaster, and abuse*. Bowen Hills, Australia: Australian Academic Press. 316 pp.
- Oygucu, I. H., Kurt, M. A., Ikiz, I., Erem, T., and Davies, D. C. (1998) Squatting facets on the neck of the talus and extensions of the trochlear surface of the talus in late Byzantine males. *Journal of Anatomy* 192:287–291.
- Oztunc, H., Yoldas, O., and Nalbantoglu, E. (2006) The periodontal disease status of the historical population of Assos. *International Journal of Osteoarchaeology* 16:76–81.
- Pääbo, S. (1985) Molecular cloning of ancient Egyptian mummy DNA. *Nature* 314:644–645.
- Pääbo, S., Poinar, H., Serre, D., Jaenicke-Deprés, Hebler, J., Rohland, N., Kurch, M., Krause, J., Vigilant, L., and Hofreiter, M. (2004) Genetic analyses from ancient DNA. *Annual Review of Genetics* 38:645–679.
- Paine, R. R., and Godfrey, L. R. (1997) The scaling of skeletal microanatomy in non-human primates. *Journal of Zoology, London* 241:803–821.
- Paine, R. R., and Brenton, B. P. (2006) Dietary health does affect histological age assessment: An evaluation of the Stout and Paine (1992) age estimation equation using secondary osteons from the rib. *Journal of Forensic Sciences* 51:489–492.
- Pálfi, G., Dutour, O., Bérato, J., and Brun, J.-P. (2000) La syphilis en Europe dans l'Antiquité: Le fœtus de Costebelle et les autres nouvelles données ostéoarchéologiques. *Vesalius* 6:55–63.
- Pálfi, G. Y., Dutour, O., Borreani, M., Brun, J.-P., and Bérato J. (1992) Pre-Columbian congenital syphilis from late antiquity in France. *International Journal of Osteoarchaeology* 2:245–261.
- Palkovich, A. M. (1987) Endemic disease patterns in paleopathology: Porotic hyperostosis. *American Journal of Physical Anthropology* 74:527–537.
- Parker Pearson, M. (2001) *The archaeology of death and burial*. College Station, TX: Texas A&M University Press. 250 pp.
- Parsons, T. J., and Weedn, V. W. (1997) Preservation and recovery of DNA in postmortem specimens and trace samples. In: W. D. Haglund and M. H. Sorg (Eds.) *Forensic taphonomy: The postmortem fate of human remains*. Pp. 109–138. Boca Raton, FL: CRC Press.
- Pavón, M. V., Cucina, A., and Tiesler, V. (2010) New formulas to estimate age at death in maya populations using histomorphological changes in the fourth human rib. *Journal of Forensic Sciences* 55:473–477.
- Pearson, H. (2005) Image manipulation: CSI—cell biology. *Nature* 434:952–953.
- Pennisi, E. (2006) The dawn of stone age genomics. *Science* 314:1068–1071.
- Petersen, L. R., Marshall, S. L., Barton-Dickson, C., Hajjeh, R. A., Lindsley, M. D., Warnock, D. W., Panackal, A. A., Shaffer, J. B., Haddad, M. B., Fisher, F. S., Dennis, D. T., and Morgan, J. (2004) Coccidioidomycosis among workers at archeological site, northeastern Utah. *Emerging Infectious Diseases* [serial online]. Accessed 2010 Aug 30. Available from: <http://www.cdc.gov/ncidod/EID/vol10no4/03-0446.htm>
- Pfau, R. O., and Sciulli, P. W. (1994) A method for establishing the age of subadults. *Journal of Forensic Sciences* 39:165–176.
- Pfeiffer, S., Lazenby, R., and Chang, J. (1995) Brief communication: Cortical remodeling data are affected by sampling location. *American Journal of Physical Anthropology* 96:89–92.
- Phenice, T. W. (1969) A newly developed visual method of sexing in the *os pubis*. *American Journal of Physical Anthropology* 30:297–301.
- Pickering, R. B., and Bachman, D. C. (1997) *The use of forensic anthropology*. Boca Raton, FL: CRC Press. 170 pp.
- Pickering, T. R., and Egeland, C. P. (2006) Experimental patterns of hammerstone percussion damage on bones: Implications for inferences of carcass processing by humans. *Journal of Archaeological Science* 33:459–469.
- Pietrusewsky, M. (2000) Metric analysis of skeletal remains: Methods and applications. In: M. A. Katzenberg and S. R. Saunders (Eds.) *Biological anthropology of the human skeleton* (1st ed.). Pp. 375–415. New York, NY: Wiley-Liss.
- Pietrusewsky, M. (2002) *Ban Chiang, a prehistoric village site in northeast Thailand, vol. 1: The human skeletal remains*. Philadelphia, PA: University of Pennsylvania Museum of Archaeology and Anthropology. 493 pp.
- Pietrusewsky, M. (2008) Metric analysis of skeletal remains: Methods and applications. In: M. A. Katzenberg and S. R. Saunders (Eds.) *Biological anthropology of the human skeleton* (2nd ed.). Pp. 487–532. New York, NY: Wiley-Liss.
- Pijoan, C. M., Mansilla, J., Leboeiro, I., Lara, V. H., and Bosch, P. (2007) Thermal alterations in archaeological bones. *Archaeometry* 49:713–727.
- Pinhasi, R., and Mays, S. (Eds.) (2008) *Advances in human palaeopathology*. Hoboken, NJ: John Wiley and Sons. 408 pp.
- Poinar, H. N., Höss, M., Bada, J. L., and Pääbo, S. (1996) Amino acid racemization and the preservation of ancient DNA. *Science* 272:864–866.
- Pollanen, M. S., and Ubelaker, D. H. (1997) Forensic significance of the polymorphism of hyoid bone shape. *Journal of Forensic Sciences* 42:890–892.

- Pourquié, O. (2009) *The Skeletal System*. Cold Spring Harbor, NY: Cold Spring Harbor Laboratory Press. 550 pp.
- Powell, M. L. (1985) The analysis of dental wear and caries for dietary reconstruction. In: R. I. Gilbert and J. H. Meikle (Eds.) *The analysis of prehistoric diets*. Pp. 307–338. Orlando, FL: Academic Press.
- Powell, M. L., and Cook, D. C. (2005) *The myth of syphilis: the natural history of treponematoses in North America*. Gainesville, FL: University Press of Florida. 509 pp.
- Price, T. D. (1989) *The chemistry of prehistoric human bone*. New York, NY: Cambridge University Press. 291 pp.
- Primorac, D., Andelinovic, S., Definis-Gojanovic, M., Drmic, I., Rezac, B., Baden, M. M., Kennedy, M. A., Schanfield, M. S., Skakel, S. B., and Lee, H. C. (1996) Identification of war victims from mass graves in Croatia, Bosnia, and Herzegovina by the use of standard forensic methods and DNA typing. *Journal of Forensic Sciences* 41:891–894.
- Pruvost, M., Schwarz, R., Correia, V. B., Champlot, S., Braguier, S., Morel, N., Fernandez-Jalvo, Y., Grange, T., and Geigl, E.-M. (2007) Freshly excavated fossil bones are best for amplification of ancient DNA. *Proceedings of the National Academy of Sciences* 104:739–744.
- Pucciarelli, H. M. (1974) The influence of experimental deformation on neurocranial wormian bones in rats. *American Journal of Physical Anthropology* 41:29–38.
- Purkait, R. (2001) Measurements of ulna: A new method for determination of sex. *Journal of Forensic Sciences* 46:924–927.
- Putz, R., and Pabst, R. (Eds.) (2009) *Sobotta atlas of anatomy* (14th ed.). Munich Germany: Urban & Fischer Verlag/Elsevier.
- Radosevich, S. C. (1993) The six deadly sins of trace element analysis: A case of wishful thinking in science. In: M. K. Sandford (Ed.) *Investigations of ancient human tissue: Chemical analyses in anthropology*. Pp. 269–332. Langhorne, PA: Gordon and Breach Science Publishers, SA.
- Ramsthaler, F., Kettner, M., Gehl, A., and Verhoff, M. A. (2010) Digital forensic osteology: Morphological sexing of skeletal remains using volume-rendered cranial CT scans. *Forensic Science International* 195:148–152.
- Raoult, D., Aboudharam, G., Crubézy, E., Larrouy, G., Ludes, B., and Drancourt, M. (2000) Molecular identification by “suicide PCR” of *Yersinia pestis* as the agent of medieval Black Death. *Proceedings of the National Academy of Sciences, USA* 97:12800–12803.
- Rathburn, T. A., and Buikstra, J. E. (Eds.) (1984) *Human identification: Case studies in forensic anthropology*. Springfield, IL: C. C. Thomas. 435 pp.
- Rautman, A. E., and Fenton, T. W. (2005) A case of historic cannibalism in the American West: Implications for southwestern archaeology. *American Antiquity* 70:321–341.
- Reader, J. (1988) *Missing links: The hunt for earliest man* (2nd ed.). Middlesex, UK: Penguin Books. 288 pp.
- Reeves, N. M. (2009) Taphonomic effects of vulture scavenging. *Journal of Forensic Sciences* 54:523–528.
- Reichs, K. J. (Ed.) (1998) *Forensic osteology: Advances in the identification of human remains* (2nd ed.). Springfield, IL: C. C. Thomas. 567 pp.
- Reichs, K. J., and Craig, E. (1998) Facial approximation: Procedures and pitfalls. In: K. J. Reichs (Ed.) *Forensic osteology: Advances in the identification of human remains* (2nd ed.). Pp. 491–512. Springfield, IL: C. C. Thomas.
- Reinhard, K. J., and Danielson, D. R. (2005) Pervasiveness of phytoliths in prehistoric southwestern diet and implications for regional and temporal trends for dental microwear. *Journal of Archaeological Science* 32:981–988.
- Renne, P. R., WoldeGabriel, G., Hart, W. K., Heiken, G., and White, T. D. (1999) Chronostratigraphy of the Miocene-Pliocene Sagantole Formation, Middle Awash Valley, Afar Rift, Ethiopia. *Geological Society of America Bulletin* 111:869–885.
- Rennick, S. L., Fenton, T. W., and Foran, D. R. (2005) The effects of skeletal preparation techniques on DNA from human and non-human bone. *Journal of Forensic Sciences* 50:1016–1019.
- Resnick, D. (2002) *Diagnosis of bone and joint disorders, vols. 1–5* (4th ed.). Philadelphia, PA: Saunders. 5472 pp.
- Reyment, R. A., Blackith, R. E., and Campbell, N. A. (1984) *Multivariate morphometrics* (2nd ed.). London, UK: Academic Press. 233 pp.
- Reynard, L. M., and Hedges, R. E. M. (2008) Stable hydrogen isotopes of bone collagen in palaeodietary and palaeoenvironmental reconstruction. *Journal of Archaeological Science* 35:1934–1942.
- Rhine, S. (1990) Non-metric skull racing. In: G. W. Gill and S. Rhine (Eds.) *Skeletal attribution of race: Methods for forensic anthropology* (Anthropological Papers Number 4). Pp. 9–20. Albuquerque, NM: Maxwell Museum of Anthropology.
- Ricaut, F.-X., Auriol, V., von Cramon-Taubadel, N., Keyser, C., Murail, P., Ludes, B., and Crubézy, E. (2010) Comparison between morphological and genetic data to estimate biological relationship: The case of the Egyin Gol necropolis (Mongolia). *American Journal of Physical Anthropology* 143:355–364.
- Richards, G. D. (1985) Analysis of a microcephalic child from the Late Period (ca. 1100–1700 A.D.) of Central California. *American Journal of Physical Anthropology* 68:343–357.

- Richards, G. D., and Antón, S. C. (1991) Craniofacial configuration and postcranial development of a hydrocephalic child (ca. 2500 B.C.–A.D. 500): With a review of cases and comment on diagnostic criteria. *American Journal of Physical Anthropology* 85:185–200.
- Richards, G. D., and Antón, S. C. (1987) The Berkeley primate skeletal collection: A new resource for studies in paleopathology. *Paleopathology Newsletter* 57:8–11.
- Richards, L. C., and Miller, S. L. J. (1991) Relationships between age and dental attrition in Australian aboriginals. *American Journal of Physical Anthropology* 84:159–164.
- Richards, M., Harvati, K., Grimes, V., Smith, C., Smith, T., Hublin, J.-J., Karkanas, P., and Panagopoulou, E. (2008) Strontium isotope evidence of Neanderthal mobility at the site of Lakonis, Greece using laser-ablation PIMMS. *Journal of Archaeological Science* 35:1251–1256.
- Richards, M. P., Jacobi, R., Cook, J., Pettitt, P. B., and Stringer, C. B. (2005) Isotope evidence for the intensive use of marine foods by Late Upper Palaeolithic humans. *Journal of Human Evolution* 49:390–394.
- Richman, J. R., and Forsyth M. P. (Eds.) (2004) *Legal perspectives on cultural resources*. Walnut Creek, CA: AltaMira Press. 284 pp.
- Richtsmeier, J. T., Cheverud, J. M., and Lele, S. (1992) Advances in anthropological morphometrics. *Annual Reviews in Anthropology* 21:283–305.
- Richtsmeier, J. T., DeLeon, V. B., and Lele, S. R. (2002) The promise of geometric morphometrics. *Yearbook of Physical Anthropology* 119:63–91.
- Rios, L., Ovejero, C., Ignacio, J., and Puente Prieto, J. (2010) Identification process in mass graves from the Spanish Civil War I. *Forensic Science International* 199:E27–E36.
- Rivals, F., and Semperebon, G. M. (2006) A comparison of the dietary habits of a large sample of the Pleistocene pronghorn *Steckoceros onusrosagris* from the Papago Springs Cave in Arizona to the modern *Antilocapra americana*. *Journal of Vertebrate Paleontology* 26:495–500.
- Robb, J. (2000) Analysing human skeletal data. In: M. Cox and S. Mays (Eds.) *Human osteology in archaeology and forensic science*. Pp. 475–490. London, UK: Greenwich Medical Media, Ltd.
- Roberts, C. (1994) Treponematosis in Gloucester, England: A theoretical and practical approach to the pre-Columbian theory. In: O. Dutour, G. Pálfi, J. Bérato, and J.-P. Brun (Eds.) *The origin of syphilis in Europe: before or after 1493?* Pp. 101–108. Toulon, France: Centre Archéologique du Var.
- Roberts, C. A., and Buikstra, J. E. (2003) *The bioarchaeology of tuberculosis: A global view on a reemerging disease*. Gainesville, FL: University Press of Florida. 368 pp.
- Roberts, C. A., and Ingham, S. (2008) Using ancient DNA analysis in palaeopathology: A critical analysis of published papers, with recommendations for future work. *International Journal of Osteoarchaeology* 18:600–613.
- Roberts, C., and Manchester, K. (1995) *The Archaeology of Disease* (2nd ed.). Ithaca, NY: Cornell University Press. 243 pp.
- Roberts, C., and Manchester, K. (2007) *The archaeology of disease* (3rd ed.). Ithaca, NY: Cornell University Press. 338 pp.
- Robinson, C., Eisma, R., Morgan, B., Jeffery, A., Graham, E. A. M., Black, S., and Ruttly, G. N. (2008) Anthropological measurement of lower limb and foot bones using multi-detector computed tomography. *Journal of Forensic Sciences* 53:1289–1295.
- Robinson, M. S., and Bidmo, M. A. (2009) The skull and humerus in the determination of sex: Reliability of discriminant function equations. *Forensic Science International* 186:86.e1–86.e5.
- Robling, A. G., and Stout, S. D. (2008) Histomorphometry of human cortical bone: Applications to age estimation. In: M. A. Katzenberg and S. R. Saunders (Eds.) *Biological anthropology of the human skeleton* (2nd ed.). Pp. 149–182. New York, NY: Wiley-Liss.
- Robling, A. G., and Ubelaker, D. H. (1997) Sex estimation from the metatarsals. *Journal of Forensic Sciences* 42:1062–1069.
- Rogers, J., and Waldron, T. (1989) Infections in paleopathology: The basis of classification into most probable cause. *Journal of Archaeological Science* 16:611–625.
- Rogers, J., Waldron, T., Dieppe, P., and Watt, I. (1987) Arthropathies in palaeopathology: The basis of classification according to most probable cause. *Journal of Archaeological Science* 14:179–193.
- Rogers, S. L. (1986) *The personal identification of living individuals*. Springfield, IL: C. C. Thomas. 92 pp.
- Rogers, T. L. (1999) A visual method of determining the sex of skeletal remains using the distal humerus. *Journal of Forensic Sciences* 44:57–60.
- Rogers, T. L., and Saunders, S. (1994) Accuracy of sex determination using morphological traits of the human pelvis. *Journal of Forensic Sciences* 39:1047–1056.
- Rohen, J. W., Yokochi, C., and Lütjen-Drecoll, E. (2006) *Color atlas of anatomy: A photographic study of the human body* (6th ed.). Philadelphia, PA: Lippincott Williams & Wilkins. 528 pp.
- Rohen, J. W., Yokochi, C., and Lütjen-Drecoll, E. (2010) *Color atlas of anatomy: A photographic study of the human body* (7th ed.). Philadelphia, PA: Lippincott Williams & Wilkins. 556 pp.

- Rohlf, F. J., and Bookstein, F. L. (Eds.) (1990) *Proceedings of the Michigan Morphometrics Workshop (Special Publication No. 2)*. Ann Arbor, MI: University of Michigan Museum of Zoology. 380 pp.
- Rose, F. (2008) Intra-community variation in diet during the adoption of a new staple crop in the Eastern Woodlands. *American Antiquity* 73:413–439.
- Rose, J. C., Antón, S. C., Aufderheide, A. C., Eisenberg, L., Gregg, J. B., Neiburger, E. J., and Rothschild, B. (1991) *Skeletal Database Committee recommendations*. Detroit, MI: Paleopathology Association. 12 pp.
- Rösing, W. (1984) Discreta of the human skeleton: A critical review. *Journal of Human Evolution* 13:319–323.
- Ross, A. H., and Cunningham, S. L. (in press) Time-since-death and bone weathering in a tropical environment. *Forensic Science International*. Early view: www.elsevier.com/locate/forsciint, DOI: doi:10.1016/j.forsciint.2010.05.018.
- Rossi, D., de Gruchy, S., and Lovell, N. C. (2004) A comparative experiment in the consolidation of cremated bone. *International Journal of Osteoarchaeology* 14:104–111.
- Rossner, M., and Yamada, K. M. (2004) What's in a picture? The temptation of image manipulation. *Journal of Cell Biology* 166:11–15.
- Rothschild, B. M. (1992) Advances in detecting disease in earlier human populations. In: S. R. Saunders and M. A. Katzenberg (Eds.) *Skeletal biology of past peoples: Research methods*. Pp. 131–151. New York, NY: Wiley-Liss.
- Rothschild, B. M., Hershkovitz, I., Dutour, O., Latimer, B., Rothschild, C., and Jellema, L. M. (1997) Recognition of Leukemia in skeletal remains: Report and comparison of two cases. *American Journal of Physical Anthropology* 102:481–496.
- Rothschild, B. M., Woods, R. J., and Ortel, W. (1990) Rheumatoid arthritis “in the buff”: Erosive arthritis in defleshed bones. *American Journal of Physical Anthropology* 82:441–449.
- Rougé, D., Telmon, N., Arrue, P., Larrouy, G., and Arbus, L. (1993) Radiographic identification of human remains through deformities and anomalies of post-cranial bones: A report of two cases. *Journal of Forensic Sciences* 38:997–1007.
- Rougé-Maillart, C., Telmon, N., Rissech, C., Malgosa, A., and Rougé, D. (2004) The determination of male adult age at death by central and posterior coxal analysis: A preliminary study. *Journal of Forensic Sciences* 49:1–7.
- Rubio, L., Martinez, L. J., Martinez, E., and Martin de las Heras, S. (2009) Study of short- and long-term storage of teeth and its influence on DNA. *Journal of Forensic Sciences* 54:1411–1413.
- Ruff, C. B. (1992) Biomechanical analyses of archaeological human skeletal samples. In: S. R. Saunders and A. Katzenberg (eds.) *The skeletal biology of past peoples*. Pp. 41–62. New York, NY: Alan R. Liss.
- Ruff, C. B., Larsen, C. S., and Hayes, W. C. (1984) Structural changes in the femur with the transition to agriculture on the Georgia coast. *American Journal of Physical Anthropology* 64:125–136.
- Ruff, C. B., Trinkaus, E., Walker, A., and Larsen, C. S. (1993) Postcranial robusticity in *Homo*, I: Temporal trends and mechanical interpretation. *American Journal of Physical Anthropology* 91:21–53.
- Rühli, F. J., Lanz, C., Ulrich-Bochsler, S., and Alt, K. W. (2002) State-of-the-art imaging in palaeopathology: The value of multislice computed tomography in visualizing doubtful cranial lesions. *International Journal of Osteoarchaeology* 12:372–379.
- Rühli, F. J., Kuhn, G., Evison, R., Müller, R., and Schultz, M. (2007) Diagnostic value of micro-CT in comparison with histology in the qualitative assessment of historical human skull bone pathologies. *American Journal of Physical Anthropology* 133:1099–1111.
- Russell, M. D., and LeMort, F. (1986) Cutmarks on the Engis 2 calvaria? *American Journal of Physical Anthropology* 69:317–323.
- Russell, K. F., Simpson, S. W., Genovese, J., Kinkel, M. D., Meindl, R. S., and Lovejoy, C. O. (1993) Independent test of the fourth rib aging technique. *American Journal of Physical Anthropology* 92:53–62.
- Sallares, R., and Gomzi, S. (2001) Biomolecular archaeology of malaria. *Ancient Biomolecules* 3:195–213.
- Salmon, M. H. (1997) Ethical considerations in anthropology and archaeology, or relativism and justice for all. *Journal of Anthropological Research* 53:47–60.
- Salo, W. L., Aufderheide, A. C., Buikstra, J., and Holcomb, T. A. (1994) Identification of *Mycobacterium tuberculosis* DNA in a pre-Columbian Peruvian mummy. *Proceedings of the National Academy of Sciences of the United States of America* 91:2091–2094.
- Sampson, H. W., Montgomery, J. L., and Henryson, G. L. (1991) *Atlas of the human skull*. College Station, TX: Texas A&M University Press. 200 pp.
- Sandford, M. K. (Ed.) (1993) *Investigations of ancient human tissue: Chemical analyses in anthropology*. Langhorne, PA: Gordon and Breach Science Publishers, SA. 432 pp.
- Sarajlić, N. (2006) [Age estimation based on sternal rib ends changes in Bosnian male population. (in Bosnian)] *Medicinski Arhiv (Sarajevo)* 60:343–346.
- Saunders, S. R. (1978) Non-metric traits of the human infracranial skeleton (abstract). *American Journal of Physical Anthropology* 48:433.

- Saunders, S. R. (1989) Nonmetric skeletal variation. In: M. Y. İşcan and K. A. R. Kennedy (Eds.) *Reconstruction of life from the skeleton*. Pp. 95–108. New York, NY: Alan R. Liss.
- Saunders, S. R., Fitzgerald, C., Rogers, T., Dudar, C., and McKillop, H. (1992) A test of several methods of skeletal age estimation using a documented archaeological sample. *Canadian Society of Forensic Science Journal* 25:97–118.
- Saunders, S. R., and Herring, A. (Eds.) (1998) *Grave reflections: Portraying the past through cemetery studies*. Toronto: Canadian Scholars' Press. 281 pp.
- Saunders, S. R., and Katzenberg, M. A. (Eds.) (1992) *Skeletal biology of past peoples: Research methods*. New York, NY: Wiley-Liss. 288 pp.
- Saunders, S. R., and Rainey, D. L. (2008) Nonmetric trait variation in the skeleton: Abnormalities, anomalies, and atavisms. In M. A. Katzenberg and S. R. Saunders (Eds.) *Biological anthropology of the human skeleton* (2nd ed.). Pp. 487–532. New York, NY: Wiley-Liss.
- Scarre, C., and Scarre, G. (Eds.) (2006) *The ethics of archaeology: Philosophical perspectives on archaeological practice*. New York, NY: Cambridge University Press. 322 pp.
- Schablitsky, J., Dixon, K. J., and Leney, M. D. (2006) Forensic technology and the historical archaeologist. *Historical Archaeology* 40 (*Remains of the day: Forensic applications in archaeology*):1–7.
- Schaefer, M., Black, S., and Scheuer, L. (2009) *Juvenile osteology: A laboratory and field manual*. San Diego, CA: Academic Press. 284 pp.
- Scheid, R. C. (2007) *Woelfel's dental anatomy: Its relevance to dentistry* (7th ed.). Baltimore, MD: Lippincott Williams and Wilkins. 534 pp.
- Schermer, S. J., Franciscus, R. G., and Lillie, R. M. (2000) Development of a useable research collection: The University of Iowa-Stanford Collection. Poster presented at the Human Remains: Conservation, Retrieval, and Analysis Conference, Williamsburg, VA, November 1999, and the Paleopathology Association Annual Meeting, San Antonio, TX.
- Scheuer, L. (2002) A blind test of mandibular morphology for sexing mandibles in the first few years of life. *American Journal of Physical Anthropology* 119:189–191.
- Scheuer, L., and Black, S. (2004) *The juvenile skeleton*. San Diego, CA: Academic Press. 400 pp.
- Scheuer, L., and Black, S. (2000) *Developmental juvenile osteology*. San Diego, CA: Academic Press. 587 pp.
- Schillaci, M. A., Irish, J. D., and Wood, C. C. E. (2009) Further analysis of the population history of ancient Egyptians. *American Journal of Physical Anthropology* 139:235–243.
- Schmidt, C. W. (2010) On the relationship of dental microwear to dental macrowear. *American Journal of Physical Anthropology* 142:67–73.
- Schmidt, C. W., and Symes, S. A. (Eds.) (2008) *The analysis of burned human remains*. Burlington, VT: Academic Press. 296 pp.
- Schmidt-Schultz, T. H., and Schultz, M. (2004) Bone protects proteins over thousands of years: Extraction, analysis, and interpretation of extracellular proteins in archeological skeletal remains. *American Journal of Physical Anthropology* 123:30–39.
- Schmitt, A. (2004) Age-at-death assessment using the os pubis and the auricular surface of the ilium: A test on an identified Asian sample. *International Journal of Osteoarchaeology* 14:1–6.
- Schmucker, B. J. (1985) Dental attrition: A correlative study of dietary and subsistence patterns in California and New Mexico Indians. In: C. F. Merbs and R. J. Miller (Eds.) *Health and disease in the prehistoric Southwest*. (Anthropological Research Papers 34). Pp. 275–323. Tempe, AZ: Arizona State University.
- Schoeninger, M. J. (1995) Stable isotope studies in human evolution. *Evolutionary Anthropology* 3:83–98.
- Schroeder, H., O'Connell, T. C., Evans, J. A., Shuler, K. A., and Hedges, R. E. (2009) Trans-Atlantic slavery: Isotopic evidence for forced migration to Barbados. *American Journal of Physical Anthropology* 139:547–557.
- Shufeldt, R. W. (1893) Notes on palaeopathology. *Popular Science Monthly* 42:679–684.
- Schultz, M. (1997a) Microscopic structure of bone. In: W. D. Haglund and M. H. Sorg (Eds.) *Forensic taphonomy: The postmortem fate of human remains*. Pp. 187–199. Boca Raton, FL: CRC Press.
- Schultz, M. (1997b) Microscopic investigation of excavated skeletal remains: A contribution to paleopathology and forensic medicine. In: W. D. Haglund and M. H. Sorg (Eds.) *Forensic taphonomy: The postmortem fate of human remains*. Pp. 201–222. Boca Raton, FL: CRC Press.
- Schultz, M., Schmidt-Schultz, T. H., Wolf, M. (2003) Paläopathologische und paläobiologische Untersuchungen an ausgewählten Skelettfunden aus der Nekropole von Bajkara (Kasachstan). In: H. Parzinger, Y. Zajtbert, and A. Nagler (Eds.) *Der große Kurgan von Bajkara* (Archäologie in Eurasien, vol. 16). Pp. 149–194. Mainz, Germany: Verlag Philipp von Zabern.
- Schünke, M., Ross, L. M., Lamperti, E. D., Schulte, E., Schumacher, U., Rude, J., Voll, M., and Wesker, K. (2006) *Thieme atlas of anatomy: General anatomy and musculoskeletal system*. New York, NY: Thieme. 560 pp.
- Schwarcz, H. P., White, C. D., and Longstaffe, F. J. (2010) Stable and radiogenic isotopes in biological archaeology: Some applications. In: J. B. West, G. J. Bowen, T. E. Dawson, and K. P. Tu (Eds.) *Isoscapes: Understanding movement, pattern, and process on Earth through isotope mapping*. Pp. 335–356. New York, NY: Springer Science+Business Media.

- Schwartz, G. T., and Dean, M. C. (2005) Sexual dimorphism in modern human permanent teeth. *American Journal of Physical Anthropology* 128:312–317.
- Schwartz, J. H. (2006) *Skeleton keys: An introduction to human skeletal morphology, development, and analysis* (2nd ed.). New York, NY: Oxford University Press. 416 pp.
- Scott, D., Willey, P., and Connor, M. (Eds.) (2002) *They died with Custer: Soldiers' bones from the Battle of Little Bighorn*. Norman, OK: Red River Books, University of Oklahoma Press. 416 pp.
- Scott, E. C. (1979) Dental wear scoring technique. *American Journal of Physical Anthropology* 51:213–218.
- Scott, G. R., and Turner, C. G. (1988) Dental anthropology. *Annual Review of Anthropology* 17:99–126.
- Scott, G. R., and Turner, C. G. (1997) *The anthropology of modern human teeth: Dental morphology and its variation in recent human populations*. New York, NY: Cambridge University Press. 382 pp.
- Scott, R. S., Ungar, P. S., Bergstrom, T. S., Brown, C. A., Grine, F. E., Teaford, M. F., and Walker, A. (2005) Dental microwear texture analysis shows within-species diet variability in fossil hominins. *Nature* 436:693–695.
- Scott, R. S., Ungar, P. S., Bergstrom, T. S., Brown, C. A., Childs, B. E., Teaford, M. F., and Walker, A. (2006) Dental microwear texture analysis: Technical considerations. *Journal of Human Evolution* 51:339–349.
- Scott-Lichter, D., and the Editorial Policy Committee, Council of Science Editors. (2009) CSE's White paper on promoting integrity in scientific journal publications, 2009 update. Reston, VA: Council of Science Editors. Accessed 2010 Sept 4. Available from: <http://www.councilscienceeditors.org/i4a/pages/index.cfm?pageid=3331>
- Sease, C. (1994) *A conservation manual for the field archaeologist* (3rd ed.). Los Angeles, CA: Cotsen Institute of Archaeology. 120 pp.
- Sedgewick, J. (2008) *Scientific imaging with Photoshop: Methods, measurement, and output*. Berkeley, CA: New Riders Press. 312 pp.
- Seidemann, R. M. (2009) Altered meanings: The Department of the Interior's rewriting of the Native American Graves Protection and Repatriation Act to regulate culturally unidentifiable human remains. *Temple Journal of Science, Technology, & Environmental Law* 28:1–47.
- Seo, S. B., Zhang, A., Kim, H. Y., Yi, J. A., Lee, H. Y., Shin, D. H., and Lee, S. D. (2010) Technical note: Efficiency of total demineralization and ion-exchange column for DNA extraction from bone. *American Journal of Physical Anthropology* 141:158–162.
- Shafer, H. J., Marek, M., and Reinhard, K. J. (1989) A Mimbres burial with associated colon remains from the NAN Ranch Ruin, New Mexico. *Journal of Field Archaeology* 16:17–30.
- Shafritz, A. B., Shore, E. M., Gannon, F. H., Zasloff, M. A., Taub, R., Muenke, M., and Kaplan, F. S. (1996) Overexpression of an osteogenic morphogen in fibrodysplasia ossificans progressiva. *The New England Journal of Medicine* 335:555–561.
- Shahack-Gross, R., Bar-Yosef, O., and Weiner, S. (1997) Black-coloured bones in Hayonim Cave, Israel: Differentiating between burning and oxide staining. *Journal of Archaeological Science* 24:439–446.
- Sherwood, R. J., Meindl, R. S., Robinson, H. B., and Mayo, R. L. (2000) Fetal age: Methods of estimation and effects of pathology. *American Journal of Physical Anthropology* 113:305–315.
- Shipman, P., Walker, A., and Bichell, D. (1985) *The Human Skeleton*. Cambridge, MA: Harvard University Press. 343 pp.
- Shiroma, C. Y., Fielding, C. G., Lewis, J. A. Jr., Gleisner, M. R., and Dunn, K. N. (2004) A minimally destructive technique for sampling dentin powder for mitochondrial DNA testing. *Journal of Forensic Sciences* 49:791–795.
- Shore, E. M., Xu, M., Feldman, G. J., Fenstermacher, D. A., Cho, T.-J., Choi, I. H., Connor, J. M., Delai, P., Glaser, D. L., LeMerrer, M., Morhart, R., Rogers, J. G., Smith, R., Triffitt, J. T., Urtizberea, J. A., Zasloff, M., Brown, M. A., and Kaplan, F. S. (2006) A recurrent mutation in the BMP type I receptor ACVR1 causes inherited and sporadic fibrodysplasia ossificans progressiva. *Nature Genetics* 38:525–527.
- Shreeve, J. (2010) Evolutionary Road. *National Geographic Magazine* 218:34–67.
- Shubin, N. (2009) *Your inner fish: A journey into the 3.5-billion-year history of the human body*. New York, NY: Vintage Books. 256 pp.
- Sillen, A., Sealey, J. C., and van der Merwe, N. J. (1989) Chemistry and paleodietary research: No more easy answers. *American Antiquity* 54:504–512.
- Simmons, D. J. (1985) Options for bone aging with the microscope. *Yearbook of Physical Anthropology* 28:249–263.
- Sjøvold, T. (1984) A report on the heritability of some cranial measurements and nonmetric traits. In: G. N. van Vark and W. W. Howells (Eds.) *Multivariate statistical methods in physical anthropology*. Pp. 223–246. Dordrecht, Holland: D. Reidel.
- Skinner, M., Alempijevic, D., and Djuric-Srejic, J. (2003) Guidelines for international forensic bio-archaeology monitors of mass grave exhumations. *Forensic Science International* 134:81–92.

- Skinner, M., and Goodman, A. H. (1992) Anthropological uses of developmental defects of enamel. In: S. R. Saunders and M. A. Katzenberg (Eds.) *Skeletal biology of past peoples: Research methods*. Pp. 153–174. New York, NY: Wiley-Liss.
- Skinner, S. A., Saunders, C., Poirier, D. A., Krofina, D. L., and Wheat, P. (1998) Be prepared: The archeology merit badge is here. *Common Ground* 3:38–43.
- Slice, D. E. (Ed.) (2005) *Modern morphometrics in physical anthropology*. New York, NY: Kluwer Academic/Plenum Publishers. 384 pp.
- Smith, B. H. (1984) Patterns of molar wear in hunter-gatherers and agriculturalists. *American Journal of Physical Anthropology* 63:39–56.
- Smith, B. H. (1991) Standards of human tooth formation and dental age assessment. In: M. A. Kelley and C. S. Larsen (Eds.) *Advances in dental anthropology*. Pp. 143–168. New York, NY: Wiley-Liss.
- Smith, B. H., and Garn, S. M. (1987) Polymorphisms in eruption sequence of permanent teeth in American children. *American Journal of Physical Anthropology* 74:289–303.
- Smith, D. R., Limbird, K. G., and Hoffman, J. M. (2002) Identification of human skeletal remains by comparison of bony details of the cranium using computerized tomographic (CT) scans. *Journal of Forensic Sciences* 47:1–3.
- Smith, H. F., Terhune, C. E., and Lockwood, C. A. (2007) Genetic, geographic, and environmental correlates of human temporal bone variation. *American Journal of Physical Anthropology* 134:312–322.
- Smith, J., and Latimer, B. (1989) A method for making three-dimensional reproductions of bones and fossils. *Kirtlandia* (Cleveland Museum of Natural History) 44:3–16.
- Snodgrass, J. J., and Galloway, A. (2003) Utility of pits and pubic tubercle height in parity assessment. *Journal of Forensic Sciences* 48:1–5.
- Snow, C. C. (1982) Forensic anthropology. *Annual Review of Anthropology* 11:97–131.
- Soomer, H., Ranta, R., Lincoln, J. J., Penttilä, A., and Leibur, E. (2003) Reliability and validity of eight dental age estimation methods for adults. *Journal of Forensic Sciences* 48:1–4.
- Spigelman, M., Matheson, C., Lev, G., Greenblatt, C., and Donoghue, H. D. (2002) Confirmation of the presence of *Mycobacterium tuberculosis* specific DNA in three archaeology specimens. *International Journal of Osteoarchaeology* 12:393–401.
- Spoor, C. F., Zonneveld, F. W., and Macho, G. A. (1993) Linear measurements of cortical bone and dental enamel by computed tomography: Applications and problems. *American Journal of Physical Anthropology* 91:469–484.
- Spranger, J. W., Brill, P. W., and Poznanski, A. K. (2002) *Bone dysplasias: An atlas of genetic disorders of skeletal development* (2nd ed.). New York, NY: Oxford University Press. 613 pp.
- Springer, J. W. (2006) Scholarship vs. repatriationism. *Academic Questions* Winter 2005–06:6–36.
- Standring, S. S. (2008) *Gray's Anatomy: The anatomical basis of clinical practice* (40th ed.). New York, NY: Churchill Livingstone. 1576 pp.
- Steadman, D. W. (Ed.) (2009) *Hard evidence: Case studies in forensic anthropology* (2nd ed.). Upper Saddle River, NJ: Prentice Hall. 360 pp.
- Steadman, D. W., DiAntonio, L. L., Wilson, J. J., Sheridan, K. E., and Tammariello, S. P. (2006) The effects of chemical and heat maceration techniques on the recovery of nuclear and mitochondrial DNA from bone. *Journal of Forensic Sciences* 51:11–17.
- Steele, D. G., and Bramblett, C. A. (1988) *The anatomy and biology of the human skeleton*. College Station, TX: Texas A&M University Press. 291 pp.
- Steele, D. G. (1976) The estimation of sex on the basis of the talus and calcaneus. *American Journal of Physical Anthropology* 45:581–588.
- Steele, J. (2000) Skeletal indicators of handedness. In: M. Cox and S. Mays (Eds.) *Human osteology in archaeology and forensic science*. Pp. 307–323. London, UK: Greenwich Medical Media, Ltd.
- Steinbock, R. T. (1976) *Paleopathological diagnosis and interpretation*. Springfield, IL: C. C. Thomas. 423 pp.
- Stephan, E. (2000) Oxygen isotope analysis of animal bone phosphate: Method refinement, influence of consolidants, and reconstruction of palaeotemperatures for Holocene sites. *Journal of Archaeological Science* 27:523–535.
- Stevenson, J. C., Mahoney, E. R., Walker, P. L., and Everson, P. M. (2009) Prediction of sex based on five skull traits using decision analysis (CHAID) *American Journal of Physical Anthropology* 139:434–441.
- Stevenson, P. H. (1924) Age order of epiphyseal union in man. *American Journal of Physical Anthropology* 7:53–93.
- Stewart, T. D. (1979) *Essentials of forensic anthropology, especially as developed in the United States*. Springfield, IL: C. C. Thomas. 300 pp.
- Stirland, A. (1991a) Diagnosis of occupationally related paleopathology: Can it be done? In: D. J. Ortner and A. C. Aufderheide (Eds.) *Human paleopathology: Current syntheses and future options*. Pp. 40–47. Washington, DC: Smithsonian Institution Press.

- Stirland, A. (1991b) Pre-Columbian treponematosi in medieval Britain. *International Journal of Osteoarchaeology* 1:39–47.
- Stirland, A. J. (1994) The angle of femoral torsion: An impossible measurement? *International Journal of Osteoarchaeology* 4:31–35.
- St. Hoyme, L. E., and İscan, M. Y. (1989) Determination of sex and race: Accuracy and assumptions. In: M. Y. İscan and K. A. R. Kennedy (Eds.) *Reconstruction of life from the skeleton*. Pp. 53–93. New York, NY: Alan R. Liss.
- Stojanowski, C. M. (1999) Sexing potential of fragmentary and pathological metacarpals. *American Journal of Physical Anthropology* 109:245–252.
- Stokes, I. A. F., Dansereau, J., and Moreland, M. S. (1989) Rib cage asymmetry in idiopathic scoliosis. *Journal of Orthopaedic Research* 7:599–606.
- Stone, A. C. (2000) Ancient DNA from skeletal remains. In: M. A. Katzenberg and S. R. Saunders (Eds.) *Biological anthropology of the human skeleton* (1st ed.). Pp. 351–371. New York, NY: Wiley-Liss.
- Stone, A. C. (2008) DNA analysis of archaeological remains. In: M. A. Katzenberg and S. R. Saunders (Eds.) *Biological anthropology of the human skeleton* (2nd ed.). Pp. 461–484. New York, NY: Wiley-Liss.
- Stone, A. C., Milner, G. R., Pääbo, S., and Stoneking, M. (1996) Sex determination of ancient human skeletons using DNA. *American Journal of Physical Anthropology* 99:231–238.
- Stone, A. C., and Stoneking, M. (1993) Ancient DNA from a pre-Columbian Amerindian population. *American Journal of Physical Anthropology* 92:463–471.
- Stoneking, M. (1995) Ancient DNA: How do you know when you have it and what can you do with it? *American Journal of Human Genetics* 57:1259–1262.
- Stout, S. D. (1992) Methods of determining age at death using bone microstructure. In: S. R. Saunders and M. A. Katzenberg (Eds.) *Skeletal biology of past peoples: Research methods*. Pp. 21–35. New York, NY: Wiley-Liss.
- Stout, S. D., Dietze, W. H., İscan, M. Y., and Loth, S. R. (1994) Estimation of age at death using cortical histomorphometry of the sternal end of the fourth rib. *Journal of Forensic Sciences* 39:778–784.
- Stout, S. D., and Paine, R. R. (1992) Histological age estimation using rib and clavicle. *American Journal of Physical Anthropology* 87:111–116.
- Stout, S. D., Porro, M. A., and Perotti, B. (1996) Brief communication: A test and correction of the clavicle method for histological age determination of skeletal remains. *American Journal of Physical Anthropology* 100:139–142.
- Streeter, M. (2010) A four-stage method of age at death estimation for use in the subadult rib cortex. *Journal of Forensic Sciences* 55:1019–1024.
- Stuart-Macadam, P. (1987a) A radiographic study of porotic hyperostosis. *American Journal of Physical Anthropology* 74:511–520.
- Stuart-Macadam, P. (1987b) Porotic hyperostosis: New evidence to support the anemia theory. *American Journal of Physical Anthropology* 74:521–526.
- Stuart-Macadam, P. (1991) Porotic hyperostosis: Changing interpretations. In: D. J. Ortner and A. C. Aufderheide (Eds.) *Human paleopathology: Current syntheses and future options*. Pp. 36–39. Washington, DC: Smithsonian Institution Press.
- Suchey, J. M., and Katz, D. (1998) Applications of pubic age determination in a forensic setting. In: K. J. Reichs (Ed.) *Forensic osteology: Advances in the identification of human remains* (2nd ed.). Pp. 204–236. Springfield, IL: C. C. Thomas.
- Suchey, J. M., Wiseley, D. V., Green, R. F., and Noguchi, T. T. (1979) Analysis of dorsal pitting in the os pubis in an extensive sample of modern American females. *American Journal of Physical Anthropology* 51:517–540.
- Suchey, J. M., Wiseley, D. V., and Katz, D. (1986) Evaluation of the Todd and McKern-Stewart methods for aging the male os pubis. In: K. J. Reichs (Ed.) *Forensic osteology: Advances in the identification of human remains* (1st ed.). Pp. 33–67. Springfield, IL: C. C. Thomas.
- Sundick, R. I. (1984) Ashes to ashes, dust to dust or where did the skeleton go? In: T. A. Rathburn and J. E. Buikstra (Eds.) *Human identification: Case studies in forensic anthropology*. Pp. 412–423. Springfield, IL: C. C. Thomas.
- Superti-Furga, A., Unger, S., and the Nosology Group of the International Skeletal Dysplasia Society. (2007) Nosology and classification of genetic skeletal disorders: 2006 revision. *American Journal of Medical Genetics, Part A* 143A:1–18.
- Suter, S., Harders, M., Papageorgopoulou, C., Kuhn, G., Székely, G., and Rühli, F. J. (2008) Technical note: Standardized and semiautomated Harris lines detection. *American Journal of Physical Anthropology* 137:362–366.
- Sutherland, L. D., and Suchey, J. M. (1991) Use of the ventral arc in pubic sex determination. *Journal of Forensic Sciences* 36:501–511.
- Sutter, R. C., and Verano, J. W. (2007) Biodistance analysis of the Moche sacrificial victims from Huaca de la Luna Plaza 3C: Matrix method test of their origins. *American Journal of Physical Anthropology* 132:193–206.

- Suwa, G. (1990) *A comparative analysis of hominid dental remains from the Shungura and Usno formation, Omo Valley, Ethiopia*. Ph.D. thesis. Berkeley, CA: University of California, Berkeley. 522 pp.
- Suwa, G., Asfaw, B., Kono, R. T., Kubo, D., Lovejoy, C. O., and White, T. D. (2009) The *Ardipithecus ramidus* skull and its implications for hominid origins. *Science* 326:68, 68e1–68e7.
- Suwa, G., Kono, R. T., Simpson, S. W., Asfaw, B., Lovejoy, C. O., and White, T. D. (2009) Paleobiological implications of the *Ardipithecus ramidus* dentition. *Science* 326:69, 94–99.
- Suwa, G., and Kono, R. T. (2005) A micro-CT based study of linear enamel thickness in the mesial cusp section of human molars: Reevaluation of methodology and assessment of within-tooth, serial, and individual variation. *Anthropological Science* 113:273–289.
- Sweet, D. J., and Sweet, H. W. (1995) DNA analysis of dental pulp to link incinerated remains of homicide victim to crime scene. *Journal of Forensic Sciences* 40:310–314.
- Tague, R. G. (1988) Bone resorption of the pubis and preauricular area in humans and nonhuman mammals. *American Journal of Physical Anthropology* 76:251–267.
- Tang, J.-P., Hu, D.-Y., Jiang, F.-H., and Yu, X.-J. (2009) Assessing forensic applications of the frontal sinus in a Chinese Han population. *Forensic Science International* 183:104.e1–104.e3.
- Taylor, G. M., Widdison, S., Brown, I. N., and Young, D. (2000) A mediaeval case of lepromatous leprosy from 13–14th century Orkney, Scotland. *Journal of Archaeological Sciences* 27:1133–1138.
- Taylor, R. E., Hare, P. E., and White, T. D. (1995) Geochemical criteria for thermal alteration of bone. *Journal of Archaeological Science* 22:115–119.
- Taylor, R. M. S. (1978) *Variation in morphology of teeth: Anthropologic and forensic aspects*. Springfield, IL: C. C. Thomas. 384 pp.
- Teaford, M. F. (1991) Dental microwear: What can it tell us about diet and dental function? In: M. A. Kelley and C. S. Larsen (Eds.) *Advances in dental anthropology*. Pp. 341–356. New York, NY: Wiley-Liss.
- Teaford, M. F. (1994) Dental microwear and dental function. *Evolutionary Anthropology* 3:17–30.
- Teaford, M. F. (2000) Primate dental functional morphology revisited. In M. F. Teaford, M. M. Smith, and M. W. J. Ferguson (Eds.) *Development, function and evolution of teeth*. Pp. 290–304. New York, NY: Cambridge University Press.
- Temple, D. H., and Larsen, C. S. (2007) Dental caries prevalence as evidence for agriculture and subsistence variation during the Yayoi period in prehistoric Japan: Biocultural interpretations of an economy in transition. *American Journal of Physical Anthropology* 134:501–512.
- Tersigni, M. A. (2007) Frozen human bone: A microscopic investigation. *Journal of Forensic Sciences* 52:16–20.
- Thevissen, P. W., Fieuws, S., and Willems, G. (2010) Human dental age estimation using third molar developmental stages: Does a Bayesian approach outperform regression models to discriminate between juveniles and adults? *International Journal of Legal Medicine* 124:35–42.
- Thomas, B. L., and Sharpe, P. T. (1998) Patterning of the murine dentition by homeobox genes. *European Journal of Oral Sciences* 106 Suppl. 1:48–54.
- Thomas, D. H. (1986) *Refiguring anthropology: First principles of probability and statistics*. Prospect Heights, IL: Waveland Press. 532 pp.
- Thomas, D. H. (2000) *Skull wars: Kennewick man, archaeology, and the battle for Native American identity*. New York, NY: Basic Books. 368 pp.
- Tibbett, M., and Carter, D. O. (Eds.) (2008) *Soil analysis in forensic taphonomy: Chemical and biological effects of buried human remains*. Boca Raton, FL: CRC Press. 352 pp.
- Todd, T. W. (1920) Age changes in the pubic bone. I. The white male pubis. *American Journal of Physical Anthropology* 3:285–334.
- Todd, T. W. (1920) Age changes in the pubic bone. *American Journal of Physical Anthropology* 4:1–70.
- Torres-Rouff, C., and Yablonsky, L. T. (2005) Cranial vault modification as a cultural artifact: A comparison of the Eurasian steppes and the Andes. *Homo* 56:1–16.
- Travis, J. (2008) Third International Symposium on Biomolecular Archaeology: Old bones reveal new signs of scurvy. *Science* 322:368–369.
- Trinkaus, E. (2000) Human patellar articular proportions: Recent and Pleistocene patterns. *Journal of Anatomy* 196:473–483.
- Trinkaus, E. (2003) Gough's Cave 1 (Somerset, England): A study of the pelvis and lower limbs. *Bulletin of the Natural History Museum, London* 58 (suppl.):1–21.
- Trinkaus, E., Churchill, S. E., Ruff, C. B., and Vandermeersch, B. (1999) Long bone shaft robusticity and body proportions of the Saint-Césaire 1 Châtelperronian Neanderthal. *Journal of Archaeological Science* 26:753–773.
- Trinkaus, E., and Svoboda, J. (Eds.) (2006) *Early modern human evolution in central Europe: The people of Dolní Věstonice and Pavlov*. New York, NY: Oxford University Press. 500 pp.
- Trodden, B. J. (1982) A radiographic study of the calcification and eruption of the permanent teeth in Inuit and Indian children. *Archaeological Survey of Canada Papers* 112:1–136.

- Trotter, M. (1970) Estimation of stature from intact long bones. In: T. D. Stewart (Ed.) *Personal identification in mass disasters*. Pp. 71–83. Washington, DC: Smithsonian Institution Press.
- Trotter, M., and Gleser, G. C. (1958) A re-evaluation of estimation of stature based on measurements of stature taken during life and of long bones after death. *American Journal of Physical Anthropology* 16:79–123.
- Trudell, M. B. (1999) Anterior femoral curvature revisited: Race assessment from the femur. *Journal of Forensic Sciences* 44:700–707.
- Trussell, H. J., and Vrhel, M. J. (2008) *Fundamentals of digital imaging*. New York, NY: Cambridge University Press. 550 pp.
- Turner, C. G. (1986) What is lost with skeletal reburial? I. Adaptation. *Quarterly Review of Archaeology* 7:1–3.
- Turner, C. G., and Turner, J. A. (1999) *Man corn: Cannibalism and violence in the American Southwest*. Salt Lake City, UT: University of Utah Press. 547 pp.
- Turner, C. G., Nichol, C. R., and Scott, G. R. (1991) Scoring procedures for key morphological traits of the permanent dentition. In: M. A. Kelley and C. S. Larsen (Eds.) *Advances in dental anthropology*. Pp. 13–31. New York, NY: Wiley-Liss.
- Turner, T. R. (Ed.) (2005) *Biological anthropology and ethics: From repatriation to genetic identity*. Albany, NY: State University of New York Press. 327 pp.
- Twelfth International Congress of Anatomists (1989) *International Anatomical Nomenclature Committee: Nomina Anatomica* (6th ed.). New York, NY: Churchill-Livingstone. 211 pp.
- Tyrrell, A. (2000) Skeletal non-metric traits and the assessment of inter- and intra-population diversity: Past problems and future potential. In: M. Cox and S. Mays (Eds.) *Human osteology in archaeology and forensic science*. Pp. 289–306. London, UK: Greenwich Medical Media, Ltd.
- Tyrrell, A. J., Evison, M. P., Chamberlain, A. T., and Green, M. A. (1997) Forensic three-dimensional facial reconstruction: Historical review and contemporary developments. *Journal of Forensic Sciences* 42:653–661.
- Tyson, R. A., and Alcankas, E. S. D. (Eds.) (1980) *Catalog of the Hrdlička paleopathology collection*. San Diego, CA: San Diego Museum of Man. 359 pp.
- Ubelaker, D. H. (1982) The development of American paleopathology. In: F. Spencer (Ed.) *A history of American physical anthropology 1930–1980*. Pp. 337–356. New York, NY: Academic Press.
- Ubelaker, D. H. (1984) Positive identification from the radiographic comparison of frontal sinus patterns. In: T. Rathburn and J. Buikstra (Eds.) *Human identification*. Pp. 399–411. Springfield, IL: C. C. Thomas.
- Ubelaker, D. H. (1987) Estimating age at death from immature human skeletons: An overview. *Journal of Forensic Sciences* 32:1254–1263.
- Ubelaker, D. H. (1990) Positive identification of American Indian skeletal remains from radiograph comparison. *Journal of Forensic Sciences* 35:466–472.
- Ubelaker, D. H. (1992) Hyoid fracture and strangulation. *Journal of Forensic Sciences* 37:1216–1222.
- Ubelaker, D. H. (1996) Skeletons testify: Anthropology in forensic science (AAPA Luncheon Address, April 12, 1996) *Yearbook of Physical Anthropology* 39:229–244.
- Ubelaker, D. H. (1999) *Human skeletal remains: Excavation, analysis, interpretation* (3rd ed.). Washington, DC: Taraxacum. 172 pp.
- Ubelaker, D. H. (2000) Methodological considerations in the forensic applications of human skeletal biology. In: M. A. Katzenberg and S. R. Saunders (Eds.) *Biological anthropology of the human skeleton* (1st ed.). Pp. 41–67. New York, NY: Wiley-Liss.
- Ubelaker, D. H. (2005) Estimating age at death. In: J. Rich, D. E. Dean and R. H. Powers (Eds.) *Forensic medicine of the lower extremity: Human identification and trauma analysis of the thigh, leg, and foot*. Pp. 99–112. Totowa, NJ: Humana Press.
- Ubelaker, D. H., Berryman, H. E., Sutton, T. P., and Ray, C. E. (1991) Differentiation of hydrocephalic calf and human calvariae. *Journal of Forensic Sciences* 36:801–812.
- Ubelaker, D. H., and Grant, L. G. (1989) Human skeletal remains: Preservation or reburial? *Yearbook of Physical Anthropology* 32:260–287.
- Ubelaker, D. H., Katzenberg, M. A., and Doyon, L. G. (1995) Status and diet in precontact highland Ecuador. *American Journal of Physical Anthropology* 97:403–411.
- Ubelaker, D. H., and Volk, C. G. (2002) A test of the Phenice method for the estimation of sex. *Journal of Forensic Sciences* 47:19–24.
- Ungar, P. S., Brown, C. A., Bergstrom, T. S., and Walker, A. (2003) Quantification of dental microwear by tandem scanning confocal microscopy and scale-sensitive fractal analyses. *Scanning* 25:185–193.
- Ungar, P. S., Scott, R. S., Scott, J. R., and Teaford, M. F. (2008) Dental microwear analysis: Historical perspectives and new approaches. In: J. D. Irish and G. C. Nelson (Eds.) *Technique and application in dental anthropology*. Pp. 389–425. New York, NY: Cambridge University Press.
- Ungar, P. S. (Ed.) (2007) *Evolution of the human diet: The known, the unknown, and the unknowable*. New York, NY: Oxford University Press. 413 pp.

- Urdan, T. C. (2010) *Statistics in Plain English* (3rd ed.). New York, NY: Routledge. 223 pp.
- Van Arsdale, A. P., and Clark, J. L. (in press) Re-examining the relationship between cranial deformation and extra-sutural bone formation. *International Journal of Osteoarchaeology* Early view: www.interscience.wiley.com, DOI: 10.1002/oa.1188.
- Van Beek, G. C. (1983) *Dental morphology: An illustrated guide* (2nd ed.). Woburn, MA: Butterworth-Heinemann. 144 pp.
- Van Gerven, D. P., and Armelagos, G. J. (1983) "Farewell to paleodemography? Rumors of its death have been greatly exaggerated. *Journal of Human Evolution* 12:353–360.
- Vanek, D., Saskova, L., and Koch, H. (2009) Kinship and Y-chromosome analysis of 7th century human remains: Novel DNA extraction and typing procedure for ancient material. *Croatian Medical Journal* 50:286–295.
- Verano, J. W., and Ubelaker, D. H. (Eds.) (1992) *Disease and demography in the Americas*. Washington, DC: Smithsonian Institution Press. 294 pp.
- Verzeletti, A., Cassina, M., Micheli, L., Conti, A., and De Ferrari, F. (2010) Age estimation from the rib by components method analysis in white males. *American Journal of Forensic Medicine and Pathology* 31:27–33.
- Villotte, S., Castex, D., Couallier, V., Dutour, O., Knüsel, C. J., and Henry-Gambier, D. (2010) Enthesopathies as occupational stress markers: Evidence from the upper limb. *American Journal of Physical Anthropology* 142:224–234.
- Vitelli, K. D. (Ed.) (1996) *Archaeological ethics* (1st ed.). Walnut Creek, CA: AltaMira Press. 272 pp.
- Vitelli, K. D., and Colwell-Chantthaphonh, C. (Eds.) (2006) *Archaeological ethics* (2nd ed.). Walnut Creek, CA: AltaMira Press. 234 pp.
- Vogl, A. W. (2009) Awareness of and access to a unified terminology by anatomists. *Anatomical Sciences Education* 2:139–140.
- Von Endt, D. W., and Ortner, D. J. (1984) Experimental effects of bone size and temperature on bone diagenesis. *Journal of Archaeological Science* 11:247–253.
- Vuissoz, A., and Gilbert, T. P. (2007) The impact of preservation treatments on DNA. In: V. Cassman, N. Odegaard, and J. Powell (Eds.) *Human remains: Guide for museums and academic institutions*. Pp. 92–94. Lanham, MD: AltaMira Press.
- Wainwright, A. M., and Catterall, A. (2010) Legg-Calvé-Perthes disease. In: M. Benson, J. Fixsen, M. Macnicol, and K. Parsch (Eds.) *Children's orthopaedics and fractures* (3rd ed). Pp. 465–480. New York, NY: Springer.
- Waldron, T. (1991) Rates for the job: Measures of disease frequency in palaeopathology. *International Journal of Osteoarchaeology* 1:17–25.
- Waldron, T. (1994) *Counting the dead: The epidemiology of skeletal populations*. West Sussex, UK: John Wiley and Sons. 124 pp.
- Waldron, T. (2007) *Paleoepidemiology: The measure of disease in the human past*. Walnut Creek, CA: Left Coast Press. 150 pp.
- Waldron, T. (2009) *Palaeopathology (Cambridge manuals in archaeology)*. New York, NY: Cambridge University Press. 279 pp.
- Waldron, T., and Rogers, J. (1991) Inter-observer variation in coding osteoarthritis in human skeletal remains. *International Journal of Osteoarchaeology* 1:49–56.
- Walker, A. C. (1981) Dietary hypotheses and human evolution. *Philosophical Transactions of the Royal Society of London Series B* 292:57–63.
- Walker, P. L. (1986) Porotic hyperostosis in a marine-dependent California Indian population. *American Journal of Physical Anthropology* 69:345–354.
- Walker, P. L. (2004) Caring for the dead: Finding a common ground in disputes over museum collections of human remains. In: G. Grupe and J. Peters (Eds.) *Documenta archaeobiologiae 2: Conservation policy and current research, Yearbook of the state collection of anthropology and palaeoanatomy*. Pp. 13–27. Rahden, Germany: Verlag Marie Leidorf.
- Walker, P. L. (2005) Greater sciatic notch morphology: Sex, age, and population differences. *American Journal of Physical Anthropology* 127:385–391.
- Walker, P. L. (2008a) Bioarchaeological ethics: A historical perspective on the value of human remains. In: M. A. Katzenberg and S. R. Saunders (Eds.) *Biological anthropology of the human skeleton* (2nd ed.). Pp. 3–39. New York, NY: Wiley-Liss.
- Walker, P. L. (2008b) Sexing skulls using discriminant function analysis of visually assessed traits. *American Journal of Physical Anthropology* 136:39–50.
- Walker, P. L., Bathurst, R. R., Richman, R., Gjerdrum, T., and Andrushko, V. A. (2009) The causes of porotic hyperostosis and cribra orbitalia: A reappraisal of the iron-deficiency-anemia hypothesis. *American Journal of Physical Anthropology* 139:109–125.

- Walker, P. L., and Cook, D. C. (1998) Gender and sex: Vive la difference. *American Journal of Physical Anthropology* 106:255–259.
- Walker, P. L., Cook, D. C., and Lambert, P. M. (1997) Skeletal evidence for child abuse: A physical anthropological perspective. *Journal of Forensic Sciences* 42:196–207.
- Walker, P. L., Dean, G., and Shapiro, P. (1991) Estimating age from tooth wear in archaeological populations. In: M. A. Kelley and C. S. Larsen (Eds.) *Advances in dental anthropology*. Pp. 169–178. New York, NY: Wiley-Liss.
- Walker, P. L., and Erlandson, J. M. (1986) Dental evidence for prehistoric dietary change on the northern Channel Islands, California. *American Antiquity* 51:375–383.
- Walker, P. L., and Hewlett, B. S. (1990) Dental health diet and social status among Central African foragers and farmers. *American Anthropologist* 92:383–398.
- Walker, P. L., Johnson, J. R., and Lambert, P. M. (1988) Age and sex biases in the preservation of human skeletal remains. *American Journal of Physical Anthropology* 76:183–188.
- Walker, R. (1985) *Guide to postcranial bones of East African mammals*. Palo Alto, CA: Hylochoerus Press, Blackwell Scientific. 285 pp.
- Walker, R. A., and Lovejoy, C. O. (1985) Radiographic changes in the clavicle and proximal femur and their use in the determination of skeletal age at death. *American Journal of Physical Anthropology* 68:67–78.
- Walker, R. A., Lovejoy, C. O., and Cordes, R. (2009) Histomorphological variation in the appendicular skeleton. *The Open Anthropology Journal* 2:1–35.
- Wallace, D. C., and Torroni, A. (2009) American Indian prehistory as written in the mitochondrial DNA: A review. *Human Biology* 81:509–521.
- Wallin, J. A., Tkocz, I., and Kristensen, G. (1994) Microscopic age determination of human skeletons including an unknown but calculable variable. *International Journal of Osteoarchaeology* 4:353–362.
- Walrath, D., Turner, P., and Brůžek, J. (2004) Reliability test of the visual assessment of cranial traits for sex determination. *American Journal of Physical Anthropology* 125:132–137.
- Walsh-Haney, H., and Lieberman, L. S. (2005) Ethical concerns in forensic anthropology. In: T. R. Turner (Ed.) *Biological anthropology and ethics: From repatriation to genetic identity*. Albany, NY: State University of New York Press. 327 pp.
- Wapler, U., Crubézy, E., and Schultz, M. (2004) Is cribra orbitalia synonymous with anemia? Analysis and interpretation of cranial pathology in Sudan. *American Journal of Physical Anthropology* 124:333–339.
- Warden, S. J., Bogenschutz, E. D., Smith, H. D., and Gutierrez, A. R. (2009) Throwing induces substantial torsional adaptation within the midshaft humerus of male baseball players. *Bone* 45:931–941.
- Washburn, S. L. (1948) Sex differences in the pubic bone. *American Journal of Physical Anthropology* 6:199–207.
- Watkins, J. (2004) Becoming American or becoming Indian? NAGPRA, Kennewick and cultural affiliation. *Journal of Social Archaeology* 4:60–80.
- Watkins, R. (in press) Variation in health and socioeconomic status within the W. Montague Cobb Skeletal Collection: Degenerative joint disease, trauma and cause of death. *International Journal of Osteoarchaeology*. Early view: www.interscience.wiley.com, DOI: 10.1002/oa.1178.
- Watson, J. T. (2008) Changes in food processing and occlusal dental wear during the early agricultural period in northwest Mexico. *American Journal of Physical Anthropology* 135:92–99.
- Weaver, D. S. (1998) Forensic aspects of fetal and neonatal specimens. In: K. J. Reichs (Ed.) *Forensic osteology: Advances in the identification of human remains* (2nd ed.). Pp. 187–203. Springfield, IL: C. C. Thomas.
- Webb, P. A., and Suchey, J. M. (1985) Epiphyseal union of the anterior iliac crest and medial clavicle in a modern multiracial sample of American males and females. *American Journal of Physical Anthropology* 68:457–466.
- Webb, S. (1987) Reburying Australian skeletons. *Antiquity* 61:292–296.
- Webster, W. P., Murray, W. K., Brinkhous, W., and Hudson, P. (1986) Identification of human remains using photographic reconstruction. In: K. J. Reichs (Ed.) *Forensic osteology: Advances in the identification of human remains* (1st ed.). Pp. 256–289. Springfield, IL: C. C. Thomas.
- Weiss, E. (2004) Understanding muscle markers: Lower limbs. *American Journal of Physical Anthropology* 125:232–238.
- Weiss, E. (2008) *Reburying the past: The effects of repatriation and reburial on scientific inquiry*. New York, NY: Nova Science Publishers. 137 pp.
- Werner, S. B., Pappagianis, D., Heindl, I., and Mickel, A. (1972) An epidemic of coccidioidomycosis among archeology students in northern California. *New England Journal of Medicine* 286:507–512.
- Wescott, D. J. (2006) Effect of mobility on femur midshaft external shape and robusticity. *American Journal of Physical Anthropology* 130:201–213.
- Wescott, D., and Srikanta, D. (2008) Testing assumptions of the Gilbert and Gill method for assessing ancestry using the femur subtrochanteric shape. *Homo* 59:347–363.

- Weston, D. A. (2008) Investigating the specificity of periosteal reactions in pathology museum specimens. *American Journal of Physical Anthropology* 137:48–59.
- Weston, D. A. (2009) Brief communication: Paleohistopathological analysis of pathology museum specimens: Can periosteal reaction microstructure explain lesion etiology? *American Journal of Physical Anthropology* 140:186–193.
- White, G. G., and King, T. F. (2007) *The archaeological survey manual*. Walnut Creek, CA: Left Coast Press. 184 pp.
- White, C., Longstaffe, F. J., and Law, K. R. (2004) Exploring the effects of environment, physiology and diet on oxygen isotope ratios in ancient Nubian bones and teeth. *Journal of Archaeological Science* 31:233–250.
- White, T. D. (1977) New fossil hominids from Laetolil, Tanzania. *American Journal of Physical Anthropology* 46:197–230.
- White, T. D. (1992) *Prehistoric cannibalism at Mancos 5MTUMR-2346*. Princeton, NJ: Princeton University Press. 492 pp.
- White, T. D. (2004) Managing paleoanthropology's nonrenewable resources: a view from Afar. *Comptes Rendus Palevol* 3:341–351.
- White, T. D. (2009a) Ladders, bushes, punctuations, and clades: Hominid paleobiology in the late Twentieth Century. In: D. Sepkoski and M. Ruse (Eds.) *The paleobiological revolution: Essays on the growth of modern paleontology*. Pp. 122–148. Chicago, IL: University of Chicago Press.
- White, T. D. (2009b) Human origins and evolution: Cold Spring Harbor, déjà vu. In: B. Stillman, D. Stewart, and J. Witkowski (Eds.) *Evolution: The molecular landscape (Cold Spring Harbor Symposia on Quantitative Biology, 74)*. Pp. 335–344. Cold Spring Harbor, NY: Cold Spring Harbor Laboratory Press.
- White, T. D. (2010) Hominid paleobiology: How has Darwin done? In: M. A. Bell, D. J. Futuyma, W. F. Eanes, and J. S. Levinton (Eds.) *Evolution since Darwin: The first 150 years*. Pp. 519–560. Sunderland, MA: Sinauer Associates.
- White, T. D., Ambrose, S. H., Suwa, G., Su, D. F., DeGusta, D., Bernor, R. L., Boissierie, J.-R., Brunet, M., Delson, E., Frost, S., Garcia, N., Giauartsakis, I. X., Haile-Selassie, Y., Howell, F. C., Lehmann, T., Likius, A., Pehlevan, C., Saegusa, H., Semperebon, G., Teaford, M., and Vrba, E. (2009) Macrovertebrate paleontology and the Pliocene habitat of *Ardipithecus ramidus*. *Science*, 326:67, 87–93.
- White, T. D., Asfaw, B., DeGusta, D., Gilbert, H., Richards, G. D., Suwa, G., and Howell, F. C. (2003) Pleistocene *Homo sapiens* from Middle Awash, Ethiopia. *Nature* 423:742–747.
- White, T. D., Asfaw, B., Beyene, Y., Haile-Selassie, Y., Lovejoy, C. O., Suwa, G., and WoldeGabriel, G. (2009) *Ardipithecus ramidus* and the paleobiology of early hominids. *Science* 326:64, 75–86.
- White, T. D., and Folkens, P. A. (1991) *Human Osteology* (1st ed.). San Diego, CA: Academic Press. 455 pp.
- White, T. D., and Folkens, P. A. (2000) *Human Osteology* (2nd ed.). San Diego, CA: Academic Press. 563 pp.
- White, T. D., and Folkens, P. A. (2005) *The Human Bone Manual*. San Diego, CA: Academic Press. 464 pp.
- White, T. D., and Toth, N. (1989) Engis: Preparation damage, not ancient cutmarks. *American Journal of Physical Anthropology* 78:361–367.
- White, T. D., WoldeGabriel, G., Asfaw, B., Ambrose, S., Beyene, Y., Bernor, R. L., Boissierie, J. R., Currie, B., Gilbert, H., Haile-Selassie, Y., Hart, W. K., Hlusko, L. J., Howell, F. C., Kono, R. T., Lehmann, T., Louchart, A., Lovejoy, C. O., Renne, P. R., Saegusa, H., Vrba, E. S., Wesselman, H., and Suwa, G. (2006) Asa Issie, Aramis, and the origin of *Australopithecus*. *Nature* 440:883–889.
- Whittaker, D. (2000) Ageing from the dentition. In: M. Cox and S. Mays (Eds.) *Human osteology in archaeology and forensic science*. Pp. 83–99. London, UK: Greenwich Medical Media, Ltd.
- Wilkinson, C. (2004) *Forensic facial reconstruction*. New York, NY: Cambridge University Press. 290 pp.
- Wilson, R. J., Algee-Hewitt, B., Jantz, L. M. (2007) Demographic trends within the Forensic Anthropology Center's body donation program. Presented at the 2007 Annual Meeting of American Association of Physical Anthropologists. p. 252.
- Willey, P. (1981) Another view by one of the Crow Creek researchers. *Early Man* 3:2.
- Willey, P., and Emerson, T. E. (1993) The osteology and archaeology of the Crow Creek massacre. *Plains Anthropologist* 38:227–269.
- Williams, E. (Ed.) (2001) *Human remains: Conservation, retrieval and analysis*. Oxford, UK: Archaeopress. 281 pp.
- Wilson, A., and Tobin, D. (2010) Hair after death. In: R. M. Trüed and D. J. Tobin (Eds.) *Aging hair*. Pp. 249–262. New York, NY: Springer.
- Wittwer-Backofen, U., Buckberry, J., Czarnetzki, A., Doppler, S., Grupe, G., Hotz, G., Kemkes, A., Larsen, C. S., Prince, D., Wahl, J., Fabis, A., and Weise, S. (2008) Basics in paleodemography: A comparison of age indicators applied to the early medieval skeletal sample of Lauchheim. *American Journal of Physical Anthropology* 137:384–396.
- WoldeGabriel, G., Ambrose, S. H., Barboni, D., Bonnefille, R., Bremond, L., Currie, B., DeGusta, D., Hart, W. K., Murray, A. M., Renne, P. R., Jolly-Saad, M. C., Stewart, K. M., and White, T. D. (2009) The geological, isotopic, botanical, invertebrate, and lower vertebrate surroundings of *Ardipithecus ramidus*. *Science*, 326:65, e61–e65.

- Wolf, D. J. (1986) Forensic anthropology scene investigations. In: K. J. Reichs (Ed.) *Forensic osteology: Advances in the identification of human remains* (1st ed.). Pp. 3–23. Springfield, IL: C. C. Thomas.
- Wood, J. W., Milner, G. R., Harpending, H. C., and Weiss, K. M. (1992) The osteological paradox: Problems of inferring prehistoric health from skeletal samples. *Current Anthropology* 33:343–370.
- Woods, R. J., and Rothschild, B. M. (1988) Population analysis of symmetrical osive arthritis in Ohio Woodland Indians (1200 years ago). *Journal of Rheumatology* 15:1258–1263.
- World Health Organization (2007) *International statistical classification of diseases and related health problems* (10th rev., version for 2007). Accessed 2010 Aug 30. Available from: <http://apps.who.int/classifications/apps/icd/icd10online/>
- Wright, L. E., and Yoder, C. J. (2003) Recent progress in bioarchaeology: Approaches to the osteological paradox. *Current Anthropology* 11:43–70.
- von Wurmb-Schwark, N., Heinrich, A., Freudenberg, M., Gebühr, M., and Schwark, T. (2008) The impact of DNA contamination of bone samples in forensic case analysis and anthropological research. *Legal Medicine (Tokyo)* 10:125–130.
- Yang, D. Y., and Watt, K. (2005) Contamination controls when preparing archaeological remains for ancient DNA analysis. *Journal of Archaeological Science* 32:331–336.
- Yekeler, E., Tunaci, M., Tunaci, A., Dursun, M., and Acunas, G. (2006) Frequency of sternal variations and anomalies evaluated by MDCT. *American Journal of Roentgenology* 186:956–960.
- Yoder, C., Ubelaker, D. H., and Powell, J. F. (2001) Examination of variation in sternal rib end morphology relevant to age assessment. *Journal of Forensic Sciences* 46:223–227.
- Zakrzewski, S. R. (2007) Population continuity or population change: Formation of the ancient Egyptian state. *American Journal of Physical Anthropology* 132:501–509.
- Zhang, Y. D., Chen, Z., Song, Y. Q., Liu, C., and Chen, Y. P. (2005) Making a tooth: Growth factors, transcription factors, and stem cells. *Cell Research* 15:301–316.
- Zimmerman, L. J. (1981) How the Crow Creek archeologists view the question of reburial. *Early Man* 3:25–26.
- Zimmerman, L. J. (1987a) Webb on reburial: A North American perspective. *Antiquity* 61:462–463.
- Zimmerman, L. J. (1987b) The impact of the concepts of time and past on the concept of archaeology: Some lessons from the reburial issue. *Archaeological Review from Cambridge* 6:42–50.
- Zimmerman, L. J. (1989) Made radical by my own: An archaeologist learns to accept reburial. In: R. Layton (Ed.) *Conflict in the archaeology of living traditions*. Pp. 60–67. London, UK: Unwin Hyman.
- Zimmerman, L. J. (1994) Sharing control of the past. *Archaeology* Nov/Dec. 65–68.
- Zimmerman, L. J. (1997) Anthropology and responses to the reburial issue. In: T. Biolsi and L. J. Zimmerman (Eds.) *Indians and anthropologists: Vine Deloria Jr., and the critique of anthropology*. Pp. 92–112. Tucson, AZ: University of Arizona Press.
- Zimmerman, M. R., and Kelley, M. A. (1982) *Atlas of human paleopathology*. New York, NY: Praeger. 220 pp.
- Zipfel, B., DeSilva, J. M., and Kidd, R. S. (2009) Earliest complete hominin fifth metatarsal: Implications for the evolution of the lateral column of the foot. *American Journal of Physical Anthropology* 140:532–545.
- Zollikofer, C. P. E., Ponce de León, M. S., and Martin, R. D. (1998) Computer-assisted paleoanthropology. *Evolutionary Anthropology* 6:41–54.
- Zollikofer, C. P. E., and Ponce de León, M. S. (2010) The evolution of hominin ontogenies. *Seminars in Cell & Developmental Biology* 21:441–452.

INDEX

A

A- 18

Abdominal muscles 232

external oblique 232, 309

internal oblique 232, 309

rectus abdominis 232, 309

transversus abdominis 232, 309

Abduction 15, 177, 577

Abductor pollicis longus muscle 305, 307

Ablation 456, 577

Abrasion

preparation 335

taphonomic 464 *see also pot polish*

Abscess 454, 455, 577

apical 538

Accessory hip and sacral facets 236

Accessory meningeal arteries 90

Accessory process 143

Accuracy 380

color (photography) 348

micro-CT 350

of measurements 344

Acetabular crease 236

Acetabular fossa 227

Acetabular margin 227, 228, 231

Acetabular notch 227

Acetabulo-cristal buttress *see iliac pillar*

Acetabulum 227, 232, 233

Achilles tendon 270, 297

Achondroplasia 450, 451, 577

ACL *see anterior cruciate ligament*

Acoustic meatus

external 43

internal 68, 70

Acromegaly 448, 577

Acromial facet 161, 162, 163

Acromion 170, 174

Actions

abduction 15

adduction 15

circumduction 15

dorsiflexion 16

eversion 16

extension 15

flexion 15

inversion 16

mastication 99

opposition 15

plantarflexion 16

pronation 16

rotation 15

stabilization

of scapula 174

supination 16

volarflexion 16

Actualistic 461, 466

ACVR1 gene 40–41

Adduction 15, 177, 577

Adductor muscles

adductor brevis 246, 311

adductor longus 246, 311

adductor magnus 246, 247, 311

Adductor tubercle 247

Adhesives

alternatives to 358

contraindicated 526

Adolescent 384, 577

Adult 577

young adult 384, 591

middle adult 384, 585

old adult 384, 586

Afar people 541–543, 545, 546, 552

AFDIL *see Armed Forces DNA Identification*

Laboratory

AFO *see associated funerary object*

Age classes 384

subadult

fetus 384, 582

infant 384, 584

child 384, 449, 456, 579

adolescent 384, 577

adult

young adult 384, 591

middle adult 384, 585

old adult 384, 586

Age determination *see estimation of age*

Agenesis 107, 577

of coccyx 226

Aging *see estimation of age*

Agnathans 175

Air abrasion 335

Ala

definition 22, 577

of ilium 227

of sacrum 219, 223, 233

of vomer 80, 83

Alare (al.) 58

Allen's fossa 252

Allo- 18

Alveolare (ids.) 55

Alveolar portion of mandible 92, 95

Alveolar process of maxilla 55, 75, 76, 77, 78

Alveolar resorption 528, 577

Alveolar ridge 57

Alveolus 103, 577

definition 18

of mandible 92

of maxilla 57, 75, 76

Alveolon (alv.) 57

Ameloblasts 107, 577

Amelogenesis 107, 577

American Academy of Forensic Sciences 359

American Association of Physical Anthropologists 375

Amerindian *see Native American*

Amino acids 496

Analysis 341–345

Anasazi 521

Anatomical neck (of humerus) 176

Anatomical position *see standard anatomical position*

Anatomical regions 21–22

Anatomy

atlases 99–100, 316

comparative 575

cross-sectional 296–315, 518

dental 104

general 573

gross (of bones) 32–34

terminology 11–24

Ancient DNA 491, 493, 494, 496, 586

Anconeus muscle 303, 307

Anemia 528

sickle cell 493

Angle

frontal 64, 65

gonial 59, 93, 94, 95, 99

inferior 166, 168, 170, 172

mastoid 64, 65, 66, 74

occipital 64, 65, 66

of rib 153, 156, 157

pelvic inclination 237

sphenoidal 64, 65

sternal 150, 151

subpubic 240

superior 170, 172

Angular spine 88, 89, 90, 98

Ankle joint 263, 268, 270 *see also talocrural joint*

Ankylosing spondylitis 443, 577

Ankylosis 577

incomplete

of horns of hyoid 460

Anlage 39, 40, 577

Annulus fibrosus 131, 577

Antagonist 32

Ante- 18

Antebrachial 21, 578

Antecubital 21, 578 *see also cubital*

Antemortem 354, 429, 433, 439, 459, 460, 468, 578

Anterior 11, 13, 578

Anterior border

of fibula 264, 266, 267 *see anterior crest*

of palatine 78

- of radius 185
 - of ulna 194
 - Anterior calcaneal facet 284
 - Anterior clinoid process 88, 89, 90, 91
 - Anterior colliculus 258, 260
 - Anterior cranial fossae 51
 - Anterior crest (of fibula) 263
 - Anterior cruciate ligament 247, 255, 311
 - Anterior division of sacral nerve 220
 - Anterior gluteal line 227
 - Anterior groove 260
 - Anterior inferior iliac spine 232
 - Anterior intercondylar area 255
 - Anterior lacrimal crest 58, 75, 76, 77
 - Anterior margin (of fibula) *see anterior crest*
 - Anterior nasal aperture 43, 51, 55, 58, 84, 96, 97, 588
 - Anterior nasal spine 75, 76
 - Anterior oblique line 185–188, 198
 - Anterior obturator tubercle 233
 - Anterior sacral foramen 220
 - Anterior scalene muscle 156
 - Anterior superior iliac spine 226, 232, 235
 - Anterior surface
 - of radius 185, 187, 188
 - of ulna 193
 - Anterior talar facet 278
 - Anterior talofibular ligament 314–315
 - Anterior tubercle
 - of C-1 136
 - of transverse process 138
 - Anterolateral surface
 - of humerus 179
 - Anteromedial surface
 - of humerus 178
 - Anti- 18
 - Antimere 578
 - Anular ligament 307
 - Anvil striae *see percussion striae*
 - Aortic impression 139, 140, 141
 - Aperture
 - lens 345–347, 560
 - nasal
 - anterior 43, 51, 55, 58, 84, 96, 97, 588
 - posterior 80
 - septal 180, 184, 478
 - Apex
 - of fibula *see styloid process*
 - of patella 252
 - of sacrum 222
 - of tooth cusp 106
 - of tooth root 106
 - Apex (ap.) 56
 - Apical 15, 578
 - Apical abscess
 - in Atapuerca fossils 538
 - Apical bone 98
 - Apical foramen 106
 - Apo- 18
 - Apophysis 34, 135, 578
 - Appendicular skeleton 11, 578
 - Appositional growth 35, 38
 - Approximal *see interproximal*
 - Arachnoid foveae 62, 65, 66
 - Arachnoid granulations 62, 66
 - Arachnoid (membrane) 62
 - Aramis 541–558
 - Arcade, dental 103, 104
 - Arch
 - definition 22
 - neural *see vertebral arch*
 - pubic 237
 - superciliary 60, 61, 63
 - vertebral 132
 - zygomatic 45, 47, 48, 58, 86, 99
 - Archaeological Resources Protection Act 357
 - Archaeological sites *see also paleontological sites*
 - arctic 462
 - Bordeaux Trading Post 320
 - CA-LAS-7 325
 - Cottonwood Canyon 522–532
 - Crow Creek 363, 364, 367
 - Egypt 462
 - Engis 336
 - Herculaneum 1
 - Kennewick 357, 368–369, 372
 - Lake Turkana 541
 - Libben 446, 486
 - Little Big Horn 357
 - Mancos Canyon 530
 - Mesa Verde 521
 - Nuvakwewtaqa 372
 - Olduvai Gorge 541
 - Omo valley 541
 - Peruvian desert 462
 - Petralona 335
 - Spitsbergen 365
 - Stillwater marsh 513–519
 - Zhoukoudian 521
 - Arcuate line 232
 - Ardipithecus ramidus* 541–558
 - Area
 - triangular subcutaneous 264, 267
 - Arikara 363
 - Armed Forces Institute of Pathology (AFIP) 317
 - ARPA *see Archaeological Resources Protection Act*
 - Artery
 - aorta
 - impression for 139
 - greater palatine 77, 78
 - terminal branch 77
 - intercostal 153
 - internal acoustic 70
 - internal carotid 70
 - lateral sacral 220
 - meningeal 61
 - middle 61, 66
 - mylohyoid 95
 - nasopalatine 80
 - nutrient 180
 - obturator 233
 - occipital 67, 68
 - stylomastoid 70
 - subclavian 156, 157
 - supraorbital 61
- Arthritis 441, 578
 - osteoarthritis 441
- Arthropathy 578
- Articular cartilage 31
- Articular circumference
 - of radius 184, 187
 - of ulna 195
- Articular eminence 69, 71
- Articular facets
 - inferior 132, 133, 134, 136, 139
 - sacral 221, 222, 223
 - superior 132, 133, 136, 139, 142
- Articular fovea 184
- Articularis genu muscle 311
- Articular process
 - inferior 132, 133, 134, 136, 139
 - sacral 221, 222, 223
 - superior 132, 133, 136, 139, 142
- Articulated 578
- Articulation 17, 578
 - of foot bones 271
 - of hand bones 199
- Artifacts
 - funerary objects 320, 323, 325
- Artificial cranial deformation 437, 438, 528
- Artificial dental modification 456–457
- Ascending ramus 91, 94
- Associated funerary object (AFO) 320, 323, 325
- Associations and committees
 - American Academy of Forensic Sciences 359
 - American Association of Physical Anthropologists 375
 - National Association for the Practice of Anthropology 377
- Asterion (ast.) 58, 65
- Asterionic bone 98
- Asternal ribs *see "false" ribs*
- Astragalus *see talus*
- Asymmetry, dental 482
- Atlas 71, 73, 136
- Atrophy 578
- Attrition, dental 101, 578
- Auditory exostosis 98, 578
- Auditory ossicles 71
 - incus 71

- malleus 71
- stapes 71
- Auricular (au.) 58
- Auricular surface
 - of ilium 227, 232, 234
 - confusion with sacrum 223, 233
 - of sacrum 220, 222, 223
 - confusion with ilium 223, 233
- Australopithecus anamensis* 542
- Avulsion 578
- Axial skeleton 11, 578
- Axillary 21, 578
- Axillary border *see lateral border*
- Axis (named vertebra) 136
- Axis
 - distal articular 183, 184
 - dorsoplantar 290, 294
 - midhumeral 183, 184
- Aztec 521
- B**
- Bacterial infections 444–446
- Ball-and-socket joint 29, 578
- Bar, pterygo-alar 98
- Base
 - of capitate 206
 - of foot phalanx 292
 - of hamate 207
 - of hand phalanx 215, 291
 - of metacarpal 209
 - of metatarsal 285
 - of patella 252
 - of sacrum 219
 - of third cuneiform 283
 - skull 43
- Basi- 18
- Basicranium 578
- Basilar part 72
- Basilar suture 48, 50, 57, 72, 589
- Basion (ba.) 57, 96
- Basivertebral vein 132
- Bass collection 382
- Bear teeth
 - confusion with human teeth 110
- Bedacryl 122x 332
- Bi- 18
- Biauricular breadth 96
- Biceps brachii muscle 184, 197, 295–296, 304–305
 - long head 170, 177
- Biceps bursa 184
- Biceps femoris muscle 263, 311, 315
 - long head 232
 - short head 247
- Bicondylar breadth (of mandible) 96
- Bicuspid *see premolars*
- Bifid 22, 578
- Bifid ribs 158
- Bifurcated 22, 578
- Bigonial breadth 96
- “Billowed” appearance
 - of immature vertebrae 135
- Bilobate 22, 578
- Bioarchaeology 1, 513
- Biological distance 480
- Biology
 - bone 25–42
 - developmental 39
 - population 475–490
- Biomechanical length
 - of femur 251
 - of humerus 183
 - of radius 190
 - of tibia 262
 - of ulna 197
- Biorbital breadth 96
- Bizygomatic breadth 96
- Blastic lesions 431
- BMP *see bone morphogenetic protein*
- Body
 - of calcaneus 279
 - of hyoid 129
 - of ilium 227, 229
 - of ischium 227, 229, 231, 232
 - of mandible 91, 92, 94
 - of pubis 227, 231, 232, 233
 - of scapula 170
 - of sphenoid 87, 89
 - of talus 276
 - of vertebra 131, 132, 136, 139, 142, 143
 - cervical 136
 - lumbar 143
 - thoracic 139
 - pisiform 205
- Bone
 - cancellous 32, 579
 - coarsely bundled bone 35
 - compact 32, 579
 - cortical 580
 - lamellar 35, 36, 40, 405, 406, 585
 - woven 35, 36, 40, 446
- Bone biology 25–42
- Bone board *see osteometric board*
- Bone histology 36
- Bone modification
 - abrasion 464
 - carnivore marks 468
 - chop marks 469
 - cut marks 468, 469
 - fire 464
 - percussion marks
 - pits 470, 471
 - striae 470
 - pot polish 470
 - root etching 524
- Bone morphogenetic protein 40
 - BMP-3 40
- Bone repair 40–41
- Bone, types *see types of bone*
- Bordeaux Trading Post 320
- Borders
 - anterior
 - of fibula 264, 266, 267 *see anterior crest*
 - of palatine 78
 - of radius 185
 - of ulna 194
 - axillary *see lateral border*
 - cranial *see superior border*
 - interosseous
 - of fibula 264, 265, 266
 - of radius 185, 186, 187, 189
 - of ulna 185, 189, 191, 193, 194, 195, 196, 197
 - lateral
 - of humerus 176, 177, 179
 - of scapula 165
 - medial
 - of humerus 179
 - of scapula 166, 170
 - posterior
 - of fibula 265, 267 *see posterior crest*
 - of palatine 78
 - of perpendicular plate of vomer 79
 - of radius 186
 - of ulna 194
 - of vomer 80
 - posteromedial
 - of fibula 265, 266
 - superior
 - of scapula 165
 - vertebral *see medial border*
- Boss 17, 578
- Bowing
 - femoral 252
 - tibial 263
- Brachi- 18
- brachial 18
- Brachial 21, 578
- Brachialis muscle 192, 303, 307
- Brachial plexus, inferior trunk 156
- Brachioradialis muscle 187, 303, 305
- Brachy- 18
- Brachydactyly 217
- Brachymesophalangy 218
- Brain
 - cerebellum 51, 90
 - cerebellar lobes 74
 - cerebrum 74
 - frontal lobe 51, 60, 62, 90
 - occipital lobe 67, 74
 - temporal lobe 51, 67
- Brainstem 71
- Breakage *see postmortem fractures*
- dental 101
- Breastbone *see sternum*
- Bregma (b.) 55, 56, 63, 64, 96
- Bregmatic bone 98

- Bridge
 pterygo-alar 98
 pterygospinous 98
 retroarticular 146
- Brim
 pelvic 237
- Brittle bone disease *see osteogenesis imperfecta*
- Buccal
 cusp 105, 115, 117, 118, 123, 125
 direction 14, 103, 105, 578
 region 21
- Buccinator muscle 92, 299
- Buccolingual 15, 578
- Burial 460, 515–520, 516–520, 578, *see also cremation*
 articulated 578
 disarticulated 581
 extended 327, 582
 flexed 322, 323, 582
 multiple 323, 586
 primary 321, 323, 460, 588
 secondary 323, 589
 ossuary 586
- Burial object *see funerary object*
- Bursa, biceps 184
- Buttress
 acetabulo-cristal *see iliac pillar*
 endocoronoid *see endocoronoid ridge*
- C**
- C3 plants 484, 519
 C4 plants 484, 519
 CA-LAS-7 325
 Calcaneal body 279
 Calcaneal tuberosity 277–279
 Calcaneofibular ligament 284
 Calcaneus 272, 273, 276, 277–279, 280, 283, 294
 Calculus 106, 456, 483, 578
 California Environmental Quality Act 357
- Callus
 definition 578
 primary bony 40, 433, 435, 588
- Calotte 51, 578
- Calvaria 51, 579
- Canal *see also canaliculus, meatus*
 canaliculi 34, 35, 37
 carotid 69, 70
 condylar 73
 definition 18, 579
 haversian 34, 37, 583, 585
 hypoglossal 72, 73, 75, 98
 incisive 77
 infraorbital 75
 lacrimal 77, 81, 84
 mandibular 95
 obturator 233
 optic 87, 89
 pterygoid 88, 91
 pterygopalatine 78, 79
 sacral 220
 vertebral 71
- Canaliculus 18, 34, 35, 37, 579
- Cancellous bone 32, 579
- Cancer 452–454
- Canine fossa (of maxilla) 75, 76
- Canine jugum 75, 76
- Canines 103, 112
- Cannibalism 521–532
- Cape Town Univ. collection 382
- Capitate 200, 201, 202, 206–207, 209
- Capitate base 206
- Capitulum 177, 180, 181, 184
- Carabelli's effects 342, 481, 579
 on upper first molar 106
- Carcinoma 579
- Caries 107, 455, 483, 579
- Cariogenic foods 455, 483
- Carnivore marks 468
- Carotid plexus 70
- Carpal 21, 579
- Carpal articular surface 187
 for lunate 189
 for scaphoid 189
- Carpal bone 199, 202–208, 209
 capitate 200, 201, 202, 206–207, 209
 hamate 17, 200, 201, 202, 207–208, 209
 lunate 200, 201, 202, 203
 pisiform 200, 202, 204–205, 208
 scaphoid 200, 201, 202–203
 trapezium 200, 201, 202, 205, 209
 trapezoid 200, 201, 202, 206, 209
 triquetral 200, 201, 202, 204
- Carpal tunnel 202
- Carson Sink 514–520
- Cartilage 28, 37, 579
 articular 31
 costal 151, 153
 hyaline 29, 30, 583
 intervertebral disk 131, 147
 annulus fibrosus 131
 nucleus pulposus 131
 thyroid 129
- Cartilaginous joint 30, 579 *see synchondrosis*
- Case Western Reserve University 365
- Casting and molding 351–352, 492, 574
 of "Ardi" 555–557
 inhibition 337
 for SEM work 350
- Category, of tooth 103
- CAT scan *see computed tomography*
- Caudal 13, 579
- Caudal edge (of rib) 153, 155, 157
- Caudal limb, of auricular surface 227
- Cavity
 pelvic 237
 tooth *see caries*
- CEJ *see cementoamel junction*
- Cell
 ameloblast 107
 chondroblast 39
 fibroblast 40
 mastoid 67
 mesenchymal stem cell 39
 osteoblast 37, 38, 39, 40
 osteoclast 37
 osteocyte 35, 37
 red blood cell 448–450
 white blood cell 450
- Cement line 36
- Cementoamel junction (CEJ) 105, 579
- Cementum 104, 579
 -cep, -ceps 18
- Cephalic 21
 direction 13
 region 579
- Cephalopelvic disproportion 239
- CEQA *see California Environmental Quality Act*
- Cerebellar fossa 73, 74
- Cerebellar lobe 74
- Cerebellum 51, 90
- Cerebral fossa 73, 74
- Cerebrum 74
- Cervical 15, 21, 22, 579
- Cervical rib 146, 158
- Cervical vertebrae 136–139
- Cervix 22
 of tooth 105
- CHAID *see chi-squared automatic interaction detection*
- Chain of custody 328, 334
- Cheek teeth *see molars, premolars*
- Child 384, 579
- Child abuse 436, 507–512
- Chi-squared automatic interaction detection 414
- Chondro- 18
- Chondroblast 39
- Chondrosarcoma 453
- Chop mark 468, 469
- Christ Church (Spitalfields) collection 382
- Chumash tribe 362
- Cingulum 106
- Circulatory disorder 440–441
- Circum- 18
- Circumduction 15, 170
- Circumflex sulcus 173
- Clavicle 161–165
- Clavicular anteroposterior midshaft diameter 165
- Clavicular facet 170, 172
- Clavicular notch 149, 150
- Clavicular superoinferior midshaft diam-

- eter 165
- Cleaning *see washing*
- Cleft *see fissure*
- Cleft patella 254
- Cleveland Metropolitan General Hospital 503
- Clinoid process
 - anterior 88, 89, 91
 - posterior 78, 88, 89
- Clivus 87
 - nasoalveolar 76, 77
 - occipital 74, 89
- Cloaca 445, 446
- Clubbed thumb 218
- Cnemial 21, 579
- Coarsely bundled bone 35
- Cobb, W. Montague collection 382
- Coccygeal agenesis 226
- Coccygeal cornua 225–226
- Coccygeal fusion 226
- Coccygeus muscle 309
- Coccyx 219, 225–226
- Coimbra cemetery collection 382
- Collagen 27, 29, 35, 37, 40, 447, 462, 484, 579
- Collateral ligament
 - of elbow
 - radial (lateral) 180
 - ulnar (medial) 181, 195, 307
 - of fingers 31
 - of knee
 - lateral 247, 263
 - medial 247
 - of wrist 215, 218
 - radial 305
- Collections, documented skeletal 382–383
- Colliculus
 - anterior 258, 260
 - posterior 260
- Color accuracy 348
- Commingled 579
- Comminuted fracture 579
- Compact bone 32, 579
- Complete fracture 433, 434, 579
- Compound fracture 433, 579
- Compressed fracture 434, 518
- Computed tomographic (CT) scanning 516, 579, 580
- Computing 352
- Con- 19
- Concave 22
- Conchal crest 78, 79
- Condylar canal 73
- Condylar foramen 72, 73
- Condylar fossa 72, 73, 75
- Condylar neck 92, 93, 94
- Condylar part 72
- Condyle
 - definition 17, 580
 - lateral
 - of femur 242, 243, 245, 247, 248
 - of tibia 254
 - mandibular 59, 69, 92, 93, 94
 - medial
 - of femur 242, 243, 244, 247, 248
 - of tibia 254
 - occipital 72
 - in determinations of sex 412
- Condylion laterale (cdl.) 59
- Condylion mediale (cdm.) 59
- Condylion superior (cs.) 59
- Congenital disorders 439
- Conjoining *see refitting*
- Conoid 22, 580
- Conoid ligament 162, 301
- Conoid tubercle 162, 163
- Consolidants 321
 - and digitization 341
 - and labelling 355
 - and repatriation 362
 - use on fossil 550, 554
- Contamination
 - of DNA 493–494
- Context, archaeological 321
- Continuous variables 342
- Convex 22, 580
- Coprolites 483
- Coracobrachialis muscle 303
- Coracoclavicular ligament 301
- Coracohumeral ligament 303
- Coracoid 22
- Coracoid process 162, 165, 170, 171, 172, 197
- Cornua
 - of coccyx 225–226
 - of hyoid *see greater and lesser horns*
- Coronale (co.) 58
- Coronal ossicle 98
- Coronal plane 580
- Coronal suture 44, 45, 47, 48, 49, 50, 52, 56, 58, 62, 63, 66, 580
- Coronion (cr.) 59
- Coronoid 22
- Coronoid fossa 180, 181
- Coronoid process 59, 92, 94, 95, 99, 180, 191–193
- Corpus sterni 150, 151, 152
- Corrugator supercilii muscle 299
- Cortical bone 580
- Cost- 19
- Costal 21, 580
- Costal angle 157
- Costal cartilage 151
- Costal facet 139
- Costal fovea 139
- Costal groove 153, 155, 156, 157
- Costal notch (of sternum) 149, 150, 151
- Costal surface (of scapula) 174
- Costal tuberosity *see costoclavicular impression*
- Costoclavicular impression 161
- Costoclavicular ligament 161, 301
- Costoclavicular sulcus 165
- Cottonwood Canyon 522–532
- Coxal 21, 580
- Cradle-boarding *see cranial deformation*
- Cranial 11, 13, 580
- Cranial base length 96
- Cranial border *see superior border*
- Cranial breadth-height index 97
- Cranial capacity 54
- Cranial deformation, artificial 437, 438, 528
- Cranial edge (of rib) 153, 155
- Cranial fossae
 - anterior 51
 - middle 51, 90
 - posterior 51
- Cranial index 97, 342
- Cranial length-height index 97
- Cranial limb of auricular surface 227
- Cranial malformations 439
- Cranial module 79
- Cranial nerve 1 (olfactory) 82
- Cranial nerve 5 (trigeminal)
 - inferior alveolar nerve 95
 - infraorbital nerve 75
 - mandibular nerve 90
 - maxillary nerve 90
 - mental nerve 92
 - supraorbital nerve 61
 - zygomaticofacial nerve 86
 - zygomaticotemporal nerve 86
- Cranial nerve 7 (facial) 70
- Cranial nerve 12 (hypoglossal) 73
- Cranial suture 18, 32, 52, 580, 590
 - basilar 48, 50, 57, 72, 589
 - coronal 44, 45, 47, 48, 49, 50, 52, 56, 58, 62, 63, 66, 580
 - frontolacrimal 58
 - frontomaxillary 44, 45, 58
 - frontonasal 44, 45, 52, 55
 - frontozygomatic 44, 45, 47, 58
 - intermaxillary 45, 77
 - internasal 45, 55, 85
 - lacrimomaxillary 58
 - lambdoid 44, 46, 47, 48, 49, 50, 56, 58, 74, 75, 91, 98, 585
 - median palatine 48, 57
 - intermaxillary portion 46, 48, 57
 - interpalatine portion 48
 - metopic 45, 52, 61, 63, 85, 97, 585
 - nasomaxillary 44, 47
 - occipitomastoid 44, 46, 48, 50, 53, 58, 73, 98
 - parietomastoid 44, 46, 53, 58, 68
 - premaxillary 77

- sagittal 52, 56, 589
 premature closure *see scaphocephaly*
 sphenofrontal 44, 50
 sphenosquamous 69, 70
 sphenotemporal 44, 48, 50
 squamous 44, 46, 66, 70, 589
 transverse palatine 48
 zygomaticomaxillary 52
 zygomaticotemporal 44, 47, 48, 71
- Craniometric landmarks 54–58**
 alare (al.) 58
 alveolare (ids.) 55
 alveolon (alv.) 57
 apex (ap.) 56
 asterion (ast.) 58, 65
 basion (ba.) 57, 96
 bregma (b.) 55, 56, 63, 64, 96
 condylion laterale (cdl.) 59
 condylion mediale (cdm.) 59
 condylion superior (cs.) 59
 coronale (co.) 58
 coronion (cr.) 59
 dacryon (d.) 58
 ectoconchion (ec.) 58
 ectomolare (ekm.) 58
 endobasion 57
 endomolare (enm.) 58
 euryon (eu.) 58
 frontomolare orbitale (fmo.) 58
 frontomolare temporale (fmt.) 58
 frontotemporale (ft.) 58
 glabella (g.) 55, 56
 gnathion (gn.) 57
 gonion (go.) 59
 hormion (ho.) 57
 incision (inc.) 55
 infradentale (id.) 57
 inion (i.) 56
 jugale (jg.) 58, 85
 lacrimale (la.) 58
 lambda (l.) 56, 65, 74
 mastoidale (ms.) 58
 maxillofrontale (mf.) 58
 mentale (ml.) 59
 metopion (m.) 55
 nasion (n.) 55
 nasospinale (ns.) 55
 obelion (ob.) 56, 98
 opisthion (o.) 56
 opisthocranion (op.) 56
 orale (ol.) 57
 orbitale (or.) 54, 58, 76
 pogonion (pg.) 57
 porion (po.) 54, 56, 58
 prosthion (pr.) 55, 96
 pterion (pt.) 58
 rhinion (rhi.) 55
 sphenobasion (sphba.) 57
 staphylion (sta.) 57
- stephanion (st.) 58
 vertex (v.) 56
 zygion (zy.) 58
 zygomaxillare (zm.) 58
 zygoorbitale (zyo.) 58
- Craniostosis *see craniosynostosis***
Craniosynostosis 439, 580
Cranium 51, 580
 fragments
 confusion with iliac frags. 233
Cremation 323, 325, 499–505, 580
Crenulate 22, 580
Crescent of foramina 90
Crest
 anterior
 of fibula 263
 conchal 78, 79
 crista galli 82, 83
 definition 17, 580
 external occipital 72
 for triceps brachii 180
 frontal 61, 62
 iliac 34, 229, 232, 233, 236
 infratemporal 88, 89, 90
 internal occipital 73, 74
 interosseous *see interosseous border*
 of fibula 268
 of tibia 255
 intertrochanteric 243, 244, 246
 lacrimal
 anterior 58, 75, 76, 77
 posterior 58, 83
 lateral supracondylar 176, 177, 179, 181
 longitudinal 194
 medial supracondylar 181
 median sacral 221
 nasal 78
 nuchal
 in sex determination 411
 oblique *see posteromedial border*
 obturator 233
 of greater tubercle 177
 of lesser tubercle 178
 of rib head 153
 of rib neck 153, 155
 of teeth 106
 posterior
 of fibula 263
 posteromedial *see posteromedial border*
 pubic 232
 sacral
 intermediate 221
 lateral 221, 222
 median 221
 sphenoidal 87, 88, 90
 supinator 191
 supramastoid 67, 68
 suprameatal 67, 68
 suprastylloid 185, 187, 188
- Cribræ cranii 449
 Cribræ orbitalia 449, 519, 580
 Cribriform plate 82
 Crime scenes 322–321
 Crista galli 82, 83
 Cristal 22
 Cristal tubercle *see iliac tubercle*
Cross sections
 of femur 311
 of fibula 315
 of foot phalanges 217, 293
 of hand phalanges 217, 293
 of humerus 303
 of metacarpals 217, 293
 of metatarsals 217, 293
 of radius 305
 of tibia 313
 of ulna 307
 Cross striæ 580, 590
 Crow Creek 363, 364, 367
 Crowding, dental 479
 Crown 104, 105, 106, 110
 Cruciate 22, 580 *see also cruciform*
 Cruciate ligaments 313
 anterior 247, 255, 311
 posterior 247, 255, 311
 Cruciform 22, 580 *see also cruciate*
 Cruciform eminence 73, 74
 Crural 21, 580
 CT scanning *see computed tomography*
 Cubital 21, 580
 Cuboid 272–277, 280–281, 282, 283, 289
 Cuboid tuberosity 280
 Cultural affiliation 365
 Cuneiform 276, 281
 intermediate 272–275, 281, 282
 lateral 272, 273, 282–283
 medial 272–275, 281
 shape term 22, 580
 Curation 355
 Cusp 106, 580
 buccal 105, 115, 117, 118, 123, 125
 entoconid 105, 106
 hypocone 105, 106
 hypoconid 105, 106
 hypoconulid 105, 106
 lingual 105, 115, 117, 118, 123, 125
 metacone 105, 106
 metaconid 105, 106
 paracone 105, 106
 protocone 105, 106
 protoconid 105, 106
 Cusp patterns
 tribosphenic 106
 Y-5 106
 Cuspids *see canines*
 Custody *see chain of custody*
 Cutaneous 21, 580
 Cut mark 468, 469, 522, 531

- Cyanoacrylate 332
-cyte 19
- D**
- Dacryon (d.) 58
Dakota 363
Dart collection 382
Datum, site 321
Daubert decision 360, 361
Deciduous teeth 103, 580
Decision analysis 413
Deep 13, 580
Deep transverse fascia 255
Defleshing 469
Deformation, artificial 437, 438, 528
Dehiscence 580
DEJ *see dentinoenamel junction*
Delta values 484
 $\delta^{13}\text{C}$ 484, 485
 $\delta^{15}\text{N}$ 484, 485
Deltoid 22, 580
Deltoideus muscle 162, 163, 170, 179, 240,
 301, 303
Deltoid ligament 260, 313
Deltoid tuberosity 179–181
Demi- 19
Demineralization, dental 101, 107
Demography 485–487, 580
Dens 136
Dental anatomy 104
Dental arcade 580
Dental asymmetry 482
Dental attrition 101
Dental calculus 456
Dental caries 455, 483
Dental clone theory 108
Dental formula 103, 581
Dental hypoplasia 107, 455–456, 482,
 519–520, 538, 581
Dental microwear
 and scanning electron microscopy 482
Dental morphogenic field theory 108
Dental mutilations 456
Dental plaque 455, 581
Dental terminology 103
Dental wear 101, 389, 390, 454, 482, 483
Dentin 101, 104, 105, 581
Dentine *see dentin*
Dentinoenamel junction (DEJ or EDJ) 105,
 580, 581, 582
Dentinogenesis 107
Dentition 102, 103, 581
 deciduous 103
 permanent 103, 111
Deoxyribonucleic acid *see DNA*
Departmental Consulting Archaeologist
 and Archaeology and Ethnography
 Program *see National Park Service*
Department of the Interior 366
National Park Service 366, 367
 Departmental Consulting Archaeolo-
 gist and Archaeology and Ethnog-
 raphy Program 366
 U.S. Fish and Wildlife Service 519
Depressor anguli oris muscle 299
Depressor labii inferioris muscle 299
Depressor septi nasi muscle 299
Dermal 21, 581
Dermal armor 161
Determination of age *see estimation of age*
Determination of identity *see individuation*
Determination of sex *see sex determination*
Developmental biology 39
Developmental groove 104
Deviation 343
 standard 343
Di- 19
Dia- 19
Diachronic 581
Diagenesis 484, 494, 496, 581
Diaphysis 17, 34, 581
Diet 482–484
Dietary microfossil 483
Dietary reconstruction 483, 519
Diffuse idiopathic skeletal hyperostosis
 443, 581, 583
Digastric fossa 93
Digastric muscle 68, 93, 299
Digital 21, 581
Digital photography 345–349, 574
Diphyodont 581
Diploë 233
Directional terms 13–15 *see also planes of*
 reference
 anterior 11, 13, 578
 apical 15, 578
 buccal 14, 103, 105, 578
 buccolingual 15
 caudal 13
 cephalic 13
 cervical 15, 22, 579
 cranial 13, 580
 deep 13, 580
 distal 13, 14, 103
 applied to foot bones 271
 dorsal 13, 14, 202, 581
 applied to foot bones 271
 ectocranial 13
 endocranial 13
 external 13, 582
 extrinsic 13
 incisal 15, 584
 inferior 13
 internal 13, 584
 interproximal 14
 intrinsic 13
 labial 14, 103, 105
 labiolingual 15
 lateral 13
 left 11
 lingual 14, 103
 medial 13, 14
 mesial 14, 103
 mesiodistal 15
 occlusal 586
 palmar 14, 202, 587
 plantar 14, 271, 588
 posterior 11, 13, 588
 proximal 13
 applied to foot bones 271
 radial 202
 right 11
 subcutaneous 13, 590
 superficial 13, 590
 superior 13
 ulnar 202
 ventral 13, 591
 volar 14, 591
Dis- 19
Disarticulated 581
Disarticulation 468, 532
 cut marks 472
Discontinuous morphological traits
 see nonmetric traits
Discontinuous variables 342, 581
Discrete traits *see nonmetric traits*
Discrete variable 342, 581
Discriminant functions 412
Diseases and disturbances
 abscess 455
 apical 538
 achondroplasia 450, 451
 acromegaly 448
 anemia 448–450, 528
 ankylosing spondylitis 443
 bone tumors 452–453
 caries 455
 chondrosarcomas 453
 craniosynostosis 439
 diffuse idiopathic skeletal hyperostosis
 443
 enamel hypoplasia 107, 455–456, 482,
 519–520, 538, 581
 endocrine disturbances
 acromegaly 448
 eosinophilic granuloma 450
 Ewing's sarcoma 453
 fibrodysplasia ossificans progressiva
 40–41, 451–453
 fibrosarcomas 453
 gigantism 448
 Hand-Schüller-Christian disease 450
 Huntington's disease 493
 hydrocephaly 439
 kyphosis 440
 langerhans cell histiocytosis 450
 Legg-Calvé-Perthes disease 440

- Letterer-Siwe disease 450
 leukemia 450
 microcephaly 439
 multiple myeloma 450
 osteitis 443
 osteoarthritis 441, 442, 517–520
 osteochondritis dissecans 440
 osteochondroma 453
 osteomalacia 447
 osteoma 452
 osteomyelitis 443, 444, 445
 osteoporosis 447
 osteosarcoma 452
 periodontitis 454
 periostitis 443, 446, 519
 pituitary dwarfism 448
 porotic hyperostosis 449–450
 red blood cell disorders 448–450
 rheumatoid arthritis 443
 rickets 447
 scoliosis 440
 scurvy 447
 sickle cell anemia 448, 493
 spina bifida 439
 syphilis 444
 treponemal infection 444
 tuberculosis 444
 white blood cell disorders 450
- DISH *see diffuse idiopathic skeletal hyperostosis*
- Dislocation 436
 of shoulder joint 174
- Displaced fracture 434
- Distal 13, 14, 103, 581
 applied to foot bones 271
- Distal articular axis 183, 184
- Distal foot phalanx 292
- Distal hand phalanx 216
- Distal phalangeal tubercle 292
- Distal phalangeal tuberosity 216
- DNA 39, 40, 107, 412, 423, 425, 432, 491–498, 581, 586
 ancient 491, 493, 494, 496
 Neanderthal 7, 496
 ancient DNA 586
 contamination of 493–494
 extraction of 494
 mitochondrial 494, 495, 496, 517, 586
 Neanderthal nuclear genome 7, 496
 nuclear 491, 494, 496
 taphonomy of 494
- Documented skeletal collections 382–383
 Bass coll. 382
 Cape Town Univ. coll. 382
 Christ Church (Spitalfields) coll. 382
 Coimbra cemetery coll. 382
 Hamann-Todd coll. 382
 Huntington coll. 382, 404
 J.C.B. Grant coll. 382
- Maxwell coll. 382
 Museu Bocage coll. 382
 NMNH Fetal coll. 382
 Pretoria bone coll. 382
 St. Bride's Church coll. 382
 St. Thomas' cemetery 382
 Terry coll. 382, 404, 420
 Universiteit Leiden coll. 382
 Univ. of Iowa/Stanford coll. 382
 W. Montague Cobb coll. 382
- Dorsal 14, 21, 202, 581
 applied to foot bones 271
 direction 13
- Dorsal pitting 237, 399–397
- Dorsal radioulnar ligament 305
- Dorsal sacral foramen *see posterior sacral foramen*
- Dorsal tubercle 186, 187, 188, 189
- Dorsal wall of sacrum 221, 222, 223
- Dorsiflexion 16, 195, 581
- Dorsoplantar 290, 294
- Dorsum sellae 87, 89, 90
- Dura mater 61, 62, 66, 82, 90
- Dwarfism, pituitary 448
- Dysplasia 581
- E
- Eburnation 441, 442, 582
- Ecto- 19
- Ectoconchion (ec.) 58
- Ectocranial 13, 582
- Ectomolare (ekm.) 58
- Edentulous 582
- Edge
 caudal (of rib) 153, 155, 157
 cranial (of rib) 153, 155
- EDJ *see dentinoenamel junction*
- Elbow joint 174
- Elevation 174
- Eminence
 cruciform 73, 74
 definition 16, 582
 frontal 60
 iliopectineal *see iliopubic eminence*
 iliopubic 229, 231, 232
 intercondylar 254, 255, 261, 262
 mental
 in sex determination 411
- Emissary vein 73
- Enamel 104–107, 110, 582
- Enamel hypoplasia 107, 455–456, 482, 519–520, 538, 581
- Endo- 19
- Endobasion 57
- Endochondral ossification 37, 582
- Endocoronoid ridge 92, 95
- Endocranial 13, 582
- Endocrine disorders 448
 acromegaly 448
 gigantism 448
 pituitary dwarfism 448
- Endomolare (enm.) 58
- Endosteum 34, 39, 582
- Engis 336
- Entoconid 105
- Entoglenoid process 68, 69
- Eosinophilic granuloma 450–454
- Epi- 19
- Epicondyle
 definition 17, 582
 lateral
 of femur 242, 243, 245, 247
 of humerus 176, 177, 179, 180, 181, 183, 197
 medial
 of femur 242, 243, 244, 247, 248
 of humerus 180, 181, 183, 184, 197
- Epigenetic variants *see nonmetric traits*
- Epiphyseal plate 38
- Epiphysis 17, 34, 582
 traction *see Apophysis*
- Epipteris bone 98
- Error
 interobserver 430, 584
 intraobserver 430, 584
 measurement 342
 standard 343, 344
- Eruption
 dental 107, 385–387
 volcanic 546
- Estimation of age
 from teeth
 adults 387–389
 subadults 385–387
- methods
 auricular metamorphosis 400–404
 bone microstructure 405–407
 dental attrition 389, 390
 dental development 386–388
 epiphyseal closure 391–395
 long bone lengths 391–392
 radiographic analysis 405
 symphyseal metamorphosis 394–400
 seriation 380, 384, 387, 388, 405, 411
 sternal rib end 404–405
 suture closure 389–390
 multifactorial estimates 406
- Estimation of sex *see sex determination*
- Ethics 357, 362, 375
 and photography 348–349
- Ethmoid air cells 82
- Ethmoidal notch 62, 63, 66, 82
- Ethmoidal process (of inf. nasal concha) 81
- Ethmoid bone 50, 82–83
- ETL *see excessive tooth loss*
- Euryon (eu.) 58
- Eversion 16, 582
- Evolution of bone from dermal armor 161

- Evulsion 456, 582
 Ewing's sarcoma 453
 Excavation 319–329
 of burial 322
 equipment 324
 of fetal remains 322, 328
 Excessive tooth loss
 affecting sex determination 414
 Exostosis 582
 Expanded sacral hiatus 225–226
 Expert witnesses 359–360
 Extant 26
 Extended 582
 Extended burial 327
 Extension 15, 17, 32, 180, 197, 198, 582
 Extensor carpi ulnaris groove 192, 194, 195, 196, 197
 Extensor muscles
 of forearm 180, 185, 187
 extensor carpi radialis 187, 189
 brevis 303
 longus 303
 extensor carpi ulnaris 192, 194–197, 307
 extensor digitorum 32
 extensor indicis 307
 extensor pollicis brevis 305
 extensor pollicis longus 187, 189, 307
 of leg
 extensor digitorum longus 313, 315
 extensor hallucis longus 315
 Extensor pollicis longus muscle 187, 189, 307
 External 13, 582
 External acoustic meatus 43, 44, 54, 58, 67, 68, 98, 582
 External intercostal muscles 159
 External oblique muscle 232, 309
 External occipital crest 72
 External occipital protuberance 56, 71, 72
 Extramolar sulcus 92
 Extrasutural bones *see sutural bones*
 Extrinsic 13, 582
 Eye teeth *see canines*
- F**
- Facet
 acromial 161, 162, 163
 anterior calcaneal 284
 articular
 inferior 132, 133, 134, 136, 139
 sacral 221, 222, 223
 superior 132, 133, 136, 139, 142
 calcaneal
 anterior 284
 clavicular (of scapula) 170, 172
 costal 139
 inferior demifacet 139
 superior demifacet 139
 definition 17, 582
 dental
 interproximal contact 106
 occlusal contact 106
 for the cuboid 278
 lateral articular
 of patella 252
 lunate
 of radius 189
 medial articular
 of patella 252
 Poirier's 252
 squatting
 of talus 276, 284
 of tibia 263
 superior articular
 of sacrum 221, 222, 223
 talar
 anterior 278
 medial 278
 posterior 278
 transverse costal 139
 Fallon Paiute-Shoshone tribe 362, 519
 "False" pelvis 237 *see greater pelvis*
 "False" ribs 153
 Falx cerebri 62, 82
 Fascia
 deep transverse 255
 popliteus 255
 temporal 60, 65, 67, 298–299
 Faunal analysis 522
 Features *see individual features*
 terminology 16–18
 Feminine 409, 410, 412
 Femoral 21, 582
 Femoral bicondylar length 251
 Femoral biomechanical length 251
 Femoral bowing 252
 Femoral head 248, 250, 251
 Femoral midshaft circumference 251
 Femoral neck 246, 248, 251
 Femur 241–252
 Fetal remains 329
 excavation of 322–323, 328
 Fetus 384, 582
 Fibroblast 40
 Fibroblastic sarcoma *see fibrosarcoma*
 Fibrocartilage 590
 Fibrodysplasia ossificans progressiva 40, 41, 451
 Fibrosarcoma 453
 Fibrous capsule 131
 Fibula 263–270
 Fibular groove 265, 267, 268
 Fibular head 263, 264, 265, 266, 267, 269
 Fibularis brevis muscle 268, 279, 285, 315
 Fibularis longus muscle 268, 279, 280, 315
 Fibularis tertius muscle 315
 Fibular midshaft circumference 269
 Fibular neck 263, 264, 265, 266, 267
 Fibular notch 260, 261
 Fibular tubercle 279, 284
 Field equipment 324
 Fifth metacarpal *see MC 5*
 Fifth metatarsal *see MT 5*
 Fire (taphonomy) 464
 First cuneiform *see medial cuneiform*
 First metacarpal *see MC 1*
 First metatarsal *see MT 1*
 Fissure 106
 Fistula 446
 Flexed 582
 Flexed burial 322, 323
 Flexion 15, 16, 32, 180, 197, 198, 582
 Flexor digiti minimi muscle 289
 Flexor muscles
 of forearm 181, 185
 flexor digitorum profundus 307
 flexor digitorum superficialis 305, 307
 flexor carpi ulnaris 307
 flexor pollicis brevis 13
 flexor pollicis longus 13, 305
 of leg
 flexor digitorum longus 255, 313
 flexor hallucis brevis 285
 flexor hallucis longus 268, 277, 279, 315
 Flexor retinaculum 202, 205, 207
 Flexure of superior sagittal sulcus 98
 "Floating" ribs 153
 Fontanelle 18, 53, 66, 582
 Food, cariogenic 483
 Foot phalanges 292
 FOP *see fibrodysplasia ossificans progressiva*
 Foramen
 anterior sacral 220
 apical 106
 cecum 62, 66
 condylar 72, 73
 "crest of foramina" 90
 definition 18, 582
 greater palatine 78
 of Huschke 98
 incisive 76, 77
 infraorbital 75, 76
 intervertebral 139, 221
 lacerum 98
 lesser palatine 78, 79
 magnum 43, 48, 50, 51, 56, 57, 71–75, 583
 measurements 96
 mandibular 93, 95, 98
 mastoid 67, 69, 98
 mental 59, 92, 94, 98
 multiple 98
 microforamina 151
 nasal 84
 nutrient

- developmental origin 37
 - of clavicle 162, 301
 - of femur 243, 247
 - of fibula 265, 266, 268
 - of humerus 176, 180, 181
 - of radius 185, 186, 187, 194
 - of tibia 255
 - of ulna 193
 - obturator 229, 231, 233, 246
 - ovale 89, 90, 98
 - incomplete 98
 - palatine
 - greater 78
 - lesser 78, 79
 - parietal 56, 64, 65, 66, 97, 98
 - rotundum 89, 90
 - sacral
 - anterior 220
 - dorsal *see posterior sacral foramina*
 - pelvic *see anterior sacral foramina*
 - posterior 221
 - scapular 166
 - spinous 89, 90, 98
 - incomplete 98
 - sternal 152
 - supraorbital 60, 61, 63, 97
 - transverse 132, 136, 146
 - vertebral 131, 132, 136, 139
 - lumbar 143
 - zygomaticofacial 85, 86, 97
 - variation in number 97
 - zygomaticoorbital 85, 86
 - zygomaticotemporal 85, 86
 - Foramen magnum breadth 96
 - Foramen magnum length 96
 - Forensic odontology 425
 - Forensic osteology 1, 583
 - Forensics websites 573
 - Formation
 - bone 508, 510, 511
 - enamel 455
 - pattern 39
 - rift 545
 - tooth 386
 - Formula
 - dental 103, 581
 - stature 420
 - Fossa 583
 - acetabular 227
 - Allen's 252
 - canine (of maxilla) 75, 76
 - cerebellar 73, 74
 - cerebral 73, 74
 - condylar 72, 73, 75
 - coronoid 180, 181
 - cranial
 - anterior 51
 - middle 51, 90
 - posterior 51
 - definition 17
 - digastric 93
 - distal *see distal fovea*
 - glenoid
 - of temporal 68, 69
 - of scapula 166, 168, 170–172, 174
 - hypophyseal 87, 88
 - iliac 229, 230, 231, 232
 - infraspinous 170, 172
 - intercondylar 243, 247, 248
 - jugular 69, 70
 - lacrimal 62, 63
 - malleolar 265, 266, 268, 269
 - mandibular 68, 69
 - masseteric 94, 95
 - mesial *see mesial fovea*
 - olecranon 177, 180, 181
 - pterygoid 89, 90, 91
 - radial 180, 181
 - sublingual 92, 93
 - submandibular 92, 93
 - subscapular 165
 - supraspinous 170, 172
 - temporal 85, 86, 90
 - trochanteric 246
 - vastus 254
 - Fossil field 544
 - Fossilization 463
 - Fourth metacarpal *see MC 4*
 - Fourth metatarsal *see MT 4*
 - Fovea
 - arachnoid 62, 65, 66
 - articular (of radius) 184
 - costal 139
 - definition 17, 583
 - as dental term 106
 - fovea capitis 181, 241, 244, 248
 - as nonmetric trait 252
 - pterygoid 94
 - ulnar 195
 - Fracture 35, 39, 40, 337, 354, 433–435, 436, 460, 470, 508
 - ancient 460
 - comminuted 579
 - complete 433, 434, 579
 - compound 433
 - compressed 434
 - displaced 434
 - linear 434
 - nondisplaced 434
 - oblique 434
 - transverse 434
 - compound 579
 - compressed 518
 - from butchery 467
 - greenstick *see incomplete fracture*
 - healed 433, 435, 510
 - partially healed 509
 - healing 321
 - incomplete 434, 584
 - greenstick 434
 - infracture *see incomplete fracture*
 - oblique 434
 - pathological 435, 447, 587
 - perimortem 460
 - postmortem 460, 461
 - recent 460
 - resulting in pseudarthroses 588
 - taphonomic 460–461
 - Frankfurt Horizontal 54, 56, 583
 - Frontal angle 64, 65
 - Frontal bone 44, 45, 47, 49, 50, 60–63
 - Frontal chord 96
 - Frontal crest 61, 62
 - Frontal eminence 60
 - Frontal lobe (of brain) 51, 60, 62, 90
 - Frontal plane *see coronal plane*
 - Frontal process
 - of maxilla 75, 76, 77, 85, 86
 - of zygomatic 58
 - Frontal sinus 62, 63, 66
 - Frontal squama 60, 61, 63
 - Frontolacrimal suture 58
 - Frontomalare orbitale (fmo.) 58
 - Frontomalare temporale (fmt.) 58
 - Frontomaxillary suture 44, 45, 58
 - Frontonasal suture 44, 45, 52, 55, 85
 - Frontotemporale (ft.) 58
 - Front teeth *see incisors, canines*
 - Funerary objects, associated 320, 323
 - Fusion
 - of distal femur 250
 - of distal fibula 269
 - of distal tibia 261
 - of femoral head 250–252
 - of greater trochanter 250
 - of hyoid 129
 - of lesser trochanter 250
 - of manubriosternal joint 152
 - of occipital & sphenoid 74
 - of olecranon 241
 - of proximal fibula 269
 - of sacrum and coccyx 226
 - of tibial proximal epiphysis 261
 - of tibial tuberosity 261
 - of vertebral apophyses 135
 - sacrococcygeal 226
- ## G
- Gastrocnemius muscle 247, 277, 311
 - Gemelli muscles 309, 311
 - Gender, versus sex 408
 - Genes 491–496
 - ACVR1 40–41
 - Genioglossus muscle 93, 299
 - Geniohyoid muscle 93, 299
 - Geographic variation 26
 - Gigantism 448, 583

- Girdle
 pelvic 219, 240
 shoulder 161
- Glabella (g.) 55, 56
- Glabellar region 61, 84
- Gland
 lacrimal 62
 salivary
 sublingual 93
 submandibular 92
- Glandular disorders 448
- Glenohumeral joint 174
- Glenohumeral ligaments 303
- Glenoid fossa
 of mandible 68, 69
 of scapula 166, 168, 170–172, 174
- Global positioning systems 321–322, 543
- Glossal 21, 583
- Glue *see adhesives*
- Gluteal line
 anterior 227
 inferior 227, 228
 of femur *see gluteal tuberosity*
 posterior 227
- Gluteal muscles 227
 gluteus maximus 227, 232, 240, 246
 gluteus medius 227, 240, 241
 gluteus minimus 227, 240, 241
- Gluteal surface 227
- Gluteal tuberosity 243, 246, 250
 and third trochanter 252
- Gluteus maximus muscle 311
- Gluteus minimus muscle 311
- Gluteus muscles *see gluteal muscles*
- Gnathion (gn.) 57
- Gnathostomes 175
- Gomphosis 32, 583
- Gonial angle 59, 93, 94, 95, 99
- Gonial eversion 95
- Goniometer 341
- Gonion (go.) 59
- Government agencies
 Armed Forces DNA Identification Laboratory 492
 Department of Defense
 U.S. Army 359, 363
 U.S. Army Corps of Engineers 363
 Department of the Interior 366
 National Park Service 366, 367
 Departmental Consulting Archaeologist and Archaeology and Ethnography Program 366
 U.S. Fish and Wildlife Service 519
- Gracilis muscle 309, 313
- Grant, J.C.B. collection 382
- Granuloma, eosinophilic 450
- Graves 515–520
- Great Basin 514–520
- Greater horn 129, 130
- Greater multangular *see trapezium*
- Greater palatine artery 77, 78
- Greater palatine foramen 78
- Greater palatine groove 76, 77
- Greater palatine nerve 78
- Greater palatine vein 77, 78
- Greater pelvis 237
- Greater sciatic notch 228, 229, 231, 232
- Greater trochanter 241, 243, 244, 245, 246, 248, 250
- Greater tubercle 176, 179, 184
- Greater wing (of sphenoid) 88, 89, 90, 91
- Greek
 directional terms 13–15
 feature names 16–18
 motion terms 15–16
 prefixes and suffixes 18–20
 region terms 21–22
 shape terms 22–23
- Greenstick fracture 434 *see incomplete fracture*
- Groove
 anterior 260
 costal 153, 155, 156, 157
 definition 17, 583
 as dental term 106
 developmental 104
 fibular 265, 267, 268
 for flexor hallucis longus 260
 for extensor muscle tendons 187, 189
 extensor carpi radialis 187, 188
 extensor carpi ulnaris 192, 194, 195, 196, 197
 extensor pollicis longus 187
 for fibularis longus 279
 for flexor hallucis longus 277
 for the medulla oblongata 72, 74
 greater palatine 76, 77
 intercollicular 260
 intertubercular 176, 177, 178, 180, 181, 197
 lacrimal 75, 76, 83, 84
 malleolar 260
 mastoid notch 68, 69
 meningeal 61, 62, 65, 66, 74
 middle 68, 70
 of frontal 62
 mylohyoid 93, 95, 98
 nasopalatine 80
 obturator 233
 obturator externus 246
 occipital 68, 69
 palatine, greater 76, 77
 pisiform 205
 popliteal 247, 250, 255
 posterior 258, 260
 for semimembranosus 255
 sesamoid 285
 subclavian *see subclavian sulcus*
- supra-acetabular 227
- sustentacular *see sustentacular sulcus*
- trapezial 205
- Growth
 appositional 35, 38
 of foot phalanges 292
 longitudinal 38
 of bones (general) 37–39
 of carpals 208
 of clavicle 163, 171
 of femur 250
 of fibula 269
 of hand phalanges 216
 of humerus 181, 182
 of hyoid 130
 of mandible 95
 of metacarpals 214
 of patella 253
 of radius 182
 of sacrum 222
 of scapula 170–171, 171
 of sphenoid 91
 of tarsals 283
 of tibia 38, 261
 of ulna 182, 195
 of vertebrae 135
 plate *see epiphyseal plate*
- Growth factors 39, 40
- Growth plate *see epiphyseal plate*
- Guiding ridge 191, 192
- ## H
- Hadar 541
- Hallucial 21, 583
- Hallux 271, 277, 285, 292, 583
- Hamann-Todd collection 382
- Hamate
 bone 200–202, 207–208, 209
 shape term 17, 22
- Hamate base 207
- Hamstring muscles 240
- Hamulus
 definition 17, 583
 of hamate 207
 pterygoid 88, 89, 90
- Handling the skull 51
- Hand navicular *see scaphoid*
- Hand phalanges 202, 210–212, 215–216
- Hand-Schüller-Christian disease 450
- Harris lines 430, 456, 482, 510, 583
- Haversian canal 37, 583, 585
- Haversian lamella 24, 35
- Haversian system 35, 37
- Head 17, 583
 of capitate 206
 of femur 241, 248, 250, 251
 of fibula 264, 265, 266, 267
 of hand phalanx 215, 291
 of humerus 175, 176, 181, 183

- of metacarpals 209
 - of metatarsal 285
 - of radius 184, 185, 186, 187, 188, 189, 190, 195
 - of rib 153, 155, 156
 - of talus 276, 277, 279, 281
 - of ulna 191, 192, 193, 194, 195
 - Healed fracture 433, 435, 510
 - Helical 22, 583
 - Hematoma 40
 - Hematopoietic 583
 - Hematopoietic and hematological disorders 448–450
 - Hematopoietic tissue 32
 - Hemi- 19
 - Hemispherical 22
 - Herculaneum 1
 - Heritability, of nonmetric traits 479
 - Hetero- 19
 - Heterodont 583
 - Heterotopic 40, 451
 - Hinge joint 30, 583
 - Hip bone *see os coxae*
 - Hip joint 170, 171, 174
 - Hippocrates 476
 - Histological types of bone
 - immature
 - coarsely bundled bone 35
 - woven bone 35, 36, 40, 446
 - mature
 - lamellar bone 35, 36, 40, 405, 406, 585
 - Histology 35, 36
 - Homeobox 40
 - containing genes 39, 40
 - Homeobox code hypothesis *see odontogenic homeobox code hypothesis*
 - Hominid 13, 18, 583
 - Homo erectus* 545
 - Homology
 - serial 147, 589
 - Homo neanderthalensis* 533
 - Horizontal plane *see transverse plane*
 - Horizontal plate (of palatine) 78
 - Horizontal portion (of frontal) 62
 - Hormion (ho.) 57
 - Horn
 - coccygeal *see coccygeal cornua*
 - greater 129, 130
 - lesser 129, 130
 - of sacrum *see sacral cornua*
 - Humeral bicondylar breadth 183
 - Humeral biomechanical length 183
 - Humeral head 176, 181, 183
 - Humeral midshaft circumference 183
 - Humeral shaft 178, 181, 183, 197
 - Humeral torsion 184
 - Humeroradial joint 197
 - Humeroulnar joint 197
 - Huntington collection 382, 404
 - Huntington's disease 493
 - Hyaline cartilage 29, 30, 583
 - Hydrocephaly 439
 - Hydroxyapatite 27, 35, 37, 583
 - Hyoid body 129
 - Hyper- 19
 - Hypercementosis 107, 583
 - Hyperfeminine 410, 412
 - Hypermasculine 410, 412
 - Hyperostosis 583
 - porotic 588
 - Hyperplasia 583
 - Hypertrophy 583
 - Hypocone(id) 105, 106
 - Hypoglossal canal 72, 73, 75, 98
 - Hypoglossal nerve 73
 - Hypomineralization *see hypoplasia*
 - Hypophyseal fossa 87, 88
 - Hypoplasia 583
 - dental *see enamel hypoplasia*
 - enamel 107, 455–456, 482, 519–520, 538, 581
 - in Atapuerca fossils 538
 - linear *see enamel hypoplasia*
- I
- Idiopathic 583
 - Idiosyncrasy *see idiosyncratic variation*
 - Idiosyncratic 584
 - Idiosyncratic variation 26, 27, 30, 384, 385, 391, 395, 396, 429
 - iform 19, 22
 - Iliac body 229
 - Iliac crest 34, 229, 232, 233, 236
 - inner lip 232
 - outer lip 232
 - Iliac fossa 229, 230, 231, 232
 - Iliac pillar 227, 228, 234
 - Iliac spine
 - anterior inferior 232
 - anterior superior 226, 232, 235
 - posterior inferior 228, 232
 - posterior superior 228, 232, 235
 - Iliac tubercle 227, 228, 231
 - Iliac tuberosity 227, 229, 230, 231
 - Iliacus muscle 246, 311
 - Iliofemoral ligament 232, 246
 - Iliopectineal eminence *see iliopubic eminence*
 - Iliopectineal line 237
 - Iliopsoas muscle 240, 311
 - Iliopsoas tendon 246
 - Iliopubic eminence 229, 231, 232
 - Iliopubic ramus 229
 - Ilium 226, 227, 232, 233, 234
 - confusion with cranial frags. 233
 - confusion with scapula frags. 170, 233
 - Immature 584
 - histological type of bone 35
 - Impaction 479
 - Impression
 - aortic 139, 140, 141
 - costoclavicular 161
 - for gastrocnemius
 - lateral head 247
 - for popliteus 247
 - Inca bone 98, 584
 - Incisal 15, 584
 - Incision (inc.) 55
 - Incisive canal 77
 - Incisive foramen 76, 77
 - Incisor 102, 103, 110
 - Incisor shoveling 481
 - Incomplete ankylosis
 - of horns of hyoid 460
 - Incomplete foramen ovale 98
 - Incomplete foramen spinosum 98
 - Incomplete fracture 433, 434, 584
 - Incus 71
 - Index 342, 345
 - cranial 342
 - platycnemic 263
 - scapular 172
 - vertebral canal 146
 - Individuation 2, 379, 584 *see also personal identification*
 - Infant 384, 584
 - Inferior 13, 584
 - Inferior alveolar nerve 95
 - Inferior angle (of scapula) 166, 168, 170, 172
 - Inferior articular facet 132, 133, 134, 136, 139
 - Inferior articular process 132, 133, 134, 136, 139
 - Inferior fibular articular surface 260
 - Inferior gluteal line 227, 228
 - Inferior nasal concha 45, 81–82
 - Inferior nuchal line 72
 - Inferior pubic ramus *see ischiopubic ramus*
 - Inferior temporal line 64, 65
 - Inferior trunk of brachial plexus 156
 - Infraction *see incomplete fracture*
 - Infracdentale (id.) 57
 - Infraglenoid tubercle 166, 168, 170, 197
 - Infraorbital canal 75
 - Infraorbital foramen 75, 76
 - Infraorbital nerve 75
 - Infraorbital sulcus 75, 76
 - Infraspinatus muscle 170, 177, 184, 303
 - Infraspinous fossa 170, 172
 - Infratemporal crest 88, 89, 90
 - Inguinal ligament 232, 234
 - Inhumation 584 *see burial*
 - Inion (i) 56
 - Inlet, pelvic 237
 - Inner lip of iliac crest 232
 - Innominate *see os coxae*

Insertion (of muscle) 15, 32, 584
in situ 321, 584
 Interclavicular ligament 301
 Intercollicular groove 260
 Intercondylar eminence 254, 255, 261, 262
 Intercondylar fossa 243, 247, 248
 Intercondylar line 243, 247
 Intercondylar notch *see intercondylar fossa*
 Intercoastal artery 153
 Intercoastal nerve 153
 Intercoastal vein 153
 Interdigitated 22, 584
 Intermaxillary suture 45, 77
 Intermediate cuneiform 272–275, 281, 282
 Intermediate foot phalanx 292
 Intermediate hand phalanx 216
 Interment *see burials*
 Internal 13, 584
 Internal acoustic meatus 68, 70
 Internal acoustic artery 70
 Internal carotid artery 70
 Internal jugular vein 70
 Internal oblique muscle 232, 309
 Internal occipital crest 73, 74
 Internal occipital protuberance 73, 74, 98
 Internasal suture 45, 55, 85
 Interobserver error 430, 584
 Interorbital breadth 96
 Interosseous border or crest
 of fibula 264, 265, 266, 268
 of radius 185, 186, 187, 189
 of tibia 255
 of ulna 185, 189, 191, 193–197
 Interosseous membrane
 of forearm 185, 305, 307
 of leg 19, 255, 268, 313, 315
 Interosseous surface (of tibia) 255
 Interproximal 14, 103, 106, 584
 Interspinous ligament 132
 Intertrochanteric crest 243, 244, 246
 Intertrochanteric line 246
 Intertubercular groove 176, 177, 180
 Intertubercular lamina 136
 Intervertebral disk 131, 147
 Intervertebral foramen 139, 221
 Intervertebral notch 139
 Intramembranous ossification 37, 581, 584
 Intraobserver error 430, 584
 Intrasutural bone *see sutural bone*
 Intrinsic 13, 584
in utero 584
 Inversion 16, 584
 Involutum 446
 Ischial body 229, 231, 232
 Ischial spine 228, 232
 Ischial tuberosity 232, 233, 247
 Ischiopubic ramus 228–230, 232, 233, 247
 Ischium 219, 226, 227, 232, 233
 confusion with scapula 170

Isotopic analysis 483
 -itis 19

J

J.C.B. Grant collection 382
 Joint 584
 cartilaginous 30
 geometries
 ball-and-socket 29, 578
 hinge joints 30, 218, 583
 planar joint 30, 588
 saddle-shaped *see sellar*
 sellar 30, 589
 named
 ankle 260, 263, 268, 270, 276
 elbow 174
 glenohumeral 174
 hip 170, 171, 174
 humeroradial 197
 humeroulnar 197
 knee 247, 252, 263, 270
 manubrialsternal 152
 pubic symphyseal 226, 233
 radiocarpal 197
 radioulnar 197
 sacroiliac 220
 shoulder 165, 170, 174
 sternoclavicular 161
 talocrural 260, 263, 268, 270, 276
 temporomandibular 91, 94, 590
 wrist 184, 185, 195, 197
 types
 cartilaginous *see synchondrosis*
 gomphosis 32
 pseudoarthrosis 436, 588
 sutures 32, 590
 symphysis 30, 394, 395, 396, 397, 400,
 402, 406, 408, 590
 synchondrosis 53
 syndesmosis 590
 synostosis 32
 synovial 29, 30, 32, 590
 Joint capsule 29, 436
 Joint cavity 29, 31
 Joint diseases 441–443
 Jugale (jg.) 58, 85
 Jugular fossa 69, 70, 71
 Jugular notch 73, 149, 150
 Jugular process 73, 74
 Juvenile 584

K

Kennewick 357, 368–369, 369, 372
 Knee-cap *see patella*
 Knee joint 247, 252, 263, 270
 Kumho decision 361
 Kyphosis 440–441, 444, 584

L

Labial 14, 103, 105, 584
 Labiolingual 15, 584
 Labyrinth (of ethmoid) 82
 Lacri- 19
 Lacrimal bone 44, 45, 83
 Lacrimal canal 77, 81, 84
 Lacrimal crest
 anterior 58, 75, 76, 77
 posterior 58, 83
 Lacrimale (la.) 58
 Lacrimal fossa 62, 63
 Lacrimal gland 62
 Lacrimal groove 75, 76, 83, 84
 Lacrimal process (of inf. nasal concha) 81
 Lacrimomaxillary suture 58
 Lacuna 34, 37
 Laetoli 542, 543
 Lake Turkana 541
 Lakota tribe 363
 Lambda (l.) 56, 65, 74
 Lambdoid 22, 584
 Lambdoidal *see lambdoid*
 Lambdoid suture 44, 46, 47, 48, 49, 50, 56,
 58, 74, 75, 98, 585
 Lamellae, haversian 34
 Lamellar bone 35, 36, 40, 405, 406, 585
 Lamina 585
 intertubercular 136
 lamina orbitalis 82
 of inferior nasal concha 81
 of vertebra 132, 133, 143
 Laminar 22
 Langerhans cell histiocytosis 450
 Lateral 13, 585
 Lateral articular facet (of patella) 252
 Lateral border
 of humerus 176, 177, 179
 of scapula 165
 Lateral collateral ligament 247, 263
 Lateral condyle
 of femur 242, 243, 245, 247, 248
 of tibia 254
 Lateral cuneiform 272, 273, 282–283
 Lateral epicondyle
 of femur 242, 243, 245, 247
 of humerus 176, 177, 179, 180, 181, 183,
 197
 Lateral intercondylar tubercle 255
 Lateral ligament 299
 Lateral malleolar surface (of talus) 276
 Lateral malleolus 264, 265, 267, 268, 269,
 270
 Lateral part (of occipital) 72
 Lateral process
 of calcaneus 279
 of talus 279
 Lateral pterygoideus muscle 94, 299
 Lateral pterygoid plate 77, 88, 89, 90, 98, 99
 Lateral rotation 147, 177

- Lateral sacral artery 220
 Lateral sacral crest 221
 Lateral supracondylar crest 176, 177, 179, 181
 Lateral supracondylar line 247
 Lateral surface
 of fibula 263, 264, 265, 267
 of radius 185, 186, 188
 Lateral thyrohyoid ligament 129
 Latin
 directional terms 13–15
 feature names 16–18
 motion terms 15–16
 prefixes and suffixes 18–20
 region terms 21–22
 shape terms 22–23
 Latissimus dorsi muscle 178, 303
 Law of bone transformation *see Wolff's Law*
 Laws
 Archaeological Resources Protection Act 357
 California Environmental Quality Act 357
 Native American Graves Protection and Repatriation Act (NAGPRA) 357, 365–369, 376, 586
 Cultural affiliation 365
 LCL *see lateral collateral ligament*
 Learning cranial anatomy 59
 Left 11, 585
 Legg-Calvé-Perthes disease 440–441
 Length of scapular spine 172
 Lens aperture 345–347, 560
 Lentiform 22, 585
 Lesion
 blastic 431
 definition 585
 lytic 431, 450, 452
 subperiosteal 510
 Lesser horn 129, 130
 Lesser multangular *see trapezoid*
 Lesser palatine foramen 78, 79
 Lesser palatine nerve 79
 Lesser pelvis 237
 Lesser sciatic notch 229, 230, 232
 Lesser trochanter 243, 244, 245, 246, 248, 250
 Lesser tubercle 176, 181
 Lesser wing (of sphenoid) 88, 89, 90, 91
 Letterer-Siwe disease 450
 Leukemia 450
 Levator labii superioris alaeque nasi muscle 299
 Levator labii superioris muscle 299
 Levator scapulae muscle 170
 Levator veli palatini muscle 299
 Libben site 446, 486–487
 Ligament 28, 29, 32
 annular 307
 calcaneofibular 284
 collateral
 of elbow
 ulnar (medial) 307
 of wrist 215, 218
 conoid 162, 301
 coracoclavicular 301
 coracohumeral 303
 costoclavicular 161, 301
 cruciate 313
 anterior 247, 311
 posterior 255, 311
 deltoid 260, 313
 glenohumeral 303
 iliofemoral 232, 246
 inguinal 232, 233
 interclavicular 301
 interosseous membrane
 of forearm 305
 of leg 313, 315
 interspinous 132
 lateral 299
 lateral collateral 247, 263
 lateral thyrohyoid 129
 ligamentum teres 227, 311
 nuchal 72, 299
 oblique cord 305, 307
 oblique popliteal 313
 patellar 252, 255
 periodontal 103
 popliteal 313
 posterior meniscofemoral 311
 pterygo-alar 98
 pterygospinous 90, 98
 pubic 233
 pubofemoral 233
 radial collateral 180
 radioulnar
 dorsal 305
 palmar 305
 rhomboid *see costoclavicular*
 sacrospinous 227, 232, 234
 sacrotuberus 232
 sphenomandibular 95, 299
 of Struthers 184
 stylohyoid 69, 129
 stylomandibular 299
 suprascapular 173
 supraspinous 132
 syndesmotric 315
 talofibular
 anterior 314–315
 posterior 268, 314–315
 tibiofibular 260
 transverse 268
 transverse humeral 177, 303
 trapezoid 162, 301
 ulnar collateral 181, 195
 Ligamentum teres 227, 311
 Line
 anterior oblique 185, 186, 187, 188, 198
 arcuate 232
 definition 17, 585
 gluteal
 anterior 227
 inferior 227, 228
 of femur *see gluteal tuberosity*
 posterior 227
 Harris 430, 456, 482, 510
 iliopectineal 237
 intercondylar 243, 247
 intertrochanteric 246
 lateral supracondylar 247
 linea aspera 243, 246, 247, 250
 linea terminalis 237
 medial supracondylar 243, 244, 247
 mylohyoid 92, 93
 nuchal
 inferior 72
 superior 56, 71, 72
 oblique
 of mandible 92, 94
 pectineal 232, 246
 popliteal *see soleal line*
 posterior oblique 186
 soleal 255, 258
 spiral 243, 244, 246
 temporal 58, 60, 61, 65, 66, 99
 inferior 64, 65
 superior 64, 65, 99
 transverse
 of sacrum 220, 223
 trapezoid 162
 vertical 255
 Linea aspera 243, 246, 247, 250
 Linear fracture 434
 Linear hypoplasia 107, 455–456, 482, 519–520, 538, 581
 Linea terminalis 237
 Lingual 14, 21, 585
 Lingula 92, 93, 95
 Lip *see also labial*
 of iliac crest
 inner 232
 outer 232
 patellar 242, 244, 248
 Lipping
 auricular marginal 400–402
 definition 585
 of facet for first costal cartilage 161
 of iliac crest 232
 osteoarthritic 441–442, 528, 586
 symphyseal 399
 Little Big Horn 357
 Lobate 22, 585
 Lobe
 frontal 51, 60, 62, 90

- occipital 67
 - temporal 67
 - Longissimus capitis muscle 67, 299
 - Longitudinal crest 194
 - Longitudinal growth 38
 - Longus capitis muscle 299
 - Lumbar 21, 585
 - Lumbar ribs 158
 - Lumbar vertebrae 143–145
 - Lunate 200, 201, 202, 203
 - shape term 23, 585
 - Lunate facet
 - of radius 189
 - Lunate surface
 - of acetabulum 227, 228, 234
 - Lytic lesions 431, 450, 452
- M**
- Maceration 334
 - Malleolar fossa 265, 266, 268, 269
 - Malleolar groove 260
 - Malleolar surface (of talus)
 - lateral 276, 277
 - medial 277
 - Malleolus
 - definition 17, 585
 - lateral 264, 265, 267, 268, 269, 270
 - medial 260, 261, 262
 - Malleus 71
 - Malocclusion 585
 - Mamelon 106, 585
 - Mammillary process 143
 - Mancos Canyon 530
 - Mandible 44, 45, 46, 91–95
 - Mandibular alveoli 92
 - Mandibular body 94
 - Mandibular canal 95
 - Mandibular condyle 59, 69, 92, 93, 94
 - Mandibular foramen 93, 95, 98
 - Mandibular fossa 68, 69
 - Mandibular goniometer 341
 - Mandibular length 96
 - Mandibular nerve 90
 - Mandibular notch 92, 94, 95
 - Mandibular ramus 94
 - Mandibular symphysis 93
 - Mandibular torus 93, 98
 - Mandibulometer 341
 - Manual 21, 585
 - Manubriosternal fusion 152
 - Manubriosternal joint 151, 152
 - Manubrium 149, 150, 151, 152
 - Margin
 - acetabular 227, 228, 231
 - anterior
 - of fibula *see anterior crest*
 - interosseous *see interosseous border*
 - oblique *see posteromedial border*
 - posterior
 - of fibula *see posterior crest*
 - posteromedial *see posteromedial border*
 - supraorbital 60, 61, 63
 - in sex determination 411
 - Marrow
 - red 32
 - yellow 32
 - Masculine 410, 412
 - Massacre at Crow Creek 363, 364, 367
 - Masseteric fossa 94, 95
 - Masseteric tuberosity 93, 94
 - Masseter muscle 67, 85, 86, 93, 94, 95, 99, 299
 - Mastication 91, 99, 102, 585
 - Mastoidale (ms.) 58
 - Mastoid angle 64, 65, 66, 74
 - Mastoid cells 67
 - Mastoid foramen 67, 69, 98
 - Mastoid length 96
 - Mastoid notch 68, 69, 70, 71
 - Mastoid process 58, 67, 68
 - in sex determination 411
 - Matrix
 - bone 37
 - clay 537
 - collagen 35
 - definition 585
 - fossil 334
 - of CCD 562
 - osteoid 37
 - plaque 455
 - soil 537
 - uncalcified organic *see also osteoid*
 - Matrix samples 321
 - Mature *see also adult*
 - histological type of bone 35
 - Maxilla 44, 45, 46, 47, 48, 75–77
 - Maxillary alveoli 75
 - Maxillary osteitis
 - in Atapuerca fossils 538
 - Maxillary process
 - of inferior nasal concha 81
 - of zygomatic 85, 86
 - Maxillary sinus 75, 76, 77, 79
 - Maxillary tuber 77
 - Maxillo-alveolar breadth 96
 - Maxillo-alveolar length 96
 - Maxillofrontale (mf.) 58
 - Maximum anterior breadth
 - of sacrum 224
 - Maximum anterior height
 - of sacrum 224
 - Maximum anteroposterior diameter
 - of ulna 197
 - Maximum breadth
 - of cranium 96
 - of manubrium 152
 - of patella 253
 - of mandibular ramus 97
 - Maximum diameter
 - fibular midshaft 269
 - midshaft, humerus 184
 - ulna, maximum mediolateral 197
 - Maximum height
 - of cranium 57, 96
 - of patella 253
 - of mandibular ramus 97
 - Maximum length
 - of calcaneus 283
 - of clavicle 164
 - of cranium 96
 - of femur 250
 - of fibula 269
 - of hand phalanx 216
 - of humerus 183
 - of metacarpal 214
 - of metatarsal 290
 - of radius 190
 - of scapula 172
 - of talus 284
 - of tibia 261
 - of ulna 196
 - Maxwell collection 382
 - MC 1 209
 - MC 2 209
 - MC 3 209
 - MC 4 209
 - MC 5 213
 - MCL *see medial collateral ligament*
 - Measurement error 342, 343
 - Measurements
 - angles
 - femoral torsion 251
 - humeral torsion 184
 - mandibular 97
 - spinous process 146
 - subpubic 240
 - breadths
 - anatomical scapular 172
 - biauricular 96
 - bigonial 96
 - bicondylar
 - of humerus 183
 - of mandible 96
 - bi-iliac 240
 - biorbital 96
 - bizygomatic 96
 - buccolingual crown 127
 - femoral epicondylar 251
 - foramen magnum 96
 - hand phalangeal midshaft mediolateral 217
 - immature iliac 235
 - interorbital 96
 - mandibular body 97
 - manubrial 152
 - maximum manubrial 152
 - maximum patellar 253

- maximum ramal 97
- maxillo-alveolar 96
- maximum cranial 96
- metacarpal midshaft mediolateral 214
- metatarsal midshaft 290
- minimum frontal 96
- minimum ramal 97
- morphological scapular 172
- nasal aperture 96
- obturator foramen 236
- orbital 96
- os coxae 235
- palate 96
- phalangeal midshaft mediolateral (foot) 294
- sacral anterior maximum 224
- sacral anterosuperior 225
- sacral auricular surface 225
- sacral middle 225
- superior iliac 235
- tibial maximum distal epiphyseal 262
- tibial maximum proximal epiphyseal 262
- upper facial 96
- vertebral canal 146
- chords
 - frontal 96
 - occipital 96
 - parietal 96
- circumferences
 - midshaft
 - of clavicle 165
 - of femur 251
 - of humerus 183
 - of radius 190
 - of tibia 262
 - minimum
 - of ulna 197
 - tibial, at nutrient foramen 262
- depth
 - acetabular 236
- diameters
 - anatomical conjugate 239
 - buccolingual crown 127
 - diagonal conjugate 239
- head
 - of humerus 184
 - of radius 190
- inferior sacropubic 240
- intercristal 240
- maximum anteroposterior
 - of ulna 197
- maximum mediolateral
 - of ulna 197
- median conjugate 240
- midshaft anteroposterior
 - of radius 190
 - of clavicle 165
- midshaft maximum
 - of humerus 184
- midshaft minimum
 - of humerus 184
- midshaft mediolateral
 - of hand phalanx 294
 - of metacarpal 214
 - of radius 190
- midshaft superoinferior
 - of clavicle 165
- oblique 239
- sternal end maximum (of rib) 159
- sternal end minimum (of rib) 159
- straight conjugate 240
- superior dorsoventral body 146
- transverse 239
- true conjugate 239
- error of 342–344
- heights
 - acetabular 236
 - chin 97
 - crown 127
 - hand phalangeal midshaft anteroposterior 217
 - iliac 236
 - immature iliac 236
 - mandibular body 97
 - maximum cranial 57,96
 - maximum ramal 97
 - metatarsal midshaft 290
 - nasal aperture 96
 - orbital 96
 - os coxae 235
 - total facial 96
 - sacral dorsal 225
 - sacral ventral arc 224
 - sacral auricular surface 225
 - sacral maximum anterior 224
 - symphyseal 97
 - upper facial 96
- indices
 - cranial breadth-height 97
 - cranial 97
 - cranial length-height 97
 - cranial module 97
 - nasal aperture 97
 - orbital 97
 - palatal 97
 - platymeric 252
 - sacral 225
 - total facial 97
 - upper facial 97
 - vertebral canal 146
- lengths
 - acetabulosymphyseal 236
 - biomechanical
 - of femur 251
 - of humerus 183
 - of radius 190
 - of scapular spine 172
 - of ulna 197
- cranial base 96
- external arc of rib 157
- foramen magnum 96
- iliac length 236
- of infraspinous line 172
- ischial 236
- mandibular 96
- mastoid 96
- maxillo-alveolar 96
- maximum
 - of calcaneus 283
 - of clavicle 164
 - of cranium 96
 - of femur 250
 - of humerus 183
 - of radius 190
 - of scapula 172
 - of talus 284
 - of ulna 196
- obturator foramen 236
- palate 96
- physiological
 - of ulna 197
 - femoral bicondylar 251
- pubic 236
- root 127
- of supraspinous line 172
- of carpals 208
- of clavicle 164, 164–165
- of coccyx 226
- of cranium 96–97
- of femur 250–252
- of fibula 269
- of foot phalanges 293–294
- of hand phalanges 216–218
- of humerus 183
- of hyoid 130
- of metacarpals 214, 215
- of metatarsals 290–291
- of os coxae 235
- of patella 253–254
- of pelvis 239
- of radius 190
- of ribs 157, 158
- of sacrum 224
- of scapula 172–173, 173
- of sternum 152
- of tarsals 283
- of tibia 261–262, 262
- of ulna 196
- of vertebrae 146
- presenting results 343
- volumes
 - cranial capacity 54
- Measuring tape 341
- Meatus
 - definition 18, 585
 - external acoustic 43, 44, 54, 58, 67, 68, 98

- internal acoustic 68, 70
- Medial 13, 14, 585
- Medial articular facet (of patella) 252
- Medial border
 - of humerus 179
 - of scapula 166, 170
- Medial collateral ligament
 - of knee 247
 - of elbow 181, 195, 307
- Medial condyle
 - of femur 242, 243, 244, 247, 248
 - of tibia 254
- Medial cuneiform 272–275, 281
- Medial epicondyle
 - of femur 242–244, 247, 248
 - of humerus 180, 181, 183, 184, 197
- Medial intercondylar tubercle 254
- Medial malleolar surface (of talus) 276
- Medial malleolus 260, 261, 262
- Medial margin *see medial crest*
- Medial process of calcaneus 279
- Medial pterygoideus muscle 90, 95, 99, 299
- Medial pterygoid plate 88, 89, 90
- Medial rotation 147, 165, 177
- Medial supracondylar crest 181
- Medial supracondylar line 243, 244, 247
- Medial surface
 - of fibula 264, 266, 268
 - of ulna 192, 193
- Medial talar facet 278
- Median palatine suture 46, 48
 - intermaxillary portion 46, 48, 57
 - interpalatine portion 48
- Median plane *see sagittal plane*
- Median sacral crest 221
- Medullary cavity 32–34, 585
- Membrane
 - arachnoid 62
 - dura mater 62
 - falx cerebri 62, 82
 - interosseous
 - of forearm 185, 307
 - of leg 19, 255, 268
 - meninges
 - dura mater 61, 62, 66, 82, 90
 - obturator 233
 - perichondrium 37
 - periosteum 29, 34, 37, 38, 39, 40, 446, 508
 - tentorium cerebelli 90
 - tympanic 67, 71
- Meningeal artery 61
 - accessory 90
 - middle 61, 66
- Meningeal groove 61, 62, 65, 66, 74
 - middle 68, 70
 - of frontal 62
- Meniscus 254, 255
- Mental 21, 585
- Mental eminence 93, 94
 - in sex determination 411
- Mentale (ml.) 59
- Mental foramen 59, 92, 94, 98
- Mentalis muscle 299
- Mental protuberance 93, 94
 - in sex determination 411
- Mental spine 92, 93
- Mesa Verde 521
- Mesenchymal stem cells 39
- Mesial 14, 103, 585
- Mesiodistal 15, 585
- Mesosternum *see corpus sterni*
- Meta- 19
- Metabolic diseases 447–448
- Metacarpal base 209
- Metacarpal head 209
- Metacarpal 199, 202, 209–213, 214, 215
 - first (MC 1) 209
 - second (MC 2) 209
 - third (MC 3) 209
 - fourth (MC 4) 209
 - fifth (MC 5) 213
- Metacone(id) 105, 106
- Metaphysis 34, 585
- Metatarsal 271, 272, 273, 285–291
 - confusion with prox. rib frag. 156
 - first (MT 1) 272, 273, 285
 - second (MT 2) 274, 281, 285, 290
 - third (MT 3) 283, 285, 290
 - fourth (MT 4) 285, 290
 - fifth (MT 5) 274, 275, 285, 290
- Metopic suture 45, 52, 61, 63, 97, 585
- Metopion (m.) 55
- Microcephaly 439
- Microforamina 151
- Microfossils, dietary 483
- Microwear *see dental microwear*
- Middle adult 384, 585
- Middle Awash 543
- Middle cranial fossa 51, 90
- Middle meningeal arteries 61, 66
- Middle meningeal grooves 68, 69, 70, 71
- Middle nasal concha 82
- Midhumeral axis 183, 184
- Midline *see sagittal plane*
- Midsagittal plane *see sagittal plane*
- Milk teeth *see deciduous dentition*
- Minimum frontal breadth 96
- Minimum midshaft diameter
 - of humerus 184
- Minimum number of individuals 337–339, 527, 586
- Misidentification
 - fiberglass as os coxae 318
 - rabbit as toddler 318
- Mitochondrial DNA 494, 495, 496, 517, 586
- MLD *see most likely descendent*
- MNI *see minimum number of individuals*
- Molar cusp patterns
 - tribosphenic 106
 - Y-5 106
- Molar 102, 110, 112
- Molding and casting 351–352, 492, 574
 - of “Ardi” 555–557
 - inhibition 337
 - for SEM work 350
- Morphogen 39, 586
- Morphogenesis 39, 39–40, 40, 586
- Morphology 2, 586
- Morphoscopic traits *see also nonmetric traits*
- “Most Likely Descendent” 358
- Motions 15–16
- Movements
 - abduction 15, 177, 577
 - adduction 15, 177, 577
 - circumduction 170
 - dorsiflexion 195, 581
 - elevation 174
 - eversion 582
 - extension 15, 17, 32, 180, 197, 198, 582
 - flexion 15, 16, 32, 180, 197, 198, 582
 - inversion 584
 - opposition 15, 218, 586
 - plantarflexion 588
 - pronation 16, 197
 - rotation 15, 71, 147, 159, 174, 177, 178, 184, 191, 192, 197, 246
 - lateral 147, 177
 - medial 147, 165, 177
 - supination 16, 197, 198
 - volarflexion 16 *see plantarflexion or palmarflexion*
- MT 1 272, 273, 285
- MT 2 274, 281, 285, 290
- MT 3 283, 285, 290
- MT 4 285, 290
- MT 5 274, 275, 285, 290
- mtDNA *see mitochondrial DNA*
- Multangular
 - greater *see trapezium*
 - lesser *see trapezoid*
- Multifactorial age estimation 406
- Multiple interment 323, 586
- Multiple myeloma 450, 452
- Murder 499–505
- Muscle insertion 584
- Muscle origin 586
- Muscles
 - abdominal 232
 - abductor pollicis longus 305, 307
 - adductor muscles
 - adductor brevis 246, 311
 - adductor longus 246, 311
 - adductor magnus 246, 247, 311
 - anconeus 303, 307
 - anterior scalene 156
 - articularis genu 311

- biceps brachii 184, 197, 295–296, 304–305
 long head 170, 177
- biceps femoris 263, 311, 315
 long head 232
 short head 247
- brachialis 192, 303, 307
- brachioradialis 187, 303, 305
- buccinator 92, 299
- coccygeus 309
- coracobrachialis 303
- corrugator supercilii 299
- deltoideus 162, 163, 170, 179, 240, 301, 303
- depressor anguli oris 299
- depressor labii inferioris 299
- depressor septi nasi 299
- digastric 68, 93, 299
- extensors
 of forearm 180, 185, 187
 extensor carpi radialis 187, 189
 brevis 303
 longus 303
 extensor carpi ulnaris 192, 194, 195, 196, 197, 307
 extensor digitorum 32
 extensor indicis 307
 extensor pollicis brevis 305
 extensor pollicis longus 187, 189, 307
 of leg
 extensor digitorum longus 313, 315
 extensor hallucis longus 315
- external intercostals 159
- external oblique 232, 309
- fibularis brevis 268, 279, 285, 315
- fibularis longus 268, 279, 280, 315
- fibularis tertius 315
- flexors
 of forearm 181, 185
 flexor carpi ulnaris 307
 flexor digitorum profundus 307
 flexor digitorum superficialis 305, 307
 flexor pollicis brevis 13
 flexor pollicis longus 13, 305
 of leg
 flexor digiti minimi 289
 flexor digitorum longus 255, 313
 flexor hallucis brevis 285
 flexor hallucis longus 268, 277, 279, 315
- gastrocnemius 247, 277, 311
- gemelli 309, 311
- genioglossus 93, 299
- geniohyoid 93, 299
- gluteal muscles 227
 gluteus maximus 227, 232, 240, 311
 gluteus medius 227, 240, 241
 gluteus minimus 227, 241, 311
- gracilis 309, 313
- hamstring muscles 240
- iliacus 246, 311
- iliopsoas 240, 311
- infraspinatus 170, 177, 184, 303
- internal oblique 232, 309
- lateral pterygoideus 94, 299
- latissimus dorsi 178, 303
- levator labii superioris 299
- levator labii superioris alaeque nasi 299
- levator scapulae 170
- levator veli palatini 299
- longissimus capitis 67, 299
- longus capitis 299
- masseter 67, 85, 86, 93, 94, 95, 99, 299
- medial pterygoideus 90, 95, 99, 299
- mentalis 299
- musculus uvulae 299
- mylohyoid 92, 299
- nasalis 299
- obliquus capitis superior 299
- obturator externus 246, 311
- obturator internus 232, 246, 311
- occipitofrontalis 299
- of clavicle 300–301
- of cranium 298–299
- of femur 310–311
- of fibula 314–315
- of humerus 302–303
- of mandible 298–299
- of os coxae 308–309
- of radius 304–305
- of skull 298–299
- of tibia 312–313
- of ulna 306–307
- orbicularis oculi 299
- orbicularis oris 299
- pectineus 232, 246, 311
- pectoralis major 162, 163, 177, 301, 303
- peroneus brevis *see fibularis brevis*
- peroneus longus *see fibularis longus*
- piriformis 232, 246, 311
- plantaris 311
- platysma 299
- popliteus 247, 255, 311, 313
- procerus 299
- pronator quadratus 195, 305, 307
- pronator teres 181, 186, 197, 303, 305, 307
- psoas major 246, 311
- psoas minor 309
- pterygoids
 lateral 299
 medial 299
- quadratus femoris 232, 246, 311
- quadriceps femoris 246, 252, 255, 270, 297 *see also vastus muscles, rectus femoris*
- rectus abdominis 232, 309
- rectus capitis anterior 299
- rectus capitis lateralis 299
- rectus capitis posterior major 299
- rectus capitis posterior minor 299
- rectus femoris 232
- rhomboid major 174
- rotator cuff 177
 infraspinatus 177, 184
 subscapularis 176, 177
 supraspinatus 176, 184
 teres minor 177
- sartorius 232, 313
- semimembranosus 232, 309, 313
- semispinalis capitis 299
- semitendinosus 232, 313
- serratus anterior 156, 170, 174
- soleus 255, 268, 277, 313, 315
- splenius capitis 67, 299
- sternocleidomastoideus 67, 299, 301
- sternohyoid 301
- stylopharyngeus 299
- subclavius 162, 301
- subscapularis 165, 176, 177, 303
- superior pharyngeal constrictor 299
- supinator 180, 195, 197, 305, 307
- supraspinatus 170, 176, 184, 303
- temporalis 60, 65, 67, 94, 99, 299
- tensor veli palatini 299
- teres major 170, 178, 303
- teres minor 177, 303
- tibialis anterior 313
- tibialis posterior 268, 281, 313, 315
- transversus abdominis 232, 309
- trapezius 162, 163, 170, 174, 299, 301
- triceps brachii 170, 180, 191, 197, 303, 307
- vastus 246
 vastus intermedius 311
 vastus lateralis 247, 311
 vastus medialis 246, 311
- zygomaticus major 299
- zygomaticus minor 299
- Muscular insertion 15
- Muscular origin 15
- Musculoskeletal stress markers 457–458
- Musculus uvulae 299
- Museu Bocage collection 382
- Museums
 Museu Bocage 382
 Mütter Museum 41
 National Museum of Natural History (Smithsonian Institution) 404
 Nevada State Museum 515–520
 Phoebe A. Hearst Museum of Anthropology 430
- Mutations
 R206H ACVR1 41
- Mütter Museum 41
- Mycobacterium tuberculosis* 495

- Mylohyoid artery 95
 Mylohyoid bridge 98
 Mylohyoid groove 93, 95, 98
 Mylohyoid line 92, 93
 Mylohyoid muscle 92, 299
 Mylohyoid nerve 95
 Mylohyoid vein 95
- N**
- NAGPRA 357, 365–369, 376, 575, 586
 Nakota 363
 Nasal 21, 586
 Nasal aperture
 anterior 43, 51, 55, 58, 84, 96, 97, 588
 posterior 80
 Nasal aperture breadth 96
 Nasal aperture height 96
 Nasal aperture index 97
 Nasal bone 44, 45, 47, 84–85
 Nasal concha
 inferior 45
 middle nasal concha 82
 Nasal crest 78
 Nasal foramen 84
 Nasalis muscle 299
 Nasal septum 79, 82
 Nasal spine
 anterior 75, 76
 posterior 78, 79
 Nasion (n.) 55
 Nasoalveolar clivus 76, 77
 Nasomaxillary suture 44, 47
 Nasopalatine artery 80
 Nasopalatine groove 80
 Nasopalatine nerve 77, 80
 Nasopalatine vein 80
 Nasospinale (ns.) 55
 National Association for the Practice of
 Anthropology 377
 National Park Service 366, 367
 Departmental Consulting Archaeologist
 and Archaeology and Ethnography
 Program 366
 Native American 586
 Native American Graves Protection and
 Repatriation Act (NAGPRA) 357,
 365–369, 376, 575, 586
 and cultural affiliation 365
 Native American groups
 Arikara 363
 Chumash 362
 Fallon Paiute Shoshone 362, 519
 Sioux
 Dakota 363
 Lakota 363
 Nakota 363
 Navicular 272, 273, 276, 280–283
 confusion with scaphoid 281
 hand navicular *see scaphoid*
 shape term 23, 586
 Navicular tubercle 281
 Neanderthal
 DNA 7, 496
 Neck
 anatomical (of humerus) 176
 condylar 92, 93, 94
 definition 17, 586
 of femur 241, 246, 248, 251
 of fibula 263, 264, 265, 266, 267
 of radius 184, 185, 186, 187, 188
 of rib 153, 155, 156, 157
 of scapula 166, 170
 surgical (of humerus) 176
 of talus 276
 Necrosis 586
 osteonecrosis 437
 Neonatal 586
 Neoplastic conditions 452–454
 Nerves
 brachial plexus
 inferior trunk 156
 carotid plexus 70
 cranial nerve 1 (olfactory) 82
 cranial nerve 5 (trigeminal)
 inferior alveolar nerve 95
 infraorbital nerve 75
 mandibular nerve 90
 mental nerve 92
 supraorbital nerve 61
 zygomaticofacial nerve 86
 zygomaticotemporal nerve 86
 cranial nerve 7 (facial) 70
 cranial nerve 12 (hypoglossal) 73
 intercostal 153
 mylohyoid 95
 nasopalatine 77, 80
 obturator 233
 palatine
 greater 78
 lesser 79
 sacral
 anterior divisions 220
 posterior divisions 221
 spinal 139
 suprascapular 165
 zygomaticofacial 86
 zygomaticotemporal 86
 Neural 21, 586
 Neural arch *see vertebral arch*
 Neurocranium 51, 54, 60
 Nevada State Museum 515–520
 NMNH Fetal collection 382
 Nondisplaced fracture 434
 Nonhuman teeth
 identifying 110
 Nonmetric trait 476, 586
 cranial 97–98
 auditory exostosis 98
 condylar canal patency 98
 flexure of superior sagittal sulcus 98
 inca bone 98
 incomplete foramen ovale 98
 incomplete foramen spinosum 98
 infraorbital suture, persistent 97
 mandibular torus 98
 mastoid foramen 98
 mental foramina, multiple 98
 metopic suture, persistent 97
 multiple infraorbital foramina 97
 mylohyoid bridge 98
 parietal foramen 56, 66
 pterygo-alar bridge 98
 supraorbital notch or foramen 97
 sutural bones 46, 98, 590
 tympanic dehiscence 98
 zygomaticofacial foramina, size and
 number 97
 dental
 Carabelli's effects 106, 342, 481, 579
 incisor shoveling 481
 incisor winging 481
 protostylid effects 106
 shovel-shaped incisors 107
 supernumerary molars 107
 heritability 479
 postcranial
 Allen's fossa 252
 anterior calcaneal facet 284
 anterior femoral neck torsion 252
 bifid rib 158
 cervical rib 158
 cleft patella 254
 costoclavicular sulcus 165
 femoral bowing 252
 fovea capitis 252
 lumbar rib 158
 patellar spurs 254
 platycnemia 263
 Poirier's facet 252
 retroarticular spur 138
 saber shins *see platycnemia*
 squatting facets
 of talus 276, 284
 of tibia 263
 sternal foramen 152
 supernumerary ribs 153
 supraclavicular foramen 165
 third trochanter 246, 252
 tibial bowing 263
 trochlear extension 284
 vastus fossa 254
 vastus notch 254
 Nonmetric variation 476–480
 Norma basilaris 54
 Norma frontalis 54
 Norma lateralis 54
 Norma occipitalis 54

- Norma verticalis 54
- Notch
- acetabular 227 *see acetabular fossa*
 - clavicular 149, 150
 - costal 149, 150, 151
 - ethmoidal 62, 63, 82
 - fibular 260, 261
 - intercondylar *see intercondylar fossa*
 - intervertebral 139
 - jugular 73, 149, 150
 - mandibular 92, 94, 95
 - mastoid 70
 - parietal 67
 - patellar 250, 252
 - radial 184, 191, 193, 194, 195, 196
 - scapular 165, 166
 - sciatic
 - greater 228, 229, 231, 232
 - lesser 229, 230, 232
 - substernal *see jugular notch*
 - supraorbital 60, 61, 63
 - suprasternal *see jugular notch*
 - trochlear 192, 197
 - shape 197
 - ulnar 186, 187, 189, 191, 195
- Nuchal 21, 586
- Nuchal crest
 - in sex determination 411
- Nuchal ligament 72, 299
- Nuchal lines 56, 71
- Nuchal planum 71, 72
- Nuclear DNA 491, 494, 496
- Nucleus pulposus 131
- Nutrient arteries 180
- Nutrient foramen
 - developmental origin 37
 - of clavicle 162, 301
 - of femur 243, 247
 - of fibula 265, 266, 268
 - of humerus 176, 180, 181
 - of radius 185, 186, 187, 194
 - of tibia 255
 - of ulna 193
- Nuvakwewtaqa 372
- O**
- Obelion (ob.) 56, 98
- Oblique border *see posteromedial border*
- Oblique cord 305, 307
- Oblique fracture 434
- Oblique line of mandible 92, 94
- Oblique popliteal ligament 313
- Oblique ridge
 - of clavicle *see trapezoid line*
 - of scapula 165, 172
- Obliquus capitis superior muscle 299
- Obturator artery 233
- Obturator canal 233
- Obturator crest 233
- Obturator externus groove 246
- Obturator externus muscle 246, 311
- Obturator foramen 229, 231, 233, 246
- Obturator groove 233
- Obturator internus muscle 232, 246, 311
- Obturator membrane 233
- Obturator nerve 233
- Obturator sulcus *see obturator groove*
- Obturator tubercle
 - anterior 233
 - posterior 233
- Obturator vein 233
- Occipital angle 64, 65, 66
- Occipital artery 67, 68
- Occipital bone 44, 46, 47, 48, 49, 50, 71–75, 98
- Occipital chord 96
- Occipital condyle 72
 - in determinations of sex 412
- Occipital groove 68, 69, 71
- Occipital lobe 67, 74
- Occipital planum 71, 72
- Occipital squama 71, 74
- Occipitofrontalis muscle 299
- Occipitomarginal sulcus 74
- Occipitomastoid suture 44, 46, 48, 50, 53, 58, 73, 98
- Occlusal 15, 586
- Occlusal contact facets 106
- Occlusal surface 103
- Occupational markers *see musculoskeletal stress markers*
- Odontoblast 107, 586
- Odontogenesis 586
- Odontogenic homeobox code hypothesis 108, 109
- Odontoid process 136
- Odontology, forensic 425
- Odontometric 586
- OI *see osteogenesis imperfecta*
- Old adult 384, 586
- Olduvai Gorge 541
- Olecranon 180, 191, 192, 193, 194, 195, 196, 197
- Olecranon fossa 177, 180, 181
- Olfaction 81
- Olfactory nerve 82
- OMIM *see Online Mendelian Inheritance in Man database*
- Omo valley 541
- Online Mendelian Inheritance in Man database 452
- Ontogenesis 586
- Ontogenetic variation 26, 27
- Ontogeny 25, 26, 37, 39, 459, 586
- Opisthion (o.) 56
- Opisthocranium (op.) 56
- Opposition 15, 218, 586
- Optic canal 87, 89
- Orale (ol.) 57
- Orbicularis oculi muscle 299
- Orbicularis oris muscle 299
- Orbit 43, 51, 60, 61, 75, 82, 83, 90
- Orbital 21, 586
- Orbital breadth 96
- Orbitale (or.) 54, 58, 76
- Orbital height 96
- Orbital index 97
- Orbital margin (of zygomatic) 85
- Orbital surfaces 90
 - of sphenoid 88
- Orientation of skull
 - norma basilaris 54
 - norma frontalis 54
 - norma lateralis 54
 - norma occipitalis 54
 - norma verticalis 54
- Origin, muscular 15, 32, 586
- Orthograde 13, 586
- Os cotyledon 233
- Os coxae 219, 220, 223, 226–234, 240
 - confusion with scapula 170
 - ilium 226, 227, 232–234
 - ischium 219, 226, 227, 232, 233
 - confusion with rib frag. 156
 - pubis 219, 226, 227, 232, 233
- Ossification
 - endochondral 37, 582
 - intramembranous 37
- Ossification center
 - primary 588
 - secondary 589
- Ossific nodules 394, 399
- Ossuary 586
- Osteitis 443, 586
- Osteo- 20
- Osteoarthritis 441–442, 517–520, 586
- Osteoblast 37, 38, 39, 40, 587
- Osteocartilagenous exostosis *see osteochondroma*
- Osteochondritis dissecans 440–441
- Osteochondroma 453, 587
- Osteoclast 37, 587
- Osteocyte 35, 37, 587
- Osteogenesis 37, 40, 451, 587 *see ossification*
- Osteogenesis imperfecta 450
- Osteogenic 34, 40
- Osteoid 37
- Osteoma 452, 587
- Osteomalacia 447, 587, 589
- Osteometric 587
- Osteometric board 341
- Osteometric instruments 339–345, 576
- Osteomyelitis 441, 443–446, 587
- Osteon 35, 36, 587
 - primary 36
 - secondary *see haversian system*

- Osteonecrosis 437
Osteopenia 447
Osteophyte 441, 587
Osteoporosis 447, 587
Osteoprogenitor cells 39
 chondroblasts 39
 osteoblasts 37, 38, 39, 40
Osteosarcoma 452, 587
Outer lip of iliac crest 232
Outlet, pelvic 239
Ovoid 23, 587
- P**
- Palatal index 97
Palate breadth 96
Palate length 96
Palatine bone 48, 78–79
Palatine foramina
 greater 78
 lesser 78, 79
Palatine groove
 greater 76, 77
Palatine nerve
 greater 78
 lesser 79
Palatine process
 of maxilla 76, 77
Paleoanthropology 533
Paleodemography 475, 485, 515–520, 587
 of Atapuerca fossils 538
Paleoepidemiology 429, 475
Paleontological sites *see also archaeological sites*
 Aramis 541–558
 Hadar 541
 Laetoli 542, 543
 Middle Awash 543
 Taung 374
Paleopathology 429, 587 *see diseases and disorders; see also pseudopathology*
 of Atapuerca fossils 538
 websites 574
Palmar 14, 202, 587
Palmar radioulnar ligament 305
Palpation 7
Para- 20
Parabolic 23, 587
Paracone 105, 106
Paracoronal section 11
Paraloid™ B-72 332
Paramasticatory functions 107
Parasagittal section 20, 587
Parietal bone 44, 45, 46, 47, 48, 49, 64–66
Parietal chord 96
Parietal foramen 56, 64, 65, 66, 97, 98
Parietal notch 67, 68, 69, 98
Parietal striae 64, 66
Parietal tuber 64, 65
Parietomastoid process 68
Parietomastoid suture 44, 46, 53, 58, 68
Pars orbitalis 62, 63
Part *see also portion*
 basilar 72
 condylar *see lateral*
 lateral 72
Parturition 397
 and dorsal pitting 399
 and preauricular sulci 399
Patella 252–253
Patellar 21, 587
Patellar apex 252
Patellar base 252
Patellar ligament 252, 255, 313
Patellar lip 242, 244, 247, 248
Patellar notch 250, 252
Patellar spur 254
Patellar surface 242, 248
Patellar surface (of femur) 247, 252
Patent 97, 98
Pathological fracture 435, 587
Pathology
 abscess 455
 apical 538
 achondroplasia 450, 451
 acromegaly 448
 anemia 448–450, 528
 ankylosing spondylitis 443
 bone tumors 452–453
 caries 455
 chondrosarcomas 453
 craniosynostosis 439
 diffuse idiopathic skeletal hyperostosis 443
 enamel hypoplasia 107, 455–456, 482, 519–520, 538, 581
 endocrine disturbances
 acromegaly 448
 eosinophilic granuloma 450
 Ewing's sarcoma 453
 fibrodysplasia ossificans progressiva 40–41, 451–453
 fibrosarcomas 453
 gigantism 448
 Hand-Schüller-Christian disease 450
 Huntington's disease 493
 hydrocephaly 439
 kyphosis 440
 Langerhans cell histiocytosis 450
 Legg-Calvé-Perthes disease 440
 Letterer-Siwe disease 450
 leukemia 450
 microcephaly 439
 multiple myeloma 450
 osteitis 443
 osteoarthritis 441, 442, 517–520
 osteochondritis dissecans 440
 osteochondroma 453
 osteomalacia 447
 osteoma 452
 osteomyelitis 443, 444, 445
 osteoporosis 447
 osteosarcoma 452
 periodontitis 454
 periostitis 443, 446, 519
 pituuitary dwarfism 448
 porotic hyperostosis 449–450
 red blood cell disorders 448–450
 rheumatoid arthritis 443
 rickets 447
 scoliosis 440
 scurvy 447
 sickle cell anemia 448, 493
 spina bifida 439
 syphilis 444
 treponemal infection 444
 tuberculosis 444
 white blood cell disorders 450
Pattern formation 39
PCL *see posterior cruciate ligament*
PCR *see polymerase chain reaction*
Pectineal line 232, 246
Pectineus muscle 232, 246, 311
Pectoralis major muscle 162, 163, 177, 301, 303
Pedal 21, 587
Pedicle 132, 133, 139
Pelvic brim 237
Pelvic cavity 237
Pelvic inclination 237
Pelvic inlet 237
Pelvic outlet 239
Pelvic surface 237
 of sacrum 220
Pelvis
 “false” *see greater pelvis*
 greater 237
 lesser 237
 “true” *see lesser pelvis*
Percussion marks 468
 pits 470, 471
 striae 470
Perforated sternum *see sternal foramen*
Peri- 20
Perichondrium 37
Perikymata 587, 590
Perimortem 354, 429, 435, 439, 460, 587
Perinatal 587
Periodontal disease 454–455
Periodontal ligaments 103
Periodontitis 454, 587
Periosteal inflammation (periostitis?) 519
Periosteum 29, 34, 37, 38, 39, 40, 446, 508, 587
Periostitis 443, 446, 587
Periostosis 587
Permanent dentition 111
Peroneus brevis *see fibularis brevis*

- Peroneus longus *see fibularis longus*
- Perpendicular plate
of ethmoid 82, 83
of palatine 78, 79
of vomer 80
- Personal identification 587 *see also individuation*
- Petralona 335
- Petrous pyramid 67, 68, 69, 70
- Phalangeal trochlea 215, 291
- Phalanx
foot 271, 291–292
 distal 292
 intermediate 292
 proximal 292
 terminal *see distal foot phalanx*
hand 202, 210, 211, 212, 215–216
 distal 216
 intermediate 216
 proximal 216
 terminal *see distal hand phalanx*
- Phenice technique 418–419
- Phoebe A. Hearst Museum of Anthropology 430
- Photography 345–349
-physis 20
-phyte 20
- Phytoliths 483
- Pig teeth (worn)
 confusion with human teeth 110
- Pillar, iliac 227, 228, 234
- Pitdown 367, 374
- Pine Ridge Reservation 365
- Pin flags 321, 324
- Piriform aperture *see anterior nasal aperture*
- Piriformis muscle 232, 246, 311
- Pisiform 200, 202, 204–205, 208
 shape term 23, 588
- Pituitary disorders 448
- Pituitary dwarfism 448
- Pituitary fossa *see hypophyseal fossa*
- Planar joint 30, 588
- Plane
 nuchal planum 71, 72
 occipital planum 71, 72
- Planes of reference 11–12 *see also directional terms*
 coronal 11, 580
 frontal *see coronal plane*
 horizontal section *see transverse section*
 median 11
 midline 11
 midsagittal 11
 paracoronal section 11
 parasagittal section 11
 sagittal 11, 20, 589
 transverse section 11, 590
- Plantar 14, 271, 588
- Plantarflexion 16, 588
- Plantaris muscle 311
- Plants
 C3 plants 484, 519
 C4 plants 484, 519
- Plaque 455 *see also calculus*
 on femoral head 252
- Plateau, sacral 219, 223
- Plate
 cribriform 82
 growth *see epiphyseal plate*
 horizontal
 of palatine 78
 pars orbitalis 62, 63
 perpendicular
 of ethmoid 82, 83
 of palatine 78, 79
 of vomer 80
- Platy- 20
- Platycnemia 263
- Platycnemic index 263
- Platysma muscle 299
- Pluripotent 39
- Pogonion (pg.) 57
- Poirier's facet 252
- Poisoning 448
- Pollex 21, 202, 588
- Pollical 21, 588
- Polymerase chain reaction 493, 494, 588
- Polytetrafluoroethylene (PTFE) tape 358
- Popliteal 21, 588
- Popliteal groove 247, 250, 255
- Popliteal line *see soleal line*
- Popliteal surface 247
 of femur 247
 of tibia 255
- Popliteus fascia 255
- Popliteus muscle 247, 255, 311, 313
- Population biology 475–490
- Porion (po.) 54, 56, 58
- Porosity 588
- Porotic hyperostosis 449, 449–450, 519, 588
- Portion
 alveolar (of mandible) 92, 95
 horizontal (of frontal) 60
 intermaxillary (of median palatine suture) 46, 48, 57
 interpalatine (of median palatine suture) 48
 lateral (of occipital) 53
 petrous (of temporal) 67
 squamous (of occipital) 53, 71
- Position
 tooth 103, 104, 109
- Postcranial 11, 588
- Posterior 11, 13, 588
- Posterior border
 of fibula 265, 267 *see posterior crest*
 of palatine 78
 of perpendicular plate of vomer 79
 of radius 186
 of ulna 194
 of vomer 80
- Posterior clinoid process 87, 88, 89
- Posterior colliculus 260
- Posterior cranial fossae 51
- Posterior crest (of fibula) 263
- Posterior cruciate ligament 247, 255, 311
- Posterior division of the sacral nerve 221
- Posterior gluteal line 227
- Posterior groove 258, 260
- Posterior inferior iliac spine 228, 232
- Posterior intercondylar area 255
- Posterior lacrimal crest 58, 83
- Posterior margin
 of fibula *see posterior crest*
- Posterior meniscofemoral ligament 311
- Posterior nasal aperture 80
- Posterior nasal spine 78, 79
- Posterior oblique line 186
- Posterior obturator tubercle 233
- Posterior sacral foramen 221
- Posterior superior iliac spine 228, 232, 235
- Posterior surface
 of fibula 265, 266, 267, 268
 of humerus 179
 of radius 185, 186, 187
 of tibia 255
 of ulna 193
- Posterior talar facet 278
- Posterior talofibular ligament 268, 314–315
- Posterior tubercle
 of C-1 136
 of transverse process 138
- Posteromedial border
 of fibula 265, 266
- Postglenoid process 68, 69
- Postmortem changes 429
- Postmortem fracture 461
- Postmortem modification 459, 588
- Postnatal 39
- Posture
 orthograde 13, 586
 pronograde 13, 588
- Pot polish 470
- Pre- 20
- Preauricular sulcus 232, 236, 399
- Precision 380
- Prefixes 18–20
- Premaxillary suture 77
- Premolars 102, 103
- Prenatal 588
- Preparation
 of archaeological bone 333
 of forensic bone 334
 of fossils 334–335
- Pretoria bone collection 382

- Primary bony callus 40, 433, 435, 578, 588
 Primary dentition *see deciduous dentition*
 Primary interment 321, 323, 460, 588
 Primary malignant bone tumors 452
 Primary ossification center 588
 Primary osteon 36
 Primary roots 104
 Procerus muscle 299
 Process
 accessory 143
 acromial 170, 174
 alveolar 55, 75, 76, 77, 78
 articular
 inferior
 of cervical vertebrae 133
 superior
 of sacrum 221
 clinoid
 anterior 88, 89, 90, 91
 posterior 87, 88, 89
 coracoid 162, 165, 170, 171, 172, 197
 coronoid 59, 92, 94, 95, 99, 180, 191, 192, 193
 definition 16, 588
 dens 136
 entoglenoid 68, 69
 ethmoidal
 of inf. nasal concha 81
 frontal
 of maxilla 75, 76, 77, 85, 86
 of zygomatic 58
 jugular 73, 74
 lacrimal
 of inf. nasal concha 81
 lateral
 of calcaneus 279
 of talus 279
 mammillary 143
 mastoid 58, 67, 68
 in sex determination 411
 maxillary
 of inf. nasal concha 81
 of zygomatic 85, 86
 medial
 of calcaneus 279
 odontoid 136
 palatine 76, 77
 parietomastoid 68
 postglenoid 68, 69
 pterygoid 88, 90
 pyramidal
 of palatine 77, 78, 79
 of temporal *see petrous pyramid*
 spinous
 of cervical vertebrae 132, 136
 of lumbar vertebrae 143
 of thoracic vertebrae 139
 of vertebra
 confusion with hyoid 130
 styloid
 of fibula 263–268
 of MC 3 209
 of radius 185–189
 of temporal 69, 70, 129
 of ulna 191–195
 supracondylar
 of humerus 184
 temporal
 of zygomatic 58, 85, 86
 transverse 132, 133, 135, 143
 of cervical vertebrae 136
 of coccyx 225, 226
 of lumbar vertebrae 143
 of thoracic vertebra
 confusion with prox. rib frag. 156
 of thoracic vertebrae 139
 uncinate 132, 136
 vaginal 69, 70
 xiphoid 151, 159
 zygomatic
 of frontal 60, 61, 62
 of maxilla 75, 76
 of temporal 58, 67–71, 86
 confusion with zygomatic 86
 Professional associations
 American Academy of Forensic Sciences 359
 American Association of Physical Anthropologists 375
 National Association for the Practice of Anthropology 377
 websites 575
 Promontory, sacral 219, 222, 223
 Pronation 16, 197, 588
 Pronator quadratus muscle 195, 305, 307
 Pronator ridge 191, 195
 Pronator teres muscle 181, 186, 197, 303, 305, 307
 Pronator tuberosity 186
 Pronograde 13, 588
 Prosthion (pr.) 55, 96
 Proto- 20
 Protocone(id) 105, 106
 Protostylid effects 106
 Protuberance
 external occipital 56, 71, 72
 mental 93, 94
 Provenience 334, 588
 Proximal 13, 588
 applied to foot bones 271
 Proximal fibular articular surface 263
 Proximal foot phalanx 292
 Proximal hand phalanx 216
 Pseudarthrosis 435, 436, 588
 Pseudopathology 431
 Psoas major muscle 246, 311
 Psoas minor muscle 309
 Pterion (pt.) 58
 Pterygo-alar bridge 98
 Pterygo-alar ligament 98
 Pterygoid canal 88, 91
 Pterygoid fossa 89, 90, 91
 Pterygoid fovea 94
 Pterygoid hamulus 88, 89, 90
 Pterygoid plates
 lateral 77, 88, 89, 90, 98, 99
 medial 88, 89, 90
 Pterygoid process 88, 90
 Pterygoid tuberosities 93, 95
 Pterygopalatine canal 78, 79
 Pterygospinous bridge 98
 Pterygospinous ligament 90, 98
 PTFE *see polytetrafluoroethylene tape*
 Pubic arch 237
 Pubic body 231, 232, 233
 Pubic crest 232
 Pubic ligaments 233
 Pubic rami
 iliopubic 227, 229, 232
 inferior *see ischiopubic ramus*
 ischiopubic 227, 228, 229, 230, 232, 233, 247
 superior *see iliopubic ramus*
 Pubic spine *see pubic tubercle*
 Pubic symphysis 226, 233
 Pubic tubercle 232
 extension of 399
 Pubis 219, 226, 227, 232, 233
 confusion with scapula 170
 Pubofemoral ligament 233
 Pulp 104, 105, 106, 107
 Pulp chamber 106, 107
 Pyogenic osteomyelitis 446
 Pyramidal process
 of palatine 77, 78, 79
 of temporal *see petrous pyramid*
 Pyramid, petrous 67, 68, 69, 70
 Q
 Quadrate 23, 588
 Quadrate tubercle 243, 244, 245, 246
 Quadratus femoris muscle 232, 246, 311
 Quadriceps femoris muscle 246, 252, 255, 270, 297 *see also vastus muscles, rectus femoris*
 Quadriceps tendon 254
 R
 R206H ACVR1 mutation 41 *see also fibrodysplasia ossificans progressiva*
 Rabbit
 IDD as human 318
 Radial 202
 Radial anteroposterior midshaft diameter 190
 Radial biomechanical length 190

- Radial collateral ligament 180
Radial fossa 180, 181
Radial head 184, 185, 186, 187, 188, 189, 190, 195
Radial head anteroposterior diameter 190
Radial midshaft circumference 190
Radial mediolateral midshaft diameter 190
Radial neck 184, 185, 186, 187, 188
Radial notch 184, 191, 193, 194, 195, 196
Radial shaft 184
Radial sulcus 180
Radial tuberosity 184, 185, 186, 187, 189, 197
Radiocarpal articulation 197
Radiograph 588
Radiography 349
Radiology
 websites 574
Radioulnar joint 197
Radioulnar ligaments
 dorsal 305
 palmar 305
Ramus
 definition 17, 588
 mandibular
 ascending 59, 91, 94
 horizontal *see corpus*
 pubic
 iliopubic 227, 229, 232
 inferior *see ischiopubic ramus*
 ischiopubic 227, 228, 229, 230, 232, 233, 247
 superior *see iliopubic ramus*
Ratio *see also index*
 amino acid 496
 isotopic 484–485
 sex 412, 538
Ray 202
Reactive bone 588
Reconstruction
 versus restoration 337
Rectus 23, 588
Rectus abdominis muscle 232, 309
Rectus capitis anterior muscle 299
Rectus capitis lateralis muscle 299
Rectus capitis posterior major muscle 299
Rectus capitis posterior minor muscle 299
Rectus femoris muscle 232
Red blood cell disorders 448–450
Red marrow 32
Refitting 524
Region, anatomical 21–22
Remodeling 36, 37, 38, 40, 405, 406, 430, 447, 460, 502, 588
 osteonal 406
Reporting 352–354
Resorption, alveolar 37, 107, 399, 430, 447, 528, 589
Restoration 336–337
 versus reconstruction 337
Retro- 20
Retroarticular bridge 146
Retroarticular spur 138
Rheumatoid arthritis 443, 589
Rhinion (rhi.) 55
Rhomboid 23, 589
Rhomboid ligament *see costoclavicular ligament*
Rhomboid major muscle 174
Rib 153–159
 cervical 146
 lumbar 146
Rickets 447, 589
Ridge
 alveolar 57
 cingulum 106
 definition 17, 589
 endocoronoid 92, 95
 guiding 191, 192
 oblique
 of clavicle *see trapezoid line*
 of scapula 165, 172
 pronator 191
 trapezial 205
Right 11, 589
Rims
 ventral *see obturator crest*
Root (of tooth) 104, 105, 106
Root canal 106
Root cones 104
Root etching 524
Rostock protocol 487
Rostrum (sphenoidal) 87
Rotation 15, 71, 147, 159, 174, 177, 178, 184, 191, 192, 197, 246
 medial 165
Rotator cuff muscles 177
 infraspinatus 177, 184
 subscapularis 176, 177
 supraspinatus 176, 184
 teres minor 177
rRNA 39
Rugose 589
Rugosity
 for deltoideus muscle 163
 for infraspinatus muscle 176
 for pectoralis major muscle 162, 163
 for serratus anterior muscle 170
 for supraspinatus muscle 176
 for teres major muscle 170
 for teres minor muscle 176
 for trapezius muscle 162, 163
S
Saber shins *see platycnemia*
Sacral alae 219, 223, 233
Sacral apex 222
Sacral base 219
Sacral canal 220
Sacral crest
 lateral 222
 median 221
Sacral foramen
 anterior 220
 dorsal *see posterior sacral foramina*
 pelvic *see anterior sacral foramina*
 posterior 221
Sacral hiatus 221
 expanded 225–226
Sacralized vertebra 225
Sacral nerve
 anterior divisions 220
 posterior divisions 221
Sacral plateau 219, 223
Sacral promontory 219, 222, 223
Sacral spine *see median crest*
Sacral tuberosity 220
Sacral vertebrae 219, 221, 222, 223 *see also sacrum*
Sacrococcygeal fusion 226
Sacroiliac joint 220
Sacroiliac ligaments 227, 234
Sacro pelvic surface 227
Sacrospinous ligament 232
Sacrotuberus ligament 232
Sacrum 219–223, 225, 232
Saddle-shaped *see sellar*
Saddle-shaped joint 589
Sagittal ossicle 98
Sagittal plane 11, 589
Sagittal sinus 74
 superior 61, 62, 65
Sagittal sulcus
 of frontal 61, 62
 of occipital 73, 74
 superior sagittal sulcus 98
 flexure of 98
 of parietal 65, 66
Sagittal suture 45, 46, 47, 49, 52, 56, 65, 66, 98, 589
Sample
 DNA 491–492
 matrix 321, 334
Sarcoma 589
Sartorius muscle 232, 313
Scalene tubercle 156, 157
Scanning electron microscope 589
 and dental microwear 482
Scaphocephaly 479
Scaphoid 200, 201, 202, 202–203, 203
 confusion with navicular 281
Scaphoid tubercle 202, 203
Scapula 165–174
 confusion with pelvic frags. 170
 confusion with sphenoid 171
 scapula fragments

- confusion with iliac frags. 233
- Scapular body 170
- Scapular foramen 166
- Scapular index 172
- Scapular neck 166, 170
- Scapular notch 165, 166
- Scapular spine 170, 171, 172, 174
- Sciatic notch
 - greater 228, 229, 231, 232
 - in determination of sex 415, 417
 - lesser 229, 230, 232
- Sclerosis 504
- Scoliosis 440–441
- Scrape marks 468
- Scurvy 447
- Search 318
- Search image 545
- Secondary center of ossification 589
- Secondary dentition *see permanent dentition*
- Secondary interment 323, 589
- Secondary osteon 35, 36, *see haversian system*
- Second cuneiform *see intermediate cuneiform*
- Second metacarpal *see MC 2*
- Second metatarsal *see MT 2*
- Section
 - coronal 11, 580
 - frontal *see coronal*
 - horizontal *see transverse*
 - median 11
 - midline 11
 - midsagittal 11
 - paracoronal 11
 - parasagittal 11
 - sagittal 11, 20, 589
 - transverse 11, 590
- Sellar 23, 589
- Sellar joint 30
- Sella turcica 87
- SEM *see scanning electron microscope*
- Semi- 20
- Semimembranosus muscle 232, 309, 313
- Semispinalis capitis muscle 299
- Semitendinosus muscle 232, 313
- Septal aperture 180, 184, 478
- Septum
 - midline mandibular alveolar 57
 - midline maxillary alveolar 55
 - nasal 79, 82, 90
- Serial homology 147, 589
- Seriation 380, 384, 387, 388, 405, 411
 - by age 384
 - by sex 412
- Serratus anterior muscle 156, 170, 174
- Sesamoid 23, 589
- Sesamoid bones 208, 271, 285, 589
 - of foot 291
 - in hand 199, 204
- Sesamoid groove 285
- Sex *see sex determination*
- versus gender 408
- Sex determination 386, 400, 406, 408, 412, 418, 426
 - methods
 - decision analysis 413
 - Phenice technique 418–419
 - seriation 380, 384, 387, 388, 405, 411, 412
 - traits assessed
 - mastoid process 411
 - mental eminence 411
 - nuchal crest 411
 - subpubic angle 240
 - supraorbital margin 411
- Sexing *see sex determination*
- Sex-linked variation 26, 27, 386, 409–413, 419, 494, 501
- Sex ratios 412
- Sexual dimorphism 26, 410, 412, 494, 501, 589
- Shaft 17, 589
 - of femur 246
 - of fibula 263
 - of hand phalanx 216
 - of humerus 178, 181, 183, 197
 - of metatarsal 285
 - of radius 184
 - of rib 153, 155, 156
 - of tibia 255
 - of ulna 193
- Shape-related terms 22–23
- Shin-bone *see tibia*
- Shoulder girdle 161
- Shoulder joint 165, 170, 174
- Shoveling *see shovel-shaped incisors*
- Shovel-shaped incisors 107, 481, 589
- Sickle cell anemia 448, 493
- Sides
 - left 585
 - right 589
- σ (sigma) *see standard error*
- Sigmoid 23, 589
- Sigmoid sinus 70
- Sigmoid sulcus 65, 66, 68, 69, 70, 71, 74
- Signaling molecules 40
- Sinus
 - air 54
 - ethmoid cells 82
 - frontal 62, 63
 - maxillary 75, 76, 77, 79
 - sphenoidal 87, 88
 - definition 18, 589
 - veinous
 - sagittal 74
 - superior sagittal sinus 61, 62, 65
 - sigmoid 70
 - transverse 66, 70, 74
- Sioux 363
- Dakota tribe 363
- Lakota tribe 363
- Nakota tribe 363
- Sioux Tribal Council 363
- Site datum 321
- Sites
 - archaeological
 - arctic 462
 - Bordeaux Trading Post 320
 - CA-LAS-7 325
 - Cottonwood Canyon 522–532
 - Crow Creek 363, 364, 367
 - Egypt 462
 - Engis 336
 - Herculaneum 1
 - Kennewick 357, 368–369, 372
 - Lake Turkana 541
 - Libben 446, 486
 - Little Big Horn 357
 - Mancos Canyon 530
 - Mesa Verde 521
 - Nuvakwewaqa 372
 - Olduvai Gorge 541
 - Omo valley 541
 - Peruvian desert 462
 - Petralona 335
 - Spitsbergen 365
 - Stillwater Marsh 513–519
 - Zhoukoudian 521
 - paleontological
 - Aramis 541–558
 - Hadar 541
 - Laetoli 542, 543
 - Middle Awash 543
 - Taung 374
- Skeletal collections, documented 382–383
- Skeletal dysplasias 450–452
- Skeletal trauma 433–439
- Skeleton
 - appendicular skeleton 11
 - axial skeleton 11
 - bones *refer to individual bones*
- Skull 51–100, 589
 - proper handling 51
- Skull base 43
- Sliding caliper 339
- Smithsonian Institution, National Museum
 - of Natural History 404
- Socket
 - ear *see external acoustic meatus*
 - eye *see orbit*
 - joint *see ball and socket*
 - tooth *see alveolus*
- Soleal line 255, 258
- Soleus muscle 255, 268, 277, 313, 315
- SOP *see standard operating procedure*
- Sorting 337–338
- Sphenobasion (sphba.) 57
- Sphenofrontal suture 44, 50

- Sphenoid 44, 45, 48, 50, 87–91
 Sphenoidal angle 64, 65
 Sphenoidal crest 87, 88, 90
 Sphenoidal rostrum 87, 89
 Sphenoidal sinus 87, 88
 Sphenoid bone
 confusion with scapula 171
 Sphenomandibular ligament 95, 299
 Sphenooccipital synchondrosis 52, 74, 589
 Sphenosquamous suture 69, 70, 91
 Sphenotemporal suture 44, 48, 50
 Spherical 23
 Spina bifida 225–226, 439
 Spinal cord 131, 132, 139
 Spina limitans 227
 Spinal nerves 139
 Spine
 angular 88, 89, 90, 98
 anterior nasal 75, 76
 definition 16, 589
 iliac
 anterior inferior 232
 anterior superior 226, 232, 235
 posterior inferior 228, 232
 posterior superior 228, 232, 235
 ischial 228, 232
 mental 92, 93
 nasal
 anterior 75, 76
 posterior 78, 79
 of cervical vertebrae 174
 of thoracic vertebrae 174
 posterior nasal 78, 79
 pubic *see pubic tubercle*
 sacral *see median crest*
 scapular 170, 171, 172, 174
 spina limitans 227
 Spinous process
 of cervical vertebrae 132, 136
 confusion with hyoid 130
 of lumbar vertebra 132, 143
 of thoracic vertebrae 132, 139
 Spiral line 243, 244, 246
 Spitalfields 391
 Spitsbergen 365
 Splanchno- 20
 Splanchnocranium 51, 589
 Splenius capitis muscle 67, 299
 Spongy hyperostosis *see porotic hyperostosis*
 Spreading caliper 339
 Spur
 pterygospinous 98
 retroarticular 138, 146
 supratrochlear 184
 Squama
 frontal 60, 61, 63
 occipital 71, 74
 temporal 67, 68, 70
 Squamosal *see squamous*
 of temporal 69, 70, 129
 of ulna 191–195
 Stylomandibular ligament 299
 Stylo mastoid artery 70
 Stylo mastoid foramen 69
 Stylopharyngeus muscle 299
 Sub- 20
 Subadult 590
 fetus 384
 infant 384
 child 384, 449, 456
 adolescent 384
 Subchondral bone 590
 Subclavian artery 156, 157
 Subclavian groove *see subclavian sulcus*
 Subclavian sulcus 162
 Subclavian vein 156
 Subclavius muscle 162, 301
 Subcutaneous 13, 590
 Subcutaneous areas
 triangular 264, 267
 Sublingual fossa 92, 93
 Sublingual gland 93
 Submandibular fossa 92, 93
 Submandibular gland 92
 Subperiosteal lesions 510
 Subpubic angle 240
 Subscapular fossa 165
 Subscapularis muscle 165, 176, 177, 303
 Substernal notch *see jugular notch*
 Substrate 590
 Suffixes 18–20
 Sulcus
 circumflex 173
 definition 18, 590
 extramolar 92
 infraorbital 75, 76
 obturator *see obturator groove*
 occipitomarginal 74
 preauricular 232, 236, 399
 radial 180
 sagittal
 of frontal 61, 62
 of occipital 73, 74
 superior 98
 of parietal 65, 66
 sigmoid 65, 66, 68, 70, 74
 subclavian 162
 sulcus tali 277
 sustentacular 279
 transverse 65, 73, 74
 Sum of squares 343–344
 Super- 20
 Superciliary arch 60, 61, 63
 Superficial 13, 590
 Superior 13, 590
 Superior angle (of scapula) 170, 172
 Superior articular facet
 of sacrum 221, 222, 223

- of vertebra 132, 133, 136, 139, 142
 - Superior border of scapula 165
 - Superior nuchal line 56, 71, 72
 - Superior orbital fissure 88, 89, 90
 - Superior pharyngeal constrictor muscle 299
 - Superior pubic ramus 229, 232
 - Superior sagittal sinus 61, 62, 65
 - Superior sagittal sulcus 98
 - Superior surface of clavicle 162
 - Superior temporal line 64, 65, 99
 - Supernumerary molar 107
 - Supernumerary rib 153
 - Supernumerary teeth 107, 590
 - Supination 16, 197, 198, 590
 - Supinator crest 191
 - Supinator muscle 180, 195, 197, 305, 307
 - Suppurative osteomyelitis *see pyogenic osteomyelitis*
 - Supra- 20
 - Supra-acetabular groove 227
 - Supraclavicular foramen 165
 - Supracondylar process 184
 - Supraglenoid tubercle 170, 172
 - Supramastoid crest 67, 68
 - Suprameatal crest 67, 68
 - Supraorbital artery 61
 - Supraorbital foramen 60, 61, 63, 97
 - Supraorbital margin 60, 61, 63
 - in sex determination 411
 - Supraorbital nerve 61
 - Supraorbital notch 60, 61, 63
 - Supraorbital vein 61
 - Suprascapular ligament 173
 - Suprascapular nerve 165
 - Supraspinatus muscle 170, 176, 184, 303
 - Supraspinous fossa 170, 172
 - Supraspinous ligament 132
 - Suprasternal notch *see jugular notch*
 - Suprastyloid crest 185, 187, 188
 - Supratrochlear spur *see supracondylar process*
 - Surface
 - anterior
 - of radius 185, 187, 188
 - of ulna 193
 - anterolateral
 - of humerus 179
 - anteromedial
 - of humerus 178
 - auricular
 - of ilium 227, 232, 234
 - confusion with sacrum 223
 - of sacrum 220, 222, 223
 - confusion with ilium 223
 - carpal articular 187
 - lunate facet 189
 - scaphoid facet 189
 - costal
 - of scapula 174
 - distal fibular articular 260
 - ectocranial 582
 - endocranial 582
 - for interosseous ligament
 - on fibula 264, 266
 - gluteal 227
 - interosseous
 - of tibia 255
 - lateral
 - of fibula 263, 264, 265, 267
 - of radius 185, 186, 188
 - lateral malleolar
 - of talus 276
 - lunate
 - of acetabulum 227, 228, 234
 - malleolar
 - lateral (of talus) 276
 - medial (of talus) 276
 - medial
 - of fibula 264, 266, 268
 - of ulna 192, 193
 - medial malleolar
 - of talus 276
 - occlusal 103
 - orbital 90
 - patellar 242, 248
 - pelvic 237
 - of sacrum 220
 - popliteal
 - of femur 247
 - of tibia 255
 - posterior
 - of fibula 265, 266, 267, 268
 - of humerus 179
 - of radius 185, 186, 187
 - of tibia 255 *see also popliteal surface*
 - of ulna 193
 - proximal fibular articular 263
 - sacropelvic 227
 - superior
 - of clavicle 162
 - symphyseal
 - of pubis 233
 - Surficial defects 468
 - Surgical neck 176, 180
 - Survivorship curve 486
 - Sustentacular groove *see sustentacular sulcus*
 - Sustentacular sulcus 279
 - Sustentaculum tali 279
 - Sutural bone 46, 51, 56, 98, 590
 - apical bone 98
 - asterionic bone 98
 - bregmatic bone 98
 - coronal ossicle 98
 - environmental plasticity 479
 - epipteric bone 98
 - inca bone 51, 74, 98
 - lambdoid ossicle 98
 - occipitomastoid ossicle 98
 - parietal notch bone 98
 - sagittal ossicle 98
 - Suture 18, 32, 52, 580, 590
 - basilar 48, 50, 57, 72, 589
 - coronal 44, 45, 47-50, 52, 56, 58, 62, 63, 66, 580
 - frontolacrimal 58
 - frontomaxillary 44, 45, 58
 - frontonasal 44, 45, 52, 55
 - frontozygomatic 44, 45, 47, 58
 - intermaxillary 45, 77
 - internasal 45, 55, 85
 - lacrimomaxillary 58
 - lambdoid 44, 46, 47, 48, 49, 50, 56, 58, 74, 75, 91, 98, 585
 - median palatine 48, 57
 - intermaxillary portion 46, 48, 57
 - interpalatine portion 48
 - metopic 45, 52, 61, 63, 85, 97, 585
 - nasomaxillary 44, 47
 - occipitomastoid 44, 46, 48, 50, 53, 58, 73, 98
 - parietomastoid 44, 46, 53, 58, 68
 - premaxillary 77
 - sagittal 52, 56, 589
 - premature closure *see scaphocephaly*
 - sphenofrontal 44, 50
 - sphenosquamous 69, 70
 - sphenotemporal 44, 48, 50
 - squamous 44, 46, 66, 70
 - squamous 589
 - transverse palatine 48
 - zygomaticomaxillary 52
 - zygomaticotemporal 44, 47, 48, 71
 - Symphyseal surface
 - of pubis 233
 - Symphysis 30, 590
 - mandibular 93
 - pubic 226, 233
 - Syn- 20
 - Synchondrosis 30, 53, 57, 590
 - sphenooccipital 52, 74
 - Syndesmophyte 443
 - Syndesmosis 30, 53, 590
 - Syndesmotic ligaments 315
 - Synostosis 32, 590
 - Synovial fluid 29, 436
 - Synovial joint 29, 30, 32, 590
 - Syphilis 443, 444
- ## T
- Talar body 276
 - Talar extension *see trochlear extension*
 - Talar head 276, 277, 279, 281
 - Talar neck 276
 - Talar squatting facet 276, 284
 - Talar trochlea 276, 292
 - Talocrural joint 260, 276
 - Talofibular ligament

- anterior 314–315
 posterior 268, 314–315
 Talon(id) 106, 590
 Talus 272–277, 281
 Taphonomic alteration 459–473
 Taphonomy 459, 460, 548, 590
 abrasion 464
 bone modification
 chop marks 469
 cut marks 468, 469
 percussion marks
 pits 470, 471
 striae 470
 root etching 524
 carnivore marks 468
 fire 464
 of DNA 494
 pot polish 470
 websites 575
 Tarsal 22, 271, 590
 astragalus *see talus*
 calcaneus 272, 273, 276, 277–279, 280, 283, 294
 cuboid 272–277, 280–281, 282, 283, 289
 cuneiforms 276, 281
 intermediate 272–275, 281, 282
 lateral 272, 273, 282–283
 medial 272–275, 281
 navicular 274–276, 280–283
 talus 272–277, 281
 Taung 374
 Taurodontism 107, 590
 Teeth *see dentition*
 category
 bicuspid *see premolar*
 canine 103, 112, 115, 122–123
 cuspid *see canine*
 incisor 102, 103, 110, 114, 116–117, 121–122
 molar 102, 103, 106, 110, 112, 116, 119–120, 123–125
 premolar 103, 112, 115, 117–118, 123
 crowding 479
 cusps 106
 entoconid 105
 hypocone 105
 hypoconid 105
 hypoconulid 105
 metacone 105
 metaconid 105
 paracone 105
 protocone 105
 protoconid 105
 deciduous 103
 permanent 103, 111
 Temporal 22, 590
 Temporal bone 44, 45, 46, 47, 48, 50, 67–71
 Temporal fascia 60, 65, 67, 298–299
 Temporal fossa 85, 86, 90
 Temporalis muscle 60, 65, 67, 94, 99, 299
 Temporal line 58, 60, 61, 66
 inferior 64, 65
 superior 64, 65, 99
 Temporal lobe 51, 67
 Temporal process
 of zygomatic 58, 85, 86
 Temporal squama 67, 68, 70
 Temporomandibular articular surface 68, 69
 Temporomandibular joint 91, 94, 590
 Temporomandibular joint disease
 in Atapuerca fossils 538
 Tendon 28, 32, 34
 of iliopsoas 246
 of quadriceps femoris 252, 254
 Tensor veli palatini muscle 299
 Tentorium cerebelli 90
 Teres major muscle 170, 178, 303
 Teres minor muscle 177, 303
 Terminal branch of the greater palatine artery 77
 Terminal foot phalanx *see distal foot phalanx*
 Terminal hand phalanx *see distal hand phalanx*
 Terry Collection 382, 404, 420
 Third cuneiform *see lateral cuneiform*
 Third metacarpal *see MC 3*
 Third metatarsal *see MT 3*
 Third trochanter 246
 Thoracic 22, 590
 Thoracic vertebrae 139–142
 Thyroid cartilage 129
 Tibia 254–263
 Tibial biomechanical length 262
 Tibial bowing 263
 Tibialis anterior muscle 313
 Tibialis posterior muscle 268, 281, 313, 315
 Tibial plateau 254, 255
 Tibial shaft 255
 Tibial squatting facet 263
 Tibial tuberosity 255, 261
 Tibiofibular ligaments 260
 transverse tibiofibular ligament 268
 Timing, relative
 antemortem 354, 429, 433, 439, 459, 460, 468
 perimortem 354, 429, 435, 439, 460
 postnatal 39
 TMJ *see temporomandibular joint*
 Tooth buds 107
 Tooth categories
 bicuspid *see premolar*
 canine 103, 112, 115, 122–123
 cuspid *see canine*
 incisor 102, 103, 110, 114, 116–117, 121–122
 molar 102, 103, 106, 110, 112, 116, 119–120, 123–125
 premolar 103, 112, 115, 117–118, 123
 Tooth loss
 and alveolar resorption 528
 excessive
 affecting sex determination 414
 Tooth types *see tooth categories*
 Tooth wear 101, 389, 390, 454
 microwear 482
 -topic 20
 Toroidal 23
 Torus 17, 590
 mandibular 93, 98
 Total facial height 96
 Total facial index 97
 Trabeculae 32 *see cancellous bone*
 Trace element analysis 483
 Traction epiphysis *see apophysis*
 Trait, nonmetric 476
 Transverse foramen 132, 136, 146
 Transverse fracture 434
 Transverse humeral ligament 177, 303
 Transverse line
 of sacrum 220, 223
 Transverse palatine suture 48
 Transverse plane 590
 Transverse process 132, 133, 135, 143
 of cervical vertebrae 136
 of coccyx 225, 226
 of lumbar vertebrae 143
 of thoracic vertebra 139
 confusion with prox. rib frag. 156
 Transverse sinus 66, 70, 74
 Transverse sulcus 65, 73, 74
 Transverse tibiofibular ligament 268
 Transversus abdominis muscle 232, 309
 Trapezial groove 205
 Trapezial ridge 205
 Trapezium 200, 201, 202, 205, 209
 Trapezius muscle 162, 163, 170, 174, 299, 301
 Trapezoid 200–202, 206, 209
 Trapezoid ligament 162, 301
 Trapezoid line 162
 Trauma 433–439
 gunshot wound (GSW) 321
 Traumatic lesions
 on Atapuerca fossils 538
 Trephination 438, 590
 Treponemal infections 444
 Tri- 20
 Triangular subcutaneous area 264, 267, 268
 Tribes
 Afar 541–543, 545, 546, 552
 Arikara 363
 Chumash 362
 Fallon Paiute Shoshone 362, 519
 Sioux

- Dakota 363
- Lakota 363
- Nakota 363
- Tribosphenic pattern 106
- Triceps brachii muscle 170, 180, 191, 197, 303, 307
- Trigon(id) 106, 591
- Triquetral 200–202, 204
- tRNA 39
- Trochanter
 - definition 16, 591
 - greater 241, 243–246, 248, 250
 - lesser 243–246, 248, 250
 - third 246
- Trochanteric fossa 246
- Trochlea
 - of foot phalanx 291
 - of hand phalanx 215
 - of humerus 180, 181, 183, 184, 191
 - of talus 276, 292
- Trochlear 23, 591
- Trochlear extension 284
- Trochlear notch 192, 197
 - shape 197
- trophy 20
- “True” ribs 153
- “True” pelvis 237, *see lesser pelvis*
- Tuber
 - maxillary 77
 - parietal 64, 65
- Tubercle
 - adductor 247
 - anterior
 - of C-1 136
 - of transverse process 138
 - conoid 162, 163
 - cristal *see iliac tubercle*
 - definition 16, 591
 - distal phalangeal 292
 - dorsal (of radius) 186–189
 - fibular 279, 284
 - greater 176, 179, 184
 - iliac 227, 228, 231 *see tuberculum of iliac crest*
 - infraglenoid 166, 168, 170, 197
 - lateral intercondylar 255
 - lesser 176, 178, 180, 181
 - medial intercondylar 254
 - navicular 281
 - obturator
 - anterior 233
 - posterior 233
 - of rib 153, 155–157
 - posterior
 - of C-1 136
 - of transverse process 138
 - pubic 232
 - extension of 399
 - quadrate 243–246
 - scalene 156, 157
 - scaphoid 202, 203
 - supraglenoid 170, 172
 - tuberculum of iliac crest 227
- Tuberculosis 444
- Tuberculoventral arc 159
- Tuberculoventral chord 159
- Tuberculoventral subtense 159
- Tuberculum 106
- Tuberculum of iliac crest 227
- Tuberosity
 - calcaneal 277–279
 - cuboid 280
 - definition 16, 591
 - distal phalangeal 216
 - for serratus anterior muscle 157
 - gluteal 243, 246, 250, 252
 - iliac 227, 229, 230, 231
 - ischial 232, 233, 247
 - masseteric 93, 94
 - pronator 186
 - pterygoid 93, 95
 - radial 184–187, 189, 197
 - sacral 220, 222
 - tibial 255, 261
 - ulnar 192, 193
- Tumor
 - carcinoma 579
 - multiple myeloma 450, 452
 - osteochondroma 453
 - osteoma 452
 - sarcoma 589
- Tympanic cavity 71
- Tympanic dehiscence 98
- Tympanic membrane 67, 71
- Tympanic part (of temporal) 69
- Types of bone
 - coarsely bundled bone 35
 - compact 32, 579
 - histological types
 - immature
 - coarsely bundled bone 35
 - woven bone 35, 36, 40, 446
 - mature
 - lamellar bone 35, 36, 40, 405, 406, 585
 - lamellar bone 35, 36, 40, 405, 406, 585
 - woven bone 35, 36, 40, 446
- Typology 26, 591
- U
- Ulna 191–197
 - immature
 - confusion with rib head 156
- Ulnar 202
- Ulnar biomechanical length 197
- Ulnar collateral ligament 181, 195
- Ulnar fovea 195
- Ulnar head 191–195
- Ulnar minimum circumference 197
- Ulnar notch 186, 187, 189, 191, 195
- Ulnar physiological length 197
- Ulnar shaft 193
- Ulnar styloid process 195
- Ulnar tuberosity 192, 193
- Uncinate 23
- Uncinate process 132, 136
- Underdeveloped acetabulum 236
- Universiteit Leiden collection 382
- University Hospital 503
- Univ. of Iowa/Stanford collection 382
- Upper facial breadth 96
- Upper facial height 96
- Upper facial index 97
- U.S. Army 359
- U.S. Army Corps of Engineers 363
- U.S. Fish and Wildlife Service 519
- V
- Vaginal process 69, 70, 71
- Vandals 372
- Variables
 - continuous 342
 - discontinuous 342
 - discrete 581
- Variation 25–27
 - in dental timing 387
 - geographic 26
 - idiosyncratic 26, 27, 30, 384, 385, 391, 395, 396, 429
 - nonmetric 476–480
 - ontogenetic 26, 27
 - populational 412
 - in tibiae 416
 - sex-linked 26, 27, 386, 409–413, 419, 494, 501
 - in Young’s modulus 296
- Vascular 22, 591
- Vascular disruption 437
- Vastus fossa 254
- Vastus muscles 246
 - vastus intermedius 311
 - vastus lateralis 247, 311
 - vastus medialis 246, 311
- Vastus notch 254
- Vault 23, 591
- Veinous sinus
 - sagittal 74
 - transverse 66, 70
- Vein
 - basivertebral 132
 - emissary 73
 - greater palatine 77, 78
 - intercostal 153
 - internal jugular 70
 - mylohyoid 95
 - nasopalatine 80
 - obturator 233

- subclavian 156
- supraorbital 61
- Ventral 13, 591
- Ventral rampart 233
- Ventral rim *see obturator crest*
- Vertebra
 - cervical 136–139
 - atlas 71, 73, 136
 - axis 136
 - lumbar 143–145
 - sacralized 225
 - sacral 219, 221–223 *see also sacrum*
 - thoracic 139–142
- Vertebral arch 132
- Vertebral body 131–134, 136, 139, 142, 143
- Vertebral border *see medial border*
- Vertebral canal 71
- Vertebral canal index 146
- Vertebral foramen 131, 132, 136, 139
 - lumbar 143
- Vertebral malformations 439–440
- Vertex (v.) 56
- Vertical head diameter 184
- Vertical line (of tibia) 255
- Veterans Administration Hospital
 - 516–520
- Vinac™ 332
- Volar 14, 591
- Volarflexion 16 *see also plantarflexion*
- Volkman's canals 37
- Vomer 48, 57, 78, 79–80, 82, 83

W

- Walker, Phillip 374, 507–511
- Washing of remains 326–328, 332, 333
- Wear, teeth 101, 389, 390
 - dental macrowear 454
 - dental microwear 482
- White blood cell disorders 450
- Winging 481
- W. Montague Cobb collection 382
- Wolff, Julius 28
- Wolff's Law 28
- Wormian bone 591 *see sutural bone*
- Wound *see trauma*
- Woven bone 35, 36, 40, 446
- Wrist 184, 185, 195, 197

X

- Xiphoid process 151, 159
- X-rays 349, 574, 588

Y

- Y-5 pattern 106
- Yaws 444
- Yellow marrow 32
- Young adult 384, 591

Z

- Zhoukoudian 521
- Zooarchaeology 466 *see also faunal analysis*
- Zygion (zy.) 58
- Zygo- 20
- Zygomatic arch 43, 45, 47, 48, 51, 58, 86, 90, 99
- Zygomatic bone 44, 45, 47, 48, 85–86
- Zygomaticofacial foramen 85, 86
- Zygomaticofacial nerve 86
- Zygomaticofrontal suture 44, 45, 47, 58
- Zygomaticomaxillary suture 44, 45, 48, 52, 58
- Zygomaticoorbital foramen 85, 86
- Zygomaticotemporal foramen 85, 86
- Zygomaticotemporal nerve 86
- Zygomaticotemporal suture 44, 47, 48, 71
- Zygomatic process
 - of frontal 60–62
 - of maxilla 75, 76
 - of temporal 58, 67–71, 86
 - confusion with zygomatic 86
- Zygomaticus major muscle 299
- Zygomaticus minor muscle 299
- Zygomaxillare (zm.) 58
- Zygoorbitale (zyo.) 58