

A practical approach to acute vertigo

Barry M Seemungal, Adolfo M Bronstein

Patients complaining of symptoms of acute vertigo present a diagnostic challenge for the clinician; the main differential diagnoses are acute unilateral peripheral vestibulopathy ("vestibular neuritis"), cerebellar stroke or migraine. The head impulse test is useful in the acute situation because, of these three diagnostic alternatives, it will only be positive in patients with vestibular neuritis. A history of acute vertigo and hearing loss suggests Ménière's disease but the clinician must be wary of anterior inferior cerebellar artery strokes which may cause audiovestibular loss due to peripheral vestibulocochlear ischaemia, although the accompanying brainstem signs should remove diagnostic ambiguity. We also discuss other less common vertigo diagnoses that may be referred to the neurologist from the acute general hospital take. As ever in neurology, a careful history and focussed examination is necessary in the evaluation and management of acute vertigo.

Dizziness is a common acute complaint; one Italian study reported a population-based incidence of 3.6 cases per 100 000 person-years presenting to the emergency department.¹ The exact frequency of specific vertigo diagnoses remains unclear however, partly because emergency and general internal physicians are not very good at neurological diagnosis (one prospective study found that a

neurological review resulted in a "complete change of diagnosis" in 53% of acute admissions with neurological symptoms).²

In practice, making a diagnosis is most problematic when faced with vertigo *without* additional focal neurological symptoms. We will therefore discuss first the clinical approach for patients presenting with acute isolated vertigo, and then second with acute vertigo and deafness.

B M Seemungal

Clinician Scientist and Consultant Neurologist

A M Bronstein

Professor of Neuro-otology and Consultant Neurologist

Neuro-otology Unit, Department of Clinical Neuroscience, Imperial College London, Charing Cross Hospital, London, UK

Correspondence to:

Dr B M Seemungal
Neuro-otology Unit, Department of Clinical Neuroscience, Imperial College London, Charing Cross Hospital, London W6 8RF, UK;
b.seemungal@imperial.ac.uk

Box 1 History taking tips in acute dizziness

- Make sure that both you and the patients are speaking the same language. Do they mean dizziness in the sense that you mean dizziness? Perhaps describe the sensation that you understand to mean dizziness to the patients, and ask if that is the symptom they have. Beware that oscillopsia is sometimes confused with dizziness (although dizziness and oscillopsia may occur together); dizziness can be present in the blind or in the dark, whereas oscillopsia can only occur when the patient can see.
- Avoid labels: obtain a description of the "dizziness" symptoms in the patient's own words.
 - Rotatory: horizontal "merry-go-round" (synonymous with vertigo) or vertical plane "head over heels"
 - Rocking: "like being on the deck of a boat"
 - Linear: horizontal or vertical plane (including falling).
- What exactly is the duration of any attack?
 - Subjective recall of time can be highly inaccurate, particularly at the lower end of the scale (seconds to minutes). Patients with benign positional paroxysmal vertigo (BPPV) may say that their dizziness lasted "just a couple of minutes". Count out aloud and ask patients to say "stop" when the recalled duration of intense spinning dizziness has abated. Time and again patients who describe their dizziness as lasting minutes will say "stop" after a few seconds!
 - Continuous or prolonged symptoms: after an episode of BPPV it is common for patients to feel destabilised for minutes, hours or even an entire day. If the clinician is not careful they may then obtain a history of prolonged dizziness and so be diverted from the correct diagnosis. Any prolonged symptoms will not be violent spinning vertigo but something more non-specific. Hence it cannot be over-emphasised that the clinician must get an accurate description of the patient's prolonged "dizzy" symptoms—"what does it feel like?" (for example, spinning, rocking, etc) to avoid confusing continuous "dizziness" with that of the acute vertiginous attack.

CLINICAL APPROACH TO THE PATIENT WITH ACUTE VERTIGO

In a patient presenting with acute vertigo, the main questions are:

- where is the lesion, central or peripheral?
- does this patient require immediate neuroimaging?

History taking

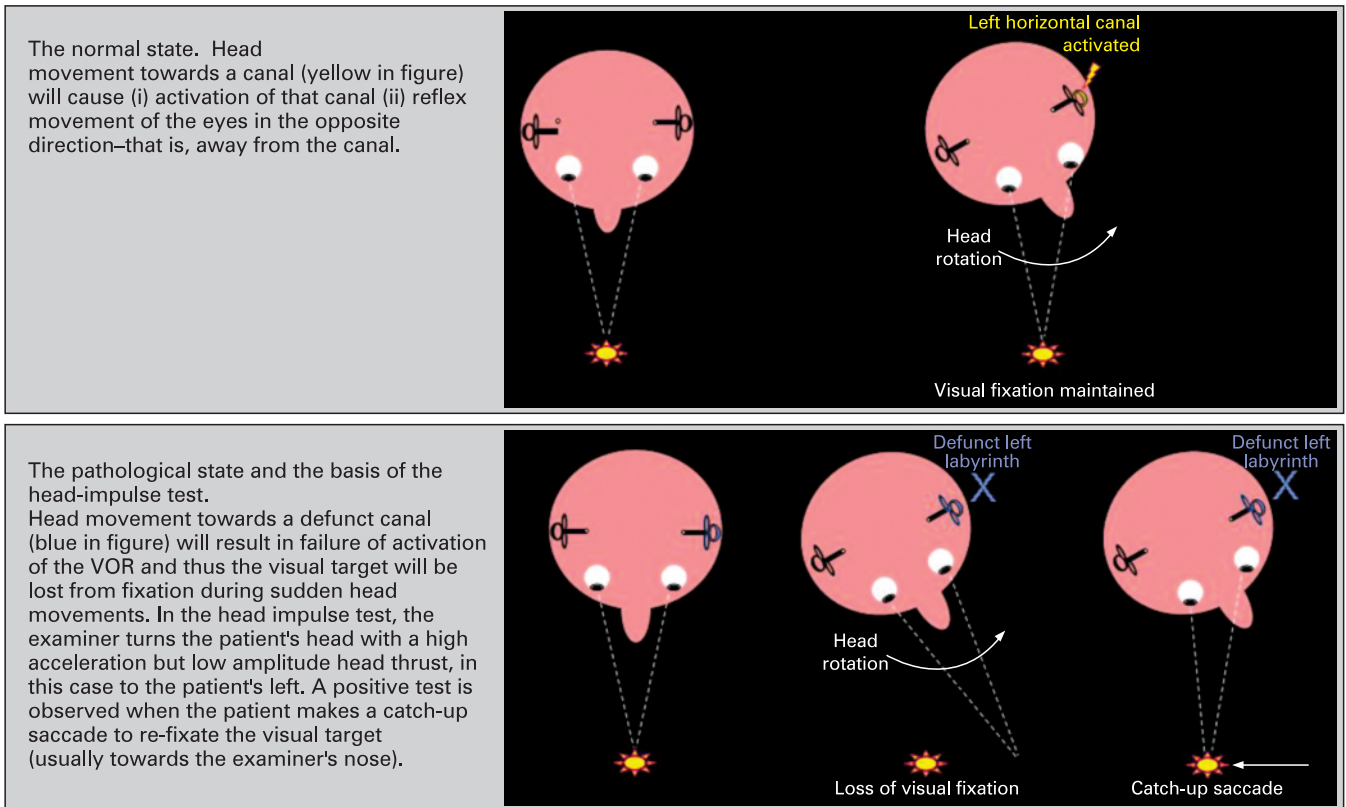
Patients use the term "dizziness" to describe a variety of subjective experiences and so very careful clarification is needed to avoid diagnostic mistakes (box 1). Rotational dizziness (vertigo) implies disturbance of the semicircular canals or their central pathways, particularly in the acute phase. In the improving, post-acute phase, many patients with vestibular disorders report other forms of dizziness, using words such as "giddiness"

or "light headedness", but beware because patients with general medical conditions (anaemia, hypoglycaemia), haemodynamic (orthostatic hypotension, pre-syncope) or psychological problems also use these very same words. Furthermore, sensory-motor disorders of the lower limbs (parkinsonism, gait ataxia, spinal cord syndromes) come into the differential diagnosis when patients describe their symptoms as imbalance or unsteadiness. It can be useful to ask patients if the problem is "in their legs or in their head" and whether the sensations are as if they are "about to faint" (pre-syncope) as opposed to "being on a merry-go-round" or "on a boat" (vestibular).

Physical examination

In deciding "is it peripheral or central?", a simple understanding of basic vestibular physiology (figs 1 and 2) is helpful in explaining many of the important clinical findings (table).

- *Unidirectional nystagmus*: in acute peripheral vestibular loss, the nystagmus is unidirectional (that is, the *direction* of the nystagmus is unaffected by changes in the direction of gaze) with the *slow* phase in the direction of the defunct labyrinth (that is, fast phase beating to the contralateral side). The nystagmus will be most visible when looking in the direction of the fast phase, less so in the midline, and least in the opposite direction (that is, the *intensity* but not direction of "vestibular" nystagmus is affected by gaze direction). Note that unidirectional nystagmus confirms that the nystagmus is "vestibular" in origin and while typical for a peripheral lesion, this can also be seen in central vestibular lesions involving the brainstem (where additional signs make localisation relatively easy).
- *Vestibular-ocular reflex (VOR) testing*: the VOR is impaired in peripheral vestibular loss. This is demonstrable when the head (face) is moved in the direction of the damaged labyrinth (or vestibular nerve). The head-impulse (or head-thrust) test is the method of choice in clinically assessing the integrity of the VOR in the acute phase (fig 3). A video demonstrating the head impulse test can be found on the weblink at the end of this article (more



extensive video tutorials on “how to do it” as well as normal and abnormal examples can be found in Bronstein and Lempert).³

- *Suppression of nystagmus:* a key sign of “peripheral” vestibular dysfunction is the suppression of unidirectional vestibular nystagmus when visual fixation is allowed. Conversely, without visual fixation, as in the dark, the nystagmus intensity is increased (that is, faster

slow-phase velocity). The ability to suppress spontaneous nystagmus in the light suggests intact central (mainly cerebellar) mechanisms. Frenzel’s glasses, an ophthalmoscope, or even observing the nystagmus beating behind closed eyelids can be used to examine the effect of loss of visual fixation on nystagmus intensity. If using an ophthalmoscope to detect nystagmus, it must be remembered that the observed direction of retinal movement (posterior aspect of the globe) is

Figure 1 Vestibulo-ocular reflex (VOR) physiology made simple.

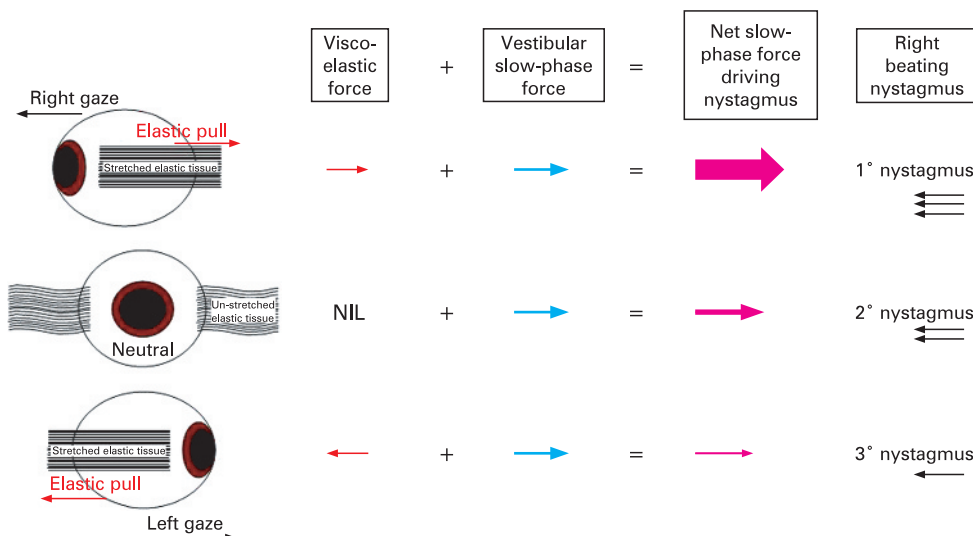


Figure 2 Unidirectional vestibular nystagmus: 1°, 2° and 3° nystagmus. Consider a left beating vestibular lesion where eye tends to drift leftward due to left hypofunction (viz. relative right overactivity). The leftward slow-phase vestibular bias (blue arrow) when added to visco-elastic forces (red arrow) will produce a net slow-phase force (pink arrow) pulling on the eye. In this way we can see clearly why in this case, looking towards the right will elicit the greatest net (leftward) slow-phase force and hence right gaze is the eye position that will most easily generate a right beating nystagmus; viz first-degree (1°) right-beating nystagmus. Nystagmus occurring in the neutral (2° nystagmus) and left gaze (3° nystagmus) are progressively less likely to occur.

TABLE Clinical signs in acute vertigo: peripheral or central?

Sign	Feature	Peripheral	Central
Vestibular ocular reflex	Head impulse test	Impaired	Intact
Spontaneous nystagmus	Nystagmus direction	*Mixed horizontal/torsional	†Pure horizontal ‡Pure vertical
§Spontaneous nystagmus	Suppression of nystagmus with visual fixation	Yes	No
§Smooth pursuit	Is pursuit "smooth" or "broken"?	Pursuit is intact. Can be difficult to assess with vigorous spontaneous nystagmus	Pursuit is broken in ipsilesional direction
Positional nystagmus		Latency Adaptability Fatiguability	No latency No adaptation No fatiguability

*Mixed horizontal/torsional—typical for vestibular neuritis nystagmus but can occur with central lesion.

†Pure horizontal—usually central but could occur with a lesion isolated to a single horizontal canal (or connections).

‡Pure vertical—usually central but could occur with bilateral, simultaneous lesions affection either both anterior canals or both posterior canals (or their connections).

§Suppression of vestibular nystagmus requires intact smooth pursuit mechanisms.

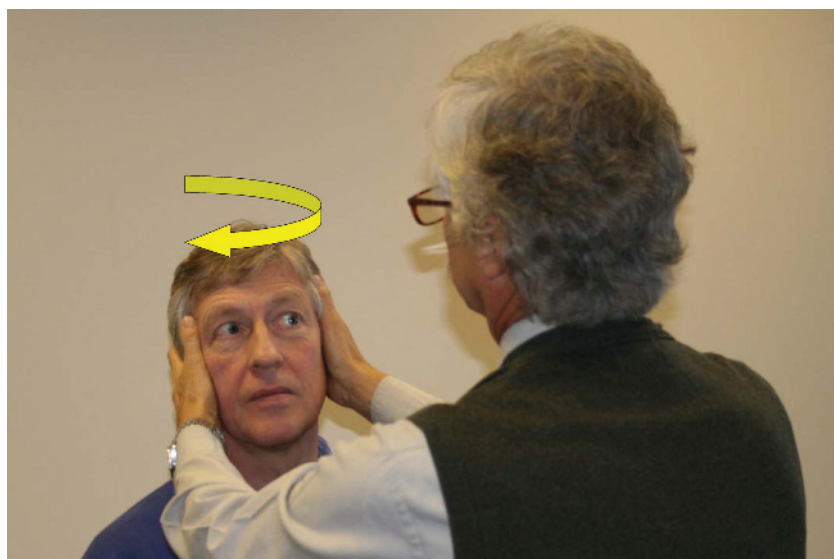

Figure 3 The head impulse or head thrust test. The examiner holds the patient's head and asks him to fixate on her nose. The examiner then delivers a discrete, low amplitude (15–20°), but very fast, head thrust to one side. If the patient's vestibular-ocular reflex (VOR) is intact then, when the head is rotated, the eyes will remain fixated on the examiner's nose. If the VOR is unilaterally impaired then, when the head is rotated the patient's eyes will momentarily lose their fixation on the examiner's nose. The examiner should look for one or more catch up saccades directed back towards the initial fixation point—that is, his nose. The figure shows a left head thrust probing the left horizontal semicircular canal function. Several trials in each direction, right and left, should be carried out in a pseudorandom order.

opposite to that of the observed movement of the sclera (anterior aspect of the globe).

- *Neurological examination:* any clearcut central neurological signs in the presence of a neuro-otological syndrome make lesion localisation relatively easy, particularly when there is brainstem involvement. Isolated cerebellar strokes, however, may mimic a peripheral vestibular syndrome (see below).
- *General examination:* a focussed general examination is also important. For example, if the history and signs suggest a peripheral neuro-otological syndrome, examination of the external auditory meatus is mandatory to look for local pathology such as cholesteatoma, eardrum perforation, discharge, the vesicles of Ramsay-Hunt syndrome, etc. If stroke is considered, a careful cardiovascular examination is required (for example, for atrial fibrillation).

ACUTE ISOLATED VERTIGO

Acute isolated vertigo is usually benign, and indeed a clinician following this rule of thumb will be right most of the time on pure probability grounds. Making a specific diagnosis is important however, as stroke can present with isolated vertigo, and also identifying benign conditions will reassure the patient and ensure expedient management. For example, benign positional paroxysmal vertigo (BPPV) should always be considered, even when acute vertigo apparently persists, because the patient's account of their symptoms may mislead (box 1). It is an important diagnosis both because it is common, and also its identification allows immediate treatment and discharge.^{4, 5}

The important causes of acute isolated vertigo lasting at least several hours that neurologists should be aware of are:

- acute idiopathic unilateral peripheral vestibulopathy ("vestibular neuritis or neuronitis", "labyrinthitis")
- cerebellar stroke
- migrainous vertigo
- "missed" BPPV
- bilateral vestibular failure.

Acute idiopathic unilateral peripheral vestibulopathy

This is the commonest cause of vertigo lasting more than 24 hours during which there are symptoms and signs of unilateral vestibular hypofunction. The syndrome is synonymous with "vestibular neuritis" or "labyrinthitis" (a viral aetiology has been suggested).⁶ Although itself not life threatening, distinguishing vestibular neuritis from stroke for example, is essential not only to avoid missing a serious diagnosis, but also to avoid over-investigation and inappropriate lifelong treatment for secondary stroke prevention.

Typically, patients have a subacute onset over hours, of spinning vertigo. Occasionally the onset is over several minutes but rarely less (when a stroke must be considered). The sensation of vertigo is intense and is almost always associated with nausea and vomiting. Patients see the visual world spinning around them, mainly in a horizontal direction. This visual perception is produced by the slow phase component of the nystagmus (because vision is suppressed during quick-phase eye movements), thus a rightward slow-phase eye movement generates the illusion of leftward visual world movement. The sense of self-movement is present with the eyes closed and is made worse by any head movement and reduced, but rarely fully suppressed, by keeping the head absolutely still. The examination findings have been covered above. Note that, in general, the nystagmus of an acute "vestibular neuritis" settles over several days, *not* due to recovery of function in the affected ear (although this often does recover over weeks to months), but rather to brainstem plasticity (see Gliddon *et al* for review of vestibular plasticity⁷).

Differential diagnoses of an acute unilateral peripheral vestibulopathy

Cerebellar stroke can usually be differentiated by its hyperacute onset—that is, within seconds—although the pace of onset is not always available (for example, if symptoms are present on waking). The head impulse test remains intact (normal) in cerebellar stroke. Occasionally, if the brainstem is not also involved, it can be difficult to distinguish stroke from a peripheral vestibulopathy; where there is any doubt acute neuroimaging is indicated

(we discuss indications for neuroimaging in the next section). In practice, patients with cerebellar infarcts presenting like a vestibular neuritis will typically have a large cerebellar hemispheric stroke and will usually not present to hospital sooner than 24 hours into their history (because they are often treated as an "ear problem" initially); in such cases CT often demonstrates the infarct (or haematoma). Of course, CT negative cases where there is still a suspicion of stroke require MRI.

Migrainous vertigo—this diagnosis is supported by a past history of migraine headache with vertigo. As patients with acute vestibular migraine may have nystagmus with central features,⁸ in an acute first presentation, urgent brain imaging may be required (see below sections on cerebellar stroke and migraine).

Investigation of acute idiopathic unilateral peripheral vestibulopathy

A caloric test is the most useful specialist examination in a patient presenting with what appears to be an acute peripheral vestibulopathy. A recent study found that the bedside iced-water caloric test compared favourably to standard warm water or warm air calorics.⁹ In this study, the authors were able to lower tap water temperature to 4°C by adding ice cubes for about 10 minutes. 2 ml of iced water is injected with a syringe into the external auditory meatus (with prior otoscopy to exclude occlusion by wax, or other local pathology). In a peripheral lesion, iced water on the damaged side either does not cause nystagmus, or has no effect on any spontaneous nystagmus in primary gaze. Electronystagmography does not add greatly to what can be gleaned from a careful clinical examination and caloric testing.

Direct visualisation of an affected vestibular nerve in "vestibular neuritis" has been reported in a single small series with gadolinium enhanced 3T MRI,¹⁰ but imaging in this condition is more of academic interest than of practical utility. Acute neuroimaging is required, however, if a central cause is suspected (for example, cerebellar stroke).

Treatment of acute idiopathic unilateral peripheral vestibulopathy

Recent data have suggested that early intervention with corticosteroids may improve

Box 2 Oculomotor and imaging findings in a patient with acute onset vertigo, nausea vomiting and headache

A 52-year-old man presented 24 hours after the onset of vertigo which came on as he bent down in the shower. The vertigo, which persisted, was severe and accompanied by nausea, vomiting and occipital headache. All symptoms increased with minimal head movement. There was no past history of headache. Clinical examination in the light showed no nystagmus, with normal saccades and smooth pursuit. There was minimal 1° nystagmus on right gaze without visual fixation. There was no on-the-couch limb ataxia and there was too much vertigo and sickness to test gait. Importantly, the head impulse test was normal, although this test provoked vomiting. Acute brain CT (and subsequent MRI) revealed a cerebellar infarct. This patient represents one of the atypical cases who do not have florid cerebellar signs even though they have had a cerebellar stroke. Importantly, the intact head impulse test, despite the disabling vertigo, meant that a peripheral vestibular cause (for example, vestibular neuritis) was an untenable diagnosis. Thus the differential diagnosis lay between migrainous vertigo and a cerebellar stroke. Furthermore, the *new* onset headache in a patient without previous migraine allied to the hyperacute onset vertigo meant that brain imaging was mandatory. Ischaemic strokes involving the cerebellar hemisphere are typically embolic and here the history of a Valsalva manoeuvre (bending down) at vertigo onset was suggestive of paradoxical embolism. A patent foramen ovale with significant right-to-left shunting on Valsalva was demonstrated in this patient who chose to have this closed.

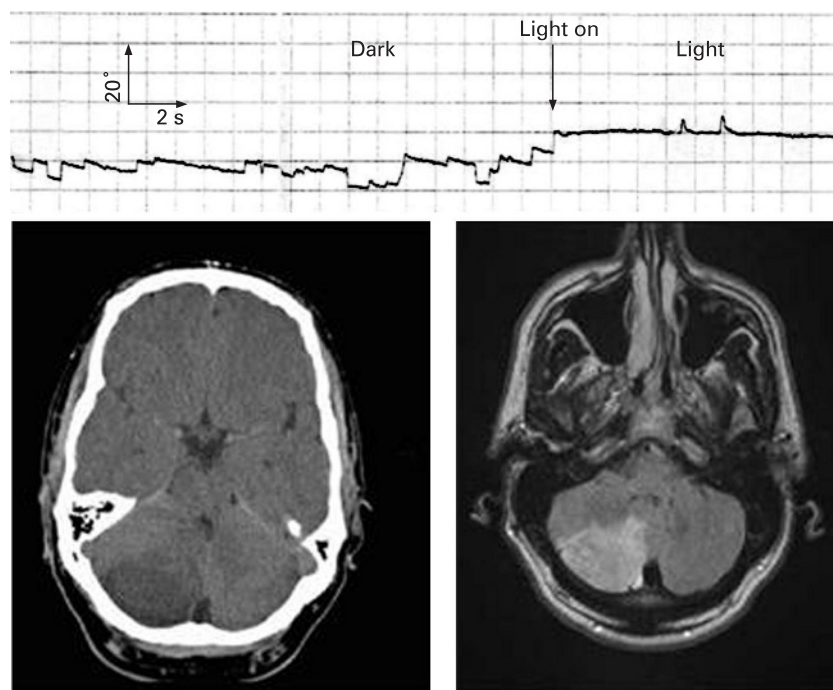


Figure 4 The electronystagmograph of a patient (see clinical vignette in box 2) with a right cerebellar stroke is shown (top) demonstrating a right beating nystagmus (upwards = rightwards on trace) on right gaze (30° from midline) in the dark. Interestingly, this patient was able to suppress his nystagmus in the light (see "light on"). Below shows the initial CT brain and the subsequent MR flair image.

long-term outcome in terms of vestibular function tested by bithermal calorics,^{11, 12} but the key measure of symptomatic outcome (which relates in part to brainstem compensation following a unilateral vestibulopathy) has not been assessed. The utility of steroids in vestibular neuritis therefore remains unclear.

Cerebellar stroke

Vertigo is the commonest symptom in cerebellar stroke.¹³ Moreover, patients with cerebellar hemispheric strokes not also involving the brainstem may complain of vertigo without any other symptoms¹⁴⁻¹⁹ and also, rarely, there may be no nystagmus or on-the-couch ataxia of the limbs.^{17, 18} Red flags include hyperacute onset vertigo, occipital headache²⁰ or profound gait ataxia.

The clinical approach and neuro-otological examination have been discussed above. A key point to note is that the head impulse test is intact in cerebellar strokes. As there is considerable divergence and pathway redundancy of primary vestibular afferents, theoretically only catastrophic strokes involving the brainstem vestibular nuclei would be sufficient to obliterate the head impulse test, but then the "central versus peripheral" question would be clear-cut on the basis of other symptoms and signs. But note that peripheral combined audiovestibular loss (with an abnormal head impulse test) can occur with vertebrobasilar ischaemia (see "acute vertigo with deafness" below).

A recent reported case illustrates the utility of assessing the VOR (in this case with caloric testing) in what initially appeared to be vestibular neuritis (although the head impulse test was not performed).¹⁹ The normal caloric test alerted the authors to the non-peripheral nature of the case which turned out to be a cerebellar stroke due to vertebral artery dissection. In box 2 and fig 4 we describe a patient with vertigo in whom a negative head impulse test lead us to perform acute brain imaging.

Immediate brain imaging is indicated in suspected cerebellar stroke. Although CT will diagnose some ischaemic strokes and virtually all cerebellar haemorrhages, MRI is more sensitive, particularly with diffusion weighting.²¹ Our criteria for neuro-imaging in acute vertigo are vertigo plus one or more of the following:

- new onset (occipital) headache
- any central neurological symptoms or signs
- acute deafness
- intact head impulse test.

Migrainous vertigo

Migrainous vertigo, although not recognised in the International Headache Society schema, is a commonly diagnosed entity among neuro-otologists. Indeed, in a typical tertiary referral neuro-otology clinic, migrainous vertigo is the commonest new diagnosis. This diagnosis requires clinical suspicion and is one of exclusion; Neuhauser *et al*²² have suggested diagnostic criteria (box 3).

Patients with this syndrome may have dizziness lasting minutes, hours or even more than a day,^{22, 23} and their dizziness ranges from a gentle "rocking-in-a-boat" to a terrifying "merry-go-round" spinning sensation. The diagnosis is easy when patients have concurrent migraine headache with their vestibular symptoms, not surprisingly these cases are less commonly seen in the specialist neuro-otology clinic. The typical patient we see is a migraineur who has noticed a recent increase in headache frequency and, over the same period, developed vestibular episodes, but with headache and vertigo not occurring together. Some patients may have non-headache migrainous symptoms (for example, photophobia) with vertigo or they may have only isolated vertigo. This diagnosis is not widely recognised outside of neuro-otological practice, hence patients are often untreated for years.

Migrainous vertigo is a diagnosis of exclusion and because some patients may have symptoms and signs (including nystagmus)⁸ suggestive of central dysfunction, then acute neuroimaging may be required on first presentation. von Brevern *et al* characterised the oculomotor features of migrainous vertigo within 12 hours of symptom onset.⁸ Of 20 patients assessed, 14 had nystagmus during the attack. Of these patients, 10 had central nystagmus, 3 had peripheral origin nystagmus, and the others remained indeterminate. Importantly, interictal testing in these patients should reveal no (or minor) oculomotor or vestibular abnormality.⁸ These findings⁸ are important both for our understanding of migrainous vertigo from a

Box 3 Neuhauser criteria for migrainous vertigo

Definite

- (1) Episodic vestibular symptoms of at least moderate severity
 - vertigo; positional dizziness and head motion intolerance
- (2) Migraine according to International Headache Criteria
- (3) One or more of the following features during at least two vertigo attacks
 - migrainous headache
 - headache
 - photophobia
 - phonophobia
 - migraine aura
- (4) Other diagnoses excluded by appropriate tests

Probable

- Criterion 1 and 4 as above plus at least ONE of the following:
 - migrainous headache
 - migraine symptoms during vertigo
 - migraine-specific triggers of vertigo (for example, specific food, etc)
 - response to antimigraine drugs

pathophysiological viewpoint, and for the clinician:

- First, that migrainous vertigo is associated with diverse forms of oculomotor dysfunction suggests it may not be a single syndrome with a single underlying pathophysiological process.
- Second, acute migrainous vertigo, particularly on first presentation, may be a diagnostic challenge for the clinician and in this setting other diagnoses (for example, cerebellar or brainstem stroke) may require exclusion with appropriate investigation.

A further problem with the diagnosis of migrainous vertigo is the assumption that migraine always causes vestibular symptoms when these symptoms co-occur. Thus one interpretation of the finding of Radtke *et al*⁴ that 50% of Ménière's patients have migrainous features during acute vertiginous episodes, is that Ménière's disease and migraine share a common pathophysiology. Another possibility is that vestibular activation per se—for example, as during motion sickness—may act as a migraine trigger.²⁵ This is supported by the observation that caloric stimulation may trigger a classical migraine attack in some migraineurs.²⁶

Although there have been no adequate randomised trials of treatment of migrainous

vertigo²⁷⁻²⁹ in the clinic setting, most neuro-otologists use standard antimigraine prophylactic drugs (for example, propranolol, pizotifen and amitriptyline) with reasonable success.

Missed BPPV diagnosis

Patients with acutely symptomatic BPPV continue to be admitted to hospital as emergencies because the spontaneous history provided by the patient may be atypical (often in terms of vertigo duration) and/or the attending physician has failed to perform a Hallpike test. BPPV is the commonest cause of acute vertigo and has such a typical history (that is, position-induced vertigo lasting seconds, typically on lying down and turning over in bed) and findings (torsional nystagmus beating towards the lower ear during the Hallpike manoeuvre) that there is usually little difficulty in making the diagnosis. A recent review⁷ re-emphasises the usefulness of conventional repositioning treatment for this condition.

Bilateral vestibular failure

By far the commonest cause of in-hospital bilateral vestibular failure is aminoglycoside toxicity.^{30, 31} It is generally not appreciated that aminoglycosides have differential effects on vestibular versus cochlear function. Thus gentamicin and streptomycin are primarily vestibulotoxic while amikacin and neomycin are predominantly cochleotoxic. Hence in patients with gentamicin associated vestibular loss, the majority will not be deaf. Indeed, ablation of vestibular function by injection of intra-tympanic gentamicin (in some patients with refractory Ménière's disease) is titrated so that hearing is preserved.

The typical patient³² with aminoglycoside vestibulotoxicity will have been in critical care, often with renal failure. About one in five patients develop episodic vertigo³² lasting several minutes to hours for a few days—which is counterintuitive because one would expect vestibular loss to occur equally on the right and left sides (the vertigo implies a right-left vestibular imbalance). Whatever their origin, the vertiginous episodes wane after a few days as the vestibular function is ablated. The patient's attempts to mobilise and rehabilitate, however, are severely

compromised by poor balance as well as severe oscillopsia on head movement, and this is sometimes compounded by the administration of a long-term vestibular sedative (for example, stemetil). The poor gait often leads to patients being labelled as having had a cerebellar stroke. The diagnosis of vestibulotoxicity must be considered in critically ill patients with "dizziness" and is easily made with the head-impulse test clinically, and confirmed by caloric testing.

Bilateral vestibular failure, which is almost always permanent, can have devastating consequences for the patient's mobility and independence. Functional recovery, which is never complete, is slow (over years). Graded physical activity is important in aiding the recovery of gait and balance. Chronic drug therapy (apart from treating any concurrent migraine) has no role in the rehabilitation of patients with bilateral vestibular failure.

ACUTE VERTIGO WITH DEAFNESS Ménière's disease

Ménière's disease is the commonest cause of acute vertigo with deafness.³³ The diagnostic gold standard is temporal bone histopathology (that is, at postmortem), but day-to-day clinical diagnosis relies on a constellation of symptoms, signs and confirmatory testing.³³⁻³⁵ Typically attacks start with a feeling of fullness in one ear, leading to progressive tinnitus, ipsilateral fluctuating loss and severe vertigo. Examination during an attack shows a peripheral vestibular nystagmus with the head impulse test lateralising the vestibular hypofunction to the symptomatic ear. Over time, there is progressive unilateral audiovestibular loss and as this happens, the severity of the acute attack peters out. Rarely, patients with Ménière's disease may develop very sudden drop attacks without other acute symptoms of Ménière's disease at the same time. In such cases a history of previous typical Ménière's attacks allows the clinician to make the diagnosis.

Vertebrobasilar ischaemia

The advent of neuroimaging, particularly MRI, has allowed an appreciation that sudden hearing loss can occasionally occur in brainstem strokes.³⁶⁻⁴⁴ As this hearing loss is almost always accompanied by vertigo, a

purely peripheral syndrome may be initially considered but the associated brainstem signs in almost every case would suggest central involvement.⁴⁰ In fact, the hearing loss that occurs in brainstem stroke is usually *peripheral* being due to occlusion of the internal auditory artery (IAA) which supplies the membranous labyrinth. This is a branch of the anterior inferior cerebellar artery (AICA) which also supplies the dorsolateral pontomedullary junction and middle cerebellar peduncle. Rarely the IAA is supplied by the medial branch of the posterior inferior cerebellar artery (PICA). Occasionally the hearing loss can be due to a central lesion affecting crossing auditory pathways (lateral lemniscus) of the contralateral dorsolateral upper pons.⁴¹ Additionally, bilateral hearing loss has been reported with vertebrobasilar ischaemia.^{36, 40}

Audiovestibular testing adds little to the diagnosis but may help with prognosis because hearing recovery is less likely with an initial severe hearing loss.⁴⁰ Cochlear dysfunction predominates over retrocochlear loss^{40, 42} but it is unclear if the site of the lesion affects the prognosis for hearing recovery. Overall, however, the prognosis is good with 80% of patients having some degree of hearing recovery in the long term.⁴⁰

A clinically isolated audiovestibular syndrome *without* overt additional neurological signs in the face of MRI evidence of brainstem infarction is rare, accounting for less than 0.35% of vertebrobasilar strokes.⁴⁰ In such cases the area of brainstem infarction is very small, thus explaining the paucity of central signs^{40, 45} (with any prominent audiovestibular symptoms most likely related to "peripheral" ischaemia). Perhaps more common, but still under-recognised because it is so non-specific, is the occurrence of brief (minutes), isolated audiovestibular episodes (mainly vertigo) before a vertebrobasilar stroke.^{40, 45} Grad and Baloh⁴⁵ noted that 60% of patients with brainstem strokes had experienced brief (minutes) isolated vertiginous episodes, presumably representing transient ischaemia either of peripheral or central vestibular structures. It is not known, however, what proportion of all patients with a transient peripheral vestibulopathy subsequently develop a vertebrobasilar stroke (the

PRACTICE POINTS

- Despite the frequency of vertigo as a presenting symptom, many clinicians find the diagnostic approach challenging.
- The first step is an accurate history while being aware of patients' use of ambiguous language to describe their "dizziness".
- If there is any suspicion of benign paroxysmal positional vertigo, or if the diagnosis is unclear, then a Hallpike test should be performed.
- In patients complaining of persisting isolated vertigo, the main differential is between a cerebellar stroke and "vestibular neuritis"—the clinician must therefore first decide whether the lesion is central or peripheral, and the head impulse test is useful in this regard.
- In patients with acute persisting vertigo and headache in whom the head impulse test is normal (that is, a peripheral cause is excluded), the differential diagnosis is between a cerebellar stroke or acute migrainous vertigo and here neuroimaging is mandatory (unless the patient is a previously-investigated migraineur presenting with a typical attack for that patient).
- Ménière's disease, one cause of acute unilateral audiovestibular loss, has such a typical history that diagnosis is straightforward (and is rarely referred to a neurologist).
- A brainstem stroke should be considered in patients with acute audiovestibular loss who do not have typical Ménière's symptoms.

large prospective cohort study to answer this has never been done).

Acoustic neuroma

Acoustic neuromas typically present with gradually progressive unilateral hearing loss and tinnitus. Although reported,⁴⁶ vertigo is rare in uncomplicated acoustic neuroma because the insidious onset allows brainstem mechanisms to almost fully compensate for the progressive peripheral (vestibular) deficit. Many authors have assumed that acute vertigo in acoustic neuroma (which although rare does occur) results from cystic expansion of the tumour, but a large retrospective series⁴⁶ found no difference in the frequency of acute vertiginous episodes between cystic and non-cystic tumours. Rarely, intratumoural haemorrhage into an acoustic neuroma with vertigo has been reported.^{47, 48}

Labyrinthine haemorrhage

Labyrinthine haemorrhage is a rare but increasingly documented cause of acute vertigo and deafness. In 1926, Voss reported a series of infants with perinatal distress and consequent hearing loss and dysequilibrium and in whom postmortem showed endolymphatic haemorrhage in the cochlear and

semicircular canals.⁴⁹ Schuknecht⁵⁰ reported similar autopsy findings in pancytopenic leukaemic patients with acute audiovestibular loss and Whitehead *et al*⁵¹ later reported labyrinthine haemorrhage in a patient with sickle cell disease. Labyrinthine haemorrhage has also been reported in association with antiplatelet and anticoagulant therapy,^{52, 53} cocaine ingestion⁵⁴ and systemic lupus erythematosus.⁵⁵ The diagnosis is made by imaging⁵² which shows hyperintense signal in the membranous labyrinth and cochlea on T2-weighted MRI with no change in signal on contrast administration. The hearing loss and vestibular canal paresis are usually severe and permanent.⁵²

AUTHORS' NOTE

Imperial College Neuro-Otology Unit website: <http://www.imperial.ac.uk/medicine/balance/research>

ACKNOWLEDGEMENTS

This article was reviewed by Richard Metcalfe, Glasgow, UK. BMS is supported by an Academy of Medical Sciences/Health Foundation Clinician Scientist Fellowship. AMB is supported by the Medical Research Council.

REFERENCES

- Crespi V. Dizziness and vertigo: an epidemiological survey and patient management in the emergency room. *Neurol Sci* 2004;**25**(Suppl 1):S24–5.
- Moulin T, *et al*. Impact of emergency room neurologists on patient management and outcome. *Eur Neurol* 2003;**50**:207–14.
- Bronstein AM, Lempert T. *Dizziness: a practical approach to diagnosis and management*. Cambridge Clinical Guides. Cambridge: Cambridge University Press, 2007.
- White J, Savvides P, Cherian N, *et al*. Canalith repositioning for benign paroxysmal positional vertigo. *Otol Neurotol* 2005;**26**:704–10.
- Furman JM, Cass SP. Benign paroxysmal positional vertigo. *N Engl J Med* 1999;**341**:1590–6.
- Baloh RW, Ishiyama A, Wackym PA, *et al*. Vestibular neuritis: clinical-pathologic correlation. *Otolaryngol Head Neck Surg* 1996;**114**:586–92.
- Gliddon CM, Darlington CL, Smith PF. GABAergic systems in the vestibular nucleus and their contribution to vestibular compensation. *Prog Neurobiol* 2005;**75**:53–81.
- von Brevern M, Zeise D, Neuhauser H, *et al*. Acute migrainous vertigo: clinical and oculographic findings. *Brain* 2005;**128**:365–74.
- Schmal F, Lubben B, Weiberg K, *et al*. The minimal ice water caloric test compared with established vestibular caloric test procedures. *J Vestib Res* 2005;**15**:215–24.
- Karlberg M, Annertz M, Magnusson M. Acute vestibular neuritis visualized by 3-T magnetic resonance imaging with high-dose gadolinium. *Arch Otolaryngol Head Neck Surg* 2004;**130**:229–32.
- Strupp M, *et al*. Methylprednisolone, valacyclovir, or the combination for vestibular neuritis. *N Engl J Med* 2004;**351**:354–61.
- Ariyasu L, Byl FM, Sprague MS, *et al*. The beneficial effect of methylprednisolone in acute vestibular vertigo. *Arch Otolaryngol Head Neck Surg* 1990;**116**:700–3.
- Amarenco P, *et al*. Very small (border zone) cerebellar infarcts. Distribution, causes, mechanisms and clinical features. *Brain* 1993;**116**:161–86.
- Huang CY, Yu YL. Small cerebellar strokes may mimic labyrinthine lesions. *J Neurol Neurosurg Psychiatry* 1985;**48**:263–5.
- Amarenco P, Rouillet E, Hommel M, *et al*. Infarction in the territory of the medial branch of the posterior inferior cerebellar artery. *J Neurol Neurosurg Psychiatry* 1990;**53**:731–5.
- Disher MJ, Telian SA, Kemink JL. Evaluation of acute vertigo: unusual lesions imitating vestibular neuritis. *Am J Otol* 1991;**12**:227–31.
- Lee H, *et al*. Nodulus infarction mimicking acute peripheral vestibulopathy. *Neurology* 2003;**60**:1700–2.
- Lee H, Cho YW. A case of isolated nodulus infarction presenting as a vestibular neuritis. *J Neurol Sci* 2004;**221**:117–19.
- Horii A, Okumura K, Kitahara T, *et al*. Intracranial vertebral artery dissection mimicking acute peripheral vertigo. *Acta Otolaryngol* 2006;**126**:170–3.
- Kumral E, Bogousslavsky J, Van Melle G, *et al*. Headache at stroke onset: the Lausanne Stroke Registry. *J Neurol Neurosurg Psychiatry* 1995;**58**:490–2.
- Schaefer PW, Copen WA, Lev MH, *et al*. Diffusion-weighted imaging in acute stroke. *Magn Reson Imaging Clin N Am* 2006;**14**:141–68.
- Neuhauser H, *et al*. The interrelations of migraine, vertigo, and migrainous vertigo. *Neurology* 2001;**56**:436–41.
- Cutrer FM, Baloh RW. Migraine-associated dizziness. *Headache* 1992;**32**:300–4.
- Radtke A, *et al*. Migraine and Ménière's disease: is there a link? *Neurology* 2002;**59**:1700–4.
- Yen Pik Sang F, Billar J, Gresty MA, *et al*. Effect of a novel motion desensitization training regime and controlled breathing on habituation to motion sickness. *Percept Mot Skills* 2005;**101**:244–56.
- Seemungal BM, *et al*. Three patients with migraine following caloric-induced vestibular stimulation. *J Neurol* 2006;**253**:1000–1.
- Dieterich M, Brandt T. Episodic vertigo related to migraine (90 cases): vestibular migraine? *J Neurol* 1999;**246**:883–92.
- Johnson GD. Medical management of migraine-related dizziness and vertigo. *Laryngoscope* 1998;**108**:1–28.
- Bikhazi P, Jackson C, Ruckenstein MJ. Efficacy of antimigrainous therapy in the treatment of migraine-associated dizziness. *Am J Otol* 1997;**18**:350–4.
- Ishiyama G, Ishiyama A, Kerber K, *et al*. Gentamicin ototoxicity: clinical features and the effect on the

- human vestibulo-ocular reflex. *Acta Otolaryngol* 2006;**126**:1057–61.
31. Rinne T, Bronstein AM, Rudge P, et al. Bilateral loss of vestibular function. *Acta Otolaryngol Suppl* 1995;**520**:247–50.
 32. Seemungal BM, Bronstein AM. Aminoglycoside toxicity: vestibular function is also vulnerable. *BMJ* 2007;**335**:952.
 33. Minor LB, Schessel DA, Carey JP. Ménière's disease. *Curr Opin Neurol* 2004;**17**:9–16.
 34. Monsell EM. New and revised reporting guidelines from the Committee on Hearing and Equilibrium. American Academy of Otolaryngology-Head and Neck Surgery Foundation, Inc. *Otolaryngol Head Neck Surg* 1995;**113**:176–8.
 35. Merchant SN, Adams JC, Nadol JB Jr. Pathophysiology of Ménière's syndrome: are symptoms caused by endolymphatic hydrops? *Otol Neurotol* 2005;**26**:74–81.
 36. Khurana RK, O'Donnell PP, Suter CM, et al. Bilateral deafness of vascular origin. *Stroke* 1981;**12**:521–3.
 37. Lownie SP, Parnes LS. Isolated vestibulocochlear dysfunction of central or peripheral vascular origin. *Laryngoscope* 1991;**101**:1339–42.
 38. Biavati MJ, Gross JD, Wilson WR, et al. Magnetic resonance imaging evidence of a focal pontine ischemia in sudden hearing loss and seventh nerve paralysis. *Am J Otol* 1994;**15**:250–3.
 39. Mort DJ, Bronstein AM. Sudden deafness. *Curr Opin Neurol* 2006;**19**:1–3.
 40. Lee H, Baloh RW. Sudden deafness in vertebrobasilar ischemia: clinical features, vascular topographical patterns and long-term outcome. *J Neurol Sci* 2005;**228**:99–104.
 41. Doyle KJ, Fowler C, Starr A. Audiologic findings in unilateral deafness resulting from contralateral pontine infarct. *Otolaryngol Head Neck Surg* 1996;**114**:482–6.
 42. Lee H, et al. Sudden deafness and anterior inferior cerebellar artery infarction. *Stroke* 2002;**33**:2807–12.
 43. Raupp SF, Jellema, Sluzewski M, et al. Sudden unilateral deafness due to a right vertebral artery dissection. *Neurology* 2004;**62**:1442.
 44. Yi HA, et al. Sudden deafness as a sign of stroke with normal diffusion-weighted brain MRI. *Acta Otolaryngol* 2005;**125**:1119–21.
 45. Grad A, Baloh RW. Vertigo of vascular origin. Clinical and electronystagmographic features in 84 cases. *Arch Neurol* 1989;**46**:281–4.
 46. Sugimoto T, et al. Relationship between cystic change and rotatory vertigo in patients with acoustic neuroma. *Acta Otolaryngol Suppl* 2000;**542**:9–12.
 47. Ihara T, et al. [Case of acoustic neurinoma with intratumoral hemorrhage extending to cerebellar hemisphere]. *No Shinkei Geka* 1984;**12**:1101–5.
 48. Schlieter M, et al. Hemorrhagic acoustic schwannoma: radiological and histopathological findings. *J Neuroradiol* 2005;**32**:210–12.
 49. Voss O. *Kinderheilk*. In: Holden HB, Schuknecht MD. Distribution pattern of blood in the inner ear following spontaneous subarachnoid haemorrhage. *J Laryngol Otol* 1968;**82**:321–9.
 50. Schuknecht HF, Igarashi M, Chasin WD. Inner ear hemorrhage in leukaemia. A case report. *Laryngoscope* 1965;**75**:662–8.
 51. Whitehead RE, MacDonald CB, Melhem ER, et al. Spontaneous labyrinthine hemorrhage in sickle cell disease. *AJNR Am J Neuroradiol* 1998;**19**:1437–40.
 52. Shinohara S, et al. Clinical features of sudden hearing loss associated with a high signal in the labyrinth on unenhanced T1-weighted magnetic resonance imaging. *Eur Arch Otorhinolaryngol* 2000;**257**:480–4.
 53. Vellin JF, et al. [Labyrinthine hemorrhage caused by anticoagulant therapy]. *Ann Otolaryngol Chir Cervicofac* 2005;**122**:194–7.
 54. Nicoucar K, et al. Intralabyrinthine haemorrhage following cocaine consumption. *Acta Otolaryngol* 2005;**125**:899–901.
 55. Sugiura M, et al. Inner ear hemorrhage in systemic lupus erythematosus. *Laryngoscope* 2006;**116**:826–8.