




ELSEVIER

Contents lists available at ScienceDirect

# Best Practice & Research Clinical Obstetrics and Gynaecology

journal homepage: [www.elsevier.com/locate/bpobgyn](http://www.elsevier.com/locate/bpobgyn)

6

## Disorders of puberty

Charles Sultan, MD, PhD, Pr<sup>a, \*</sup>, Laura Gaspari, MD<sup>a</sup>,  
Laurent Maimoun, PhD<sup>b</sup>, Nicolas Kalfa, MD, PhD, Pr<sup>c</sup>,  
Françoise Paris, MD, PhD, Pr<sup>a</sup>

<sup>a</sup> Unité d'Endocrinologie et Gynécologie Pédiatrique, Département de Pédiatrie, Hôpital A. de Villeneuve, Centre Hospitalo Universitaire de Montpellier et Université de Montpellier, France

<sup>b</sup> Service de Médecine Nucléaire, Département de Biophysique, Hôpital Layperonnie et Université de Montpellier, France

<sup>c</sup> Service de Chirurgie Pédiatrique, Département de Pédiatrie, Hôpital A. de Villeneuve, Centre Hospitalo Universitaire de Montpellier et Université de Montpellier, France



### Keywords:

Pubertal development  
Precocious puberty  
Delayed puberty  
Girls

Over the past 20 years, a clear secular trend toward the earlier onset of puberty has been described. A better knowledge should help clinicians attempting to define both precocious and delayed puberty (PP and DP, respectively). The definition of PP for girls is the appearance of secondary sex characteristics development before the age of 8 years, while DP is based on the absence of thelarche at the age of 13 years.

Regarding PP, one should clinically distinguish between true precocious puberty, i.e., complete or central PP, and incomplete PP, which refers to premature thelarche, premature pubarche, and isolated menarche. Evaluation of girls of PP requires careful examination of the clinical expression, a GnRH test, and imaging of the central neurosystem. GnRH analog is considered the gold standard treatment of central precocious puberty. Peripheral PP should be managed according to the underlying causes.

DP is suspected in girls with no breast development by the age of 13 years, or absence of menarche at 15 years with secondary sex characteristics. The clinical examination along with endocrine, radiological, and genetic investigation should be able to identify girls with permanent hypogonadism as opposed to those with transitory hypogonadism, who undergo spontaneous but DP. Estrogen therapy should be discussed according to the causes of DP.

\* Corresponding author.

E-mail address: [c-sultan@chu-montpellier.fr](mailto:c-sultan@chu-montpellier.fr) (C. Sultan).

In all cases, emotional and psychosocial disorders should be considered for these girls with disorders of puberty.

© 2017 Published by Elsevier Ltd.

## Introduction

Puberty is a sensitive period of physical, psychological, and social development for girls. A girl and her parents view any deviation from the normal course of puberty with great anxiety, whether the variant is normal or pathological.

Puberty is not a single event but is the culmination of a complex series of maturational events that start *in utero*, are activated in the neonatal period, and are then reactivated at the onset of pubertal maturation. Puberty has even come to be regarded as a biological sensor, and changes in its timing suggest that it may serve as a potential biomarker for negative environment influences on development [1].

The diagnosis of abnormal puberty requires a good understanding of normal pubertal development and its temporal course, including the variations that affect 30–50% of girls. It is described as consonant if it follows a normal sequence of pubertal changes and discordant if it is abnormal.

## Onset of puberty

The onset of puberty is determined by familial or genetic heritability and neuroendocrine factors and can be modulated by general health, nutritional adequacy, exercise, and environmental chemicals [2,3].

The neuroendocrine activation or reactivation of the hypothalamic-pituitary-ovarian axis is essential for the completion of puberty [4] and is regulated by a complex network of genes, neurotransmitters, and glial neuronal interactions within the hypothalamus (Fig. 1).

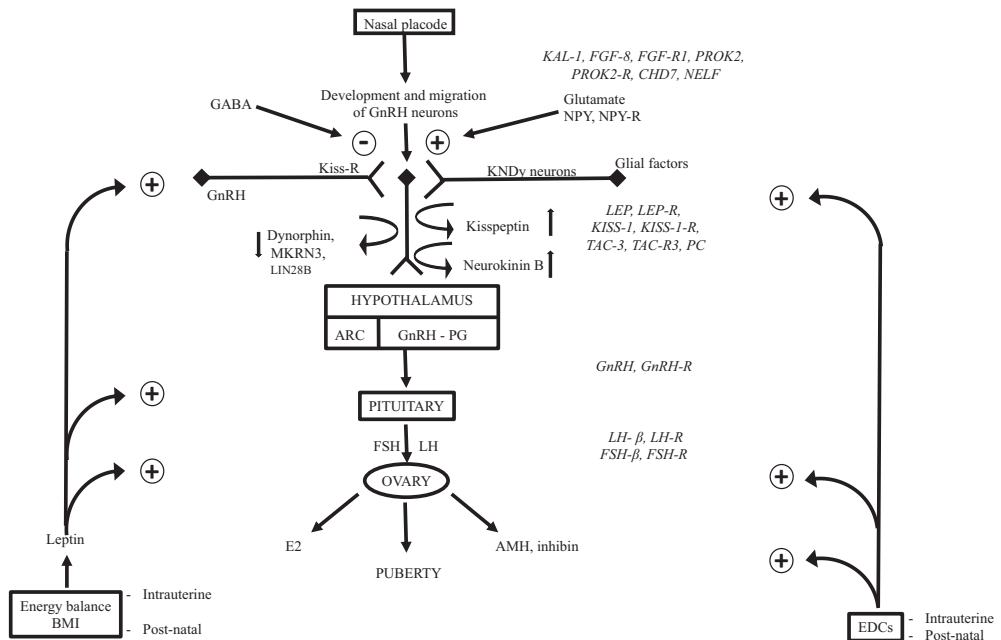


Fig. 1. Neurosecretory control of the onset of puberty.

Puberty starts with the activation of this neuroendocrine network, which results in the release of pulsatile GnRH secretion. In addition, secular trends appear to influence the physiological range for onset [5].

### *Neuroendocrine factors*

The secretion of GnRH is regulated by kisspeptin and its receptor kiss-R1, a G protein-coupled receptor, and is modulated by neurokinin B (and its receptor) and dynorphin (and its receptor). At puberty, the stimulatory effect of neurokinin b increases, while inhibition from dynorphin A is blocked. This results in an increase in GnRH secretion.

Several studies have detected loss-of-function mutations in kiss-R in idiopathic hypogonadotropic hypogonadic patients, which suggests that this receptor is a regulator of GnRH secretion after its activation by kisspeptin binding. These three supra-GnRH regulators compose the KNDy neurons, which are the key players in pubertal onset. Recently, Abreu et al. detected makorin ring finger protein 3 (MKRN3) gene mutations in families with central precocious puberty (CPP) [4]. According to this group, the function of MKRN3, a protein with a zinc-finger motif, is to inhibit the pulsatile secretion of GnRH at the onset of puberty. MKRN3 was proven to have an inhibitory effect on GnRH release and is thus considered a key factor in puberty initiation.

Moreover, the GnRH pulse generator is under excitatory and inhibitory control. The onset of puberty, i.e., the increase in GnRH secretion, starts when excitatory input increases, while inhibitory tone decreases.

Gamma amino butyric acid (GABA) is considered the major neurotransmitter that inhibits GnRH secretion during childhood.

Glutamate, neuropeptide Y, endorphins, opioids, and melatonin activate the GnRH pulse generator and regulate the timing of puberty. A cross-talk of amino acids (glutamate), peptides (kisspeptin), growth factors, and the input form of GABAergic and opioidergic neurons regulate GnRH neuron activity. The fine tuning of the epigenetic transcriptional regulation of these factors may modulate the pubertal process. The onset of puberty is marked by the increased frequency and amplitude of GnRH secretion, involving an increase in excitatory input of kisspeptin through KNDy neurons and glutamate and a decrease in inhibitory inputs from GABA neurons. Glial cells play a facilitating role through growth factor production (TGF $\alpha$ , EGF, etc.).

Moreover, thyroid transcriptional factor 1 and OCT-2, which are enhanced at puberty, are transcriptional factors that also seem to modulate GnRH secretion at puberty. Briefly, pubertal onset seems to integrate diverse genes [6] and hormone signals, modulated by peripheral signals.

MicroRNAs (MiRNAs) are short non-coding RNAs that silence gene expression post-transcriptionally. Messina et al. [7] recently showed that a switch in the miRNA expression patterns in infantile GnRH neurons inverts the balance between inductive and repressive signals, triggering an increase in hypothalamic GnRH expression and controlling the crucial transition from the early infantile phase, when levels are low, to the GnRH-fueled run-up to puberty.

This raises the suspicion that the miRNA-dependent epigenetic regulation of GnRH secretion may underlie the pathophysiology of early or delayed puberty (DP) [8].

Recent large-scale genome-wide association studies have been conducted on pubertal development and adiposity, clearly supporting the relevance of the LIN28B locus of pubertal timing (and age of menarche). Moreover, other common variants in/near LEP-R, GnRH, and TAC-R3 have been considered.

Amphiregulin is a member of the EGF family of proteins and binds the EGF-Rc to promote cell differentiation and proliferation of the mammary gland during puberty, along with estrogen signaling. In a recent work, Biro et al. [9] reported on the association of amphiregulin levels with the onset of breast development in a longitudinal cohort of girls. These authors suggested that amphiregulin levels might serve as an early biomarker of pubertal onset.

Jull et al. [10] recently reported that pubertal onset in girls was strongly influenced by genetic variations affecting FSH signaling. According to this group, breast development occurs 7.4 months later in healthy girls with the FSH-R-29AA genotype compared with that in carriers of FSH-R-29GG+GA.

### Metabolic control

The onset of puberty in girls is highly sensitive to nutritional status and energy reserves, and this metabolic information is transmitted to GnRH neurons [11]. Indeed, obesity during childhood may lead to premature thelarche or early pubertal onset [12]. The central activation of GnRH neurons by leptin has been considered a causal mechanism: the relevant action of leptin, an adipose tissue hormone, as a stimulating factor on KNDy neurons has not been fully clarified.

Because the neuropeptide  $\alpha$ -MSH plays a key role in energy homeostasis by mediating the action of leptin, Tena-Sempere et al. [13] recently analyzed the potential contribution of central MSH signaling to the metabolic control of puberty. By using wild-type and genetically modified rodent models, pharmacological studies, expression analysis, electrophysiological recording, and virogenetic approaches, this group was able to demonstrate a novel leptin  $\rightarrow$   $\alpha$ -MSH  $\rightarrow$  kisspeptin  $\rightarrow$  GnRH neuronal signaling pathway involved in transmitting the permissive effects of leptin on pubertal maturation.

Briefly, early puberty in obese girls may be related to [14]

- activation of GnRH neuron secretion by leptin;
- exaggerated insulin secretion;
- increased endocrine disrupting chemical (EDC) concentration. For example, there is a good correlation between BMI and bisphenol A (BPA) concentration.

Moreover, the intrauterine milieu may influence the timing and the tempo of puberty: early puberty is known to occur in girls with intrauterine growth restriction (IUGR).

### Role of endocrine disruptors

In the last two decades, the onset of puberty appears to have transitioned to younger ages by 12–18 months. Hypotheses explaining this shift encompass both intrinsic (nutritional status) and extrinsic factors (EDCs) [15]. Both are known to contribute to early onset and the increased prevalence of early onset in girls [16].

Evidence for an association between EDCs and early pubertal onset or early puberty (premature thelarche or central precocious puberty) has been derived from epidemiological, toxicological, clinical, and experimental studies and from wildlife observation in contaminated ecosystems [3,17].

It is now accepted that EDCs can modulate the endocrine system, and their potential impact on human health recently became a medical issue of major concern among scientists, medical practitioners, and the general public [18].

EDCs can interfere with any site, where estrogens are acting

- estrogen target tissues;
- hypothalamic-pituitary function [19].

In female rodents, prenatal BPA exposure induces the early timing of vaginal opening in most experiments. Similarly, prenatal exposure to DES is followed by early vaginal opening.

EDCs, which may cause hypomethylation, have the potential to modify the pubertal process and/or the ability of individuals to cope with the environment.

Briefly, over the past 20 years, a clear secular trend toward earlier onset of puberty [20] has been described by several international studies (Fig. 2). For instance, in Denmark, a mean decrease in age of 1 year was documented over a 15-year period [21].

In summary, better understanding of the normative ranges has a crucial impact and should help clinicians attempting to

- define both PP and DP;
- decide on the appropriate investigations;

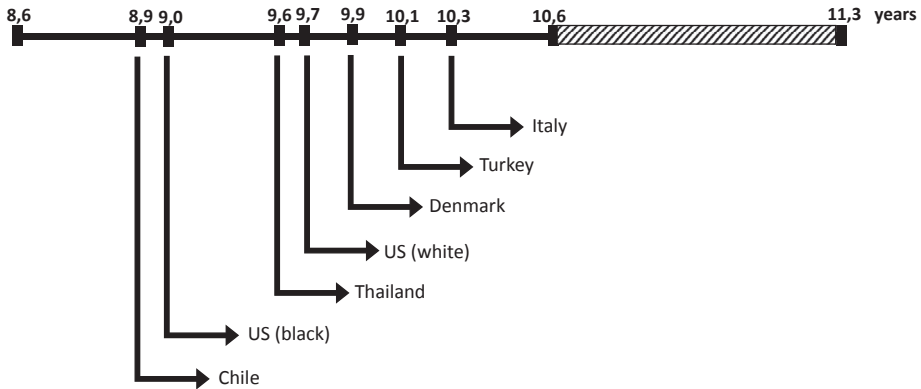


Fig. 2. Age at onset of puberty, as compared with Tanner stage B2.

- decide on the need for specialist referral;
- manage the treatment.

### Definition of abnormal puberty

The classic definition of abnormal puberty, whether premature or delayed, is according to the timing that is 2.5 SD below the mean.

The definition of PP for girls is the appearance of secondary sexual development before the age of 8 years. This definition was revised on the basis of the findings of the Pediatric Research in Office Settings (PROS) networks, but several experts disagree with these guidelines [22], which propose that PP be defined by the presence of breast (or pubic hair) development before the age of 7 years. The PROS recommendations are not routinely followed.

Conversely, the definition of pubertal delay remains based on the absence of thelarche at the age of 13 years. Primary amenorrhea corresponds to the absence of menarche at 15 years, which is approximately 2.5–3 SD from the mean.

The American Academy of Pediatrics and the American College of Obstetricians and Gynecologists have jointly published guidelines that recommend the evaluation of DP if menarche does not occur within 3 years of thelarche.

These guidelines also recommend evaluation of girls with suspected DP when

- no breast development is observed by the age of 13 years;
- menarche is absent at 14 years in the presence of some degree of breast development;
- menarche is absent at 15 years.

Age definitions should, however, be considered as general guidelines. The evaluation of the disorders of puberty needs to be managed case by case.

### Precocious puberty

The overall incidence of sexual precocity has been estimated to be between 1/5000 and 1/10,000 [23].

According to the new guidelines, puberty is not precocious unless it occurs before 7 years for Caucasian girls and 6 years for African-American girls. However, like most pediatric endocrinologists, we evaluate girls with PP prior to the cut-off age of 8 years, and especially those between 7 and 8 years, corresponding to the so-called early puberty.

Several terms have been used to describe the type of PP. It is generally accepted that one should clinically distinguish between (Table 1).

- true PP, also known as complete or CPP, and
- incomplete PP, which refers to isolated premature thelarche, isolated premature pubarche, and isolated menarche.

For a pathophysiological point of view, we usually differentiate

- central PP: GnRH dependent and
- peripheral PP: GnRH independent.

Sexual precocity has also been categorized as iso- or heterosexual, according to whether the pubertal expression is related to hyperestrogenization or virilization, respectively.

Early pubertal development is a common cause of parental anxiety and the major reason for referral to specialists. However, only a small number of girls require investigation and treatment [24].

### Central precocious puberty

#### Evaluation

The evaluation of PP requires careful examination of the secondary sexual characteristics [25] and detailed analysis of the growth chart to identify a marked increase in growth velocity, which sometimes occurs prior to the presentation of PP.

- Bone age X-rays are helpful to identify the level of advanced bone maturation.
- Evaluation of uterine size and ovarian morphology by pelvic ultrasound provides reliable information on the estrogenization level.
- In addition, imaging of the central nervous system (CNS) is mandatory regardless of the age of girls at the onset of puberty but particularly in girls younger than 7 years.

**Table 1**

Classification of female precocious puberty.

- 
- 1 Central precocious puberty, true precocious puberty: gonadotropin dependent
    - a. Idiopathic
      - Typical form
      - Other clinical forms:
        - Extremely precocious puberty
        - Slowly progressive precocious puberty
        - Spontaneously regressive precocious puberty
        - Precocious puberty in adopted children
        - Familial central precocious puberty
        - Single advanced of puberty
        - Early puberty and growth retardation
        - Early puberty after premature pubarche
        - Early puberty in IUGR
    - b. Tumoral: CNS lesions (hamartoma, etc.)
    - c. Genetic forms of precocious puberty
    - d. Secondary to hypothyroidism, to peripheral precocious puberty
  2. Incomplete isosexual precocity
    - a. Isolated thelarche
    - b. Isolated pubarche
    - c. Isolated menarche
  3. Peripheral precocious puberty, pseudo-precocious puberty
    - a. Ovarian autonomous hyperactivity
    - b. Peripheral hyperestrogenism: environmental endocrine disruptors
-

Abnormal CT scan and MRI are reported in 2% of girls with pubertal onset before 8 years and in 20% of girls when CPP started before 5 years.

- The gold standard in diagnosing CPP is the GnRH stimulation test. Because basal serum LH as a routine for diagnosis is usually inconclusive, a peak level of LH > 5–7 mIU/ml in 30 min after GnRH administration is considered adequate for diagnosing CPP [26].

#### *Clinical expression*

PP is 8 times more frequent in girls than in boys. Premature breast development, pubic hair, and growth acceleration should prompt several questions, the answers to which will provide clues as to the best adapted treatment strategy.

1. Did puberty clinically begin before 8 years of age?
2. What has been the progression of the clinical symptoms?
3. What is the neighborhood environment? The professional activity of the parents? [27]
4. Are there biological or radiographic signs of exaggerated maturation?
5. How is predicted adult height affected?
6. What are the psychological consequences?
7. Is the hormone secretion gonadotropin dependent or independent?
8. In the case of central gonadotropin activation, is it because of a tumor or is it idiopathic?

#### • Typical presentation

The simultaneous development of breasts >B3 and pubic hair >P3 in a girl younger than 8 years suggests CPP when growth rate is also accelerated (>2 SD of the mean for chronological age). When the medical history is obtained, the family should be questioned about past head X-rays, brain trauma, and neonatal CNS infection (meningitis, encephalitis). In addition, the impact on the child's psychological health or well-being should be assessed.

The clinical examination reveals a modification in the orientation of the vulva, development of the labia majora, and vaginal secretion. The weight curve should systematically be analyzed [28]. Once this initial clinical step is concluded, it is important to confirm the diagnosis of a central cause and determine the etiology. The hormone work-up is limited to GnRH testing, and a predominant LH response signals central gonadotropin activation [29,30].

In CPP, the X-ray of the left wrist and elbow reveals advanced bone maturation, and bone age is often greater than chronological age. This sign is fundamental. In certain forms of explosive PP, however, clinical expression may precede the accelerated bone maturation, which occurs only after some months.

Pelvic ultrasound is indispensable. Uterine length >35 mm indicates hyperestrogenization usually related to pubertal onset. Multifollicular ovaries reflect central stimulation. Brain MRI should still be systematic.

A CNS tumor (hypothalamic hamartoma, optic chiasm glioma, etc.) is found in 10–15% of the cases. Moreover, central structures can be affected secondary to infection (meningitis, meningoencephalitis), radiation, or brain trauma [31].

#### • Other clinical forms

In addition to the typical presentation of CPP, which usually occurs between 5 and 8 years, several other forms have been identified and can be distinguished by their etiology, progression, and therapeutic indications [32].

#### - Profoundly PP

Profoundly PP occurs between 1 and 4 years: the clinical progression is rapid and more anarchic, and menstruation occurs. The search for a cerebral tumor should be particularly painstaking.

#### - Slowly progressing puberty

Slowly progressing puberty is defined as moderate breast enlargement, E2 concentration <25 pg/ml, an advance in bone maturation of <2 years, and a ratio of LH peak over FSH peak <1. Moreover, the circulating concentration of IGF-1 is prepubertal. If the clinical picture remains stable after 6 months of observation, treatment to stop puberty is not indicated.

#### - Spontaneously regressive puberty

Cases of spontaneously regressive puberty have long been a subject of discussion: these are authentic cases of CPP in which the signs of estrogenic secretion spontaneously and completely regress in the 12 months following the consultation for sexual precocity. In our experience, no clinical, biological, or radiologic element predicts this particular course. This rare form requires no treatment but points to the need for systematic follow-up over 6–12 months for all cases of sexual precocity.

#### - Central PP in adopted children

Central PP in adopted children is seen almost exclusively in girls between 4 and 8 years, regardless of the country of origin, and its occurrence is variable after arrival in the country of adoption. This form is characterized more by the rapidity of the acceleration in growth velocity and maturation than by the clinical signs, and it evokes the relationship of poor nutrition/inadequate caloric intake, renutrition, rapid rise in IGF-1, and precocious onset of puberty.

#### - Familial central PP

Routine clinical experience has shown that the age of menarche has remained remarkably consistent across generations and that in certain families, pubertal onset has always been more or less precocious. A recent study from the group of Philips et al. reported a high proportion (27.5%) of the familial form of CPP. Analysis indicated autosomal dominant transmission with weak penetrance. These data suggest the need to pay particular attention to the girls in these families, especially because in this study, the girls with familial CPP were evaluated later than the girls with sporadic forms. This clinical form of CPP is a remarkable illustration of the implication of genetic factors in puberty onset.

#### - Simple advanced puberty

Simple advanced puberty refers to pubertal advance that remains within 2 SD of the norm, generally appearing between 8 and 10 years of age. It is often the reason for short adult height, because the acceleration of bone maturation is more rapid than statural growth. It is particularly seen in girls of Mediterranean background, and a girl showing this simple advance of puberty often has a mother who experienced the same advance (genetic character).

Some authors [33] have tried to delay puberty in order to extend the growth period and thus improve the final adult height. In fact, GnRH analogs did not improve the predicted final height.

#### - Simple advanced puberty and growth retardation

In many cases, a simple advance of puberty occurs in girls showing growth delay  $\leq -2$  SD, especially those who presented with IUGR. The prognosis for final height is affected, with adult height of 145–150 cm.

#### - Advanced puberty after premature pubarche

At a chronological age of 8–10 years, some girls have presented with premature pubarche and gonadal onset of puberty at a bone age of 10–11 years. Some of these girls, especially the obese, are at



risk of developing polycystic ovarian disease in adolescence [34]. They require close clinical, biological, and radiologic follow-up throughout the adolescent period.

#### - Early puberty/IUGR

Restricted prenatal growth may be followed by a permanent resetting of the endocrine axes that co-determine pubertal development. Several studies document a relationship between IUGR and earlier pubertal development or normal timing, but with rapid progression.

A strong association between prenatal growth and early pubertal development was first established by Person et al., but other studies have confirmed that impaired fetal growth may have long-lasting effects on pubertal development.

The mechanism behind the early pubertal development has not been fully elucidated, but one should bear in mind that nutritional rehabilitation after persistent undernutrition prompts catch-up growth associated with increased gonadotropin secretion, which in turn leads to early puberty. Some animal studies have correlated small for gestational age (SGA) and early onset of puberty and accelerated sex maturation.

#### *Molecular genetics*

Some years ago, the first heterozygous activating mutation in the KISS1R (p.Arg386Pro) was identified in adopted Brazilian girls with CPP. This activating mutation led to the prolonged activation of intracellular signaling pathways in response to kisspeptin. Other mutations in candidate genes involved in the regulatory mechanism of GnRH secretion have not been identified [35].

Conversely, different loss-of-function mutations of MKRN3 have been described in patients with CPP, evidencing the key function of MKRN3 as an inhibitor of GnRH neuron activation.

#### *Psychological problems*

Girls with PP may be stressed because of physical and hormonal changes they are too young to understand [36]. They may be teased by their peers because of their physical differences [37], and they are likely to have increased libido, leading to masturbation or inappropriate sexual behaviors. They are therefore at risk for significant psychosocial problems: poor self-esteem, higher anxiety, irritability, and eating disorders [38,39]. Notably, they are at higher risk for sexual abuse, which should thus be routinely screened for (5% of girls in our experience).

There is no consensus regarding GnRH analog treatment to prevent the negative psychosocial consequences in girls who fall outside the new recommendations for CPP treatment [6,40]. Discussion about initiating treatment to prevent long-term sequelae in these girls is appropriate.

#### *Treatment*

*Central precocious puberty.* GnRHa has been considered the gold standard treatment of CPP. It suppresses LH pulsatile secretion, and a regression of pubertal signs occurs within 3–6 months. The efficacy of these agonists is similar in terms of gonadotropin suppression [41].

The use of GnRHa to treat CPP was recently discussed in a consensus statement [42]. One of the main reasons for this treatment is to preserve height potential, with treatment indicated if the predicted height is <140 cm (55 inches). Prevention of early menarche and the psychological consequences should also be considered in an emotionally immature girl [43].

The optimal time for discontinuing GnRHa treatment has not been clearly established. In our experience, however, discontinuation at 11 years results in optimal height outcome. Mean adult height is significantly higher in treated patients, with a mean adult-height difference of 8.3 cm (3.3 inches). The decision should nevertheless consider the psychological impact on the patient.

Most studies show significant improvement in adult height compared with predicted height at the start of the treatment [44]. The extent of the improvement depends on the following:

- the age of the onset of PP and treatment initiation;
- the level of bone maturation;
- height at the beginning of treatment;
- target height;
- effective suppression of ovarian hyperactivity;
- more rarely, BMI.

According to Lazar et al., the benefits of treatment are greater in girls who are diagnosed and treated at a younger age (6 > 6–8 > 8 years) [45].

Spontaneous menses occurs 6–18 months after the cessation of treatment. In some cases, the completion of treatment is associated with increase in obesity. The risk of polycystic ovary syndrome (PCOS) has been diversely appreciated. In our experience, 20% of the cases develop signs and symptoms of PCOS, but many investigators have reported that fertility is normal in such cases. GnRHa treatment has no detrimental effect on bone mass acquisition. Pubertal signs reappear within 6–12 months after the cessation of therapy [46]. PP is associated with an increased risk of disease in adult life [47] and later psychosocial adjustment problems [48].

*Central precocious puberty and growth retardation.* Several studies have reported that GnRHa might also decrease height velocity below the age-appropriate normal range and, in some cases, impair predicted adult height. To compensate for the reduced GH-IGF1 production during GnRHa treatment, some authors have proposed the addition of hGH in combination with GnRHa. The controversial results for the adjunctive treatment of hGH plus GnRHa prompted the Lawson Wilkins Pediatric Endocrine Society and the European Society for Pediatric Endocrinology not to recommend the addition of hGH for the treatment of CPP. Conversely, several groups in China continue to associate hGH with GnRHa treatment. In a very recent systematic review, Wang et al. analyzed the effects of combined treatment in 464 Chinese patients included in 14 studies [49]. This meta-analysis clearly demonstrated that compared with GnRHa treatment alone, GnRHa plus hGH treatment led to a significant increase in predicted adult height and final height.

In our opinion, the combined treatment should be considered in exceptional conditions.

*Early puberty.* GnRHa therapy is an effective way to improve adult height in girls with CPP when treatment starts before the age of 8 years. There remains a debate on the utility of GnRHa treatment in girls with early CPP or premature thelarche, which occurs between 7 and 9 years of age.

The benefits of GnRHa treatment in girls with early puberty are controversial [50]. The psychological effects and social impact are likely to be considerable for patients and their families, and these concerns sometimes are enough to prompt the use of GnRHa. However, an analysis of the 12 main studies in 474 girls indicated that the height gain (adult height minus predicted height at start of treatment in cm) was  $3.61 \pm$  SD for girls treated between 7 and 9.3 years of age and treated for approximately 3 years.

Briefly, the result of GnRHa treatment in girls with early puberty is inconclusive, and the decision should be made case by case, on the basis of patient's and family's concerns.

#### *"Incomplete" puberty*

Incomplete puberty refers to the premature and often isolated development of a secondary sexual characteristic: the breast (premature thelarche) or pubic hair (premature pubarche). Occasionally, isolated menarche is seen. These situations are frequently observed in daily practice and are difficult to diagnose. Incomplete puberty is usually considered a variant of normal puberty, but it may be caused by an underlying pathology that should be sought, or it may be the only current sign of a CPP that will develop in the future.

#### *Premature thelarche*

Premature thelarche is a benign and self-limited condition. It is defined as isolated breast development without the development of other sexual characteristics before 8 years of age. According to

many authors, it typically occurs within the first 2 years of birth. In our opinion, this refers to the genital crisis of an infant girl with breast development associated with elevated estrogen secretion and even milk production and lasting 3–12 months after birth. In this case, the premature thelarche, which usually occurs during the first 2 years of life, is an exaggerated mini-puberty occurring in the post-natal period [51]. In many countries, it tends to occur mainly between 5 and 8 years [52].

Premature thelarche might represent one end of a continuum from isolated breast development to CPP [53,54]. Earlier thelarche tends to be gonadotrophin independent, as suggested by the unchanged age of menarche, which has been confirmed by endocrine investigations.

Clinical examination reveals that premature breast development is bilateral in half the cases, or less frequently asymmetric or unilateral. In 80% of the cases, the breast volume varies between B2 and B3 with the breast often being tender and palpation sometimes painful.

In persistent or marked forms of thelarche, the hormonal work-up should be limited to the GnRH test to confirm a predominant FSH response [55]. Bone maturation is rarely accelerated. The progression is characterized by fluctuations over time: spontaneous remission, persistence, and increase in breast volume, which should evoke the possibility of pubertal onset. In this case, the evaluation of uterine size by pelvic ultrasound can provide useful information.

Many pathophysiological factors have been suggested to contribute to its development:

- obesity (increased leptin levels);
- excessive intake of phytoestrogens (genistein);
- EDCs, which in recent years have been considered an etiological factor [56,57].

When estrogen secretion is present (simultaneous increase in uterine volume), contamination by products with estrogen-like activity should be considered and sought (soy-rich foods and EDCs.) [57–62].

These patients should be followed over a 6-month period. If the breast increases in size, investigations should be considered, and referral to a specialist with expertise in pubertal disorders is advised.

#### *Premature pubarche*

Premature pubarche, considered a benign variant of normal pubertal development [63], is particularly frequent in girls from the Mediterranean area [24]. Interestingly, in 10–20% of the cases, it has been associated with insulin resistance in obese girls [64] or in girls with late onset congenital adrenal hyperplasia (CAH). This endocrine disorder should be identified.

Premature pubarche is characterized by the presence of pubic hair in girls younger than 8 years of age [65]. It is also referred to as premature or exaggerated adrenarche, and it is considered a benign condition of normal development [66], occurring in 4–10% of prepubertal girls. However, other causes of excess androgen should be considered, such as

- PP;
- enzymatic defects of adrenal steroidogenesis (late onset CAH-21 hydroxylase deficiency);
- adrenal tumors, which must be ruled out [67].

The mechanism of the onset of adrenarche remains unknown, although the implication of leptin, IGF1, and ACTH has been considered. MC-2 receptor, CYP19, IGF1, and AR gene polymorphisms have been reported to be associated with premature pubarche in some cases. Finally, the physiological role of adrenarche in the pubertal maturational process has never been elucidated.

*Clinical features.* The consequences of androgen excess exposure in prepubertal girls are [68] as follows:

- development of pubic hair;
- development of axillary hair;
- acne;

- oily skin and hair;
- adult body odor;
- mood swings and/or behavioral changes.

In a recent study of 63 girls with premature pubarche, Voutilanen reported that 89% presented adult-type body odor, 70% had oily hair, 56% acne, 48% pubic hair, 38% axillary hair, and 12% acanthosis nigricans [66]. In 20–50%, higher childhood weight was observed. Moreover, a moderate advance of bone age is usually noted.

*Evaluation of girls with premature pubarche.* The diagnosis of premature pubarche [69] is based on the exclusion of other causes of pubertal hyperandrogenism. The focus should be on the age at the onset of signs, the tempo of their changes, and the possibility of recent growth acceleration.

- Examination of the girl should determine the pubertal staging, other signs of hyperandrogenism, and BMI: obese girls with PP are at the risk of developing PCOS [70], especially those with low birth weight. Birth size should be recorded, as should the family history of pubertal timing and metabolic syndrome and diabetes mellitus type 2 must be considered [37,71].
- Laboratory assessment is limited to measuring basal serum 17-OH progesterone, DHEAS,  $\Delta$ 4-androstenedione, and testosterone. An ACTH stimulation test should be performed if the basal 17-OH progesterone level is above 2 ng/ml. Insulin sensitivity should also be assessed if the BMI is elevated.
- Abdominal MRI should be considered when an adrenal androgen-secreting tumor is suspected [72].

*Differential diagnosis.* Premature pubarche must be distinguished from a number of pathological conditions:

- Precocious puberty: PP may be a marker for the early onset of puberty: idiopathic CPP may present with pubic and/or axillary hair [73]. Bone age and growth velocity are accelerated, and plasma androgens are abnormally elevated for age.
- Non-classical congenital adrenal hyperplasia (NC-CAH): NC-CAH is usually related to 21-OH deficiency. In this condition, NC-CAH has an extremely variable presentation. In prepubertal girls, the presenting signs include PP, cystic acne, accelerated growth, and advanced bone age. NC-CAH has been found in 1–30% of girls with PP, with a wide range of reported percentages likely related to ethnic differences. The biological diagnosis of NC-CAH is suspected when early morning basal 17-OH progesterone is >200 ng/dL and when it is increased to >1200 ng/dL after an ACTH stimulation test. In our experience, 24% of a cohort of 40 girls with premature pubarche presented a molecular defect within the 21-OH gene.
- Virilizing adrenal tumors: These tumors are rare: we recently had the opportunity to manage two very young girls referred to our clinic for isolated PP without exaggerated symptoms of virilization. MRI was performed because abdominal palpation revealed an abdominal mass [74]. In both cases, a corticosteroidoma was diagnosed and surgically removed.
- Exogenous androgen exposure: This exclusively occurs through creams or gels containing testosterone.

*Management.* There are several recommendations for the management of PP:

- If there is unusual weight gain, measurement of fasting glucose and insulin are recommended [75].
- If pubertal progress is rapid, laboratory and imaging assessment ought to be performed.
- In most cases, when clinical and laboratory findings are consistent with idiopathic premature pubarche, these girls should be followed at 6-month intervals until menarche.

- These girls should be followed at least yearly after menarche because they are considered to be at high risk for further adolescent PCOS, for those who had low birth weight and prepubertal weight gain:

Briefly,

- Premature pubarche is a frequent condition in girls, particularly in those from the Mediterranean area.
- The prevalence of premature pubarche is increasing, likely because of the recent higher incidence of obesity among prepubertal girls.
- Clinical and laboratory investigations are useful for distinguishing early adrenal maturation from the first signs of persistent hyperandrogenism.
- Extended longitudinal studies are needed to confirm the suspected association between early onset of androgen excess, insulin resistance, and PCOS.
- Premature pubarche is not always a benign condition and justifies the periodic assessment of girls at risk [74].

#### *Isolated menarche*

Several clinical manifestations of transitory ovarian activity have been observed in isolated metrorrhagia: menstruation that is isolated or associated with breast development, with inconsistent response to the GnRH test and the frequent presence of functional ovarian cysts [76]. Menstruation may recur cyclically. These rises in estrogenization increase the risk of accelerated bone maturation, and treatment to delay puberty is thus often considered but rarely undertaken.

Menstrual-like bleeding in prepubertal girls is uncommon and not well understood. It is believed to be because of the sensitivity of the endometrium to very low levels of estrogens [77]. It is also possible that EDCs can stimulate prepubertal endometrium.

#### *Peripheral precocious puberty: precocious pseudopuberty*

Peripheral precocious or precocious pseudopuberty is not characterized by the premature activation of the gonadotropic axis: it is caused by an abnormally high production of estrogens and androgens because of a “tumor” in the ovary or adrenal glands. It is iso- or heterosexual depending on whether the excess steroid hormone strengthens or transforms the child’s phenotype.

The considerable progress in determining the molecular mechanisms of hormone transduction signals has greatly contributed to our understanding of the pathophysiology and clinical expression of peripheral PP caused by ovarian autonomy [78]. This progress may one day culminate in specific treatment for this rare but incapacitating disorder [79]. Heterosexual precocious pseudopuberty secondary to a virilizing adrenal or ovarian tumor is much rarer.

Increasing attention should be given to precocious pseudopuberty secondary to environmental contamination by chemical products such as pesticides, herbicides, and fungicides [80]. Endocrine disruptors with the capacity to mimic estrogens can generate estrogen secretion, resulting in simple thelarche to veritable menstruations.

#### *Peripheral precocious puberty caused by autonomous ovarian hyperactivity*

*McCune-Albright syndrome.* McCune-Albright syndrome (MAS) is a sporadic disorder characterized by the classic triad of PP, fibrous bone dysplasia, and café-au-lait spots. Diverse endocrine abnormalities can also be associated: somatotrophic pituitary adenomas, hypothyroid goiter, and adrenal hyperplasia.

MAS affects girls almost exclusively and is characterized by its extreme precociousness and the severity of the immediate clinical picture: isolated menstruation as early as the first months or first years of life. The full clinical picture will develop later, with breast enlargement and pubic hair. The often voluminous ovarian cysts discovered by ultrasound are cyclic and difficult to treat: cystectomy or

ovariectomy is often necessary when all other treatments fail. The acceleration of growth velocity is considerable (+2, +3 SD) and constant, on the order of 9–10 cm per year (3.5–4 inches). Bone maturation is also accelerated and will thus compromise the prognosis for final adult height.

The evaluation shows very high plasma estradiol associated with dramatically low plasma gonadotropins and nonresponse to GnRH stimulation. This indicates LH/FSH-independent PP and situates it within the context of the ovarian-autonomous syndromes.

The café-au-lait spots of MAS are hyperpigmented, typically light brown or brown, with irregular borders (“coast of Maine”), and are usually unilaterally distributed, on the same side as that of bone lesions. When associated with PP, they are an essential diagnostic element.

Fibrous bone dysplasia is the third element in the classic triad. This bone abnormality may remain silent for many years, only to be revealed by a spontaneous fracture or when a slight injury occurs. X-rays reveal pseudocysts of the bone cortex that rapidly invade the entire skeleton.

Other endocrine pathologies are seen to varying degrees: hyperthyroidism, acromegaly, gigantism, hypercorticism, hyperprolactinemia, and hyperparathyroidism. These types of endocrine hyperfunctioning are also caused by autonomous hormonal hyperproduction.

Moreover, the diverse endocrine hyperfunctioning syndromes observed in the course of MAS have in common the presence and activation of cells that respond to extracellular signaling by activation of the adenylyl cyclase system. The growth and activity of ovary, thyroid, adrenal cortex, certain pituitary cells, melanocytes, and osteoblasts are stimulated by an increase in intracellular cyclic adenosine monophosphate under the dependence of adenylyl cyclase membrane.

MAS is indeed caused by a genetic abnormality that causes a constitutive activation of adenylyl cyclase. The evidence of activating *Gαs* mutations in various tissues of MAS patients further supports this mechanism [81].

Treatment has included aromatase inhibitors such as testolactone and selective estrogen receptor modulators. There have been no case-control studies to evaluate the efficacy of each treatment. In our experience, fulvestran, an aromatase inhibitor, could reduce vaginal bleeding and the accelerated bone maturation, but no change in the predicted target height or the frequency of ovarian cysts was observed. When the shift from gonadotropin-independent to gonadotropin-dependent puberty occurs, GnRHa should be prescribed.

*Granulosa cell tumor.* Although rare (10% of the ovarian tumors in children), granulosa tumors are expressed in early childhood by strong estrogen secretion that results in marked breast development, accelerated growth velocity, and menstruation [82].

The hormonal activity of the tumor explains why 80–90% of the girls under 8 years present isosexual precocious pseudopuberty. On clinical examination, breast development is frequently noted, but this is variable, and metrorrhagia, accelerated growth velocity, and sometimes advanced bone age are also noted. The preoperative plasma estrogen concentration is usually elevated. Virilization (precocious pubarche, acne, hirsutism, and rarely clitoromegaly) is present in rare cases.

Early diagnosis through the early recognition of endocrine signs from ovarian granulosa cell tumors (OGCTs) significantly improves its prognosis with a lower risk of peritoneal extension.

This pubertal advance induced by the estrogen secretion of tumor cells is independent of the low levels of GnRH and prepubertal gonadotropins. In most patients, the levels of inhibin and anti-Müllerian hormone (AMH) are elevated and return to normal post-surgery. The level of inhibin is correlated with tumor extension and eventual relapse. If the estradiol level is initially high, this too can be useful for follow-up [83].

Surgery is the treatment of choice for a granulosa cell tumor. In stages with extraovarian extension, chemotherapy is recommended. Follow-up includes careful clinical, hormonal, and ultrasound evaluation.

Because of its excellent prognosis and the often complete recovery after initial surgery, juvenile OGCT has usually been considered a benign condition.

Molecular biology [84] has identified two markers of prognosis:

- Mutations of the *Gαs* protein have been found in 30% of patient DNAs. Patients with hyper-activated *Gαs* exhibited a significantly more advanced tumor ( $p < 0.05$ ).

- Another prognostic factor of OGCT could be the level of FOXL2 expression, one of the earliest differentiating genes of granulosa cell. Patients with no or reduced expression of FOXL2 in their tumor exhibit significantly more advanced oncological staging, and they require complementary treatment (chemotherapy or complementary surgery).

#### *Peripheral hyperestrogenization: EDCs*

One of the major recent causes of earlier puberty onset could be extensive exposure to the many estrogenic chemicals in the environment, such as phthalates, bisphenol A, polybrominated diphenyl ethers, and organochlorine pesticides [80,85–88].

The association of EDCs and early puberty has been extensively studied in animals. Many experimental data indicated the impact of chemical contamination (pesticides) during gestation on the timing and tempo of puberty, and these data have been extensively reviewed [89]. The growing recognition of the potential impact of endocrine disruption on the timing of puberty should prompt in-depth investigation of the environmental conditions of a child with PP when conventional etiologies prove negative [90].

In girls, transient exposure to dichlorophenylethylene (DDE) was related to PP in girls who migrated from Africa (where DDE is still used) to Europe (where DDE is banned).

Phthalates have been reported in association with advanced puberty [91]. In Puerto Rico, phthalate levels in the blood of girls with PP were 68% higher than those of a control group. In Korea, some groups have reported a significant relationship between plasma phthalate levels and PP in girls.

Both OP and nonyphenol plasma levels were higher in girls with PP.

Genistein was 2.7 times higher in the plasma of girls with PP.

EDCs may interfere with pubertal onset by actions at different levels:

- the neuroendocrine hypothalamic-pituitary axis;
- the ovary, through activation of aromatase enzyme activity;
- the peripheral estrogen target tissues, such as breast (through binding to estrogen receptors).

Several reports have detailed veritable epidemics of precocious pseudopuberty. In Italy, 21% of the girls in preschool classes presented with premature thelarche in association with poultry intake. More recently, the high frequency of PT before 7 years (34%) in Puerto Rico was associated with phthalates levels 3 times higher than that seen in controls.

Moreover, European pediatric endocrinology groups and our team agree that the frequency of PP has clearly been rising over the past several years [92,93].

In conclusion, daily clinical practice reveals great diversity in the clinical expression of PP in girls. Pubertal development seems to occur along a continuum from normal to advanced to precocious, which reinforces the importance of an etiological approach to these increasingly frequent situations, through clinical, biological, and radiological examinations. A better understanding of the clinical presentation should improve the therapeutic indication, especially concerning the use of GnRH analogs, which should be limited to CPP before the age of 8 years as this particular situation is liable to compromise final adult height, according to the clinical, biological, and radiologic data.

#### **Delayed puberty**

DP, which occurs in about 2% of girls, is defined as the lack of breast development at a chronological age  $>-2.5$  SD of the population mean age of pubertal onset. Family history of DP is present in up to 50% of parents or siblings. The clinical examination, along with endocrine, radiological, and genetic investigations, seeks to identify which girls will have permanent hypogonadism as opposed to those with transitory hypogonadism, who will undergo spontaneous but DP (constitutional delay of puberty and growth, CDGP).

Late puberty (congenital or acquired) is classified into three major groups: (Table 2):

- CDGP, when puberty occurs at the extreme end of the normal spectrum.

**Table 2**

Causes of delayed puberty.

- 
1. Constitutional delay in growth and puberty
  2. Hypogonadotropic hypogonadism
    - Functional hypogonadotropic hypogonadism
      - Chronic disease
      - Endocrine disease: hypothyroidism, GH deficiency, etc.
      - Hypothalamic amenorrhea: anorexia nervosa, competitive sports, and excess stress
    - Permanent hypogonadotropic hypogonadism
      - Isolated gonadotropic deficiency
        - Mutations of GnRH, GnRH-Rc, Kiss-1, Kiss-1-Rc, TAC3 neurokinin B, and TAC3-Rc
        - Kallmann syndrome: mutations of KAL1, FGF8, ProKr, and ProKr-Rc
      - Multiple pituitary hormone deficiency: mutations of HESX1, PROP-1, SOX-2, SOX-3, LH-X3, and LH-X4
      - Associated with genetic syndromes (Prader-Willi, Laurence-Moon, etc.)
  3. Hypergonadotropic hypogonadism
    - Congenital
      - XX-syndromic/non-syndromic
      - XO: ovarian dysgenesis
      - XY: DSD
    - Acquired
      - Radio-, chemotherapy
      - Chronic disease
      - Auto-immune disease
      - Environmental endocrine chemical disruptors
  4. Idiopathic
- 

- Hypogonadotropic hypogonadism, which can be transient because of an underlying medical condition or persistent because of a GnRH defect. Midline congenital defects, such as cleft lip and palate, and neural tube defect are suggestive of permanent hypogonadotropic hypogonadism.
- Hypergonadotropic hypogonadism due to gonadal failure.

In a retrospective study of clinical and laboratory data from 74 adolescent girls with DP, Sadlmeyer et al. [94] reported that the most common cause of DP in girls was CDGP (30%), the remaining subjects falling into four other categories:

- Functional hypogonadotropic hypogonadism (delayed but spontaneous pubertal development): 19%
- Permanent hypogonadotropic hypogonadism: 12%
- Permanent hypergonadotropic hypogonadism: 13%
- Unclassified causes: 5%.

Our experience on the causes of DP is reported in [Fig. 3](#).

Currently, 50 etiologies of DP have been identified by this group.

### Diagnosis of delayed puberty

Pubertal developmental should be evaluated by ([Fig. 4](#)):

- Detailed physical examination:
  - to identify the breast development stage, determine the growth velocity, measure the body proportion, and examine any dental abnormalities.
  - to determine the level of exercise, the degree of food restriction, the ability to smell, and the presence of neurological disorders.
  - to establish the presence/absence of pubic hair because presence is more likely associated with hypogonadotropic hypogonadism.
- Diagnosis of DP usually depends on hormonal, imaging, and genetic investigations [95].



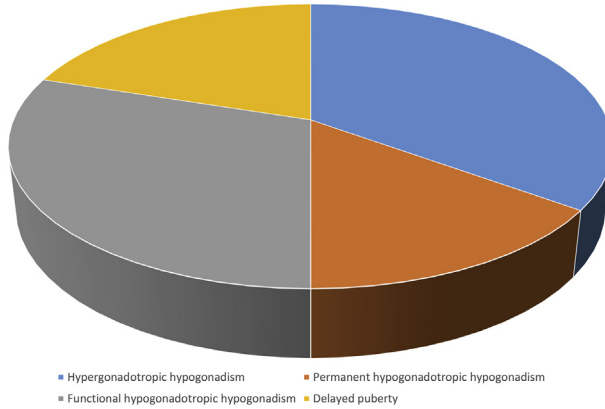


Fig. 3. Causes of delayed puberty (personal experience).

**Hormonal investigation**

In most cases, it is very difficult to distinguish patients with DP from those with hypogonadotropic hypogonadism. Basal levels of FSH and LH and levels after the GnRH stimulation test are low.

- In addition to plasma and stimulated LH and FSH plasma levels,
- Check free T4, TSH, and prolactin.

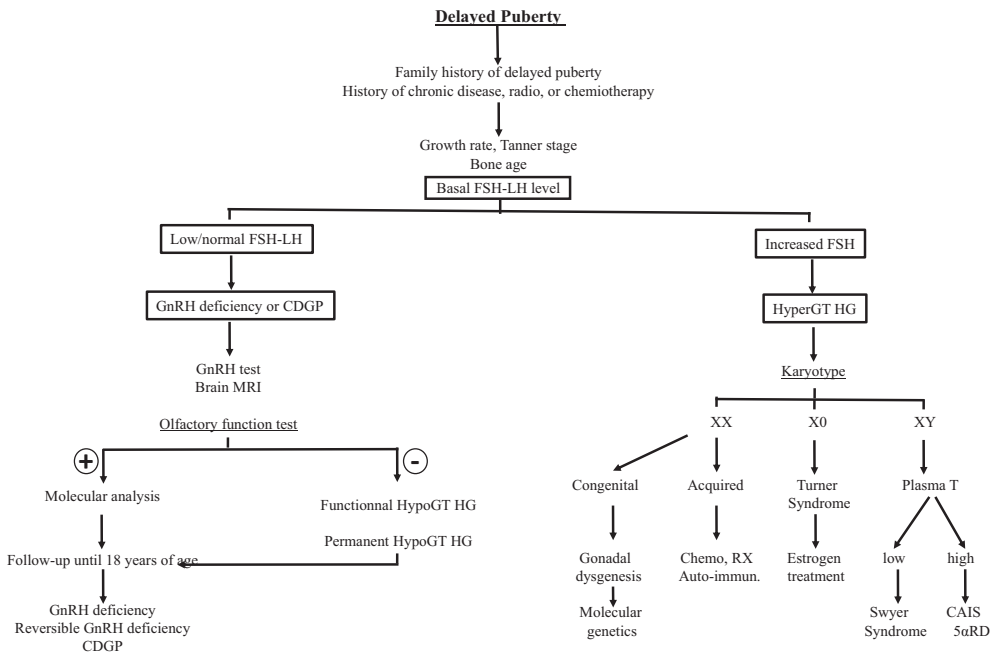


Fig. 4. Decisional tree for diagnosis of delayed puberty.

## Imaging

- A bone age <11 years is encountered in DP.
- Pelvic ultrasound:
  - gonads may be small or absent (in favor of hypergonadotropic hypogonadism);
  - ovarian volume >2 ml indicates a subnormal hypothalamic-pituitary-ovarian axis, as does uterine length >35 mm.
- Brain MRI should be performed to eliminate organic hypothalamic-pituitary disease or tumors.
- Osteodensitometry is helpful to evaluate the impact of estrogen deficiency on bone mineral density.

Karyotyping should be obtained in all patients with hypergonadotropic hypogonadism: it can reveal an XO, XX, or XY formula.

Molecular genetic analysis should be considered, depending on the clinical situation.

## Differential diagnosis

The physical findings provide clues for the differential diagnosis:

- Absence or presence of breast development indicates whether the production of estrogens is ongoing;
- Absence of pubic hair reveals a pituitary defect (corticotrophic axis) or insufficient androgen biosynthesis;
- Severe growth retardation should raise the suggestion of Turner syndrome (TS);
- Vaginal agenesis orients toward the Mayer-Rokitansky syndrome (when normal breast development and pubic hair are present) or an XY disorder of sex development (DSD) if breast development is subnormal.

## Constitutional delay of puberty

CDGP occurs in about 2% of girls, but the prevalence of CDGP may be underestimated. CDGP can be considered an extreme of the normal spectrum of pubertal timing but can be diagnosed only after the exclusion of other underlying conditions. The differential diagnosis of CDGP mainly includes congenital hypogonadotropic hypogonadism and transient or functional hypogonadotropic hypogonadism, where pubertal delay is because of maturational delay of the hypothalamo-pituitary-ovarian axis, secondary to an underlying cause.

CDGP is usually short stature, skeletal maturation is delayed, and height is compatible with bone age. A proportion of CDGP girls do not attain a height consistent with their target heights. Bone mineral density can be compromised, and the attainment of peak bone mass may be impaired.

Familial forms of CDGP suggest the involvement of genetic factors. In a recent report of 14 girls seen for CDGP with a familial component, Brauner et al. found exclusive maternal inheritance in 79% of the cases [96]. Maternal inheritance seems to be the major mode of transmission in these girls.

Several observations suggest that there are common pathophysiological mechanisms that associate self-limited DP and idiopathic hypogonadotropic hypogonadism (IHH). To determine whether the genetics of self-limited DP overlaps with those of IHH, Zhu et al. analyzed the potentially pathogenic variant of IHH genes in DP family members of an IHH proband and in DP individuals with no family history of IHH [97]. This group reported a significant genetic overlap between self-limited DP and IHH by identifying TAC3, TAC3R, and IL17RD as candidate DP genes. Thus, self-limited DP and IHH share an underlying pathophysiology in some cases.

Recently, Howard et al. reported ISGF10 mutations in DP. ISGF10 is an immunoglobulin superfamily member involved in GnRH neuronal migration in the nasal region [98]. Dysregulations of GnRH neuronal migration during embryologic development may thus result in DP.

Treatment may depend on the presence of breast development, chronological age, family preference, and psychosocial difficulties: estrogen therapy can be beneficial for adolescents who have decreased self-esteem and anxiety regarding fertility. Low-dose estrogen therapy (oral or transdermal

17 $\beta$ -estradiol) should be considered: small doses of 17 $\beta$ -estradiol (2 mg daily orally or 100 mcg/patch) are usually proposed for 6–12 months, if the patient expresses the desire.

### *Hypogonadotropic hypogonadism*

Hypogonadotropic hypogonadism may be congenital because of isolated FSH-LH deficiency or multiple gonadotropin deficiency. It may be secondary to acquired hypothalamic-pituitary disease. Hypothalamic-pituitary diseases include Kallmann syndrome, Prader-Willi syndrome, congenital hypopituitarism, and septo-optic dysplasia.

#### *Congenital hypogonadotropic hypogonadism*

Any type of hypogonadotropic hypogonadism can arise either as a complete form of the disease, in which all signs of puberty are absent, or as an incomplete form, in which partial functioning of the hypothalamo-pituitary pathway activity is reflected in some degrees of pubertal development.

The classic example of congenital hypogonadotropic hypogonadism is Kallmann syndrome, in which hypogonadism is characteristically accompanied by hypo or anosmia. Mutation in the KAL1 gene is responsible for the X chromosome recessive form, while mutations in other genes are responsible for the autosomal dominant form.

Hypogonadotropic hypogonadism can also manifest without any abnormalities of the sense of smell.

Hypogonadotropic hypogonadism, often revealed by pubertal delay, may be due to genetic abnormalities [99]. Recognizing these gene variations may improve our diagnosis capabilities:

- GnRH receptors, KISS1/KISS1R and TAC3/TACR3, should be the first genes to be screened in a clinical setting for equivocal cases such as DP versus IHH because they are the main causes of GnRH pulse generator defects.
- In Kallmann syndrome, genetic screening for particular genes should be prioritized depending on the association of specific clinical features: synkinesia (KAL1), dental agenesis (FGF8/FGFR1), bone anomalies (FGF8/FGFR1), and hearing loss (CHD7, SOX1). New genes have recently been identified, and the list of genes involved in hypogonadotropic hypogonadism is still growing.

Common or rare variants in IHH are GnRH, GnRH-R, FGF-R1, GPR-54, KAL1, KISS1, LEP, LEP-R, PROKR2, PROKR2, TAC-3, and TAC-R3.

More than 25 different genes have been implicated in congenital hypogonadotropic hypogonadism and/or Kallmann syndrome, which account for about 50% of cases [100].

### *Acquired hypogonadotropic hypogonadism*

*Tumoral.* Delayed maturation of the hypothalamic-pituitary-ovarian axis may be secondary to acquired hypothalamic-pituitary disease, such as

- brain tumor: craniopharyngioma, astrocytoma;
- infiltration diseases of the CNS: histiocytosis;
- chemo- or radiotherapy;
- hyperprolactinemia.

*Functional hypothalamic hypogonadism (transient).* The term functional hypogonadotropic hypogonadism refers to a reversible dysfunction on the hypothalamic-pituitary-ovarian axis.

Delayed maturation of the hypothalamic-pituitary-ovarian axis may be due to underlying conditions, such as

- chronic diseases: Crohn's disease, celiac disease, anemia, kidney disease, cystic fibrosis, and, more frequently, cardiopathies and immunodeficiency;
- endocrine diseases, such as growth hormone deficiency, hypothyroidism, Cushing syndrome;
- hypothalamic amenorrhea (HA):
  - o undernutrition, as observed in anorexia nervosa (AN). During puberty, some girls begin to be preoccupied with dieting for weight loss, which is reinforced by a vulnerability to sociocultural influences focused on body image and weight. Caloric restriction causes HA because of the reduction in GnRH pulse generator activity, which then causes low FSH and LH production. In our experience, low bone mineral density is the key issue of this triad [101]. Our group recently demonstrated that oral contraceptives partially protect from bone loss in adolescents with AN. HA has been traditionally viewed as a functional form of GnRH deficiency resulting from insufficient energy availability (excessive competitive sports, AN), psychological stress, or both. However, adolescents vary in their susceptibility to develop HA. To determine whether this susceptibility reflects genetic predisposition, Caronia et al. [102] analyzed the coding sequence of genes associated with IHH in adolescents with HA. Six heterozygous mutations were identified in 12% of patients: variants in the FGF receptor 1 gene (FGFR1) and the prokineticin receptor 2 gene (PROKR2), and one in the GnRH receptor gene and one in the Kallmann syndrome 1 sequence gene KAL1. This group demonstrated that patients with HA have mutations in genes regulating GnRH production and action.
  - o intensive and competitive sports. Female adolescent athletes involved in long-distance running, high-performance gymnastics, and other sports are at high risk to develop the so-called female athlete triad: drastic caloric restriction, amenorrhea (primary or secondary), and osteoporosis [101].

### *Hypergonadotropic hypogonadism*

There are four principal causes for hypergonadotropic hypogonadism:

- genetic and molecular abnormalities;
- immunological disorders;
- metabolic diseases;
- EDCs.

Hypergonadotropic hypogonadism may be congenital or acquired.

According to the karyotype, one can distinguish

- XX hypergonadotropic hypogonadism: premature ovarian insufficiency;
- XO hypergonadotropic hypogonadism: TS;
- XY hypergonadotropic hypogonadism: disorders of sex development.

### *XX karyotype*

Premature ovarian insufficiency (POI) is the common expression of hypergonadotropic hypogonadism. It affects about 1/10,000 adolescent girls and is characterized by severe estrogen deficiency due to ovarian dysgenesis, which can be congenital or acquired [103].

- Congenital hypergonadotropic hypogonadism

Several mechanisms have been considered, including a reduction in the number of oocytes or ovarian reserve, an increase in follicular destruction, or an alteration in follicular recruitment and maturation.

Regarding the congenital forms of POI, candidate genes on the X chromosome are FMR1, BMP15, AR, FOXO4, POF1B, DACH2, and PGRMC1.

Candidate genes on autosomes are FOXL2, GALT, AIRE, EIF2B, POLG, NOG, PMM2, HSD17B4, BCM, ATM, WRM, and PECQL4.

In addition, Perrault syndrome is characterized by ovarian failure associated with progressive deafness. It is related to a mutation of HSD17B4.

Other mutations have been identified by whole exome sequencing. Recently, Patino et al. used whole exome sequencing and, in 33 out of 69 patients, they identified 55 coding variants in 49 genes potentially related to POI and participating in ovarian function, such as meiosis, follicular development, granulosa cell differentiation, and ovulation. Interestingly, the presence of at least two mutations in distinct genes in half the patients is in favor of the polygenic nature of POI [104].

From a molecular view, it has been shown that hundreds of genes belonging to complex molecular cascades involved in the numerous steps from ovary determination to ovulation might contribute to POI etiology:

- ovary genes;
- meiosis genes;
- folliculogenesis and ovulation genes.

Routinely, the genetic causes of POI are related to FMR1, FMR2, BMP5, GDF9, LH-Rc, or FSH-Rc.

Some heterozygous mutations might be associated with a background of POI predisposition.

Next-generation sequencing has increased the number of mutations known to be involved in POI, and epigenetic research seems mandatory for a better understanding of POI.

#### - Acquired hypergonadotropic hypogonadism

POI may be acquired by ovarian exposure to radiation during treatment for abdominal malignancy, and it may become permanent. Total body irradiation during conditioning or prior to bone marrow transplant will be followed by secondary ovarian failure in about 50% of the cases. POI is a common late effect of cancer treatment and hematopoietic stem cell transplantation (HSCT). In adolescents, ovarian insufficiency may subsequently lead to delayed/absence of pubertal development. In a single study cohort of 109 female patients transplanted during childhood, a cumulative incidence of POI was found in 56% of adolescent girls at the median follow-up of 7.2 years. Interestingly, a more advanced pubertal stage at HSCT was associated with POI.

Autoimmune mechanisms are the cause of 14% of the POI, which usually occurs during adolescence. Associated disorders are alopecia, vitiligo, candidiasis, Addison's disease, Sjorgen's syndrome, and autoimmune polyendocrinopathy candidiasis ectodermal dystrophy.

Infiltration of the ovary with iron from multiple blood transfusions or with galactose metabolites induces ovarian fibrosis and progressive ovarian failure.

Galactosemia is caused by deficiency in galactose 1-P uridyl transferase (GALT). Ovarian failure is a common long-term effect in affected girls. It is likely that excess galactose toxicity impairs folliculogenesis and accelerates follicular atresia.

Metabolic defects and pre-/post-natal contamination by EDCs have also been related to POI.

*Premature ovarian insufficiency assessment.* Assessment of POI must include careful attention to growth parameters and patterns in the context of target height, history of health problems, chronic diseases, and past treatments such as chemotherapy, radiotherapy, or corticotherapy. The family history of pubertal timing must be considered, and clinical examination should differentiate pubertal absence from pubertal arrest.

The diagnosis of POI is devastating and has major emotional impact on most adolescent girls, with special concerns regarding its impact on fertility. These adolescents thus have a higher risk of major anxiety, depression, decreased self-esteem, and lower social insertion [105].

Management strategies [106] should aim to achieve adequate feminization, optimize bone mass acquisition, and reduce psychosocial and emotional disorders without compromising height attainment [107].

### Turner syndrome

TS is the most prevalent example of hypergonadotropic hypogonadism. Although 20% of TS patients will begin puberty spontaneously, only a small minority will progress to menarche. Delayed, arrested, and absent puberty are frequent clinical expressions of TS. In most TS cases, primary ovarian failure can be expected.

Clinical manifestations include linear growth failure, ovarian insufficiency, pubertal delay, and other disorders such as cardiovascular abnormalities, skeletal malformations, and hearing loss.

The type and frequency of chromosome abnormalities are as follows:

- 45, X: 40–50%
- 45, X/46, XX: 15–25%
- 45, X/46, XY: 10–12%
- 46, XiqY: 10%

However, the karyotype does not systematically predict the phenotype in an individual patient, although mosaicism is usually associated with a milder phenotype, pubertal progression, and even spontaneous menarche and pregnancy.

*Treatment.* Estrogen treatment should begin at 11–12 years, as soon as FSH increases.

There are various treatment protocols: estrogen therapy should be routinely initiated around the age of 12–13 years at a low dose (approximately, 1/10 of adult dose) and gradually increased over 2–4 years. Transdermal estrogens (patch or gel) seem more physiological.

Regardless of the estrogen form, route, and dose, it is also crucial to introduce appropriate estrogen therapy to prepare patients if they desire an assisted reproductive technology procedure.

Clinical practice guidelines for girls with TS were published on the basis of an international consensus meeting [108]. The main recommendations regarding induction of puberty were as follows:

1. Estrogen replacement should start between 11 and 12 years of age, increasing to adult dosing over 2–3 years. Doses can increase approximately every 6 months for a period of 2–3 years, until adult dosing is reached.
2. Low-dose estradiol is the preferred estrogen, and it should be administered by systemic route, although the transdermal route is often preferred.
3. Progesterone treatment should be started after 2 years of estrogen treatment or when bleeding occurs.
4. Very low doses of estrogen supplementation in the prepubertal years are not recommended.

### XY karyotype

46, XY DSD refers to 46, XY adolescents with under masculinization, leading in some cases to a female phenotype. The hormonal levels of T, AMH, FSH, and LH, and the presence of Mullerian derivatives noted by pelvic ultrasound, can differentiate gonadal dysgenesis (associated with insufficient gonadal secretion of T and AMH) from T production defects or androgen insensitivity.

#### 1 Gonadal dysgenesis

Gonadal dysgenesis is a genetic defect in testis determination characterized by a variable alteration in Leydig and Sertoli cell function. This disorder may be secondary to mutations in any of the several genes taking part in the differentiation process of the primitive gonad to a testis.

##### a SRY gene abnormalities

SRY gene abnormalities express with a clinical picture of 46, XY sex reversal with female phenotype. The diagnosis is made in the pubertal period in the context of DP (associated with primary amenorrhea). However, some patients may present partial pubertal development, often caused by an

association with a secreting gonadoblastoma. This picture of 46, XY sex reversal is associated with a SRY gene mutation in 20% of the cases.

#### b Abnormalities in other sex determination genes

About 80% of the cases of gonadal dysgenesis are not caused by a SRY gene abnormality. They may be secondary to abnormalities in the other genes that take part in testis determination, however, and are autosomal or X-linked.

Some cases of gonadal dysgenesis have been linked to SF1 gene mutation. This gene is involved in the development of male gonads and adrenal glands. The phenotype is variable, from female with isolated clitoral hypertrophy to adolescents with primary amenorrhea and hyperandrogenism. Adrenal insufficiency may be associated but is not commonly observed.

In some patients, gonadal dysgenesis is associated with renal dysfunction. In these cases, the diagnosis of Drash syndrome – defined as Wilms tumor associated with renal insufficiency – or Frasier syndrome – which is proteinuria secondary to focal glomerular sclerosis – may be made. Both syndromes are due to WT1 gene abnormalities that are nevertheless quite specific for each syndrome. In particular, heterozygous mutations in the open reading frame have been associated with Drash syndrome, while intron mutations leading to splicing abnormalities have been found in Frasier patients.

Sox9 gene abnormalities have been reported. Sox9 is a key gene in early male sex determination. Several mutations have been identified in patients with severe skeletal malformations such as campomelic dysplasia, associated in some cases with sex reversal and gonadal dysgenesis.

Homozygous or composite heterozygous mutations of the desert hedgehog gene, which is involved in testis differentiation and perineal development, have been identified. The phenotype is usually female, and a neuropathy may be associated.

## 2 Defects in testosterone production

Defects in T production are rare and characterized by variable degrees of external genital under-virilization. Conversely, no Mullerian derivatives are present because AMH is normally secreted by Sertoli cells. These defects are due to an enzymatic defect in T biosynthesis or they may be secondary to an LH receptor gene abnormality.

### Defect in 3-beta-hydroxysteroid dehydrogenase

This defect is associated with a variable but insufficient virilization of the 46, XY male, ranging from a female phenotype to minor forms of DSD. The biological and genetic investigations are the same as for 46, XX DSD.

### Defect of 17-alpha-hydroxylase

The phenotype in cases of a 17-alpha-hydroxylase defect may also be extremely variable. In some individuals, the diagnosis is made only during the pubertal period because of pubertal delay or stagnation. An excess of 11-deoxycorticosterone causes hypertension during puberty. The plasma levels of pregnenolone, progesterone, and corticosterone are elevated, which contrasts with the low values of T and D4 that are unresponsive to stimulation. The genetic abnormality concerns the CYP17 gene with recessive transmission.

### Defect of 17-beta-hydroxysteroid reductase

This is a rare testicular block that causes a deficit in testicular T production. The phenotype is more frequently female. The diagnosis is based on a considerable increase in plasma D4 level contrasting with a low T level. In these adolescents with female phenotype and DP with some breast development,

virilization occurs at puberty associated with gynecomastia. The mutation involves the 17 $\beta$ -HSD type 3 gene, which is expressed only in testis, and its transmission is recessive.

#### Leydig cell agenesis or hypoplasia

This is a rare form of 46, XY DSD, first identified in a patient with female phenotype associated with the 46, XY karyotype. She presented primary amenorrhea and no breast development at puberty, associated with low T at baseline and after hCG stimulation testing. The discrepancy between increased LH and normal FSH levels is generally evocative. This condition is determined by a homozygous or double heterozygous inactivating mutation of the LH receptor gene.

### 3 Androgen-resistance disorders

Androgen-resistance disorders are characterized by normal/high T and AMH production, in contrast to the under masculinization in 46, XY DSD. These disorders are represented by androgen receptor defect or 5 $\alpha$ -reductase deficiency.

#### a Complete Androgen insensitivity syndrome (CAIS)

Androgen insensitivity represents more than 50% of 46, XY DSD in our experience and is caused by a T receptor abnormality.

The diagnosis of CAIS is often made during the pubertal period, when primary amenorrhea is associated with normal breast development and sparse axillary, and pubic hair suggests this diagnosis. The adolescent also presents no acne, which is a further sign of no androgen action on target tissues.

The endocrine investigations performed in neonatal CAIS patients show high plasma T, along with a high LH level. An AR gene mutation confirms this diagnosis [109].

#### b 5 $\alpha$ -reductase deficiency

In the case of 5 $\alpha$ -reductase (5 $\alpha$ -R) deficiency, T is not converted to dihydrotestosterone (DHT), which is responsible for external genital virilization. The phenotype is usually female, but it may assume all degrees of undervirilization. If the diagnosis was not made in the neonatal period, it is usually made at puberty because of amenorrhea, absence of breast development, striking virilization including hirsutism, clitoral hypertrophy, significant muscle development, and masculinization in behavior. The hormonal investigations usually reveal an increased T/DHT ratio >10. The molecular investigation confirms the diagnosis by identifying a 5 $\alpha$ R2 gene mutation.

In conclusion, the XY adolescent referred for DP encompasses a wide variety of endocrine and genetic disorders. This complex situation requires a multidisciplinary team for diagnostic investigations, gender choice, treatment, and psychological management.

#### *Delayed puberty: treatment*

The goal of the treatment is to first ensure full pubertal development of sexual features, to reduce the psychological consequences of DP, and to achieve optimal bone mass.

Some authors propose a short-term test with a low dose of estrogen for 6–12 months (2–6 mg/day) [107]. Although there is no consensus about this procedure, we have followed this advice.

The overall goal of estrogen therapy in girls with hypogonadism is to start the development and maturation of secondary sexual characteristics and uterine growth and ensure normal growth velocity and bone mass acquisition.

Pubertal estrogen replacement therapy has mainly been based on each personal experience because there has no consensus regarding the estrogen drug, treatment route, dose and dosing time, or tempo.



### Practice points

- The onset of puberty is determined by genetic heritability and the neuroendocrine network, and it is modulated by metabolic factors and environmental endocrine disruptors.
- Clinical expression of PP is heterogeneous: besides the typical form of central PP that occurs below 8 years of age, there are several other clinical forms of central PP, incomplete puberty (premature thelache and premature pubarche), and peripheral precocious puberty (PPP), usually related to autonomous ovarian hyperactivity. Peripheral hyperestrogenization by environmental disruptors is increasing.
- Diagnosis of DP is difficult. The differential diagnosis of congenital and acquired hypogonadotropic hypogonadism with DP requires careful clinical, endocrine, radiological, and genetic investigation.

### Research agenda

- The mechanisms of the onset of puberty need further investigation.
- The exact role of endocrine disruptors in the development of PP should be further examined.
- The molecular genetics of PP must be developed.
- The treatment of PPP merits special research.
- The molecular genetics of DP should be amplified.

### Conflicts of Interests

None.

### Acknowledgments

None.

### References

- [1] Paris F, Gaspari L, Sultan C. Maturation of the hypothalamic–pituitary–ovarian axis and the onset of puberty. *Switzerland: Frontiers in Gynecological Endocrinology*; 2017. p. 57–66.
- [2] Leka-Emiri S, Chrousos GP, Kanaka-Gantenbein C. The mystery of puberty initiation: genetics and epigenetics of idiopathic central precocious puberty (ICPP). *J Endocrinol Invest* 2017;40(8):789–802.
- [3] Poursafa P, Ataei E, Kelishadi R. A systematic review on the effects of environmental exposure to some organohalogenes and phthalates on early puberty. *J Res Med Sci* 2015;20(6):613–8.
- [4] Abreu AP, Kaiser UB. Pubertal development and regulation. *Lancet Diabetes Endocrinol* 2016;4(3):254–64.
- [5] Walvoord EC. The timing of puberty: is it changing? Does it matter? *J Adolesc Health* 2010;47(5):433–9.
- [6] Day FR, Perry JR, Ong KK. Genetic regulation of puberty timing in humans. *Sci Rep* 2015;5: 11208.
- [7] Messina A, Langlet F, Chachlaki K, Roa J, Rasika S, Jouy N, et al. A microRNA switch regulates the rise in hypothalamic GnRH production before puberty. *Nat Neurosci* 2016;19(6):835–44.
- [8] Lomniczi A, Ojeda SR. The emerging role of epigenetics in the regulation of female puberty. *Endocr Dev* 2016;29:1–16.
- [9] Biro FM, Pinney SM, Schwartz RC, Huang B, Cattran AM, Haslam SZ. Amphiregulin as a novel serum marker of puberty in girls. - S1083-3188(17)30049-9 [pii] *J Pediatr Adolesc Gynecol* 2017;30(5):535–9. <https://doi.org/10.1016/j.jpjag.2017.02.003>.
- [10] Hagen CP, Sorensen K, Aksglaede L, Mouritsen A, Mieritz MG, Tinggaard J, et al. Pubertal onset in girls is strongly influenced by genetic variation affecting FSH action. *Sci Rep* 2014;4:6412.
- [11] Castellano JM, Tena-Sempere M. Metabolic control of female puberty: potential therapeutic targets. *Expert Opin Ther Targets* 2016;20(10):1181–93.
- [12] Burt Solorzano CM, McCartney CR. Obesity and the pubertal transition in girls and boys. *Reproduction* 2010;140(3): 399–410.
- [13] Manfredi-Lozano M, Roa J, Ruiz-Pino F, Piet R, Garcia-Galiano D, Pineda R, et al. Defining a novel leptin-melanocortin-kisspeptin pathway involved in the metabolic control of puberty. *Mol Metab* 2016;5(10):844–57.

- [14] Hillman JB, Huang B, Fau-Pinney SM, Pinney SM, Fau-Biro FM, Biro FM. Early pubertal development and insulin sensitivity among school-aged girls: mediation via adiposity. *J Pediatr Adolesc Gynecol* 2013;2651:47–50.
- [15] Euling SY, Selevan SG, Pescovitz OH, Skakkebaek NE. Role of environmental factors in the timing of puberty. *Pediatrics* 2008;121(Suppl. 3):S167–71.
- [16] Kempinas Wde G. Environmental factors in dysregulation of puberty timing and progression. *Reprod Toxicol* 2014;44:v–vi.
- [17] Harley KG, Rauch SA, Chevrier J, Kogut K, Parra KL, Trujillo C, et al. Association of prenatal and childhood PBDE exposure with timing of puberty in boys and girls. *Environ Int* 2017;100:132–8.
- [18] Dearthoff J, Fyfe M, Ekwaru JP, Kushi LH, Greenspan LC, Yen IH. Does neighborhood environment influence girls' pubertal onset? findings from a cohort study. *BMC Pediatr* 2012;12:27.
- [19] Chen CY, Chou YY, Wu Y-M, Wu YM, Lin C-C, Lin S-J, Lee C-C. Phthalates may promote female puberty by increasing kisspeptin activity. *Hum Reprod* 2013;28(10):2765–73.
- [20] Slyper AH. The pubertal timing controversy in the USA, and a review of possible causative factors for the advance in timing of onset of puberty. *Clin Endocrinol (Oxf)* 2006;65(1):1–8.
- [21] Juul A, Teilmann G, Scheike T, Hertel NT, Holm K, Laursen EM, et al. Pubertal development in Danish children: comparison of recent European and US data. *Int J Androl* 2006;29(1):247–55.
- [22] Kaplowitz P, Bloch C. Evaluation and referral of children with signs of early puberty. *Pediatrics* 2016;137(1). <https://doi.org/10.1542/peds.2015-3732>.
- [23] Brito VN, Spinola-Castro AM, Kochi C, Kopacek C, Silva PC, Guerra-Junior G. Central precocious puberty: revisiting the diagnosis and therapeutic management. *Arch Endocrinol Metab* 2016;60(2):163–72.
- [24] Sultan C, Gaspari L, Kalfa N, Paris F. Clinical expression of precocious puberty in girls. *Endocr Dev* 2012;22:84–100.
- [25] Brown DB, Loomba-Albrecht LA, Bremer AA. Sexual precocity and its treatment. *World J Pediatr* 2013;9(2):103–11.
- [26] Leger J, Carel CJ. Central precocious puberty: from diagnosis to treatment. Switzerland: *Frontiers in Gynecological Endocrinology*; 2017. p. 25–38.
- [27] Massart F, Seppia P, Pardi D, Lucchesi S, Meossi C, Gagliardi L, et al. High incidence of central precocious puberty in a bounded geographic area of northwest Tuscany: an estrogen disrupter epidemic? *Gynecol Endocrinol* 2005;20(2):92–8.
- [28] Styne DM. Puberty, obesity and ethnicity. *Trends Endocrinol Metab* 2004;15(10):472–8.
- [29] Mogensen SS, Aksglaede L, Mouritsen A, Sorensen K, Main KM, Gideon P, et al. Diagnostic work-up of 449 consecutive girls who were referred to be evaluated for precocious puberty. *J Clin Endocrinol Metab* 2011;96(5):1393–401.
- [30] Vestergaard ET, Schjorring ME, Kamperis K, Petersen KK, Rittig S, Juul A, et al. The follicle-stimulating hormone (FSH) and luteinizing hormone (LH) response to a gonadotropin-releasing hormone analogue test in healthy prepubertal girls aged 10 months to 6 years. *Eur J Endocrinol* 2017;176(6):747–53.
- [31] Giabicani E, Allali S, Durand A, Sommet J, Couto-Silva A-C, Brauner R. Presentation of 493 consecutive girls with idiopathic central precocious puberty: a single-center study. *PLoS One* 2013;8(7):70931.
- [32] Kumar M, Mukhopadhyay S, Dutta D. Challenges and controversies in diagnosis and management of gonadotropin dependent precocious puberty: an Indian perspective. *Indian J Endocrinol Metab* 2015;19(2):228–35.
- [33] Savas-Erdeve S, Siklar Z, Hacıhamdioglu B, Kocaay P, Camtosun E, Ocal G, et al. Gonadotropin-releasing hormone analogue treatment in females with moderately early puberty: no effect on final height. *J Clin Res Pediatr Endocrinol* 2016;8(2):211–7.
- [34] Ibanez L, Diaz R, Lopez-Bermejo A, Marcos MV. Clinical spectrum of premature pubarche: links to metabolic syndrome and ovarian hyperandrogenism. *Rev Endocr Metab Disord* 2009;10(1):63–76.
- [35] Shin YL. An update on the genetic causes of central precocious puberty. *Ann Pediatr Endocrinol Metab* 2016;21(2):66–9.
- [36] Kim EY, Lee MI. Psychosocial aspects in girls with idiopathic precocious puberty. *Psychiatr Investig* 2012;9(1):25–8.
- [37] Mendle J, Turkheimer E, Emery RE. Detrimental psychological outcomes associated with early pubertal timing in adolescent girls. *Dev Rep* 2007;27(2):151–71.
- [38] Kaltiala-Heino R, Kosunen E, Rimpela M. Pubertal timing, sexual behaviour and self-reported depression in middle adolescence. *J Adolesc* 2003;26(5):531–45.
- [39] Mensah FK, Bayer JK, Wake M, Carlin JB, Allen NB, Patton GC. Early puberty and childhood social and behavioral adjustment. *J Adolesc Health* 2013;53(1):118–24.
- [40] Copeland W, Shanahan L, Miller S, Costello EJ, Angold A, Maughan B. Outcomes of early pubertal timing in young women: a prospective population-based study. *Am J Psychiatry* 2010;167(10):1218–25.
- [41] Brauner R. Paediatric endocrinology: treatment of girls with central precocious puberty. *Nat Rev Endocrinol* 2015;11(7):386–7.
- [42] Carel JC, Eugster EA, Rogol A, Ghizzoni L, Palmert MR, Antoniazzi F, et al. Consensus statement on the use of gonadotropin-releasing hormone analogs in children. *Pediatrics* 2009;123(4):752–62.
- [43] Lien L, Haavet OR, Dalgard F. Do mental health and behavioural problems of early menarche persist into late adolescence? A three year follow-up study among adolescent girls in Oslo, Norway. *Soc Sci Med* 2010;71(3):529–33.
- [44] Latronico AC, Brito VN, Carel JC. Causes, diagnosis, and treatment of central precocious puberty. *Lancet Diabetes Endocrinol* 2016;4(3):265–74.
- [45] Lazar L, Leventhal Y, Yackobovitch-Gavan M, Shalitin S, de Vries L, Phillip M, et al. Treated and untreated women with idiopathic precocious puberty: BMI evolution, metabolic outcome, and general health between third and fifth decades. *Clin Endocrinol* 2014;80(4):570–6.
- [46] Guaraldi F, Beccuti G, Gori D, Ghizzoni L. MANAGEMENT OF ENDOCRINE DISEASE: long-term outcomes of the treatment of central precocious puberty. *Eur J Endocrinol* 2016;174(3):79–87.
- [47] Mantovani A, Fucic A. Puberty dysregulation and increased risk of disease in adult life: possible modes of action. *Reprod Toxicol* 2014;44:15–22.
- [48] Tremblay L, Frigon JY. Precocious puberty in adolescent girls: a biomarker of later psychosocial adjustment problems. *Child Psychiatry Hum Dev* 2005;36(1):73–94.
- [49] Wang M, Zhang Y, Lan D, Hill JW. The efficacy of GnRHa alone or in combination with rhGH for the treatment of Chinese children with central precocious puberty. *Sci Rep* 2016;13(6). 24259.

- [50] Willemsen RH, Elleri D, Williams RM, Ong KK, Dunger DB. Pros and cons of GnRHa treatment for early puberty in girls. *Nat Rev Endocrinol* 2014;10(6):352–63.
- [51] Osterbrand M, Fors H, Allvin K, Norjavaara E. 17beta-estradiol and gonadotropin levels for the diagnosis of the benign form of breast development in girls aged up to 4 Years in real-life clinical practice. *Horm Res Ped* 2017;87(5):315–23.
- [52] Takakuwa S. Premature thelarche in later childhood demonstrates a pubertal response to GnRH stimulation test at one year after breast development. *Clin Pediatr Endocrinol* 2011;20(4):81–7.
- [53] de Vries L, Guz-Mark A, Lazar L, Reches A, Phillip M. Premature thelarche: age at presentation affects clinical course but not clinical characteristics or risk to progress to precocious puberty. *J Pediatr* 2010;156(3):466–71.
- [54] de Vries L, Horev G, Schwartz M, Phillip M. Ultrasonographic and clinical parameters for early differentiation between precocious puberty and premature thelarche. *Eur J Endocrinol* 2006;154(6):891–8.
- [55] Bizzarri C, Spadoni GI, Bottaro G, Montanari G, Giannone G, Cappa M, et al. The response to gonadotropin releasing hormone (GnRH) stimulation test does not predict the progression to true precocious puberty in girls with onset of premature thelarche in the first three years of life. *J Clin Endocrinol Metab* 2014;99(2):433–9.
- [56] Deodati A, Sallemi A, Maranghi F, Germani D, Puglianiello A, Baldari F, et al. Serum levels of polybrominated diphenyl ethers in girls with premature thelarche. *Horm Res Ped* 2016;86(4):233–9.
- [57] Paris F, Gaspari L, Servant N, Philibert P, Sultan C. Increased serum estrogenic bioactivity in girls with premature thelarche: a marker of environmental pollutant exposure? *Gynecol Endocrinol* 2013;29(8):788–92.
- [58] Asci A, Durmaz E, Erkekoglu P, Pasli D, Bircan I, Kocer-Gumusel B. Urinary zearalenone levels in girls with premature thelarche and idiopathic central precocious puberty. *Minerva Pediatr* 2014;66(6):571–8.
- [59] Chou YY, Huang PC, Lee C-C, Wu M-H, Lin S-J. Phthalate exposure in girls during early puberty. *J Pediatr Endocrinol Metab* 2009;22(1):69–77.
- [60] Colon I, Caro D, Bourdony CJ, Rosario O. Identification of phthalate esters in the serum of young Puerto Rican girls with premature breast development. *Environ Health Perspect* 2000;108(9):895–900.
- [61] Lomenick JP, Calafat AM, Melguizo Castro MS, Mier R, Stenger P, Foster MB, et al. Phthalate exposure and precocious puberty in females. *J Pediatr* 2010;156(2):221–5.
- [62] McKee RH. Phthalate exposure and early thelarche. *Environ Health Perspect* 2004;112(10):541–3.
- [63] DeSalvo DJ, Mehra R, Vaidyanathan P, Kaplowitz PB. In children with premature adrenarche, bone age advancement by 2 or more years is common and generally benign. *J Pediatr Endocrinol Metab* 2013;26(3–4):215–21.
- [64] Mantyselka A, Jaaskelainen J, Lindi V, Viitasalo A, Tompuri T, Voutilainen R, et al. The presentation of adrenarche is sexually dimorphic and modified by body adiposity. *J Clin Endocrinol Metab* 2014;99(10):3889–94.
- [65] Utriainen P, Laakso S, Liimatta J, Jaaskelainen J, Voutilainen R. Premature adrenarche—a common condition with variable presentation. *Horm Res Paediatr* 2015;83(4):221–31.
- [66] Voutilainen R, Jaaskelainen J. Premature adrenarche: etiology, clinical findings, and consequences. *J Steroid Biochem Mol Biol* 2015;145:226–36.
- [67] Leung AK, Robson WL. Premature adrenarche. *J Pediatr Health Care* 2008;22(4):230–3.
- [68] Idkowiak J, Lavery GG, Dhir V, Barrett TG, Stewart PM, Krone N, et al. Premature adrenarche: novel lessons from early onset androgen excess. *Eur J Endocrinol* 2011;165(2):189–207.
- [69] Oberfield SE, Sopher AB, Gerken AT. Approach to the girl with early onset of pubic hair. *J Clin Endocrinol Metab* 2011;96(6):1610–22.
- [70] Kousta E. Premature adrenarche leads to polycystic ovary syndrome? Long-term consequences. *Ann N Y Acad Sci* 2006;1092:148–57.
- [71] Ibanez L, Dimartino-Nardi J, Potau N, Saenger P. Premature adrenarche—normal variant or forerunner of adult disease? *Endocr Rev* 2000;21(6):671–96.
- [72] Zadik Z. Premature adrenarche: not always benign? *J Pediatr Endocrinol Metab* 2013;26(3–4):195.
- [73] Biro FM, Huang B, Daniels SR, Lucky AW. Pubarche as well as thelarche may be a marker for the onset of puberty. *J Pediatr Adolesc Gynecol* 2008;21(6):323–8.
- [74] Paris F, Kalfa N, Philibert P, Jeandel C, Gaspari L, Sultan C. Very premature pubarche in girls is not a pubertal variant. *Horm (Athens)* 2012;11(3):356–60.
- [75] Bordini B, Littlejohn E, Rosenfield RL. LH dynamics in overweight girls with premature adrenarche and slowly progressive sexual precocity. *Int J Pediatr Endocrinol* 2010. <https://doi.org/10.1155/2010/724696>. 724696 [pii].
- [76] Aydin BK, Saka N, Bas F, Yilmaz Y, Haliloglu B, Guran T, et al. Evaluation and treatment results of ovarian cysts in childhood and adolescence: a multicenter, retrospective study of 100 patients. *J Pediatr Adolesc Gynecol* 2017;30(4):449–55.
- [77] Merckx M, Weyers S, Santegoeds R, De Schepper J. Menstrual-like vaginal bleeding in prepubertal girls: an unexplained condition. *Facts Views Vis Obgyn* 2011;3(4):267–70.
- [78] Sultan C, G L, Kalfa N, Paris F. Management of peripheral precocious puberty in girls. Switzerland: *Frontiers in Gynecological Endocrinology*; 2017. p. 39–48.
- [79] Schoelwer M, Eugster EA. Treatment of peripheral precocious puberty. *Endocr Dev* 2016;29:230–9.
- [80] Roy JR, Chakraborty S, Chakraborty TR. Estrogen-like endocrine disrupting chemicals affecting puberty in humans—a review. *Med Sci Monit* 2009;15(6):137–45.
- [81] Lumbroso S, Paris F, Sultan C. Activating galpha mutations: analysis of 113 patients with signs of McCune-Albright syndrome—a European Collaborative Study. *J Clin Endocrinol Metab* 2004;89(5):2107–13.
- [82] Fleming NA, de Nanassy J, Lawrence S, Black AY. Juvenile granulosa and theca cell tumor of the ovary as a rare cause of precocious puberty: case report and review of literature. *J Pediatr Adolesc Gynecol* 2010;23(4):127–31.
- [83] Sivasankaran S, Itam P, Ayensu-Coker L, Sanchez J, Egler RA, Anderson ML, et al. Juvenile granulosa cell ovarian tumor: a case report and review of literature. *J Pediatr Adolesc Gynecol* 2009;22(5):114–7.
- [84] Kalfa N, Veitia RA, Benayoun BA, Boizet-Bonhoure B, Sultan C. The new molecular biology of granulosa cell tumors of the ovary. *Genome Med* 2009;1(8):81.
- [85] Shi H, Cao Y, Shen Q, Zhao Y, Zhang Z, Zhong Y. Association between urinary phthalates and pubertal timing in Chinese adolescents. *J Epidemiol* 2015;25(9):574–82.

- [86] Wen Y, Liu SD, Lei X, Ling YS, Luo Y, Liu Q. Association of PAEs with precocious puberty in children: a systematic review and meta-analysis. *Int J Environ Res Public Health* 2015;12(12):15254–68.
- [87] Ye X, Pan W, Zhao Y, Zhao S, Zhu Y, Liu W, et al. Association of pyrethroids exposure with onset of puberty in Chinese girls. *Environ Pollut* 2017;227:606–12.
- [88] Yum T, Lee S, Kim Y. Association between precocious puberty and some endocrine disruptors in human plasma. *J Environ Sci Health* 2013;48(8):912–7.
- [89] Paris F, G L, Sultan C. Precocious puberty and environmental endocrine disruptors. *Early Puberty* (Springer); 2016. p. 9–20.
- [90] Gaspari L, Paris F, Jeandel C, Sultan C. Peripheral precocious puberty in a 4-month-old girl: role of pesticides? *Gynecol Endocrinol* 2011;27(9):721–4.
- [91] Wolff MS, Teitelbaum SL, McGovern K, Windham GC, Pinney SM, Galvez M, et al. Phthalate exposure and pubertal development in a longitudinal study of US girls. *Hum Reprod* 2014;29(7):1558–66.
- [92] Gaspari L, Morcrette E, Jeandel C, Valé FD, Paris F, Sultan C. Dramatic rise in the prevalence of precocious puberty in girls over the past 20 years in the south of France. *Horm Res Ped* 2014;82:291–2.
- [93] Somod ME, Vestergaard ET, Kristensen K, Birkebaek NH. Increasing incidence of premature thelarche in the Central Region of Denmark - challenges in differentiating girls less than 7 years of age with premature thelarche from girls with precocious puberty in real-life practice. *Int J Pediatr Endocrinol* 2016;4.
- [94] Sedlmeyer IL, Palmert MR. Delayed puberty: analysis of a large case series from an academic center. *J Clin Endocrinol Metab* 2002;87(4):1613–20.
- [95] Wei C, Crowne EC. Recent advances in the understanding and management of delayed puberty. *Arch Dis Child* 2016; 101(5):481–8.
- [96] Winter S, Ousidhoum A, McElreavey K, Brauner R. Constitutional delay of puberty: presentation and inheritance pattern in 48 familial cases. *BMC Pediatr* 2016;16:37.
- [97] Zhu J, Choa RE, Guo MH, Plummer L, Buck C, Palmert MR, et al. A shared genetic basis for self-limited delayed puberty and idiopathic hypogonadotropic hypogonadism. *J Clin Endocrinol Metab* 2015;100(4):646–54.
- [98] Howard SR, Guasti L, Ruiz-Babot G, Mancini A, David A, Storr HL, et al. IGSF10 mutations dysregulate gonadotropin-releasing hormone neuronal migration resulting in delayed puberty. *EMBO Mol Med* 2016;8(6):626–42.
- [99] Boehm U, Bouloux PM, Dattani MT, de Roux N, Dode C, Dunkel L, et al. Expert consensus document: European Consensus Statement on congenital hypogonadotropic hypogonadism—pathogenesis, diagnosis and treatment. *Nat Rev Endocrinol* 2015;11(9):547–64.
- [100] Bonomi M, Vezzoli V, Krausz CG, Guizzardi F, Vezzani S, Simoni M, et al. Characteristics of a nationwide cohort of patients presenting with Isolated Hypogonadotropic Hypogonadism (IHH). *EJE-17-0065* [pii]. *Eur J Endocrinol* 2018 Jan;178(1): 23–32. <https://doi.org/10.1530/EJE-17-0065>. Epub 2017 Sep 7.
- [101] Maimoun L, Guillaume S, Lefebvre P, Philibert P, Bertet H, Picot M-C, et al. Role of sclerostin and dickkopf-1 in the dramatic alteration in bone mass acquisition in adolescents and young women with recent anorexia nervosa. *J Clin Endocrinol Metab* 2014;99(4):582–90.
- [102] Caronia LM, Martin C, Welt CK, Sykiotis GP, Quinton R, Thambundit A, et al. A genetic basis for functional hypothalamic amenorrhea. *N Engl J Med* 2011;364(3):215–25.
- [103] Cox L, Liu JH. Primary ovarian insufficiency: an update. *Int J Womens Health* 2014;6:235–43.
- [104] Patiño LC, Beau I, Carlosama C, Buitrago JC, González R, Suárez CF, et al. New mutations in non-syndromic primary ovarian insufficiency patients identified via whole-exome sequencing. *Hum Reprod* 2017;13:1–9.
- [105] Kanj RV, Ofei-Tenkorang NA, Altaye M, Gordon CM. Evaluation and management of primary ovarian insufficiency in adolescents and young adults. *J Pediatr Adolesc Gynecol* Aug 4 2017;3:30314–5. <https://doi.org/10.1016/j.jpag.2017.07.005>. S1083-3188(17)30314-5 [pii].
- [106] Zacharin M. Pubertal induction in hypogonadism: current approaches including use of gonadotrophins. *Best Pract Res Clin Endocrinol Metab* 2015;29(3):367–83.
- [107] Dunkel L, Quinton R. Transition in endocrinology: induction of puberty. *Eur J Endocrinol* 2014;170(6):R229–39.
- [108] Gravholt CH, Andersen NH, Conway GS, Dekkers OM, Geffner ME, Klein KO, et al. Clinical practice guidelines for the care of girls and women with Turner syndrome: proceedings from the 2016 Cincinnati International Turner Syndrome Meeting. *Eur J Endocrinol* 2017;177(3):1–70.
- [109] Sultan C, Gaspari L, Audran F, Maimoun L, Kalfa N, Paris F. Androgen insensitivity syndrome. *Academic Press Genet Steroid Disord* 2013:225–37.