



Departamento
de Anatomía y Medicina Legal

FACULTAD DE MEDICINA
UNIVERSIDAD DE CHILE

MEDIASTINO

Christian Arriagada Abarzúa, TM MsCs
Departamento de Anatomía y Medicina Legal
Facultad de Medicina
Universidad de Chile

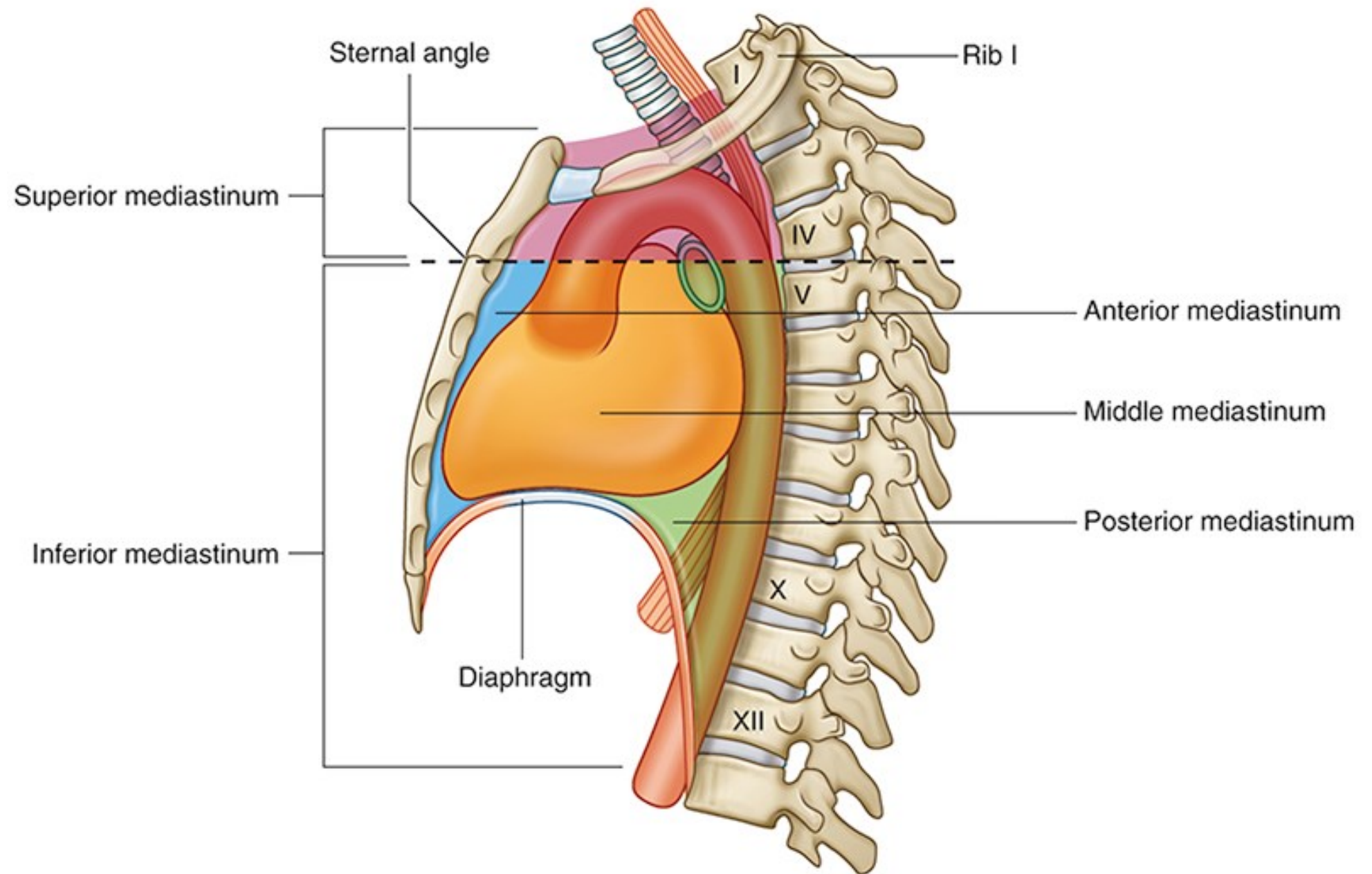
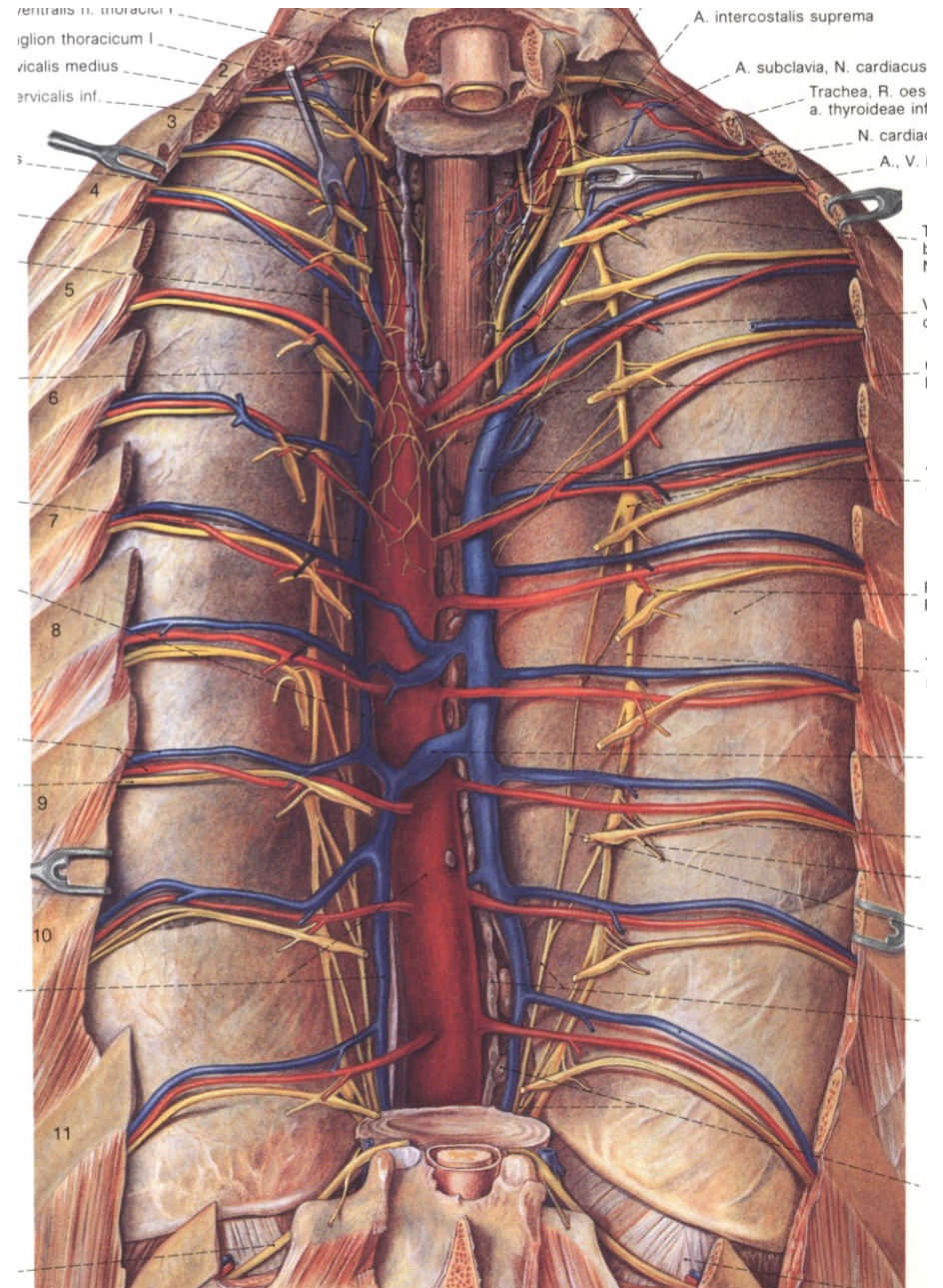
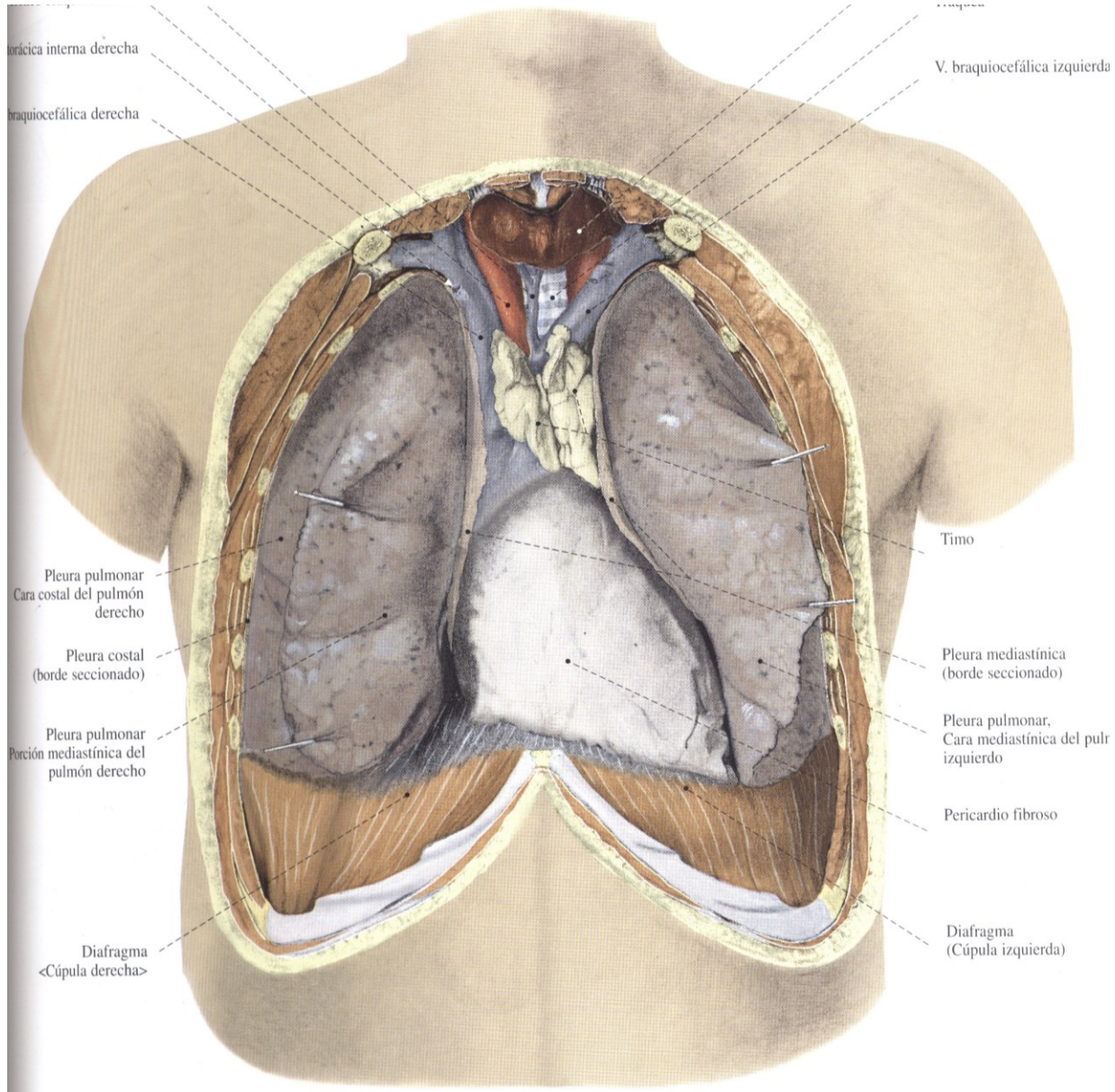


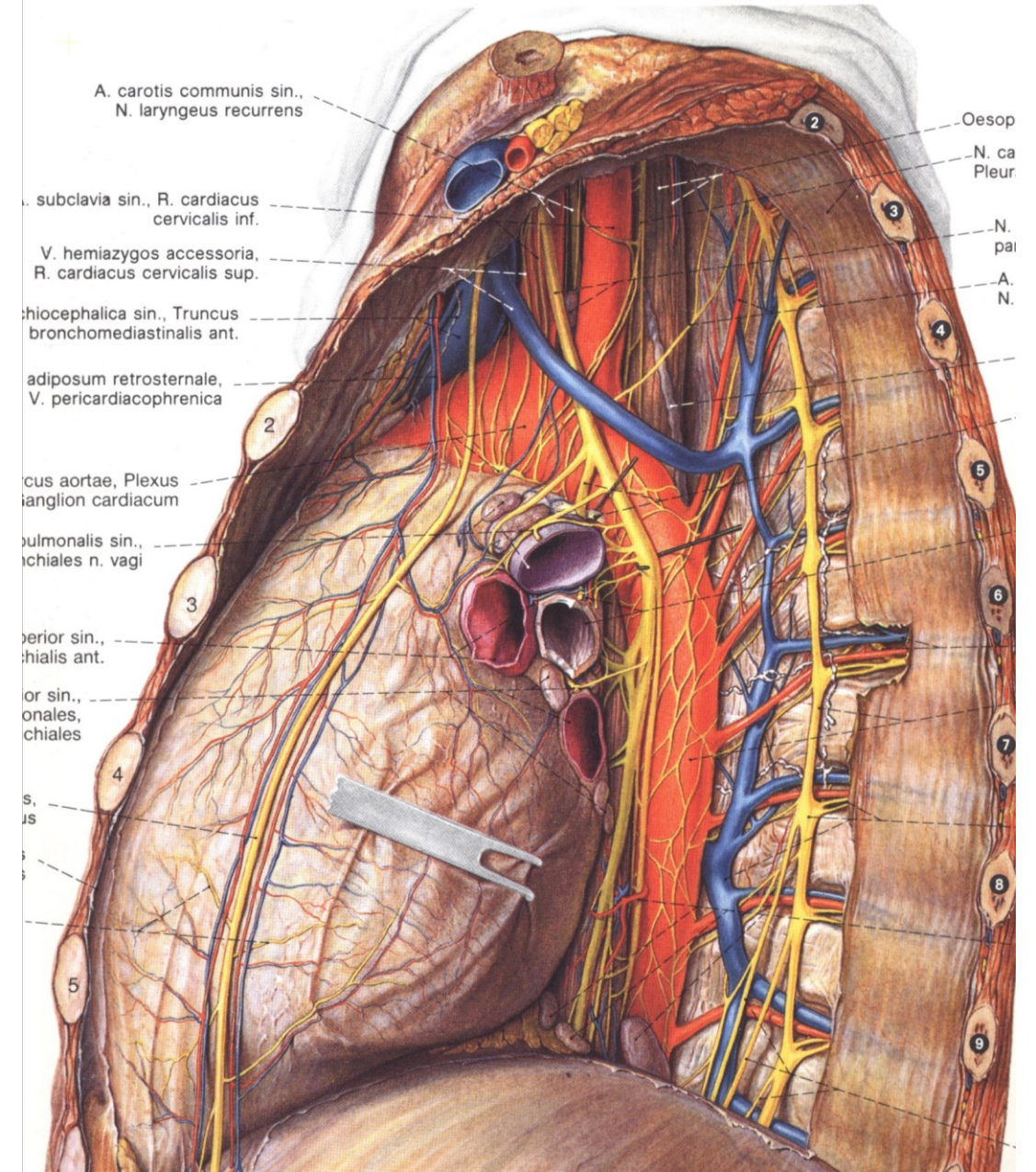
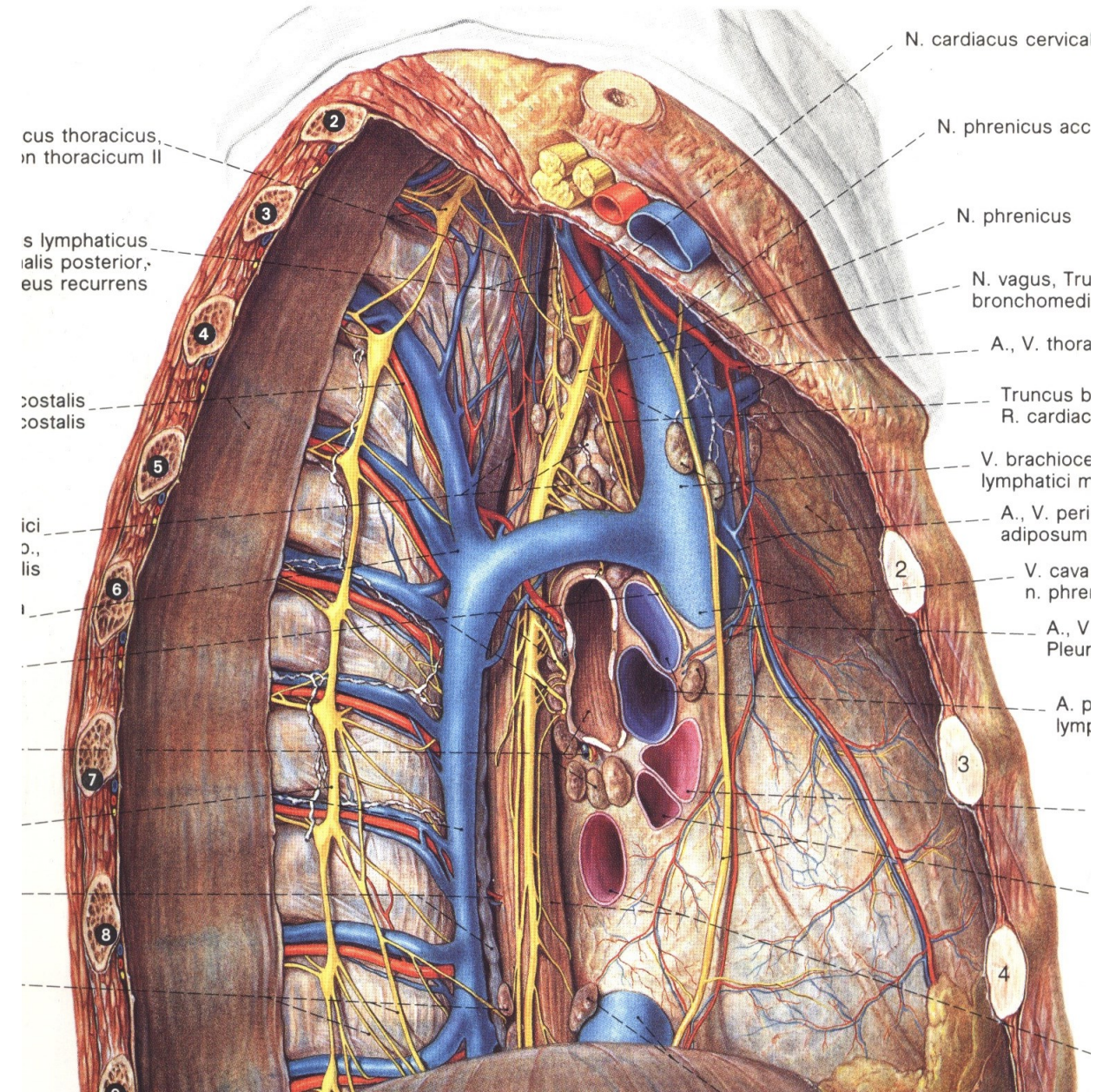


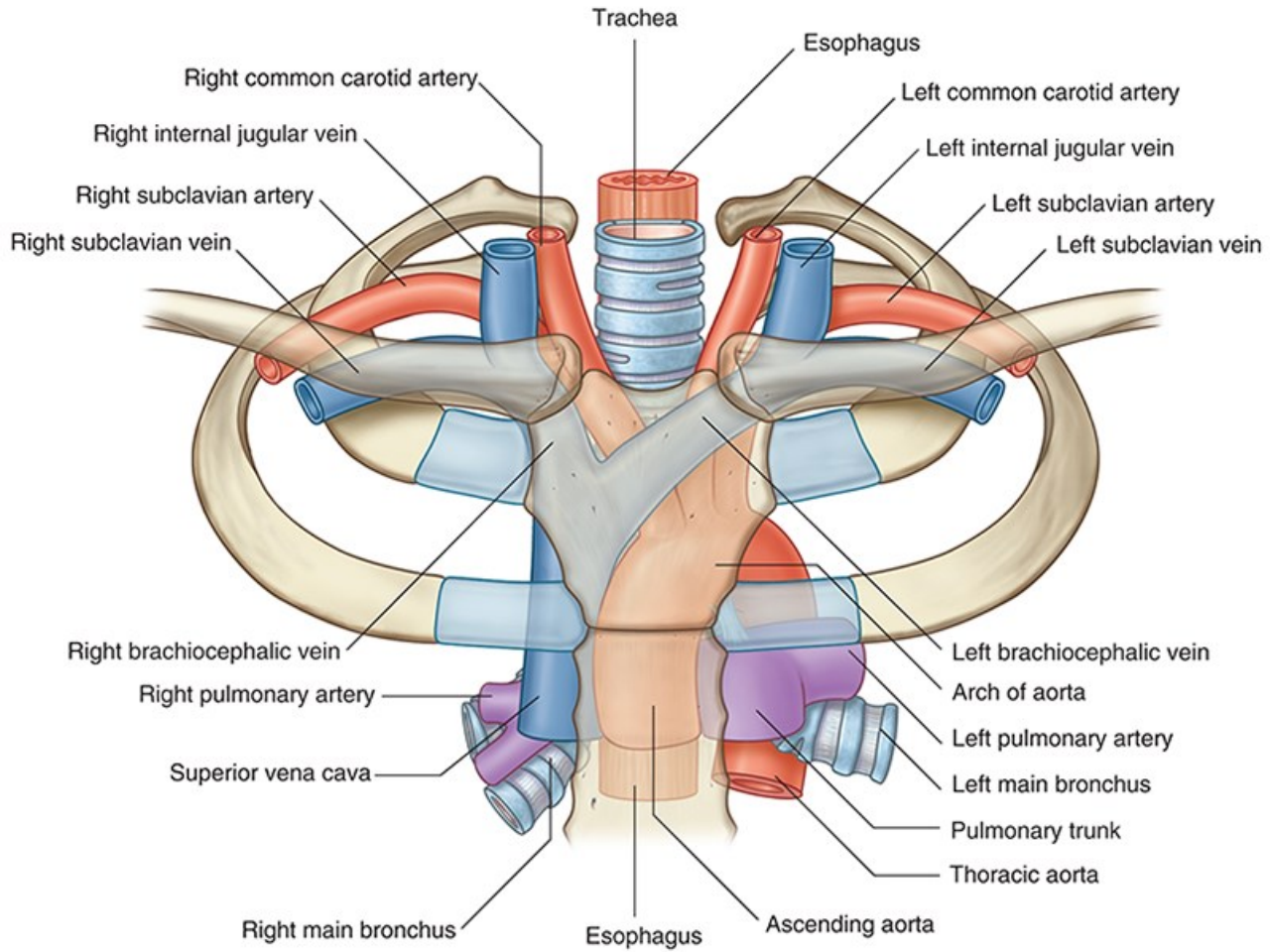
Table 7.1

Contents of the mediastinum

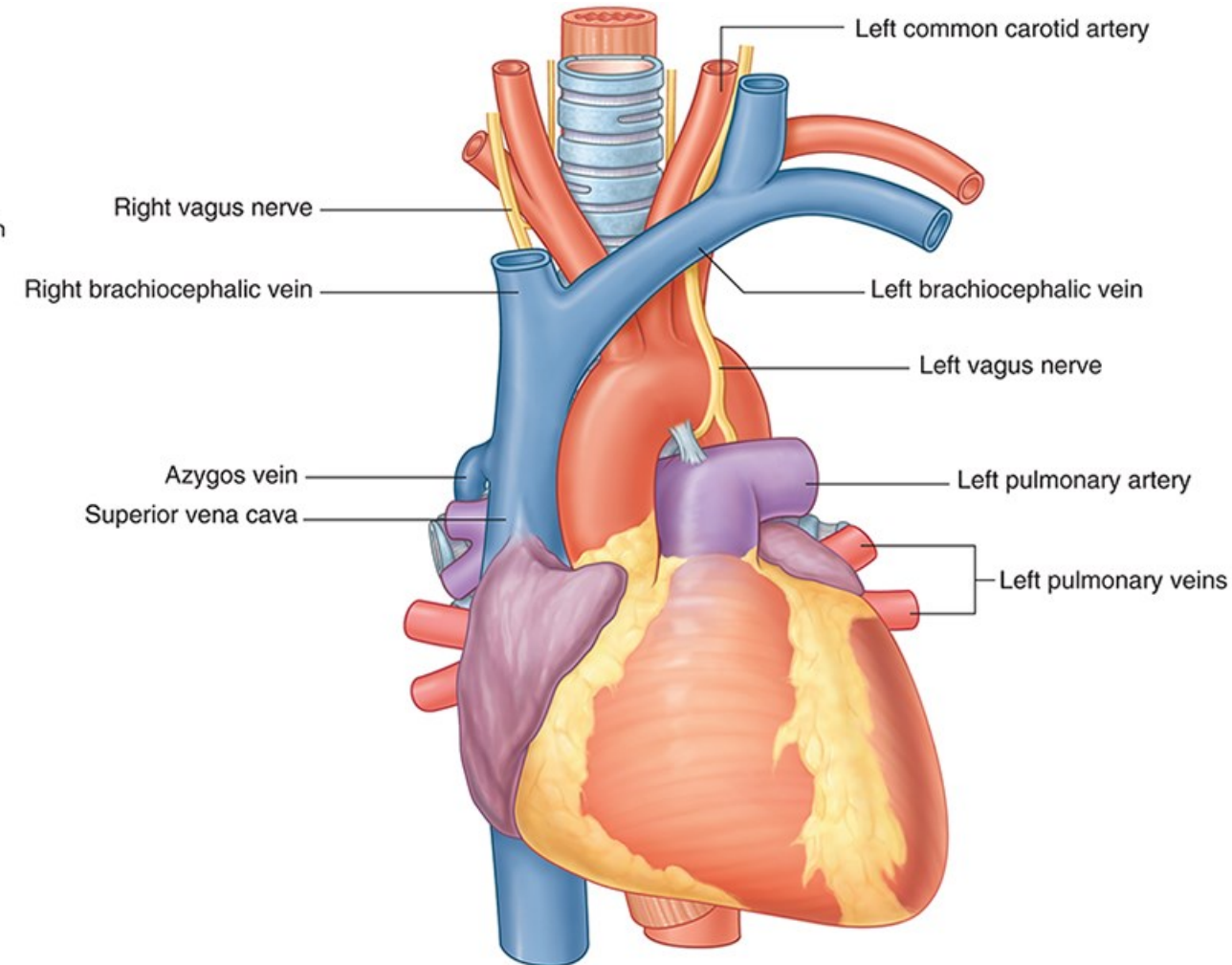
	Superior mediastinum	Inferior mediastinum		
		<i>Anterior</i>	<i>Middle</i>	<i>Posterior</i>
Organs	<ul style="list-style-type: none"> • Thymus • Trachea • Esophagus 	<ul style="list-style-type: none"> • Thymus (in children, see Fig. 7.5) 	<ul style="list-style-type: none"> • Heart • Pericardium 	<ul style="list-style-type: none"> • Esophagus
Arteries	<ul style="list-style-type: none"> • Aortic arch • Brachiocephalic trunk • Left common carotid a. • Left subclavian a. 	<ul style="list-style-type: none"> • Smaller vessels 	<ul style="list-style-type: none"> • Ascending aorta • Pulmonary trunk and branches • Pericardiacophrenic aa. and vv. 	<ul style="list-style-type: none"> • Thoracic aorta and branches
Veins and lymph vessels	<ul style="list-style-type: none"> • Superior vena cava • Brachiocephalic vv. • Thoracic duct 	<ul style="list-style-type: none"> • Smaller vessels, lymphatics, and lymph nodes 	<ul style="list-style-type: none"> • Superior vena cava • Azygos v. • Pulmonary vv. • Pericardiacophrenic aa. and vv. 	<ul style="list-style-type: none"> • Azygos v. • Hemiazygos v. • Thoracic duct
Nerves	<ul style="list-style-type: none"> • Vagus nn. • Left recurrent laryngeal n. • Cardiac nn. • Phrenic nn. 	<ul style="list-style-type: none"> • None 	<ul style="list-style-type: none"> • Phrenic nn. 	<ul style="list-style-type: none"> • Vagus nn.



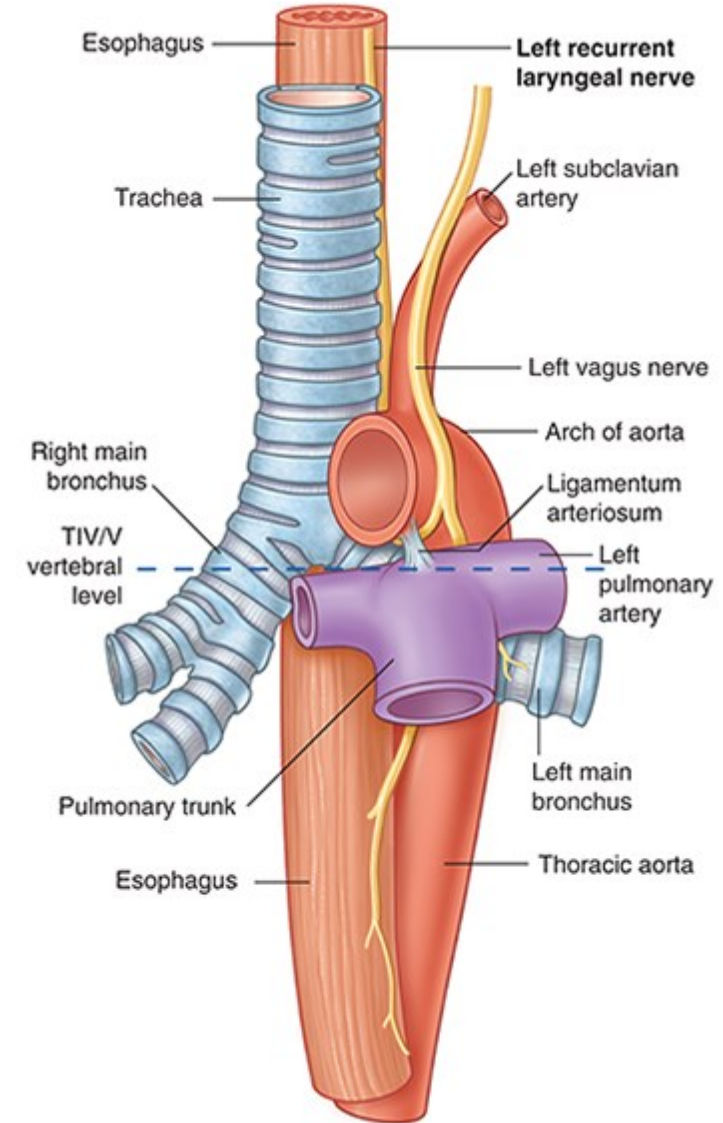
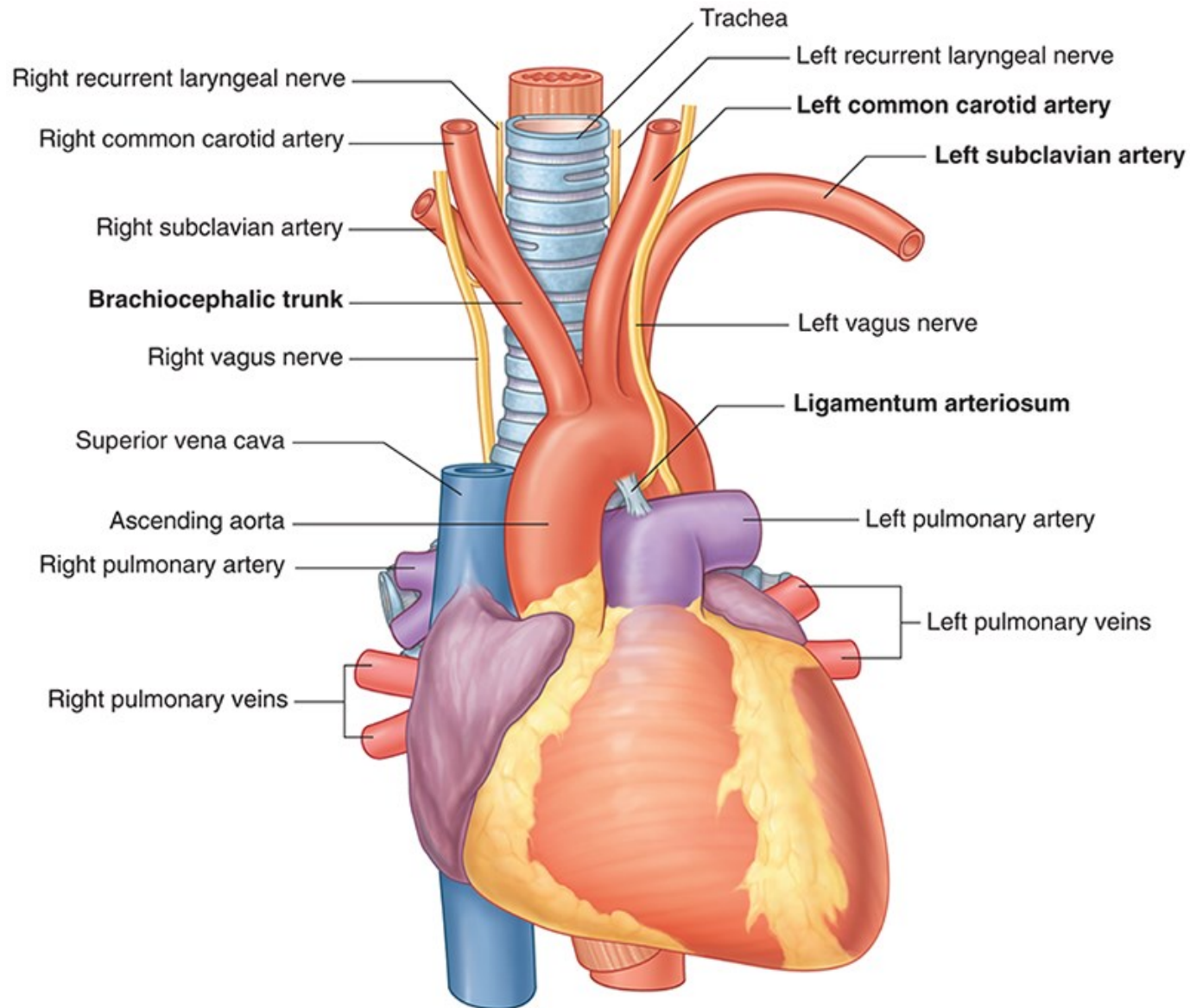


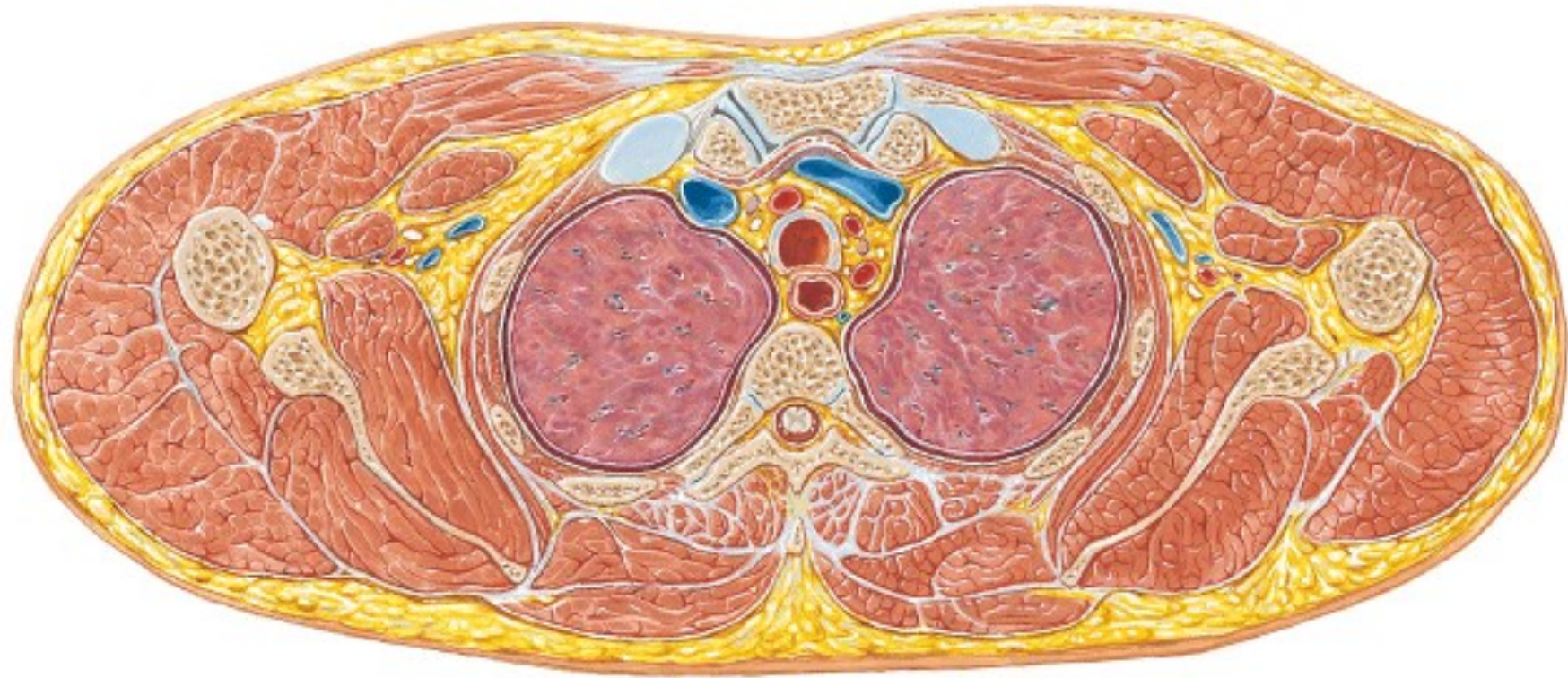


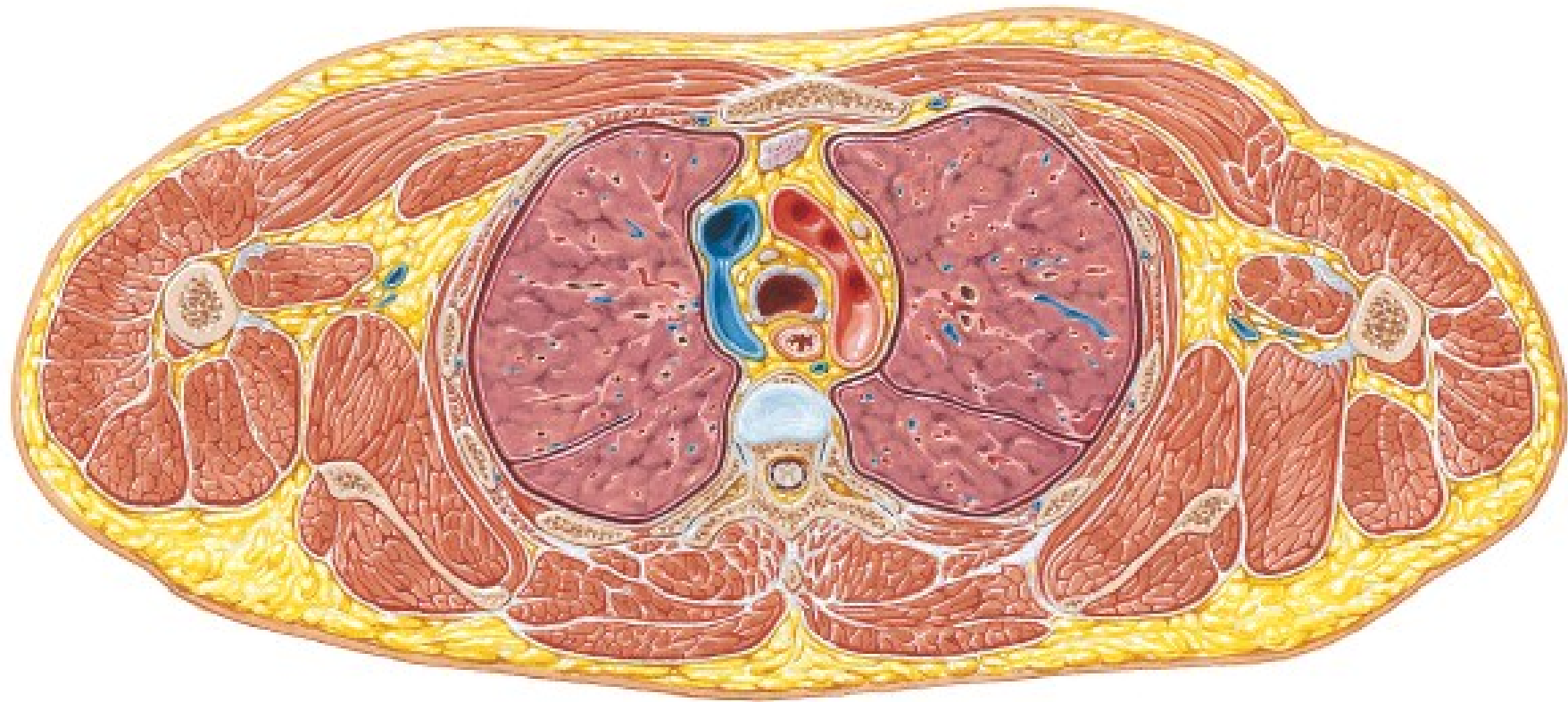
Copyright © 2020 Elsevier Inc. All rights reserved.

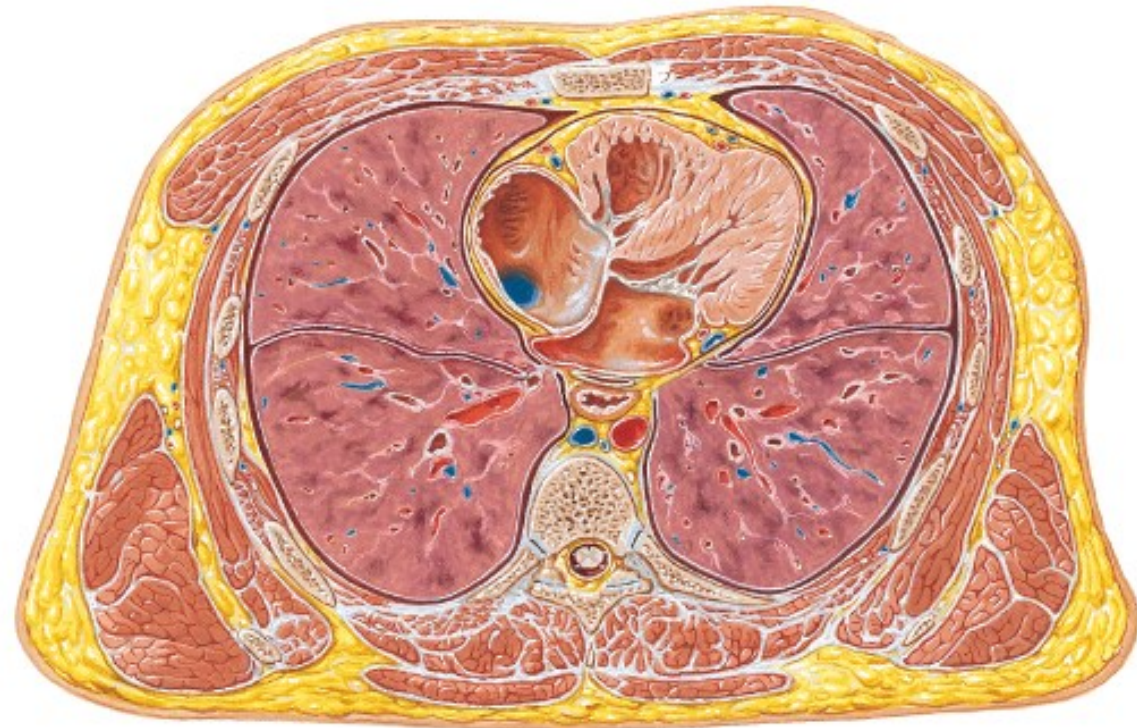
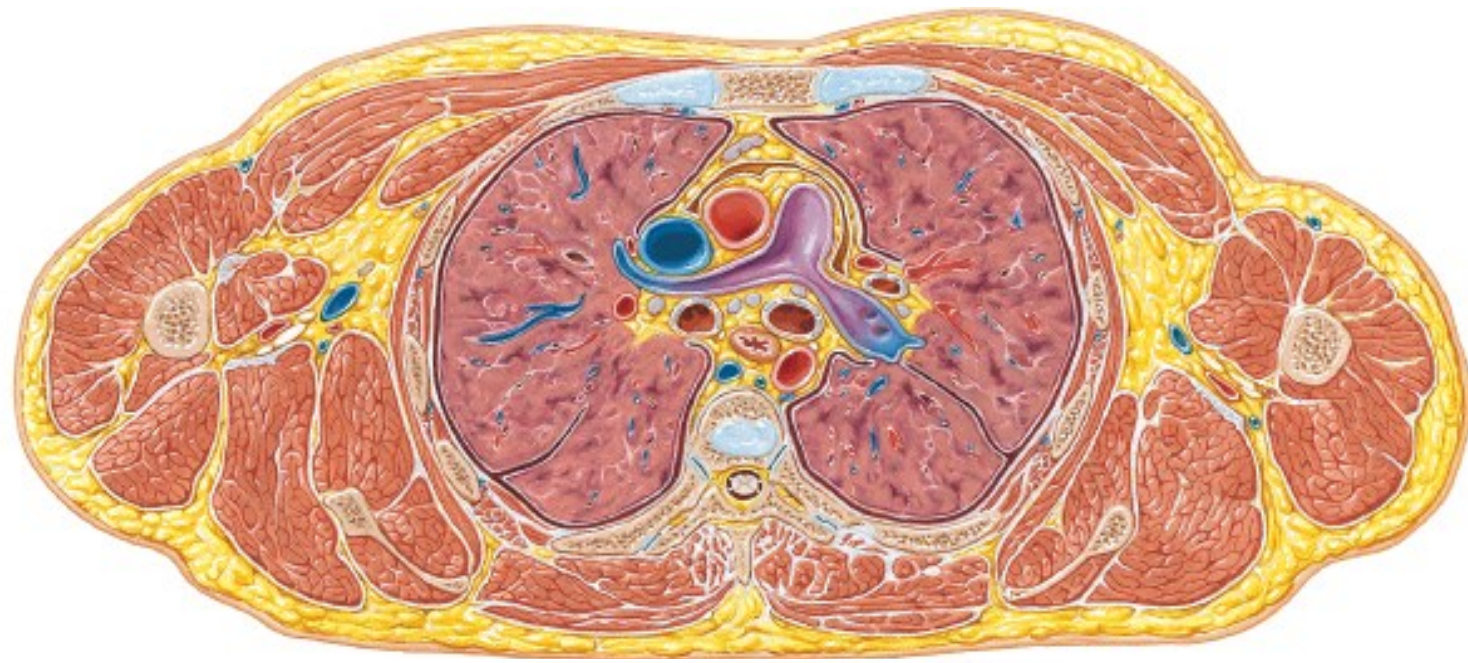


Copyright © 2020 Elsevier Inc. All rights reserved.











Imágenes obtenidas de:

1. Drake R: *GRAY Anatomía para estudiantes*. Elsevier
2. Gilroy A. *Atlas of Anatomy*. Thieme
3. Kopf-Maier P. *Atlas de Anatomía de Wolf Heidegger*. Marban
4. Netter F. *Atlas de Anatomía*. Elsevier
5. Platzer W. *Pernkopf Anatomía*. Marbán